



LUND UNIVERSITY

Osteochondritis dissecans of the hip.

Lindén, B; Jonsson, Kjell; Redlund-Johnell, Inga

Published in:
Acta Radiologica

DOI:
[10.1034/j.1600-0455.2003.00020.x](https://doi.org/10.1034/j.1600-0455.2003.00020.x)

2003

[Link to publication](#)

Citation for published version (APA):

Lindén, B., Jonsson, K., & Redlund-Johnell, I. (2003). Osteochondritis dissecans of the hip. *Acta Radiologica*, 44(1), 67-71. <https://doi.org/10.1034/j.1600-0455.2003.00020.x>

Total number of authors:
3

General rights

Unless other specific re-use rights are stated the following general rights apply:

Copyright and moral rights for the publications made accessible in the public portal are retained by the authors and/or other copyright owners and it is a condition of accessing publications that users recognise and abide by the legal requirements associated with these rights.

- Users may download and print one copy of any publication from the public portal for the purpose of private study or research.
- You may not further distribute the material or use it for any profit-making activity or commercial gain
- You may freely distribute the URL identifying the publication in the public portal

Read more about Creative commons licenses: <https://creativecommons.org/licenses/>

Take down policy

If you believe that this document breaches copyright please contact us providing details, and we will remove access to the work immediately and investigate your claim.

LUND UNIVERSITY

PO Box 117
221 00 Lund
+46 46-222 00 00

OSTEOCHONDRITIS DISSECANS OF THE HIP

B. LINDÉN¹, K. JONSSON² and I. REDLUND-JOHNELL³

¹Department of Orthopedic Surgery, Höglunds Hospital, Eksjö, ²Center for Medical Imaging and Physiology, University Hospital, Lund, and ³Department of Diagnostic Radiology, MAS University Hospital, Malmö, Sweden.

Abstract

Purpose: To investigate the clinical and radiological characteristics of osteochondritis dissecans (OD) of the hip and the outcome of this condition after treatment.

Material and Methods: Twelve male and 3 female patients with OD were retrospectively studied. Six patients had a history of Legg-Calvé-Perthes disease (LCPD) and among them 2 also had had a trauma to the hip. A further 5 had had trauma and 1 a developmental dislocation of the hip (DDH). The remaining 3 patients had no history of previous hip disease or trauma. All patients were examined with plain radiography, 7 with MR, 3 with CT and 2 with hip arthrography.

Results: All OD lesions were detected at plain radiography, and most of them were located near the fovea. At MR the lesions had low signal intensity at T1-weighted sequences, and 6/7 had edema or fluid collection in or adjacent to the lesion on T2-weighted sequences. The early treatment in 7 patients was surgery, 2 had had conservative treatment and 6 no treatment. At follow-up 12 years after radiological diagnosis, 5 patients had hip arthrosis, 4 of whom were treated with arthroplasty. All but 3 had reduced hip rotation and all but 2 (with arthroplasty) had load pain. Three of the patients with earlier surgery had not developed arthrosis.

Conclusions: OD lesions are usually well seen with plain radiography. There is a great risk of developing early arthrosis and it seems that early surgery is connected with arthrosis development. Thus only symptomatic treatment is recommended.

Key words: Hip joint, osteochondritis dissecans; Legg-Calvé-Perthes disease; MR imaging.

Correspondence: Bjarne Lindén, Valbäcksv. 27, SE-575 36 Eksjö, Sweden.
FAX +46 381 535 54.
E-mail: Roglandets.halsa.fritid@telia.com

Accepted for publication 24 October 2002.

Osteochondritis dissecans (OD) is defined as a condition where a fragment of articular cartilage together with subchondral bone becomes separated partly or completely from the joint surface (1, 4). The borderline between OD and osteochondral fractures is not well defined (9).

OD of the hip is a rare condition. Most reports deal with OD cases secondary to Legg-Calvé-Perthes disease (LCPD) (2, 3, 5–8, 10–14, 16, 18, 19). However, we have seen cases without any signs of previous LCPD but with or without trauma in their medical histories. Little is known about the natural cause of OD in the hip.

The purpose of the present study was to investigate the clinical and radiological characteristics and outcome of this condition in the hip.

Material and Methods

In 1998 we wrote letters to all radiological departments in Sweden and asked for cases of proven or suspected OD of the hip in their files. There were no restrictions concerning age at onset of symptoms. The suspicion of OD was founded on radiological criteria, i.e., loose bodies or a defect of the femoral head with or without a bony body in the defect

found with radiography, CT or MR. Most radiological departments do not have systematic diagnostic records, so in fact the outcome depended on whether any of the staff members had a personal experience of OD cases. We received answers from only 10 of 93 departments. The radiographic examinations of the suspected cases were collected and reviewed (K.J. and I.R.J.). Altogether, 22 cases were submitted, but 7 were excluded because they did not fulfill the criteria of OD. The material finally consisted of 15 patients with radiological signs of OD. A follow-up examination was performed by one of the authors (B.L.). All previous details of the lesions were registered from the hospital records. Special attention was paid to early trauma or disease of the hip.

All 15 patients had been examined with plain radiography, 7 with MR, 3 with CT and 2 with hip joint arthrography.

There were 12 male and 3 female patients. The median age at the first symptom was 18 (6–49) years, the median age at the first radiographic examination was 20 (1–45) years and the median age at the follow-up 32 (16–52) years, and follow-up length from the first radiographic examination was 12 (1–37) years. The right hip was affected in 8 cases and the left in 7.

Seven of our 15 patients had a previous trauma to the hip. The trauma was often mild, i.e., a fall on the hip in connection with sports activities which had not been medically treated. One patient was as a new-born baby treated in von Rosen-splint because of developmental dislocation of the hip (DDH). Six patients had sustained LCPD and later developed OD in the hip. Two patients had both LCPD and trauma in their medical histories. Three patients had neither history of previous hip disease nor trauma.

Results

All osteochondritic lesions were located in the superior-anterior part of the femoral head. In most

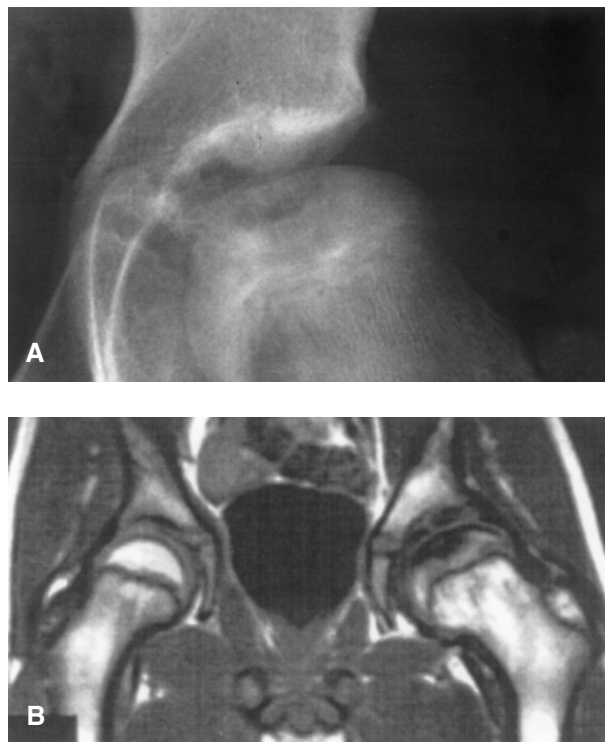


Fig. 1. Patient 10 at age 12. OD after LCPD. A) A.p. view. A defect in the left femoral head is seen. B) MR with T1-weighted coronal section through both hip joints. The lesion in the left femoral head has low signal. The lesion appears larger than on radiography, probably due to edema around the lesion.

cases the lesion was located adjacent to the fovea of the femoral head. In 1 patient the lesion extended to the weight-bearing surface of the femoral head.

In all 15 patients the lesion was seen as an excavation of the femoral head, in 4 best seen with the Lauenstein view (Figs 1 and 2). The lesions measured from 5 mm in diameter up to 30 × 15 mm in one view. Bony bodies were seen in these excavated lesions in 9 patients. Loose bodies were seen on plain radiographs outside the lesion in 2 patients. These bodies were verified with CT. In 1 patient

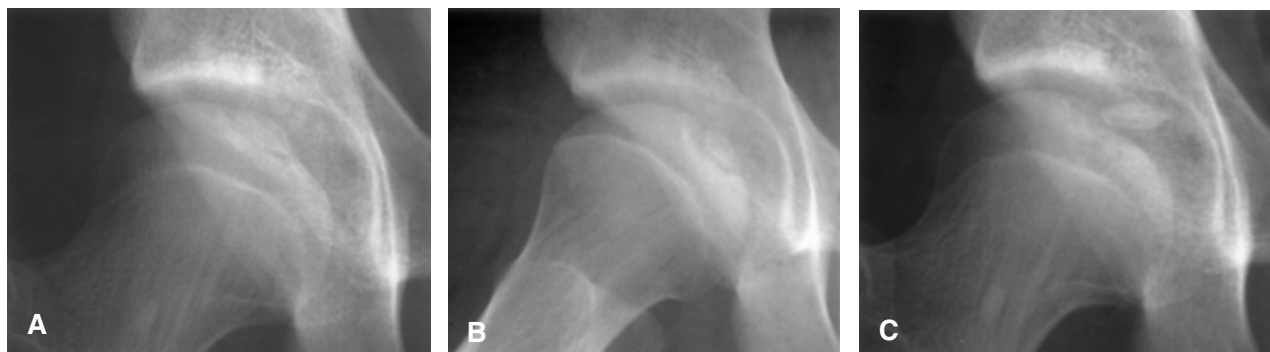

Fig. 2. Patient 5. OD after trauma. A) A.p. view at age 16. B) Lauenstein view at age 16. The bony fragment is better outlined in this view compared to the a.p. view. C) At age 18, the bony body has dislocated from its position at the bottom of the lesion.

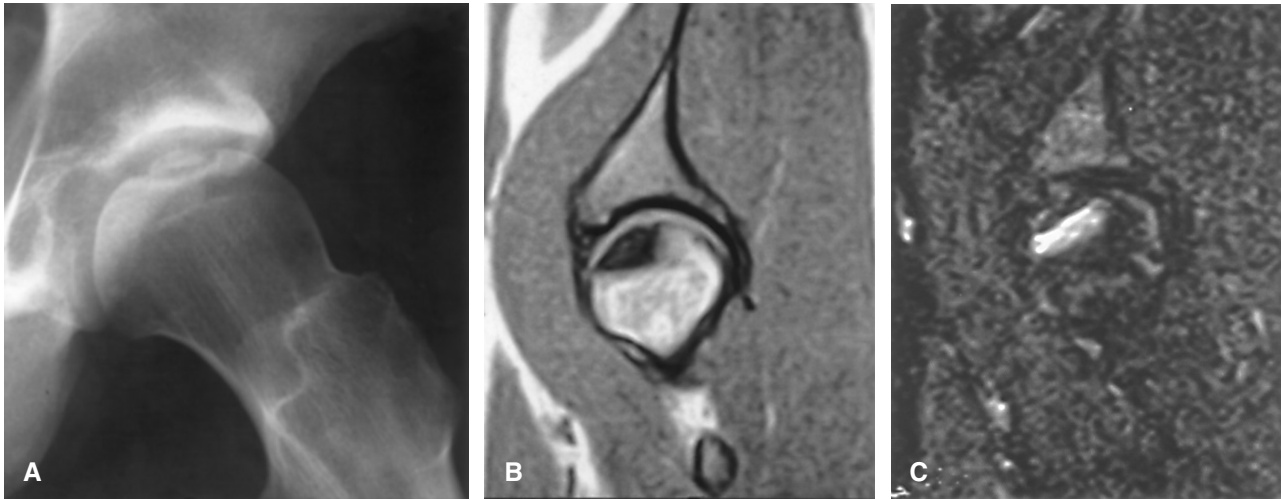

Fig. 3. Patient 1. A) Lauenstein view of the left hip at age 18. B) and C). MR at age 22. T1-weighted sagittal view in (B) shows low signal intensity, while the STIR sequence (C) shows marked edema in and around the lesion.

a bony body within the excavation dislocated slightly at a follow-up examination, indicating that the bony body was or had become loose (Fig. 1).

On MR all 7 lesions had low signal intensity on T1-weighted sequences (Figs 1 and 3). Only in 1 patient was a cartilage defect found adjacent to the lesion, while all the other patients had intact cartilage over the lesion. Edema or fluid collections were seen in or around the lesions in 6 patients (Fig. 3). In the 7th patient the examination did not allow evaluation concerning edema or fluid. In 3 patients a low-signal bony body was seen in the lesion, indicating necrotic bone.

Arthrography of the hip had been performed in 2 patients. In 1 patient, the cartilage over the lesion was thin, while the cartilage was normal in the other patients. Neither cartilage defect nor leakage of contrast medium into the lesions was found.

The follow-up examination comprised a review of present symptoms, range of motion and review of treatment (Table).

Surgery of the hip had been performed in 7 patients, such as drilling from the greater trochanter alone (1 patient) or in combination with nailing, excision of the lesion, periosteal transplantation, removal of free bodies or rotational osteotomy, all in different combinations and in 4 patients more than once. Two of these multioperated patients developed arthrosis of the hip, 1 was treated with arthroplasty at age 29, while 1 has clear arthrosis but has not yet (2002) been operated with arthroplasty. Two multioperated patients had no arthrosis. Two patients with a single operation developed arthrosis and were treated with arthroplasty. Two patients only had conservative treatment in the form

of analgesics and/or physiotherapy. One of these 2 patients had physiotherapy as a young boy but at the age of 52 he got an arthroplasty of the affected hip. The other patient had no signs of arthrosis. Of our 15 patients, 6 received no treatment. At follow-up none of these patients had developed arthrosis.

Thus, arthrosis was the long-term result in 5 patients, 4 of them previously subjected to hip surgery. Of those patients without arthroplasties, none was free from symptoms. They all had pain, mostly when walking. Normal range of motion was recorded in 3 patients, the rest had reduced rotation of the hip.

Discussion

Little is known about OD in the hip, especially the long-term follow-up. OD is a process that leads to demarcation of a relatively small piece of bone and overlying cartilage. The etiology is still unclear. However, when this condition appears in the hip, according to the literature, it is most often secondary to LCPD (2, 5–8, 11, 12, 14–16).

In this retrospective study the diagnosis was confirmed by early radiography. Nine of our 15 patients had no history of LCPD. We believe that OD in the hip can exist as a condition without any connection to LCPD. However, mild forms of LCPD may exist with no clinical suspicion in childhood. In such cases LCPD may heal with normal shape of the femoral head, but a small fragment may remain, later diagnosed as OD. Trauma and unknown etiology have been described (9, 18)

A number of disorders can precede OD in the hip leading to disruption of the normal vascularity of the femoral head, especially after LCPD. The frequency

Table
Clinical data for 15 patients with osteochondritis dissecans of the hip

Sex/ side	Hip disorder	Age span (and length) of radiographic follow-up, years	Early treatment	Symptoms at follow-up	Arthrosis	Late arthroplasty	
6	M/R	LCPD	6–30 (24)	Drilling Nailing Excision	Load pain	Yes	0
11	F/L	LCPD	7–29 (22)	Excision of nest and loose body	Load pain	Yes	Arthroplasty at age 29
7	M/R	Overturn motor cycle age 15	49–51 (2)	Drilling	0	Yes	Arthroplasty at age 51
13	M/L	Minor trauma goalkeeper	45–68 (23)	Osteotomy	–	Yes	Arthroplasty at age 68. (Dead)
9	F/R	LCPD	25–36 (11)	Drilling Periost transplant Excision	Load pain Locking	0	0
12	M/L	Fall from 3 m at age 12 + LCPD	1–37 (36)	Drilling	Load pain	0	0
15	M/L	LCPD	6–34 (28)	Osteotomy Excision	Load pain	0	0
3	M/R	Football trauma	26–52 (26)	Conservative	0	Yes	Arthroplasty at age 52
8	F/R	DDH	21–27 (6)	Conservative	Load pain	0	0
1	M/L	0	19–20 (1)	0	Load pain	0	0
2	M/R	0	18 Dead	0	–	0	0
4	M/R	0	30–34 (4)	0	Load pain	0	0
5	M/R	Fall from bike age 3	14–16 (2)	0	Load pain	0	0
10	M/L	LCPD + fall at handball	6–18 (12)	0	Load pain	0	0
14	M/L	Minor football trauma	26–27 (1)	0	Load pain	0	0

LCPD = Legg-Calvé-Perthes disease. DDH = Developmental dislocation of the hip.

of OD after LCPD is estimated to 3.5–5.8% (2, 12, 16). OD has also been described following treatment of congenital hip dislocation (3, 18) and we have a further case in our material. Other causes of OD in the hip can be previous infection, especially tuberculosis (19) or be a familiar condition (13).

The etiology of OD is thus unclear and multifactorial. Trauma can be a causal factor, as pointed out by previous authors (9, 12, 17). In our series, 7 patients had a history of trauma in their records, often in connection with sports. Two of these patients also had LCPD, but in the remaining 5 patients we found no other explanation for OD than trauma.

Some authors (5, 7, 8, 16) have pointed out that all their patients were males. They also observed that the lesion may remain silent or cause minimal symptoms for many years. We cannot fully support those statements, as we had 3 females in our series.

Radiological examination usually reveals a “nest” with a bony body (Figs 1–3). With the deformed femoral head after LCPD it may be difficult to see the lesion, and CT is of value for confirmation of a loose body. With plain radiography the Lauenstein

view proved to be of value for diagnosis in several patients.

The MR examinations disclosed fluid or edema in or around the lesions in 6 of 7 hips. This indicates that there is a potential risk of loosening of a bony body in the lesion, although only 1 patient showed a cartilage defect adjacent to the lesion. This supports the statement that the lesion may be silent for a long time. However, with fluid and/or edema adjacent to the lesion the cartilage may be vulnerable to a mild new trauma where an underlying bony body is set loose. The MR findings are non-specific and some of our refused cases had a similar MR finding, but no excavation or bony body seen at radiography. The finding in those cases may represent a localized osteonecrosis of the femoral head, without OD.

There is one interesting observation in our series that may be of importance. Most lesions were located adjacent to the fovea of the femoral head. This may indicate an early vascular disturbance from the artery of ligamentum teres to the femoral head. This has not been noted in previous reports, but the finding is similar to the illustrations in the

report from ROWE et al. (16). Most cases in previous reports have had fairly advanced LCPD deformity of the femoral heads, often with involvement of the weight-bearing joint surface.

We have not seen spontaneous healing of OD in the hip as has been reported in an earlier paper (3), but postoperative fusion of a bony body at the bottom of the lesions was found in 1 patient in our series. This may be regarded as healing. Concerning treatment, some authors advocate surgery in the form of drilling, pinning, excision, etc. (2). Others recommend surgery only when there is locking or catching (3, 5). Anti-inflammatory drugs are often used in the short term.

All our patients, except 2 operated with arthroplasty, had pain when walking and all except 3 had reduced rotation of the hip at follow-up, regardless of previous treatment. The value of the suggested surgical treatment modalities thus seems to be limited to prevent arthrosis in the long run. Three patients with earlier surgery did not develop arthrosis.

On the basis of this series of OD of the hip, only symptomatic conservative treatment seems to be justified as the first line. When locking or catching occurs we recommend, in concordance with other authors (5, 12), that the loose bodies should be removed. In the long run there is a high risk that arthrosis will occur regardless of treatment.

ACKNOWLEDGMENT

We would like to express our sincere gratitude to Dr. K.-B. Ylverton Tegner for providing us with several cases.

REFERENCES

1. Aichroth P. Osteochondritis dissecans of the knee. *J. Bone Joint Surg. Br.* 1971; 53B: 440.
2. Bowen JR, Kumar VP, Joyce JJ, Bowen JC. Osteochondritis dissecans following Perthe's disease. *Clin. Orthop.* 1986; 209: 49.
3. Buxton RA, McCullough CJ. Healing of osteochondritis dissecans following congenital dislocation of the hip. *Clin. Orthop.* 1980; 147: 157.
4. Fairbanks HAT. Osteo-chondritis dissecans. *Br. J. Surg.* 1933; 21: 67.
5. Filipe G, Roy-Camille. MY, Carlioz H, Cogan D. L'ostéochondrite disséquante de la hanche dans la maladie de Legg-Perthes-Calvé. *Rev. Chir. Orthop.* 1985; 71: 55.
6. Goldman AB, Hallel T, Salvati EM, Freiburger RH. Osteochondritis dissecans complicating Legg-Perthes-disease. *Radiology* 1976; 121: 561.
7. Kamhi E, MacEwen D. Osteochondritis dissecans in Legg-Calvé-Perthes disease. *J. Bone Joint Surg.* 1975; 57A: 506.
8. Lahdes-Vasama TT, Lamminen AE, Merikanto EOJ, Peltonen JI. Le cartilage de croissance dans l'ostéochondrite primitive de hanche: étude prospective en IRM. *Rev. Chir. Orthop.* 1995; 81: 395.
9. Lindén B. Osteochondritis dissecans of the femoral condyles. A long-term follow-up study. *J. Bone Joint Surg.* 59A. 769. 1977.
10. Lindholm TS, Österman K, Vankka E. Osteochondritis dissecans of elbow, ankle and hip. *Clin. Orthop.* 1980; 148: 245.
11. Morris ML, McGibbon KC. Osteochondritis dissecans following Legg-Calvé-Perthes' disease. *J. Bone Joint Surg.* 1962; 44B: 562.
12. Österman K, Lindholm TS. Osteochondritis dissecans following Perthes' disease. *Clin. Orthop.* 1980; 152: 247.
13. Paes RA. Familial osteochondritis dissecans. *Clin. Radiol.* 1989; 40: 501.
14. Pantazopoulos T, Matsoukas J, Gavras M et al. Osteochondritis dissecans following coxa plana. *Acta Orthop. Scand.* 1972; 43: 532.
15. Ratcliff AHC. Osteochondritis dissecans following Legg-Calvé-Perthes' disease. *J. Bone Joint Surg.* 1967; 49B: 108.
16. Rowe SM, Kim HS, Yoon TR. Osteochondritis dissecans in Perthes' disease. *Acta Orthop. Scand.* 1989; 60: 545.
17. Smillie JS. Osteochondritis dissecans: loose bodies in joints. Etiology, pathology, treatment. Edinburgh: E & S Livingstone, 1960.
18. Weissman SL. Osteochondritis dissecans following congenital dislocation of the hip. *J. Bone Joint Surg.* 1974; 56B: 454.
19. Wood JB, Klassen RA, Peterson HA. Osteochondritis dissecans of the femoral head in children and adolescents: A report of 17 cases. *J. Pediatr. Orthop.* 1995; 15: 313.