



LUND UNIVERSITY

beta-lactamase-producing nontypeable *Haemophilus influenzae* fails to protect *Streptococcus pneumoniae* from amoxicillin during experimental acute otitis media

Westman, E; Lundin, S; Hermansson, Ann; Melhus, Åsa

Published in:
Antimicrobial Agents and Chemotherapy

DOI:
[10.1128/AAC.48.9.3536-3542.2004](https://doi.org/10.1128/AAC.48.9.3536-3542.2004)

2004

[Link to publication](#)

Citation for published version (APA):

Westman, E., Lundin, S., Hermansson, A., & Melhus, Å. (2004). beta-lactamase-producing nontypeable *Haemophilus influenzae* fails to protect *Streptococcus pneumoniae* from amoxicillin during experimental acute otitis media. *Antimicrobial Agents and Chemotherapy*, 48(9), 3536-3542. <https://doi.org/10.1128/AAC.48.9.3536-3542.2004>

Total number of authors:
4

General rights

Unless other specific re-use rights are stated the following general rights apply:
Copyright and moral rights for the publications made accessible in the public portal are retained by the authors and/or other copyright owners and it is a condition of accessing publications that users recognise and abide by the legal requirements associated with these rights.

- Users may download and print one copy of any publication from the public portal for the purpose of private study or research.
- You may not further distribute the material or use it for any profit-making activity or commercial gain
- You may freely distribute the URL identifying the publication in the public portal

Read more about Creative commons licenses: <https://creativecommons.org/licenses/>

Take down policy

If you believe that this document breaches copyright please contact us providing details, and we will remove access to the work immediately and investigate your claim.

LUND UNIVERSITY

PO Box 117
221 00 Lund
+46 46-222 00 00

β -Lactamase-Producing Nontypeable *Haemophilus influenzae* Fails To Protect *Streptococcus pneumoniae* from Amoxicillin during Experimental Acute Otitis Media

Eva Westman,^{1*} Susanne Lundin,² Ann Hermansson,³ and Åsa Melhus²

Department of Oto-Rhino-Laryngology, Umeå University Hospital, Umeå,¹ Department of Medical Microbiology, Malmö University Hospital, Malmö,² and Department of Oto-Rhino-Laryngology, Lund University Hospital, Lund,³ Sweden

Received 8 July 2003/Returned for modification 26 November 2003/Accepted 24 May 2004

Acute otitis media (AOM) is the most common reason for outpatient antimicrobial therapy. Mixed infections pose a potential problem, since the first-line drug used for the treatment of AOM, amoxicillin, can be neutralized by β -lactamase-producing pathogens of the upper respiratory tract. To study the effects of a 5-day course of amoxicillin on a mixed middle ear infection, rats were challenged with *Streptococcus pneumoniae* alone or in combination with β -lactamase-producing nontypeable *Haemophilus influenzae*. Amoxicillin was introduced at the clinical peak of the infection. Local and systemic changes were monitored by otomicroscopy, bacterial culture, and analysis of histological changes and the expression of the transforming growth factor beta (TGF- β) gene. β -Lactamase-producing *H. influenzae* did not demonstrate an ability to protect *S. pneumoniae*. Amoxicillin eradicated the pneumococci in all treated animals but increased to some degree the ability of *H. influenzae* to persist at the site of infection. Thus, only an insignificant acceleration of the resolution of the AOM caused by a mixture of pathogens was observed during treatment. Moderate to major morphological changes could not be avoided by treatment of the mixed infections, but a slight downregulation of TGF- β expression was observed. In contrast to infections caused by a single pathogen, the mixed infections induced white plaques in the tympanic membrane at a remarkably high frequency independent of treatment. These experimental findings constitute support for further studies of antimicrobial drugs and AOM caused by bacteria with and without mechanisms of antibiotic resistance.

Acute otitis media (AOM) is one of the most common bacterial infections in pediatric patients. The predominant pathogens causing AOM are *Streptococcus pneumoniae*, *Haemophilus influenzae*, and *Moraxella catarrhalis* (22). Of these three agents *S. pneumoniae* has the lowest spontaneous clearance rate, and it is the microorganism most often associated with severe and fatal complications of AOM (1, 18, 25). As a consequence, the antimicrobial drug used for the treatment of AOM in routine practice must have a spectrum which covers this bacterium to be efficacious.

Hitherto, amoxicillin has been the first-line therapeutic choice in several countries (10, 14). Its pharmacokinetic and pharmacodynamic profiles are attractive, but its utility is sometimes compromised by an increasing proportion of β -lactamase-resistant isolates. About 14 to 65% of the nontypeable (NT) *H. influenzae* isolates from the middle ear produce β -lactamase (16, 20, 22, 24). For *M. catarrhalis* isolates the frequency is virtually 100% (20, 22, 24). Because of the high rate of β -lactamase production in these two species, the use of β -lactamase-resistant drugs such as macrolides and trimethoprim-sulfamethoxazole is often recommended (9). However, many of these antibiotics are not entirely effective as empirical treatment for AOM, especially macrolides for the treatment of infections caused by NT *H. influenzae*, and they may increase

the rates of nasopharyngeal carriage of resistant organisms and promote their spread (7, 8, 28).

It has been suggested that β -lactamases not only protect the producing bacteria themselves but also frustrate the therapy of concomitant infections caused by penicillin-susceptible respiratory tract pathogens with penicillins, resulting in a sheltering effect. There is experimental evidence for such a sheltering effect for *Staphylococcus aureus* in group A beta-hemolytic streptococcal abscesses (3) and *M. catarrhalis* in pneumococcal pneumonia (21). *S. pneumoniae* and NT *H. influenzae* coexist in up to 10% of the samples of middle ear fluid (16). The activity of amoxicillin against the pneumococcus in a mixed infection could thereby be threatened.

In order to explore a possible sheltering effect for β -lactamase-producing NT *H. influenzae* in amoxicillin-treated pneumococcal AOM, a well-established rat model of AOM was used. Apart from the clinical and bacteriological outcomes, protection against reinfection, morphological changes, and expression of transforming growth factor beta (TGF- β) were also analyzed.

MATERIALS AND METHODS

Animals and surgical procedures. Healthy male Sprague-Dawley rats (weight, 250 to 350 g) were used. The study protocol was approved by the Ethics Committee of Lund University, and the animals were managed as described previously (31). During anesthesia induced with chloralhydrate (Apoteksbolaget, Malmö, Sweden) and after a blunt dissection of the soft tissue in the neck, approximately 50 μ l of a bacterial suspension was inoculated directly into the middle ear cavity through the bony wall of the bulla. The tympanic membrane was left intact, and correct inoculation was verified with an otomicroscope.

* Corresponding author. Mailing address: Department of Oto-Rhino-Laryngology, Sundsvall Hospital, S-85186 Sundsvall, Sweden. Phone: 46 60 181000. Fax: 46 60 182294. E-mail: eva.borjesdotter.westman@lvn.se.

TABLE 1. Experimental design

| Animal group | Strain(s) ^a used for challenge | Amoxicillin treatment | Strain used for rechallenge | Evaluation |
|--------------|---|-----------------------|-----------------------------|---|
| A (n = 20) | Pnc | + | Pnc (n = 4) | Otomicroscopy on days 3–8, 28, 32, and 56; morphological changes on days 3, 8, and 56; middle ear fluid cultures |
| B (n = 24) | Pnc, NTHi | + | Pnc (n = 8) | Otomicroscopy on days 3–8, 28, 32, and 56; morphological changes on days 3, 8, and 56; serum amoxicillin concentration determination; cytokine gene expression on day 56; middle ear fluid cultures |
| C (n = 24) | Pnc, NTHi | – | Pnc (n = 8) | Otomicroscopy on days 3–8, 28, 32, and 56; morphological changes on days 3, 8, and 56; cytokine gene expression on day 56; middle ear fluid cultures |
| D (n = 4) | Pnc | – | – | Otomicroscopy on days 3, 8, and 28; middle ear fluid cultures |
| E (n = 6) | NTHi | – | – | Otomicroscopy on days 3, and 8; middle ear fluid cultures |

^a Pnc, *S. pneumoniae*; NTHi, NT *H. influenzae*.

Bacteria and media. Two bacterial strains isolated at the Department of Medical Microbiology at Malmö University Hospital were used: *S. pneumoniae* type 3 (amoxicillin MIC and minimal bactericidal concentration [MBC], 0.032 and 0.125 mg/liter, respectively; ampicillin MIC and MBC, 0.016 and 0.064 mg/liter, respectively) and *H. influenzae* strain 3144 biotype II (amoxicillin MIC and MBC, 128 and >256 mg/liter, respectively; ampicillin MIC and MBC, 32 and >256 mg/liter, respectively). The MICs and MBCs were determined by Etest, according to the instructions of the manufacturer (Biodisk AB, Solna, Sweden), and β -lactamase production in strain 3144 was detected with the chromogenic cephalosporin nitrocefin (Biodisk AB, Solna, Sweden). A PCR was carried out by the method described by Falla et al. (13) to screen for encapsulation of the *H. influenzae* strain. The strain was found to be genetically NT.

The bacteria were stored at -70°C , and all cultures were initially inoculated from these frozen stocks onto solid medium. The media used were chocolate and blood agars and brain heart infusion broth (Difco Laboratories, Detroit, Mich.) supplemented with NAD and hemin (Sigma, St. Louis, Mo.), each at 10 mg/liter.

The inocula for middle ear challenge were prepared as described earlier (30). Early-stationary-phase NT *H. influenzae* was used at a concentration of 10^8 CFU/ml, and *S. pneumoniae* was used at a concentration of 10^7 CFU/ml. The viable counts of the bacterial suspensions were determined at the time of challenge. All cultures were grown at 37°C in an atmosphere with 5% CO_2 .

Experimental design. A total of 78 animals were challenged with *S. pneumoniae*, NT *H. influenzae*, or a combination of both bacteria. See Table 1 for details of the experimental design. Forty-four animals were treated, while the remaining 34 animals served as controls.

To investigate if the intense inflammatory reaction induced by the mixed infection would disturb the protection against reinfection that normally develops after a primary infection, a rechallenge was performed 1 month after the initial inoculation. A total of 20 animals from groups A to C were challenged in the left, contralateral middle ear with the pneumococcal strain. At this rechallenge, four unchallenged animals were added as controls to ensure the presence of an established infection.

From day 0 to day 56 after challenge the animals were repeatedly inspected under an otomicroscope (see Table 1 for the exact days). The status of the tympanic membrane and the quantity and quality of the effusion behind the membrane were evaluated. The otomicroscopic findings were categorized as follows: opaque effusion, turbid effusion behind the entire tympanic membrane, turbid effusion behind the pars flaccida, and clear or no effusion. A team member blinded to the identity of each animal carried out the inspections. The diagnosis of AOM required direct visualization of opaque fluid behind the tympanic membrane with or without a vascular reaction. Bacterial samples were collected from the external ear canals of animals with either spontaneously perforated tympanic membranes or bilateral infections (day 3; $n = 25$) or by inserting a swab directly into the middle ear cavity after the bulla was opened (day 8; $n = 40$). The swab was streaked directly onto chocolate agar. All cultures of specimens from middle ears with mixed infections with no visible growth of pneumococci but with abundant or moderate growth of NT *H. influenzae* were subcultured on blood agar.

For histological studies the animals were killed on day 3 (groups A and B; $n = 3$ animals each), day 8 (groups A to C; $n = 3$ animals each), and day 56 (groups A to C; $n = 6, 4,$ and 5 animals, respectively). The bullae were removed and transferred to vials for fixation in 3% glutaraldehyde solution in 0.1 M sodium cacodylate buffer supplemented with 4% polyvinylpyrrolidone.

Animals with mixed infections were also killed on day 56 (groups B and C; n

= 8 animals each) to study TGF- β gene expression. The middle ear tissues were removed unilaterally from the right ear, and the samples were immediately frozen in liquid nitrogen and stored at -70°C until analysis.

Treatment and pharmacokinetic studies. Treatment with amoxicillin (Amimox; Tika Läkemedel AB, Lund, Sweden) was introduced on day 3 after the first challenge via the drinking water (250 mg/500 ml, the recommended dose for rats by veterinary standards). Water consumption was measured on a daily basis until day 8, when the antibiotic treatment was discontinued. Water consumption and serum amoxicillin concentrations were monitored more closely in two animals, for which water consumption was registered every hour for a 4-h period. Blood samples were then collected whenever an animal consumed water. The amoxicillin concentrations were measured by the agar disk diffusion method with *Sarcina lutea* (ATCC 9341) as the test strain, and the antibiotic levels were calculated from duplicate assays.

Morphological examination. Tissue samples were collected from two well-defined areas in the middle ear. The areas represented the fossa nasalis and the pars flaccida. After a brief rinse in buffer, the specimens were postfixed for 2 h with 1% OsO_4 in the same buffer and, after another rinse, were dehydrated in increasing concentrations of acetone and embedded in an Epon mixture (POLYBED; Polysciences Inc., Warrington, Pa.). The specimens were sectioned (thickness, 1 μm) for light microscopy and stained with toluidine blue. They were examined under a light microscope at an objective magnification of $\times 40$. A team member who was unaware of the challenge and treatment procedures performed the examination. The degree of inflammation, with emphasis on inflammatory cells, vascular reaction, metaplasia, and epithelial proliferation, was recorded; and the three following categories were defined: no or minor changes, moderate changes, and major changes.

Reverse transcription-PCR. To detect expression of the gene for TGF- β , an anti-inflammatory cytokine which facilitates the anabolic effects of growth factors on tissue repair and whose expression is more pronounced during pneumococcal AOM than during NT *H. influenzae* AOM (32), mRNA was extracted from the frozen middle ear tissue samples with Dynabeads Oligo (dT)₂₅ (DynaL A.S, Oslo, Norway). After elution of the mRNA from the beads, it was reverse transcribed and amplified as described previously (32). The sequences of the primers used to detect the TGF- β gene were 5'-AGCTCCACAGAGAAGAACTGC-3' (sense) and 5'-TCATGTTGGACAACCTGCTCC-3' (antisense). The PCR products were subjected to electrophoresis, and all samples were further analyzed in a competitive PCR assay (32).

The PCR products were quantified by using two different competitors, one for the housekeeping β -actin gene by use of primers with the sequences 5'-TGGA GAAGAGCTATGAGCTGC-3' (sense) and 5'-TCCACACAGAGTACTTGC GC-3' (antisense) and one for the TGF- β gene. The β -actin served as an internal control for total cell mass and mRNA recovery, and the levels of TGF- β expressed were corrected for the β -actin transcript levels in each sample.

Statistical analysis. Fisher's exact test was used for statistical analysis of the rat model studies, and Student's *t* test was used to compare the TGF- β mRNA levels between treated and untreated animals. A difference was considered statistically significant when P was <0.05 .

RESULTS

Clinical findings and protective rate. All animals developed AOM after the first challenge. In 8 (10%) animals the infection progressed into a bilateral middle ear infection on day 4. Four

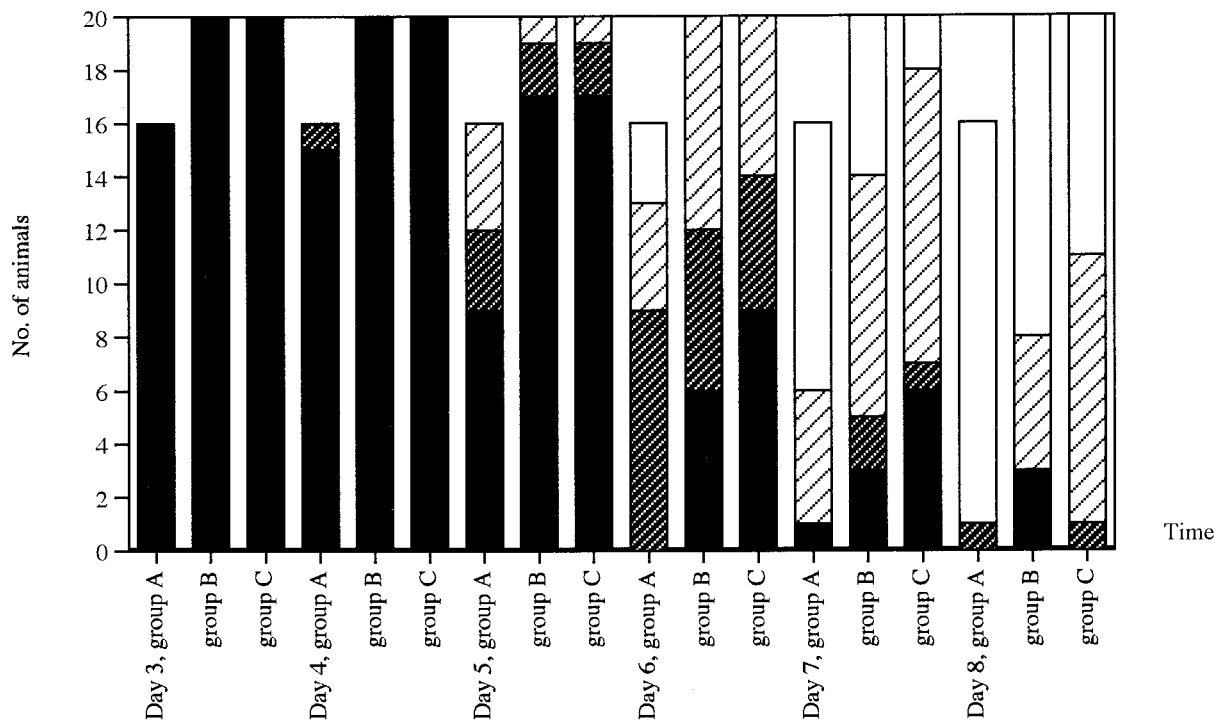


FIG. 1. Otomicroscopic changes in rat middle ears recorded on days 3 to 8 after bacterial challenge. Only the data for animals in groups A to C that were monitored daily are shown. Group A, amoxicillin-treated animals with pneumococcal infection; group B, amoxicillin-treated animals with mixed infection with *S. pneumoniae* and beta-lactamase-producing NT *H. influenzae*; group C, untreated animals with mixed infection with the same bacteria as in group B. ■, opaque effusions; ▩, turbid effusion behind the entire tympanic membrane; ▨, turbid effusion behind the pars flaccida; □, clear or no effusions.

of these animals belonged to untreated group C with mixed infections, whereas the remaining four belonged to either treatment group B with mixed infections ($n = 2$) or group D with untreated pneumococcal infections ($n = 2$). The courses of these contralateral infections were relatively short, and they were resolved on day 7 in all but two animals. These two animals belonged to untreated pneumococcus-infected group D and exhibited opaque effusions behind the tympanic membrane on day 8. Seven animals (9%) developed severe, systemic infections and died. Four of these animals (57%) had bilateral infections. In group A, the deaths ($n = 2$) occurred early and before or just after the antibiotic treatment of the pneumococcal AOM had been initiated, i.e., on days 3 and 4. In group B, which consisted of animals with treated mixed infections, the animals succumbed ($n = 2$) on days 4 and 5, and in group C, which consisted of animals with untreated mixed infections, the animals succumbed on days 4 ($n = 1$) and 6 ($n = 2$). All seven animals were excluded from further studies.

The otomicroscopic aspects of untreated and amoxicillin-treated AOM are shown in Fig. 1. The treatment accelerated the resolution of the infection. The most rapid clearance took place in group A (treated pneumococcal infections), which was significantly faster than that observed in the groups with mixed infections, groups B (treated) and C (untreated), on treatment days 3 to 5, i.e., on days 6 to 8 postinoculation ($P = 0.00001$ to 0.02). On day 8, the last day of treatment, 94% of the infections in group A, 60% of the infections in group B ($P = 0.02$), and 45% of the infections in group C ($P = 0.0002$) had cleared, as determined by otomicroscopy. At no time point were there any

statistically significant differences between the groups with mixed infections, groups B (treated) and C (untreated). The only group in which all animals had a normal status on day 8 was untreated group E, challenged with NT *H. influenzae*. There was, however, no substantial difference between this group and groups B ($P = 0.06$) and C ($P = 0.08$). Opaque effusions could be observed only in animals in group B (treated mixed infections) and group D (untreated pneumococcal infections) after day 7.

The proneness to develop AOM after rechallenge of the left middle ear was similar among animals in groups A to C. The protective rate is presented in Table 2. The otomicroscopic appearance of the right tympanic membrane was also evaluated in these three groups. On day 56, the presence of white plaques in the tympanic membrane was substantial in the right ears of all animals with resolved mixed infections. The plaques extended over both the pars flaccida and the pars tensa of the tympanic membrane, and this was independent of antibiotic therapy. In animals challenged with the pneumococcal strain alone, the white plaques in the right tympanic membrane were limited to the pars tensa. After rechallenge the myringosclerotic-like changes were restricted to the vessel area of the pars tensa in the left ears of animals in all groups.

Antibiotic and bacteriological data. There were no differences in the levels of water consumption between the animal groups, and the treatment was well tolerated. The daily dose of amoxicillin was 58 ± 9 mg/kg of body weight, as deduced from the level of water consumption. Serum amoxicillin concentrations were 4 ± 3 μ g/ml (range, 1.7 to 6.1 μ g/ml).

TABLE 2. Frequency of positive middle ear fluid cultures during primary infection and protective rate after rechallenge

| Animal group | Inoculum ^b | Growth (no. of specimens with growth/total no.) on: | | Protective rate (no. of animals protected/total no. [%]) |
|----------------|-----------------------|---|-------------------------|--|
| | | Day 3 | Day 8 | |
| A ^a | Pnc | — ^c | 0/10 | 2/4 (50) |
| B ^a | Pnc and NTHi | — | 0/11 (Pnc), 5/11 (NTHi) | 5/8 (62) |
| C | Pnc and NTHi | 16/16 (NTHi), 16/16 (Pnc) ^d | 4/10 (Pnc), 1/10 (NTHi) | 4/8 (50) |
| D | Pnc | 3/3 | 3/3 | |
| E | NTHi | 5/6 | 2/6 | |

^a Amoxicillin treated.

^b Pnc, *S. pneumoniae*; NTHi, NT *H. influenzae*.

^c —, prior to the amoxicillin treatment, all animals in group A were included in untreated group D, and all animals in group B were included in untreated group C. The culture results on day 3 for groups A and B can therefore be found only in groups D and C, respectively.

^d For 9 of 16 cultures there was an overgrowth of NT *H. influenzae* on the chocolate agar. The growth of pneumococci in these middle ears could be demonstrated only after subculture on blood agar.

The frequencies of positive middle ear fluid cultures on days 3 and 8 in the various groups are shown in Table 2. On day 3, 96% of the middle ear fluid cultures were positive, and for 56% of the animals with mixed infections, NT *H. influenzae* overgrew the pneumococci. The effect of amoxicillin on pneumococcal growth was significant in both animals with mixed infections and animals with pure pneumococcal infections. None of the specimens from animals in treatment groups A and B yielded growth of pneumococci on day 8, whereas the values for untreated groups C and D were 40% ($P = 0.04$) and 100% ($P = 0.003$), respectively. In contrast to the pneumococci, the β -lactamase-producing NT *H. influenzae* exhibited a slight tendency to persist at the infection site during treatment (Table 2, groups B and C). This tendency was not statistically significant ($P = 0.08$).

Structural observations and expression of TGF- β . The structural changes are summarized in Table 3. On day 3, the specimens were categorized into two groups. In the group with major changes, specimens exhibited a massive inflammatory response with abundant inflammatory cells (Fig. 2a). The degree of epithelial proliferation could not be determined due to the inflammatory changes. Sclerosis occurred in one specimen. On day 8, the degree of inflammation had decreased in three animals treated with amoxicillin. All but one of the specimens with mixed infections were assigned to the category with major changes, with numerous inflammatory cells still present. Gland-like formations and polyps in the fossa nasalis extended

into the middle ear cavity in some specimens, and sclerosis occurred. Ciliated cells and goblet cells were increased in number and were also present in the inner epithelium of the pars flaccida. After 56 days, the middle ears of treated animals challenged with *S. pneumoniae* had no or minor changes (Fig. 2b) or moderate changes, whereas the specimens from the groups with mixed infections exhibited moderate changes (Fig. 2c) or major changes (Fig. 2d). The major changes were characterized by extensive alterations in the epithelium in the fossa nasalis, with several newly formed layers of epithelial cells and connective tissue and increased numbers of ciliated and secretory cells. Islands of epithelial cells were observed in subepithelial tissue, and polyps extended into the middle ear cavity. The pars flaccida was thickened, and ciliated cells were present in the inner epithelium. Three of four specimens from the animals with amoxicillin-treated mixed infections (group B) and three of five specimens from the animals with untreated mixed infections (group C) were assigned to this category.

The expression of TGF- β differed between the animal groups with mixed infections. The transcript levels were lower for animals in group B (amoxicillin treated; mean, 25.9 \pm 11.1 fg) than animals in group C (untreated; mean 35.4 \pm 27.5 fg), but the difference was not statistically significant ($P = 0.34$).

DISCUSSION

In vitro and in vivo studies have demonstrated the ability of β -lactamase-producing strains to protect penicillin-susceptible

TABLE 3. Summary of structural changes in pars flaccida and fossa nasalis in relation to time and challenge group^a

| Day | Category | Histological findings | | | | Category assignment by challenge group ^b |
|-----------------|---------------------|-----------------------|------------|--------------------------|-----------------|---|
| | | Inflammatory cells | Metaplasia | Epithelial proliferation | Vessel reaction | |
| 3 (prior to ab) | Moderate changes | ++ | ++ | NA | ++ | A, n = 1/3; B and C, n = 2/3 |
| | Major changes | +++ | ++/+++ | NA | ++ | A, n = 2/3; B and C, n = 1/3 |
| 8 | Moderate changes | + | +/+++ | 0 | + | A, n = 2/3; B, n = 1/3 |
| | Major changes | ++ | ++/+++ | ++ | ++ | A, n = 1/3; B, n = 2/3; C, n = 3/3 |
| 56 | No or minor changes | 0 | 0/+ | 0 | + | A, n = 3/6 |
| | Moderate changes | 0/+ | +/+++ | ++ | ++ | A, n = 3/6; B, n = 1/4; C, n = 2/5 |
| | Major changes | ++ | ++/+++ | ++/+++ | ++ | B, n = 3/4; C, n = 3/5 |

^a Abbreviations 0, no changes; +, minor changes; ++, moderate changes; +++, extensive changes, NA, not applicable; ab, antibiotic treatment.

^b A, *S. pneumoniae* infection and antibiotic treatment; B, *S. pneumoniae* and *H. influenzae* infections and antibiotic treatment; C, *S. pneumoniae* and *H. influenzae* infections and antibiotic treatment. The data (n values) indicate the number of animals in the group/total number of animals.

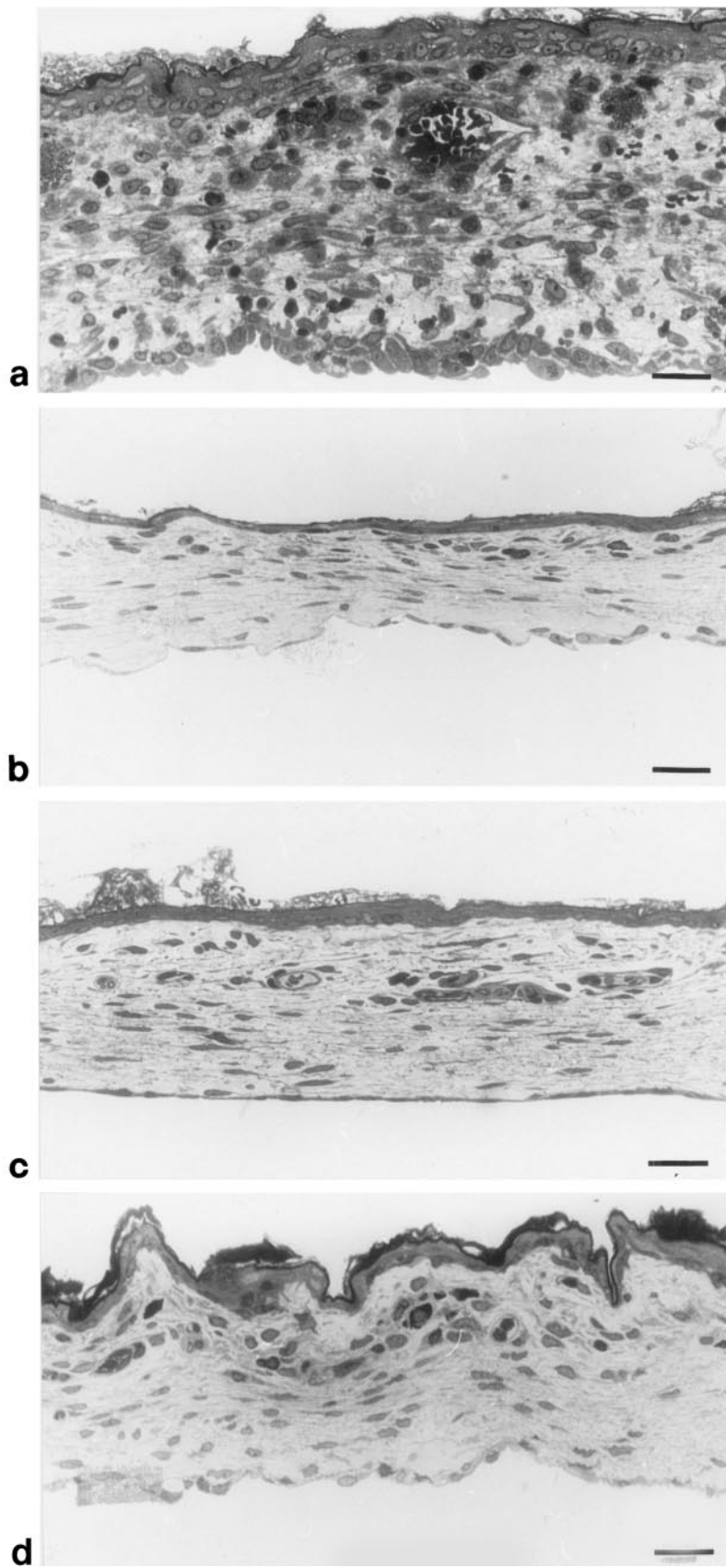


FIG. 2. Light micrographs representing pars flaccida after challenge. (a) major changes prior to treatment on day 3; (b) no or minor changes on day 56 after treatment of pneumococcal infection, (c) moderate changes on day 56 caused by mixed infections; and (d) major changes on day 56 caused by mixed infections. Magnifications, $\times 336$.

bacteria in localized mixed infections at various sites (3, 4, 19, 21). In contrast to that work, the present study could not demonstrate this phenomenon. Despite the presence of NT *H. influenzae* cells, which produced sufficient amounts of β -lactamase to protect themselves, the pneumococci were successfully eradicated from the rat middle ear by the amoxicillin treatment. These findings indicate that the degrading effect may vary with the type of β -lactamase and the microorganism producing the β -lactamase. Thus, the presence of β -lactamase-producing upper respiratory tract pathogens or commensal organisms in polymicrobial infections or in the immediate surroundings does not automatically render penicillins ineffective against otherwise susceptible bacteria. Results similar to the present results have been demonstrated in a surgical animal model by Renneberg and Walder (33) and indirectly in a clinical study by Joki-Erkkilä et al. (23).

Although *H. influenzae* did not frustrate the amoxicillin treatment of *S. pneumoniae* infections, the inadequate antibiotic coverage against this microorganism resulted in moderate to major structural changes in the middle ear mucosa. These changes did not affect the protective rate, but in the majority of the group B animals with treated mixed infections the changes were more extensive than those usually observed after untreated AOM induced by NT *H. influenzae* (31). The substantial myringosclerotic-like changes found in all animals with mixed infections, independent of treatment, also indicate that considerable injury to the tympanic membrane was caused by the combination of gram-positive and gram-negative bacteria. The development of white plaques in both the pars flaccida and the pars tensa in 100% of the animals has not previously been observed in this model of AOM. The fact that the first case of sclerosis was recorded on day 3 and the fact that the antibiotic treatment did not reduce the frequency of white plaques in the tympanic membrane, their distributions, or the morphological alterations to the mucosa suggest that the initial tissue injury was established early during the course of AOM and was probably established prior to the introduction of antibiotic treatment.

How the two bacterial species may interact with each other in the middle ear cavity is not known, but Elliott and coworkers (11) have shown that the relationship can be close and of a parasitic or symbiotic nature. In the present study, the overgrowth of NT *H. influenzae* in the middle ear tissue cultures on day 3 and the shift from early to late deaths when NT *H. influenzae* was added to the inoculum support the idea of a bacterial interaction or local competition. Despite a possibly competitive situation that might limit bacterial expansion to some extent, a mixed infection in the middle ear appeared to increase the strain on host tissues and defenses. Mixed infections are most common in AOM patients with treatment failure (16). To avoid long-standing mixed infections, measures in the form of tympanocentesis and a change of treatment to an antibiotic with a broader spectrum of activity should probably be taken without delay in suspected cases.

The widespread use of antibiotics for the treatment of AOM has lately led to prevalent β -lactamase production among the leading gram-negative pathogens of the middle ear, so why insist on using amoxicillin and not amoxicillin-clavulanate (AMC) as the first-line drug? Apart from differences in virulence and spontaneous recovery rates between gram-positive

and gram-negative pathogens, ecological issues must be considered. The impact of AMC on the gastrointestinal flora is not negligible (15, 29), but of more concern is its effect on the nasopharyngeal flora. A wider spectrum of bacteria is eradicated by AMC than amoxicillin (5), and the competitive balance between pneumococci and commensal organisms could thereby be disturbed (17). Cultures of nasopharyngeal specimens from otitis-prone children show low numbers of alpha-hemolytic streptococci with activity that interferes with common pathogens that cause otitis (34), and significantly fewer children recently treated with amoxicillin than those treated with AMC have been shown to be prone to otitis (2). Furthermore, in the work of Joki-Erkkilä et al. (23), the presence of β -lactamase-producing *M. catarrhalis*, but not β -lactamase-producing *H. influenzae*, appeared to prevent the development of penicillin resistance among pneumococcal isolates in the nasopharynx, presumably by reducing the selection pressure. In this context, it is interesting to compare the remarkably low frequency of isolation of *M. catarrhalis* and the high frequency of isolation of penicillin-resistant pneumococcus in Spain with the corresponding frequencies found in northern Europe and the United States (6, 9, 24).

In an era with a high prevalence of resistance among pathogens of the middle ear, the potential benefit to the individual who is treated with antibiotics must be weighed against the public health risk for the emergence of resistant microorganisms. In Scandinavia the frequency of isolation of pneumococci with reduced susceptibilities to penicillin is lower than that in most European countries (12, 26, 27), and penicillin V is still, after more than 45 years, the drug of choice for the treatment of AOM, with *S. pneumoniae* as the primary target. The step from treatment with penicillin V and amoxicillin to AMC might appear to be short, but it requires consideration and should probably not be taken unless it is called for.

ACKNOWLEDGMENTS

This work was supported by grants from the H. and J. Forssman's Foundation, Malmö Health Services District Foundations, and Mid Sweden Research and Development Center.

REFERENCES

1. Barry, B., J. Delattre, F. Vié, J.-P. Bedos, and P. Géhanno P. 1999. Orogenic intracranial infections in adults. *Laryngoscope* **109**:483-487.
2. Block, S. L., J. A. Hedrick, R. D. Tyler, R. A. Smith, and C. J. Harrison. 2001. Microbiology of acute otitis media recently treated with aminopenicillins. *Pediatr. Infect. Dis. J.* **20**:1017-1021.
3. Brook, I., and J. D. Gilmore. 1993. Evaluation of bacterial interference and β -lactamase production in management of experimental infection with group A beta-hemolytic streptococci. *Antimicrob. Agents Chemother.* **37**:1452-1455.
4. Brook, I. 1991. In vitro susceptibility vs. in vivo efficacy of various antimicrobial agents against the *Bacteroides fragilis* group. *Rev. Infect. Dis.* **13**:1170-1180.
5. Brook, I., and A. E. Gober. 2002. Effect of amoxicillin and co-amoxiclav on the aerobic and anaerobic nasopharyngeal flora. *J. Antimicrob. Chemother.* **49**:689-692.
6. Casselbrant, M. L., E. M. Mandel, M. Kurs-Lasky, H. E. Rockette, and C. D. Bluestone. 1995. Otitis media in a population of black American and white American infants, 0-2 years of age. *Int. J. Pediatr. Otorhinolaryngol.* **33**:1-16.
7. Dagan, R., E. Leibovitz, G. Cheletz, A. Leiberman, and N. Porat. 2001. Antibiotic treatment in acute otitis media promotes superinfection with resistant *Streptococcus pneumoniae* carried before initiation of treatment. *J. Infect. Dis.* **183**:880-886.
8. Dagan, R., E. Leibovitz, A. Leiberman, and P. Yagupsky. 2000. Clinical significance of antibiotic resistance in acute otitis media and implication of antibiotic treatment on carriage and spread of resistant organisms. *Pediatr. Infect. Dis. J.* **19**:S57-S65.

9. Del Castillo, F., F. Baquero-Artigao, and A. Garcia-Perea. 1998. Influence of recent antibiotic therapy on antimicrobial resistance of *Streptococcus pneumoniae* in children with acute otitis media in Spain. *Pediatr. Infect. Dis. J.* **17**:94–97.
10. Dowell, S. F., and B. Schwartz. 1997. Resistant pneumococci: protecting patients through judicious use of antibiotics. *Am. Fam. Physician* **55**:1647–1654.
11. Elliott, J. A., R. R. Facklam, C. Nathan, R. A. Weinstein, L. Kauffmann, J. McAllister, and P. Stadnik. 1999. Coisolation of *Streptococcus pneumoniae* and *Haemophilus influenzae* from middle ear fluid and sputum: effect on MIC results. *J. Clin. Microbiol.* **37**:277.
12. Eriksson, M., B. Henriques, and K. Ekdahl. 2000. Epidemiology of pneumococcal infections in Swedish children. *Acta Pediatr. Suppl.* **89**:35–39.
13. Falla, T. J., D. W. M. Crook, L. N. Brophy, D. Maskell, J. S. Kroll, and E. R. Moxon. 1994. PCR for capsular typing of *Haemophilus influenzae*. *J. Clin. Microbiol.* **32**:2382–2386.
14. Froom, J., L. Culpepper, M. Jacobs, R. A. DeMelker, L. A. Green, L. Van Buchem, P. Grob, and T. Heeren. 1997. Antimicrobials for acute otitis media? A review from the international primary care network. *BMJ* **315**:98–102.
15. Fuchs, P. C., A. L. Barry, M. A. Pfaller, D. J. Hardy, J. C. McLaughlin, and E. H. Gerlach. 1993. In vitro activity of ampicillin, amoxicillin, ampicillin-sulbactam, and amoxicillin-clavulanic acid against consecutive clinical isolate of Enterobacteriaceae. *Diagn. Microbiol. Infect. Dis.* **17**:171–175.
16. Gehanno, P., L. N'Guyen, M. Derriennic, F. Pichon, J.-M. Goehrs, and P. Berche. 1998. Pathogens isolated during treatment failures in otitis. *Pediatr. Infect. Dis. J.* **17**:885–890.
17. Ghaffar, F., I. R. Friedland, K. Katz, L. S. Muniz, J. L. Smith, P. Davis, J. Reynolds, and G. H. McCracken, Jr. 1999. Increased carriage of resistant non-pneumococcal α -hemolytic streptococci after antibiotic therapy. *J. Pediatr.* **135**:618–623.
18. Goldstein, N. A., M. L. Casselbrant, C. D. Bluestone, and M. Kurs-Lasky. 1998. Intratemporal complications of acute otitis media in infants and children. *Otolaryngol. Head Neck Surg.* **119**:444–454.
19. Hackman, A. S., and T. D. Wilkins. 1975. In vivo protection of *Fusobacterium necrophorum* from penicillin by *Bacteroides fragilis*. *Antimicrob. Agents Chemother.* **7**:698–703.
20. Hoban, D., and D. Felmingham. 2002. The PROTEKT surveillance study: antimicrobial susceptibility of *Haemophilus influenzae* and *Moraxella catarrhalis* from community-acquired respiratory tract infections. *J. Antimicrob. Chemother.* **50**(Suppl. S1):49–59.
21. Hol, C., E. E. M. Van Dijke, C. M. Verduin, J. Verhoef, and H. Van Dijk. 1994. Experimental evidence for *Moraxella*-induced penicillin neutralization in pneumococcal pneumonia. *J. Infect. Dis.* **170**:1613–1616.
22. Jacobs, M. R., R. Dagan, P. C. Appelblum, and D. J. Burch. 1998. Prevalence of antimicrobial-resistant pathogens in middle ear fluid: multinational study of 917 children with acute otitis media. *Antimicrob. Agents Chemother.* **42**:589–595.
23. Joki-Erkkilä, V.-P., J. Aittoniemi, R. Vuento, and H. Puhakka. 2002. β -Lactamase-producing *Moraxella catarrhalis* may prevent the emergence of penicillin-resistant *Streptococcus pneumoniae* in children with recurrent acute otitis media. *Int. J. Pediatr. Otolaryngol.* **63**:219–222.
24. Kilpi, T., E. Herva, T. Kaijalainen, R. Syrjänen, and A. K. Takala. 2001. Bacteriology of acute otitis media in a cohort of Finnish children followed for the first two years of life. *Pediatr. Infect. Dis. J.* **20**:654–662.
25. Klein, J. O. 1994. Otitis media. *Clin. Infect. Dis.* **19**:823–833.
26. Kondradsen, H. B., and M. S. Kalso. 2002. Invasive pneumococcal infections in Denmark from 1995 to 1999: epidemiology, serotypes, and resistance. *Clin. Diagn. Lab. Immunol.* **9**:358–365.
27. Kristiansen, B. E., R. A. Sandnes, L. Mortensen, Y. Tveten, and L. Vorland. 2001. The prevalence of antibiotic resistance in bacterial respiratory pathogens from Norway is low. *Clin. Microbiol. Infect.* **7**:682–687.
28. Kristinsson, K. G. 1997. Effect of antimicrobial use and other risk factors on antimicrobial resistance in pneumococci. *Microb. Drug Resist.* **3**:117–123.
29. Leflon-Guibout, V., G. Ternat, B. Heym, and M.-H. Nicolas-Chanoine. 2002. Exposure to co-amoxiclav as a risk factor for co-amoxiclav-resistant *Escherichia coli* urinary tract infection. *J. Antimicrob. Chemother.* **49**:367–371.
30. Melhus, Å., A. Hermansson, and K. Prellner. 1994. Nontypeable and encapsulated *Haemophilus influenzae* yield different clinical courses of experimental otitis media. *Acta Otolaryngol. (Stockholm)* **114**:289–294.
31. Melhus, Å., H. Janson, E. Westman, A. Hermansson, A. Forsgren, and K. Prellner. 1997. Amoxicillin treatment of experimental acute otitis media caused by *Haemophilus influenzae* with a non- β -lactamase-mediated resistance to β -lactams: aspects of virulence and treatment. *Antimicrob. Agents Chemother.* **41**:1979–1984.
32. Melhus, Å., and A. F. Ryan. 2000. Expression of cytokine genes during pneumococcal and nontypeable *Haemophilus influenzae* acute otitis media in the rat. *Infect. Immun.* **68**:4024–4031.
33. Renneberg, J., and M. Walder. 1989. The role of beta-lactamase in mixed infections in mice in relation to treatment with ampicillin. *J. Infect. Dis.* **160**:337–341.
34. Roos, K., E. Grahn, and S. Holm. 2001. Effect of recolonisation with “interfering” α streptococci on recurrences of acute and secretory otitis media in children: randomised placebo controlled trial. *BMJ* **322**:1–4.