



LUND UNIVERSITY

Reduced full-field electroretinogram (ERG) in a patient treated with methotrexate.

Ponjavic, Vesna; Grånse, Lotta; Bengtsson-Stigmar, Elisabeth; Andréasson, Sten

Published in:
Acta Ophthalmologica Scandinavica

DOI:
[10.1046/j.1600-0420.2003.00181.x](https://doi.org/10.1046/j.1600-0420.2003.00181.x)

2004

[Link to publication](#)

Citation for published version (APA):
Ponjavic, V., Grånse, L., Bengtsson-Stigmar, E., & Andréasson, S. (2004). Reduced full-field electroretinogram (ERG) in a patient treated with methotrexate. *Acta Ophthalmologica Scandinavica*, 82(1), 96-99.
<https://doi.org/10.1046/j.1600-0420.2003.00181.x>

Total number of authors:
4

General rights

Unless other specific re-use rights are stated the following general rights apply:
Copyright and moral rights for the publications made accessible in the public portal are retained by the authors and/or other copyright owners and it is a condition of accessing publications that users recognise and abide by the legal requirements associated with these rights.

- Users may download and print one copy of any publication from the public portal for the purpose of private study or research.
- You may not further distribute the material or use it for any profit-making activity or commercial gain
- You may freely distribute the URL identifying the publication in the public portal

Read more about Creative commons licenses: <https://creativecommons.org/licenses/>

Take down policy

If you believe that this document breaches copyright please contact us providing details, and we will remove access to the work immediately and investigate your claim.

LUND UNIVERSITY

PO Box 117
221 00 Lund
+46 46-222 00 00

Case Report

Reduced full-field electroretinogram (ERG) in a patient treated with methotrexate

Vesna Ponjavic, Lotta Gränse, Elisabeth Bengtsson Stigmar and Sten Andréasson

Department of Ophthalmology, University of Lund, Sweden

ABSTRACT.

Purpose: To examine retinal function in a patient with decreased vision possibly due to treatment with methotrexate.

Methods: Ophthalmological examination included testing of visual acuity (VA), fundus inspection, fundus photography and kinetic perimetry. Retinal function was tested objectively with three electrophysiological methods: full-field electroretinography (ERG), multifocal electroretinography (mfERG) and electro-oculography (EOG).

Results: A 13-year-old boy with psoriasis arthritis had been treated with methotrexate on a weekly basis for 8.5 years. After terminating treatment, his VA, which was reduced to 0.3 in both eyes initially, improved during the following 3 years but did not return to normal. No visual field defects were found with kinetic perimetry. The rod and cone responses in the full-field ERG were markedly reduced in b-wave amplitude initially, but grew slowly to nearly normal values 3 years later. After withdrawal of the drug, the mfERG demonstrated normal responses in the macular region. The Arden index in the EOG was normal.

Conclusion: Chronic treatment with methotrexate may affect VA, and may reversibly reduce rod and cone function. In patients who use systemic medication and whose vision is reduced, objective evaluation of retinal function with electrophysiological methods is recommended.

Key words: full-field electroretinography – retinal dysfunction – drug side-effects – methotrexate

Acta Ophthalmol. Scand. 2004; 82: 96–99

Copyright © Acta Ophthalmol Scand 2003.

doi: 10.1046/j.1600-0420.2003.00181.x

Introduction

Administration of certain oral medications is known to cause different ocular side-effects. Several comprehensive reviews of ocular toxicity caused by systemic medications have been published previously (Grant 1986; Fraunfelder & Meyer 1989; Imperia et al. 1989; Pavan-Langston & Dunkel

1991; Novack 1997; Soukasian & Raizman 2000). Adverse ocular manifestations caused by certain drugs such as chloroquine and thioridazine have been extensively documented in the literature (Henkind et al. 1954; Hobbs et al. 1959; Bernstein & Ginsberg 1964; Davidorf 1973; Oshika 1995; Tekell et al. 1996), and are therefore known to every ophthalmologist. However, the

adverse ocular effects of several other drugs have not been reported. New medications are continuously introduced by the pharmaceutical industries, with a speed that makes it difficult to update the practising ophthalmologist on possible connections between ocular pathology and drug toxicity.

Previous studies have demonstrated adverse side-effects associated with methotrexate medication, mainly blepharitis, conjunctivitis, ocular burning and pain (Imperia et al. 1989). A few studies have reported abnormalities of the retinal pigment epithelium and maculopathy on fundus inspection (Millay et al. 1986; Fishburne et al. 1997), but there are, to our knowledge, no descriptions of retinal dysfunction verified with electroretinography (ERG) caused by methotrexate in humans. Velez et al. (2002) recently published a case report demonstrating unaffected ERGs after intravitreal injections of methotrexate. A previous study of rabbits treated with five single injections of methotrexate intravitreally demonstrated unaffected retinal function with ERG (Velez et al. 2001).

At our department for patients with hereditary retinal degenerations at the University Hospital of Lund, we sometimes encounter patients with retinal dysfunction not caused by a genetic disorder. These patients are previously healthy subjects who have developed an acquired retinal dysfunction caused by systemic medication. We here present electrophysiological findings

in a patient with acquired retinal dysfunction probably caused by methotrexate.

Methods

Ophthalmological examination included best corrected visual acuity (VA), slit-lamp inspection, dilated fundus examination and fundus photography. Kinetic perimetry was performed with a Goldmann perimeter using standardized objects I4E and V4E.

Full-field ERGs were recorded in a Nicolet analysis system (Nicolet Biomedical Instruments; Madison, Wisconsin, USA), after dark adaptation for 40 min, dilatation of the pupils with topical cyclopentolate 1% and meta-oxedrine 10% and topical anaesthesia. A Burian Allen bipolar contact lens was used and a ground electrode was applied to the forehead. Responses were obtained with a wide band filter (-3 dB at 1 Hz and 500 Hz) stimulating with single full-field flash (30 μs) with blue light (Wratten filter nos. 47, 47A and 47B) and white light (0.81 cd-s/m² and 3.93 cd-s/m²). Cone responses were obtained with 30 Hz flickering white light (0.81 cd-s/m²) averaged from 20 sweeps. Recordings of the isolated cone responses were obtained without background illumination on the Ganzfield screen.

An electro-oculogram (EOG) was recorded in a Nicolet analysis system (Nicolet Biomedical Instruments; Madison, Wisconsin, USA), as described previously (Andréasson et al. 1997). Examination with multifocal ERG (mfERG) was conducted according to previous descriptions, with a stimulus pattern of 103 hexagons covering up to ±23 degrees of the visual field (Sutter

& Tran 1992; Bearnse & Sutter 1996). The responses were measured by using a bipolar contact lens electrode attached to the eye.

Case Report

In January 1997 a 13-year-old boy was referred to our department because of low VA. At 5 years of age he had developed a psoriasis arthritis that was treated with methotrexate on a weekly basis during the following 8.5 years. He received a total dose of methotrexate of 2550 mg. During the first 14 months of treatment he received a dose of 7.5 mg methotrexate each week. During the remaining period, the dose was 5 mg/week (for 69 months) and 2.5 mg/week (for 16 months). The patient was also given a daily dose of naproxene (250 mg) during this period, as well as a few intra-articular injections of steroids. There was no history of hereditary eye disorders in family members. The patient's rheumatologist had observed poor growth and his cardiologist had documented heart enlargement, which was suspected to be caused by a deposition of methotrexate in cardiac tissue. At the initial examination in January 1997, VA was reduced to 0.3 in both eyes (from 0.65 at 5 years of age on routine examination, when no signs of iritis were found but ametropia amblyopia was confirmed). No visual field defects were found with the Goldmann method. The patient's full-field ERG was markedly reduced (Table 1 and Fig. 1). The reduction in rod and cone b-wave amplitude was statistically significant compared to normal controls. The EOG result was normal

(Arden index: right eye 1.8 and left eye 1.6). No retinal or vitreous pathology was found on fundus examination (Fig. 2).

In June 1997 the medication was terminated because of the described ocular side-effects and also because of a cardiomyopathy possibly caused by methotrexate, according to the patient's cardiologist. Follow-up examinations demonstrated a remarkable recovery of retinal function (Table 1). The rod and cone responses in full-field ERG improved during the following years. After 3 years, there was a four-fold increase in the isolated rod response and a three-fold increase in the combined rod-cone response. The isolated cone b-wave amplitude was doubled. Multifocal ERG, performed only at the last examination in 1999, demonstrated normal macular function.

Discussion

Methotrexate is known to have several adverse effects on different tissues of the eye (Imperia et al. 1989). However, only two studies have documented retinal pathology in humans, demonstrating pigmentary retinal epithelium changes in patients treated for malignant neoplasms (Millay et al. 1986; Fishburne et al. 1997). No electrophysiological evaluation of retinal function was performed in those cases. The present study demonstrates the recovery of retinal function in a young boy after terminating treatment with methotrexate. The dose of methotrexate given to this patient is an ordinary dose for children with juvenile arthritis. The ERG amplitudes increased considerably

Table 1. ERG results of the patient treated with methotrexate. Full-field ERG amplitudes were assessed at three different examinations, demonstrating a normalization of the amplitudes with three different stimuli. The rods were stimulated after 40 min of dark adaptation with a dim blue single flash (30 μs, Wratten filter nos. 47, 47A and 47B). The total retinal response was obtained by stimulating the dark adapted eye with a weak (0.81 cd-s/m²) single flash of white light. Isolated cone responses were obtained with 30 Hz flickering white light (0.81 cd-s/m²) averaged from 20 sweeps, without background illumination on the Ganzfield screen and without previous light adaptation. Normative values are presented both as the median (95% confidence interval) and as the mean ± 2 SD.

Age (years)	Exam ERG	Visual acuity		Blue flash ampl (μV)		White flash ampl (μV)		30 Hz flick ampl (μV)		30 Hz flick IT (ms)	
		RE	LE	RE	LE	RE	LE	RE	LE	RE	LE
13	Jan 1997	0.3	0.3	26	38	87	91	13	17	29.2	28.0
14	Jan 1998	0.4	0.4	83	66	165	134	34	27	26.4	26.6
16	Oct 1999	0.5	0.5	120	109	303	280	41	41	28.2	26.2
Median in 70 controls (95% CI)				149 (99–290)		301 (203–477)		61 (33–101)		29.2 (27.2–32.2)	

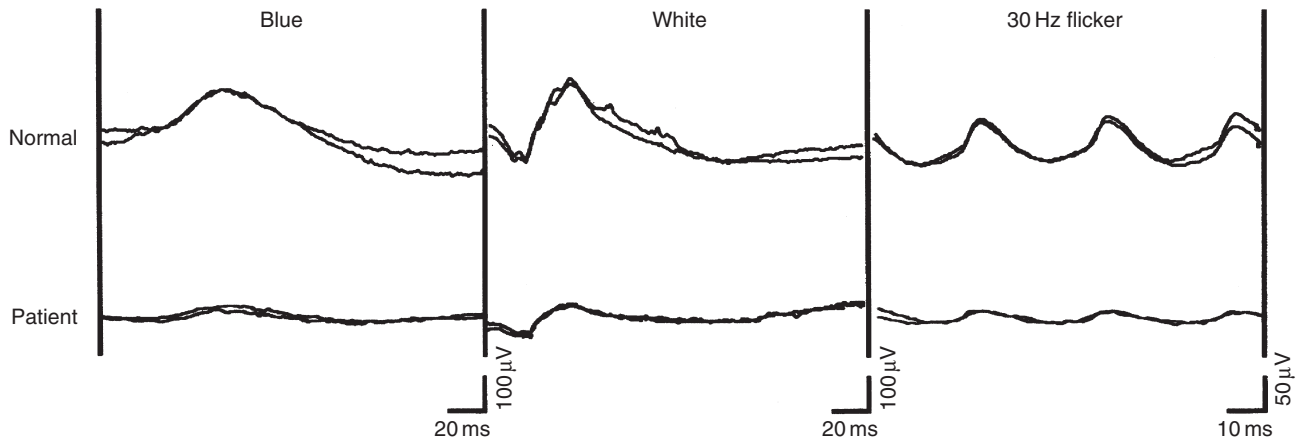


Fig. 1. Electrophysiological results from the patient treated with methotrexate. The upper row demonstrates the full-field ERG of a normal subject; the lower row demonstrates the patient's left eye, showing reduced responses to three different stimuli (January 1997).

during a period of approximately 3 years after the treatment was terminated. This is the first report demonstrating a possible association between retinal dysfunction verified with ERG, and oral methotrexate medication in humans.

Millay et al. (1986) reported macular oedema and pigment epithelial changes in a patient who received an ipsilateral

intracarotid injection of methotrexate. We did not find any macular pathology on fundus inspection in our patient at the initial examination and the EOG was normal. The results from the present study indicate that the cause of the reduction in VA may be a generalized photoreceptor or inner retina dysfunction, and not accumulation of the

drug in the macula or in the pigment epithelium.

In conclusion, this case report demonstrates reversible retinal dysfunction possibly caused by methotrexate. Patients with visual disturbance, who are on longterm systemic medication, should be investigated using electrophysiological methods before excluding the drug as a potential pathogenic cause of the visual dysfunction.

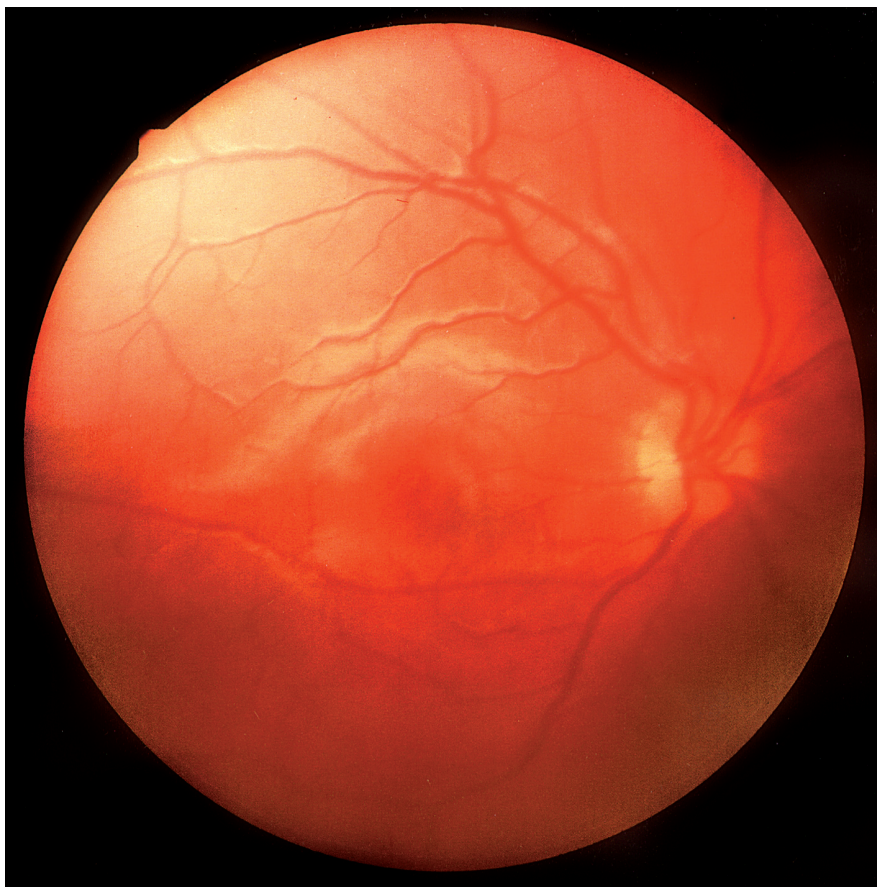


Fig. 2. Fundus of the patient treated with methotrexate. Fundus photography of the patient's right eye reveals no visible pathology (January 1997).

Acknowledgements

We thank Ing-Marie Holst, Susanne Boy and Boel Nilsson for skilful technical assistance. This study was supported by grants from the Segerfalks Stiftelse, the H&L Nilssons Stiftelse, the Kronprinsessans Margaretas Arbetsnämnd för Synskadade, the Medical Society of Lund (Lunds Läkarsällskap), the Swedish Medical Research project no. 73 × 12597-03 A, 14P-12964-01AK and Stiftelsen Synfrämjandets Forskningsfond.

References

- Andréasson S, Ponjavic V, Abrahamson M, Ehinger B, Wu W, Fujita R, Buraczynska M, Swaroop A (1997): Phenotypes in three Swedish families with X-linked retinitis pigmentosa caused by different mutations in the *RPGR* gene. *Am J Ophthalmol* **124**: 95–102.
- Bearse MA & Sutter EE (1996): Imaging localized retinal dysfunction with the multifocal electroretinogram. *J Opt Soc Am A* **13**: 634–640.
- Bernstein H & Ginsberg J (1964): The pathology of chloroquine retinopathy. *Arch Ophthalmol* **71**: 146–153.
- Davidorf FH (1973): Thioridazine pigmentary retinopathy. *Arch Ophthalmol* **90**: 251–255.

- Fishburne BC, Wilson DJ, Rosenbaum JT, Neuwelt EA (1997): Intravitreal methotrexate as an adjunctive treatment of intraocular lymphoma. *Arch Ophthalmol* **115**: 1152–1156.
- Fraunfelder FT & Meyer SM (1989): *Drug-Induced Ocular Side Effects and their Drug Interactions*. 3rd edn. Philadelphia: Lea & Febiger.
- Grant WM (1986): *Toxicology of the Eye*. 3rd edn. Springfield, Illinois: Charles C Thomas.
- Henkind P, Carr R, Siegel I (1954): Early chloroquine retinopathy: clinical and functional findings. *Arch Ophthalmol* **71**: 157.
- Hobbs HE, Sorsky A, Freedman A (1959): Retinopathy following chloroquine therapy. *Lancet* **2**: 478–480.
- Imperia PS, Lazarus HM, Lass JH (1989): Ocular complications of systemic cancer chemotherapy. *Surv Ophthalmol* **34**: 209.
- Millay RH, Klein ML, Shults WT, Dahlborg SA, Neuwelt EA (1986): Maculopathy associated with combination chemotherapy and osmotic opening of the blood–brain barrier. *Am J Ophthalmol* **102**: 626–632.
- Novack GD (1997): Ocular toxicology. *Curr Opin Ophthalmol* **8**: 88–92.
- Oshika T (1995): Ocular adverse effects of neuropsychiatric agents. *Incidence Manage Drug Safety* **12**: 256–263.
- Pavan-Langston D & Dunkel EC (1991): *Handbook of Ocular Drug Therapy and Ocular Side Effects of the Systemic Drugs*. Boston: Little, Brown.
- Soukasian SK & Raizman MB (2000): Ocular toxicity of systemic medications. In: Albert DM & Jacobiec FA, (eds). *Principles and Practise of Ophthalmology*. Philadelphia: W B Saunders Co. 455–468.
- Sutter EE & Tran D (1992): The field topography of ERG components in man. I. The photopic luminance response. *Vision Res* **32**: 433–446.
- Tekell JL, Silva JA, Maas JA, Bowden CL, Starck T (1996): Thioridazine-induced retinopathy. *Am J Psychiatry* **153**: 1234–1235.
- Velez G, Boldt HC, Whitcup SM, Nussenblatt RB, Robinson MR (2002): Local methotrexate and dexamethasone phosphate for the treatment of recurrent primary intraocular lymphoma. *Ophthalmic Surg Lasers* **33**: 329–333.
- Velez G, Yuan P, Sung C, Tansey G, Reed GF, Chan CC, Nussenblatt RB, Robinson MR (2001): Pharmacokinetics and toxicity of intravitreal chemotherapy for primary intraocular lymphoma. *Arch Ophthalmol* **119**: 1518–1524.

Received on March 10th, 2003.
Accepted on September 22nd, 2003.

Correspondence:

Dr Vesna Ponjavic
Department of Ophthalmology
University of Lund
S 221 85 Lund
Sweden
Tel: +46 46 17 14 70
Fax: +46 46 13 90 45
Email: vesna.ponjavic@bredband.net