



LUND UNIVERSITY

Management of postmenopausal bleeding in Sweden: a need for increased use of hydrosoneography and hysteroscopy.

Epstein, Elisabeth

Published in:

Acta Obstetricia et Gynecologica Scandinavica

DOI:

[10.1111/j.1600-0412.2004.00357.x](https://doi.org/10.1111/j.1600-0412.2004.00357.x)

2004

[Link to publication](#)

Citation for published version (APA):

Epstein, E. (2004). Management of postmenopausal bleeding in Sweden: a need for increased use of hydrosoneography and hysteroscopy. *Acta Obstetricia et Gynecologica Scandinavica*, 83(1), 89-95.
<https://doi.org/10.1111/j.1600-0412.2004.00357.x>

Total number of authors:

1

General rights

Unless other specific re-use rights are stated the following general rights apply:

Copyright and moral rights for the publications made accessible in the public portal are retained by the authors and/or other copyright owners and it is a condition of accessing publications that users recognise and abide by the legal requirements associated with these rights.

- Users may download and print one copy of any publication from the public portal for the purpose of private study or research.
- You may not further distribute the material or use it for any profit-making activity or commercial gain
- You may freely distribute the URL identifying the publication in the public portal

Read more about Creative commons licenses: <https://creativecommons.org/licenses/>

Take down policy

If you believe that this document breaches copyright please contact us providing details, and we will remove access to the work immediately and investigate your claim.

LUND UNIVERSITY

PO Box 117
221 00 Lund
+46 46-222 00 00

Management of postmenopausal bleeding in Sweden: a need for increased use of hydrosonography and hysteroscopy

ELISABETH EPSTEIN

From the Department of Obstetrics and Gynecology, Malmö University Hospital, Lund University, Sweden

Acta Obstet Gynecol Scand 2004; 83: 89–95. © Acta Obstet Gynecol Scand 83 2004

Background. The objective was to determine how postmenopausal bleeding (PMB) is managed in Sweden today, and to relate the findings to a new evidence-based algorithm for the management of PMB.

Methods. A questionnaire regarding the role of ultrasound and the use of different endometrial biopsy methods in the management of PMB was sent to all 61 gynecologic departments in Sweden.

Results. Fifty-nine of the 61 departments (97%) satisfactorily answered the questionnaire. Ultrasound was either always ($n = 54$, 92%) or most commonly ($n = 5$, 8%) used in the diagnostic work-up of PMB. In women with endometrial thickness ≤ 4 mm, 18 of the departments (31%) routinely sampled the endometrium; 12 (15%) followed the women with ultrasound; three (5%) did both sampling and follow-up with ultrasound; and the remaining 29 (49%) used expectant management (i.e. no biopsy or routine follow-up). In women with endometrium ≥ 5 mm, hydrosonography was performed routinely in two departments (3%), occasionally in 37 departments (63%), and never in 20 departments (34%). In women with endometrium ≥ 5 mm, endometrial biopsy was obtained routinely by Endorette[®]/Pipelle[®] in 39 departments (66%), while in 26 departments (44%) operative hysteroscopy was never performed.

Conclusion. More than one-third of the gynecologic departments in Sweden never perform hydrosonography to rule out focal lesions or operative hysteroscopy for the removal of such lesions. Hydrosonography and hysteroscopy have a central role in the new guidelines for the management of PMB. Therefore, a need exists to broaden the use of hydrosonography and hysteroscopy.

Key words: postmenopausal bleeding; ultrasound; hydrosonography; hysteroscopy; saline contrast sonohysterography

Submitted 11 February, 2003

Accepted 21 June, 2003

Abnormal uterine bleeding is a common clinical problem, accounting for 70% of all gynecologic visits by peri- and postmenopausal women (1). The main aim in investigating postmenopausal bleeding (PMB) is to exclude endometrial cancer. Conventional transvaginal ultrasound, with or without saline infusion (hydrosonography), can

assist in individualizing the choice of endometrial biopsy procedures or help to confidently omit further investigation in women at low risk of endometrial cancer. However, there is a considerable debate as to how the investigation of PMB should be performed. Management strategies using ultrasound as the primary tool, in contrast to those using endometrial biopsy, are more cost-effective in the investigation of PMB (2). Based on the results of several recently published studies (3–9), simple clinical guidelines were set out during a consensus conference in September

Abbreviations:

PMB: postmenopausal bleeding; HRT: hormone replacement therapy; D&C: dilatation and curettage; CI: confidence interval.

2002 by the Workgroup for Ultrasonography (Ultra-ARG “arbetsgruppen”) of the Swedish Society of Obstetricians and Gynecologists (Fig. 1). By using these guidelines, unnecessary invasive procedures can be avoided while, at the same time, the safety and accuracy of the investigation can be improved. We set out to answer the question: how is PMB managed in gynecologic departments in Sweden today?

Methods

In 2001 a questionnaire was sent to all 61 gynecologic departments in Sweden. The survey sought to determine how conventional transvaginal ultrasound, saline infusion sonography (hydrosonography) and hysteroscopy were being used in the management of PMB in relation to endometrial thickness (Table I). Information was also gathered on the use of different biopsy methods [i.e. simple sampling devices such as Endorette® or Pipelle®, dilatation and curettage (D&C), and operative hysteroscopy], depending on sonographic findings and endometrial thickness (Table I). The questions could be answered by “yes,” “no,” or “sometimes/in some cases,” with the last alternative followed by a request to elaborate.

Results

The questionnaires were satisfactorily filled out by 59 of the 61 departments surveyed (97%). One of the remaining two questionnaires was not

returned and the other was incomplete. The department whose questionnaire was incomplete used a different management strategy based on the analysis of the lactate dehydrogenase isoenzyme pattern extracted from endometrial biopsies (10). In the other 59 departments, ultrasound was either always ($n=54$, 92%) or most commonly ($n=5$, 8%) used in the diagnostic work-up of PMB. Thirty-six departments (61%) had clinical guidelines for the management of PMB. The 5-mm cutoff (‘ ≤ 4 mm’ (i.e. ≤ 4.4 mm) or ‘ ≥ 5 mm’ (i.e. ≥ 4.5 mm) was used by 46 departments, 10 used a cutoff of 4 mm, and the remaining three used various cutoffs, depending on the preference of the doctor in attendance.

In analyzing responses to the questionnaire, it was difficult to interpret exactly how the 4-mm cutoff was defined. In six of the cases, it seemed to be defined as an endometrium of ≤ 4 mm (i.e. what we had called a 5-mm cut-off), whereas others defined it as an endometrium of < 4 mm (i.e. 3.9 mm or less). In women with an endometrial thickness of ≤ 4 mm, 18 departments (31%) routinely sampled the endometrium either by D&C ($n=1$, 2%) or by Endorette®/Pipelle® ($n=17$, 29%); nine (15%) followed the women with ultrasound; three (5%) both sampled and followed the women by ultrasound; and the remaining 29 (49%) used expectant management (i.e. neither biopsy nor routine follow-up). All departments using ultrasound follow-up ($n=12$) offered the women a single follow-up examination within 6 months. Indications that endometrial sampling should be repeated or performed after the primary visit were as follows: among departments that routinely sampled the endometrium at the first visit ($n=18$), rebleeding was an indication for repeated sampling in 11 of the departments (61%); among those performing ultrasound follow-up ($n=12$), both endometrial growth and rebleeding were in all cases indications for endometrial sampling (100%); and among those using expectant management ($n=29$), rebleeding was an indication in 25 departments (86%) for endometrial sampling.

The use of hydrosonography and hysteroscopy in the diagnostic work-up among women with endometrium ≥ 5 mm is shown in Table II. In 22% of the departments (8/36), diagnostic hysteroscopy was always performed under local anesthesia; in 14% of all cases (5/36), local anesthesia was occasionally used, whereas in the remaining 64% (23/36), all women were given general anesthesia. The preferred methods of endometrial biopsy in women with endometrium ≥ 5 mm are presented in Table III.

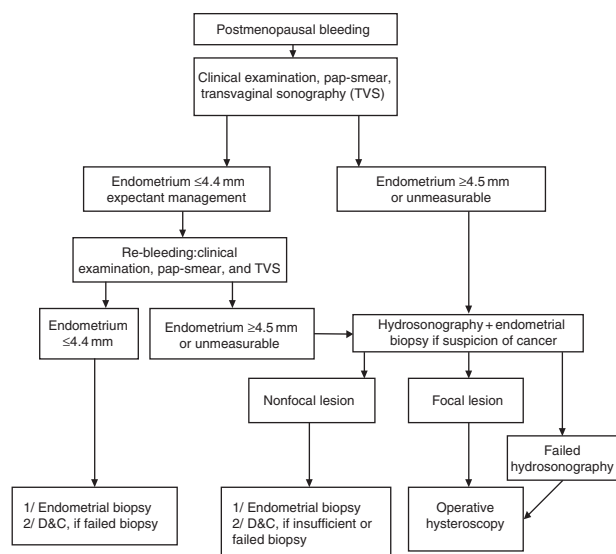


Fig. 1. Clinical guidelines for the management of postmenopausal bleeding, as set out by the Workgroup for Ultrasonography of the Swedish Society of Obstetricians and Gynecologists.

Table I. Questionnaire used in the survey

1 Does the department have clinical guidelines for the management of PMB?	
2 Is transvaginal ultrasound used to measure the endometrium?	
3 Is the management dependent on the endometrial thickness?	
4 Is the 5-mm cutoff used, i.e. ≤ 4 vs. ≥ 5 mm?	
5 Management of PMB with endometrium ≤ 4 mm:	Is endometrial biopsy or D&C performed? Are these women followed by ultrasound? What are the indications for endometrial biopsy after the primary visit?
6 Management of PMB with endometrium ≥ 5 mm:	Is hydrosonegography or diagnostic hysteroscopy performed? Is diagnostic hysteroscopy performed with general or local anesthesia? How is an endometrial sample obtained (Pipelle [®] or Endorette [®] /D&C/ operative hysteroscopy)?

Discussion

The high percentage of departments responding to the questionnaire (97%) indicates that there is great interest in the management of PMB. Solid evidence exists that ultrasound can be used to discriminate between women at high and low risk of endometrial cancer. Recently, two meta-analyses and a consensus conference regarding the ability of transvaginal ultrasound to predict endometrial pathology in women with PMB concluded that the negative predictive value of a thin endometrium (< 5 mm to ≤ 4 mm) is very high (9,11,12). Following a negative scan (endometrium ≤ 4 mm), the risk of endometrial cancer decreases by 90%, regardless of hormone use (9). By using the 5-mm cutoff to define an abnormal endometrium, 96% [95% confidence interval (CI) 94–98] of women with endometrial cancer will be detected at a false-positive rate (1-specificity) of 39% (9). As was the case with the 5-mm cutoff, there was some difficulty in interpreting exactly how the 5-mm cutoff was defined by different gynecologic departments. Nevertheless, Smith-Bindman et al. found that results did not differ if the 5-mm cutoff was defined as < 5 or ≤ 5 mm (9). With the ultrasound systems of today it is possible to discriminate one-tenth of a millimeter. Therefore, in our investigations of women with PMB, we have defined ≤ 4 mm as < 4.4 mm, and ≥ 5 mm as ≥ 4.5 mm (5,6,13,14). The same definitions are used in the new guidelines (Fig. 1).

It was reassuring to find very few comments that the use of hormone replacement therapy (HRT) had altered the management of PMB. Transvaginal ultrasound is highly effective at detecting endometrial disease, regardless of HRT medication, when a 5-mm cutoff is used to define endometrial pathology (the sensitivity being 95% among HRT nonusers and 91% among users) (9). However, the false-positive rate was higher among HRT users than among nonusers (23% vs. 8%) (9). According to the metaanalysis, the use of a 7-mm cutoff in HRT users would have lowered the false-positive rate to 12% (similar to that of the 5-mm cutoff in nonusers), but then the detection rate of endometrial abnormalities would have decreased from 91% to 83% (9). In women on sequential combined therapy, the false-positive rate might be reduced by measuring the endometrial thickness within a week after the last progestin pill. This is supported by the findings of Omodei et al., who showed that endometrial thickness did not differ in women on sequential or continuous combined HRT (3.6 mm vs. 3.2 mm) if the measurement in question were taken on about the fifth day following the last progestin pill (15).

It was not surprising to find a great diversity in the management of women with PMB and endometrium ≤ 4 mm. With the present state of knowledge, we do not know the best management strategy for these women. However, we do know that the risk of finding endometrial pathology

Table II. Diagnostic work-up in women with PMB and endometrium ≥ 5 mm

	Always	Occasionally	Never
Hydrosonegography, <i>n</i> (%)	2 (3)	37* (63)	20 (34)
Diagnostic hysteroscopy, <i>n</i> (%)	0 (0)	36† (61)	23 (39)

*Indications for hydrosonegography: suspicion of focal lesion ($n=23$), diffuse endometrial borders ($n=4$), endometrial thickness > 8 mm ($n=4$), or preference of attending doctor ($n=6$).

†Indications for hysteroscopy: suspicion of focal lesion ($n=20$), diffuse endometrial borders ($n=5$), rebleeding and suspicion of focal lesion ($n=5$), endometrial thickness > 8 mm ($n=1$), or preference of attending doctor ($n=5$).

Table III. Preferred method of obtaining an endometrial biopsy in women with PMB and endometrium ≥ 5 mm

	Routinely	Occasionally	Never	No answer
Pipelle [®] /Endorette [®] , <i>n</i> (%)	39 (66)	19* (32)	2 (3)	0 (0)
D&C, <i>n</i> (%)	6 (10)	51 [†] (86)	0 (0)	2 (3)
Hysteroscopy, <i>n</i> (%)	0 (0)	30 [‡] (51)	26 (44)	3 (5)

*Indications for Pipelle[®]/Endorette[®]: endometrium 5–8, or 5–10 mm (*n*=6), doctor's preference (*n*=6), no suspicion of polyp or cancer (*n*=3), age of woman <65 years (*n*=2), patient's preference (*n*=1), woman in poor health (*n*=1).

[†]Indications for D&C: failed or insufficient endometrial biopsy (*n*=27), heavy bleeding or suspicion of malignancy (*n*=11), endometrium >8 mm (*n*=6), rebleeding (*n*=2), doctor's preference (*n*=3), age of woman >65 (*n*=2).[‡]Indications for hysteroscopy: suspicion of focal lesion at ultrasound/hydrosonography (*n*=22), rebleeding with suspicion of focal lesion (*n*=3), endometrium >8 mm, or >10 mm (*n*=2), doctor's preference (*n*=2), no remarks noted (*n*=1).

in a woman with PMB and endometrium ≤ 4 mm is very small, and therefore it may be justifiable to refrain from invasive endometrial sampling in these women. The risk of missing an endometrial cancer by using expectant management in women with endometrium ≤ 4 will be 2–6% (9). However, we do not know the accuracy of simple endometrial sampling devices with regard to detecting endometrial cancer in women with endometrium ≤ 4 mm. Based on our limited knowledge, the long time consequences of expectant management seem reassuring. In two recent studies, none of the 274 women with PMB and endometrium ≤ 4 mm developed endometrial cancer when followed up for 3.5–5 years (13) or for 10–13 years (7). Gull and co-workers showed that the risk of developing cancer later in life was not increased in women with PMB and endometrium ≤ 4 mm compared to the general population (7). However, in women with PMB and endometrium ≥ 5 mm, the relative risk of developing cancer was 44.5 times higher (95% CI 6.6–320.1) than in the general population (7). Nevertheless, no endometrial cancer was diagnosed in these women, unless rebleeding occurred (7). Should women with PMB and endometrium ≤ 4 mm be offered ultrasound follow-up? The results of one randomized trial (13) and one prospective study (16) on women with PMB and endometrium ≤ 4 mm, monitored by ultrasound follow-up, showed that benign endometrial pathology was more common among women with endometrial growth than among those without endometrial growth. In women with isolated rebleeding, no endometrial pathology was found (13,16).

It is still not known if endometrial growth is a better predictor of malignancy than isolated rebleeding. Based on these results, it would appear safe to manage women with PMB and endometrium ≤ 4 mm expectantly, as suggested in the algorithm (Fig. 1), or by ultrasound follow-up, where both rebleeding and increased endometrial thickness ≥ 5 mm should be taken as indicators for sampling the endometrium.

Sixty-six of the departments represented in Table III routinely used Endorette[®] or Pipelle[®] to obtain an endometrial sample in women with PMB and endometrium ≥ 5 mm. Even though 80% of the women with PMB and endometrium ≥ 5 mm have endometrial pathology, and most of these pathological lesions (98%) have a focal growth pattern (5), there is still widespread use of “blind endometrial sampling methods” such as D&C or Endorette[®]/Pipelle[®]. We know that Endorette[®]/Pipelle[®] fails to diagnose the majority of polyps and a large proportion of simple hyperplasias (6,17–19), whereas the sensitivity of Pipelle[®] in detecting endometrial cancer has been reported to be 99.6%, with a specificity of 99.5%, according to a recently published meta-analysis (20). There are methodological shortcomings in this study, however, as pointed out by the authors themselves (20). For example, only a minority of the studies cited (27%) have a true reference standard (hysterectomy). Several other investigators have shown that D&C fails to diagnose approximately half of all benign pathological lesions (5,21–23), and sometimes endometrial cancer as well (5,21,22); and the procedure commonly (38–100%) leaves all or part of the lesions behind in the uterine cavity (5,21,23–25). However, the agreement between D&C and operative hysteroscopy in diagnosing endometrial abnormalities in women without focally growing lesions at hysteroscopy was excellent (94%) (5). We still do not know if Endorette[®] and/or Pipelle[®] are as good as D&C in diagnosing endometrial cancer when no focal lesions are present.

The question remains: when is it appropriate to use Endorette[®]/Pipelle[®] in the management of PMB? In cases where there is a high suspicion of cancer (cancer prevalence >31%), simple sampling devices have been shown to be cost-effective diagnostic tools (2). However, in an unselected population of women with PMB, the prevalence of endometrial cancer will only be around 10% (9), indicating that ultrasound-initiated evaluation of the endometrium will be more

cost-efficient. Thus, Pipelle[®]/Endorette[®] should only be used in women with PMB and endometrium ≥ 5 mm, in cases where focal lesions have been ruled out by hydrososonography. It might also be beneficial to take an endometrial sample at the time of ultrasound examination, whenever there is a high suspicion of malignancy, to obviate the need for hysteroscopy before hysterectomy. In our experience, the failure rate when performing endometrial biopsy using Endorette[®]/Pipelle[®] is approximately the same (16%) (6) as the failure rate when performing hydrososonography (13%) (3). Nevertheless, we consider that the insemination catheter used for hydrososonography is frequently more easily inserted through the cervix than the biopsy device. It would be an advantage if we could use the hydrososonography catheter for endometrial biopsy in women without focal lesions at hydrososonography. To the best of our knowledge, however, with regard to detecting endometrial cancer, the accuracy of the insemination catheter used at hydrososonography has not been studied.

The algorithm suggests that all focal lesions should be removed by operative hysteroscopy. Is this really necessary? There is positive evidence supporting complete removal of all polypoid lesions in women with PMB. A benign polyp cannot be definitely confirmed until the lesion has been completely removed, because endometrial cancer is fairly frequently confused with a benign polyp at both hysteroscopy and hydrososonography (3). Moreover, there is a threefold increased risk for polyps to regrow when they are removed by D&C, as compared to hysteroscopic resection/removal (26). Polyps are a risk factor for the development of endometrial cancer (27–29), and premalignant or malignant changes are present in polyps in 24% vs. 1.5% of the cases, respectively (30). Finally, from the woman's point of view, it is reassuring to receive a correct diagnosis and obtain appropriate management at the first visit, thus avoiding repeated surgical procedures.

It was surprising to find that almost half of the departments surveyed performed no operative hysteroscopy in the management of PMB. The most probable explanation for this is the fact that D&C is still regarded as the "gold standard" in many departments, and that there is a delay before evidence-based knowledge is transformed into clinical practice. Unfortunately, we did not inquire into how operative hysteroscopy was performed, although we did ask that question about diagnostic hysteroscopy. Two-thirds of the departments using diagnostic hysteroscopy used general anesthesia. The use of hys-

teroscopy might be more appealing if a larger proportion of hysteroscopies were performed under local anesthesia, which would save time and money.

In cases of women with PMB and endometrium ≥ 5 mm, hydrososonography was never performed in one-third of the departments, and performed only occasionally in the remaining two-thirds. The most common reason given for hydrososonography was "suspicion of focal lesion" at conventional ultrasound. However, conventional transvaginal ultrasound, without the use of saline infusion, will only have a sensitivity of 67–78% (and a specificity of 88–100%) (3, 31–32) with regard to detection of focally growing lesions among women with PMB, making it a poor screening tool for the selection of those women who would benefit from hydrososonography. Four departments carried out hydrososonography only in cases where the endometrium measured more than 8 mm. In one of our studies on women with PMB, we found focal lesions at hysteroscopy in 46 out of 48 women with an endometrium between 5 mm and 8 mm (3). By performing hydrososonography only in women with an endometrium > 8 mm, many focal lesions would have been missed. Hydrososonography, first described by Parsons and Lense in 1993 (33), can easily and accurately rule out focal lesions, the reported sensitivity being 93–100% and the false-positive rate 6–15% when hysteroscopy or hysterectomy are used as the "gold standard" (3, 34,35–37). However, it is important to emphasize that hydrososonography cannot reliably discriminate between benign and malignant focal lesions (3,35). Hydrososonography is easy to learn, well-tolerated by the patient, less expensive in comparison to outpatient hysteroscopy (34,38,39), and can be performed quickly, with a minimum of extra equipment, as part of an ultrasound examination. Given appropriate training, all gynecologists who counsel women with PMB can learn to measure the endometrial thickness accurately, and to perform hydrososonography. Measuring the endometrium in postmenopausal women is often more difficult than in women of fertile age, due to the upright position of the uterus, the presence of vessel calcification, and a more diffusely marked endometrial-myometrial border. In women where the endometrium cannot be measured, endometrial pathology – and even endometrial cancer – is not an uncommon finding (5,8). Hydrososonography can be very helpful where the endometrium is difficult to measure, as it will assist the practitioner in visualizing the endometrium and in most cases make endometrial measurement possible.

This study indicates a need for uniform guidelines regarding the management of PMB. The new evidence-based guidelines for the management of PMB demand a more widespread use of hydrosoneography and operative hysteroscopy. The use of blind endometrial sampling as the "gold standard" should be abandoned.

Acknowledgments

This study was supported by grants obtained by the Swedish Society for Ultrasound in Medicine.

References

- Spencer CP, Cooper AJ, Whitehead MI. Management of abnormal bleeding in women receiving hormone replacement therapy. *Br Med J* 1997; 315: 37–42.
- Medverd JR, Dubinsky TJ. Cost analysis model: US versus endometrial biopsy in evaluation of peri- and postmenopausal abnormal vaginal bleeding. *Radiology* 2002; 222: 619–27.
- Epstein E, Ramirez A, Skoog L, Valentin L. Transvaginal sonography, saline contrast sonohysterography, and hysteroscopy for the investigation of women with postmenopausal bleeding and endometrium >5 mm. *Ultrasound Obstet Gynecol* 2001; 18: 157–62.
- Epstein E. Ultrasound in the management of women with post-menopausal bleeding. Thesis. University of Lund, 2001.
- Epstein E, Ramirez A, Skoog L, Valentin L. Dilatation and curettage fails to detect most focal lesions in the uterine cavity in women with postmenopausal bleeding. *Acta Obstet Gynecol Scand* 2001; 80: 1131–6.
- Epstein E, Skoog L, Valentin L. Comparison of Endorette and dilatation and curettage for sampling of the endometrium in women with postmenopausal bleeding. *Acta Obstet Gynecol Scand* 2001; 80: 959–64.
- Gull B. Transvaginal sonography of the endometrium in postmenopausal women. Thesis. University of Gothenburg, 2001.
- Karlsson B, Granberg S, Wikland M, Ylostalo P, Torvid K, Marsal K et al. Transvaginal ultrasonography of the endometrium in women with postmenopausal bleeding – a Nordic multicenter study. *Am J Obstet Gynecol* 1995; 172: 1488–94.
- Smith-Bindman R, Kerlikowske K, Feldstein VA, Subak L, Scheidler J, Segal M et al. Endovaginal ultrasound to exclude endometrial cancer and other endometrial abnormalities. *J Am Med Assoc* 1998; 280: 1510–17.
- Niklasson O, Skude G, Johansson R, Stormby N. Screening for endometrial carcinoma by endouterine aspiration cytology with analysis of tumor markers in the aspirates. Development and application of a new screening technique. *Anal Quant Cytol* 1985; 7: 61–8.
- Gupta JK, Chien PF, Voit D, Clark TJ, Khan KS. Ultrasonographic endometrial thickness for diagnosing endometrial pathology in women with postmenopausal bleeding: a meta-analysis. *Acta Obstet Gynecol Scand* 2002; 81: 799–816.
- Goldstein RB, Bree RL, Benson CB, Benacerraf BR, Bloss JD, Carlos R et al. Evaluation of the woman with postmenopausal bleeding: Society of Radiologists in Ultrasound-Sponsored Consensus Conference statement. *J Ultrasound Med* 2001; 20: 1025–36.
- Epstein E, Valentin L. Re-bleeding and endometrial growth in women with post-menopausal bleeding and endometrium < 5 mm managed by dilatation and curettage or ultrasound follow-up. A randomised controlled study. *Ultrasound Obstet Gynecol* 2001; 18: 499–504.
- Epstein E, Skoog L, Isberg PE, De Smet F, De Moor B, Olofsson PA et al. An algorithm including results of gray-scale and power Doppler ultrasound examination to predict endometrial malignancy in women with postmenopausal bleeding. *Ultrasound Obstet Gynecol* 2002; 20: 370–6.
- Omodei U, Ferrazzia E, Ruggeri C, Palai N, Fallo L, Dordoni D et al. Endometrial thickness and histological abnormalities in women on hormonal replacement therapy: a transvaginal ultrasound/hysteroscopic study. *Ultrasound Obstet Gynecol* 2000; 15: 317–20.
- Gull B, Carlsson S, Karlsson B, Ylostalo P, Milsom I, Granberg S. Transvaginal ultrasonography of the endometrium in women with postmenopausal bleeding: is it always necessary to perform an endometrial biopsy? *Am J Obstet Gynecol* 2000; 182: 509–15.
- Batool T, Reginald PW, Hughes JH. Outpatient pipelle endometrial biopsy in the investigation of postmenopausal bleeding. *Br J Obstet Gynaecol* 1994; 101: 545–6.
- Reid PC, Brown VA, Fothergill DJ. Outpatient investigation of postmenopausal bleeding. *Br J Obstet Gynaecol* 1993; 100: 498.
- Van den Bosch T, Vandendael A, Van Schoubroeck D, Wrantz PA, Lombard CJ. Combining vaginal ultrasonography and office endometrial sampling in the diagnosis of endometrial disease in postmenopausal women. *Obstet Gynecol* 1995; 85: 349–52.
- Dijkhuizen FP, Mol BW, Brolmann HA, Heintz AP. The accuracy of endometrial sampling in the diagnosis of patients with endometrial carcinoma and hyperplasia: a meta-analysis. *Cancer* 2000; 89: 1765–72.
- Bettocchi S, Ceci O, Vicino M, Marelllo F, Impedovo L, Selvaggi L. Diagnostic inadequacy of dilatation and curettage. *Fertil Steril* 2001; 75: 803–5.
- Stovall TG, Solomon SK, Ling FW. Endometrial sampling prior to hysterectomy. *Obstet Gynecol* 1989; 73: 405–9.
- Valle RF. Hysteroscopic evaluation of patients with abnormal uterine bleeding. *Surg Gynecol Obstet* 1981; 153: 521–6.
- Gebauer G, Hafner A, Siebzehrubl E, Lang N. Role of hysteroscopy in detection and extraction of endometrial polyps: results of a prospective study. *Am J Obstet Gynecol* 2001; 184: 59–63.
- Goldfarb HA. D&C results improved by hysteroscopy. *N J Med* 1989; 86: 277–9.
- Bouda J Jr, Hradecky L, Rokyta Z. Hysteroscopic polypectomy versus fractionated curettage in the treatment of corporal polyps – recurrence of corporal polyps. *Ceska Gynecol* 2000; 65: 147–51.
- Pettersson B, Adami HO, Lindgren A, Hesselius I. Endometrial polyps and hyperplasia as risk factors for endometrial carcinoma. A case-control study of curettage specimens. *Acta Obstet Gynecol Scand* 1985; 64: 653–9.
- Sherman AI, Brown S. The precursors of endometrial carcinoma. *Am J Obstet Gynecol* 1979; 135: 947–56.
- Kurman RJ, Kaminski PF, Norris HJ. The behavior of endometrial hyperplasia. A long-term study of 'untreated' hyperplasia in 170 patients. *Cancer* 1985; 56: 403–12.

30. Anastasiadis PG, Koutlaki NG, Skaphida PG, Galazios GC, Tsikouras PN, Liberis VA. Endometrial polyps: prevalence, detection, and malignant potential in women with abnormal uterine bleeding. *Eur J Gynaecol Oncol* 2000; 21: 180–3.
31. Cicinelli E, Romano F, Anastasio PS, Blasi N, Parisi C. Sonohysterography versus hysteroscopy in the diagnosis of endometrial polyps. *Gynecol Obstet Invest* 1994; 38: 266–71.
32. Schwarzler P, Concin H, Bosch H, Berlinger A, Wohlgenannt K, Collins WP et al. An evaluation of sonohysterography and diagnostic hysteroscopy for the assessment of intrauterine pathology. *Ultrasound Obstet Gynecol* 1998; 11: 337–42.
33. Parsons AK, Lense JJ. Sonohysterography for endometrial abnormalities: preliminary results. *J Clin Ultrasound* 1993; 21: 87–95.
34. Widrich T, Bradley LD, Mitchinson AR, Collins RL. Comparison of saline infusion sonography with office hysteroscopy for the evaluation of the endometrium. *Am J Obstet Gynecol* 1996; 174: 1327–34.
35. Bernard JP, Lecuru F, Darles C, Robin F, de Bievre P, Taurelle R. Saline contrast sonohysterography as first-line investigation for women with uterine bleeding. *Ultrasound Obstet Gynecol* 1997; 10: 121–5.
36. Kamel HS, Darwish AM, Mohamed SA. Comparison of transvaginal ultrasonography and vaginal sonohysterography in the detection of endometrial polyps. *Acta Obstet Gynecol Scand* 2000; 79: 60–4.
37. Williams CD, Marshburn PB. A prospective study of transvaginal hydrosonography in the evaluation of abnormal uterine bleeding. *Am J Obstet Gynecol* 1998; 179: 292–8.
38. Timmerman D, Deprest J, Bourne T, Van den Berghe I, Collins WP, Vergote I. A randomized trial on the use of ultrasonography or office hysteroscopy for endometrial assessment in postmenopausal patients with breast cancer who were treated with tamoxifen. *Am J Obstet Gynecol* 1998; 179: 62–70.
39. Rogerson L, Bates J, Weston M, Duffy S. A comparison of outpatient hysteroscopy with saline infusion hysterosonography. *Br J Obstet Gynecol* 2002; 109: 800–4.

Address for correspondence:

Elisabeth Epstein
Department of Obstetrics and Gynecology
Malmö University Hospital
SE-205 02 Malmö
Sweden
e-mail: elisabeth.epstein@obst.mas.lu.se