



# LUND UNIVERSITY

## **Alzheimer's disease (AD) with and without white matter pathology-clinical identification of concurrent cardiovascular disorders.**

Andin, Ulla; Passant, Ulla; Gustafson, Lars; Englund, Elisabet

*Published in:*  
Archives of Gerontology and Geriatrics

*DOI:*  
[10.1016/j.archger.2006.06.002](https://doi.org/10.1016/j.archger.2006.06.002)

2007

[Link to publication](#)

*Citation for published version (APA):*  
Andin, U., Passant, U., Gustafson, L., & Englund, E. (2007). Alzheimer's disease (AD) with and without white matter pathology-clinical identification of concurrent cardiovascular disorders. *Archives of Gerontology and Geriatrics*, 44, 277-286. <https://doi.org/10.1016/j.archger.2006.06.002>

*Total number of authors:*  
4

### **General rights**

Unless other specific re-use rights are stated the following general rights apply:  
Copyright and moral rights for the publications made accessible in the public portal are retained by the authors and/or other copyright owners and it is a condition of accessing publications that users recognise and abide by the legal requirements associated with these rights.

- Users may download and print one copy of any publication from the public portal for the purpose of private study or research.
- You may not further distribute the material or use it for any profit-making activity or commercial gain
- You may freely distribute the URL identifying the publication in the public portal

Read more about Creative commons licenses: <https://creativecommons.org/licenses/>

### **Take down policy**

If you believe that this document breaches copyright please contact us providing details, and we will remove access to the work immediately and investigate your claim.

LUND UNIVERSITY

PO Box 117  
221 00 Lund  
+46 46-222 00 00



This is an author produced version of a paper published in Archives of Gerontology and Geriatrics. This paper has been peer-reviewed but does not include the final publisher proof-corrections or journal pagination.

Citation for the published paper:

Andin, Ulla and Passant, Ulla and Gustafson, Lars and Englund, Elisabet

"Alzheimer's disease with and without white matter pathology  
-clinical identification of concurrent cardiovascular disorders "

Archives of Gerontology and Geriatrics, 2006, Issue: Aug 17.

<http://dx.doi.org/10.1016/j.archger.2006.06.002>

Access to the published version may require journal subscription.

Published with permission from: Elsevier

Alzheimer's disease with and without white matter pathology  
-clinical identification of concurrent cardiovascular disorders.

Ulla Andin<sup>a</sup>, Ulla Passant<sup>a</sup>, Lars Gustafson<sup>a</sup>, Elisabet Englund<sup>b</sup>

Dept of Psychogeriatrics <sup>a</sup>, Dept of Pathology <sup>b</sup>, Lund University Hospital, Sweden

**Corresponding address:**

Ulla Andin

Departments of Geriatrics

Örebro University Hospital

S-70185 Örebro, Sweden

Tel:+46 19 602 26 43

Fax:+46 19 602 26 45

Mobile: +46 706611046

Email: ulla.andin@orebroll.se

## **Abstract**

Clinical vascular features, either as manifest vascular disease or as cardiovascular risk factors were compared in AD with and without neuropathological white matter disease (WMD). The aim of the study was to investigate whether the presence of WMD and the severity of either AD pathology or WMD were associated with different cardiovascular profiles.

A total of 44 AD cases were retrospectively studied. All the cases were neuropathologically diagnosed as AD with WMD (n=22) and as AD without WMD (n=22), respectively.

The patients' medical records were studied with regard to their medical history and to somatic and neurological findings including arrhythmia, congestive heart failure, angina, myocardial infarctions, signs of TIA/stroke, diabetes mellitus, and blood pressure abnormalities, such as hypertension and orthostatic hypotension.

In AD-WMD, hypertension, orthostatic hypotension as well as dizziness/unsteadiness were significantly more common than in AD without WMD. Cardiovascular symptoms were more frequent in AD-WMD than in the other group, though the difference did not reach statistical significance.

Hypothetically, abnormal and unstable blood pressure levels underlie recurrent cerebral hypoperfusion, which may in turn leave room for the development of WMD. Furthermore, dizziness/unsteadiness may be a symptom reflecting the presence of WMD.

**Keywords:** Neuropathology, cardiovascular, Alzheimer's disease, white matter disease, incomplete infarction, dizziness, hypertension, orthostatic hypotension

## 1. Introduction

White matter disease (WMD) is frequently found in the brains of Alzheimer's disease (AD) (Brun and Englund, 1986). The most marked white matter changes typical of AD, constitute a combination of axonal and myelin reduction, a mild reactive gliosis and a small vessel arteriosclerosis. Described as selective incomplete white matter infarction (Englund et al., 1988) these changes are considered to be ischemic/vascular in type, albeit generally associated with the primary neurodegenerative disease of AD. The possible association of vascular mechanisms and the development of AD have been a recent topic of discussion. It has been suggested that vascular factors are important contributory factors in AD (de la Torre, 2004). Cerebral amyloid angiopathy (CAA) however, in itself a vascular disorder directly associated with AD, has no immediate association with traditional cerebrovascular disease factors, such as atherosclerosis, hypertension and hyperlipidemia (Wang et al., 2002), but has been shown to correlate with severity of WMD (Haglund and Englund, 2002). WMD, judged to be a form of vascular ischemic complication in many AD patients, occurs and progresses along the course of dementia (de Leeuw et al., 2005; Englund et al., 2002). Although CAA in AD correlates positively with WMD severity, WMD is also more prevalent in higher ages. These correlations indicate a multifactorial pathogenesis of WMD in AD, in which other vascular and/or cardiac features may possibly play a role.

Different symptomatology have been described in AD with and without WMD / incomplete infarction (Londos et al., 2001; Englund et al., 1989). These findings support the heterogeneity of AD and may have implications for treatment strategies (Wallin and Blennow, 1996).

In earlier retrospective assessments of the medical records in AD with and without WMD some vascular features consistently occurred in association with WMD; these were not only

cardiac disease, hypertension and orthostatic hypotension, but also clinical features, such as dizziness and unsteadiness (Englund et al., 1989). Furthermore, executive dysfunction was found to correlate with MRI-detected frontal white matter changes among AD patients in a recent clinical study (own unpublished results).

In the present study we tried to investigate whether there are also other traits typical of vascular disease in AD-WMD, not previously reported in our material.

The aim of the study was to compare clinical cardiovascular features, either as manifest vascular disease or cardiovascular risk factors, in AD with and without WMD, and thus to investigate whether the presence of WMD and the severity of either AD pathology or WMD are associated with different profiles in these aspects.

## **2. Materials**

A total of 44 neuropathologically diagnosed AD cases was retrospectively studied, half of which were AD with WMD (7 males and 15 females) and the others representing AD without WMD (9 males and 13 females). Mean age at death was 81.1 years (range 62-91) in AD with WMD and 74.4 years (range 61-91) in the AD group without WMD ( $p=0.012$ ) (Table 1).

*Table 1 insert here.*

All patients had been diagnosed and followed by means of repeated evaluations at the Department of Psychogeriatrics. They subsequently underwent a post mortem neuropathological examination. The AD-WMD group comprised consecutive dementia cases from the Lund Longitudinal Dementia Study (Brun and Gustafson, 1993), selected for a previous study (Andin et al., 2005) to represent AD-WMD without interference from other brain disease. The 22 AD cases without WMD were selected from the same period of time. The clinical diagnoses were categorized in terms of ICD 10 (World Health Organization, 1992). The neuropathological diagnoses were established using the Brun and Englund criteria

(Brun and Englund, 1981), comparable with the CERAD and Braak criteria (Braak and Braak, 1991; Mirra et al., 1991) but encompassing more histopathological details in an assessment of the entire brain, thus allowing for the exclusion of cases with additional pathology.

Cases with insufficient clinical data were excluded, as were cases in which concurrent pathology, e.g. vascular lesions such as focal complete infarcts, were found. Consequently there was no case in this study exhibiting the combined pathology of AD and vascular disease/mixed dementia by traditional definitions (Kalaria et al., 2004; Langa et al., 2004).

### **3. Methods**

#### *3.1. Clinical evaluation*

The medical records were studied retrospectively with regard to the medical history and to somatic/neurological examinations including CT. In addition the records from somatic neurological and psychogeriatric examinations were studied with regard to arrhythmia, congestive heart failure, angina, myocardial infarctions, signs of TIA/stroke, diabetes mellitus, and blood pressure abnormalities: hypertension and orthostatic hypotension.

Hypertension was defined as blood pressure >140/90 mm Hg for people below 70 years, and >160/90 mm Hg for people above 70 years, recorded on three separate occasions (Thulin and Liedholm, 1993). Orthostatic hypotension was defined as a systolic blood pressure fall of more than 20 mm Hg upon standing from the supine rest position (Mathias and Bannister, 1992). Apart from other clinical features regularly noted, special attention was given to the presence of falls and of dizziness/unsteadiness, for which patients' subjective reports and objective observations from caregivers were used.

#### *3.2. Neuropathological assessment.*

The severity of white matter changes, as noted from the protocols, allowed for specification of three main degrees of pathology, (mild, moderate and severe). A similar rating (mild,



moderate, severe; here designated 1, 2 and 3, respectively) of the overall whole brain Alzheimer pathology (Brun and Englund, 1981) was also retrieved from the protocols and the rating was revisited with additional use of the Braak-Braak grading scale for temporolimbic regions (Braak and Braak, 1991) (Table 1).

### *3.3. Statistical analysis*

The statistical work was conducted in SPSS 13.0. for Windows (SPSS Inc).

The  $\chi^2$ -test or Fisher's exact tests (when the expected cell counts were <5) were carried out for comparison of cardio-cerebrovascular diagnoses and other clinical symptoms. Confidence intervals for proportions were calculated in accordance with the method described by Newcombe & Altman (Newcombe and Altman, 2000). A one way ANOVA test was used to compare means between the groups.

## **4. Results**

Hypertension, orthostatic hypotension and also dizziness / unsteadiness were significantly more frequent in AD-WMD vs. AD whereas recorded falls did not differ between the groups (fig.1).

*Fig. 1. Insert here*

Cardiovascular features, such as arrhythmia, angina, myocardial infarction, and congestive heart failure were more frequent in AD-WMD than in AD, though the differences did not reach statistical significance between the groups (fig 2).

*Fig. 2. Insert here*

Clinically diagnosed TIA / stroke was recorded in three AD and four AD-WMD cases but stroke was not pathologically verified in any of the cases. Diabetes mellitus was found in one single AD case and in two AD-WMD cases.

Mean AD pathology (whole brain and temporo-limbic assessments) was equally severe in both groups (table 1). Brain weight (not shown in table) correlated inversely with the severity of AD pathology in both groups.

## **5. Discussion**

In this study cardiovascular features were investigated and compared in AD-WMD and in AD without white matter disease. In many earlier studies, mixed VaD-AD and pure groups of AD and VaD, respectively, were compared with regard to cardiovascular features (Jellinger and Mitter-Ferstl, 2003; Mungas et al., 2001; Wallin et al., 2000), but few studies, especially among those including a neuropathological examination, have focused on cardiovascular features in the AD-group alone.

### *5.1. Cardiovascular features.*

In clinical dementia research hypertension and orthostatic hypotension are frequently investigated features (Eguchi et al., 2004; Passant, 1997; Skoog, 1998; van Dijk et al., 2004), and an association between elevated blood pressure and white matter lesions is recognized (de Leeuw et al., 1999; de Leeuw et al., 2004; Dufouil et al., 2001; Lazarus et al., 2005; Liao et al., 1997). An interesting finding in the present study was that hypertension as well as orthostatic hypotension were more frequent in AD-WMD than in AD without WMD. Hypertension preceded orthostatic hypotension in only one case (AD-WMD), however, and the elevated versus low blood pressure levels were found in separate groups among the 44 cases. Earlier studies have shown that midlife hypertension increases the risk of Alzheimer's disease in later life (Kivipelto et al., 2001; Skoog et al., 1999). These latter studies, however, had no neuropathological confirmation of the clinical diagnoses, or reference to any coexisting WMD. Even though we found more hypertension in AD-WMD than in AD without WMD, the total number of individuals in which hypertension was recorded at some

point was only 13 out of a total number of 44. The number of verified nonhypertensive AD cases was 9 (of 44), whereas in the remaining cases, hypertension was not explicitly negated. Previous studies have shown that variability in blood pressure has a stronger correlation to WMD than hypertension per se (Puisieux et al., 2001; van Dijk et al., 2004). One may speculate that a lack of capacity to regulate abnormal blood pressure, well recognized in AD (Burke et al., 1994), leads to recurrent dysfunction of cerebral perfusion and leaves room for the development of WMD (Englund, 1988).

Antihypertensive medication was considered when appropriate. Medication strategies, as well as the number of drugs used, varied markedly in all cases, and there was no significant difference between AD and AD-WMD in this respect.

As regards cardiac features, shown to be associated with WMD in an earlier study (Englund et al., 1989), there was a tendency towards more symptoms (arrhythmia, angina, etc) in the AD-WMD group, but this could not be verified statistically (Fig 2.).

Diabetes mellitus, another potential vascular risk factor, was rare in both groups. The same finding was reported previously by us (Passant et al., 1997) and others (Tiberghien et al., 1993).

## *5.2. Clinical symptoms.*

Of all the symptoms investigated, dizziness/unsteadiness emerged as the symptom possibly associated with WMD, and was significantly more frequent in the AD-WMD group. Although we were aware of the difference between the connotations of dizziness and unsteadiness, we did not attempt to subcategorize the two entities in this material.

Lower limb weakness was reported in AD patients with CT verified leukoaraiosis already in 1987 (Steingart et al., 1987). It is reasonable to anticipate frequent falls and/or drop attacks in the group with reported dizziness/unsteadiness, but this association, however, was not found

in our material. We suggest that falls and dizziness/unsteadiness often have different geneses; both features, however, having a multifactorial background.

The extent to which the presence of WMD increases the likelihood of a dementia diagnosis in patients with asymptomatic low-grade AD pathology and the extent to which it may accentuate cortical AD pathology or clinical dementia in subclinical or manifest AD is still to be determined (Capizzano et al., 2004; Greenberg, 2002; Iadecola and Gorelick, 2003; Prins et al., 2004). Perhaps concurrent WMD and other forms of ischemic cerebrovascular disease are likely to cause a deterioration from preclinical to clinical AD (Englund, 1988; Jellinger and Attems, 2005; Jellinger and Mitter-Ferstl, 2003; Roman and Royall, 2004; Snowden et al., 1997)

To summarise, it is generally difficult to clinically separate AD from AD with WMD in a standardised diagnostic investigation. Symptoms of dizziness / unsteadiness might be a distinguishing feature and a sign of WMD, of value for future treatment attempts.

## **6. Acknowledgements**

This study was supported by the Swedish Alzheimer Foundation, Stiftelsen Ellen och Henrik Sjöbrings Minnesfond and the Swedish Research Council (projects no K2005-21X-03950-33A). Professor A. Brun is acknowledged for early diagnostic work on the material and advice. Special thanks to Anders Magnusson for statistical advice, to Helena Andersson for secretarial assistance and to Rose Ready for language check.

## 7. References

- Andin, U., Gustafson, L., Passant, U., Brun, A., 2005. A clinico-pathological study of heart and brain lesions in vascular dementia. *Dement. Geriatr. Cogn. Disord.* 19, 222-228.
- Braak, H., Braak, E., 1991. Neuropathological staging of Alzheimer-related changes. *Acta. Neuropathol. (Berl.)* 82, 239-259.
- Brun, A., Englund, E., 1981. Regional pattern of degeneration in Alzheimer's disease: neuronal loss and histopathological grading. *Histopathology.* 5, 549-64.
- Brun, A., Englund, E., 1986. A white matter disorder in dementia of the Alzheimer type: a pathoanatomical study. *Ann. Neurol.* 19, 253-262.
- Brun, A., Gustafson, L., 1993. The Lund Longitudinal Dementia Study: A 25-year perspective on neuropathology, differential diagnoses and treatment, in: Zatta, P. (Ed.), *Alzheimer's Disease: Advances in Clinical and Basic Research*, John Wiley & Sons Ltd, pp. 3-18.
- Burke, W.J., Coronado, P.G., Schmitt, C.A., Gillespie, K.M. and Chung, H.D., 1994. Blood pressure regulation in Alzheimer's disease. *J. Auton. Nerv. Syst.* 48, 65-71.
- Capizzano, A.A., Acion, L., Bekinschtein, T., Furman, M., Gomila, H., Martinez, A., Mizrahi, R., Starkstein, S.E., 2004. White matter hyperintensities are significantly associated with cortical atrophy in Alzheimer's disease. *J. Neurol. Neurosurg. Psychiatry.* 75, 822-827.
- de la Torre, J.C., 2004. Is Alzheimer's disease a neurodegenerative or a vascular disorder? Data, dogma and dialectics. *Lancet. Neurol.* 3, 184-190.
- de Leeuw, F.E., Barkhof, F., Scheltens, P., 2005. Progression of cerebral white matter lesions in Alzheimer's disease: a new window for therapy? *J. Neurol. Neurosurg. Psychiatry.* 76, 1286-1288.

- de Leeuw, F.E., de Groot, J.C., Oudkerk, M., Witteman, J.C., Hofman, A., van Gijn, J., Breteler, M.M., 1999. A follow-up study of blood pressure and cerebral white matter lesions. *Ann. Neurol.* 46, 827-833.
- de Leeuw, F.E., Richard, F., de Groot, J.C., van Duijn, C.M., Hofman, A., Van Gijn, J., Breteler, M.M., 2004. Interaction between hypertension, apoE, and cerebral white matter lesions. *Stroke.* 35, 1057-1060.
- Dufouil, C., de Kersaint-Gilly, A., Besancon, V., Levy, C., Auffray, E., Brunnereau, L., Alperovitch, A., Tzourio, C., 2001. Longitudinal study of blood pressure and white matter hyperintensities: the EVA MRI Cohort. *Neurology.* 56, 921-926.
- Eguchi, K., Kario, K., Hoshida, S., Hoshida, Y., Ishikawa, J., Morinari, M., Hashimoto, T., Shimada, K., 2004. Greater change of orthostatic blood pressure is related to silent cerebral infarct and cardiac overload in hypertensive subjects. *Hypertens. Res.* 27, 235-241.
- Englund, E., 1988. A white matter disease in dementia. A study with special reference to Alzheimer's disease, Lund University, Thesis.
- Englund, E., Brun, A., Alling, C., 1988. White matter changes in dementia of Alzheimer's type. Biochemical and neuropathological correlates. *Brain.* 111, 1425-1439.
- Englund, E., Brun, A., Gustafson, L., 1989. A white-matter disease in dementia of Alzheimer's type-clinical and neuropathological correlates. *Int. J. Geriatr. Psychiatry.* 4, 87-102.
- Englund, E., Risberg, J., Passant, U., Gustafson, L., 2002. The appearance of white matter changes in the course of Alzheimer's disease. *Neurobiol. Aging.* 23, S489.
- Greenberg, S.M., 2002. Cerebral amyloid angiopathy and dementia: two amyloids are worse than one. *Neurology.* 58, 1587-1588.

- Haglund, M., Englund, E., 2002. Cerebral amyloid angiopathy, white matter lesions and Alzheimer encephalopathy - a histopathological assessment. *Dement. Geriatr. Cogn. Disord.* 14, 161-166.
- Iadecola, C., Gorelick, P.B., 2003. Converging pathogenic mechanisms in vascular and neurodegenerative dementia. *Stroke.* 34, 335-337.
- Jellinger, K.A., Attems, J., 2005. Prevalence and pathogenic role of cerebrovascular lesions in Alzheimer disease. *J. Neurol. Sci.* 229-230, 37-41.
- Jellinger, K.A., Mitter-Ferstl, E., 2003. The impact of cerebrovascular lesions in Alzheimer disease--a comparative autopsy study. *J. Neurol.* 250, 1050-1055.
- Kalaria, R.N., Kenny, R.A., Ballard, C.G., Perry, R., Ince, P., Polvikoski, T., 2004. Towards defining the neuropathological substrates of vascular dementia. *J. Neurol. Sci.* 226, 75-80.
- Kivipelto, M., Helkala, E.L., Laakso, M.P., Hanninen, T., Hallikainen, M., Alhainen, K., Soininen, H., Tuomilehto, J., Nissinen, A., 2001. Midlife vascular risk factors and Alzheimer's disease in later life: longitudinal, population based study. *BMJ.* 322, 1447-1451.
- Langa, K.M., Foster, N.L., Larson, E.B., 2004. Mixed dementia: emerging concepts and therapeutic implications. *JAMA.* 292, 2901-2908.
- Lazarus, R., Prettyman, R., Cherryman, G., 2005. White matter lesions on magnetic resonance imaging and their relationship with vascular risk factors in memory clinic attenders. *Int. J. Geriatr. Psychiatry.* 20, 274-279.
- Liao, D., Cooper, L., Cai, J., Toole, J., Bryan, N., Burke, G., Shahar, E., Nieto, J., Mosley, T., Heiss, G., 1997. The prevalence and severity of white matter lesions, their relationship with age, ethnicity, gender, and cardiovascular disease risk factors: the ARIC Study. *Neuroepidemiology.* 16, 149-162.

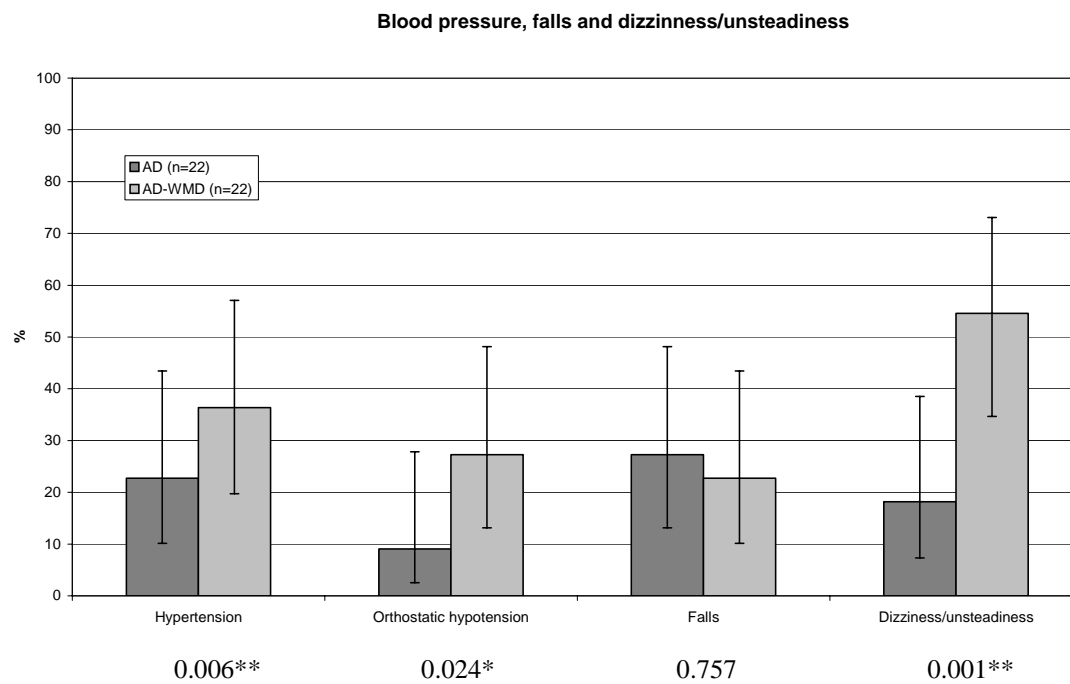
- Londos, E., Passant, U., Gustafson, L., Brun, A., 2001. Neuropathological correlates to clinically defined dementia with Lewy bodies. *Int. J. Geriatr. Psychiatry*. 16, 667-679.
- Mathias, C.J., Bannister, R., 1992. Investigation of autonomic disorders, in: Bannister, R., Mathias, C.J. (Eds.), *Autonomic Failure. A Textbook of Clinical Disorders of the Autonomic Nervous System*. Oxford University Press, Oxford, pp. 255-290.
- Mirra, S.S., Heyman, A., McKeel, D., Sumi, S.M., Crain, B.J., Brownlee, L.M., Vogel, F.S., Hughes, J.P., van Belle, G., Berg, L., 1991. The Consortium to Establish a Registry for Alzheimer's Disease (CERAD). Part II. Standardization of the neuropathologic assessment of Alzheimer's disease. *Neurology*. 41, 479-486.
- Mungas, D., Reed, B.R., Ellis, W.G. and Jagust, W.J., 2001. The effects of age on rate of progression of Alzheimer disease and dementia with associated cerebrovascular disease. *Arch. Neurol*. 58, 1243-1247.
- Newcombe, R.G., Altman, D.G., 2000. Proportions and their differences, in: Altman, D.G., Machin, D., Bryant, T.N., Gardner, M.J. (Eds.), *Statistics with Confidence*. BMJ Books, London, pp. 45-56.
- Passant, U., Warkentin, S., Gustafson, L., 1997. Orthostatic hypotension and low blood pressure in organic dementia: a study of prevalence and related clinical characteristics. *Int. J. Geriatr. Psychiatry*. 12, 395-403.
- Prins, N.D., van Dijk, E.J., den Heijer, T., Vermeer, S.E., Koudstaal, P.J., Oudkerk, M., Hofman, A., Breteler, M.M., 2004. Cerebral white matter lesions and the risk of dementia. *Arch. Neurol*. 61, 1531-1534.
- Puisieux, F., Monaca, P., Deplanque, D., Delmaire, C., di Pompeo, C., Monaca, C., Leys, D., Pruvo, J.P., Dewailly, P., 2001. Relationship between leuko-araiosis and blood pressure variability in the elderly. *Eur. Neurol*. 46, 115-120.



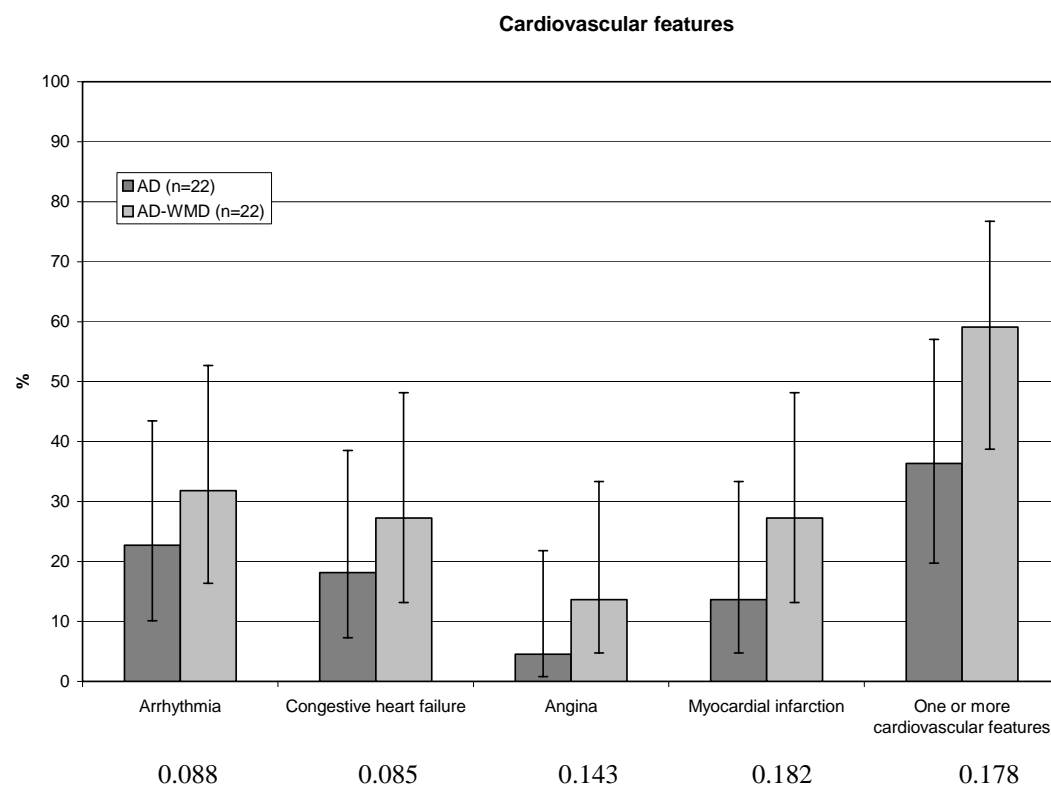
- Roman, G.C., Royall, D.R., 2004. A diagnostic dilemma: is "Alzheimer's dementia" Alzheimer's disease, vascular dementia, or both? *Lancet. Neurol.* 3, 141.
- Skoog, I., 1998. A review on blood pressure and ischaemic white matter lesions. *Dement. Geriatr. Cogn. Disord.* 9, S13-S19.
- Skoog, I., Kalaria, R.N., Breteler, M.M., 1999. Vascular factors and Alzheimer disease. *Alzheimer. Dis. Assoc. Disord.* 13, S106-S114.
- Snowdon, D.A., Greiner, L.H., Mortimer, J.A., Riley, K.P., Greiner, P.A., Markesbery, W.R., 1997. Brain infarction and the clinical expression of Alzheimer disease. The Nun Study. *JAMA.* 277, 813-817.
- Steingart, A., Hachinski, V.C., Lau, C., Fox, A.J., Fox, H., Lee, D., Inzitari, D., Merskey, H., 1987. Cognitive and neurologic findings in demented patients with diffuse white matter lucencies on computed tomographic scan (leuko-araiosis). *Arch. Neurol.* 44, 36-39.
- Thulin, T., Liedholm, H., 1993. *Hypertoni, Almqvist & Wiksell, Stockholm.*
- Tiberghien, D., Robitaille, Y., Laroche-Cholette, A., Houde, L., Grenon, M., Gauvreau, D., 1993. Retrospective Assessment of Relative Risks of Coronary Arteriosclerosis and Myocardial Infarct in Autopsy Confirmed Dementias of the AD and Non-AD Types, John Wiley & Sons Ltd.
- Wallin, A., Blennow, K., 1996. Clinical subgroups of the Alzheimer syndrome. *Acta. Neurol. Scand. Suppl.* 165, 51-57.
- Wallin, A., Sjogren, M., Edman, A., Blennow, K., Regland, B., 2000. Symptoms, vascular risk factors and blood-brain barrier function in relation to CT white-matter changes in dementia. *Eur. Neurol.* 44, 229-235.
- van Dijk, E.J., Breteler, M.M., Schmidt, R., Berger, K., Nilsson, L.G., Oudkerk, M., Pajak, A., Sans, S., de Ridder, M., Dufouil, C., Fuhrer, R., Giampaoli, S., Launer, L.J.,

- Hofman, A., 2004. The association between blood pressure, hypertension, and cerebral white matter lesions: cardiovascular determinants of dementia study. *Hypertension*. 44, 625-630.
- Wang, L., Zhang, J., Xie, H., 2002. Negative relationship between severity of atherosclerosis and Alzheimer-like pathologic changes in hippocampus - a quantitative study. *Neurobiol. Aging*. 23, S490.
- World Health Organization, 1992. The ICD-10 Classification of Mental and Behavioural Disorders: Clinical Descriptions and Diagnostic Guidelines, World Health Organization, Geneva.

**Fig. 1**



**Fig. 2**



## Figure Legends

Fig. 1

Blood pressure, falls and dizziness/ unsteadiness in AD and AD-WMD, frequency (%) and confidence intervals for proportions. Fisher's exact test (\* $p < 0.05$ , \*\* $p < 0.01$ ).

Fig. 2

Cardiovascular features in AD and AD-WMD, frequency (%) and confidence intervals for proportions. Fisher's exact test (\* $p < 0.05$ , \*\* $p < 0.01$ ).

Table 1. Demographic and pathological data for Alzheimer's disease (AD) and AD with white matter disease (AD-WMD).

| AD             |              |  |  |  | AD-WMD         |              |  |  |  |
|----------------|--------------|--|--|--|----------------|--------------|--|--|--|
| Pat.nr /gender | Age at death | Nonfocal white matter pathology <sup>1</sup> | Whole brain AD pathology Brun/Englund <sup>2</sup> | Temporo-limbic AD pathology Braak <sup>3</sup> | Pat.nr /gender | Age at death | Nonfocal white matter pathology <sup>1</sup> | Whole brain AD pathology Brun/Englund <sup>2</sup> | Temporo-limbic AD pathology Braak <sup>3</sup> |
| 1 m            | 80           | 0  | 3  | V  | 23 f           | 82           | 1  | 3  | V  |
| 2 f            | 77           | 0  | 3  | V  | 24 f           | 88           | 3  | 2  | V  |
| 3 f            | 73           | 0  | 3  | IV   | 25 f           | 85           | 1  | 3  | VI   |
| 4 m            | 61           | 0  | 3  | VI   | 26 f           | 84           | 1  | 3  | VI   |
| 5 m            | 78           | 0  | 3  | IV   | 27 f           | 83           | 1  | 3  | V  |
| 6 f            | 72           | 0  | 3  | VI   | 28 f           | 76           | 2  | 3  | V  |
| 7 f            | 79           | 0  | 3  | V  | 29 m           | 66           | 1  | 3  | IV   |
| 8 f            | 91           | 0  | 3  | VI   | 30 f           | 72           | 3  | 2  | IV   |
| 9 f            | 88           | 0  | 3  | VI   | 31 f           | 85           | 2  | 3  | VI   |
| 10 f           | 61           | 0  | 3  | V  | 32 f           | 81           | 1  | 3  | V  |
| 11 f           | 78           | 0  | 3  | V  | 33 f           | 75           | 1  | 2  | V  |
| 12 f           | 67           | 1  | 3  | IV   | 34 m           | 82           | 2  | 3  | V  |
| 13 m           | 62           | 0  | 3  | V  | 35 f           | 89           | 2  | 3  | V  |
| 14 m           | 81           | 0  | 2  | VI   | 36 f           | 81           | 2  | 2  | III-IV   |
| 15 m           | 78           | 0  | 2  | V  | 37 f           | 91           | 2  | 2  | III  |
| 16 f           | 81           | 1  | 2  | VI   | 38 m           | 89           | 1  | 2  | V  |
| 17 m           | 65           | 0  | 2  | IV   | 39 m           | 62           | 2  | 3  | VI   |
| 18 m           | 77           | 0  | 2  | V  | 40 f           | 86           | 2  | 3  | VI   |
| 19 f           | 58           | 0  | 2  | V  | 41 m           | 80           | 1  | 2  | V  |
| 20 m           | 88           | 0  | 2  | III  | 42 f           | 91           | 2  | 3  | VI   |
| 21 f           | 70           | 0  | 3  | V  | 43 m           | 76           | 2  | 3  | VI   |
| 22 f           | 71           | 0  | 2  | IV   | 44 m           | 79           | 1  | 3  | V  |
| Mean           | 74.4         | (0.09)                                       | 2.64   |  | Mean           | 81.1         | (1.64)                                       | 2.68   |  |
| SD             | 9.26         | (0.29)                                       | 0.49   |  | SD             | 7.58         | (0.66)                                       | 0.48   |  |

<sup>1</sup>Mild =1, Moderate=2, Severe=3

<sup>2</sup>Grade of AD pathology according to Brun and Englund 1981

<sup>3</sup>Temporolimbic stage according to Braak and Braak 1991

Differences in AD-pathology between the groups: Fisher's exact test: p=1.000

Differences in WMH-pathology between the groups:  $\chi^2$ -test: p=0.000\*\*\*