



LUND UNIVERSITY

Observations on cerebral amyloid angiopathy and microvascular pathology in Alzheimer's disease and vascular dementia

Haglund, Mattias

2005

[Link to publication](#)

Citation for published version (APA):

Haglund, M. (2005). *Observations on cerebral amyloid angiopathy and microvascular pathology in Alzheimer's disease and vascular dementia*. [Doctoral Thesis (compilation), Tumor microenvironment]. Department of Clinical Sciences, Lund University.

Total number of authors:

1

General rights

Unless other specific re-use rights are stated the following general rights apply:

Copyright and moral rights for the publications made accessible in the public portal are retained by the authors and/or other copyright owners and it is a condition of accessing publications that users recognise and abide by the legal requirements associated with these rights.

- Users may download and print one copy of any publication from the public portal for the purpose of private study or research.
- You may not further distribute the material or use it for any profit-making activity or commercial gain
- You may freely distribute the URL identifying the publication in the public portal

Read more about Creative commons licenses: <https://creativecommons.org/licenses/>

Take down policy

If you believe that this document breaches copyright please contact us providing details, and we will remove access to the work immediately and investigate your claim.

LUND UNIVERSITY

PO Box 117
221 00 Lund
+46 46-222 00 00

Observations on cerebral amyloid angiopathy
and microvascular pathology in
Alzheimer's disease and vascular dementia

Doctoral thesis

Mattias Haglund

Department of Clinical Sciences
Lund University

With due permission by the Faculty of Medicine
at Lund University to be defended publicly
at the Department of Pathology, December 2nd, 13.00

External examiner: Professor Irina Alafuzoff, Kuopio, Finland

© Mattias Haglund 2005
ISBN 91-85481-02-5
ISSN 1652-8220
Printed by Media-Tryck
Lund, Sweden, 2005

To my parents.

Abstract

Dementia is a state of permanent loss of cognitive function, most commonly affecting the elderly. With a rapidly growing aged population, the spectrum of disorders that lead to dementia is exerting an ever-increasing toll on patients, families and society alike. The most common dementing disorders are Alzheimer's disease and vascular dementia. Although Alzheimer's disease is very common and was described almost a century ago, the pathomechanisms are imperfectly understood, and mainly symptomatic therapy is available. Treatment options are even more meagre in vascular dementia, but in many cases, this disorder can possibly be prevented by risk factor management.

Since both Alzheimer's disease and vascular dementia are common in the elderly population, it is not uncommon for both diseases to be present to some degree in the same patient. Increasing evidence suggests that the disease mechanisms not only coexist, but that they interact synergistically, further exacerbating the clinical disorder. The purpose of this thesis was to explore features of vascular pathology in Alzheimer's disease and vascular dementia, to improve basic understanding of the disease processes in play.

We have shown that one of the major hallmarks of Alzheimer's disease, deposition of amyloid protein in the cerebrovasculature (cerebral amyloid angiopathy), is surprisingly common in vascular dementia, and frequently more severe than in Alzheimer's disease. In Alzheimer's disease, cerebral amyloid angiopathy is associated with ischemic white matter disease, but in vascular dementia, cerebral amyloid angiopathy is associated with cortical microinfarctions. Furthermore, the interrelationship between the amyloid beta (A β) peptide species deposited is affected by the presence of cerebrovascular disease, which is associated with a relative increase in deposition of the more fibrillogenic and toxic variant of the A β peptide, and more severe degeneration of vascular components.

Original papers

This thesis is based on the following papers, which will be referred to by their Roman numerals:

I. Haglund M, Englund E. Cerebral amyloid angiopathy, white matter lesions and Alzheimer encephalopathy - a histopathological assessment. *Dement Geriatr Cogn Disord.* 2002;14:161-6.

II. Haglund M, Sjöbeck M, Englund E. Severe cerebral amyloid angiopathy characterizes an underestimated variant of vascular dementia. *Dement Geriatr Cogn Disord.* 2004;18:132-7.

III. Haglund M, Passant U, Sjöbeck M, Ghebremedhin E, Englund E. Cerebral amyloid angiopathy and cortical microinfarcts as putative substrates of vascular dementia. Submitted.

IV. Haglund M, Kalaria RN, Slade JY, Englund E. Differential deposition of amyloid beta peptides in cerebral amyloid angiopathy associated with Alzheimer's disease and vascular dementia. Submitted.

V. Haglund M, Sjöbeck M, Englund E. Locus ceruleus degeneration is ubiquitous in Alzheimer's disease - possible implications for diagnosis and treatment. Submitted.

Papers I and II are reprinted by permission of S. Karger AG, Basel, Switzerland.

Serenity now

List of abbreviations

A β	Amyloid beta
A40	40-amino acid variant of the amyloid beta peptide
A42	42-amino acid variant of the amyloid beta peptide
Ach	Acetylcholine
AchE	Acetylcholine esterase
AchEi	Acetylcholine esterase-inhibitors
AD	Alzheimer's disease
AE	Alzheimer encephalopathy
ApoE	Apolipoprotein E
APP	Amyloid precursor protein
CAA	Cerebral amyloid angiopathy
CERAD	Consortium to Establish a Registry for Alzheimer's Disease
CT	Computerized tomography
fMRI	Functional magnetic resonance imaging
HAAS	Honolulu-Asia Aging Study
HCHWA-D	Hereditary cerebral hemorrhage with amyloidosis – Dutch type
HCHWA-I	Hereditary cerebral hemorrhage with amyloidosis – Icelandic type
LC	Locus ceruleus
LRP	Low-density lipoprotein receptor-related protein
MD	Mixed dementia
MID	Multi-infarct dementia
MRC	Medical Research Council
MRI	Magnetic resonance imaging
NBM	Nucleus basalis of Meynert
NIA	National Institute on Aging
PET	Positron emission tomography
RAGE	Receptor for advanced glycation end-products
SDAT	Senile dementia of the Alzheimer type
SIWI	Selective incomplete white matter infarction
SMA	Smooth muscle actin
VaD	Vascular dementia
VaD-ac	Vascular dementia with concomitant (but minor) Alzheimer encephalopathy
WMD	White matter disease
WML	White matter lesions

Table of Contents

Introduction	1
Dementia and dementing disorders	1
Alzheimer's disease	1
Vascular dementia	3
Other dementing disorders	4
Epidemiology of dementia	5
Epidemiology of Alzheimer's disease and vascular dementia	6
Repercussions on society	7
Background	9
Alzheimer's disease – disease mechanisms and pathology	11
The amyloid hypothesis	11
Apolipoprotein E and Alzheimer's disease	15
Nerve cell nuclei and neurotransmitters	16
Neuropathological diagnosis of Alzheimer's disease	18
Mechanisms of vascular dementia	19
The connection between Alzheimer's disease and vascular dementia	20
White matter pathology in dementia	21
- Definition of terms	21
Cerebral amyloid angiopathy	23
Pathogenesis of cerebral amyloid angiopathy	26
Cerebral amyloid angiopathy in Alzheimer's disease	27
Apolipoprotein E, cerebral amyloid angiopathy and the two major amyloid beta peptide species	27
Anti-amyloid treatment of Alzheimer's disease	28
Cerebral amyloid angiopathy as a putative complication of anti-amyloid treatment of Alzheimer's disease	30
Aims	31
The present investigation	33
Paper I: Cerebral amyloid angiopathy, white matter lesions and Alzheimer encephalopathy – a histopathological assessment	34
Paper II: Severe cerebral amyloid angiopathy characterizes an underestimated variant of vascular dementia	36
Paper III: Cerebral amyloid angiopathy and cortical microinfarcts as putative substrates of vascular dementia	38
Paper IV: Differential deposition of amyloid beta peptides in cerebral amyloid angiopathy associated with Alzheimer's disease and vascular dementia	40

Paper V: Locus ceruleus degeneration is ubiquitous in Alzheimer's disease - possible implications for diagnosis and treatment	42
Conclusions	45
Populärvetenskaplig sammanfattning på svenska	47
Acknowledgements	49
References	51
Paper I	75
Paper II	85
Paper III	95
Paper IV	117
Paper V	139

Introduction

Dementia and dementing disorders

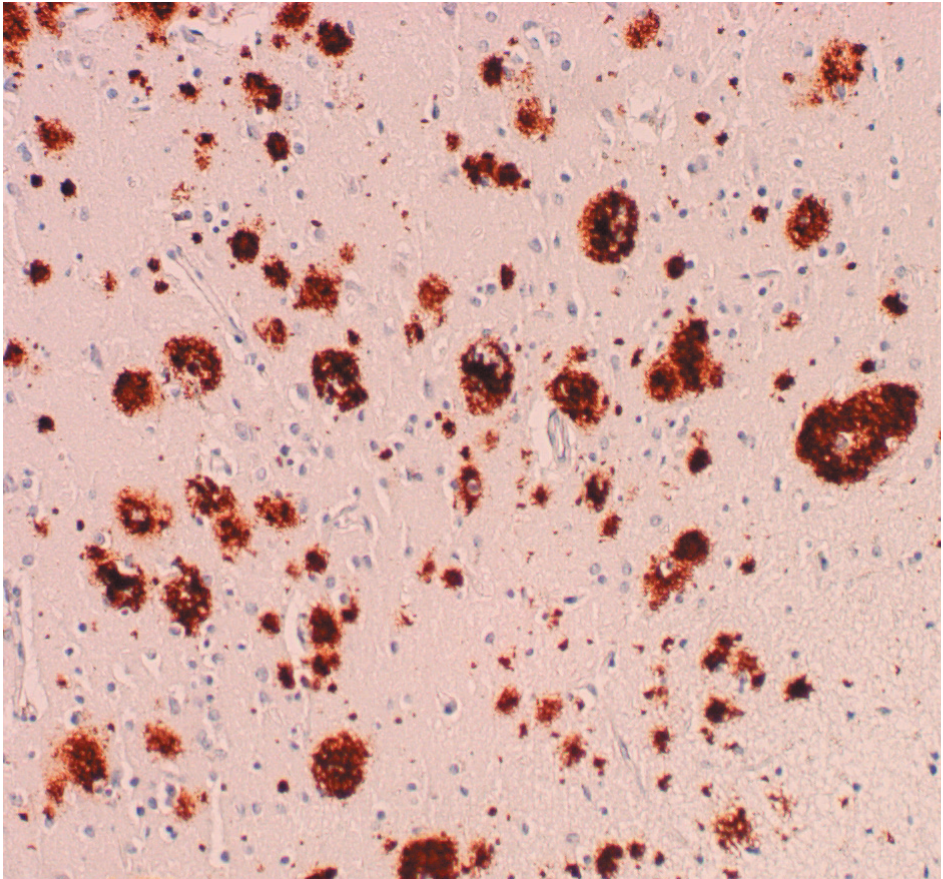
The concept of dementia (Latin: “de mens”, without mind) in the elderly was described by Greek and Roman scholars thousands of years ago. It refers to a state where cognitive function is permanently and irreversibly impaired, and thus differentiates it from states where the cognitive impairment is reversible by correction of underlying factors (for instance cobalamin deficiency or pseudodementia due to depression) or states where the cognitive impairment is transient (for instance delirium or intoxication). Dementia per se is not a diagnosis. The term dementia describes a state of impairment of several cognitive domains. At the root of the problem, in turn, is an underlying diagnosis.

Several diseases and conditions may lead to dementia, the most common of which are Alzheimer’s disease (AD) and vascular dementia (VaD).

Alzheimer’s disease

In 1907, German psychiatrist and neuropathologist Alois Alzheimer published a report on a fascinating case (Alzheimer, 1907). A 51-year-old woman, “Auguste D”, presented with a puzzling clinical condition, with diverse psychiatric and neurological symptoms such as memory deficits, irritability and language difficulties. When Auguste D deceased only a few years later, the neuropathological examination conducted by Alzheimer showed a conspicuous presence of argyrophilic plaques (“amyloid plaques”) in the cerebral cortex (picture 1), as well as thread- or flame-like intraneuronal structures (“neurofibrillary tangles”).

Initially, the diagnosis of AD referred to a rare disease of “presenile” dementia, i.e. dementia occurring before the age of 65. Dementia with AD-like symptoms occurring at an older age, which has always been relatively prevalent, was called “Senile Dementia of the Alzheimer Type” (SDAT). The terms “hereditary” or “familial” and “sporadic” AD have also been used to distinguish between AD in elderly and relatively younger (45-65 years old) patients. Since the disease forms are generally considered to be pathologically similar, and believed to arise by the same or at least partly the same pathomechanisms, the term AD at present refers to both presenile AD and



Picture 1. Amyloid plaque pathology of the cerebral cortex. Note that in this particular section, there is no apparent cerebral amyloid angiopathy.

SDAT, despite the fact that there is considerable clinical heterogeneity (Blennow, 1992; Raskind, 1995; Menendez, 2004).

The clinical presentation of AD is naturally very variable, but most commonly, one of the earliest symptoms is mild forgetfulness, which progresses insidiously. At times, the patient may forget how to carry out simple tasks like cooking or filling out forms. These symptoms progress until the patient becomes completely dependent on others to help with his or her activities of daily living.

Vascular dementia

The first observation that patients afflicted by stroke often develop permanent cognitive deficit has been ascribed to Thomas Willis in 1672. This condition was further characterized by Otto Binswanger and Alois Alzheimer in the late 19th century (Roman, 2003). Interest in the disorder surged in the mid-late 20th century when Hachinski proposed the concept of multi-infarct dementia (MID) (Hachinski, 1974). The history of the relationship between cerebrovascular disease and cognitive impairment has recently been reviewed (Gustafson, 2004a).

The term MID has been criticized because it only applies to a subgroup of patients with VaD. In fact, the spectrum of pathology in VaD is very broad, and for that and other reasons, it has been subject to intense debate (Wallin, 1994; Hulette 1997; Stewart, 2002). A multitude of systems and schemes for clinical and pathological diagnosis and subclassification have been introduced (Konno, 1997; Kalaria, 2004; Stewart, 2004), but so far, no system has been accepted globally.

The clinical presentation of VaD is also very heterogeneous (Desmond, 1999), but it is typically described as being less insidious in terms of its onset, with more of a stepwise decline in abilities (Hachinski, 1975). Neurological deficits such as aphasia and gait impairment typically appear early (status post stroke) in this condition compared to in AD, and memory deficits are typically less pronounced (Rockwood, 2002). It deserves mentioning that this “typical” presentation of VaD may be less common than has traditionally been believed, and may actually apply in less than half of VaD cases (Gustafson, 2004b).

Even though it is oftentimes difficult to distinguish between AD and VaD based on the clinical picture alone, a few of the typical findings in each disorder are shown in table 1.

Alzheimer's disease	Vascular dementia
Insidious onset, steady decline	Abrupt onset, stepwise decline
Memory deficits prominent	Depression prominent
Focal neurological symptoms appear late in the process	Focal neurological symptoms appear early and may precede dementia

Table 1. "Typical" features that may help distinguish Alzheimer's disease from vascular dementia.

Other dementing disorders

Even though AD and VaD are by far the most common causes of dementia, there is a vast range of other dementing disorders. The clinical and pathological features of these disorders are constantly appraised and reappraised, and for the scope of this thesis, there is little reason to make more than a cursory description of the most commonly discussed diseases and syndromes.

Table 2 outlines a few other important disorders that may cause dementia.

Name of disorder	Features
Pick's disease	Bizarre behavior, aggression, hypersexuality
Frontal lobe degeneration	Similar to Pick's
Lewy body dementia	Visual hallucinations, fluctuating mentation, parkinsonism
Parkinson plus	Dementia (often with behavioral changes) superimposed on Parkinson-like disease
Alcohol-related dementia	Ataxia, peripheral neuropathy, global cognitive deficits
Argyrophilic grain disease	Memory deficits, preserved cognition, personality change
Creutzfeldt-Jakob's disease	Rapidly progressive dementia with vertigo, myoclonia, EEG abnormalities and changes in consciousness

Table 2. Important disorders associated with dementia. These disorders range from very rare to relatively common, but their relative prevalences are highly disputed.

Epidemiology of dementia

A clear picture of the magnitude of the challenges that the spectrum of dementing disorders poses cannot be obtained without a basic understanding of how prevalent they are. Unlike many other phenomena investigated by medical researchers today, dementia is a distinctly common condition. Accounts vary, but in people above 65 years of age, most studies show a prevalence of dementia in the 4-10% range (Folstein, 1991; Canadian Study of Health and Aging, 1994; Wang, 2000), depending on the population studied and what criteria of dementia are applied (Erkinjuntti, 1997). For a population of 85 years of age or older, those numbers increase dramatically to 23-33% (Heeren, 1991; Skoog, 1993; Ebly, 1994; Ott, 1995). An interesting and frequently quoted finding is that the prevalence of dementia doubles roughly every five years in the 65 to 85 age range (Jorm, 1987). Another measure of how common dementia is in the elderly is the finding that almost 10% of

non-demented elderly between the ages of 85 and 88 become demented each year (Aevarsson, 1996).

Worldwide, approximately 25,000,000 people are estimated to be suffering from dementia (Wimo, 2003), 7,000,000 of whom in Europe (Wancata, 2003). As many as 150,000-200,000 could be affected in Sweden alone.

Epidemiology of Alzheimer's disease and vascular dementia

In most populations, neuropathological examinations have shown AD to be the pathological substrate of dementia in approximately half to two thirds of all clinical dementia patients (Jorm, 1991; Brun, 1993; Hendrie, 1998), VaD being the second most common with numbers ranging from 9% (Jellinger, 2002) to 26% (Brun, 1993) reported. These numbers are subject to intense debate, however, and depend heavily on the methods used for diagnosis and the populations studied. Because both AD and VaD are very common entities in any elderly population, they coexist in a large number of cases, possibly as many as an additional 20-40% (Zekry, 2002), again depending on the criteria applied. The coexistence of AD and VaD is often referred to as "mixed" dementia (MD) (for a recent review, see Langa, 2004).

AD has been found to be the most common cause of dementia (Jorm, 1991; Fratiglioni, 2000; Vas, 2001) in every studied population except for the Japanese (where VaD is generally reported to be more common (Yoshitake, 1995; Ueda, 2002; Yanagihara 2002)). It should be noted, however, that there is a trend toward VaD becoming relatively less prevalent in Asian countries with a traditionally high prevalence (China, Japan, Korea etc) (Suh, 2001), and there have been reports based on Japanese populations where AD was found to be the most common cause of dementia (Akatsu, 2002; Meguro, 2002).

As we will discuss later, epidemiological studies on dementia are hampered by the fact that a definite diagnosis of AD or VaD requires post-mortem neuropathological examination. This may help explain the conflicting results from different countries and regions. It could also have an impact on the confusion regarding the relative prevalences of AD, MD and VaD in South-east Asia, where the practice of postmortem diagnosis has historically been considered culturally unacceptable.

Repercussions on society

Since the 80+ age group is the segment of the population that grows the most rapidly in developed nations (Kinsella, 2001), it is logical that the prevalence of dementia will increase dramatically as a consequence. In fact, the prospect of a rapidly growing population of patients suffering from age-related disorders such as dementia is increasingly being considered a threat to the future health care economy (Brookmeyer, 1998; Sadik, 2003; Khachaturian, 2005). Estimates of the total cost of dementia are naturally fraught with difficulties, but even the very broad range discussed (the total cost in the US for AD alone is estimated at \$5.6-\$88.3 billion annually (Bloom, 2003)) indicates that the impact on society is significant. The total cost of dementing disorders in Sweden was estimated at more than 30 billion SEK as early as in 1991 (Wimo, 1997).

In Europe, there are currently approximately 70 persons of working age for every patient suffering from dementia, but if current trends do not abate, by the year 2050 that ratio will have changed to 20:1 (Wancata, 2003). Unless there is a dramatic change in the way dementing disorders can be prevented and/or treated, there is little doubt that the financial consequences alone will be devastating (for an interesting perspective on the situation that looms in the US, see eg McConnell, 2005). It is difficult to envision the already strained healthcare delivery systems of today being able to withstand the challenges of the future.

Background

This chapter gives a brief background on current hypotheses regarding

- pathomechanisms of AD and VaD
- the amyloid hypothesis
- the role of neurotransmitter aberrations in AD
- the neuropathological diagnosis of AD
- white matter pathology of the brain in dementia
- cerebral amyloid angiopathy and its role in aging and AD
- anti-amyloid treatment of AD

Alzheimer's disease – disease mechanisms and pathology

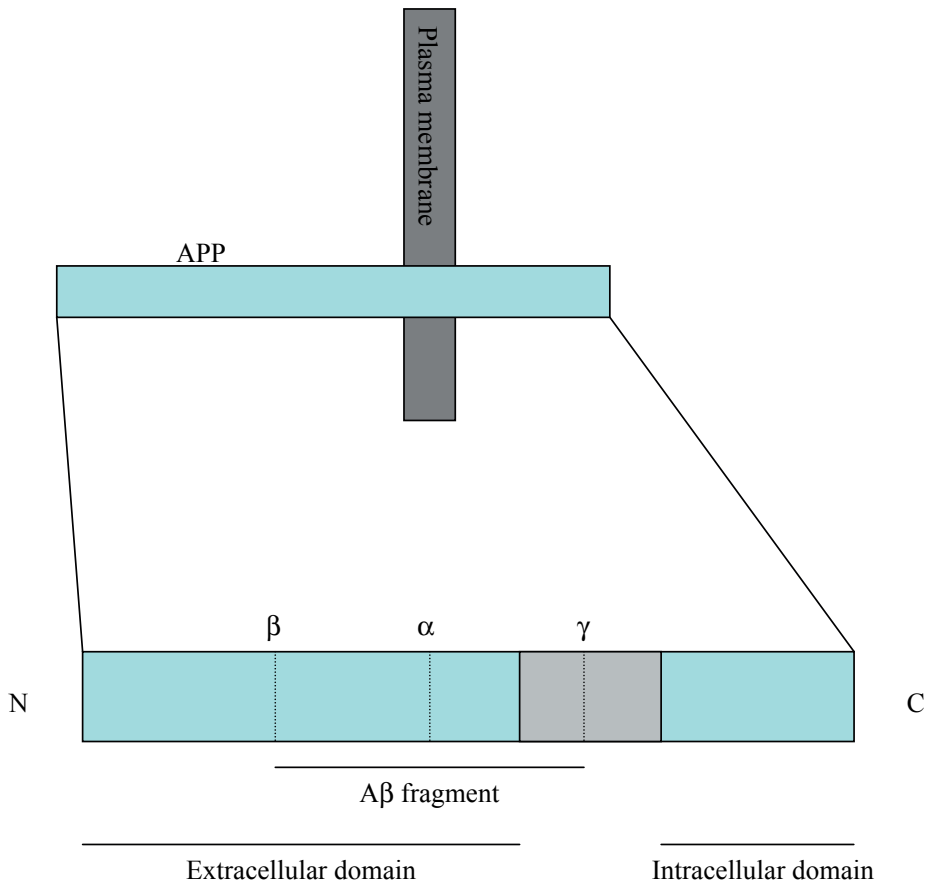
Literally thousands of research studies have been conducted to improve our understanding of Alzheimer's disease, but almost to the year one century since the first report by Alzheimer, there is still significant controversy surrounding the topic. Over the years, many theories on the mechanism of AD have been conceived and investigated. Many diverse theories still have enthusiastic proponents. The roles of vascular pathology (de la Torre, 2002), aluminum (Crapper, 1976; Martyn, 1989), Chlamydia infection (Balin, 1998), acetylcholine deficiency (Coyle, 1983) and cholesterol (Jarvik, 1995) have all been the focus of numerous studies. The significance of neurofibrillary pathology has also been discussed intensely (for reviews, see eg Hardy, 2003; Iqbal, 2005).

The last few decades, the majority of researchers have come to focus on the amyloid hypothesis (Hardy, 1992), according to which overproduction of an aberrant peptide ($A\beta$) leads to formation of $A\beta$ -containing plaques in the brain parenchyma (picture 1), which in turn is hypothesized to lead to neuronal dysfunction and death. The exact mechanism by which $A\beta$ deposits mediate toxicity has remained elusive, but is believed to involve overproduction of reactive oxygen species, in turn causing oxidative changes of vital cellular proteins, mitochondrial dysfunction and neuronal apoptosis (Mattson, 2004).

Currently, the overwhelming majority of AD research being conducted is focused on different aspects of $A\beta$ metabolism (Schenk, 2001; Hardy, 2002), and an abundance of drugs targeting $A\beta$ production and/or increasing $A\beta$ elimination are currently at various stages of development (Maiorini, 2002; Schenk, 2002; Selkoe, 2003). By the majority of experimental AD researchers, tau pathology is at present mainly considered secondary to $A\beta$ dysmetabolism (Hardy, 2002; Wolfe, 2002), although there are numerous proponents of the tau hypothesis who would disagree (Iqbal, 2003). A full declaration of the merits and weaknesses of each theory is beyond the scope of this thesis.

The amyloid hypothesis

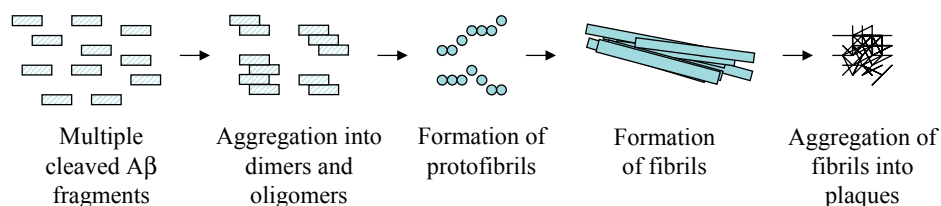
The $A\beta$ peptide found in the amyloid plaques considered to be the primary pathological hallmark of AD was first described in 1984 (Glennner, 1984). It is derived from Amyloid precursor protein (APP) (Kang, 1987), a ubiquitous transmembrane receptor-like protein with a myriad of physiological functions (for a review, see Panegyres, 2001). APP is cleaved by beta-secretase at



Picture 2. Schematic illustration of APP and the different secretase cleavage sites. Dotted lines represent cleavage sites for alpha-, beta- and gamma-secretase, respectively. The shaded area represents the intramembranous domain of APP.

the N-terminus of the A β sequence and by gamma-secretase at the C-terminus of the A β sequence, yielding free, extracellular A β (Sinha, 1999). Alternatively, APP can be cleaved by alpha-secretase, the cleavage site of which lies within the A β sequence (picture 2). Thus, alpha-secretase cleavage of APP does not lead to the formation of free A β (Esch, 1990).

Alpha-protease cleavage of APP is generally believed to be non-detrimental, whereas beta- and subsequent gamma-secretase cleavage is implicated in AD, even though both pathways seem to occur to some extent under physiological conditions (Shoji, 1992). Subsequent to beta- and gamma-secretase



Picture 3. Schematic illustration of the buildup of cleaved A β into amyloid plaques. Note that protofibrils, fibrils and plaques are not in scale relative to the A β peptide.

cleavage, free A β aggregates into soluble di- and oligomers, which in turn successively aggregate into proto-fibrils, fibrils and plaques (Zerovnik, 2002) (picture 3).

Thus, the amyloid plaque is mainly (but not exclusively) composed of A β peptides. A β peptides exist in chiefly two variants. One variant consists of 40 amino acids (A β (40)), whereas the second, longer variant is 42 amino acids (A β (42)) long (Mori, 1992; Roher, 1993; Suzuki, 1994). The difference is due to the fact that gamma-secretase primarily has two cleavage sites at the end of the A β sequence (Hartmann, 1997). Significant efforts have been made to characterize the mechanisms behind A β (40) and A β (42) production and deposition, and the interplay between the two. Other constituents of the amyloid plaques include alpha-1-antichymotrypsin (Abraham, 1988), heparan sulfate proteoglycans (Snow, 1988), and complement factors and immunoglobulins (Eikelenboom, 1982). Each discovery of a novel plaque constituent created hope for experimental investigators trying to understand the pathomechanisms of AD, but the role played by these non-APP-derived factors, if any, has remained elusive.

The strongest argument against the amyloid hypothesis has been the observation that amyloid plaques do not correlate as well with cognition scores as do neurofibrillary tangles (Arriagada, 1992; Bierer, 1995; Nagy, 1995; Berg, 1998). Interestingly, recent discoveries indicate that soluble A β oligomers rather than the actual plaques (although being the most striking pathological finding) are more closely correlated to the clinical severity of disease and synapse loss (McLean, 1999; Lue, 1999; Naslund, 2000; Kirkitadze, 2002). Proponents have considered these observations landmark findings in favor of the amyloid hypothesis, even though it required modification of the hypothesis as it was originally conceived, and the focus has gradually shifted from

Finding	References
The APP gene is located on chromosome 21, trisomy of which (Down's syndrome) is invariably associated with presenile Alzheimer-like pathology.	Burger, 1973
Mutations in the APP gene cause presenile AD.	Goate, 1991
Mutations in other genes that cause presenile AD (presenilin 1 & 2) also increase production of A β .	Citron, 1997
Transgenic mice overproducing A β exhibit cognitive impairment, which can be ameliorated with immunotreatment directed against A β .	Schenk, 1999

Table 3. Evidence implicating a causative role of A β in AD.

the amyloid plaque itself onto A β oligomers. For a brief summary of a few major findings often interpreted as evidence in favor of the amyloid hypothesis, see table 3.

Under physiological conditions, cleaved A β is believed to be cleared from the brain by proteolytic cleavage (primarily by neprilysin (Iwata, 2000) or insulin-degrading enzyme (Kurochkin, 1994) (for a review, see Selkoe, 2001)) or active transport across the blood-brain barrier, possibly mediated by low-density lipoprotein receptor-related protein (LRP) (Kang, 2000). A β may also be transported from the blood into the central nervous system, possibly mediated by the Receptor for Advanced Glycation End products (RAGE). The actions of LRP and RAGE have been proposed to be in a state of homeostasis, suggested to be perturbed in AD (Deane, 2004).

Because of the many mechanisms involved in amyloid production and elimination (reviewed by Tanzi, 2005), there are several conceivable factors that can disturb the normal production and metabolism/elimination of A β , hypothetically leading to A β accumulation and amyloid deposition.

In conclusion, studies on transgenic animals have generated an abundance of tentative mechanisms by which amyloid peptides accumulate in the aging brain. The challenge for future experimental investigations is to assess what mechanisms – if any – are relevant for AD. Possibly, different mechanisms

are in play in different stages and/or variants of AD, and the discussion on which factor is the most relevant will likely continue for many years, if not decades.

Apolipoprotein E and Alzheimer's disease

Apolipoprotein E (ApoE) is a cholesterol transport protein abundantly expressed in the liver and the central nervous system (Mahley, 1988). There are three ApoE alleles, named E2, E3 and E4. A role for ApoE E4 in AD was suggested in 1993, when Strittmatter and colleagues showed that the ApoE E4 allele was more than three times as common in AD patients as in age-matched, cognitively intact controls (Strittmatter, 1993). Numerous other genes have been suggested to affect the risk of developing sporadic AD, but considering the enormous amount of resources being put into finding and assessing candidate genes, surprisingly little has emerged (Finckh, 2003), and ApoE E4 status remains the only uncontroversial genetic risk factor for sporadic AD (Bertram, 2004). Interestingly, a recent study implicated two polymorphisms in the gene coding for the afore-mentioned A β degrading enzyme neprilysin as risk factors for sporadic AD (Helisalmi, 2004). If these results are verified, it would constitute another significant piece of evidence in favor of the amyloid hypothesis.

The actual risk increase for a person carrying one or two copies of the ApoE E4 allele is not firmly established. Prospective studies have shown that persons with at least one ApoE E4 allele (E2/E4, E3/E4, E4/E4) are approximately three to four times more likely to develop AD than are patients without E4 alleles (E2/E2, E2/E3 or E3/E3) (Lindsay, 2002; Myers, 1996). Other investigators mention similar risk figures for E4/E4 homozygotes (Bird, 2005), whereas retrospective studies have shown an odds ratio for AD in E4/E4 individuals as high as 10-20 (Farrer, 1997).

Even though ApoE E4 is a risk factor for sporadic AD, it is not known how ApoE affects the AD disease process. Several intriguing experimental studies indicate that ApoE binds directly to the A β peptide and that particularly ApoE E4 in doing so promotes fibrillogenesis (Wisniewski T, 1994; Castano, 1995). Others emphasize the fact that ApoE E4 is a well-known risk factor for cardiovascular disease (reviewed by Davignon, 1988), suggesting that the association between ApoE E4 and AD is a consequence of ApoE E4 playing a role in cholesterol transport and vascular disease (Sparks, 1996). An alternative theory, that ApoE E4 plays a role in neuroinflammation, is based on the

finding that presence of ApoE E4 promotes astrogliosis in the cortex of AD patients more so than the other alleles (Overmyer, 1999). Hence, it is fair to say that the exact pathological mechanisms behind the association between ApoE E4 and AD are still a matter of considerable debate (for reviews, see for instance Tomiyama, 1999 or Poirier, 2003).

Nerve cell nuclei and neurotransmitters

The amyloid hypothesis notwithstanding, amyloid plaques and neurofibrillary tangles are far from the only findings on postmortem examination of the typical AD brain. In fact, AD pathology extends well beyond the cortex. For instance, degeneration of specific nerve cell nuclei such as the nucleus basalis Meynert (NBM) was described several years ago (Whitehouse, 1982). The NBM is the major source of the neurotransmitter acetylcholine (Ach), loss of which has long been implicated in AD (Coyle, 1983).

Thus, pharmacologic interventions aimed at normalizing cholinergic transmission were introduced. So far, the most practical approach to increasing brain levels of Ach has been inhibiting the enzyme chiefly responsible for its degradation, acetylcholine esterase (AChE). At the present time, three pharmaceutical agents that belong to the family of AChE inhibitors (AChEi) are the mainstay of treatment in AD (table 4).

Generic name	Trade name	Proposed mechanism of action
Donepezil	Aricept	Inhibition of AchE
Galantamine	Reminyl/Razadyne	Inhibition of AchE (and direct agonistic effect on nicotinic receptors*)
Rivastigmine	Exelon	Inhibition of AchE (and butyrylcholine esterase*)

Table 4. Current treatment options for AD based on the cholinergic hypothesis. Apart from the AchEi group of therapeutics, there is also memantine (Ebixa/Namenda), which is believed to work by blocking glutamate receptors. This in turn is hypothesized to inhibit apoptosis.

** This effect, although shown in vitro, is of uncertain clinical importance.*

Although their effect is modest and occasionally questioned (Courtney, 2004; Kaduszkiewicz, 2005), most investigators and clinicians agree that cholinergic treatment represents real and important progress in the treatment of dementia. Recently, a number of studies have suggested that AchEi treatment favorably affects the symptomatological profile (Gauthier, 2002; Paleacu, 2002), which can be construed as evidence of their having a place in the therapeutic arsenal despite the fact that cholinergic treatment does not seem to have a significant effect on the prognosis of AD itself (Wallin, 2004).

However, the NBM is not the only nerve cell nucleus affected in AD. Several studies have reported degeneration of the locus ceruleus (LC), the main source of brain noradrenaline (Mann, 1980; Tomlinson, 1981). Noradrenaline content is also decreased in the cortex of AD patients (Palmer, 1987; Matthews, 2002). These reports were recently reinforced by a study showing more severe loss of neurons in the LC than in the NBM in AD patients (Zarow, 2003). The noradrenergic system has been suggested to play a number of roles in the regulation of cerebral blood flow, abnormalities of which are prominent features of AD (Jagust, 1997; Matsuda, 2001).

The mechanisms behind and the role played by damage to specific nerve cell

nuclei in AD are poorly known, but the availability of neurotransmitters to therapeutical intervention should serve as an incentive for investigators trying to elucidate their role.

Neuropathological diagnosis of Alzheimer's disease

The gold standard of diagnosis of dementing disorders including AD remains post-mortem neuropathological examination. Several different staging criteria and characterization systems have been proposed (Brun, 1981; Khachaturian, 1985; Braak, 1991; Mirra/CERAD, 1991).

It is obvious that universally accepted criteria for the neuropathological diagnosis of AD would have been of tremendous value to researchers and clinicians alike. There are, however, several problems inherent in the task of designing uniform neuropathological diagnostic criteria for dementia. For instance, neuropathologists do not agree on what lesions are the most important. This is exemplified by the fact that the Khachaturian criteria are more or less entirely based on amyloid plaque density, whereas the opposite is true for the criteria proposed by Braak. Furthermore, it is still not settled to what extent some degree of plaque or tangle pathology can be perceived as a normal and inevitable consequence of aging, considering the abundance of plaque and tangle pathology found in cognitively normal elderly (Hof, 1996; Hulette, 1998; Kazee, 1998; Knopman, 2003). Also, the dynamics of the natural life span of the amyloid plaque is poorly known - it has been suggested that plaques resolve over time, based on the finding that as AD patients age, neurofibrillary tangles accumulate whereas amyloid plaques do not (Hyman, 1993). As we shall discuss later, many potential future therapies of AD are based on the immune system attacking parenchymal depositions of amyloid. Therefore, it is not inconceivable that "normal" immune system attacks on amyloid plaques slowly lead to their dissolution over time, which would make staging of AD based on plaque counts alone a flawed concept.

To address some of these concerns, the National Institute on Aging and Reagan Institute (NIA/Reagan) consensus criteria were introduced in 1997, incorporating assessments of both tangle and plaque pathology, essentially fusing the Braak and the Mirra/CERAD criteria. The NIA/Reagan criteria have been evaluated in a number of studies. As can be surmised, the NIA/Reagan criteria are more specific than previous criteria, but the increased specificity comes at the expense of decreased sensitivity (Geddes, 1997; Newell, 1999; Schmitt, 2000). Thus, they do not address the underlying methodological

problems caused by 1) that the interaction between plaque and tangle pathology is poorly known, and 2) the uncertain relationship between clinical symptoms and plaque vis-à-vis tangle pathology.

Decades of difficulties in developing mutual and internationally accepted histopathological criteria for diagnosis, along with the rapid emergence of neuroimaging modalities such as positron emission tomography (PET), MRI and functional MRI (fMRI) have led to an ongoing “turf war” between imaging specialists and pathologists. Radiologists and neurologists are increasingly pushing toward establishing PET and/or fMRI as the gold standard of morphological diagnosis of AD.

Mechanisms of vascular dementia

The aging vascular system is prone to damage. Atherosclerosis, hypertensive arteriosclerosis, thromboembolic disease and cardiac arrhythmias may all have profound effects on vital organs, and the brain is no exception. VaD is said to be present when the effects of cerebrovascular disease amount to severe irreversible cognitive impairment. Because damage to the brain mediated by vascular factors (infarctions and/or hemorrhages) is irreversible once cell death has occurred, there is little potential for effective treatment other than prevention. In the distant future, it is possible that stem cell therapy will facilitate regrowth of lost neurons (Lindvall, 2005).

Most typically, VaD is caused by stroke, particularly in patients that have suffered multiple strokes. The most common cause of clinically apparent stroke is ischemic infarction caused by thrombotic artery occlusion, but many strokes are caused by cerebral hemorrhage. Cerebral infarctions and hemorrhages are both relatively common in the elderly population, and the term “vascular dementia” incorporates both patients having suffered dementia as a consequence of ischemic infarcts and patients where the substrate is cerebral hemorrhage, as well as patients where both lesions are present. Thus, the VaD diagnosis does not reveal the true etiology in any given patient. The usefulness of VaD as a clinical diagnosis has been questioned by studies that showed a distinct lack of reliability in applying the most commonly used diagnostical criteria (Chui, 2000; Pohjasvaara, 2000).

To increase the precision of the clinical diagnosis, some investigators suggest that the focus should not only be put on diagnosing VaD vis-à-vis AD

or other dementing disorders, but also on defining the subgroups of VaD (Bowler, 2000) and identifying a subgroup diagnosis in each patient.

Studies on VaD have suffered from the lack of diagnostic criteria for a neuropathological diagnosis of VaD. Such criteria were recently proposed (Kalaria, 2004), and if they are widely adopted, will help further the understanding of VaD and how it relates to neurodegenerative disease.

The connection between Alzheimer's disease and vascular dementia

VaD, although in many ways conceptually easier to comprehend than AD, is still a diagnosis surrounded by confusion and controversy. Some researchers question the diagnosis of VaD entirely, based on the fact that an overwhelming majority of VaD patients exhibit some degree of AD-related findings on autopsy. This has generated a heated debate on the topic (Roman, 2004). Conversely, some researchers invoke that cerebrovascular disease is common on autopsy in AD patients and contend that the impact of cerebrovascular disease on cognition may be even more significant than has previously been realized (Fernando, 2004). Several intriguing studies have shown that AD pathology is associated with, and may be secondary to, hypoperfusion and cerebral ischemia caused by cerebrovascular disease (de la Torre, 2003; Roher, 2004). The conclusion that can be inferred from these contentions – that AD itself is primarily a vascular disease and that amyloid pathology is partly or entirely secondary to cerebrovascular disease and/or ischemia – is very controversial and has relatively few adherents. However, the hypothesis has some degree of experimental support by a number of studies implicating ischemia as a cause of amyloid dysmetabolism and deposition (Palacios, 1995; Shi, 2000; Wen, 2004). Furthermore, studies on transgenic mice over-expressing APP have shown that they are more sensitive to ischemia than are non-transgenic mice (Zhang, 1997; Koistinaho, 2002).

It deserves emphasizing that both Alzheimer pathology such as plaques and tangles and cerebrovascular pathology such as infarcts, athero- and arteriosclerosis are extremely common in the elderly population. It is therefore not surprising that both cerebrovascular pathology and Alzheimer-related pathology are found on neuropathological examination of elderly patients, even in cases where the patient exhibited no clinical signs of dementia. It is quite obvious that this adds to the confusion when investigators – clinicians, pathologists and radiologists alike – try to reach consensus guidelines and criteria for the neuropathological diagnosis.

White matter pathology in dementia

Traditionally, the emphasis in most brain research has been on the cerebral cortex or even the subcortical gray matter. The white matter has been viewed as wiring only, and it has rarely been considered to play a significant role outside of diseases where it is unequivocally the primary locus of disease (for instance multiple sclerosis, adrenoleukodystrophy and progressive multifocal leukoencephalopathy).

White matter changes, distinct enough to warrant the label “white matter disorder” in AD were first reported by Brun and Englund in 1986 (Brun, 1986). In recent years, interest in white matter pathology in different dementing disorders has increased dramatically, and an abundance of clinicoradiological and clinicopathological studies have been carried out.

There is considerable confusion regarding the terminology of white matter pathology in dementia. Terms such as white matter pathology, white matter disease, white matter lesions, white matter damage and white matter loss are used seemingly interchangeably. To clarify this potentially complicated issue, the terms used in this thesis are explained in the following chapter.

- Definition of terms

“White matter pathology” is an inclusive term, covering all aspects of white matter abnormalities. The term white matter pathology does not imply a certain etiology, pathogenesis or that the pathology is necessarily defined. The spectrum of white matter pathology includes for instance infarctions and perifocal infarctions in VaD, or the gliotic white matter pathology with demyelination described in frontotemporal dementia (Englund, 1987).

“White matter disease” (WMD) of AD is a more sharply defined term that refers to a distinct type of pathology. For purposes related to dementia, WMD is a specific entity characterized by diffuse white matter attenuation with associated oligodendrocyte loss (Sjöbeck, 2003a) and myelin reduction, axonal loss and mild reactive gliosis. There is also extensive fibrohyalinosis of the arterioles and a relative paucity of capillaries (Sjöbeck, 2003b). The etiology is believed to be ischemic (Englund, 1990), and the term selective incomplete white matter infarction (SIWI) has been proposed (Englund, 1988).

“White matter lesions” (WML) is a loosely defined term, which unlike the term “white matter disease” does not imply that the entire brain has been in-

vestigated, and does not necessarily suggest a certain etiology. It also implies focality, in contrast with the WMD of AD, which by definition is non-focal.

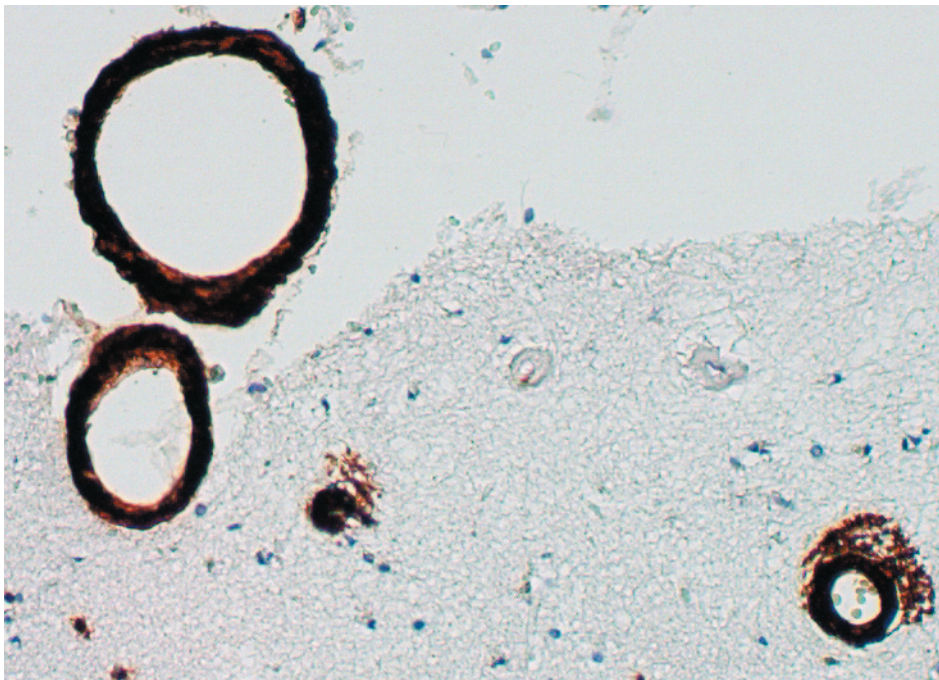
The significance of white matter pathology in AD and other dementias is highly controversial. Clinicoradiological studies are limited by the fact that current imaging methods do not necessarily create accurate depictions of the state of the white matter at a cellular level. Clinicopathological studies, on the other hand, are limited by the fact that they require postmortem examination, at which point the clinical assessment has to be made retrospectively from the clinical records.

When the concept of WMD in AD was proposed, it was based on neuropathological findings, and there was, for obvious reasons, sparse evidence to suggest that the white matter pathology affected the clinical features. Furthermore, the methodological differences between different centers regarding the assessment and grading of white matter pathology using different modalities (computerized tomography (CT), MRI, histopathology) initially resulted in a multitude of conflicting and ostensibly contradictory reports. The etiology of WMD in AD has also been contested. Although initially proposed to be ischemic, some investigators have suggested that the main cause of white matter pathology in AD is Wallerian degeneration (Leys, 1991; Bozzali, 2002). Although Wallerian degeneration can account for white matter pathology, two observations argue against Wallerian degeneration as a cause of WMD in AD: 1) WMD severity does not correlate with severity of other AD pathology (Brun, 1986) and 2) WMD is most commonly found in the frontal lobes (Englund, 1998), whereas the cortical AD pathology is generally the most pronounced in the parietal and temporal lobes (Brun, 1981).

Several years later, a number of studies had shown that presence of different measures of white matter pathology in AD correlate with a different profile of symptoms when compared to AD patients with normal white matter (Englund, 1989; Starkstein, 1997; Tsiskaridze, 1998; Londos, 2001). Although the presence of white matter hyperintensities on MRI, probably reflecting white matter pathology, has been found by most researchers not to correlate very well with cognition scores (Almkvist, 1992; Hirono, 2000), some have reported the opposite (Stout, 1996). Some researchers have gone as far as to suggest that white matter pathology plays an integral role in cognitive decline in the elderly and the AD disease process itself (Bartzokis, 2004).

Cerebral amyloid angiopathy

The presence of amyloid deposits in the cerebrovasculature (picture 4) was described by Divry in the 1920s, but the discovery has also been attributed to Scholtz (Revesz, 2003). In 1935, Arnason described the presence of severe CAA in an Icelandic family with devastating cerebral hemorrhages. Some thirty years later, a Dutch family was described with a similar hereditary form of CAA associated with dementia without a significant presence of plaques. These diseases have become known as Hereditary Cerebral Hemorrhage with Amyloidosis – Icelandic/Dutch type (HCHWA-I/D) (Revesz, 2002).



Picture 4, Amyloid protein has been deposited in the walls of cerebral blood vessels, and visualized using immunohistochemistry.

Name of disorder	Amyloid protein deposited	Pathological features	Clinical features	References
Hereditary cerebral hemorrhage with amyloidosis, Dutch type	Mutated variant of A β	Hemorrhages, microhemorrhages, cortical microinfarcts, white matter lesions	Recurrent hemorrhagic strokes beginning at 40-65 years of age, dementia	Bornebroek, 1996
Hereditary cerebral hemorrhage with amyloidosis, Icelandic type	Mutated variant of Cystatin C	Large cerebral hemorrhages	Hemorrhagic stroke causing death at 30-40 years of age	Palsdottir, 1988
Familial British dementia	ABri	Similar to Alzheimer's disease but plaques lack neuritic pathology	Spasticity, ataxia, dementia	Vidal, 1999
Familial Danish dementia	ADan	Similar to Familial British dementia	Cataracts, deafness, ataxia and dementia	Vidal, 2000
Iowa dementia	Mutated variant of A β	White matter pathology, occipital calcifications, tangle pathology	Aphasic dementia	Grabowski, 2001

Table 5. Selected familial diseases where CAA and its consequences are considered the major pathological substrates.

Since the description of HCHWA-I and -D, numerous familial CAA syndromes have been reported (table 5), which has served to fuel interest in experimental research on CAA (Kiuru, 1999; Mead, 2000; Grabowski, 2001). In the familial CAA-associated diseases, cerebrovascular deposition of amyloid causes hemorrhages and infarctions, with neurological impairment and frequently dementia as a result, and at least in HCHWA-D, dementia is believed to be associated with the presence of CAA rather than plaques or tangles (Natte, 2001).

Although their prevalence is very low, the familial CAA-associated diseases have spurred a lot of interest. Sporadic CAA, in contrast, has not received much attention in the research community. Whereas the amyloid plaque or even the neurofibrillary tangle has been considered the primary lesion in AD, the role of CAA in sporadic dementia has not only been uncertain, but largely neglected. Paradoxically, the first reports describing the amyloid protein found in AD brains were based on cerebrovascular amyloid (Glenner, 1984).

Recent population studies have yielded somewhat conflicting results regarding the role of sporadic (i.e. non-hereditary) CAA on cognitive function in the elderly. The Medical Research Council Cognitive Function and Aging Study in Britain (Neuropathology group, MRC, 2001) showed that CAA was associated with cognitive decline independent of other AD findings, whereas the Honolulu-Asia Aging Study (HAAS) showed no such clear-cut association (Pfeifer LA, 2002). On the other hand, the HAAS showed that CAA and other AD pathology combined to cause more severe cognitive decline than AD pathology alone. It should be pointed out that the ethnic makeup of the studies differ significantly, as do the study setups with regard to CAA assessment. The way the clinical and neuropathological diagnosis were made may also have contributed to the differing results.

Sporadic CAA has been associated with a number of pathological complications. In 1977, Jellinger reported that CAA was associated with nontraumatic cerebral hemorrhages (Jellinger, 1977). This finding has been corroborated by a number of studies (Okazaki, 1979; Mandybur, 1986; Itoh, 1993), suggesting that CAA is an important cause of nonhypertensive cerebral hemorrhage, especially in cases where the hemorrhage site is located in either of the lobes of the cerebrum (Ishihara, 1991). Several studies have associated CAA with small cerebral infarctions (Olichney, 1995; Cadavid, 2000), and

it has long been supposed that CAA in AD is the cause of the white matter pathology often seen in this disease (Gray, 1985). However, several studies undertaken to investigate the correlation between white matter pathology (as visualized using a wide range of methods) and CAA have yielded negative results (Janota, 1989; Munoz, 1993; Scheltens, 1995; Erkinjuntti, 1996; Tomimoto, 1999). CAA has also been associated with small foci of petechial cerebral hemorrhage (Greenberg, 1993; Silbert, 1995), dubbed “microbleeds” (Fazekas, 1999). Microbleeds are common in HCHWA-D (van den Boom, 2005), but the prevalence of microbleeds in cases of sporadic A β CAA have to date not been investigated systematically.

Pathogenesis of cerebral amyloid angiopathy

When CAA was first described, it was believed that the cerebrovascular amyloid depositions arose by the same mechanism that amyloid deposits arise in systemic amyloidoses: by aggregation and deposition of a blood-borne amyloid component. Alternate theories have since been proposed, however: 1) that CAA arises due to in situ production by vascular or perivascular cells (either pericytes or smooth muscle cells (Wisniewski HM, 1994; Wisniewski HM, 2000)) or 2) that the amyloid in the vasculature derives from cortical neurons. The etiology and pathogenesis of CAA were recently reviewed by Rensink, 2003 and Revesz, 2003.

The theory of a blood-borne pathogen prevailed for decades, but gradually lost importance when a range of experimental and ultrastructural studies of CAA showed results compatible with the competing theories. Several intriguing studies have shown that at least in experimental animals, a neuronal source of A β is sufficient to produce CAA (Calhoun, 1999; van Dorpe, 2000). Another important finding that seems to contradict the hypothesis of a blood-borne amyloid component is that cerebrovascular amyloid deposits seem to begin at the outer, rather than the luminal, basement membrane (Yamaguchi, 1992).

Currently, one of the most popular theories on how CAA arises suggests that the A β that is deposited in the cerebral vasculature is produced by cortical neurons. After proteolytic cleavage by beta- and gamma-secretase, soluble A β fibrils are supposedly cleared by way of perivascular channels that run from capillaries to arterioles to arteries. The theory of A β elimination via perivascular channels was first proposed by Weller et al (Weller, 1998), and since, several studies have been published that support or at least are compatible

with a role for perivascular channels in the clearance of A β (Preston, 2003; Roher, 2003).

Cerebral amyloid angiopathy in Alzheimer's disease

The association between CAA and AD is complicated. Generally, most researchers consider CAA to be a pathological hallmark of AD much like the amyloid plaques and neurofibrillary tangles, and that it plays an important and overlooked role in the pathogenesis of AD (Nicoll, 2004). Others consider it little more than a secondary finding without major pathological impact (Castellani, 2004). Studies have shown that practically every AD patient has some degree of meningeal or cortical CAA on autopsy (depending on how much of the actual brain is investigated and the thresholds applied for labeling a case as CAA-positive), but CAA is not uncommon in the elderly, whether suffering from dementia or not (Esiri, 1986; Fernando, 2004).

The findings from the HAAS described earlier are partly supported by a histopathological investigation that suggested an inverse correlation between CAA and plaque pathology (Goulding, 1999). This led to the proposition that presence of CAA constitutes another “burden” on a brain affected by plaque pathology, so as to cause clinical dementia at a lower plaque level than would be the case in a patient with a similar amount of plaques but spared from CAA.

Apolipoprotein E, cerebral amyloid angiopathy and the two major amyloid beta peptide species

Several lines of evidence suggest that the role of the ApoE genotype in dementing disorders is not restricted to the previously discussed relationship between ApoE E4 and AD. ApoE E4 has also been suggested to be a strong risk factor for CAA (Schmechel, 1993; Greenberg, 1995; Premkumar, 1996). In fact, a study by Chalmers and colleagues on the effects of ApoE genotype on the morphology of AD showed that ApoE E4 was associated with CAA rather than amyloid plaques (Chalmers, 2003).

Experimental support for the hypothesis that ApoE E4 promotes cerebrovascular amyloid deposition (in the form of CAA) rather than parenchymal amyloid deposition (in the form of plaques) comes from an animal study, which showed that presence of human ApoE E4 in a transgenic mouse model of AD (Tg2576) favored cerebrovascular rather than parenchymal A β deposition (Fryer, 2005). This was associated with an increase in the ratio of A β (40) to

A β (42), which is compatible with the fact that A β (40) is the most predominant species found in cerebrovascular A β depositions (Gravina, 1995). Correspondingly, in parenchymal depositions (plaques), A β (42) is typically more pronounced (Iwatsubo, 1994). There are conflicting reports on whether the experimental observation of a relative increase of A β (40) holds true for human AD cases (Mann, 1997; McNamara, 1998).

A β (40) is more soluble than A β (42), and it has been suggested that A β (42) traps A β (40), serving as a linchpin for subsequent growth of the A β depositions by additional aggregation of A β (40) (Jarrett, 1993; Alonzo, 1998).

Further complicating the relationship between AD phenotype and ApoE genotype, a large study recently showed that ApoE E4 homozygosity was associated with an increased number of plaques, whereas heterozygosity was not (Tiraboschi, 2004). Also, a recent study investigating cases without AD questioned whether the ApoE E4 allele is a risk factor for CAA in patients not afflicted by AD (Love, 2003). This study contradicts a previous study on the subject, which had shown ApoE E4 homozygosity (but not heterozygosity) to be a risk factor for CAA in patients without clinical dementia (Walker, 2000).

In brief, AD associated with ApoE E4 homo- or heterozygosity is associated with more severe CAA and A β (40) deposition than AD in patients without ApoE E4 alleles, but unless there is concomitant A β dysmetabolism (for example manifested as AD), the relationship between ApoE E4 and the risk of developing CAA is not firmly established.

Anti-amyloid treatment of Alzheimer's disease

The amyloid hypothesis in AD has generally been well received by the scientific community. This is not surprising, since it offers an attractive way of describing the disease, and offers several opportunities for creating animal models. Unlike in VaD, where the onus currently is on prevention rather than treatment, the amyloid hypothesis of AD offers several potential targets of pharmacological agents affecting the metabolism of A β .

Several experimental treatment options directed against the amyloid protein have been found to be effective in decreasing amyloid deposition in plaque-forming experimental animals, and this has been accompanied by increased cognition in many models (Lemere, 2003). The efficacy and ostensible safety

of a vaccine against A β in animal models led to the first trials of anti-amyloid treatment (AN-1792) in 2001 (Thattai, 2001). The trials were halted (Senior, 2002) when 18 out of the 300 patients receiving treatment developed symptoms of meningoencephalitis. 12 patients recovered to their baseline level of functioning, whereas six sustained some degree of persistent deficits (Orgogozo, 2003). Even though the trial was a substantial setback, not to mention a disaster for those affected by the side effects, from a purely scientific standpoint, important information could still be extracted from the results of the study. Postmortem examination of the first case that came to autopsy after AN-1792 immunization showed low plaque levels, but no apparent attenuation of CAA. There were signs of perivascular inflammation and T-lymphocyte meningoencephalitis, which was presumed to be the pathological substrate of the clinically apparent side effects (Nicoll, 2003).

The unacceptable side effects made it clear that this particular form of anti-amyloid treatment would not be a viable therapeutic option in AD. However, if one could detect a clinical improvement or halted clinical decline in the majority of patients that did not develop side effects but did mount an immune response against A β , one would have to conclude that the therapeutic principle is viable. This would also constitute near irrefutable evidence in favor of the amyloid hypothesis, which would allow researchers to focus their efforts and settle a century-long debate. Just recently, preliminary results on cognition in patients showing immunological signs of responding to treatment without exhibiting adverse effects were published. Unfortunately, no significant effects on the cognitive assessments were seen, but when composite z scores were calculated, they seemed to favor patients that developed an antibody response to the immunization (Gilman, 2005). The significance of this study has been widely discussed. While there is no doubt that the results are a disappointment, the authors emphasize the trend toward better cognition in responders versus non-responders. Over the next couple of years, follow-up studies will probably be able to settle the debate on the cognitive effects of A β immunization.

Another interesting finding in patients that were immunized were that they exhibited a significant decrease in brain volume as assessed on MRI (Fox, 2005). Although the authors speculate that this is due to removal of A β , another – less encouraging – possibility is that the decrease is explained by accelerated cerebral atrophy. Other hypotheses that have been put forward is that the shrinkage observed was due to (1) decreased brain water content due

to lost osmotic activity of cleared amyloid plaques, or (2) decreased inflammatory activity (astrogliosis) leading to decreased cellular swelling (Gandy, 2005).

Cerebral amyloid angiopathy as a putative complication of anti-amyloid treatment of Alzheimer's disease

Considering the current hypothesis on how CAA arises, researchers have warned that CAA may be a complication of amyloid-eliminating therapy, especially in cases where cerebrovascular disease is present (Weller, 2002). Indeed, CAA and hemorrhages have been reported in transgenic mice receiving immunotherapy against deposited amyloid (Pfeifer M, 2002), and CAA was a prominent finding in the few post-mortem examinations conducted after administration of anti-amyloid treatment (Nicoll, 2003; Ferrer, 2004; Masliah, 2005). That said, it is not clear whether the dramatic side effects seen were in fact due to CAA, and if so, what the mechanism was.

Because of the striking presence of a perivascular inflammatory reaction, it is presumed that the amyloid cleared from the brain drained to the vasculature, where T lymphocytes were exposed to new epitopes, triggering a devastating immune reaction (Greenberg, 2003). Recently, it has been shown that an anti-amyloid antibody without affinity for deposited A β (as opposed to soluble) was not associated with CAA-related hemorrhage (Racke, 2005), whereas antibodies that triggered immune reactions toward deposited A β did produce the features typical of CAA-associated hemorrhage. This adds further to the growing evidence identifying soluble A β , rather than the plaque itself, as a worthwhile therapeutic target.

If indeed CAA proves to be a consequence of plaque-targeting treatment of AD, it may have pronounced implications for future treatment strategies. If immune reactions directed against already formed A β can lead to the development of (or exacerbation of) CAA and its consequences in terms of hemorrhage and infarctions, A β production inhibiting agents (beta- and/or gamma-secretase inhibitors) may be a more attractive therapeutic strategy than immunotreatment targeting A β . Needless to say, several such drugs are currently at various stages of development (Cumming, 2004; Siemers, 2005), and during the next couple of years, we will learn whether either of these drugs will bring about the as yet elusive breakthrough in the pharmacological management of Alzheimer's disease.

Aims

As the average life expectancy increases, so do the demands on society to provide health care and medical services to the growing population of elderly individuals. In that light, the spectrum of dementing disorders constitutes a tremendous problem. These disorders can turn previously healthy and self-sufficient individuals into patients requiring 24 hour monitoring and assistance in every aspect of their activities of daily life. Needless to say, any progress in delaying the onset or impeding the progression of dementing disorders would translate to enormous financial gains for society, not to mention the humanitarian effects in terms of alleviating suffering for patients and next-of-kin alike.

Seeing as it is the most common dementing disorder, it is worth underscoring that progress in the treatment of AD has been modest. In part, this can be attributed to the fact that the mechanisms by which AD produces dementia are poorly understood. Chances of discovering new and effective treatments would be greatly increased by improved understanding of the disease mechanisms in play.

This thesis explores several issues relating to vascular pathology in the two largest dementing disorders; AD and VaD. Specifically, the primary aims were to improve our understanding of:

- 1) The possible role of CAA in white matter pathology in AD
- 2) The prevalence and features of CAA in VaD
- 3) The pattern of vascular A β deposition in AD and VaD with regard to degeneration of normal vessel wall components
- 4) The association between LC degeneration, WMD and other Alzheimer pathology in AD

The present investigation

This chapter introduces, summarizes and discusses the findings of the papers included in the thesis.

All cases included in this study were part of the Lund Longitudinal Dementia Study, an ongoing prospective dementia study started in 1968 by professor Lars Gustafson and the Lund Dementia Research Group. Patients with a referral to the department of Geriatric Psychiatry in Lund are routinely offered inclusion in this study, where clinical, radiological and pathological tests and investigations are carried out. After the initial workup, a clinical diagnosis is made. Patients are followed on an outpatient basis until their time of death, after which a neuropathological examination is made. Paraffinized whole-brain tissue blocks are archived at the Department of Pathology. To date, more than 800 patients have been included in the study.

Paper I: Cerebral amyloid angiopathy, white matter lesions and Alzheimer encephalopathy – a histopathological assessment

Background and setup

In 1985, Gray and Dubas suggested that the white matter pathology often seen in AD was caused by CAA (Gray, 1985). This was based on a case series, and there was no statistical evidence in favor of the hypothesis. Several investigators followed up on the work by Gray and Dubas (Janota, 1989; Munoz, 1993; Scheltens, 1995; Erkinjuntti, 1996; Tomimoto, 1999), but no studies showed a clear-cut correlation between CAA and any measure of white matter pathology. To investigate the association, we examined 66 cases with some degree of Alzheimer pathology on neuropathological examination from the Lund Longitudinal Dementia Study for presence of CAA in the leptomeninges of the frontal poles and white matter lesions of the frontal lobes. Cases were sorted into either of three groups: AD, AD and VaD (mixed) or VaD with Alzheimer encephalopathy (AE) (VaD-ae) (i.e. not severe enough to warrant a diagnosis of AD).

Results

There was a significant correlation between CAA and WML in the entire group studied; however, the correlation was only present in cases exhibiting manifest AD. In cases with admixture of VaD (i.e. belonging to either the mixed group or the VaD-ae group), there was no such correlation. There were no significant differences between the groups with regard to CAA or WML severity. Neither CAA nor WML severity correlated with age.

Discussion

This study is the first to prove the hypothesis by Gray and Dubas. One could conceive of several reasons why other studies did not show statistically significant results. Several studies used small sample sizes, and others used only a semi-quantitative measure of CAA.

Furthermore, we used Congo Red staining to visualize vascular amyloid deposits, whereas other investigators (Tomimoto, 1999) have employed A β immunohistochemistry. Because A β immunohistochemistry is more sensitive than Congo Red, it is possible that the statistical correlation between WML and CAA is obscured when vessels positive for A β at an early stage, where the A β has not yet assumed a beta-sheet structure, are included.

This study does not allow for conclusions as to why there was no association between CAA and WML in non-AD cases. Neither CAA nor WML were any less severe in the non-AD group, in fact, there was a trend toward more CAA in the mixed dementia group, and the group of patients that had VaD with only mild Alzheimer encephalopathy had just as high a degree of CAA as did 'pure' AD patients. The typical white matter pathology in VaD (typically complete infarctions with surrounding incomplete infarction) (Englund, 2000) differs from that of AD (which is typically void of complete infarction), and this is likely to be a manifestation of different pathogenetic mechanisms. Hypothetically, widespread CAA in the absence of cerebrovascular disease may predispose to mild hypoxia and ischemia without causing overt infarction.

Paper II: Severe cerebral amyloid angiopathy characterizes an underestimated variant of vascular dementia

Background and setup

In paper I, we found that CAA was no more severe in AD cases than in cases with only mild Alzheimer encephalopathy. Because CAA is considered a consequence of the Alzheimer disease process, this was surprising. We followed up these results by investigating CAA and its features in 11 VaD cases with mild AE and 11 age-matched AD pseudo-controls. One entire temporal lobe section was obtained from each case, and stained using A β immunohistochemistry. Each section was subsequently analyzed for presence of cortical and leptomeningeal CAA, plaques and other pathological findings commonly associated with CAA.

Results

Every AD case had at least a few amyloid-positive vessels within the areas examined, whereas the VaD group exhibited a distinctly different pattern – six out of 11 cases had severe CAA, much more than was seen in any AD case, but five of 11 had little ($n = 1$) or no ($n = 4$) CAA.

As a group, the VaD cases on average had more CAA both in the leptomeninges and in the cortex. However, the ratio of cortical to leptomeningeal involvement was higher in the AD group, and morphologically, leptomeningeal CAA was more severe in VaD cases, whereas there was no difference regarding cortical CAA.

Cortical infarctions were markedly more common in the VaD group, whereas perivascular hemosiderin (interpreted as the histopathological correlate of a previous microbleed) was only found in two out of 660 studied cortical vessels. Perivascular hemosiderin deposition was common in the white matter, however.

Discussion

The finding that several cases with VaD and only mild Alzheimer encephalopathy exhibited an even higher degree of CAA than patients with more severe Alzheimer pathology suggests that CAA is not only a result of the AD disease process itself. Concurrent cerebrovascular pathology seems to increase the risk of CAA that is more severe than that normally seen in ‘pure’ AD cases.

Hence, this study is consistent with the proposed role of the cerebrovasculature in physiological elimination of amyloid. The fact that CAA was severe in such a large proportion of cases with only limited Alzheimer pathology suggested that amyloid overproduction is not the only factor in play. This is further strengthened by the fact that CAA displayed morphologically and topographically different profiles in VaD and AD cases – CAA was more pronounced in the leptomeninges of VaD cases, and relatively more severe in the cortex of AD cases.

On the basis of these observations, one could hypothesize that there are (at least) two different mechanisms that contribute to the formation of CAA. We speculate that one mechanism (failed elimination due to cerebrovascular disease) is more prominent in VaD with CAA, and another mechanism (neuronal overproduction of A β) is more prominent in AD.

This study also broaches on the subject of how to measure severity of CAA. Although the grading system proposed by Vonsattel (Vonsattel, 1991) has been used by several investigators, it was originally designed for studies of cerebral hemorrhage associated with CAA. Thus, it puts an emphasis on late-stage CAA-associated pathology such as “vessel-in-vessel” phenomena, scarring and necrosis and does not account for the distribution of CAA in a given section. To illustrate, a case where 97% of vessels are positive for amyloid but no vessel-in-vessel phenomena are found would only reach a Vonsattel score of 2 (out of 4), which is reasonable if one is primarily interested in effects of CAA on the risk of hemorrhage. Given that lobar hemorrhages are rare (in fact absent in the present material) and CAA is common, the factors that mediate potential effects of CAA on cognition may not be identical with factors that increase the risk of lobar hemorrhage.

Furthermore, the finding of severe CAA in such a large group of VaD cases warrants further investigation. Although this group of patients was selected for presence of some degree of Alzheimer pathology, the findings of this study suggest that CAA in VaD is not rare.

Paper III: Cerebral amyloid angiopathy and cortical microinfarcts as putative substrates of vascular dementia

Background and setup

Our previous studies showed an unusually high degree of CAA in cases with a neuropathological diagnosis of VaD. This was surprising because CAA has traditionally been associated with AD rather than VaD. Because the statistical material in these two studies did not allow for conclusions regarding the prevalence of CAA in an unselected group of patients with VaD, we investigated the frequency and severity of CAA in a consecutive VaD material. We examined temporal and parietal lobes of every VaD case in our laboratory from 1994 to 1998. Clinical records were analyzed retrospectively, to ascertain whether VaD cases with CAA exhibited a particular clinical profile.

Results

CAA was severe in eight out of 26 cases, and was strongly correlated with the presence of cortical microinfarcts in both the temporal and the parietal lobes. As secondary findings, there was a trend toward more infarcts and CAA in individuals with at least one ApoE E4 allele, and capillary CAA was noted in two patients, both of whom were ApoE E4 heterozygotes. Analysis of the clinical records suggested that psychiatric symptoms (except depression) were more common in VaD cases with CAA than in age-matched VaD cases without CAA. Conversely, neurological symptoms were less pronounced in the VaD+CAA group.

Discussion

The correlation between CAA and cortical microinfarcts suggests that in this group, CAA has tangible pathological consequences, especially considering the strong correlation between presence of cortical microinfarctions and cognitive impairment shown by Kovari et al (Kovari, 2004). Although sporadic CAA has occasionally been associated with VaD, this is the first study to investigate the role of CAA in a consecutive series of VaD patients with clinical follow-up, and the first study to suggest that CAA is a common feature of VaD, especially of the small-vessel disease subtype.

Taking the theory of A β elimination via perivascular channels into account, one could invoke that cerebral infarcts cause CAA by obstructing the flow of amyloid, rather than CAA being a causative risk factor for cerebral infarction. Cerebral cortical vessels in immediate proximity to cortical microinfarcts were

often engorged with A β in this study, as has been described earlier (Weller, 2002). This could also explain the relationship between ApoE E4 and CAA in which ApoE E4, also well-known as a cardiovascular risk factor, may increase the risk of cerebral infarction, leading to a subsequent development of CAA as a secondary phenomenon due to the hampered perivascular flow of amyloid. However, severe CAA in HCHWA-D is associated with microinfarcts (Wattendorff, 1995) irrespective of other cardio- or cerebrovascular risk factors. Also, previous studies have shown that the correlation between CAA and cerebral infarcts is consistent within groups of patients stratified by their ApoE genotype (Olichney, 2000) and there is still significant controversy regarding the role of ApoE E4 as a risk factor for cerebral infarction. Furthermore, since blood flow is centripetal from the leptomeninges and A β is suggested to flow in the opposite direction, if CAA were caused by these infarcts and subsequently halted A β flow, one would expect to see the most pronounced CAA immediately beneath superficial cortical infarcts, rather than immediately above them, which is more often the case.

As others have noted, capillary CAA is most commonly seen in ApoE E4 hetero- or homozygotes (Thal, 2002). The reason for this is not clear, but recent work on lipoprotein related protein receptor -1 (LRP-1) may provide important clues. LRP-1 is abundantly expressed in the capillary endothelium, and it is believed to eliminate soluble A β from the brain parenchyma (Shibata, 2000). LRP-1 is also an ApoE receptor (Kounnas, 1995), and unlike A β bound by ApoE, free A β is not eliminated via the LRP pathway (Narita, 1997), at least not to a significant degree. Furthermore, the ApoE E4 isoform has been shown to bind A β with less avidity than does ApoE E2 or ApoE E3 (LaDu, 1994).

Based on these observations, we hypothesize that capillary depositions of A β arise in individuals with at least one ApoE E4 allele by way of low-avidity binding of free A β by ApoE E4 and subsequent impaired clearance by endothelium-associated LRP-1. While most experimental work on A β clearance via the LRP-1 pathway has been carried out using A β (40) peptides, it is not inconceivable that the higher aggregability of the A β (42) peptide precludes it from being used under experimental conditions.

Paper IV: Differential deposition of amyloid beta peptides in cerebral amyloid angiopathy associated with Alzheimer's disease and vascular dementia

Background and setup

Several studies have shown that vessels affected by CAA exhibit signs of degeneration such as loss of smooth muscle actin (SMA). The loss of normal vascular components has been associated with the complications of CAA. It is believed that replacement of contractile elements by A β leads to blood flow aberrations and predisposes to vascular rupture and hemorrhage. To investigate SMA loss and CAA in a large material, we investigated 62 consecutive cases of AD, VaD and MD from the Lund Longitudinal Dementia Study. Immunohistochemistry for A β , SMA, A β (40) and A β (42) was carried out.

Results

In all three groups, there was a strong inverse correlation between A β positivity and SMA positivity. For VaD cases, there was a significant, but weak, correlation between Braak stage (0 – III) and CAA. Generally, the A β (42) staining identified more parenchymal deposits, whereas cerebrovascular positivity was chiefly identified as A β (40). For cases with similar CAA levels, there was no significant difference between the three groups in terms of vascular A β (40) positivity. There was, however, a significant difference in A β (42) positivity, being less marked in the AD group than in either the VaD or the MD group. More marked SMA degeneration was seen in the VaD and MD groups than in the AD group.

Discussion

The differing A β (40)/A β (42) profiles in CAA associated with VaD/MD (CAA-VaD/MD) and CAA associated with AD (CAA-AD) are a novel finding, and could be a manifestation of different mechanisms of accumulation and deposition. Since numerous experimental studies have shown effects of ischemia on the metabolism of APP (Palacios, 1995; Shi, 2000; Wen, 2004), we propose that ischemia-mediated APP dysmetabolism and subsequent A β accumulation is primarily associated with deposition of A β (42) in the vasculature.

Our findings may help explain previous reports of severe CAA in VaD, despite the fact that A β overproduction is not generally associated with this disease. If one considers that cerebrovascular A β (42) is believed to serve as a

nidus for subsequent A β (40) deposition, the amount of CAA in VaD cases could be explained by more “effective” trapping of soluble A β (40), rather than an abundance of A β (40) per se.

Furthermore, the fact that A β (42) is less soluble could make it more dependent on effective mechanisms of removal. If these mechanisms are perturbed by cerebrovascular disease (Weller, 2002), it is not inconceivable that this manifests as impaired removal of A β (42) more so than A β (40).

Paper V: Locus ceruleus degeneration is ubiquitous in Alzheimer's disease - possible implications for diagnosis and treatment

Background and setup

The pathological consequences of locus ceruleus (LC) degeneration in AD, if any, are poorly known. We hypothesized that LC degeneration would cause perturbations of cerebral blood flow autoregulation, which in turn might predispose the aging brain to hypoperfusion. A consequence of hypoperfusion is ischemic damage to selectively vulnerable regions of the brain, such as the deep white matter.

We hypothesized that LC degeneration would be associated with WML in AD. 71 consecutive AD cases from the Lund Longitudinal Dementia Study were included, and the white matter was assessed as in study I and using optical density measurements. A LC degeneration grading scale was designed, and tested for interrater reliability and specificity using 10 VaD cases as pseudo-controls. Information on duration of dementia was retrieved from the clinical records, and AD pathology was assessed using Braak staging and Brun & Englund scores.

Results

In 66 cases, sufficient tissue sections were available for analysis. There was no correlation between LC degeneration as assessed using our scale and degree of white matter damage, neither microscopically nor using optical density measurements.

No correlation was found between LC degeneration and general AD pathology or duration of dementia. The scale used to assess LC degeneration was found to be reliable (single rater intraclass correlation coefficient = 0.78) and resulted in significantly different scores between AD and VaD cases.

Discussion

We were unable to confirm our hypothesis regarding the association between LC degeneration and WML. However, there may be other consequences of noradrenergic dysfunction in AD, and considering the fact that noradrenergic therapy is available and safe, our negative findings do not offset the potential benefit of such therapy, should it prove to have an effect on the symptomatology or progression of AD.

The fact that LC degeneration was seen to some degree in all AD cases and was only very limited in VaD cases indicate that LC degeneration could be incorporated as a feature diagnostic of AD, even if it has not been shown to affect the pathogenesis itself. LC degeneration is not considered in the current neuropathological criteria for AD, but we have shown that it can easily be assessed with a high degree of reliability.

We suggest that future studies should be undertaken to elucidate the role of LC degeneration in AD, and to establish whether it should be considered a pathological hallmark of AD.

Conclusions

- Ischemic WMD in AD is associated with, and possibly caused by, CAA of the penetrating arteries. However, CAA is most likely not the only factor of importance.
- Even though it is almost ubiquitous in AD, CAA is not pathognomonic for AD. In fact, the most severe CAA is not typically seen in AD, but in cerebrovascular disease with additional Alzheimer pathology and/or MD.
- CAA may be a pathological substrate of VaD, typically VaD associated with cortical microinfarcts. CAA in VaD more typically exhibits severe leptomenigeal involvement, but is not unconditionally associated with white matter pathology.
- The syndrome of VaD and severe CAA with cortical microinfarcts may have a profile of symptoms that separates it from VaD without CAA.
- Concomitant cerebrovascular disease, as in VaD and MD, affects the deposition pattern of A β species. For a given level of CAA, there is more A β (42) deposition in CAA-VaD/MD than in CAA-AD, and more damage to the normal vascular architecture, including more smooth muscle degeneration. The role of cerebrovascular disease in affecting the metabolism and removal of A β needs clarification.
- Structural damage to the LC is present to some degree in virtually every AD case. Although the pathogenetic significance remains elusive, degeneration of the LC could be used as a diagnostic tool, distinguishing AD from VaD and possibly other dementing disorders.

Populärvetenskaplig sammanfattning på svenska

Alzheimers sjukdom och vaskulär demens är de vanligaste orsakerna till demens hos äldre, ett tillstånd som i takt med den ökande åldrade befolkningen kommer att innebära ett allt större lidande och en alltjämt ökande ekonomisk belastning. Direkta och indirekta kostnader för vård och omsorg av demenspatienter uppgår sannolikt till ca 40 miljarder kronor om året. Detta är ca fyra gånger så mycket som den totala kostnaden för diabetes och övervikt tillsammans.

Idag är behandlingsmöjligheterna vid Alzheimers sjukdom och vaskulär demens mycket små, vilket i sin tur delvis kan förklaras av att vår förståelse för sjukdomsförloppen ännu är otillräcklig. Inom ramen för detta projekt har vi undersökt mikroskopiska fynd vid Alzheimers sjukdom och vaskulär demens för att öka den basala förståelsen för processerna som pågår i hjärnan vid dessa tillstånd.

Vid mikroskopisk undersökning karakteriseras Alzheimers sjukdom främst av tuggummiliknande inlagringar av protein i hjärnvävnaden (amyloida plack). Att inlagringar av liknande karaktär även återfinns i hjärnans kärl (cerebral amyloid angiopati, CAA) har varit känt sedan länge, men vad dessa kärlinlagringar får för konsekvenser i den åldrande hjärnan är inte klarlagt.

Denna avhandling beskriver fynden från mikroskopiska studier av vävnad som tillvaratagits från patienter som avlidit med diagnosen Alzheimers sjukdom och/eller vaskulär demens.

I delarbete I visade vi att CAA har samband med förändringar i hjärnans vita substans, och att CAA sannolikt inte enbart är en följd av Alzheimerprocessen, då patienter med Alzheimers sjukdom inte tycks ha mer CAA än patienter med vaskulär demens och endast diskreta Alzheimerförändringar (VaD-ae).

I delarbete II undersökte vi skillnader i CAA mellan å ena sidan patienter med vaskulär demens och diskreta Alzheimerförändringar (VaD-ae) och å andra sidan åldersmatchade patienter med Alzheimers sjukdom. Det visade sig att VaD-ae-gruppen inte bara hade mer utbredd CAA, även mönstret i var kärlförändringarna förekom och dess svårighetsgrad skilde sig åt mellan grupperna.

I delarbete III undersökte vi hur vanligt det är med CAA i en större grupp patienter med vaskulär demens. Vi fann att en överraskande stor andel av patienter med vaskulär demens hade mycket svår CAA, och att detta hade ett samband med förekomst av små infarkter i hjärnbarken. Dessutom tycktes den kliniska profilen skilja sig mellan patienter med vaskulär demens med och utan CAA.

I delarbete IV undersökte vi hur hjärnans kärl skadas i samband med inlagring av A β i kärlväggen, och om och i så fall hur detta förlopp påverkas av samtidig annan kärlsjukdom. Vi fann att CAA vid AD och VaD skilde sig med avseende på de två viktigaste amyloid-komponenterna (och deras effekt på kärlets normala komponenter), vilket i sin tur kan bero på olika uppkomstmekanismer vid AD och vid VaD.

I delarbete V undersökte vi skador i hjärnstamskärnan locus ceruleus (LC) och dess samband med skador i hjärnans grå och vita substans hos Alzheimerpatienter. Även om vi inte upptäckte något samband, var det slående hur väl skador på LC kan skilja Alzheimers sjukdom från vaskulär demens. Detta kan eventuellt utnyttjas i framtida riktlinjer för neuropatologisk diagnos av demenstillstånd.

Acknowledgements

Obviously, a great number of people have made tremendous contributions to this thesis. First and foremost, I would like to thank my supervisor, associate professor Elisabet Englund, for having been an inspirational and infectiously enthusiastic supervisor through every stage and aspect of this project. By possessing and displaying all of the character traits required in a leader – being involved, being a facilitator and being an encouragement – she has guided this thesis through thick and thin. Secondly, a lot is owed to my fellow PhD students in the Englund group; Martin Sjöbeck and Annette Persson.

Other contributors at the department of Pathology include professor emeriti Arne Brun and Nils Jonsson, professor Per Alm, Sanaz Mojighashghaei, Christina Thunberg, Anna Härfstrand, Mikaela Bodell and Thomas Lindén. Especially, I am very grateful to the Head of the Department of Pathology and Cytology at Lund University Hospital, Henryk Domanski, for generously providing facilities. Equally deserving of special mention is Kerstin Stureson, whose great knowledge and experience has been of tremendous help.

At the department of Psychogeriatrics, I would like to thank associate professor Ulla Passant, professor Lars Gustafson and Helena Andersson.

International contributors include professor Raj Kalaria at the University of Newcastle upon Tyne and dr Estifanos Ghebremedhin at the Johann Wolfgang Goethe University.

I would also like to thank associate professor Steven Greenberg, assistant professor Matthew Frosch, dr Edip Gurol, Elissa Robbins and KarLotta Fitch, all at Massachusetts General Hospital in Boston, USA, for being gracious hosts and introducing me to the CAA grading project.

This study was supported financially by Sparbanksstiftelsen Färs & Frosta, The Swedish Alzheimer Foundation, The Crafoord Foundation, Stiftelsen Landshövding Per Westlings Minnesfond, The Royal Physiographic Society in Lund, Lunds Läkaresällskap and the Faculty of Medicine at Lund University.

The costs associated with the printing of this thesis and hosting a dissertation were borne in part by the Faculty of Medicine at Lund University.

References

- Abraham CR, Selkoe DJ, Potter H. Immunochemical identification of the serine protease inhibitor alpha 1-antichymotrypsin in the brain amyloid deposits of Alzheimer's disease. *Cell*. 1988;52:487-501.
- Aevarsson O, Skoog I. A population-based study on the incidence of dementia disorders between 85 and 88 years of age. *J Am Geriatr Soc*. 1996;44:1455-60.
- Akatsu H, Takahashi M, Matsukawa N, Ishikawa Y, Kondo N, Sato T, Nakazawa H, Yamada T, Okada H, Yamamoto T, Kosaka K. Subtype analysis of neuropathologically diagnosed patients in a Japanese geriatric hospital. *J Neurol Sci*. 2002;196:63-9.
- Almkvist O, Wahlund LO, Andersson-Lundman G, Basun H, Backman L. White-matter hyperintensity and neuropsychological functions in dementia and healthy aging. *Arch Neurol*. 1992;49:626-32.
- Alonzo NC, Hyman BT, Rebeck GW, Greenberg SM. Progression of cerebral amyloid angiopathy: Accumulation of amyloid-beta40 in affected vessels. *J Neuro-pathol Exp Neurol* 1998;57:353-59
- Alzheimer A. Über eine eigenartige Erkrankung der Hirnrinde. *Allgemeine Zeitschrift für Psychiatrie und Psychisch-Gerichtliche Medizin* 1907;64:146-48.
- Arriagada PV, Growdon JH, Hedley-Whyte ET, Hyman BT. Neurofibrillary tangles but not senile plaques parallel duration and severity of Alzheimer's disease. *Neurology*. 1992;42:631-9.
- Balin BJ, Gerard HC, Arking EJ, Appelt DM, Branigan PJ, Abrams JT, Whittum-Hudson JA, Hudson AP. Identification and localization of *Chlamydia pneumoniae* in the Alzheimer's brain. *Med Microbiol Immunol*. 1998;187:23-42.
- Bartzokis G. Age-related myelin breakdown: a developmental model of cognitive decline and Alzheimer's disease. *Neurobiol Aging*. 2004;25:5-18.
- Berg L, McKeel DW Jr, Miller JP, Storandt M, Rubin EH, Morris JC, Baty J, Coats M, Norton J, Goate AM, Price JL, Gearing M, Mirra SS, Saunders AM. Clinicopathologic studies in cognitively healthy aging and Alzheimer's disease: relation of histologic markers to dementia severity, age, sex, and apolipoprotein E genotype. *Arch Neurol*. 1998;55:326-35.
- Bertram L, Tanzi RE. The current status of Alzheimer's disease genetics: what do

we tell the patients? *Pharmacol Res.* 2004;50:385-96.

Bierer LM, Hof PR, Purohit DP, Carlin L, Schmeidler J, Davis KL, Perl DP. Neocortical neurofibrillary tangles correlate with dementia severity in Alzheimer's disease. *Arch Neurol.* 1995;52:81-8.

Bird TD. Genetic factors in Alzheimer's disease. *N Engl J Med.* 2005;352:862-4.

Blennow K, Wallin A. Clinical heterogeneity of probable Alzheimer's disease. *J Geriatr Psychiatry Neurol.* 1992;5:106-13.

Bloom BS, de Pouvourville N, Straus WL. Cost of illness of Alzheimer's disease: how useful are current estimates? *Gerontologist.* 2003;43:158-64.

Bornebroek M, Haan J, Maat-Schieman ML, Van Duinen SG, Roos RA. Hereditary cerebral hemorrhage with amyloidosis-Dutch type (HCHWA-D): I--A review of clinical, radiologic and genetic aspects. *Brain Pathol.* 1996;6:111-4.

Bowler JV. Criteria for vascular dementia: replacing dogma with data. *Arch Neurol.* 2000;57:170-1.

Bozzali M, Falini A, Franceschi M, Cercignani M, Zuffi M, Scotti G, Comi G, Filippi M. White matter damage in Alzheimer's disease assessed in vivo using diffusion tensor magnetic resonance imaging. *J Neurol Neurosurg Psychiatry.* 2002;72:742-6.

Braak H, Braak E. Neuropathological staging of Alzheimer-related changes. *Acta Neuropathol.* 1991;82:239-59.

Brookmeyer R, Gray S, Kawas C. Projections of Alzheimer's disease in the United States and the public health impact of delaying disease onset. *Am J Public Health.* 1998;88:1337-42.

Brun A, Englund E. Regional pattern of degeneration in Alzheimer's disease: neuronal loss and histopathological grading. *Histopathology.* 1981;5:549-64.

Brun A, Englund E. A white matter disorder in dementia of the Alzheimer type: a pathoanatomical study. *Ann Neurol.* 1986;19:253-62.

Brun A, Gustafson L. The longitudinal dementia study: A 25-year perspective on neuropathology, differential diagnosis and treatment. In Corain B, Iqbal K, Nicolini M, Winblad B, Wisniewski H, Zatta P (eds): *Alzheimer's Disease - Advances in Clinical and Basic Research*, New York, John Wiley and Sons Ltd, 1993. 3-18.

Burger PC, Vogel FS. The development of the pathologic changes of Alzheimer's disease and senile dementia in patients with Down's syndrome. *Am J Pathol.* 1973;73:457-76.

Cadavid D, Mena H, Koeller K, Frommelt RA. Cerebral beta amyloid angiopathy is a risk factor for cerebral ischemic infarction. A case control study in human brain biopsies. *J Neuropathol Exp Neurol.* 2000;59:768-773.

Calhoun ME, Burgermeister P, Phinney AL, Stalder M, Tolnay M, Wiederhold KH, Abramowski D, Sturchler-Pierrat C, Sommer B, Staufenbiel M, Jucker M. Neuronal overexpression of mutant amyloid precursor protein results in prominent deposition of cerebrovascular amyloid. *Proc Natl Acad Sci USA.* 1999;96:14088-93.

Canadian study of health and aging: study methods and prevalence of dementia. *CMAJ.* 1994;150:899-913.

Castano EM, Prelli F, Wisniewski T, Golabek A, Kumar RA, Soto C, Frangione B. Fibrillogenesis in Alzheimer's disease of amyloid beta peptides and apolipoprotein E. *Biochem J.* 1995;306:599-604.

Castellani RJ, Smith MA, Perry G, Friedland RP. Cerebral amyloid angiopathy: major contributor or decorative response to Alzheimer's disease pathogenesis. *Neurobiol Aging.* 2004;25:599-602.

Chalmers K, Wilcock GK, Love S. APOE epsilon 4 influences the pathological phenotype of Alzheimer's disease by favouring cerebrovascular over parenchymal accumulation of A beta protein. *Neuropathol Appl Neurobiol.* 2003;29:231-8.

Chui HC, Mack W, Jackson JE, Mungas D, Reed BR, Tinklenberg J, Chang FL, Skinner K, Tasaki C, Jagust WJ. Clinical criteria for the diagnosis of vascular dementia: a multicenter study of comparability and interrater reliability. *Arch Neurol.* 2000;57:191-196.

Citron M, Westaway D, Xia W, Carlson G, Diehl T, Levesque G, Johnson-Wood K, Lee M, Seubert P, Davis A, Kholodenko D, Motter R, Sherrington R, Perry B, Yao H, Strome R, Lieberburg I, Rommens J, Kim S, Schenk D, Fraser P, St George Hyslop P, Selkoe DJ. Mutant presenilins of Alzheimer's disease increase production of 42-residue amyloid beta-protein in both transfected cells and transgenic mice. *Nat Med.* 1997;3:67-72.

Courtney C, Farrell D, Gray R, Hills R, Lynch L, Sellwood E, Edwards S, Hardy-

man W, Raftery J, Crome P, Lendon C, Shaw H, Bentham P; AD2000 Collaborative Group. Long-term donepezil treatment in 565 patients with Alzheimer's disease (AD2000): randomised double-blind trial. *Lancet*. 2004;363:2105-15.

Coyle JT, Price DL, DeLong MR. Alzheimer's disease: a disorder of cortical cholinergic innervation. *Science*. 1983;219:1184-90.

Crapper DR, Krishnan SS, Quittkat S. Aluminium, neurofibrillary degeneration and Alzheimer's disease. *Brain*. 1976;99:67-80.

Cumming JN, Iserloh U, Kennedy ME. Design and development of BACE-1 inhibitors. *Curr Opin Drug Discov Devel*. 2004;7:536-56.

Davignon J, Gregg RE, Sing CF. Apolipoprotein E polymorphism and atherosclerosis. *Arteriosclerosis*. 1988;8:1-21.

de la Torre JC. Alzheimer disease as a vascular disorder: nosological evidence. *Stroke*. 2002;33:1152-62.

de la Torre JC, Pappas BA, Prevot V, Emmerling MR, Mantione K, Fortin T, Watson MD, Stefano GB. Hippocampal nitric oxide upregulation precedes memory loss and A beta 1-40 accumulation after chronic brain hypoperfusion in rats. *Neurol Res*. 2003;25:635-41.

Deane R, Wu Z, Zlokovic BV. RAGE (yin) versus LRP (yang) balance regulates alzheimer amyloid beta-peptide clearance through transport across the blood-brain barrier. *Stroke*. 2004;35:2628-31.

Desmond DW, Erkinjuntti T, Sano M, Cummings JL, Bowler JV, Pasquier F, Moroney JT, Ferris SH, Stern Y, Sachdev PS, Hachinski VC. The cognitive syndrome of vascular dementia: implications for clinical trials. *Alzheimer Dis Assoc Disord*. 1999;13:S21-9.

Ebly EM, Parhad IM, Hogan DB, Fung TS. Prevalence and types of dementia in the very old: results from the Canadian Study of Health and Aging. *Neurology*. 1994;44:1593-600.

Eikelenboom P, Stam FC. Immunoglobulins and complement factors in senile plaques. An immunoperoxidase study. *Acta Neuropathol*. 1982;57:239-42.

Englund E, Brun A. Frontal lobe degeneration of non-Alzheimer type. IV. White matter changes. *Arch Gerontol Geriatr*. 1987;6:235-43.

Englund E, Brun A, Alling C. White matter changes in dementia of Alzheimer's type. Biochemical and neuropathological correlates. *Brain*. 1988;111:1425-39.

Englund E, Brun A, Gustafson L. A white-matter disease in dementia of Alzheimer's type – clinical and neuropathological correlates. *Int J Geriatr Psychiatry*. 1989;4:87-102.

Englund E, Brun A. White matter changes in dementia of Alzheimer's type: the difference in vulnerability between cell compartments. *Histopathology*. 1990;16:433-9.

Englund E. Neuropathology of white matter changes in Alzheimer's disease and vascular dementia. *Dement Geriatr Cogn Disord*. 1998;S1:6-12.

Erkinjuntti T, Benavente O, Eliasziw M, Munoz DG, Sulkava R, Haltia M, Hachinski V. Diffuse vacuolization (spongiosis) and arteriolosclerosis in the frontal white matter occurs in vascular dementia. *Arch Neurol*. 1996;53:325-332.

Erkinjuntti T, Ostbye T, Steenhuis R, Hachinski V. The effect of different diagnostic criteria on the prevalence of dementia. *N Engl J Med*. 1997;337:1667-74.

Esch FS, Keim PS, Beattie EC, Blacher RW, Culwell AR, Oltersdorf T, McClure D, Ward PJ. Cleavage of amyloid beta peptide during constitutive processing of its precursor. *Science*. 1990;248:1122-4.

Esiri MM, Wilcock GK. Cerebral amyloid angiopathy in dementia and old age. *J Neurol Neurosurg Psychiatry*. 1986;49:1221-6.

Farrer LA, Cupples LA, Haines JL, Hyman B, Kukull WA, Mayeux R, Myers RH, Pericak-Vance MA, Risch N, van Duijn CM. Effects of age, sex, and ethnicity on the association between apolipoprotein E genotype and Alzheimer disease. A meta-analysis. APOE and Alzheimer Disease Meta Analysis Consortium. *JAMA*. 1997;278:1349-56.

Fazekas F, Kleinert R, Roob G, Kleinert G, Kapeller P, Schmidt R, Hartung HP. Histopathologic analysis of foci of signal loss on gradient-echo T2*-weighted MR images in patients with spontaneous intracerebral hemorrhage: evidence of microangiopathy-related microbleeds. *AJNR Am J Neuroradiol*. 1999;20:637-42.

Fernando MS, Ince PG; MRC Cognitive Function and Ageing Neuropathology Study Group. Vascular pathologies and cognition in a population-based cohort of elderly people. *J Neurol Sci*. 2004;226:13-7.

Ferrer I, Boada Rovira M, Sanchez Guerra ML, Rey MJ, Costa-Jussa F. Neuropathology and pathogenesis of encephalitis following amyloid-beta immunization in Alzheimer's disease. *Brain Pathol.* 2004;14:11-20.

Finckh U. The future of genetic association studies in Alzheimer disease. *J Neural Transm.* 2003;110:253-66.

Folstein MF, Bassett SS, Anthony JC, Romanoski AJ, Nestadt GR. Dementia: case ascertainment in a community survey. *J Gerontol.* 1991;46:M132-8.

Fox NC, Black RS, Gilman S, Rossor MN, Griffith SG, Jenkins L, Koller M; AN1792(QS-21)-201 Study. Effects of Abeta immunization (AN1792) on MRI measures of cerebral volume in Alzheimer disease. *Neurology.* 2005;64:1563-72.

Fratiglioni L, Launer LJ, Andersen K, Breteler MM, Copeland JR, Dartigues JF, Lobo A, Martinez-Lage J, Soininen H, Hofman A. Incidence of dementia and major subtypes in Europe: A collaborative study of population-based cohorts. *Neurologic Diseases in the Elderly Research Group. Neurology.* 2000;54:S10-5.

Fryer JD, Simmons K, Parsadanian M, Bales KR, Paul SM, Sullivan PM, Holtzman DM. Human apolipoprotein E4 alters the amyloid-beta 40:42 ratio and promotes the formation of cerebral amyloid angiopathy in an amyloid precursor protein transgenic model. *J Neurosci.* 2005;25:2803-10.

Gandy S, Heppner FL. Alzheimer's amyloid immunotherapy: quo vadis? *Lancet Neurol.* 2005;4:452-3.

Gauthier S, Feldman H, Hecker J, Vellas B, Ames D, Subbiah P, Whalen E, Emir B; Donepezil MSAD Study Investigators Group. Efficacy of donepezil on behavioral symptoms in patients with moderate to severe Alzheimer's disease. *Int Psychogeriatr.* 2002;14:389-404.

Geddes JW, Tekirian TL, Soutanian NS, Ashford JW, Davis DG, Markesbery WR. Comparison of neuropathologic criteria for the diagnosis of Alzheimer's disease. *Neurobiol Aging.* 1997;18:S99-105.

Gilman S, Koller M, Black RS, Jenkins L, Griffith SG, Fox NC, Eisner L, Kirby L, Rovira MB, Forette F, Orgogozo JM; AN1792(QS-21)-201 Study Team. Clinical effects of Abeta immunization (AN1792) in patients with AD in an interrupted trial. *Neurology.* 2005;64:1553-62.

Glennier GG, Wong CW. Alzheimer's disease: initial report of the purification and characterization of a novel cerebrovascular amyloid protein. *Biochem Biophys Res*

Commun. 1984;120:885-90.

Goate A, Chartier-Harlin MC, Mullan M, Brown J, Crawford F, Fidani L, Giuffra L, Haynes A, Irving N, James L, Mantparallel R, Newton P, Rooke K, Roques P, Talbot C, Pericak-Vance M, Roses A, Williamson R, Rossor M, Owenparallel M, Hardy J. Segregation of a missense mutation in the amyloid precursor protein gene with familial Alzheimer's disease. *Nature*. 1991;349:704-6.

Goulding JM, Signorini DF, Chatterjee S, Nicoll JA, Stewart J, Morris R, Lammie GA. Inverse relation between Braak stage and cerebrovascular pathology in Alzheimer predominant dementia. *J Neurol Neurosurg Psychiatry*. 1999;67:654-7.

Grabowski TJ, Cho HS, Vonsattel JP, Rebeck GW, Greenberg SM. Novel amyloid precursor protein mutation in an Iowa family with dementia and severe cerebral amyloid angiopathy. *Ann Neurol*. 2001;49:697-705.

Gravina SA, Ho L, Eckman CB, Long KE, Otvos L Jr, Younkin LH, Suzuki N, Younkin SG. Amyloid beta protein (A beta) in Alzheimer's disease brain. Biochemical and immunocytochemical analysis with antibodies specific for forms ending at A beta 40 or A beta 42(43). *J Biol Chem*. 1995;270:7013-6.

Gray F, Dubas F, Rouillet E, Escourolle R. Leukoencephalopathy in diffuse hemorrhagic cerebral amyloid angiopathy. *Ann Neurol*. 1985;18:54-9.

Greenberg SM, Vonsattel JP, Stakes JW, Gruber M, Finklestein SP. The clinical spectrum of cerebral amyloid angiopathy: presentations without lobar hemorrhage. *Neurology*. 1993;43:2073-9.

Greenberg SM, Rebeck GW, Vonsattel JP, Gomez-Isla T, Hyman BT. Apolipoprotein E epsilon 4 and cerebral hemorrhage associated with amyloid angiopathy. *Ann Neurol*. 1995;38:254-9.

Greenberg SM, Bacskai BJ, Hyman BT. Alzheimer disease's double-edged vaccine. *Nat Med*. 2003;9:389-90.

Gustafson L. Historical overview. In O'Brien J, Ames D, Gustafson L, Folstein M, Chiu E (eds): *Cerebrovascular Disease, Cognitive Impairment and Dementia*, London, Martin Dunitz, 2004a. 3-15.

Gustafson L, Passant U. Clinical pathological correlates. In O'Brien J, Ames D, Gustafson L, Folstein M, Chiu E (eds): *Cerebrovascular Disease, Cognitive Impairment and Dementia*, London, Martin Dunitz, 2004b. 197-210.

Hachinski VC, Lassen NA, Marshall J. Multi-infarct dementia. A cause of mental deterioration in the elderly. *Lancet*. 1974;2:207-10.

Hachinski VC, Iliff LD, Zilhka E, Du Boulay GH, McAllister VL, Marshall J, Russell RW, Symon L. Cerebral blood flow in dementia. *Arch Neurol*. 1975;32:632-7.

Hardy JA, Higgins GA. Alzheimer's disease: the amyloid cascade hypothesis. *Science*. 1992;256:184-5.

Hardy J, Selkoe DJ. The amyloid hypothesis of Alzheimer's disease: progress and problems on the road to therapeutics. *Science*. 2002;297:353-6.

Hardy J. The relationship between amyloid and tau. *J Mol Neurosci*. 2003;20:203-6.

Hartmann T, Bieger SC, Bruhl B, Tienari PJ, Ida N, Allsop D, Roberts GW, Masters CL, Dotti CG, Unsicker K, Beyreuther K. Distinct sites of intracellular production for Alzheimer's disease A beta40/42 amyloid peptides. *Nat Med*. 1997;3:1016-20.

Heeren TJ, Lagaay AM, Hijmans W, Rooymans HG. Prevalence of dementia in the 'oldest old' of a Dutch community. *J Am Geriatr Soc*. 1991;39:755-9.

Helisalmi S, Hiltunen M, Vepsalainen S, Iivonen S, Mannermaa A, Lehtovirta M, Koivisto AM, Alafuzoff I, Soininen H. Polymorphisms in neprilysin gene affect the risk of Alzheimer's disease in Finnish patients. *J Neurol Neurosurg Psychiatry*. 2004;75:1746-8.

Hendrie HC. Epidemiology of dementia and Alzheimer's disease. *Am J Geriatr Psychiatry*. 1998;6:S3-18.

Hirono N, Kitagaki H, Kazui H, Hashimoto M, Mori E. Impact of white matter changes on clinical manifestation of Alzheimer's disease: A quantitative study. *Stroke*. 2000;31:2182-8.

Hof PR, Glannakopoulos P, Bouras C. The neuropathological changes associated with normal brain aging. *Histol Histopathol*. 1996;11:1075-88.

Hulette C, Nochlin D, McKeel D, Morris JC, Mirra SS, Sumi SM, Heyman A. Clinical-neuropathologic findings in multi-infarct dementia: a report of six autopsied cases. *Neurology*. 1997;48:668-72.

Hulette CM, Welsh-Bohmer KA, Murray MG, Saunders AM, Mash DC, McIntyre LM. Neuropathological and neuropsychological changes in "normal" aging: evidence for preclinical Alzheimer disease in cognitively normal individuals. *J Neuropathol Exp Neurol.* 1998;57:1168-74.

Hyman BT, Marzloff K, Arriagada PV. The lack of accumulation of senile plaques or amyloid burden in Alzheimer's disease suggests a dynamic balance between amyloid deposition and resolution. *J Neuropathol Exp Neurol.* 1993;52:594-600.

Iqbal K, Alonso AC, El-Akkad E, Gong CX, Haque N, Khatoon S, Tanimukai H, Tsujio I, Grundke-Iqbal I. Alzheimer neurofibrillary degeneration: Significance, mechanism and therapeutic targets. In Iqbal K, Winblad B (eds): *Alzheimer's Disease and Related Disorders: Research Advances*, Bucharest, "Ana Aslan" International Academy of Aging, 2003, pp 277-292.

Iqbal K, Grundke-Iqbal I. Metabolic/signal transduction hypothesis of Alzheimer's disease and other tauopathies. *Acta Neuropathol.* 2005;109:25-31.

Ishihara T, Takahashi M, Yokota T, Yamashita Y, Gondo T, Uchino F, Iwamoto N. The significance of cerebrovascular amyloid in the aetiology of superficial (lobar) cerebral haemorrhage and its incidence in the elderly population. *J Pathol.* 1991;165:229-34.

Itoh Y, Yamada M, Hayakawa M, Otomo E, Miyatake T. Cerebral amyloid angiopathy: a significant cause of cerebellar as well as lobar cerebral hemorrhage in the elderly. *J Neurol Sci.* 1993;116:135-41.

Iwata N, Tsubuki S, Takaki Y, Watanabe K, Sekiguchi M, Hosoki E, Kawashima-Morishima M, Lee HJ, Hama E, Sekine-Aizawa Y, Saido TC. Identification of the major Abeta1-42-degrading catabolic pathway in brain parenchyma: suppression leads to biochemical and pathological deposition. *Nat Med.* 2000;6:143-50.

Iwatsubo T, Odaka A, Suzuki N, Mizusawa H, Nukina N, Ihara Y. Visualization of A beta 42(43) and A beta 40 in senile plaques with end-specific A beta monoclonals: evidence that an initially deposited species is A beta 42(43). *Neuron.* 1994;13:45-53.

Jagust WJ, Eberling JL, Reed BR, Mathis CA, Budinger TF. Clinical studies of cerebral blood flow in Alzheimer's disease. *Ann NY Acad Sci.* 1997;826:254-62.

Janota I, Mirsen TR, Hachinski VC, Lee DH, Merskey H. Neuropathologic correlates of leuko-araiosis. *Arch Neurol.* 1989;46:1124-1128.

Jarrett JT, Berger EP, Lansbury PT. The carboxy terminus of the beta amyloid protein is critical for the seeding of amyloid formation: implications for the pathogenesis of Alzheimer's disease. *Biochemistry*. 1993;32:4693-7.

Jarvik GP, Wijsman EM, Kukull WA, Schellenberg GD, Yu C, Larson EB. Interactions of apolipoprotein E genotype, total cholesterol level, age, and sex in prediction of Alzheimer's disease: a case-control study. *Neurology*. 1995;45:1092-6.

Jellinger K. Cerebrovascular amyloidosis with cerebral hemorrhage. *J Neurol*. 1977;214:195-206.

Jellinger KA. The pathology of ischemic-vascular dementia: an update. *J Neurol Sci*. 2002;203-204:153-7.

Jorm AF, Korten AE, Henderson AS. The prevalence of dementia: a quantitative integration of the literature. *Acta Psychiatr Scand*. 1987;76:464-479.

Jorm AF. Cross-national comparisons of the occurrence of Alzheimer's and vascular dementias. *Eur Arch Psychiatry Clin Neurosci*. 1991;240:218-22.

Kaduszkiewicz H, Zimmermann T, Beck-Bornholdt HP, van den Bussche H. Cholinesterase inhibitors for patients with Alzheimer's disease: systematic review of randomised clinical trials. *BMJ*. 2005;331:321-7.

Kalaria RN, Kenny RA, Ballard CG, Perry R, Ince P, Polvikoski T. Towards defining the neuropathological substrates of vascular dementia. *J Neurol Sci*. 2004;226:75-80.

Kang DE, Pietrzik CU, Baum L, Chevallier N, Merriam DE, Kounnas MZ, Wagner SL, Troncoso JC, Kawas CH, Katzman R, Koo EH. Modulation of amyloid beta-protein clearance and Alzheimer's disease susceptibility by the LDL receptor-related protein pathway. *J Clin Invest*. 2000;106:1159-66.

Kang J, Lemaire HG, Unterbeck A, Salbaum JM, Masters CL, Grzeschik KH, Multhaup G, Beyreuther K, Muller-Hill B. The precursor of Alzheimer's disease amyloid A4 protein resembles a cell-surface receptor. *Nature*. 1987;325:733-6.

Kazee AM, Johnson EM. Alzheimer's Disease Pathology in Non-Demented Elderly. *J Alzheimers Dis*. 1998;1:81-89.

Khachaturian ZS. Diagnosis of Alzheimer's disease. *Arch Neurol*. 1985;42:1097-105.

Khachaturian ZS, Khachaturian AS. Public health premise for national research priorities: Mortality versus disability. *Alzheimer's & Dementia*. 2005;1:2-4.

Kinsella K, Velkoff VA. *An Aging World: 2001*, Washington DC, U.S. Government Printing Office, 2001, pp 1-3.

Kirkitadze MD, Bitan G, Teplow DB. Paradigm shifts in Alzheimer's disease and other neurodegenerative disorders: the emerging role of oligomeric assemblies. *J Neurosci Res*. 2002;69:567-77.

Kiuru S, Salonen O, Haltia M. Gelsolin-related spinal and cerebral amyloid angiopathy. *Ann Neurol*. 1999;45:305-11.

Knopman DS, Parisi JE, Salviati A, Floriach-Robert M, Boeve BF, Ivnik RJ, Smith GE, Dickson DW, Johnson KA, Petersen LE, McDonald WC, Braak H, Petersen RC. Neuropathology of cognitively normal elderly. *J Neuropathol Exp Neurol*. 2003;62:1087-95.

Koistinaho M, Kettunen MI, Goldsteins G, Keinanen R, Salminen A, Ort M, Bures J, Liu D, Kauppinen RA, Higgins LS, Koistinaho J. Beta-amyloid precursor protein transgenic mice that harbor diffuse A beta deposits but do not form plaques show increased ischemic vulnerability: role of inflammation. *Proc Natl Acad Sci USA*. 2002;99:1610-5.

Konno S, Meyer JS, Terayama Y, Margishvili GM, Mortel KF. Classification, diagnosis and treatment of vascular dementia. *Drugs Aging*. 1997;11:361-73.

Kounnas MZ, Moir RD, Rebeck GW, Bush AI, Argraves WS, Tanzi RE, Hyman BT, Strickland DK. LDL receptor-related protein, a multifunctional ApoE receptor, binds secreted beta-amyloid precursor protein and mediates its degradation. *Cell*. 1995;82:331-40.

Kovari E, Gold G, Herrmann FR, Canuto A, Hof PR, Michel JP, Bouras C, Giannakopoulos P. Cortical microinfarcts and demyelination significantly affect cognition in brain aging. *Stroke*. 2004;35:410-4.

Kurochkin IV, Goto S. Alzheimer's beta-amyloid peptide specifically interacts with and is degraded by insulin degrading enzyme. *FEBS Lett*. 1994;345:33-7.

LaDu MJ, Falduto MT, Manelli AM, Reardon CA, Getz GS, Frail DE. Isoform-specific binding of apolipoprotein E to beta-amyloid. *J Biol Chem*. 1994;269:23403-6.

Langa KM, Foster NL, Larson EB. Mixed dementia: emerging concepts and therapeutic implications. *JAMA*. 2004;292:2901-8.

Lemere CA, Spooner ET, Leverone JF, Mori C, Iglesias M, Bloom JK, Seabrook TJ. Amyloid-beta immunization in Alzheimer's disease transgenic mouse models and wildtype mice. *Neurochem Res*. 2003;28:1017-27.

Leys D, Pruvo JP, Parent M, Vermersch P, Soetaert G, Steinling M, Delacourte A, Defossez A, Rapoport A, Clarisse J, Petit H. Could Wallerian degeneration contribute to "leuko-araiosis" in subjects free of any vascular disorder? *J Neurol Neurosurg Psychiatry*. 1991;54:46-50.

Lindsay J, Laurin D, Verreault R, Hebert R, Helliwell B, Hill GB, McDowell I. Risk factors for Alzheimer's disease: a prospective analysis from the Canadian Study of Health and Aging. *Am J Epidemiol*. 2002;156:445-53.

Lindvall O, Kokaia Z. Stem cell therapy for human brain disorders. *Kidney Int*. 2005;68:1937-9.

Loeb C, Meyer JS. Vascular dementia: still a debatable entity? *J Neurol Sci*. 1996;143:31-40.

Londos E, Passant U, Gustafson L, Brun A. Neuropathological correlates to clinically defined dementia with Lewy bodies. *Int J Geriatr Psychiatry*. 2001;16:667-79.

Love S, Nicoll JA, Hughes A, Wilcock GK. APOE and cerebral amyloid angiopathy in the elderly. *Neuroreport*. 2003;14:1535-6.

Lue LF, Kuo YM, Roher AE, Brachova L, Shen Y, Sue L, Beach T, Kurth JH, Rydel RE, Rogers J. Soluble amyloid beta peptide concentration as a predictor of synaptic change in Alzheimer's disease. *Am J Pathol*. 1999;155:853-62.

Mahley RW. Apolipoprotein E: cholesterol transport protein with expanding role in cell biology. *Science*. 1988;240:622-30.

Maiorini AF, Gaunt MJ, Jacobsen TM, McKay AE, Waldman LD, Raffa RB. Potential novel targets for Alzheimer pharmacotherapy: I. Secretases. *J Clin Pharm Ther*. 2002;27:169-83.

Mandybur TI. Cerebral amyloid angiopathy: the vascular pathology and complications. *J Neuropathol Exp Neurol*. 1986;45:79-90.

Mann DM, Lincoln J, Yates PO, Stamp JE, Toper S. Changes in the monoamine containing neurones of the human CNS in senile dementia. *Br J Psychiatry*. 1980;136:533-41.

Mann DM, Iwatsubo T, Pickering-Brown SM, Owen F, Saido TC, Perry RH. Preferential deposition of amyloid beta protein (Abeta) in the form Abeta40 in Alzheimer's disease is associated with a gene dosage effect of the apolipoprotein E E4 allele. *Neurosci Lett*. 1997;221:81-4.

Martyn CN, Barker DJ, Osmond C, Harris EC, Edwardson JA, Lacey RF. Geographical relation between Alzheimer's disease and aluminum in drinking water. *Lancet*. 1989;1:59-62.

Masliah E, Hansen L, Adame A, Crews L, Bard F, Lee C, Seubert P, Games D, Kirby L, Schenk D. Abeta vaccination effects on plaque pathology in the absence of encephalitis in Alzheimer disease. *Neurology*. 2005;64:129-31.

Matsuda H. Cerebral blood flow and metabolic abnormalities in Alzheimer's disease. *Ann Nucl Med*. 2001;15:85-92.

Matthews KL, Chen CP, Esiri MM, Keene J, Minger SL, Francis PT. Noradrenergic changes, aggressive behavior, and cognition in patients with dementia. *Biol Psychiatry*. 2002;51:407-16.

Mattson MP. Pathways towards and away from Alzheimer's disease. *Nature*. 2004;430:631-9.

McConnell S, Riggs J. Alzheimer's research: Can it help save our nation's entitlement programs? *Alzheimer's & Dementia*. 2005;1:84-86.

McLean CA, Cherny RA, Fraser FW, Fuller SJ, Smith MJ, Beyreuther K, Bush AI, Masters CL. Soluble pool of Abeta amyloid as a determinant of severity of neurodegeneration in Alzheimer's disease. *Ann Neurol*. 1999;46:860-6.

McNamara MJ, Gomez-Isla T, Hyman BT. Apolipoprotein E genotype and deposits of Abeta40 and Abeta42 in Alzheimer disease. *Arch Neurol*. 1998;55:1001-4.

Mead S, James-Galton M, Revesz T, Doshi RB, Harwood G, Pan EL, Ghiso J, Frangione B, Plant G. Familial British dementia with amyloid angiopathy: early clinical, neuropsychological and imaging findings. *Brain*. 2000;123:975-91.

Meguro K, Ishii H, Yamaguchi S, Ishizaki J, Shimada M, Sato M, Hashimoto R,

Shimada Y, Meguro M, Yamadori A, Sekita Y. Prevalence of dementia and dementing diseases in Japan: the Tajiri project. *Arch Neurol.* 2002;59:1109-14.

Menendez M. Pathological and clinical heterogeneity of presenilin 1 gene mutations. *J Alzheimers Dis.* 2004;6:475-82.

Mirra SS, Heyman A, McKeel D, Sumi SM, Crain BJ, Brownlee LM, Vogel FS, Hughes JP, van Belle G, Berg L. The Consortium to Establish a Registry for Alzheimer's Disease (CERAD). Part II. Standardization of the neuropathologic assessment of Alzheimer's disease. *Neurology.* 1991;41:479-86.

Mori H, Takio K, Ogawara M, Selkoe DJ. Mass spectrometry of purified amyloid beta protein in Alzheimer's disease. *J Biol Chem.* 1992;267:17082-6.

Munoz DG, Hastak SM, Harper B, Lee D, Hachinski VC. Pathologic correlates of increased signals of the centrum ovale on magnetic resonance imaging. *Arch Neurol.* 1993;50:492-497.

Myers RH, Schaefer EJ, Wilson PW, D'Agostino R, Ordovas JM, Espino A, Au R, White RF, Knoefel JE, Cobb JL, McNulty KA, Beiser A, Wolf PA. Apolipoprotein E epsilon4 association with dementia in a population-based study: The Framingham study. *Neurology.* 1996;46:673-7.

Nagy Z, Esiri MM, Jobst KA, Morris JH, King EM, McDonald B, Litchfield S, Smith A, Barnetson L, Smith AD. Relative roles of plaques and tangles in the dementia of Alzheimer's disease: correlations using three sets of neuropathological criteria. *Dementia.* 1995;6:21-31.

Narita M, Holtzman DM, Schwartz AL, Bu G. Alpha2-macroglobulin complexes with and mediates the endocytosis of beta-amyloid peptide via cell surface low-density lipoprotein receptor-related protein. *J Neurochem.* 1997;69:1904-11.

Naslund J, Haroutunian V, Mohs R, Davis KL, Davies P, Greengard P, Buxbaum JD. Correlation between elevated levels of amyloid beta-peptide in the brain and cognitive decline. *JAMA.* 2000;283:1571-7.

Natte R, Maat-Schieman ML, Haan J, Bornebroek M, Roos RA, van Duinen SG. Dementia in hereditary cerebral hemorrhage with amyloidosis-Dutch type is associated with cerebral amyloid angiopathy but is independent of plaques and neurofibrillary tangles. *Ann Neurol.* 2001;50:765-72.

Neuropathology Group. Medical Research Council Cognitive Function and Aging Study. Pathological correlates of late-onset dementia in a multicentre, community-

based population in England and Wales. Neuropathology Group of the Medical Research Council Cognitive Function and Ageing Study (MRC CFAS). *Lancet*. 2001;357:169-75.

Newell KL, Hyman BT, Growdon JH, Hedley-Whyte ET. Application of the National Institute on Aging (NIA)-Reagan Institute criteria for the neuropathological diagnosis of Alzheimer disease. *J Neuropathol Exp Neurol*. 1999;58:1147-55.

Nicoll JA, Wilkinson D, Holmes C, Steart P, Markham H, Weller RO. Neuropathology of human Alzheimer disease after immunization with amyloid-beta peptide: a case report. *Nat Med*. 2003;9:448-52.

Nicoll JA, Yamada M, Frackowiak J, Mazur-Kolecka B, Weller RO. Cerebral amyloid angiopathy plays a direct role in the pathogenesis of Alzheimer's disease. Pro-CAA position statement. *Neurobiol Aging*. 2004;25:589-97

Okazaki H, Reagan TJ, Campbell RJ. Clinicopathologic studies of primary cerebral amyloid angiopathy. *Mayo Clin Proc*. 1979;54:22-31.

Olichney JM, Hansen LA, Hofstetter R, Grundman R, Katzman R, Thal LJ. Cerebral infarction in Alzheimer's disease is associated with severe amyloid angiopathy and hypertension. *Arch Neurol*. 1995;52:702-708.

Olichney JM, Hansen LA, Hofstetter CR, Lee JH, Katzman R, Thal LJ. Association between severe cerebral amyloid angiopathy and cerebrovascular lesions in Alzheimer disease is not a spurious one attributable to apolipoprotein E4. *Arch Neurol*. 2000;57:869-74.

Orgogozo JM, Gilman S, Dartigues JF, Laurent B, Puel M, Kirby LC, Jouanny P, Dubois B, Eisner L, Flitman S, Michel BF, Boada M, Frank A, Hock C. Subacute meningoencephalitis in a subset of patients with AD after Abeta42 immunization. *Neurology*. 2003;61:46-54.

Ott A, Breteler MM, van Harskamp F, Claus JJ, van der Cammen TJ, Grobbee DE, Hofman A. Prevalence of Alzheimer's disease and vascular dementia: association with education. The Rotterdam study. *BMJ*. 1995;310:970-3.

Overmyer M, Helisalimi S, Soininen H, Laakso M, Riekkinen P Sr, Alafuzoff I. Astrogliosis and the ApoE genotype. an immunohistochemical study of postmortem human brain tissue. *Dement Geriatr Cogn Disord*. 1999;10:252-7.

Palacios G, Mengod G, Tortosa A, Ferrer I, Palacios JM. Increased beta-amyloid precursor protein expression in astrocytes in the gerbil hippocampus following

ischaemia: association with proliferation of astrocytes. *Eur J Neurosci.* 1995;7:501-10.

Paleacu D, Mazeh D, Mirecki I, Even M, Barak Y. Donepezil for the treatment of behavioral symptoms in patients with Alzheimer's disease. *Clin Neuropharmacol.* 2002;25:313-7.

Palmer AM, Wilcock GK, Esiri MM, Francis PT, Bowen DM. Monoaminergic innervation of the frontal and temporal lobes in Alzheimer's disease. *Brain Res.* 1987;401:231-8.

Palsdottir A, Abrahamson M, Thorsteinsson L, Arnason A, Olafsson I, Grubb A, Jensson O. Mutation in cystatin C gene causes hereditary brain haemorrhage. *Lancet.* 1988;2:603-4.

Panegyres PK. The functions of the amyloid precursor protein gene. *Rev Neurosci.* 2001;12:1-39.

Pfeifer LA, White LR, Ross GW, Petrovitch H, Launer LJ. Cerebral amyloid angiopathy and cognitive function: the HAAS autopsy study. *Neurology.* 2002;58:1629-34.

Pfeifer M, Boncristiano S, Bondolfi L, Stalder A, Deller T, Staufenbiel M, Mathews PM, Jucker M. Cerebral hemorrhage after passive anti-Abeta immunotherapy. *Science.* 2002;298:1379.

Pohjasvaara T, Mantyla R, Ylikoski R, Kaste M, Erkinjuntti T. Comparison of different clinical criteria (DSM-III, ADDTC, ICD-10, NINDS-AIREN, DSM-IV) for the diagnosis of vascular dementia. *Stroke.* 2000;31:2952-7.

Poirier J. Apolipoprotein E and cholesterol metabolism in the pathogenesis and treatment of Alzheimer's disease. *Trends Mol Med.* 2003;9:94-101

Premkumar DR, Cohen DL, Hedera P, Friedland RP, Kalaria RN. Apolipoprotein E-epsilon4 alleles in cerebral amyloid angiopathy and cerebrovascular pathology associated with Alzheimer's disease. *Am J Pathol.* 1996;148:2083-95.

Preston SD, Steart PV, Wilkinson A, Nicoll JA, Weller RO. Capillary and arterial cerebral amyloid angiopathy in Alzheimer's disease: defining the perivascular route for the elimination of amyloid beta from the human brain. *Neuropathol Appl Neurobiol.* 2003;29:106-17.

Racke MM, Boone LI, Hepburn DL, Parsadainian M, Bryan MT, Ness DK,

Pirooz KS, Jordan WH, Brown DD, Hoffman WP, Holtzman DM, Bales KR, Gitter BD, May PC, Paul SM, DeMattos RB. Exacerbation of cerebral amyloid angiopathy-associated microhemorrhage in amyloid precursor protein transgenic mice by immunotherapy is dependent on antibody recognition of deposited forms of amyloid beta. *J Neurosci.* 2005;25:629-36.

Raskind MA, Carta A, Bravi D. Is early-onset Alzheimer disease a distinct subgroup within the Alzheimer disease population? *Alzheimer Dis Assoc Disord.* 1995;9:S2-6.

Rensink AA, de Waal RM, Kremer B, Verbeek MM. Pathogenesis of cerebral amyloid angiopathy. *Brain Res Brain Res Rev.* 2003;43:207-23

Revesz T, Holton JL, Lashley T, Plant G, Rostagno A, Ghiso J, Frangione B. Sporadic and familial cerebral amyloid angiopathies. *Brain Pathol.* 2002;12:343-57.

Revesz T, Ghiso J, Lashley T, Plant G, Rostagno A, Frangione B, Holton JL. Cerebral amyloid angiopathies: A pathologic, biochemical and genetic view. *J Neuro-pathol Exp Neurol.* 2003;62:885-898.

Rockwood K. Vascular cognitive impairment and vascular dementia. *J Neurol Sci.* 2002;203-204:23-7.

Roher AE, Lowenson JD, Clarke S, Wolkow C, Wang R, Cotter RJ, Reardon IM, Zurcher-Neely HA, Heinrikson RL, Ball MJ, Greenberg B. Structural alterations in the peptide backbone of beta-amyloid core protein may account for its deposition and stability in Alzheimer's disease. *J Biol Chem.* 1993;268:3072-83.

Roher AE, Kuo YM, Esh C, Knebel C, Weiss N, Kalback W, Luehrs DC, Childress JL, Beach TG, Weller RO, Kokjohn TA. Cortical and leptomeningeal cerebrovascular amyloid and white matter pathology in Alzheimer's disease. *Mol Med.* 2003;9:112-22.

Roher AE, Esh C, Rahman A, Kokjohn TA, Beach TG. Atherosclerosis of cerebral arteries in Alzheimer disease. *Stroke.* 2004;35:2623-7.

Roman GC. Vascular dementia: A historical background. *Int Psychogeriatr.* 2003;15:S11-13.

Roman GC. Facts, myths, and controversies in vascular dementia. *J Neurol Sci.* 2004;226:49-52.

Sadik K, Wilcock G. The increasing burden of Alzheimer disease. *Alzheimer Dis*

Assoc Disord. 2003;17:S75-9.

Scheltens P, Barkhof F, Leys D, Wolters EC, Ravid R, Kamphorst W. Histopathologic correlates of white matter changes on MRI in Alzheimer's disease and normal aging. *Neurology*. 1995;45:883-888.

Schenk D, Barbour R, Dunn W, Gordon G, Grajeda H, Guido T, Hu K, Huang J, Johnson-Wood K, Khan K, Kholodenko D, Lee M, Liao Z, Lieberburg I, Motter R, Mutter L, Soriano F, Shopp G, Vasquez N, Vandever C, Walker S, Wogulis M, Yednock T, Games D, Seubert P. Immunization with amyloid-beta attenuates Alzheimer-disease-like pathology in the PDAPP mouse. *Nature*. 1999;400:173-7.

Schenk D, Games D, Seubert P. Potential treatment opportunities for Alzheimer's disease through inhibition of secretases and Abeta immunization. *J Mol Neurosci*. 2001;17:259-67.

Schenk D. Amyloid-beta immunotherapy for Alzheimer's disease: the end of the beginning. *Nat Rev Neurosci*. 2002;3:824-8.

Schmechel DE, Saunders AM, Strittmatter WJ, Crain BJ, Hulette CM, Joo SH, Pericak-Vance MA, Goldgaber D, Roses AD. Increased amyloid beta-peptide deposition in cerebral cortex as a consequence of apolipoprotein E genotype in late-onset Alzheimer disease. *Proc Natl Acad Sci USA*. 1993;90:9649-53.

Schmitt FA, Davis DG, Wekstein DR, Smith CD, Ashford JW, Markesbery WR. "Preclinical" AD revisited: neuropathology of cognitively normal older adults. *Neurology*. 2000;55:370-6.

Selkoe DJ. Clearing the brain's amyloid cobwebs. *Neuron*. 2001;32:177-80.

Selkoe DJ, Schenk D. Alzheimer's disease: molecular understanding predicts amyloid-based therapeutics. *Annu Rev Pharmacol Toxicol*. 2003;43:545-84.

Senior K. Dosing in phase II trial of Alzheimer's vaccine suspended. *Lancet Neurol*. 2002;1:3.

Shi J, Yang SH, Stubbley L, Day AL, Simpkins JW. Hypoperfusion induces overexpression of beta-amyloid precursor protein mRNA in a focal ischemic rodent model. *Brain Res*. 2000;853:1-4.

Shibata M, Yamada S, Kumar SR, Calero M, Bading J, Frangione B, Holtzman DM, Miller CA, Strickland DK, Ghiso J, Zlokovic BV. Clearance of Alzheimer's amyloid-ss(1-40) peptide from brain by LDL receptor-related protein-1 at the

blood-brain barrier. *J Clin Invest.* 2000;106:1489-99.

Shoji M, Golde TE, Ghiso J, Cheung TT, Estus S, Shaffer L, Cai XD, McKay DM, Tintner R, Frangione B, Younkin SG. Production of the Alzheimer amyloid beta protein by normal proteolytic processing. *Science* 1992;258:126-129.

Siemers E, Skinner M, Dean RA, Gonzales C, Satterwhite J, Farlow M, Ness D, May PC. Safety, Tolerability, and Changes in Amyloid beta Concentrations After Administration of a gamma-Secretase Inhibitor in Volunteers. *Clin Neuropharmacol.* 2005;28:126-132.

Silbert PL, Bartleson JD, Miller GM, Parisi JE, Goldman MS, Meyer FB. Cortical petechial hemorrhage, leukoencephalopathy, and subacute dementia associated with seizures due to cerebral amyloid angiopathy. *Mayo Clin Proc.* 1995;70:477-80.

Sinha S, Lieberburg I. Cellular mechanisms of beta-amyloid production and secretion. *Proc Natl Acad Sci USA.* 1999;96:11049-53.

Sjöbeck M, Englund E. Glial levels determine severity of white matter disease in Alzheimer's disease: a neuropathological study of glial changes. *Neuropathol Appl Neurobiol.* 2003a;29:159-69.

Sjöbeck M, Haglund M, Persson A, Sturesson K, Englund E. Brain tissue microarrays in dementia research: white matter microvascular pathology in Alzheimer's disease. *Neuropathology.* 2003b;23:290-5.

Skoog I, Nilsson L, Palmertz B, Andreasson LA, Svanborg A. A population-based study of dementia in 85-year-olds. *N Engl J Med.* 1993;328:153-8.

Snow AD, Mar H, Nochlin D, Kimata K, Kato M, Suzuki S, Hassell J, Wight TN. The presence of heparan sulfate proteoglycans in the neuritic plaques and congophilic angiopathy in Alzheimer's disease. *Am J Pathol.* 1988;133:456-63.

Sparks DL, Scheff SW, Liu H, Landers T, Danner F, Coyne CM, Hunsaker JC 3rd. Increased density of senile plaques (SP), but not neurofibrillary tangles (NFT), in non-demented individuals with the apolipoprotein E4 allele: comparison to confirmed Alzheimer's disease patients. *J Neurol Sci.* 1996;138:97-104.

Starkstein SE, Sabe L, Vazquez S, Di Lorenzo G, Martinez A, Petracca G, Teson A, Chemerinski E, Leiguarda R. Neuropsychological, psychiatric, and cerebral perfusion correlates of leukoaraiosis in Alzheimer's disease. *J Neurol Neurosurg Psychiatry.* 1997;63:66-73.

Stewart R. Vascular dementia: a diagnosis running out of time. *Br J Psychiatry*. 2002;180:152-6.

Stewart R. Classification and diagnostic criteria. In O'Brien J, Ames D, Gustafson L, Folstein M, Chiu E (eds): *Cerebrovascular Disease, Cognitive Impairment and Dementia*, London, Martin Dunitz, 2004. 17-32.

Stout JC, Jernigan TL, Archibald SL, Salmon DP. Association of dementia severity with cortical gray matter and abnormal white matter volumes in dementia of the Alzheimer type. *Arch Neurol*. 1996;53:742-9.

Strittmatter WJ, Saunders AM, Schmechel D, Pericak-Vance M, Enghild J, Salvesen GS, Roses AD. Apolipoprotein E: high-avidity binding to beta-amyloid and increased frequency of type 4 allele in late-onset familial Alzheimer disease. *Proc Natl Acad Sci USA*. 1993;90:1977-81.

Suh, GH, Shah A. A review of the epidemiological transition of dementia – cross-national comparisons of the indices related to Alzheimer's disease and vascular dementia. *Acta Psychiatr Scand*. 2001;104:4-11.

Suzuki N, Cheung TT, Cai XD, Odaka A, Otvos L Jr, Eckman C, Golde TE, Younkin SG. An increased percentage of long amyloid beta protein secreted by familial amyloid beta protein precursor (beta APP717) mutants. *Science*. 1994;264:1336-40.

Tanzi RE, Moir RD, Wagner SL. Clearance of Alzheimer's Abeta peptide: the many roads to perdition. *Neuron*. 2004;43:605-8.

Thal DR, Ghebremedhin E, Rub U, Yamaguchi H, Tredici KD, Braak H. Two types of sporadic cerebral amyloid angiopathy. *J Neuropathol Exp Neurol*. 2002;61:282-93.

Thatte U. AN-1792 (Elan). *Curr Opin Investig Drugs*. 2001;2:663-7.

Tiraboschi P, Hansen LA, Masliah E, Alford M, Thal LJ, Corey-Bloom J. Impact of APOE genotype on neuropathologic and neurochemical markers of Alzheimer disease. *Neurology*. 2004;62:1977-83.

Tomimoto H, Akiguchi I, Akiyama H, Ikeda K, Wakita H, Lin JX, Budka H. Vascular changes in white matter lesions of Alzheimer's disease. *Acta Neuropathol*. 1999;97:629-634.

- Tomiyama T, Corder EH, Mori H. Molecular pathogenesis of apolipoprotein E-mediated amyloidosis in late-onset Alzheimer's disease. *Cell Mol Life Sci.* 1999;56:268-79.
- Tomlinson BE, Irving D, Blessed G. Cell loss in the locus coeruleus in senile dementia of Alzheimer type. *J Neurol Sci.* 1981;49:419-28.
- Tsiskaridze A, Shakarishvili R, Janelidze M, Vashadze T, Chikhladze M. Cognitive correlates of leukoaraiosis in the early stages of Alzheimer's disease. *Funct Neurol.* 1998;13:17-25.
- Ueda K, Kawano H, Hasuo Y, Fujishima M. Prevalence and etiology of dementia in a Japanese community. *Stroke.* 1992;23:798-803.
- van den Boom R, Bornebroek M, Behloul F, van den Berg-Huysmans AA, Haan J, van Buchem MA. Microbleeds in hereditary cerebral hemorrhage with amyloidosis-Dutch type. *Neurology.* 2005;64:1288-9.
- van Dorpe J, Smeijers L, Dewachter I, Nuyens D, Spittaels K, Van Den Haute C, Mercken M, Moechars D, Laenen I, Kuiperi C, Bruynseels K, Tesseur I, Loos R, Vanderstichele H, Checler F, Sciot R, Van Leuven F. Prominent cerebral amyloid angiopathy in transgenic mice overexpressing the london mutant of human APP in neurons. *Am J Pathol.* 2000;157:1283-98.
- Vas CJ, Pinto C, Panikker D, Noronha S, Deshpande N, Kulkarni L, Sachdeva S. Prevalence of dementia in an urban Indian population. *Int Psychogeriatr.* 2001;13:439-50.
- Vidal R, Frangione B, Rostagno A, Mead S, Revesz T, Plant G, Ghiso J. A stop-codon mutation in the BRI gene associated with familial British dementia. *Nature.* 1999;399:776-81.
- Vidal R, Revesz T, Rostagno A, Kim E, Holton JL, Bek T, Bojsen-Moller M, Braendgaard H, Plant G, Ghiso J, Frangione B. A decamer duplication in the 3' region of the BRI gene originates an amyloid peptide that is associated with dementia in a Danish kindred. *Proc Natl Acad Sci USA.* 2000;97:4920-5.
- Vonsattel JP, Myers RH, Hedley-Whyte ET, Ropper AH, Bird ED, Richardson EP. Cerebral amyloid angiopathy without and with cerebral hemorrhages: a comparative histological study. *Ann Neurol.* 1991;30:637-649.
- Walker LC, Pahnke J, Madauss M, Vogelgesang S, Pahnke A, Herbst EW, Stausske D, Walther R, Kessler C, Warzok RW. Apolipoprotein E4 promotes the

early deposition of Abeta42 and then Abeta40 in the elderly. *Acta Neuropathol.* 2000;100:36-42.

Wallin A, Blennow K. The clinical diagnosis of vascular dementia. *Dementia.* 1994;5:181-4.

Wallin AK, Gustafson L, Sjogren M, Wattmo C, Minthon L. Five-year outcome of cholinergic treatment of Alzheimer's disease: early response predicts prolonged time until nursing home placement, but does not alter life expectancy. *Dement Geriatr Cogn Disord.* 2004;18:197-206.

Wancata J, Musalek M, Alexandrowicz R, Krautgartner M. Number of dementia sufferers in Europe between the years 2000 and 2050. *Eur Psychiatry.* 2003;18:306-13.

Wang W, Wu S, Cheng X, Dai H, Ross K, Du X, Yin W. Prevalence of Alzheimer's disease and other dementing disorders in an urban community of Beijing, China. *Neuroepidemiology.* 2000;19:194-200.

Wattendorff AR, Frangione B, Luyendijk W, Bots GT. Hereditary cerebral haemorrhage with amyloidosis, Dutch type (HCHWA-D): clinicopathological studies. *J Neurol Neurosurg Psychiatry.* 1995;58:699-705.

Weller RO, Massey A, Newman TA, Hutchings M, Kuo YM, Roher AE. Cerebral amyloid angiopathy: amyloid beta accumulates in putative interstitial fluid drainage pathways in Alzheimer's disease. *Am J Pathol.* 1998;153:725-33.

Weller RO, Yow HY, Preston SD, Mazanti I, Nicoll JA. Cerebrovascular disease is a major factor in the failure of elimination of Abeta from the aging human brain: implications for therapy of Alzheimer's disease. *Ann NY Acad Sci.* 2002;977:162-8.

Wen Y, Onyewuchi O, Yang S, Liu R, Simpkins JW. Increased beta-secretase activity and expression in rats following transient cerebral ischemia. *Brain Res.* 2004;1009:1-8.

Whitehouse PJ, Price DL, Struble RG, Clark AW, Coyle JT, Delon MR. Alzheimer's disease and senile dementia: loss of neurons in the basal forebrain. *Science.* 1982;215:1237-9.

Wimo A, Karlsson G, Sandman PO, Corder L, Winblad B. Cost of illness due to dementia in Sweden. *Int J Geriatr Psychiatry.* 1997;12:857-61.

Wimo A, Winblad B, Aguero-Torres H, von Strauss E. The magnitude of dementia occurrence in the world. *Alzheimer Dis Assoc Disord.* 2003;17:63-7.

Wisniewski HM, Wegiel J. Beta-amyloid formation by myocytes of leptomeningeal vessels. *Acta Neuropathol.* 1994;87:233-41.

Wisniewski HM, Wegiel J, Vorbrodt AW, Mazur-Kolecka B, Frackowiak J. Role of perivascular cells and myocytes in vascular amyloidosis. *Ann NY Acad Sci.* 2000;903:6-18.

Wisniewski T, Castano EM, Golabek A, Vogel T, Frangione B. Acceleration of Alzheimer's fibril formation by apolipoprotein E in vitro. *Am J Pathol.* 1994;145:1030-5.

Wolfe MS. Therapeutic strategies for Alzheimer's disease. *Nat Rev Drug Discov.* 2002;1:859-66.

Yamaguchi H, Yamazaki T, Lemere CA, Frosch MP, Selkoe DJ. Beta amyloid is focally deposited within the outer basement membrane in the amyloid angiopathy of Alzheimer's disease. An immunoelectron microscopic study. *Am J Pathol* 1992;141:249-59.

Yanagihara T. Vascular dementia in Japan. *Ann N Y Acad Sci.* 2002;977:24-8.

Yoshitake T, Kiyohara Y, Kato I, Ohmura T, Iwamoto H, Nakayama K, Ohmori S, Nomiyama K, Kawano H, Ueda K, et al. Incidence and risk factors of vascular dementia and Alzheimer's disease in a defined elderly Japanese population: the Hisayama Study. *Neurology.* 1995;45:1161-8.

Zarow C, Lyness SA, Mortimer JA, Chui HC. Neuronal loss is greater in the locus coeruleus than nucleus basalis and substantia nigra in Alzheimer and Parkinson diseases. *Arch Neurol.* 2003;60:337-41.

Zekry D, Hauw JJ, Gold G. Mixed dementia: Epidemiology, diagnosis and treatment. *J Am Geriatr Soc.* 2002;50:1431-1438.

Zerovnik E. Amyloid-fibril formation. Proposed mechanisms and relevance to conformational disease. *Eur J Biochem.* 2002;269:3362-71.

Zhang F, Eckman C, Younkin S, Hsiao KK, Iadecola C. Increased susceptibility to ischemic brain damage in transgenic mice overexpressing the amyloid precursor protein. *J Neurosci.* 1997;17:7655-61.