



LUND UNIVERSITY

Molecular and morphological studies on non-healing venous leg ulcers.

Lundqvist, Katarina

2006

[Link to publication](#)

Citation for published version (APA):

Lundqvist, K. (2006). *Molecular and morphological studies on non-healing venous leg ulcers*. [Doctoral Thesis (compilation), Dermatology and Venereology (Lund)]. Department of Clinical Sciences, Lund University.

Total number of authors:

1

General rights

Unless other specific re-use rights are stated the following general rights apply:

Copyright and moral rights for the publications made accessible in the public portal are retained by the authors and/or other copyright owners and it is a condition of accessing publications that users recognise and abide by the legal requirements associated with these rights.

- Users may download and print one copy of any publication from the public portal for the purpose of private study or research.
- You may not further distribute the material or use it for any profit-making activity or commercial gain
- You may freely distribute the URL identifying the publication in the public portal

Read more about Creative commons licenses: <https://creativecommons.org/licenses/>

Take down policy

If you believe that this document breaches copyright please contact us providing details, and we will remove access to the work immediately and investigate your claim.

LUND UNIVERSITY

PO Box 117
221 00 Lund
+46 46-222 00 00

Molecular and morphological studies on non-healing venous leg ulcers

Katarina Lundqvist
Leg Läkare



FACULTY OF MEDICINE
Lund University

2006

© Katarina Lundqvist, 2006

Typeset by
Ilgot Liljedahl

Printed by
print@soc, Lund, 2006

ISBN 91-85559-42-3
ISSN 1652-8220

*This thesis is dedicated in memory of my father,
Sven Nilsson (1921-1975)*

Table of contents

List of publications	7
Aims	8
Introduction	9
Historical aspects	9
Background – chronic ulcers	9
The wound healing process	11
Chronic wound pathogenesis	13
Modes of determining wound status	14
Current therapies	15
Materials and methods	17
Patients, paper I-V	17
Biopsies, paper I-V	17
Wound fluid collection, paper I-V	17
Bacterial strains, paper IV-V	18
Immunohistochemistry, paper I-V	18
SDS-PAGE, paper III, IV, V	18
Immunoblotting, paper III, IV, V	18
HBP-release, paper IV	19
Viable count assay, paper IV	19
Radial diffusion assay, paper V	19
Statistical analyses, paper II and IV	20
Other methods used in this thesis	20
Results and comments (paper I-V)	21
Paper I	21
Paper II	24
Paper III	25
Paper IV	27
Paper V	29
Conclusions and future perspectives	31
Sammanfattning på svenska	33
Acknowledgements	36
References	38

Paper I	43
Paper II	51
Paper III	55
Paper IV	65
Paper V	75

List of publications

- I. Lundqvist K, Schmidtchen A. Immunohistochemical studies on proteoglycan expression in normal skin and chronic ulcers. *Br. J. Dermatol.* 2001; 144: 254-259
- II. Lundqvist K, Schmidtchen A. Cyclin A expression in chronic leg ulcers. *Acta Derm Venereol.* 2006; 86: 61-62
- III. Allhorn M, Lundqvist K, Schmidtchen A, Åkerström B. Heme-scavenging role of α_1 -microglobulin in chronic ulcers. *J. Invest. Dermatol.* 2003; 121: 640-646
- IV. Lundqvist K, Sonesson A, Herwald H, Schmidtchen A. Heparin binding protein is increased in chronic leg ulcer fluid and released from granulocytes by secreted products of *Pseudomonas aeruginosa*. *Thromb. Haemost.* 2004; 92: 281-287
- V. Lundqvist K, Schmidtchen A. Human neutrophil α -defensins in chronic venous leg ulcers. In manuscript.

Published articles are reproduced with permission from the publishers.

Aims

The overall aim of this thesis has been to explore different aspects of the molecular etiology of non-healing venous leg ulcers. Throughout these studies, a particular objective has been to determine which factors contribute to maintaining chronic wounds.

I have focused on four main questions.

- Is it possible to identify molecular and morphological deviations in non-healing venous leg ulcers?
- How can bacteria interfere with the wound healing process?
- Is there a defective cell proliferation at the wound edges of venous leg ulcers?
- Which factors maintain the high proteolysis and the ongoing inflammation in venous leg ulcers?

Introduction

Historical aspects

Throughout history, skin wounds have constituted a threat to human beings. Thus, humans have always had an interest in wound care and the wound healing process. Documentation on these topics dates back to the ancient Egypt civilisation 1500 B.C (Falanga, 2001). The Egyptians' great interest in wound care resulted in documentation of cardinal signs of infection and inflammation and treatment advice for different types of wounds. Wounds were frequently treated through topical administration of honey, grease, carbon and copper with additives of milk, urine, raw meat and wine (Sipos et al. 2004). The Greeks studied wound healing conditions more systematically, and were probably the first to differentiate between non-healing versus acute wounds and document these findings (Toledo-Pereyra 2002). Claudius Galen of Pergamum (130-200 AD), a Greek physician and scientist served as a surgeon to the Roman gladiators. He studied the recovery of injured slaves and discovered that wounds in a continuously moist environment healed faster than those that were allowed to dry out (Toledo-Pereyra 2002). In modern time, Oscar Gilje re-discovered these findings and documented his observations in a dissertation in 1948 (Gilje 1948). However, this knowledge was not converted into medical practice until 1962, when George Winter found an increased epithelialization rate of porcine wounds kept in a moist environment (Winter 1962). One year later, Hinnman and Mailbach confirmed these results in human skin (Hinnman et al. 1963, Falanga 2001). Modern wound care continues to become increasingly advanced and is often specific to certain wound types. Still in many aspects, historical knowledge is rediscovered. Consequently, today's arsenal of wound treatments includes acetic acid, silver, maggot therapy, charcoal, seaweed and collagen in combinations with moist and compression bandages.

Background – chronic ulcers

The integrity of the human body is dependent on a strict function of the skin barrier to prevent dehydration but also to protect against microorganisms and chemical substances.

Undamaged skin is essential to human life. When skin damage occurs a well-orchestrated chain of matrix signals initiate chemokines, cytokines and enzymes, leading to recruitment of white blood cells, and migration of fibroblasts and epithelial cells (Singer & Clark 1999). The human skin is normally colonised by various bacteria and fungi. During evolution the innate and the adaptive immune system have developed different defence mechanisms to prevent microbial invasion. Antimicrobial peptides occur in all living organisms and are fundamental parts of the innate immunity system, which mounts a rapid non-specific defence against a broad spectrum of microbes (Hancock et al. 2000). These peptides are found on the epithelial skin and mucosal surfaces but also in internal organs such as kidneys, lungs and the gut (Hancock et al. 2000). Under normal conditions we live in an ecological balance with the microbial flora. Disturbed microbial balance is seen in diseases like atopic dermatitis (Roll et al. 2004; Guzik et al. 2005) but also in leg ulcers related to venous insufficiency (Jones et al. 2004).

Chronic venous leg ulcers represent a major health problem with an increasing burden on health care providers and long lasting suffering for the affected patients (van Korlaar et al. 2003; Lindholm et al. 1993). The chronic venous leg ulcer is defined as an ulcer distal to the knee, caused mainly by venous dysfunction, which does not heal within six weeks (Nelzén & Bergqvist 1995). The etiology is multifactorial and it is necessary to take into consideration underlying diseases like diabetes, venous and arterial insufficiency, various inflammatory conditions like vasculitis, rheumatological disease, pyoderma gangrenosum, skin tumours and infections. The prevalence of non-healing leg ulcers varies in different published reports (Beebe-Dimmer et al. 2005; Nelzén & Bergqvist 1995; Ragnarson-Tennvall et al. 2004). Recently published epidemiological data from Sweden for non-healing leg ulcers reports a point prevalence of 0.12-0.3 %. (Ragnarson-Tennvall et al. 2004). The prevalence increases dramatically with age. More than 90 % of the patients are over the age of 60 years (Ågren et al. 2000). In recent calculations 38-54 % of all leg ulcers are related to venous insufficiency (Ragnarson-Tennvall et al. 2004). These patients require extensive resources, and ulcer size as well as healing duration are important cost factors. The total direct annual cost of venous leg ulcers in Sweden in 2002 has been estimated to about 73 million euro (Ragnarson-Tennvall et al. 2004). At least 50% of deep venous insufficiencies have a history of deep venous thrombosis (Nelzén & Bergqvist 1995). Although chronic venous leg ulcers are multifactorial they are all characterized by ongoing and unregulated inflammatory condition that always includes bacterial infestation (Ågren et al. 2000). It is hard to establish experimental models for chronic wounds and since this group of patients mainly includes elderly, interfering multiple diseases are common and have to be considered. The time consuming

wound care at the outcome clinic requires considerable human resources and quality of life parameters demonstrate a marked impact on the daily life of patients with leg ulcer disease. (Lindholm et al. 1993).

The wound healing process

Normal wound repair involves an initial inflammation phase characterized by neutrophil infiltration, excessive protease activity followed by macrophage migration and angiogenesis, as well as by keratinocyte and fibroblast proliferation and migration (Singer & Clark 1999). The overlapping processes of inflammation, re-epithelialization, tissue granulation and remodelling are controlled by complex patterns of growth factors, cytokines, proteinases and their inhibitors. These, in concert with matrix adhesion molecules, enable proper cell proliferation and migration but also a well regulated protease activity for degradation of devitalised tissue and wound bed fibrin, which altogether facilitate a complete closure of the wound (Santoro & Gaudino 2005).

The inflammatory phase

At the moment of skin injury, the coagulation cascade forms a temporary barrier by the blood clot, consisting of fibrin and trapped platelets releasing fibrinogen, vaso-active mediators, growth factors like Platelet Derived Growth Factor (PDGF), cytokines and chemo-attractant mediators (Santoro & Gaudino 2005; Singer & Clark 1999). These mediators recruit inflammatory blood cells like neutrophil granulocytes and macrophages (Santoro & Gaudino 2005; Singer & Clark 1999). Polymorphonuclear granulocytes (PMN) enter the wound as early as a few minutes after tissue damage. The recruitment of leukocytes from the circulation is regulated by molecular changes at the surface of endothelial cells of the capillary wall (Ågren et al. 2000). By phagocytosis they “clean up” the debris and bacteria at the wound site. In normal wound healing the PMN are in cell majority the first five days (Ågren et al. 2000). Monocytes, essential for wound healing, enter the wound area 24-48 hours after wounding. Besides having phagocytic functions these cells are also important sources of cytokines and growth factors like PDGF, Tumor Necrosis Factor α (TNF- α), TGF- β and Vascular Endothelial Growth Factor (VEGF), which are important for the initiation of granulation tissue formation (Singer & Clark 1999; Goldman 2004).

Epithelialization

This phase is characterized by cell proliferation and migration of epidermal cells, which is mainly regulated by increased expression of growth factors, metalloproteinases (MMP) and integrins but also stimulation by the “free edge” of the wound margin (Santoro & Gaudino 2005; Singer & Clark 1999). Within 24 hours after injury, keratinocytes and follicular epithelial cells undergo marked phenotypic alteration. Up-regulated cell proliferation behind the migrating leading edge results in a hyperproliferative epithelium (Santoro & Gaudino 2005). Although the epithelialization factors are still not determined in detail, Keratinocyte Growth Factor (KGF), Epidermal Growth Factor (EGF) and Transforming Growth Factor- α (TGF- α) are three participants in the proliferation process (Werner et al. 2003). Integrins are transmembrane cell surface receptors, critical for modulating focal cell contact, binding of matrix proteins and interacting with cytoskeletal structures (Baum & Arpey 2005; Cavani et al. 1993). Dissolution of hemidesmosomal links, cellular retraction of tonofilaments and desmosomes together with formation of cytoplasmic actin filaments, promote cell migration in lateral movement towards the skin defect (Singer & Clark 1999). Localized proteolysis at the wound site is promoted by MMP-1, which is consistently expressed by migrating keratinocytes following injury, driven by keratinocyte contact with type-1 collagen (Ravanti et al. 2000). This results in matrix degradation, which is critical in the process of facilitating keratinocyte migration and matrix remodelling (Ravanti et al. 2000).

Granulation phase

Granulation tissue formation commences 3-4 days after injury and is characterized by fibroblast phenotypic alterations and migration into the wound site, followed by formation of new collagen fibres and ground substance as well as of sprouting angiogenesis. PMNs are gradually replaced by macrophages, which release various stimulating growth factors, which mediate fibroblast proliferation and angiogenesis (Singer & Clark 1999). Fibroblasts, stimulated by PDGF and TGF- β 1 are important for the production of extracellular matrix major components (Santoro & Gaudino 2005). Initially, a provisional matrix is formed consisting of molecules as fibrin, fibronectin, hyaluronic acid, collagen, proteoglycans and elastin (Singer & Clark 1999). Simultaneous proteolytic processes are required in this phase (Ravanti et al. 2000). Low oxygen tension and various fibroblast growth factors promote angiogenesis whereas other growth factors, such as VEGF, are critical in the neovascularisation of the granulation tissue (Singer & Clark 1999). Furthermore, proteoglycans like syndecans also promote angiogenesis (Gallo 1994).

Remodelling phase

Deposition and remodelling of the extracellular matrix proteins are dynamic processes including synthesis and catabolism long after the functional skin barrier is complete. Macromolecules such as fibronectin, proteoglycans, hyaluronic acid and collagen are important components. Under the influence of TGF- β and other growth factors, fibroblasts synthesize a new collagen-rich matrix, forming larger collagen bundles and new intermolecular cross-links to increase connective tissue tensile strength (Singer & Clark 1999). Myofibroblasts play the main part in wound contraction, resulting in decreased wound size (Amadeu 2003). Initially produced collagen type III fibers are replaced by collagen type I and gradually, significant programmed cell death of fibroblasts occur (Falanga 2001)

Chronic wound pathogenesis

In contrast to acute wounds, chronic venous ulcers fail to follow this timely pattern of events and persist in a chronic inflammatory stage involving high protease levels, bacterial influence, endothelial cell leakage and high oxidative stress (Ågren et al. 2000).

It is well known that the main underlying etiology for venous leg ulcer is venous hypertension in the lower extremities, due to incompetent valves in the venous system, causing disturbed microcirculation in the tissue (Ågren et al. 2000). This leads to increased pressure in the capillary bed with a subsequent trapping of PMN and a vascular leakage of fibrinogen and other macromolecules (Phillips & Dover 1991; Ågren et al. 2000). The cell population of the inflammatory infiltrate in the wound bed is dominated by PMN and macrophages. Excessive proteolysis in the wound area has been proposed as one of the mechanisms leading to defective wound repair (Ågren et al. 2000). Although, there are several other overlapping hypotheses for impaired wound healing in venous insufficiency.

The “trap hypothesis”, focuses on leakage of macromolecules like albumin and α_2 -macroglobulin. These molecules bind growth factors and cytokines, which make them unavailable for the repair process (Falanga & Eaglestein 1993; Higley et al. 1995).

The “fibrinogen leakage hypothesis”, suggests that extravasated fibrinogen is polymerised to fibrin complexes, which form fibrin cuffs around the capillary wall. The fibrin cuffs are proposed to cause impaired oxygen diffusion and trapping of growth factors, which make them incapable to take part in the wound repair process (Van de Scheur & Falanga 1997). Fibrin cuffs have been demonstrated in lipodermatoscle-

rotic tissue, which is commonly seen below the knee level in patients with venous insufficiency (Falanga et al. 1987; Falanga et al. 1992).

The “venous hypertension theory” proposes the development of venous leg ulcers caused by endothelial activation and damage by adherence of inflammatory cells to the vessel wall, leading to microcirculation ischemia as well as extravasation of erythrocytes and white blood cells (Coleridge-Smith 1988; Saharay 1998).

The “oxidative stress theory” is based on dermal iron deposition, which is derived from extravasated erythrocytes. The typical hyperpigmentation in the surrounding wound contains higher heme levels, and the corresponding iron deposition generates free radicals via the Fenton reaction, maintaining oxidative stress due to toxic oxygen metabolites (Ågren et al. 2000). The activated white blood cells release inflammatory mediators, which increase the capillary permeability that leads to extravasation of blood cells and formation of oedema in the dermis (Scott et al. 1991).

The “bacterial burden theory” proposes that the presence of microorganisms maintains the inflammatory response with constant and high release of chemotactic factors, recruiting additional inflammatory cells, which preserve high proteolytic activity and all together these actions are suggested to result in a self-amplifying detrimental condition (Bowler 2002; Mertz & Ovington 1993; Robson et al. 1990).

Obviously, there are still a number of additional unknown etiological factors, all of which are possible factors, maintaining sustained chronic wounds. Modulation of the inflammatory response is therefore a potential target for therapeutic intervention in order to transfer chronic wounds into the healing phase.

Modes of determining wound status

To establish correct underlying etiology for leg ulcer, medical history of previous wound and healing duration, deep vein thrombosis or leg trauma, varicose vein diseases and oedema tendency of the lower extremities are important in order to confirm the diagnosis. A general physical examination including ankle/brachial index (ABI) is required. The venous ulcer location is in the typical case found at the gaiter area. The ulcer appearance usually shows various sizes with irregular margins, and the wound bed is often covered with granulation and fibrinous material. The wound depth is usually moderate without any visible tendons. The surrounding ulcer area generally shows skin induration, due to lipodermatosclerosis and occasionally eczematous changes (Valencia et al. 2001). Hemosiderin deposition in the dermis gives the characteristic lower leg hyperpigmentation (Valencia et al. 2001). Atrophic blanche with its typical whitish network with deep red punctuated telangiectasias is sometimes seen due to vascular disturbances, and is often associated with therapy re-

sistant severe pain (Valencia et al. 2001). To determine venous insufficiency either a handheld Doppler is used, or if a detailed examination is preferable, a colour duplex examination is executed to evaluate venous valve function in the venous system of the lower extremities. The systolic ankle index is always determined. Other conditions like local and general infection, immunological disease or diabetes are determined by routine physical examination and laboratory blood tests.

Current therapies

Chronic venous leg ulcers are treated with regular routine therapies. The normal wound care includes mechanical and sometimes enzymatic debridement. Variants of moist, occlusive wound dressing are standard. In case of inflammation and cellulitis with bacterial infection, active antiseptic wound dressings containing acetic acid, iodine or silver are applied. If needed, local and/or per oral pharmacological treatment, antibiotics, antiinflammatory and analgesic drugs are added. Compression multi-layer bandage is always applied in treatment of venous leg ulcers, having an ABI >0.8. Anti oedema treatment with intermittent pneumatic compression sometimes combined with additional diuretic therapy is effective if lower leg oedema is massive. When healing response is poor, several additional therapies are available. Vacuum Assisted Closure therapy (VAC) was recently introduced for wound healing promotion. The equipment is applied directly to the wound surface. This brings negative pressure into the wound bed and it has been reported by others to stimulate tissue formation and promote angiogenesis (Loree et al. 2004). Surgical intervention using skin grafting (pinch graft) is frequently used. Furthermore, patients with diagnostic superficial venous insufficiency should undergo vascular examination and assessment for possible surgery or other related vascular intervention therapy.

Pharmacological treatment with pentoxifylline is well known to improve wound healing in chronic leg ulcers. The drug is interesting because of its multifunctional effect. High doses of the drug have fibrinolytic activities (Falanga et al. 1999). It improves the microcirculation by its ability to increase the deformability of erythrocytes and white blood cells and reduces the adhesion properties of the capillary endothelium. The drug also prevents thrombocyte and erythrocyte aggregation, due to its anti-thrombotic effect (Falanga et al. 1999). Recent reports state that the drug exerts immunomodulatory and antiinflammatory activity due to inhibition of the production of proinflammatory cytokines (Fantin et al. 2006).

Materials and methods

Patients, paper I-V

The research project was approved by the Ethics committee, Lund University Hospital. Informed consent was obtained from all patients. Patients were recruited from the Department of Dermatology, Lund University Hospital. Patients with chronic venous ulcers (duration > 3 months) were included in these studies. The age ranged from 72 to 86 years with a mean age of 80.2 years. In the wound fluid study, the control group consisted patients from the surgical Department at Landskrona Hospital (9 females, mean age 65 years).

Biopsies, paper I-V

4 mm biopsies were taken from the edge of the ulcer and from a control area on the thigh. The biopsies were fixed overnight in 4% paraformaldehyde, dehydrated sequentially with ethanol, and subsequently embedded in paraffin. Tissue sections (5 μ m) were cut in a microtome, mounted on slides, and used for the immunostaining procedures.

Wound fluid collection, paper I-V

Tegaderm or OpSite dressings were applied on the wound and wound fluid was collected by gentle aspiration underneath the film after 2 hours (Grinnell et al. 1996), centrifuged at 10000 rpm in an Eppendorf centrifuge, aliquoted and stored at -20° C until further use.

The control group included patients after surgery. Wound fluid was obtained from surgical drainages following mastectomy. The fluid was collected for 24 hours, 24 to 48 hours after surgery. The wound fluid was thereafter immediately transported on ice and centrifuged for 10 minutes at 10000 rpm. The supernatant was carefully removed and thereafter stored in -20° C.

Bacterial strains, paper IV-V

Bacterial cultures were obtained from patients with venous leg ulcers as previously described (Schmidtchen et al. 2001). In paper IV, six strains of *S. aureus* were derived from patients with atopic dermatitis (kindly provided by Dr. Andreas Sonesson).

Immunohistochemistry, paper I-V

Sections were deparaffinized by routine procedures, and endogenous peroxidase activity was blocked with 3 % H₂O₂ in methanol for 10 min. After rinsing in distilled water, followed by PBS, sections were permeabilized with 0.05% Tween 20 in PBS. To unmask epitopes we used heat-induced epitope retrieval. Slides were transferred to 0.01M sodium citrate buffer, pH 6.0, briefly boiled in a microwave oven (at 900 W) and then for 6 min (at 90 W). Thereafter sections were rinsed in PBS. After pre-incubation with normal goat serum (1%) for 30 min at room temperature, overnight incubation at 4° C was performed with specific primary antibodies, each one specified in the different papers. Antibody detection was performed with the standard avidin-biotin-complex (ABC) detection system using DAB as the chromogenic substrate. Sections were counterstained with Mayer's Hemalum mounted with Pertex and examined and photographed using a Olympus BHS photomicrographic system.

Sodium dodecyl sulfate-polyacrylamide gel electrophoresis (SDS-PAGE), paper III, IV, V

For protein detection and degradation analysis, 10 %, 12%, 16.5% or 3–12 % SDS-PAGE was used. For HBP degradation analysis in paper IV the protein was pre-incubated with purified *P. aeruginosa* elastase, supernatants from *E. faecalis* and *P. mirabilis* strains or human neutrophil elastase. For details see paper III, IV, V. After separation, the gel was stained with Coomassie Brilliant blue and then dried.

Immunoblotting, paper III, IV, V

The proteins were transferred onto a nitrocellulose membrane and immunoprinting of the transferred proteins was done, as previously described (Towbin et al. 1979; Schmidtchen 1999) followed by incubation with polyclonal antibodies against either HBP, α -defensin, or α_1 -microglobulin. Bound antibodies were detected using a peroxidase-conjugated secondary antibody.

HBP-release, paper IV

Bacteria grown in Todd-Hewitt medium over night were centrifuged at 3000 rpm for 10 min and the supernatants were incubated at 37° C for 30 min with blood from healthy volunteers (diluted in PBS). Unconditioned Todd-Hewitt medium was used as a control. For determination of total HBP concentration in neutrophil granulocytes, cells were completely lysed by addition of 0.1 % Triton X-100 to the blood solution. This was considered as 100% release. Thereafter the samples were centrifuged and the supernatant was removed. The HBP concentration was determined by a sandwich ELISA (Tapper et al. 2002).

Viable count assay, paper IV

Bacterial strains, cultured over night, were grown to mid-log phase in TH-medium and then washed and diluted in 10mM Tris-HCl, pH 7.5 containing 5 mM glucose. Either human serum or acute or chronic wound fluids were added to a final concentration of 20 %. 50 µl of bacterial suspension, 2×10^6 CFU/ml was incubated at 37° C for 4 hours with different HBP concentrations (0, 2, 10, 20, 40, 100 µg/ml). Quantification of bactericidal activity was achieved by serial dilutions of the incubation mixture, followed by plating on TH agar and incubation overnight at 37°C. Thereafter the bacterial colonies were counted (Andersson et al. 2004).

Radial diffusion assay, paper V

The RDA-assay is previously described (Lehrer et al. 1991; Andersson et al. 2004). *P. aeruginosa* and *E. coli* bacteria were incubated over night at 37° C in full-strength (3% w/v) trypticase soy broth (TBS). 200 µl of each bacterial strain was inoculated in 10 ml fresh TBS and grown to mid-log phase for an additional 3 h at 37°C. Thereafter the bacterial solution was centrifuged and washed, followed by re-suspension in cold 10 ml 10 mM Tris-buffer, pH 7,4. After optical density had been measured at 620 nm, the bacterial solution was centrifuged and resuspended to a concentration of 2×10^9 CFU/ml. 2.2 µl of each bacterial solution was mixed with 5 ml, undergel (at 50° C) containing 1.5 mg TBS, 250 mg Low electroendosmosis-type agarose (Low-EEO) (Sigma-Aldrich, St Louis, Mo) and 1 µl Tween 20 in 10mM Tris and the solution was poured into a 90 mm petridish. 4 mm wells were punched out in the solidified gel and 6 µl of each peptide were added into the wells followed by incubation for 3 h at 37° C. Thereafter an overlay agar containing 6 % TBS and 0.5% Low-

EEO was poured over the undergel. The dishes were incubated overnight at 37°C. After staining the gels with Coomassie brilliant blue, the clear inhibition zone was measured with a metric scale.

Statistical analyses, paper II and IV

The Wilcoxon test was used for evaluation of HBP release in paper IV. For evaluation of Cyclin A positive cell counts in paper II, the Mann-Whitney rank sum test was performed.

Other methods used in this thesis

- Affinity chromatography, previously described (Allhorn et al 2002). Paper III.
- Biochemical methods for quantification and determination of α_1 -microglobulin, porphyrins and iron in wound fluid and plasma (Åkerström 1985; Falk 1964). Paper III.
- ELISA methods for quantification of concentration α -defensin and HBP levels in wound fluid. The methods are previously described (Tapper et al. 2002; Faurschou et al. 2002). Paper IV and V.

Results and comments (paper I-V)

Paper I

Lundqvist K, Schmidtchen A. Immunohistochemical studies on proteoglycan expression in normal skin and chronic ulcers. *Br. J. Dermatol.* 2001; 144: 254-259

The investigation in this paper was focused on proteoglycans (PG) in non-healing venous leg ulcers. The purpose was to survey the morphological patterns of different PGs in non-healing wounds. PGs represent a large family of complex molecules, which constitute a major part of extracellular matrices. They are integrated in membrane structures and are also found in cartilage and other fibrous supporting tissue (Bernfield et al. 1992; Salmivirta et al. 1995; Iozzo et al. 1996). The complex molecules consist of a core protein, covalently linked to different glycosaminoglycans (GAG) such as chondroitin/dermatan sulphate, keratan sulphate, heparan sulphate or heparin. The molecules are interesting since they are multivalent and participate in many biological processes such as coagulation, control of cell adhesion, cell growth and organization of extracellular matrix. They have specific functions during cellular development processes but also in different pathological conditions like cancer and inflammation (Taylor & Gallo 2006; Fears 2006; Perrimon et al. 2000). PGs have important regulatory functions in wound healing since the molecules bind growth factors, promote angiogenesis (Gallo 1994) and are involved in regulation of proliferation, proteolysis and matrix adhesion (Elenius et al. 1991; Oksala et al. 1995; Andriessen et al. 1997).

The syndecan family are a group of membrane integrated PGs comprising at least four different gene products. They are implicated in activation and binding of growth factors and also have a protease protecting function by binding elastase and cathepsin, resulting in protection from anti-proteases (Essner et al. 2005; Bernfield et al. 1992; Salmivirta et al. 1995; Kainulainen et al. 1998). Furthermore, syndecan is critical in the wound healing process since it promotes angiogenesis (Gallo 1994). It is proposed that syndecan-4 is essential for adhesion formation via certain integrins, and for cell proliferation and migration in response to growth factors (Santoro & Gaudino 2005). It has recently been reported that syndecan-2 promotes cellular interaction and adhesion as well as involvement in the angiogenesis, serving as a co-

receptor for VEGF, all important factors in cancer cell invasion (Beauvaris & Rapraeger 2004; Essner et al. 2006).

CD-44 a membrane-associated macromolecule is abundant in epithelial cells and binds both hyaluronate and fibronectin (Turley 1992; Lesley et al. 1993). It has been reported that CD44 may be involved in fibroblast migration in wound healing and interestingly, expression of CD44 has been found to be increased in hypertrophic scar fibroblasts (Messadi & Bertolami 1993). Glypican binds antithrombin and acts as an anticoagulant at the endothelial surface (Mertens et al. 1992; David et al. 1993). The basal membrane associated PG, perlecan acts a reservoir for different growth factors (Ruoslahti et al. 1991) and recent reports have proposed that perlecan have regulatory properties in the angiogenesis *in vivo* (Zhou et al. 2004).

Considering the above, PGs are intimately involved in the wound healing process. Therefore, the purpose of this paper was to study the morphological pattern of human skin PGs in chronic wound edges and in normal skin.

Six PGs were studied, and all were identified in the wound tissue by immunohistochemistry. As mentioned above, five of these are cell associated; syndecan-1, syndecan-2, syndecan-4, CD-44 and glypican, whereas one PG, perlecan is associated with the basal membrane. The morphological studies showed that syndecan-1 was detected in the pericellular regions of the keratinocytes in the epidermis. The signal seemed to fade out towards the wound edge. Endothelial cells did not express any signal for this PG. This may indicate poor angiogenesis in this area since other reports have indicated that growing capillaries express syndecan-1 in murine wound models (Elenius et al. 1991; Gallo 1994). Syndecan-2 showed intracellular staining in keratinocytes, fibroblasts, glandular cells and endothelial cells in normal skin. The basal cells yielded weaker signals, both in chronic wounds and in normal skin. The chronic wound margin at the protruding basal layer lacked syndecan-2 expression. Moreover, the endothelial staining was weaker at the wound margin compared to normal skin. This pattern may be the result of impaired angiogenesis in the chronic wound tissue but could also be related to altered cell-to-cell communication in the basal layer protruding keratinocytes (Essner et al. 2005). Syndecan-4 and glypican had similar staining pattern and were expressed in a pericellular fashion but also intracellularly in the epidermal keratinocytes in normal skin. Fibroblasts and endothelial cells were lightly stained. In chronic wounds, the signal for syndecan-4 was predominantly expressed intracellularly in the epidermal basal layer keratinocytes, fading out towards the leading edge. Furthermore, the endothelial cells showed mostly intracellular signals and the expression appeared to fade towards the wound outer edge. Hypothetically, this pattern may be related to the PGs role as receptors for various extracellular

ligands such as growth factors. Another alternative explanation of this pattern could be the fact that syndecan-4 is involved in cell adhesion (Woods & Couchman 1994). For glypican, the wound edge keratinocyte staining was mostly intracellular and the basal pericellular pattern seemed to fade out towards the wound edge in chronic wound tissue. Perlecan was detected at the basal membrane (BM) at the dermo-epidermal junction and in the endothelial cells in the dermis, both in normal skin and chronic wounds. Other studies have reported that perlecan is absent the first week in normal wound healing (Andriessen 1997; Oksala 1995). These findings may reflect the static nature of the edges of chronic wounds, enabling the synthesis and incorporation of BM components such as perlecan into the BM. CD44 was identified in the epidermis but also in the fibroblasts and the endothelial cells both in the chronic wound edges as well as in normal skin.

In conclusion, this paper demonstrated specific and different distribution patterns of human skin PGs, in normal skin and in chronic wound tissues. Whether these patterns are specific for chronic ulcers or apply to wound healing in general remains to be investigated.

Paper II

Lundqvist K, Schmidtchen A. Cyclin A expression in chronic leg ulcers. *Acta Derm Venereol.* 2006; 86: 61-62

Proliferation of the epidermis is fundamental for proper wound healing. Cyclins are intracellular subunits of regulatory proteins, essential for the passage through specific stages of the mitotic cell cycle. They have been the objects of interest in a number of previous cell-proliferation studies (Inohara et al. 1994; Gniadecki 1998; Desdouets et al. 1995; Vade Berg et al. 2003). Other proliferation markers like PCNA, Ki67, cytokeratin 16 and 17, have been studied by others and reported to be upregulated in chronic venous leg ulcers, indicating that cell proliferation is not a limiting factor for impaired wound healing (Andriessen et al. 1995; Galkowska et al. 2003). Different cyclins are associated with a certain stage of the mitotic cycle (Johnson & Walker 1999). Cyclin A regulate the S-phase of DNA synthesis. Over expression of cyclins has been reported in association with increased cellproliferation in diseases like psoriasis as well as in tumour formation (Yam et al. 2002). Since epidermal proliferation is essential for wound healing, the purpose of this study was to assess whether cyclin A expression could be utilized as a novel marker for epidermal proliferation in chronic leg ulcers.

The immunohistochemistry results showed that about 5% of the cells in the epidermal basal cell layer of normal skin stained positive for Cyclin A. In chronic as well as in acute wounds, 25 % of the epidermal basal cells had positive Cyclin A signals. Thus, there was a fivefold increased expression pattern for Cyclin A in both acute and chronic wounds when compared to normal skin. There was no significant difference in the staining pattern between chronic and acute wounds. In the immediate leading edge in both the chronic and acute wounds, no Cyclin A-positive cells were detected. This indicates that these cells are non-proliferating and may originate from basal stem cells beneath the leading edge.

In conclusion, our data indicate that the cellular proliferation in the epidermal basal cell layers of chronic venous ulcers is not impaired when compared to acute healing wounds. These findings correspond to others (Andriessen et al. 1995; Galkowska et al. 2003) and suggest that defective cell proliferation is not a major pathogenetic factor for impaired wound healing of venous ulcers.

Paper III

Allhorn M, **Lundqvist K**, Schmidtchen A, Åkerström B. Heme-scavenging role of α_1 -microglobulin in chronic ulcers. *J Invest Dermatol.* 2003; 121; 640-646

This paper focused on inflammation and oxidative stress as consequences of deposition of free iron and heme in dermal tissues of chronic venous leg ulcers. As previously mentioned, non-healing chronic leg ulcers are characterized by an ongoing and unregulated tissue inflammation (Ågren et al. 2000). Increase of intravasal venous blood pressure and backflow due to incomplete valves in the deep and/or superficial veins of the lower extremities results in skin damage and ulceration (Nicolaidis et al. 1993). Still, the pathogenesis is not clearly understood and there are many proposed pathogenetic mechanisms involving stasis of the microcirculation, white blood cell trapping, free radical damage and growth factor blockade (Falanga & Eaglestein 1993; Higley et al. 1995, see also Introduction in this thesis). Deposition of heme and free iron into the extracellular matrix structures is due to endothelial dysfunction and leakage of erythrocytes. The free iron or complex bound iron (as heme) in dermal tissue has been implicated as an important pro-inflammatory factor (Ackerman et al. 1988; Wagener et al. 2001; Wenk et al. 2001). The oxidized ferric (Fe^{3+}) form of heme and free iron are strong oxidative agents, which can generate oxygen-derived free radicals by the Fenton reaction (Halliwell 1989; Gutteridge 1986). Increases of free radicals can lead to cell destruction and tissue damage by oxidative stress and have been proposed to participate in the pathogenesis of chronic ulcers (Ågren et al 2000).

The liver is the main site of synthesis of a 26 kDa glycoprotein, α_1 -microglobulin (α_1 -m), which belongs to the lipocalin superfamily (Daveau et al. 1998; Åkerström et al. 1990). Approximately 50 % of α_1 -m are complex bound to IgA (Grubb et al. 1986). α_1 -m is found in various tissues, both intra- and extravasal, although its function is still not completely elucidated (Berggård et al. 1998). A recent investigation has indicated that α_1 -m has heme-binding properties and may be involved in heme-metabolism in tissues (Allhorn et al. 2002). Haemoglobin induces processing of α_1 -m to a cleaved form, lacking a C-terminal tetrapeptide, so called truncated α_1 -m ($t\text{-}\alpha_1\text{-m}$) (Allhorn et al. 2002). The active form, $t\text{-}\alpha_1\text{-m}$, has a tissue-protecting role against heme-induced oxidative stress due to its heme-binding and heme-degrading properties (Allhorn et al. 2002).

In venous insufficiency the characteristic hyperpigmentation of the lower leg is a well-known sign, reflecting among others, tissue deposition of heme and iron. This is a frequent clinical finding due to long standing inflammation and increased venous pressure. Thus, non-healing venous leg ulcers represent an interesting model for studying the relation between chronic inflammation, oxidative stress and the interactions with α_1 -m and heme.

Wound fluid from twelve patients suffering from chronic venous leg ulcer was analysed. Three variants of α_1 -m in wound fluid were identified: free α_1 -m, t- α_1 -m and complex Ig-A bound α_1 -m. Analysed plasma from the same patients showed no detectable t- α_1 -m. Furthermore, concentration of heme as protoporphyrin IX, and free iron were measured in wound fluid from five patients. Heme was found both in plasma and in wound fluid from patients with venous leg ulcers. In addition, both complex bound IgA- α_1 -m and free α_1 -m were exogenously added to chronic wound fluid. The results of this analysis demonstrated cleavage of α_1 -m to the truncated, active form of α_1 -m, but also processing of IgA-bound α_1 -m. These findings propose that mobilisation of activated, heme-binding and heme-degrading α_1 -m from an IgA- α_1 -m complex may act as a reservoir from which activated t- α_1 -m is released. However, the identity of the cleavage factor in the wound fluid is not yet determined. Additionally, this paper in concert with other studies (Wenk et al. 2001; Blomgren et al. 2001) report presence of heme and iron in chronic wound fluid. It is therefore tempting to speculate that the processing of α_1 -m in chronic leg ulcer is induced by hemoglobin or hemoglobin variants.

The morphological distribution of α_1 -m in chronic wound tissue was investigated by immunohistochemistry. Heme and iron deposition was detected by tissue staining using Fouchet technique and Perls' Prussian blue staining respectively. Tissue sections from acute wound and normal skin were used as controls. The result showed that tissue deposition of heme and iron are accentuated in chronic ulcer tissues, in contrast to acute wounds and normal skin. As expected, α_1 -m was ubiquitously present both in normal skin and chronic ulcers.

In summary, the co-localisation of α_1 -m, heme and iron in chronic wound tissues together with heme induced α_1 -m cleavage and activation and the documented heme-binding and heme-degradation properties of α_1 -m, support the hypothesis that α_1 -m constitute a novel defence mechanism against high heme levels and heme-induced oxidative stress in chronic venous leg ulcers.

Paper IV

Lundqvist K, Sonesson A, Herwald H, Schmidtchen A. Heparin binding protein is increased in chronic leg ulcer fluid and released from granulocytes by secreted products of *Pseudomonas aeruginosa*. *Thromb. Haemost.* 2004; 92: 281-287

Heparin binding protein (HBP), also known as CAP37/azurocidin, belongs to the family of serine proteases, which are stored in PMN granules (Pereira 1995). The protein has multifunctional properties and acts as an interesting mediator involved in host response as well as in initiation of vascular leakage (Heinzlemann et al. 1999; Gautam et al. 2001; Herwald et al. 2004). Furthermore, the protein has antimicrobial effects (Gabay et al. 1989).

Considering these multiple roles of HBP, this paper focused on its potential role in venous ulcers. It is well known that chronic wounds are colonized by high bacterial loads such as *P. aeruginosa*, *S. aureus*, *E. faecalis* and *P. mirabilis* (Hansson et al. 1995). These ulcers are also characterized by chronic inflammation, leading to endothelial dysfunction with leakage of erythrocytes and leukocytes (Ågren et al. 2000). The pathophysiology of the endothelial dysfunction is not clearly understood. In order to address this, we analysed HBP in wound tissues and in wound fluid from venous ulcers and acute wounds as well as its release in response to bacteria. The concentrations of HBP in wound fluid from 12 patients with chronic venous leg ulcer as well as in a control group (n=9) were determined by ELISA. The HBP levels in the chronic ulcer fluids were significantly higher (p=0.0021), in contrast to those detected in the acute wound fluids. In the chronic wound tissues, HBP was identified in the pericellular parts of the inflammatory infiltrate but also in PMNs as well as inside macrophages. These findings correspond to other reports, demonstrating that macrophages internalise neutrophil-derived HBP (Heinzlemann et al. 1998). In nine of these chronic wound patients bacterial swabs were sampled, identifying bacterial growth of *S. aureus*, *P. aeruginosa*, *E. faecalis*, and *P. mirabilis*. There was no clear correlation between type of bacterial isolate and the concentration of HBP in the individual patients. Intact HBP in chronic wound fluid from patients colonised with *P. aeruginosa* was identified using SDS-PAGE and immunoblotting, indicating that HBP is stable in highly proteolytic environments. A commonly found bacterium in chronic venous leg ulcers, the Gram-negative *P. aeruginosa* (Hansson et al. 1995; Schmidtchen et al. 2001; Schmidtchen et al. 2003), was found to induce HBP release from PMNs. Furthermore, HBP did not exert any antimicrobial effects in presence of wound fluid.

Thus, the results indicate that the HBP, released in response to common bacteria such as *P. aeruginosa*, is not antimicrobial *in vivo*, but may act as a mediator for endothelial activation and vascular leakage, leading to erythema and oedema, significant clinical “hall-marks” of venous ulcerations.

Paper V

Lundqvist K, Schmidtchen A. Human neutrophil α -defensins in chronic venous leg ulcers. In manuscript.

α -defensins represent a group of small and evolutionally conserved, cationic, antimicrobial peptides stored in the azurophilic granules of PMNs (Lehrer & Ganz 2002). They have a multifunctional role in the innate host defence since they not only protect against microbial invasion, but also exert chemotactic effects and thus participate in inflammation (Ganz 1985; Ganz & Lehrer 1998; Boman 2000; Harder & Schröder 2005; Yang 2004). It is believed that α -defensins mainly exert their antimicrobial activity in lysosomal compartments of PMNs, but may also be released upon strong stimulation of PMNs (Yang 2004).

Considering the high influx of white blood cells into the surroundings of venous ulcers (Ågren et al. 2000), as well as bacterial presence, the purpose of this paper was to identify and study the potential role(s) of α -defensins in chronic venous ulcers. Immunohistochemistry was used to identify α -defensin in acute wounds, chronic venous leg ulcer tissues and in normal skin from five patients. As expected, the venous ulcers showed intracellular staining for α -defensins in PMNs, but there were also a pericellular staining around the PMNs. The infiltrate of acute wounds (3-4 days after wounding) was less dense and the staining pattern for α -defensins was predominantly intracellular. There was no detectable staining for α -defensins in normal skin.

To evaluate whether the staining pattern differed between acute and chronic wounds, two randomly chosen 0.09 square-mm dermal areas beneath the wound edge on each slide of chronic and acute wound section were examined. Stained cells, showing intracellular staining only or with additional pericellular staining, were counted in the microscope. As expected, chronic wounds contained significantly higher amount of PMNs per area. However, the ratio of degranulated PMNs in acute and chronic wounds was similar. Furthermore, the concentration of α -defensin in wound fluid was determined by ELISA (Faurischou et al. 2002). The result showed a significantly higher concentration of α -defensin in chronic wound fluid in contrast to acute wound fluid. This could be related to the increased levels of PMNs in chronic wound tissues.

Moreover, the antibacterial activity of this peptide was explored. Radial diffusion assay was performed (Lehrer et al. 1991) using *E. coli* and *P. aeruginosa* isolates from chronic wounds. The antibacterial effects of 50 and 100 μ M of α -defensin were examined in presence of added wound fluid. The antimicrobial peptide LL-37 was used as a control peptide. This peptide is strongly expressed in normal healing skin but is

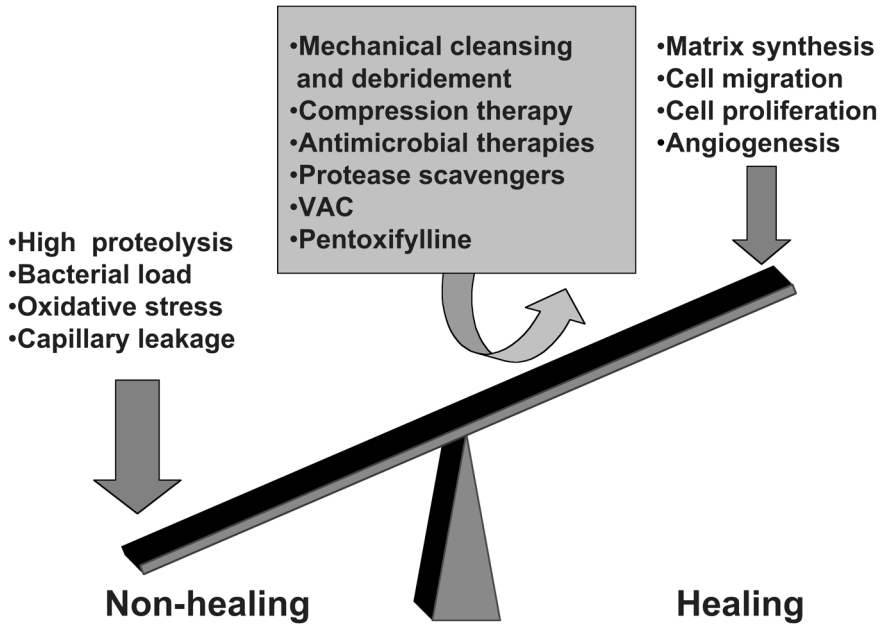
not expressed in chronic wound tissues (Heilborn et al. 2003). The results showed that addition of chronic wound fluid significantly inhibited the antimicrobial effect of α -defensin but not the activity of the peptide LL-37.

Taken together, the findings indicate a significant extracellular release of α -defensins in venous ulcers. Apparently, like HBP, α -defensins have no antimicrobial capacity in wound fluids *in vivo*, as suggested by the RDA experiment mentioned above. However, considering the chemotactic roles of α -defensins, a high and uncontrolled release of these molecules could attract PMNs and other inflammatory cells to chronic ulcer areas, thus contributing to the unregulated inflammation noted in this disease.

Conclusions and future perspectives

The main findings in this thesis are the identification of several molecules in venous ulcers and in acute wounds, which are involved in regulation of endothelial function (HBP), chemotaxis (α -defensins), oxidative stress (α_1 -microglobulin, heme, and iron), and cell proliferation (cyclin A and proteoglycans). The venous ulcers contained significantly increased levels of the chemotactic peptide α -defensin, as well as HBP, a factor known to induce capillary leakage. Secreted products of *P. aeruginosa*, a bacterium often found in chronic ulcers, were found to induce release of HBP from human neutrophils. Taken together, the data suggests a possible link between bacterial presence, neutrophil activation and HBP-release in venous ulcers. These results may help to explain the clinical observation of classic inflammatory signs such as high exudation, swelling, and erythema often accompanied by *P. aeruginosa* infected wounds. Thus, high HBP and α -defensin levels, promoting capillary leakage and chemotaxis, respectively, in concert with heme-mediated oxidative stress, may constitute a “vicious loop”, which underlies the high inflammation noted in non-healing venous ulcers. Interestingly, our data, in concert with previous studies by others, does not indicate that there is a defective cell proliferation in the wound edges of venous ulcers. These findings provide novel diagnostic markers and reinforce the view that future therapeutic approaches directed at venous ulcers should target inflammatory mechanisms and excessive bacterial influence.

It is well known that the pathogenesis of venous ulcers is multifactorial and the various pieces in the “etiologic puzzle” are numerous. It is interesting to note that many of the currently recommended therapies (but also traditional ones, see Introduction) for venous leg ulcers indeed target these pathological conditions. Basal wound care, including proper irrigation and mechanical debridement of devitalized tissues likely removes the bacterial burden and their biofilms. Antimicrobial treatments, like cleansing with acetic acid (Hansson et al. 1995), cadexomer iodine (Hansson 1998) or silver containing bandages (Percival 2005), are used in order to lower the bacterial burden on critically colonized wounds (see; schematic illustration below, of chronic venous ulcer pathogenesis and therapeutic options).



Thus, interfering with one pathogenetic step in the development of ulcers by targeting bacterial influence should minimize neutrophil activation and lead to less HBP as well as α -defensin release.

Furthermore, proper compression, or sclerotherapy, will improve venous blood flow and the microcirculation, which prevents oedema and hence, minimizes capillary leakage, erythrocyte extravasation, hemosiderin formation, and oxidative stress. Morphological tissue changes such as capillary fibrin cuffs, dermal fibrosis, organized oedema and iron deposition increases by prolonged venous ulcer duration, why prompt medical care should be initiated (Smith 2006). Studies of treatment with Pentoxifylline have reported improved healing rates in venous leg ulcer patients (Falanga et al. 1999). Interestingly, besides well-documented therapeutic effects on the microcirculation, the drug has recently discovered immuno-modulatory and anti-inflammatory actions, which could be of advantage in venous leg ulcer therapy (Fantin et al. 2006).

In a future perspective, therapeutic models with selected drugs or dressings, blocking HBP or α -defensin release or function, are interesting concepts in developing new treatment options. To study levels of biological markers in wound fluids or in tissues before and after new treatments, should be valuable in future clinically oriented wound healing studies.

Sammanfattning på svenska

Den övergripande målsättningen med denna avhandling har varit att undersöka molekylära förändringar i icke läkande venösa bensår. Framförallt har fokus lagts på faktorer som underhåller den ständigt pågående inflammationen i venösa sår. Med tanke på att alla venösa sår alltid koloniserar av olika bakterier, har vi undersökt hur bakterier kan påverka sårhäkning och inflammation. Slutligen har vi studerat huruvida det finns hållpunkter för defekt celldelning i sårkanter från kroniska sår.

I det normala fallet läker uppkomna sårskador. Vid hudskada initieras sårhättningsprocessen som en väl koordinerad kedja av enzymer och cytokiner vilket leder till invandring av vita blodkroppar som rensar upp i sårområdet (inflammationsfasen). Denna fas följs av celltillväxt och invandring av blodkärl och epitelceller (granulations och epitelialiseringfasen).

Vår hud är koloniserad med olika bakterier och svampar. Intakt hud och god sårhäkning, tillsammans med olika antimikrobiella skyddssystem baserade på antikroppar, antimikrobiella peptider och olika vita blodkroppar är förutsättningen för att vi inte skall drabbas av inträngande infektioner.

Ibland drabbas vi dock av icke läkande sår. Cirka 2 % av populationen kommer att någon gång drabbas av kroniska bensår. Behandlingen är resurskrävande och belastar sjukvården med stora kostnader. Den bakomliggande orsaken till icke läkande venösa bensår är multifaktoriell. Utredning av bakomliggande orsaker grundas på den sammantagna informationen om sjukhistoria, kliniskt status, laboratorieutredningar samt fysiologiska undersökningar, t ex mätning av ankelindex och kartläggning av venös insufficiens. Man räknar med att ca hälften av alla bensår är relaterade till venös insufficiens orsakad av defekta venklaffar, ofta till följd av djup ventrombos i benen vilket resulterat i ett patologiskt förhöjt intravenöst tryck. Det höga trycket fortleds vidare till de mindre kärlen i läder huden som leder till ett ökat tryck i de minsta kapillärerna med ödemtendens som följd. Det är känt att när tillståndet blir kroniskt leder detta till permanenta vävnadsförändringar, bland annat fibros av läder huden, tillväxt av kapillärer och kapillärväggsförtjockning genom bildning av så kallade fibrinkuffar runt de minsta kärlen.

Icke läkande venösa sår karaktäriseras av en kontinuerlig inflammationsfas med hög vävnadsnedbrytning i sårområdet till skillnad från akuta, läkande sår där den inflammatoriska fasen är över på 3-5 dagar efter skada. Dessutom är kroniska sår alltid koloniserade av bakterier vilket sammantaget initierar en aktivering av immunförsva-

ret och leder till rekrytering av vita blodkroppar. Dessa celler innehåller olika proteiner, proteinfofragment (peptider), och enzymer som är viktiga för både inflammation och infektionsförsvar. Heparin bindande protein (HBP) och α -defensiner är två exempel på sådana ämnen som lagras i vita blodkroppar. HBP initierar en aktivering av kärlväggens celler vilket bidrar till läckage av vätska och utträde av röda och vita blodkroppar som deponeras i läderhuden. α -defensiner bidrar till rekrytering av ytterligare vita blodkroppar från blodbanan vilket förstärker den inflammatoriska aktiviteten. Höga koncentrationer av HBP och α -defensin identifierades i sårvätska från venösa kroniska sår. Bakterier, framför allt *P. aeruginosa* (som ofta förekommer i kroniska sår), visade sig initiera frisättning av HBP, till skillnad från *S. aureus* som ej hade denna effekt på HBP frisättning. Fyndet kan förklara varför kolonisation med *P. aeruginosa* i kroniska sår vanligtvis är förenad med kliniska tecknen på inflammation, dvs. rodnad, svullnad, värmeökning och smärta.

Röda blodkroppar innehåller stora mängder järn och häm som är bundet till hemoglobin. När kärlen läcker ut röda blodkroppar går dessa i hemolys och järnet kommer att deponeras i läderhuden. Rent kliniskt resulterar denna deposition till den karaktäristiska hyperpigmenteringen på underbenen som ses vid venös insufficiens. Höga halter av häm och järn har uppmätts i kronisk sårvätska. Fritt järn och häm som via en kemisk reaktion reagerar med syre, bildar vävnadsskadande fria radikaler vilket resulterar i oxidativ stress. α_1 -microglobulin är ett protein som förekommer i blod och vävnad vilket både binder och bryter ner häm. Detta protein har påvisats i kronisk sårvätska. Hypotetiskt bör förekomst av α_1 -microglobulin kunna utgöra en skyddsmekanism mot oxidativ stress i sårbädden.

Sammanfattningsvis understryker resultaten i detta arbete betydelsen av hög inflammation (relaterad till hög oxidativ stress, bakteriebörda, höga halter av vita blodkroppar och kemotaktiska substanser) för utvecklingen av kroniska venösa sår. Någon defekt celledelningsförmåga hos keratinocyterna i sårkanten har inte kunnat påvisas. Ett flertal av de molekyler som studerats i detta arbete, som HBP och defensiner, skulle kunna tjäna som ”markörer” för utvecklingen av nya terapier designade för att blockera inflammationen i venösa sår.

Marknaden erbjuder ett stort och växande utbud av aktiva sårförband. Erfarenheter från klinisk verksamhet och från forskning har bidragit till ökad kunskap om vilka behandlingsalternativ som lämpar sig bäst vid olika kliniska sårtilstånd. Trots detta så lyckas vi inte läka alla sår. Hur det molekylärt ter sig i sårbädden före och efter olika typer av antiinflammatoriska eller antibakteriella behandlingar, eller när ett tidigare svårsläkt sår växlar över till klinisk läkningsfas är många gånger ökänt.

Avhandlingen identifierar flera nya mätbara sårmarkörer involverade i inflammationsprocessen, med möjlighet för koncentrationsbestämningar i sårvätska men också med möjlighet till att studera distributionsmönster i sårvävnad. Dessa inkluderar defensiner, HBP, olika proteoglykaner, celldelningsmarkörer, järn, och hem. Dessa ”markörer” kan vara värdefulla vid utvärdering genom analys av sårvätska före och efter behandling. Om kroniska venösa bensår på så sätt kan erbjudas förfinade terapier och individuellt designade behandlingsregimer och därmed snabbare växla över till läkningsfas så kan detta bidra till ett minskat lidande för de drabbade patienterna men också till betydande ekonomiska vinster för sjukvården.

Acknowledgements

Dear Reader,

I wish to express my sincere gratitude to all of those who supported me during these years of work and to everyone who made this thesis become reality, in particular:

Artur Schmidtchen, my tutor and colleague at the Department of Dermatology and Venereology, for introducing me to scientific research and experimental dermatology and letting me share your great knowledge. Your warm and generous support, endless enthusiasm and enormous patience have been invaluable. Thank you so much.

Bertil Persson, head of the clinical department of Dermatology and Venereology for excellent advice and support during ups and downs and for giving me the freedom to combine my clinical practise with medical research.

Ove Bäck, Professor at the Department of Dermatology and Venereology, for encouragement and constructive criticism.

Halvor Möller, Professor emeritus and my mentor, for excellent advice and constructive criticism.

My co-authors Bo Åkerström, Heiko Herwald and Ole Sørensen, for sharing exciting sources of inspiration and knowledge in your fields of speciality.

Maria Allhorn, co-author and friend at BMC for helping me straighten out my question marks in the world of α_1 -microglobulin.

Elisabeth Englund, for excellent advice on evaluation of the immunohistochemistry.

Victoria Rydengård, Emma Nordahl, Mina Davoudi, Andreas Sonesson, and all the other talented co-workers, for all your help and for creating such a positive atmosphere in the lab.

Julie Christiansen, my colleague and office mate at the clinical department of Dermatology and Venereology, for professional advice, all the jolly chats and good laughs at the office. Also thank you for introducing me to and guiding me through the amazing Norwegian landscape (net op!!), and for cosy barbeque evenings with your family.

Lena Jahn, my sister in law and dear friend, for correcting my English in this thesis and for all the long nice talks during summer evenings at Enhörna.

My mother, for your love, great care, support and understanding.

My mother and father-in-law, for great care and support.

The nurses in the ward of the clinical department of Dermatology and Venereology, for excellent assistance and for always being helpful when sampling wound fluid.

Ola Bergendorff, for professional help with chemical issues and tricky computers.

Anna Hultgårdh-Nilsson, for many years of friendship, all our pleasant lunch chats, great visits with your family in Genarp, and for sharing your experience in professional research.

All the participating patients.

Colleagues and staff at BMC, B14, for professional and skilful technical assistance and a helpful and friendly attitude.

Colleagues and staff at the clinical department of Dermatology and Venereology, for great support and encouragement. It's a pleasure to be a part of your team.

And most of all, my dear husband Claes, and our sons Axel and August, for always being there and for invaluable support, patience, love and understanding. I love you!

Thank you all,

Katarína

References

- Ackerman Z, Seidenbaum M, Loewenthal E, Rubinow A. Overload of iron in the skin of patients with varicose ulcers. Possible contributing role of iron accumulation in progression of the disease. *Arch Dermatol* 1988; 124: 1376-8.
- Ågren MS, Eaglstein WH, Ferguson MW, Harding KG, Moore K, Saarialho-Kere UK, Schultz GS. Causes and effects of the chronic inflammation in venous leg ulcers. *Acta Derm Venereol Suppl* (Stockh) 2000; 210: 3-17.
- Åkerström B. Immunological analysis of alpha 1-microglobulin in different mammalian and chicken serum. alpha 1-Microglobulin is 5-8 kilodaltons larger in primates. *J Biol Chem* 1985; 260: 4839-44.
- Åkerström B, Logdberg L. An intriguing member of the lipocalin protein family: alpha 1-microglobulin. *Trends Biochem Sci* 1990; 15: 240-3.
- Allhorn M, Berggård T, Nordberg J, Olsson ML, Åkerström B. Processing of the lipocalin alpha(1)-microglobulin by hemoglobin induces heme-binding and heme-degradation properties. *Blood* 2002; 99: 1894-901.
- Amadeu TP, Coulomb B, Desmouliere A, Costa AM. Cutaneous wound healing: myofibroblastic differentiation and in vitro models. *Int J Low Extrem Wounds* 2003; 2: 60-8.
- Andersson E, Rydengård V, Sonesson A, Mörgelin M, Björck L, Schmidtchen A. Antimicrobial activities of heparin-binding peptides. *Eur J Biochem* 2004; 271: 1219-26.
- Andriessen MP, van Bergen BH, Spruijt KI, Go IH, Schalkwijk J, van de Kerkhof PC. Epidermal proliferation is not impaired in chronic venous ulcers. *Acta Derm Venereol* 1995; 75: 459-62.
- Andriessen MP, van den Born J, Latijnhouwers MA, Bergers M, van de Kerkhof PC, Schalkwijk J. Basal membrane heparan sulphate proteoglycan expression during wound healing in human skin. *J Pathol* 1997; 183: 264-71.
- Baum CL, Arpey CJ. Normal cutaneous wound healing: clinical correlation with cellular and molecular events. *Dermatol Surg* 2005; 31: 674-86; discussion 86.
- Beauvais DM, Rapraeger AC. Syndecans in tumor cell adhesion and signaling. *Reprod Biol Endocrinol* 2004; 2: 3.
- Beebe-Dimmer JL, Pfeifer JR, Engle JS, Schottenfeld D. The epidemiology of chronic venous insufficiency and varicose veins. *Ann Epidemiol* 2005; 15: 175-84.
- Berggård T, Oury TD, Thøgersen IB, Åkerström B, Enghild JJ. Alpha1-microglobulin is found both in blood and in most tissues. *J Histochem Cytochem* 1998; 46: 887-94.
- Bernfield M, Kokenyesi R, Kato M, Hinkes MT, Spring J, Gallo RL, Lose EJ. Biology of the syndecans: a family of transmembrane heparan sulfate proteoglycans. *Annu Rev Cell Biol* 1992; 8: 365-93.
- Blomgren L, Johansson G, Siegbahn A, Bergqvist D. Coagulation and fibrinolysis in chronic venous insufficiency. *Vasa* 2001; 30: 184-7.
- Boman HG. Innate immunity and the normal microflora. *Immunol Rev* 2000; 173: 5-16.
- Bowler PG. Wound pathophysiology, infection and therapeutic options. *Ann Med* 2002; 34: 419-27.
- Cavani A, Zambruno G, Marconi A, Manca V, Marchetti M, Giannetti A. Distinctive integrin expression in the newly forming epidermis during wound healing in humans. *J Invest Dermatol* 1993; 101: 600-4.
- Coleridge Smith PD, Thomas P, Scurr JH, Dormandy JA. Causes of venous ulceration: a new hypothesis. *Br Med J (Clin Res Ed)* 1988; 296: 1726-7.
- Daveau M, Jean L, Soury E, Olivier E, Masson S, Lyoumi S, Chan P, Hiron M, Lebreton JP, Husson A, Jegou S, Vaudry H, Salier JP. Hepatic and extra-hepatic transcription of inter-alpha-inhibitor family genes under normal or acute inflammatory conditions in rat. *Arch Biochem Biophys* 1998; 350: 315-23.

- David G. Integral membrane heparan sulfate proteoglycans. *Faseb J* 1993; 7: 1023-30.
- Desdouets C, Sobczak-Thépot J, Murphy M, Brechot C. Cyclin A: function and expression during cell proliferation. *Prog Cell Cycle Res* 1995; 1: 115-23.
- Elenius K, Vainio S, Laato M, Salmivirta M, Thesleff I, Jalkanen M. Induced expression of syndecan in healing wounds. *J Cell Biol* 1991; 114: 585-95.
- Essner JJ, Chen E, Ekker SC. Syndecan-2. *Int J Biochem Cell Biol* 2006; 38: 152-6.
- Falanga V. *Cutaneous wound healing*: Martin Dunitz Ltd, Taylor and Francis group, 2001: 24-5, 222-6.
- Falanga V, Eaglstein WH. The "trap" hypothesis of venous ulceration. *Lancet* 1993; 341: 1006-8.
- Falanga V, Fujitani RM, Diaz C, Hunter G, Jorizzo J, Lawrence PF, Lee BY, Menzoian JO, Tretbar LL, Holloway GA, Hoballah J, Seabrook GR, McMillan DE, Wolf W. Systemic treatment of venous leg ulcers with high doses of pentoxifylline: efficacy in a randomized, placebo-controlled trial. *Wound Repair Regen* 1999; 7: 208-13.
- Falanga V, Kirsner R, Katz MH, Gould E, Eaglstein WH, McFalls S. Pericapillary fibrin cuffs in venous ulceration. Persistence with treatment and during ulcer healing. *J Dermatol Surg Oncol* 1992; 18: 409-14.
- Falanga V, Moosa HH, Nemeth AJ, Alstadt SP, Eaglstein WH. Dermal pericapillary fibrin in venous disease and venous ulceration. *Arch Dermatol* 1987; 123: 620-3.
- Fantin M, Quintieri L, Kusz E, Kis E, Glavinas H, Floreani M, Padriani R, Duda E, Vizler C. Pentoxifylline and its major oxidative metabolites exhibit different pharmacological properties. *Eur J Pharmacol* 2006; 535: 301-9.
- Faurschou M, Sørensen OE, Johnsen AH, Askaa J, Borregaard N. Defensin-rich granules of human neutrophils: characterization of secretory properties. *Biochim Biophys Acta* 2002; 1591: 29-35.
- Fears CY, Woods A. The role of syndecans in disease and wound healing. *Matrix Biol* 2006.
- Gabay JE, Scott RW, Campanelli D, Griffith J, Wilde C, Marra MN, Seeger M, Nathan CF. Antibiotic proteins of human polymorphonuclear leukocytes. *Proc Natl Acad Sci USA* 1989; 86: 5610-4.
- Galkowska H, Olszewsk WL, Wojewodzka U, Mijal J, Filipiuk E. Expression of apoptosis- and cell cycle-related proteins in epidermis of venous leg and diabetic foot ulcers. *Surgery* 2003; 134: 213-20.
- Gallo RL, Ono M, Povsic T, Page C, Eriksson E, Klagsbrun M, Bernfield M. Syndecans, cell surface heparan sulfate proteoglycans, are induced by a proline-rich antimicrobial peptide from wounds. *Proc Natl Acad Sci USA* 1994; 91: 11035-9.
- Ganz T, Lehrer RI. Antimicrobial peptides of vertebrates. *Curr Opin Immunol* 1998; 10: 41-4.
- Ganz T, Selsted ME, Szklarek D, Harwig SS, Daher K, Bainton DF, Lehrer RI. Defensins. Natural peptide antibiotics of human neutrophils. *J Clin Invest* 1985; 76: 1427-35.
- Gautam N, Olofsson AM, Herwald H, Iversen LF, Lundgren-Åkerlund E, Hedqvist P, Arfors KE, Flodgaard H, Lindbom L. Heparin-binding protein (HBP/CAP37): a missing link in neutrophil-evoked alteration of vascular permeability. *Nat Med* 2001; 7: 1123-7.
- Gilje. Ulcus cruris in venous circulation disturbances; investigations of etiology, pathogenesis and therapy of leg ulcers. *Acta Derm Venereol* 1948; 1948: 454-67.
- Gniadecki R. Regulation of keratinocyte proliferation. *Gen Pharmacol* 1998; 30: 619-22.
- Goldman R. Growth factors and chronic wound healing: past, present, and future. *Adv Skin Wound Care* 2004; 17: 24-35.
- Grinnell F, Zhu M. Fibronectin degradation in chronic wounds depends on the relative levels of elastase, alpha1-proteinase inhibitor, and alpha2-macroglobulin. *J Invest Dermatol* 1996; 106: 335-41.
- Grubb A, Mendez E, Fernandez-Luna JL, Lopez C, Mihaesco E, Vaerman JP. The molecular organization of the protein HC-IgA complex (HC-IgA). *J Biol Chem* 1986; 261: 14313-20.
- Gutteridge JM. Iron promoters of the Fenton reaction and lipid peroxidation can be released from haemoglobin by peroxides. *FEBS Lett* 1986; 201: 291-5.
- Guzik TJ, Bzowska M, Kasprowicz A, Czerniawska-Mysik G, Wojcik K, Szmyd D, Adamek-Guzik T, Pryjma J. Persistent skin colonization with *Staphylococcus aureus* in atopic dermatitis: relationship to clinical and immunological parameters. *Clin Exp Allergy* 2005; 35: 448-55.

- Halliwell B. Free radicals, reactive oxygen species and human disease: a critical evaluation with special reference to atherosclerosis. *Br J Exp Pathol* 1989; 70: 737-57.
- Hancock RE. The role of cationic antimicrobial peptides in innate host defences. *Trends in microbiology* 2000; 8: 402-10.
- Hansson C. The effects of cadexomer iodine paste in the treatment of venous leg ulcers compared with hydrocolloid dressing and paraffin gauze dressing. Cadexomer Iodine Study Group. *Int J Dermatol* 1998; 37: 390-6.
- Hansson C, Faergemann J. The effect of antiseptic solutions on microorganisms in venous leg ulcers. *Acta Derm Venereol* 1995; 75: 31-3.
- Hansson C, Hoborn J, Möller A, Swanbeck G. The microbial flora in venous leg ulcers without clinical signs of infection. Repeated culture using a validated standardised microbiological technique. *Acta Derm Venereol* 1995; 75: 24-30.
- Harder J, Schröder JM. Antimicrobial peptides in human skin. *Chem Immunol Allergy* 2005; 86: 22-41.
- Heilborn JD, Nilsson MF, Kratz G, Weber G, Sørensen O, Borregaard N, Stähle-Bäckdahl M. The cathelicidin anti-microbial peptide LL-37 is involved in re-epithelialization of human skin wounds and is lacking in chronic ulcer epithelium. *J Invest Dermatol* 2003; 120: 379-89.
- Heinzelmann M, Platz A, Flodgaard H, Polk HC, Jr., Miller FN. Endocytosis of heparin-binding protein (CAP37) is essential for the enhancement of lipopolysaccharide-induced TNF-alpha production in human monocytes. *J Immunol* 1999; 162: 4240-5.
- Herwald H, Cramer H, Mörgelin M, Russell W, Sollenberg U, Norrby-Teglund A, Flodgaard H, Lindbom L, Björck L. M protein, a classical bacterial virulence determinant, forms complexes with fibrinogen that induce vascular leakage. *Cell* 2004; 116: 367-79.
- Higley HR, Ksander GA, Gerhardt CO, Falanga V. Extravasation of macromolecules and possible trapping of transforming growth factor-beta in venous ulceration. *Br J Dermatol* 1995; 132: 79-85.
- Hinnman CD MH. Effect of air exposure and occlusion on experimental human skin wounds. *Nature* 1963; 200: 377-8.
- Inohara S. Immunohistochemical detection of cyclin D and cyclin A in human vascular endothelial cells of the skin. *Acta Derm Venereol* 1994; 74: 471-2.
- Iozzo RV, Murdoch AD. Proteoglycans of the extracellular environment: clues from the gene and protein side offer novel perspectives in molecular diversity and function. *Faseb J* 1996; 10: 598-614.
- Johnson DG, Walker CL. Cyclins and cell cycle checkpoints. *Annu Rev Pharmacol Toxicol* 1999; 39: 295-312.
- Jones SG, Edwards R, Thomas DW. Inflammation and wound healing: the role of bacteria in the immuno-regulation of wound healing. *Int J Low Extrem Wounds* 2004; 3: 201-8.
- Kainulainen V, Wang H, Schick C, Bernfield M. Syndecans, heparan sulfate proteoglycans, maintain the proteolytic balance of acute wound fluids. *J Biol Chem* 1998; 273: 11563-9.
- Lehrer RI, Ganz T. Antimicrobial peptides in mammalian and insect host defence. *Curr Opin Immunol* 1999; 11: 23-7.
- Lehrer RI, Ganz T. Defensins of vertebrate animals. *Curr Opin Immunol* 2002; 14: 96-102.
- Lehrer RI, Rosenman M, Harwig SS, Jackson R, Eisenhauer P. Ultrasensitive assays for endogenous antimicrobial polypeptides. *J Immunol Methods* 1991; 137: 167-73.
- Lesley J, Hyman R, Kincade PW. CD44 and its interaction with extracellular matrix. *Adv Immunol* 1993; 54: 271-335.
- Lindholm C, Bjellerup M, Christensen OB, Zederfeldt B. Quality of life in chronic leg ulcer patients. An assessment according to the Nottingham Health Profile. *Acta Derm Venereol* 1993; 73: 440-3.
- Loree S, Dompmartin A, Penven K, Harel D, Leroy D. Is Vacuum Assisted Closure a valid technique for debriding chronic leg ulcers? *J Wound Care* 2004; 13: 249-52.
- McGrath JA, Eady RA. Heparan sulphate proteoglycan and wound healing in skin. *J Pathol* 1997; 183: 251-2.
- Mertens G, Cassiman JJ, Van den Berghe H, Vermylen J, David G. Cell surface heparan sulfate proteoglycans from human vascular endothelial cells. Core protein characterization and antithrombin III binding properties. *J Biol Chem* 1992; 267: 20435-43.

- Mertz PM, Ovington LG. Wound healing microbiology. *Dermatol Clin* 1993; 11: 739-47.
- Messadi DV, Bertolami CN. CD44 and hyaluronan expression in human cutaneous scar fibroblasts. *Am J Pathol* 1993; 142: 1041-9.
- Nelzén O, Bergqvist D. *Treatment of venous leg ulcers*. Workshop, The Swedish Medical Products Agency and the Norwegian Medicines Control Authority 1995; 5: 38-43.
- Nicolaides AN, Hussein MK, Szendro G, Christopoulos D, Vasdekis S, Clarke H. The relation of venous ulceration with ambulatory venous pressure measurements. *J Vasc Surg* 1993; 17: 414-9.
- Oksala O, Salo T, Tammi R, Hakkinen L, Jalkanen M, Inki P, Larjava H. Expression of proteoglycans and hyaluronan during wound healing. *J Histochem Cytochem* 1995; 43: 125-35.
- Percival SL, Bowler PG, Russell D. Bacterial resistance to silver in wound care. *J Hosp Infect* 2005; 60: 1-7.
- Pereira HA. CAP37, a neutrophil-derived multifunctional inflammatory mediator. *J Leukoc Biol* 1995; 57: 805-12.
- Perrimon N, Bernfield M. Specificities of heparan sulphate proteoglycans in developmental processes. *Nature* 2000; 404: 725-8.
- Phillips TJ, Dover JS. Leg ulcers. *J Am Acad Dermatol* 1991; 25: 965-87.
- Ragnarson-Tennvall G, Andersson K, Bjellerup M, Hjelmgren J, Öien R. Venösa bensår kan behandlas både bättre och billigare. *Läkartidningen* 2004; 101: 1506-13.
- Ravanti L, Kahari VM. Matrix metalloproteinases in wound repair (review). *Int J Mol Med* 2000; 6: 391-407.
- Robson MC, Stenberg BD, Hegggers JP. Wound healing alterations caused by infection. *Clin Plast Surg* 1990; 17: 485-92.
- Roll A, Cozzio A, Fischer B, Schmid-Grendelmeier P. Microbial colonization and atopic dermatitis. *Curr Opin Allergy Clin Immunol* 2004; 4: 373-8.
- Ruoslahti E, Yamaguchi Y. Proteoglycans as modulators of growth factor activities. *Cell* 1991; 64: 867-9.
- Russell AD. Introduction of biocides into clinical practice and the impact on antibiotic-resistant bacteria. *Symp Ser Soc Appl Microbiol* 2002: 121S-35S.
- Saharay M, Shields DA, Georgiannos SN, Porter JB, Scurr JH, Coleridge Smith PD. Endothelial activation in patients with chronic venous disease. *Eur J Vasc Endovasc Surg* 1998; 15: 342-9.
- Salmivirta M, Jalkanen M. Syndecan family of cell surface proteoglycans: developmentally regulated receptors for extracellular effector molecules. *Experientia* 1995; 51: 863-72.
- Santoro MM, Gaudino G. Cellular and molecular facets of keratinocyte reepithelization during wound healing. *Exp Cell Res* 2005; 304: 274-86.
- Schmidtchen A. Chronic ulcers: a method for sampling and analysis of wound fluid. *Acta Derm Venereol* 1999; 79: 291-5.
- Schmidtchen A, Holst E, Tapper H, Björck L. Elastase-producing *Pseudomonas aeruginosa* degrade plasma proteins and extracellular products of human skin and fibroblasts, and inhibit fibroblast growth. *Microb Pathog* 2003; 34: 47-55.
- Schmidtchen A, Wolff H, Hansson C. Differential proteinase expression by *Pseudomonas aeruginosa* derived from chronic leg ulcers. *Acta Derm Venereol* 2001; 81: 406-9.
- Scott HJ, Coleridge Smith PD, Scurr JH. Histological study of white blood cells and their association with lipodermatosclerosis and venous ulceration. *Br J Surg* 1991; 78: 210-1.
- Singer AJ, Clark RA. Cutaneous wound healing. *N Engl J Med* 1999; 341: 738-46.
- Sipos P, Gyory H, Hagymasi K, Ondrejka P, Blazovics A. Special wound healing methods used in ancient Egypt and the mythological background. *World J Surg* 2004; 28: 211-6.
- Smith PC. The causes of skin damage and leg ulceration in chronic venous disease. *Int J Low Extrem Wounds* 2006; 5: 160-8.
- Tapper H, Karlsson A, Mörgelin M, Flodgaard H, Herwald H. Secretion of heparin-binding protein from human neutrophils is determined by its localization in azurophilic granules and secretory vesicles. *Blood* 2002; 99: 1785-93.

- Taylor KR, Gallo RL. Glycosaminoglycans and their proteoglycans: host-associated molecular patterns for initiation and modulation of inflammation. *Faseb J* 2006; 20: 9-22.
- Toledo-Pereyra LH. Claudius Galenus of Pergamum: surgeon of gladiators. Father of experimental physiology. *J Invest Surg* 2002; 15: 299-301.
- Towbin H, Staehelin T, Gordon J. Electrophoretic transfer of proteins from polyacrylamide gels to nitrocellulose sheets: procedure and some applications. *Proc Natl Acad Sci U S A* 1979; 76: 4350-4.
- Turley EA. Hyaluronan and cell locomotion. *Cancer Metastasis Rev* 1992; 11: 21-30.
- Wagener FA, Eggert A, Boerman OC, Oyen WJ, Verhofstad A, Abraham NG, Adema G, van Kooyk Y, de Witte T, Figdor CG. Heme is a potent inducer of inflammation in mice and is counteracted by heme oxygenase. *Blood* 2001; 98: 1802-11.
- Valencia IC, Falabella A, Kirsner RS, Eaglstein WH. Chronic venous insufficiency and venous leg ulceration. *J Am Acad Dermatol* 2001; 44: 401-21; quiz 22-4.
- Van de Scheur M, Falanga V. Pericapillary fibrin cuffs in venous disease. A reappraisal. *Dermatol Surg* 1997; 23: 955-9.
- van Korlaar I, Vossen C, Rosendaal F, Cameron L, Bovill E, Kaptein A. Quality of life in venous disease. *Thromb Haemost* 2003; 90: 27-35.
- Vande Berg JS, Robson MC. Arresting cell cycles and the effect on wound healing. *Surg Clin North Am* 2003; 83: 509-20.
- Wenk J, Foitzik A, Achterberg V, Sabiwalsky A, Dissemond J, Meewes C, Reitz A, Brenneisen P, Wlaschek M, Meyer-Ingold W, Scharffetter-Kochanek K. Selective pick-up of increased iron by deferoxamine-coupled cellulose abrogates the iron-driven induction of matrix-degrading metalloproteinase 1 and lipid peroxidation in human dermal fibroblasts in vitro: a new dressing concept. *J Invest Dermatol* 2001; 116: 833-9.
- Werner S, Grose R. Regulation of wound healing by growth factors and cytokines. *Physiol Rev* 2003; 83: 835-70.
- Winter GD. Formation of the scab and the rate of epithelisation of superficial wounds in the skin of the young domestic pig. 1962. *J Wound Care* 1995; 4: 366-7; discussion 8-71.
- Woods A, Couchman JR. Syndecan 4 heparan sulfate proteoglycan is a selectively enriched and widespread focal adhesion component. *Mol Biol Cell* 1994; 5: 183-92.
- Yam CH, Fung TK, Poon RY. Cyclin A in cell cycle control and cancer. *Cell Mol Life Sci* 2002; 59: 1317-26.
- Zhou Z, Wang J, Cao R, Morita H, Soininen R, Chan KM, Liu B, Cao Y, Tryggvason K. Impaired angiogenesis, delayed wound healing and retarded tumor growth in perlecan heparan sulfate-deficient mice. *Cancer Res* 2004; 64: 4699-702.