Fixation of the cemented acetabular component in hip arthroplasty.

Flivik, Gunnar

Published in:
Acta Orthopaedica. Supplementum

DOI:
10.1080/03008820510040685

2005

Contents

List of Papers

This thesis is based on the following papers, which in the text are referred to by their Roman numerals:

I. **Circulating blood diminishes cement penetration into cancellous bone. *In vivo* studies of 21 arthrotic femoral heads.**
Juliusson R, Flivik G, Nilsson J, Ryd L, Önnerfält R.
Acta Orthop Scand 1995; 66(3): 234–238.

II. **Effects of lamination on the strength of bone cement.**
Flivik G, Yuan X, Ryd L, Juliusson R, Lidgren L.
Acta Orthop Scand 1997; 68(1): 55–58.

III. **A comparison of structural and mechanical properties in cancellous bone from the femoral head and acetabulum.**
Thompson MS, Flivik G, Juliusson R, Odgaard A, Ryd L.
J Engineering in Medicine (ProcIMechE part H) 2004; 218(6): 425–429.

IV. **Improved acetabular pressurization gives better cement penetration. *In vivo* measurements during total hip arthroplasty.**
Flivik G, Wulff K, Sanfridsson J, Ryd L.
J Arthroplasty 2004; 19(7): 911–918.

V. **Migration of the acetabular component: Effect of cement pressurization and significance of early radiolucency. A randomized 5-year study using radiostereometry.**
Flivik G, Sanfridsson J, Önnerfält R, Kesteris U, Ryd L.
Acta Orthop, in press.

VI. **Removal or retention of the subchondral bone plate? – Effect on cemented acetabular component fixation. A randomized 2-year study using radiostereometry.**
Flivik G, Kristiansson I, Kesteris U, Ryd L.
Submitted manuscript.

Abbreviations

FEA – Finite Element Analysis
HHS – Harris Hip Score
ME – Mean error of rigid body fitting
PMMA – Polymethylmethacrylate
RSA – Radiostereometric analysis
SF-36 – 36-Item Short-Form Health Survey
SF-12 – 12-Item Short-Form Health Survey
THA – Total hip arthroplasty
WOMAC – Western Ontario and McMaster Universities Osteoarthritis Index

Introduction

Sir John Charnley introduced the concept of low-friction hip arthroplasty in the early 1960s. He used a stainless steel stem articulating against a polyethylene acetabular component, with both components fixed to the bone using polymethylmethacrylate (PMMA) bone cement, polymerized in situ. This was the start of a new era in the history of hip arthroplasty and today it still constitutes the basis of total hip arthroplasty (THA). Over the years many different implant materials, designs and fixation methods, both uncemented and cemented, have been used. However, the cemented all metal stem against a cemented polyethylene cup is still the gold standard in Sweden, showing very good long-term follow-up results. The first THA in Sweden was done in 1967 and today well over 10,000 THAs are performed in Sweden annually. More than 90% of the acetabular components are cemented (Herberts et al. 2004). The use of uncemented acetabular cups has not improved the cup survival. On the contrary, higher revision rates are reported for uncemented cups in both the Swedish and the Norwegian Hip Registers (Havelin et al. 2000, Havelin et al. 2002, Herberts et al. 2004).

The results of THA today are generally very good with a Swedish national average for 10 years prosthesis survival of over 92%. The 20 years survival is projected to be over 80%. THA has been said to be one of the most cost effective operations in surgery (Chang et al. 1996). The effect in terms of pain reduction, improved function and quality of life outcome is striking. However, aseptic loosening of the prosthesis remains a problem and in Sweden today revisions constitute about 10% of hip arthroplasties. In international comparisons Sweden has a relatively low revision burden, compared with for instance the United States with a revision burden of about 20%. With such a large number of revision operations each year, which is probably increasing as people live longer and expect more active later lives, the cost of revision surgery is becoming an important issue. All patients who are outlived by their prosthesis with continued good function mean considerable gains on both the individual and societal levels. With today's good long term results younger patients are considered for operations, which puts higher demands on both the implants and the surgical technique. There is a need of well designed research projects in order to follow-up patients with the aim of understanding the causes of implant failure and thus continuing the improvement in operating results.

The overall complication rate of THA has decreased continuously over the years, partly because of improved materials, better aseptic techniques and perioperative regimes, but also because of better cementing technique, as shown in the Swedish national hip register (Malchau et al. 1993, Malchau et al. 2002) As for the major remaining problem of aseptic loosening it seems that the long term results of the acetabular component have gained less from the improvements, and aseptic loosening of the cup predominates over femoral loosening (Callaghan et al. 2000, Berry et al. 2002). Especially in younger and more active patients long term acetabular cup fixation is problematic (Ballard et al. 1994, Mulroy and Harris 1997).

In cemented joint arthroplasty a major prerequisite for lasting implant fixation is an initially stable and secure fixation at the cement-bone interface (Kärrholm et al. 1994, Mjöberg 1994, Ryd et al. 1995, Stocks et al. 1995). In this way micromovement between cement and bone is minimized and, furthermore, the access and influence of hydrostatic pressure from the joint on the interface is impeded, as is the migration of later produced wear debris along the interface (Eftekhar and Nercessian 1988, Schmalzried et al. 1992, Aspenberg and Van der Vis 1998). The fixation is dependent on the interdigitation of bone cement into the cancellous bone, and the greater the penetration into this porous trabecular structure, up to 3–5 mm, the stronger the mechanical interlock (Huiskes and Slooff 1981, Krause et al. 1982, Askew et al. 1984, MacDonald et al. 1993, Majkowski et al. 1993). To achieve this degree of penetration, high cementation pressures are needed (Juliusson et al. 1994) and adequate preparation of the cancellous bone

bed is essential (Krause et al. 1982, Majkowski et al. 1993).

The appearance and anatomy of the acetabulum raises particular difficulties for cement pressurization and penetration, quite different from the femur where high pressures are achieved more easily. The acetabulum has a large surface area, a wide opening and a discontinuity in the wall under the transverse ligament, all of which make it difficult to achieve adequate intrusion pressure on the cement. The subchondral bone plate, which is a thin but dense structure, plays according to 2-Dimensional Finite Element Analysis (2-D FEA) an important role in stress distribution in the acetabulum even after the insertion of a prosthesis (Jacob et al. 1976, Vasu et al. 1982, Carter et al. 1983). Retention of the subchondral bone plate when preparing the acetabulum has therefore been identified as part of modern cementing technique since it was introduced with the so-called second generation cementing technique in the early 1980s (Cornell and Ranawat 1986, Weber 1988, Kobayashi and Terayama 1990, Mulroy et al. 1995, Ziegler and Lachiewicz 1996, Ranawat et al. 1997). As no cement penetration can occur through the subchondral bone plate and all cement interdigitation has to take place in anchorage holes, the question arises what effect this has on the stability of the interface. The validity of the earlier 2-D FEA studies has also been questioned (Dalstra 1993, Sutherland et al. 2000). Today there is no consensus regarding retention or removal of the subchondral bone plate.

The bone structure and the permeability of the cancellous bone in the acetabulum are important factors for cement penetration that have not been fully evaluated. Results from studies on cancellous bone from other skeletal parts of the body have instead been extrapolated to be applicable in the acetabulum. Those studies show wide variations in permeability (Grimm and Williams 1997, Lim and Hong 2000, Ochia and Ching 2002).

Timing of cement application and cup introduction influences cement penetration because of the time-dependent changes in the viscosity of the cement. The basic principle is that the lower viscosity, the better the penetration (Krause et al. 1982, Noble and Swarts 1983, Stone et al. 1996). However, cement becomes more difficult to handle at low viscosity, and in the acetabulum leakage around the edges becomes more of a problem, thus putting higher demands on transforming the cavity into a closed space during cement pressurization. Furthermore, low viscosity cement risks escaping more easily into the venous system instead of penetrating deeper into the bone (Breusch et al. 2002). Certain information is still lacking on the behavior of cement under different circumstances, for example how the cement responds to higher pressure in the presence of intact blood circulation.

Failure of the surgeon to achieve a secure and closed cement-bone interface can often be visualized on plain radiographs as a thin radiolucent line at the interface between bone and cement, most often in the proximal periphery of the acetabulum, i.e. zone 1 according to the modified Charnley DeLee classification (DeLee and Charnley 1976, Ranawat et al. 1995). The presence and especially the progress of this radiolucency have been shown to be important prognostic indicators of later loosening (Hodgkinson et al. 1988, Ranawat et al. 1995, Garcia-Cimbrelo et al. 1997). Even a minor radiological demarcation present postoperatively or emerging during the first year has been shown to result in a high degree of radiographical loosening within 10 years (Mulroy and Harris 1990, Hodgkinson et al. 1993, Ritter et al. 1999). Signs of early prosthetic migration have also proved to correlate with later failure by aseptic loosening (Freeman and Plante-Bordeneuve 1994, Kärrholm et al. 1994, Ryd et al. 1995, Krismer et al. 1996). The most precise method of measuring prosthetic micromotion is radiostereometry (RSA) (Selvik 1989, Kärrholm et al. 1997).

The patient's subjective outcome in function and quality of life, as measured by patient administered questionnaires, has previously been shown to be an early indicator of prosthesis loosening (Nilsson et al. 1994, Hilding et al. 1997). There is, however, no such study focusing on early cup loosening. As initial cup loosening gives limited or often no symptoms an investigation of that kind will put high demands on the evaluation tools.

Cemented cup fixation is thus a successful concept, but still with an unacceptably high rate of aseptic loosening. This slow, but progressive, process can be seen on early radiographs as a thin radiolucent line, which later thickens and gives rise to increasing bone loss, pain and impaired func-

tion, all together leading up to revision surgery. Improvements in cementation technique, with the aim of better primary cup fixation by means of a more secure and closed cement-bone interface may increase cup survival. To reach this goal, a better knowledge of the principles of fixation of the cemented acetabular component is needed.

Aims of the studies

The overall aim of this thesis was to evaluate the principles of cemented fixation of the acetabular component and to improve the cup fixation and thereby the length of cup survival.

The specific aims were:

To determine the cementation pressure needed for adequate cement penetration into cancellous bone under *in vivo* conditions, i.e. with persistent blood circulation (Paper I).

To evaluate the prerequisites regarding the cement strength for an improved cementation technique with sequential cementation of each anchorage hole prior to filling up the rest of the acetabulum with cement (Paper II).

To characterize the cancellous bone into which cement penetration occurs in the acetabulum and compare it to the cancellous bone of the femoral head in order to find out if earlier studies on femoral heads are applicable to the conditions in the acetabulum (Paper III).

To test the sequential cementation technique under *in vivo* conditions in comparison to current pressurizing technique by intraoperative cementation pressure recordings and postoperative radiographical penetration measurements (Paper IV).

To evaluate the effect of improved cement pressurization in comparison to fingerpacking of the cement in the acetabulum by migration analysis with RSA, zone analysis by radiographical measurements and clinical outcome by follow up questionnaires (Paper V).

To evaluate the effect of removal or retention of the subchondral bone plate in the acetabulum by migration analysis with RSA, zone analysis by radiographical measurements and clinical outcome by follow up questionnaires (Paper VI).

Materials, patients and methods

Patient cohorts (Papers I and IV–VI)

The patient studies were all approved by the Ethics Committee of Lund University and the patients had all given their informed written consent to participation. All patients were operated on for primary coxarthrosis. In studies I, V and VI the patients were selected from the waiting list at Lund University Hospital and operated on in Lund (studies I and V) or Landskrona Hospitals (study VI). In study IV the patients were selected from the waiting list at Ystad County Hospital, where they were also operated on. In studies V and VI a selection was made so that only patients in Charnley class A (unilateral hip disease with no other walking disability) or class B (bilateral hip disease with no other walking disability) at the time of operation were included. Patients in Charnley class C (systemic medical conditions or other physical conditions that impair locomotor abilities) were thus excluded from the studies.

Surgical procedures and randomization (Papers IV–VI)

In all three clinical studies (studies IV–VI) the basic surgical procedures were similar. A postero-lateral approach was used. In studies IV and V most of the acetabular subchondral bone plate was preserved, whereas in study VI this was determined by the randomization into groups of removal or retention of the subchondral bone plate. In study IV, the same two surgeons performed all operations, assisting each other. In study V, five surgeons performed the operations, of which two surgeons did the majority (33 out of 50). In study VI, two surgeons performed all operations, one of them doing the majority (43 out of 50). In all three studies the patients were randomized by the closed envelope method. In studies IV and V the envelope was opened after the preparation of the acetabulum had been finished, while in study VI randomization took place just before the start of acetabular preparation.

Implants, pressurization devices and bone cement (Papers I–II and IV–VI)

In study IV, the Exeter cup (Stryker Orthopaedics, USA) was used and in studies V and VI the Opticup (Biomet, UK). The pressurization device used in studies IV and VI for conventional cement pressurization was a commercially available pressurizer (Richards, Smith-Nephew, USA) (Figure 1). For the sequential cementation procedure used in one group in each of studies IV and V, custom-made devices were made of silicone. The sequential procedure included an initial cementation of each individual anchorage hole via a silicone nozzle (outer diameter 15 mm) (henceforth called the injector) attached to the tip of the cement gun (Figure 2). Subsequent filling of the rest of the acetabulum with cement was performed through a full size pressurizer (henceforth called the compressor) replacing the nozzle at the tip of the gun (Figure 3).

The bone cement used throughout all the studies was pre-chilled Palacos® with Gentamicin (Schering-Plough, Belgium). The cement was mixed according to the manufacturer's instructions, by the use of an Optivac® vacuum-mixing system (Biomet Cementing Technologies, Sweden).

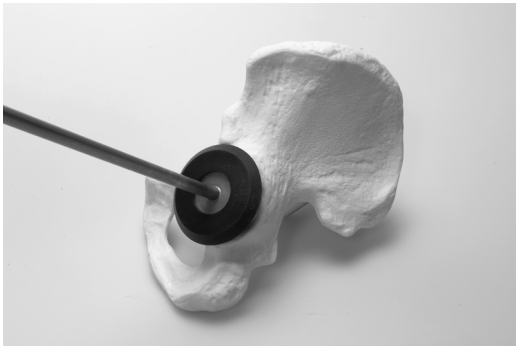

Figure 1. Illustration of the conventional pressurizer used in studies IV and VI.

Figure 2. Illustration of the injector used for initial cementation of the anchorage holes during sequential cementation in studies IV and V.

Figure 3. Illustration of the compressor used for the second phase of a sequential cementation in studies IV and V.

In vivo pressure measurements (Papers I and IV)

In study I the pressure created from the cement gun during pressurization was recorded by a balloon catheter (Shiley, Pfizer, USA) filled with saline and attached to the tip of the cement gun and further connected to a transducer (Druck, PDCR 75, Germany). The values were recorded continuously by a chart recorder.

In study IV a custom-made pressure transducer (modified Entran, EPB-B02, diameter 3.6 mm with a 100 mm shaft) was introduced and temporarily fixed in a drill channel just penetrating the bottom of the uppermost anchoring hole at the dome of the acetabulum (Figure 4). In this way the pressure recorded reflects the pressure at the bottom of this specific anchorage hole. The pressure transducer was connected to a patient monitor (model 78342A, Hewlett Packard, USA) that had been rebuilt and modified for the purpose. The pressure readings were received, amplified and then forwarded to an A/D-converter (Pico® ADC-11, Pico Technology Ltd, UK), which was in turn linked to a portable PC (Figure 5). The pressure was recorded continuously in real time during the whole cementation and cup insertion procedure. The peak pressures were noted and the area under the pressure-time curve, which represents the total pressurization during a given time period, was calculated. The mean pressure was then obtained by dividing the area under the curve by the pressurization time.

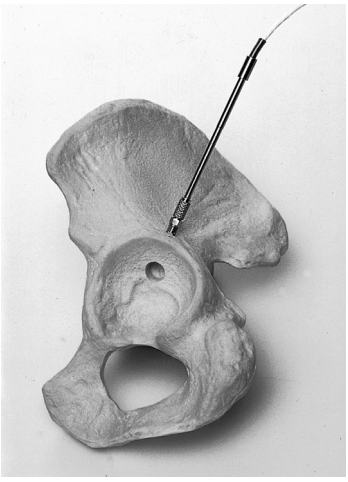

Figure 4. Illustration of the positioning of the pressure transducer used in the in vivo measurements of the acetabular pressure in study IV.

Penetration measurements (Papers I and IV–V)

The cement penetration into the femoral heads in study I was measured using a low magnification microscope. The specimens from the femoral heads were cut into 2–3 mm thick slices perpendicular to the cemented holes, and the penetration was assessed by measuring the two slices with the largest penetration areas twice and calculating the mean.

In studies IV and V the cement penetration into the anchorage holes was measured on special postoperative anterior-posterior digital radiographs taken at a standardized angle to the cup. The measurements were performed on a workstation by a



Figure 5. Setup in study IV of pressure recordings with a modified patient monitor connected to a PC via an A/D converter. The pressure transducer mounted in the patient's acetabulum is connected through the white signal input wire on the front.

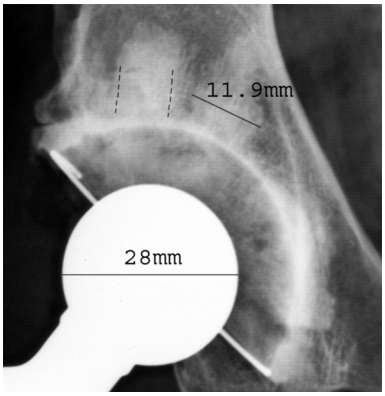

Figure 6. Simplified illustration of how cement penetration in the anchorage holes was measured in study IV and V. The dotted line of the lateral hole indicates the width of the drill hole (9 mm).

radiologist blinded to the operative procedure. The cement width of the medial/uppermost acetabular anchorage tap was measured twice to obtain a mean value for the widest part of the tap (Figure 6). The measurement scale was calibrated for magnification using the known diameter of the patient's prosthetic femoral head. The observer was free to optimize the digital image on the monitor before measurement with respect to magnification, contrast and density levels. With this optimization, in combination with the standardized positioning of the three 9 mm anchorage holes of os ilium, the potential difficulty in distinguishing between the cement protrusions from the adjacent anchorage holes was overcome.



Figure 7. A cement bar before (top) and after (bottom) fracture in the tensile strength test in study II.

Biomechanical testing (Papers II–III)

In study II cement bars with a lamination interface, either dry or including blood or saline, were made at different time intervals after cement mixing. They were radiographed to allow the exclusion of those with voids at the interface. The remaining specimens were machined to dumbbell tensile test specimens (Figure 7) and the tensile strength was tested in an Instron materials testing-machine (Figure 8). The average ultimate tensile stress was calculated by dividing the ultimate tensile force by the cross-sectional area of the fracture surface.

In study III bone specimens were taken with a core drill from the articular surfaces of the acetabulum and a corresponding site on the femoral head during THA. The specimens were then analyzed after mechanical and chemical defattening. The permeability was evaluated by mounting each specimen in a 9 mm tube and letting saline solution from a tank 1 meter above the specimen (i.e. a static fluid pressure of 9.8 kPa) be drained through the specimen for 1 minute in each of two tests. With the knowledge of the measured fluid flow velocity (υ), the saline viscosity (η) and the pressure gradient (dP / dx), the mean permeability (k) could then be calculated using Darcy's law, $\upsilon = (- k / \eta)(dP / dx)$. The apparent density was calcu-

Figure 8. Instron testing-machine with a cement bar mounted as in study II.

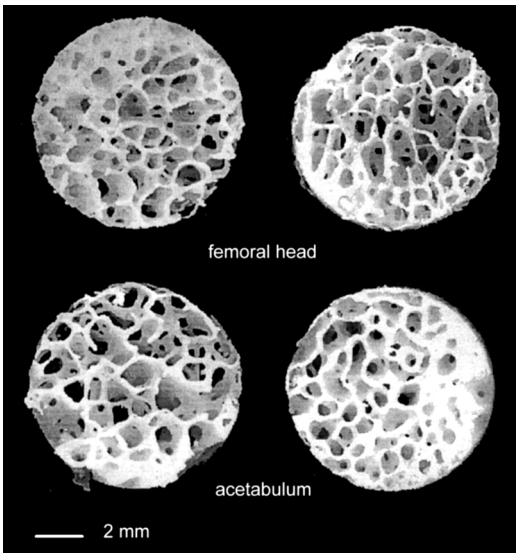

Figure 9. Reconstruction after serial sections of typical specimens from femoral and acetabular bone. For the structural analysis in study III.

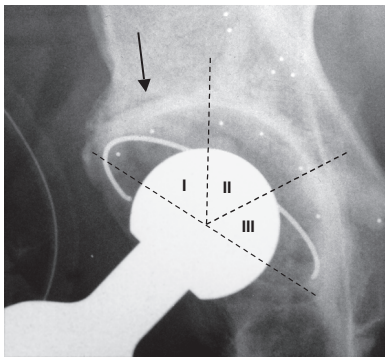

Figure 10. Postoperative radiograph from study V with a thin radiolucency in zone 1.

lated from the dry weight and volume. Mechanical testing, to obtain Young's modulus, was carried out non-destructively using an Instron materials testing-machine. Measurements of the bone architecture were done using an automated serial sectioning technique with a camera mounted above the osteotome. Thereafter a three-dimensional computer reconstruction of the bone could be obtained (Figure 9). The reconstruction was used to determine the structural properties, namely bone volume fraction (density), anisotropy (degree of directionality of the trabecular network) and connectivity (number of trabecular connections per unit volume bone) (Odgaard and Gundersen 1993).

Radiological evaluation—zone analysis (Papers V–VI)

In both studies V and VI zone analysis was done on the postoperative pelvic and AP-view radiographs according to the Hodgkinson classification (Hodgkinson et al. 1988). Accordingly, the region around the acetabular component was divided into three equal zones of 60° in relation to the baseline of the cup (zone 1 = outer lateral = 0–60°, zone 2 = central = 60–120° and zone 3 = outer medial = 120–180°) (Figure 10). The known diameter of the prosthetic femoral head was used to calibrate for magnification. The visual definition of a radiolucency involves a grey zone. In order not to overestimate the phenomenon, a radiolucent line at the cement-bone interface was considered to be present if there was a radiolucency width of >0.3 mm

(excluding the sclerotic demarcation) and a length of >50% of the interface in that zone (Hultmark et al. 2003). The radiographs were then classified with Grade 0 = no radiolucency; Grade 1 = radiolucent line in outer 1/3; Grade 2 = radiolucent line in outer and middle 1/3; Grade 3 = complete radiolucent line and Grade 4 = obvious signs of cup migration. In study V the zone analysis was done on printed radiographs using a digital slide calliper with a 1/100 mm scale. In study VI the measurements were performed on digital radiographs on a workstation using the software I-SoftView 5.2 and OrthoWorks® (Cedara, Canada). In this study the postoperative as well as the 1 and 2 year pelvic and AP-view radiographs were analyzed with regard to the extent and width of radiolucent lines at the cement-bone interface. In addition to the Hodgkinson classification, the extent of the radiolucency was also described as the percentage of the maximum 180º (the subtending angle to the radiolucent line divided by 180º).

In both studies V and VI the inclination of the cup was determined with the teardrop line as reference.

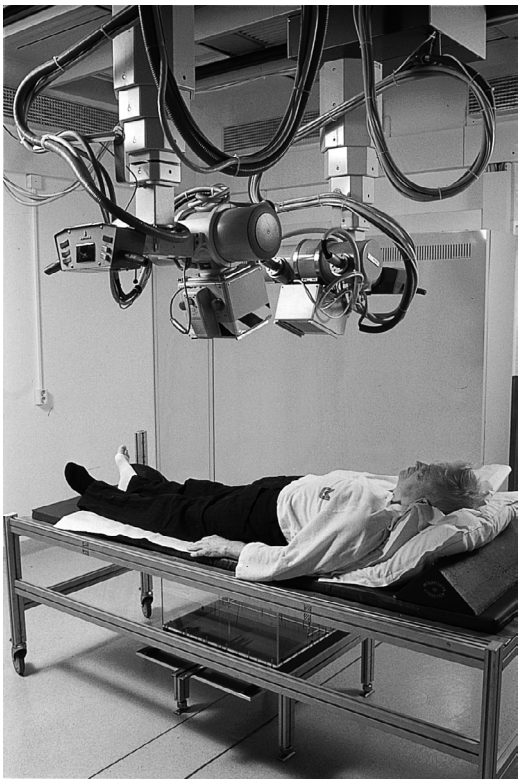

Figure 11. Patient in position for RSA examination with the two X-ray tubes above and the calibration cage beneath the patient.

Radiostereometry (RSA) (Papers V–VI)

In studies V and VI RSA was used to measure migration during the follow-up period. The radiostereometric examinations were done with a uniplanar technique (Selvik 1989, Kärrholm et al. 1997) with the patient in a supine position (Figure 11). A type 41 calibration cage (Tilly Medical AB, Sweden) was used in both studies, and the computer software used for the RSA analysis was UmRSA® version 5.0 (RSA Biomedical, Sweden).

The cups were marked by the manufacturer with 7–9 tantalum markers. In study V 0.8 mm markers and in study VI 1.0 mm markers were used. The cups were available in sizes 46 to 56 mm. Intraoperatively, after the preparation of the acetabulum, but before cementation of the cup, 9 tantalum markers (0.8 mm) were inserted into the periacetabular bone through the anchorage holes as scattered as possible. The reference examination was performed within one week of the operation in study V, whereas in study VI it was done on the morning of the first postoperative day, before any patient mobilisation. In study VI, 12 patients had an extra examination on the fifth postoperative day in order to evaluate if there was any measurable prosthesis migration during the first few days of mobilisation. In both studies the follow-up RSA examinations were performed at 3, 6, 12 and 24 months after the operation, and in study V there was an additional follow-up at 5 years. The cut-off level for exclusion of specific examinations from the study was established regarding condition number (an expression for how adequately the tantalum markers have been scattered during insertion) and set to be 150. For the mean error of rigid body fitting (an expression for marker stability within the bone or prosthesis) the cut-off level was set at 0.35. Migration results from RSA were expressed as rotation and translation about/along the three axes in an orthogonal coordinate system, i.e. with 6 degrees of freedom of motion (Figure 12). Of these, proximal translation (Y-axis) and sagittal rotation (Z-axis) were selected as primary effect variables for

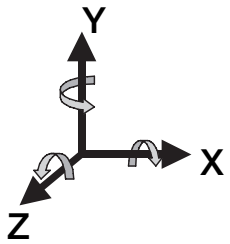

Figure 12. The six possible migrations as either translation or rotation along to the three cardinal axes. Arrows indicate positive directions.

both studies. In study VI polyethylene wear was also measured. These wear measurements were calculated from point motion analyses as proximal migration of the head into the cup and the resultant 3D vector. The limits for the smallest significant movements were set to equal the precision of the RSA measurements, which was assessed by two repeated examinations of the patient within an interval of 10–15 minutes, so-called double examinations (Table 1). In study V there was a total of 40 double examinations and in study VI there were 60. Results of both studies were given as signed values of migration, i.e. the direction of migration was taken into account. Because of insufficient number of tantalum markers or inadequate scatter of the markers in the bone 2 patients in study V and 1 patient in study VI had to be excluded from this part of the studies. At the 5 year follow-up in study V, 43 out of 50 hips remained for analysis and at the 2 year follow-up in study VI there were 49 out of 50 hips remaining.

Clinical evaluation and outcome questionnaires (Papers V–VI)

Before the operation the patients were all classified according to Charnley class (Charnley 1979), and only class A (unilateral hip disease with no other walking disability) and B (bilateral hip disease with no other walking disability) were considered for the studies. The patients' height and weight were recorded and their Body Mass Index (BMI) calculated (weight (kg) / height^2 (m)). In both studies V and VI the patients were evaluated by self-administered outcome questionnaires. In study V the patients completed the general 36-Item Short-Form Health Survey (SF-36) (Ware and Sherbourne 1992) preoperatively and at 1 and 5 years postoperatively. Additionally, they were evaluated using the Harris Hip Score (HHS) (Harris 1969) preoperatively and at 1 year. In study VI the patients were evaluated preoperatively and at 1 and 2 years postoperatively using the general 12-Item Short-Form Health Survey (SF-12) (Ware et al. 1996) as well as the hip-specific Western Ontario and McMaster Universities Osteoarthritis Index (WOMAC) (Bellamy et al. 1988) and HHS.

Table 1. Precision of the RSA measurements, measured with 99% significance limits for migration. Values represent mean +2.7SD of the error obtained from the double investigations of patients in the studies

	Study V	Study VI
Translations (mm)		
Medial–lateral (X)	0.19	0.12
Proximal–distal (Y)	0.12	0.18
Anterior–posterior (Z)	0.22	0.27
Rotations (°)		
Transverse axis (X)	0.74	0.69
Longitudinal axis(Y)	0.74	0.53
Sagittal axis (Z)	0.59	0.35
Wear (mm)		
Proximal–distal (Y)	–	0.14
3D penetration	–	0.20

Statistical analysis (Papers I–VI)

Throughout the studies p-values below 0.05 were considered to be significant. The software used throughout the projects was SPSS statistical packages in various versions (SPSS Inc, Chicago, USA). Parametric tests were used when equal variances were assumed, otherwise the non-parametric equivalent. Student's t-test, or ANOVA if there were more than 2 groups, was used in most cases to assess the differences between groups. In studies V and VI the RSA results over time were analyzed by repeated measures ANOVA (MANOVA), using RSA values from examinations at 3, 6, 12, 24 and for study V also at 60 months. By means of a covariance analysis the RSA results were adjusted for covariates. For analysis of the outcome questionnaires the Friedman test was performed over time and the Mann-Whitney U-test for comparison between the groups. Spearman correlation analysis was used for tests comparing RSA and outcome

questionnaires results. The correlation analyses in studies I, III and IV were performed with Pearson's regression analysis. Comparison of the cross tabulation results in study V was done by means of Fisher's exact test.

A power analysis for the randomized clinical RSA-studies revealed that 21 patients were needed in each group at an alfa of 0.05 and a beta of 0.8. We included 25 patients in each group to allow for drop-outs.

Summary of Papers

Study I: Circulating blood diminishes cement penetration into cancellous bone. *In vivo* studies of 21 arthrotic femoral heads

Study design: *In vivo* experimental.

Objective: Earlier *in vitro* studies have indicated the need for high cementation pressures to achieve the desired cement penetration of 3–4 mm. This study aimed at investigating the influence of an intact blood circulation on the cement penetration and evaluating the correlation between applied pressure and penetration achieved.

Materials and methods: The cementation experiments were performed during 32 THAs. Of these 11 had to be excluded because of technical difficulties, final results thus being based on 21 femoral heads. After dislocation, but before osteotomy of the femoral neck (i.e. intact circulation), a 10 mm hole was drilled in the uppermost sclerotic part of the femoral head to simulate the anchorage holes made in the subchondral bone plate of the acetabulum. After thorough cleaning, the hole was cemented for 20 seconds with a cement gun provided with a silicone nipple. According to a random schedule each femoral head was pressurized at 0.1, 0.2 or 0.3 MPa and at 1, 2 or 4 minutes after start of cement mixing. Thereafter the femoral neck was cut (i.e. circulation disrupted) and the cementation procedure was repeated in exactly the same way in a new drill hole, made at least 15 mm away, but still in the same sclerotic part of the femoral head. Bone blocks were cut out and measurements of the cement penetration achieved surrounding the hole were performed.

Results: The cement penetration ranged from 0.1 mm to 4.6 mm among specimens cemented in the presence of circulation and between 0.8 and 8.2 mm for those cemented in the absence of circulation. In all cases penetration was less in the presence of circulation with a mean decrease in penetration of 50% ($p<0.0001$) (Figure 13). The penetration depth increased with the applied pressure level, but did not correlate with the time from mixing to cement application. There was a strong correlation between penetration with or without circulation in the individual heads ($r^2=0.7$, $p<0.0001$).

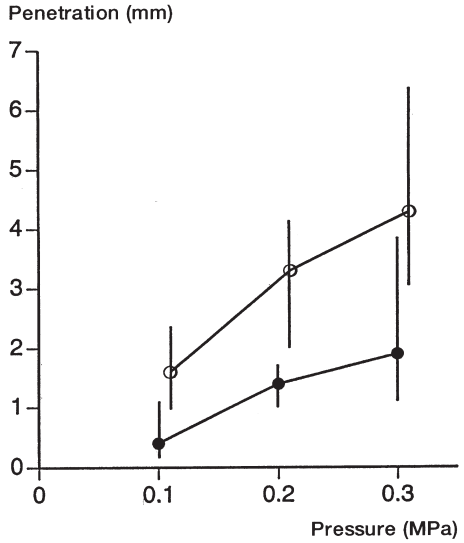

Figure 13. Diagram showing the relation between pressure and cement penetration for 21 femoral heads cemented with (-●-) or without (-○-) circulation (mean with 25–75 percentiles).

Conclusions: Cement penetration increases with the applied pressure. In the presence of circulation penetration decreases by 50%. The influence of circulation is due to incompressibility of fluid and lack of escape routes rather than the intraosseous blood pressure itself. Pressures higher than those achievable with current acetabular pressurization techniques seem to be needed to achieve adequate cement penetration.

Study II: Effects of lamination on the strength of bone cement

Study design: Laboratory experimental.

Objective: To improve cement penetration into the cancellous bone in the acetabulum a sequential cementation of each anchorage hole may be feasible. This study aimed at determining the condi-

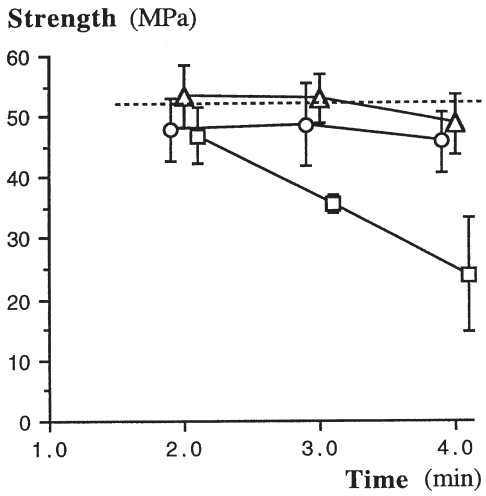

Figure 14. The relation between interfacial cement strength and the time elapsed from start of cement mixing up to lamination for 3 different kinds of cement-cement interface (△ saline, ○ dry, □ blood). Dotted line refers to the reference strength of solid bars (mean ± SD).

tions under which laminations arising during such a procedure affect the strength of the cement, i.e. if and under what conditions a sequential cementation procedure may be used in the acetabulum.

Materials and methods: Approximately 200 cement bars were made at 2, 3 or 4 minutes after start of cement mixing with either a dry lamination interface or laminations including fresh venous blood or saline. Solid unlaminated bars were used as references. The specimens were tested for tensile strength in an Instron materials testing-machine. Because of voids in the cement found on radiographs or fractures outside the lamination area, more than half of the specimens were excluded. The ultimate tensile stresses of the different interfaces and of the solid reference bars were recorded.

Results: The solid unlaminated bars had a mean tensile strength value of 52 (47–62) MPa. Dry laminations and laminations including saline did not reduce the specimen strength for any of the time groups. However, blood laminated bars showed a time-from-mixture dependent decrease in cement strength. There was no decrease in strength when the blood lamination was made at 2 minutes after cement mixing, but when made at 3 minutes the strength had decreased by about 30% ($p<0.0001$) and at 4 minutes by more than 50% ($p<0.0001$) (Figure 14).

Conclusions: A sequential cementation procedure in the acetabulum is feasible as regards cement strength, provided it is performed within 2-3 minutes after start of cement mixing. If the cement area is kept free from blood or washed with saline, the time may be prolonged up to 4 minutes without the risk of weakening the cement strength. These results further emphasize the importance of keeping the bone-bed dry and thoroughly cleaned prior to cementation.

Study III: A comparison of structural and mechanical properties in cancellous bone from the femoral head and acetabulum

Study design: In vivo experimental.

Objective: This study aimed at characterizing the acetabular cancellous bone and its relevance to cement penetration. A further aim was to compare the properties of acetabular and femoral cancellous bone and to assess the suitability of femoral cancellous bone in cementation studies as a model for acetabular bone, which is more difficult to obtain.

Materials and methods: During 12 THAs bone biopsies were taken from the articular surface of the acetabulum and the corresponding point on the femoral head. After exclusion because of damage or cysts in the specimens, a total of 14 specimens (7 pairs) remained for analysis and were characterized using flow measurements, mechanical testing and finally serial sectioning and three-dimensional computer reconstruction. Results were achieved regarding permeability, stiffness, porosity and connectivity of the specimens.

Results: There was no difference in permeability between acetabular (1.155×10^{-10} m^2) and femoral cancellous bone (1.064×10^{-10} m^2), but a large variation in permeability with a factor of over 50 between the highest and the lowest, which is similar to earlier studies on human bone. Nor could any significant differences be found in any of the other measured properties. The correlation between measured structural properties and permeability was weak ($r^2=0.26$).

Conclusions: There is no significant difference in permeability, stiffness, porosity or connectivity between cancellous bone specimens from the acetabulum and the femoral head. Results obtained

from cement penetration studies on femoral head cancellous bone (such as in paper I) are thus also relevant to penetration into acetabular cancellous bone.

Study IV: Improved acetabular pressurization gives better cement penetration. *In vivo* measurements during total hip arthroplasty

Study design: Randomized controlled trial.

Objective: The pressure reached in the cancellous cement-bone interface *in vivo* during THA is not known. Information is also lacking on how that pressure *in vivo* correlates to the cement penetration achieved. This study aimed at investigating these questions by a comparison between conventional pressurization of the acetabulum and the sequential cementation technique, including individual pressurization of each anchorage hole before filling up the rest of the acetabulum with cement.

Patients and methods: 14 patients at a mean age of 70 (range 56–82) and operated on with THA because of primary coxarthrosis were randomized into two groups with different techniques to pressurize the cement, either with a conventional pressurizer or with the sequential cementation technique. The intraoperative cementation pressure inside one of the acetabular anchorage holes was measured in real time during the whole cementation and cup insertion procedure (Figure 15). Special postoperative digital radiographs were analyzed and the cement penetration in the medial/uppermost acetabular anchorage hole was measured.

Results: The early peak pressures were higher for the sequential method (mean 860 mmHg, always during injector phase), resulting in a significantly better cement penetration of 2.8 mm compared to 0.7 mm with the conventional pressurizer (mean 650 mmHg) ($p = 0.03$). There was a strong correlation ($r^2 = 0.64$) between cement penetration into the cancellous bone of the anchoring holes and peak cementation pressure measured before cup insertion. The highest peak pressures, however, were always achieved later during cup insertion (mean 1150 mmHg), but these pressures did not correlate with cement penetration.

Conclusions: Good cement penetration in the acetabulum is dependent on cement pressurization before cup insertion. The sequential cementation procedure seems to be preferable to conventional methods which appear to be insufficient. A combination of early cement application under sustained high pressure and late cup insertion is probably optimal for good cement penetration.

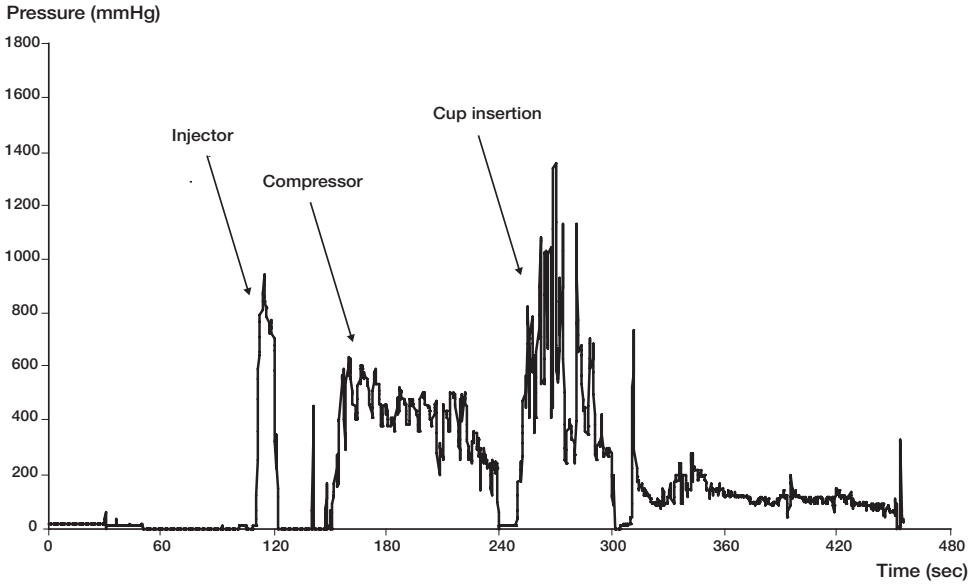

Figure 15. Example of a time-pressure curve during a sequential cementation procedure.

Study V: Migration of the acetabular component: Effect of cement pressurization and significance of early radiolucency. A randomized 5-year study using radiostereometry

Study design: Randomized controlled trial.

Objective: Cementing technique in the acetabulum is an important factor for long term cup survival. This study aimed at comparing migration, radiographical findings and clinical outcome for patients operated with or without increased pressurization prior to cup insertion.

Patients and methods: 50 THA operations were performed because of primary coxarthrosis in 45 patients at a mean age of 65 (range 51–82). They were randomized into two groups of cementing the acetabulum, either "fingerpacking" of the cement or using the sequential pressurization technique. In this study the subchondral bone plate was retained during reaming. The patients were followed for 5 years with repeated RSA-examinations to evaluate cup migration. The postoperative radiographs were examined regarding cement penetration in the anchorage holes and the presence and extent of radiolucent lines, which were correlated to the RSA-results. For clinical evaluation SF-36 and HHS were used.

Results: The only difference in migratory behavior was that the pressurized group was significantly more stable regarding changes in inclination ($p=0.002$) (Figure 16). The fingerpacked group tilted slightly, but continuously, towards a more horizontal position, whereas the sequentially cemented group stabilized early in a slightly more vertical position. The mean proximal cup migration for each group was 0.6 mm at 5 years (Figure 17). Cement penetration was deeper with the pressurization technique (0.7 mm) as compared to fingerpacking (0.2 mm) ($p=0.02$). For the whole group taken together, there was a strong relation between presence of radiolucent lines postoperatively and later migration observed by RSA at both 2 and 5 years ($p<0.001$) (Figure 18). No difference in clinical outcome was seen.

Conclusions: Increased pressurization of the cement prior to cup insertion gives better cement penetration in the anchorage holes, which seems to have a stabilizing effect on changes in inclination over time. Early radiographical radiolucency predicts later unfavorable cup migration as measured by RSA.

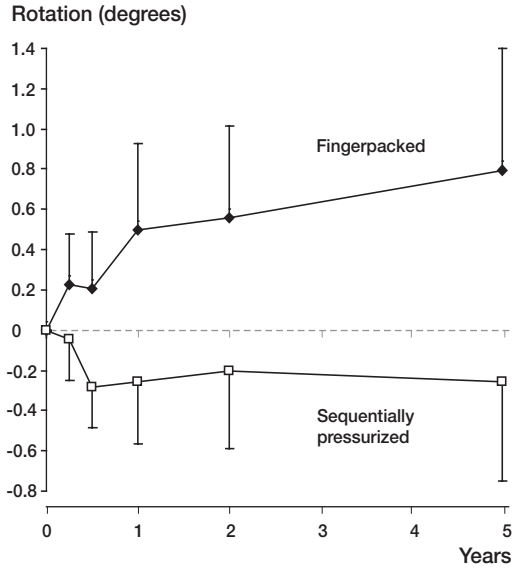

Figure 16. Rotation around the sagittal axis (Z), i.e. changes in inclination, up to 5 years. Values are shown as mean with 95% confidence intervals.

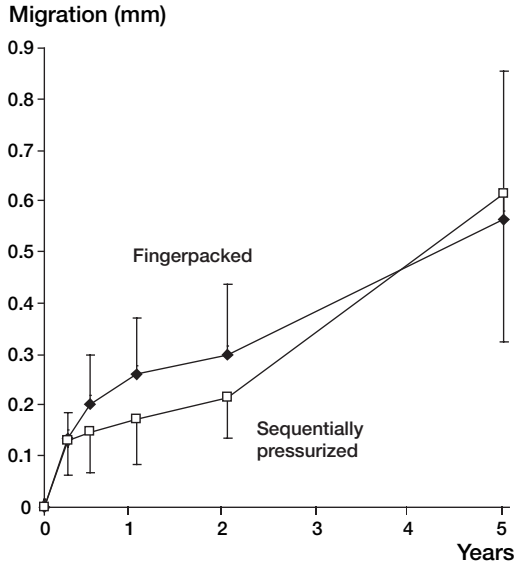

Figure 17. Proximal cup migration (Y-axis) up to 5 years. Values are mean with 95% confidence intervals.

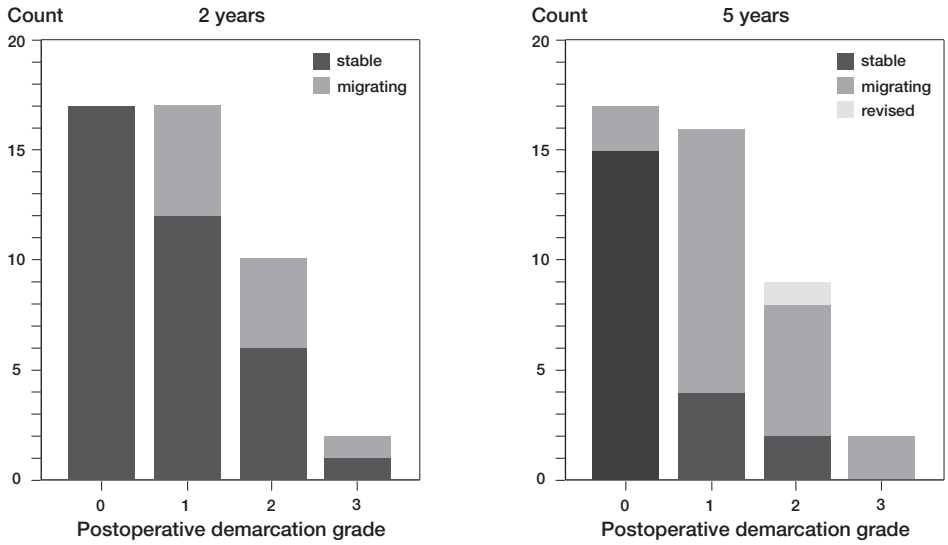

Figure 18. Distribution of migrating or stable cups determined by RSA at 2 and 5 years, respectively. Depending on the distribution of direct postoperative radiographical demarcation, all patients were grouped as grade 0 (no demarcation), grade 1 (outer 1/3), grade 2 (outer and middle 1/3) and grade 3 (complete demarcation).

Study VI: Removal or retention of the subchondral bone plate? – Effect on cemented acetabular component fixation. A randomized 2-year study using radiostereometry

Study design: Randomized controlled trial.

Objective: Retention of the subchondral bone plate during acetabular preparation in THA has been identified as part of modern cementing technique, an opinion mainly based on 2-D FEA studies. However, those studies have been questioned and there is no longer any real consensus concerning that issue. The present study aimed at comparing the effect of either retention or removal of the subchondral bone plate by comparing cup migration, wear, radiological result and clinical outcome.

Patients and methods: 50 patients at a mean age of 68 (range 54–82) were operated on with THA because of primary coxarthrosis. They were randomized into two groups of either retention or removal of the subchondral bone plate during acetabular reaming (Figure 19). The effect was evaluated during a 2-year follow-up period by repeated RSA examinations, analyses of radiolucent lines on conventional radiographs and clinical follow-ups with WOMAC, SF-12 and HHS.

Results: Removal of the subchondral bone plate resulted in an improved radiological appearance of the cement-bone interface and less development of radiolucent lines ($p<0.001$). The removal group increased from 0% postoperatively to a mean of 4.1% of the interface with a visible radiolucency at 2 years while the retention group increased from 3.4% postoperatively to 28.8% at 2 years (see radiographs on front cover). Both the retention and the removal group showed small migrations, as measured by RSA, with a tendency towards better stability and less scattered results in the removal group. The only significant difference was found concerning change in inclination at 2 years ($p=0.04$). The removal group had stabilized after 1 year in a slightly more vertical position whereas the retention group, from 6 months onwards, slightly but continuously rotated into a more horizontal position (Figure 20). The mean proximal cup migration at 2 years was 0.06 mm for the removal group and 0.12 mm for the retention group ($p=0.12$)(Figure 21). No differences between groups were found in clinical outcome or polyethylene wear.

Conclusions: To optimize the cement-bone interface and thereby increase the long term cup survival, removal of the subchondral bone plate, where possible, appears to be advantageous. It

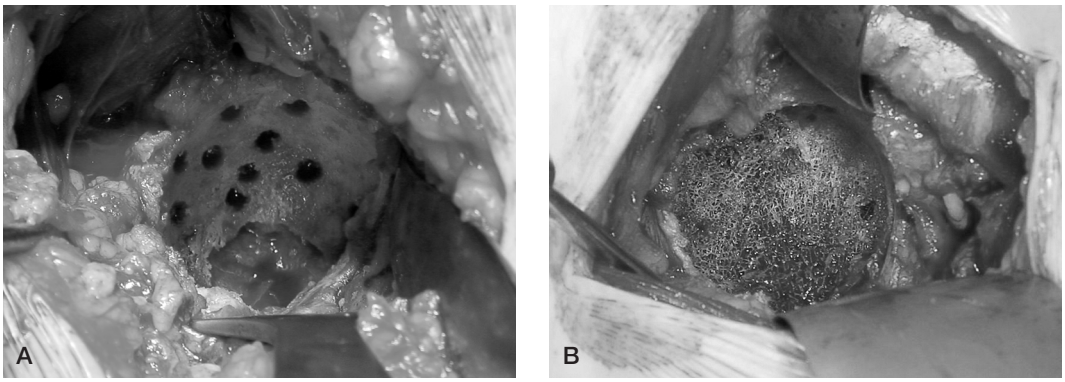

Figure 19. Examples of acetabulum with retention (A) and removal (B) of the subchondral bone plate after reaming.

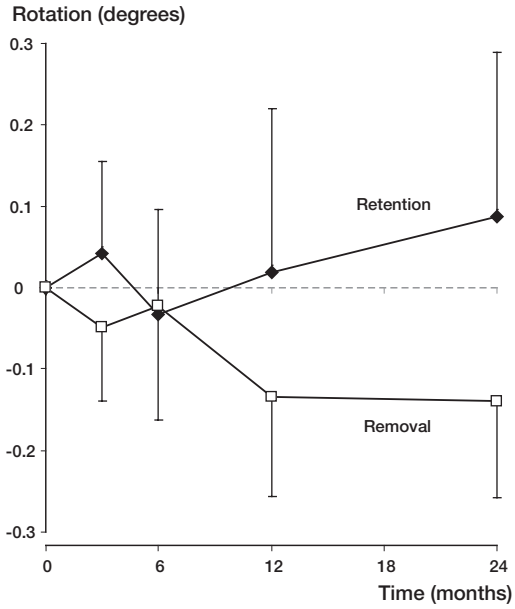

Figure 20. Rotation around the sagittal axis (Z), i.e. changes in cup inclination, up to 2 years. Values are shown as mean with 95% confidence interval.

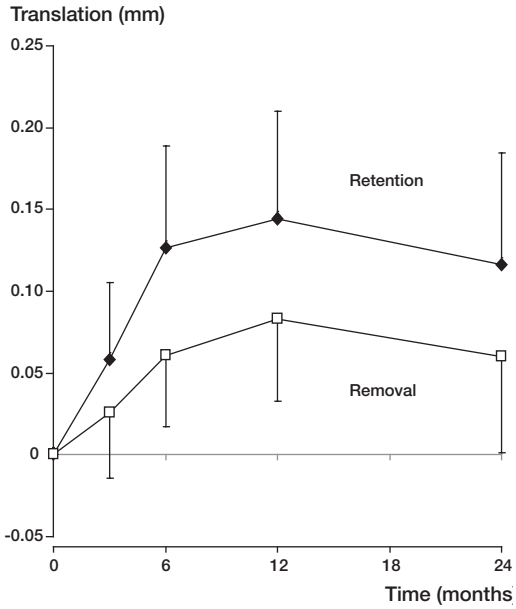

Figure 21. Proximal cup migration (Y-axis) up to 2 years. Values are mean with 95% confidence intervals.

results in a distinct improvement in radiological appearance without, contrary to earlier theories, jeopardizing the cup stability. It should be noted that controlled subchondral bone removal is a more demanding surgical technique.

General discussion

This thesis concerns different aspects of fixation of the cemented acetabular component in THA. Even though the long-term results of this surgery are generally good and there have been continuous improvements in cementing techniques and materials, aseptic loosening of the cemented cup remains a problem. One of the crucial factors for long time survival of the implant is the initial fixation and stability (Kärrholm et al. 1994, Ryd et al. 1995, Stocks et al. 1995, Mjöberg 1997). In the cemented cup, loosening initiates and progresses between the cement and the bone (Schmalzried et al. 1992), whereas loosening between cup and cement, if present, occurs later as a secondary effect. The natural focus of these studies has thus been the integrity of the cement-bone interface and the optimization of conditions for a good and long lasting cement-bone interlock.

Cement penetration and pressure

In *study I,* we could confirm earlier results showing increased cement penetration depth with higher cementation pressures (Rey et al. 1987, Juliusson et al. 1994). Cement penetration interdigitating the cancellous bone between 2–5 mm has been considered optimal to give the cement-bone interface a high tensile and shear strength (Krause et al. 1982, Askew et al. 1984, MacDonald et al. 1993, Majkowski et al. 1993, Mann et al. 1997). To reach this level of penetration into the cancellous bone of the anchorage holes, with intact blood circulation, we found in *study I* that a pressure of at least 0.3 MPa is needed. This *in vivo* study was performed on femoral heads during THA operations as a model for cancellous bone in the hip joint, since for obvious reasons acetabular bone is impossible to use for sectioning and microscopic measurements after surgery is completed. The justification for using this model was established by *study III*, in which no significant differences in permeabilities and structural properties of acetabular and femoral cancellous bone could be found. It is obvious from this and several other studies on cancellous bone from elsewhere in the skeleton that there is a large variation in permeability of the cancellous bone both between different individuals and different locations. Previous studies were performed on either non-human bone (Lim and Hong 2000) or healthy human bone from vertebrae (Ochia and Ching 2002) or calcaneus (Grimm and Williams 1997). The comparatively low permeabilities measured in *study III* may reflect the architecture of the pathologically remodelled bone involved in the osteoarthritis process.

Of interest when discussing cement and bone permeability is also the fact that bone cement is a non-Newtonian fluid, like silicone and linseed oil. Non-Newtonian fluids feature shear-thinning behavior meaning that the viscosity decreases with increasing injection velocity. Hence bone should allow the flow of cement better than our measurements with water in *study III* would indicate.

For the surgeon to produce the high cementation pressures indicated in *study I,* in an acetabulum with a 50 mm diameter and an ideal opening possible to be completely sealed by a pressurizer, a force of almost 600 N must be applied (force (N) = pressure (MPa) × area (mm^2)). This is difficult to achieve for longer than instantaneous moments. Therefore, in *study II* we suggested the use of the sequential cementation procedure which we used in *studies IV* and *V.* The equipment used for this purpose was the injector and the compressor (figures 2 and 3). The rationale for using the sequential technique instead of a conventional cement pressurizer is the difference in ratio between orifice and surface of the small anchorage hole on one hand, and on the other hand the whole acetabulum with its wide opening and large surface area on which the pressure is to be applied. This is simply the law of hydraulics in reverse. Furthermore, it is easier to seal the small anchorage hole than the irregular opening of the acetabulum. However, the sequential procedure may create laminations in the cement, some of which may include blood. It is known from earlier studies that inclusion of blood in the cement mass (Holm 1977, Lee et al. 1978, Saha and Pal 1984) or in laminations created from between 4–6 minutes

after cement mixing (Gruen et al. 1976) reduces the mechanical strength of the bone cement. In *study II,* however, we could show that if the laminations were made within 2-3 minutes from the start of cement mixing there was little or no decrease in strength. If the cement area is kept free from blood or cleansed with saline, the procedure will be feasible for up to 4 minutes. The conclusion is that a sequential cementation procedure, which may be one way to achieve better cement penetration by higher cementation pressure, is permissible from the point of view of cement strength.

In *study IV* we tested the sequential cementation technique in an *in vivo* comparison with pressurization of the cement by a conventional pressurizer. We found a distinct correlation between the early peak cementation pressures and cement penetration into the cancellous bone of the anchorage holes. These peak pressures were higher for the sequential method, and thus cement penetration was significantly improved when sequential cementation was used. All early peak values in the sequential group occurred during the injector phase. The highest peak pressures during the entire cementation procedure were in all cases of both groups achieved later during the cup insertion. However, these late high pressures did not increase the cement penetration any further, probably due to the higher cement viscosity at this stage. The cement will not penetrate any further into the bone but instead take the path of least resistance and escape out of the acetabulum, around the advancing cup, where there is no counterpressure (Beverland et al. 1993, Bernoski et al. 1998). We concluded that good cement penetration should be obtained before cup insertion and that cement can be applied in a rather early phase, provided it is possible to make a closed space of the cavity that is being pressurized. However, the cement cannot be handled at a too early stage, as the low viscosity makes it more difficult to handle and there will be more cement leakage. Furthermore, in an animal study it has been shown that low-viscosity cement gives less penetration than high-viscosity cement (Breusch et al. 2002). The author's explanation was that low-viscosity cement may have a tendency to leak out into the venous system before deeper cement penetration can occur. In addition, the cement may be extruded (pushed out again) by the relatively low intraosseous blood pressure (<30 mmHg) (Benjamin et al. 1987, Shelley and Wroblewski 1988), if it is inserted early and not kept under pressure. This emphasizes the importance of maintaining an adequate pressure on the cement until the increased viscosity can resist displacement. The risk of bone marrow embolism, described for femoral pressurization (Christie et al. 1995), is unlikely to occur in the acetabulum since even our highest pressure recordings were well below the typical values achieved in the femur during pressurization and stem insertion (Davies and Harris 1993, Song et al. 1994, McCaskie et al. 1997, Dozier et al. 2000).

The effect of improved cement pressurization was also evaluated in *study V.* The sequential cementation technique was tested against fingerpacking of the cement prior to cup insertion in a randomized trial. As was the case in *study IV,* we found a significantly deeper cement penetration into the anchorage holes with the sequential pressurization method, something which further proves the importance of cement pressurization before cup insertion. The lower penetration values in *study V* compared to those in *study IV* may be explained by differences in patient cohorts but also by an increased heterogeneity among surgeons, 5 surgeons being involved in *study V* compared to 2 in *study IV*. The sequential technique is more demanding for the surgeon because of the change of cement intrusion devices, handling of the cement in a relatively low-viscosity state, and the risk of the cement being drawn out from the anchorage hole when the injector is withdrawn. Furthermore, the crucial parts of the sequential procedure are being performed in the depth of the acetabulum.

Cup fixation and radiolucency

Measured by RSA the only significant effect in *study V* of the deeper cement penetration was a difference in rotation around the sagittal axis (i.e. change of inclination) between groups. The group with pressurization of the cement stabilized in a slightly more vertical position, whereas the group with only fingerpacking continued to rotate into a more horizontal position. The difference was observed early in the follow-up period and persisted up to 5 years. The most striking result in *study V* was the strong relation between the find-

ings of direct postoperative demarcation around the cup and later migration as shown by RSA. In the group with no demarcation on the initial radiograph, none at 2 years and only 2 out of 17 at 5 years showed signs of migration. In the group with demarcation (>0.3 mm thick) 10 out of 29 at 2 years and 21 out of 27 at 5 years (including the only cup that was revised) were migrating. This study clearly supports previous reports that any demarcation at the cement-bone interface around the cup, observed on immediate postoperative radiographs, is an important prognostic indicator of later loosening. Even a minor radiological demarcation present postoperatively or emerging during the first year has been shown to result in 35–40% radiographical loosening within 10 years (Mulroy and Harris 1990, Hodgkinson et al. 1993, Ranawat et al. 1995, Garcia-Cimbrelo et al. 1997, Ritter et al. 1999). Apparently it is not the width of the gap, but the length of the demarcation that is the most important factor (Hodgkinson et al. 1988, Schmalzried et al. 1992, Garcia-Cimbrelo et al. 1997, Hultmark et al. 2003). Ritter et al (2003) reported on the problems of preventing radiolucency occurring in zone 1. He concludes that despite their attempts over the years, early postoperative zone 1 radiolucency still occurred in between 20–30% of the cases. It was not until they started to ream down through the subchondral bone plate during the acetabular reaming that they got better radiographical and clinical results (Crites et al. 2000). In *study V* we had a high rate of type 1 and type 2 demarcations in both groups according to the Hodgkinson classification. We believe the reason to be the bone preparation technique we used with retention of the subchondral bone plate. With RSA we did not find a significant difference between the groups regarding overall continuous migration, the only proven prognostic RSA indicator of later loosening. For the whole group of patients in *study V* there was a relatively large and slowly continuous proximal migration up to 0.6 mm at 5 years. One could speculate whether the radiolucencies were the reason why the better cement penetration was not born out in the RSA-results as less continuous migration. Possibly the presence of radiolucencies overcame the effect of better penetration in the anchorage holes.

Subchondral bone plate

In *study VI* we evaluated the effect of bone bed preparation by randomizing between retention and removal of the subchondral bone plate in the acetabulum while reaming. In both groups pressurization of the cement was performed in the same manner with a conventional pressurizer. In the literature there are arguments for retaining the subchondral bone plate in order to maintain structural strength of the entire acetabular construct. Removal of the subchondral bone plate could weaken the normal acetabulum. Early 2-D FEA-studies indicated that removal results in higher peak stresses, which in turn would be conducive to micromotion (Jacob et al. 1976, Vasu et al. 1982, Carter et al. 1983). That was the reason why, at introduction of the second generation cementing technique in the early 80-ties, retention of the subchondral bone plate was considered an important part and several reports have later emphasized this importance (Cornell and Ranawat 1986, Weber 1988, Kobayashi and Terayama 1990, Kobayashi et al. 1994, Mulroy et al. 1995, Ziegler and Lachiewicz 1996, Ranawat et al. 1997, Nercessian et al. 2003). In a survey among British orthopedic surgeons 88% claimed that they were retaining the subchondral bone (Hashemi-Nejad et al. 1994). In more recent literature there has been little debate and there remains uncertainty how the subchondral bone plate should be treated during acetabular preparation. An argument against 2-D FEA-models is that they do not account for the out-of-plane sections of the acetabular wall and loads and that the stiffness of the acetabulum is often underestimated (Dalstra 1993). In fact, earlier claims on the advantages of retention of the subchondral bone have also been contradicted by a more recent 2-D FEA study. Sutherland et al. (2000) showed that reducing the stiffness of the cup-cement-bone complex by removal of the subchondral bone plate decreases peak stresses, and the study concluded that subchondral bone retention might not be advantageous. Dalstra (1993) used 3-D FEA and found that increasing the stiffness of the cup-cement-bone-complex resulted in stresses in the underlying bone becoming more concentrated, especially in the periphery, while in the dome area of the acetabulum stress shielding took place. A possible consequence is an increased

risk of interface failure and bone resorption in the dome area. This is probably one of the reasons why metal-backed cemented cups have had higher failure rates (Ritter 1995, Chen et al. 1998) and are now obsolete. Those cups were recommended at the same time and on the same theoretical FEA-based grounds as was retention of the subchondral bone plate (Carter et al. 1983).

The RSA-results of *study VI* give no support for retaining the subchondral bone plate for stability reasons, but rather indicate less early micromotion if the subchondral bone plate is removed. The only statistically significant difference in migration was seen at 2 years for changes in inclination, with the cups in the removal group stabilizing after minimal migration into a more vertical position and the cups in the retention group showing a slight, but from 6 months onwards, a seemingly continuous rotation towards a more horizontal position.

The pattern, with a change towards more cup inclination for the less well-fixed group, as seen in both *studies V* and *VI*, is a new and maybe interesting observation. The migrations, especially in *study VI*, were small but if they are confirmed in further studies or longer follow-ups they may indicate a new insight into the loosening process of acetabular cups. They may represent an RSA finding that corresponds to the presence or absence of the radiolucency in the critical cranial region (i.e. zone 1). A radiolucent line in this region has proven to represent lack of long-term stability (Hodgkinson et al. 1988, Hodgkinson et al. 1993, Ranawat et al. 1995, Garcia-Cimbrelo et al. 1997, Ritter et al. 1999). With the lack of cranial stability the cup will therefore hinge outwards of the acetabulum. Indeed, a parallel pattern can be seen in the results from Thanner et al. (2000) on uncemented cup, with and without screws. The cups with cranial screws showed minute rotation into a more vertical position, while the ones without screws rotated into a more horizontal position. The difference in their study was statistically insignificant.

The radiographical evaluation with zone analysis up to the 2-year follow-up in *study VI* also clearly shows that removal of the subchondral bone plate results in a superior cement-bone interface with less development of radiolucent lines ($p<0.001$). In general there were smaller migrations in *study VI* as compared to *study V,* with an average proximal migration of only 0.09 mm at 2 years. This difference in the magnitude of migrations in *study VI* probably represents the generally better direct postoperative radiographical appearance. From *study VI* we could conclude that by removing the subchondral bone plate we achieved a distinct improvement in longer term (2 years) radiographical appearance without jeopardizing the stability.

Cement–bone interface

The possibility of achieving a secure and stable cement-bone interface is probably reduced when the subchondral bone is retained, as the cancellous bone is only exposed to cement penetration through the anchorage holes, which represent a rather small part of the total acetabular area. On the rest of the acetabular surface there is almost no possibility of penetration and micro-interlock between cement and bone. Here the cement overlies a smooth and hard bone surface, particularly in OA patients. In the case of more open cancellous bone there will be small spikes of cement all over the surface which give the cement-bone interface a much larger surface area and thus a better stress distribution under load per unit of area, even if the cement penetration is less. Hence, the problem of achieving such high pressures as indicated in *studies I* and *IV* over the entire acetabulum may be less crucial. It has been shown that the strength of the cement-bone interface is maximized if as much as possible of the interface consists of bone interdigitated with cement (MacDonald et al. 1993, Mann et al. 1997). Furthermore, Volz and Wilson (1977) tested mechanical stability on cadaver acetabuli and found an increase in failure torque when the subchondral bone was removed. With a larger area of cement penetration it may not be necessary to inject each anchorage hole to get good cement penetration locally. The surgeon may instead aim at closing the acetabular cavity as well as possible and keep a sustained pressure until cup insertion. Cement penetration over the entire acetabular surface probably also results in a better sealed off cement-bone interface.

In direct connection with the surgery, a thin layer of bone necrosis is probably produced over the entire acetabular interface because of the mechanical trauma at reaming, the thermal effect of cement

polymerization and cement monomer toxicity (Mjöberg 1986). When this layer resorbs it is replaced by a thin fibrous membrane (Sew Hoy et al. 1981, Paul and Bargar 1987), which together with the initial cement shrinkage may promote micromovements. When this situation is present in the circumferential periphery, i.e. in zone 1, a gap between the acetabular cavity and the joint space has occurred. A radiolucent line on plain radiographs represents such a gap. This gap opens the interface which then is exposed to the effect of hydrostatic pressure from the joint fluid and inflow of later on produced wear debris. Micromovement and the effect on the interface of fluid pressure from the membrane under loading as well as from the joint may give rise to bone resorption and further fibrous membrane formation (Sew Hoy et al. 1981, Mjöberg 1994, Ryd et al. 1995, Aspenberg and Van der Vis 1998). There has also been a biological process described, starting at a small opening in the periphery with bone resorption and progressive membrane formation towards the dome of the acetabulum due to macrophage mediated inflammatory response to the engulfed wear particles (Schmalzried et al. 1992). Maybe a better sealed interface covering a larger area can resist both the mechanical and the biological processes better and provide a more stable situation for the cement-bone contact to be re-established. Furthermore, if the cement is in contact with the biologically active cancellous bone, supplied with the osteogenetic factors necessary for bone regeneration, the mesenchymal cells of the early interface may differentiate and make a stable long term interface which replaces the initial necrosis. The less vascularized subchondral bone plate may not be equally favorable in these respects. Sew Hoy et al. (1981) could show that in the acetabulum the fibrous membrane was thinnest where the cement-bone interlock was most substantial, and they also hypothesized that micromovement in regions of poor interlock was a significant stimulus to membrane formation. Paul and Bargar (1987) used retention of the acetabular subchondral bone in their experimental arthroplasty study on dogs. They found that after 6 months there was a continuous fibrous membrane in almost all histological sections with direct bone-to-cement contact only in the drilled fixation holes, i.e. where cement had direct contact with cancellous bone.

In the early days of hip arthroplasty, exposure of the cancellous bone was common, but without any cement pressurization and with the use of a central guidance hole that limited the possibility to obtain a closed cavity for cementing. Furthermore, the cups were available only in a small number of sizes and they were probably of suboptimal design and quality of the polyethylene. The limited improvements in cup survival, which after all have been achieved since the introduction of the second generation cementing technique, can probably be accounted for by other improvements in the technique.

Outcome measurements

In both *studies V* and *VI,* we evaluated the clinical outcomes of the patient cohorts by self-administered general health questionnaires, namely SF-36 (*study V*) and SF-12 (*Study VI*) and the hip disease specific WOMAC (*Study VI*) as well as the HHS (*studies V and VI*) which is staff administered. In contrast to some previous reports (Nilsson et al. 1994, Hilding et al. 1997) we could not in either of our two studies demonstrate any correlation between RSA migratory patterns and the subjective outcome of the patients regarding life quality and outcome on hip status. However, as early as 2 and 5 years there are unlikely to appear any major outcome differences, as early loosening of the cup often gives limited or no symptoms. These patient cohorts will continue to be followed, which may reveal a correlation between these outcome parameters and RSA.

Technical consideration

In recent years more convincing evidence has emerged that the technical skill by which an arthroplasty is performed is probably the most crucial factor determining the longevity of the arthroplasty. It should be emphasized that there is a technical risk inherent in removal of the subchondral bone plate, as too much bone may be removed with the aim of exposing the cancellous bone. The surgical technique of removal is undoubtedly more demanding compared to that of retaining the bone plate. The transition zone between remnants of the subchondral bone plate and complete removal is not always obvious. One has to be cautious not to continue with larger and larger reamers, but stop

as soon as an appropriate acetabular rim diameter has been achieved. Thereafter the procedure should continue with a reamer several sizes smaller for local work on the remnants of the subchondral bone plate in order to expose the cancellous bone, which is not always possible to achieve. A critical area in the acetabulum is the upper-lateral periphery (zone 1), where the most sclerotic bone occurs and the cancellous bone is most difficult to expose. It is an advantage if anchorage holes can be located in the periphery, but at the same time that is the most inaccessible area for drilling. This difficulty may be overcome by flexible drills. To compensate in cases of excessive deepening of the acetabulum during reaming, bone chips from the last reamed portion can be placed onto the sclerotic bone in the fossa acetabuli. This procedure also provides a good bed for cement interdigitation even in this area where there is no cancellous bone to be exposed. Furthermore, the graft at the same time seals off the cement escape route under the transverse ligament while the cement is being pressurized.

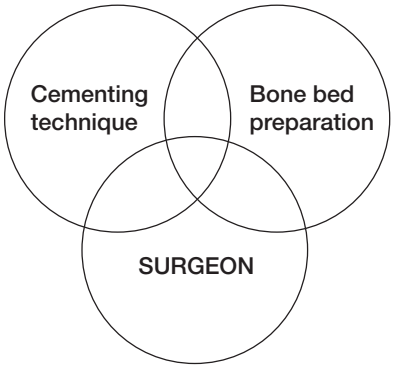

This thesis has shown that to improve the cement-bone interface and thereby increase the long-term cup survival, a high cementation pressure is needed with the appropriate timing and technique both at cementation and at cup insertion. What seems equally important is the bone bed preparation, where removal of the subchondral bone plate, wherever possible, appears to be an advantage. For the overall result, finally, it is up to the surgeon to use the golden opportunity of the primary operation to optimize the surgery so that a revision will hopefully never be needed.

Conclusions

1. High cementation pressure is needed to achieve an adequate cement penetration in the acetabulum, preferably higher than is possible with conventional pressurization devices. An important factor to be considered in the evaluation of penetration studies is the presence or absence of intact blood circulation.

2. In order to improve cement pressurization into the anchorage holes a sequential cementation procedure in the acetabulum is feasible concerning cement strength, provided it is performed within 4 minutes of the start of cement mixing and the cement area is kept free from blood or cleansed with saline.

3. There is no significant difference between cancellous bone from the acetabulum and load-bearing areas of the femoral head in arthrotic hips regarding permeability and structural parameters. Thus results obtained from cement penetration studies on femoral heads are also relevant for conclusions about penetration into acetabular cancellous bone.

4. Cement penetration is most affected by the pressure applied in the early phase of cementation. The high pressures attained in the later phase, during cup insertion, appear to have no further effect. If the cement pressurization can be improved it will result in better cement penetration also under *in vivo* conditions.

5. Increased pressurization of the cement prior to cup insertion gives better cement penetration compared to fingerpacking and has a stabilizing effect on inclination of the cup over time, as measured by RSA. Early radiolucency, even as a thin demarcation line, is a strong predictor of later unfavourable cup migration, all together indicating poor long-term results.

6. Preparation of the acetabular bone bed is an important factor for cup fixation. Contrary to earlier theories, removal of the subchondral bone plate, where possible, appears advantageous. It results in a radiographically superior cement-bone interface, and RSA indicates similar or even better cup stability than after retention of the subchondral bone plate.

Acknowledgments

I would like to express my sincere gratitude to everyone who has been involved in this thesis project, directly or indirectly. In particular I would like to thank:

Leif Ryd, Associate Professor, my supervisor, now head of the Department of Orthopedics, Karolinska University Hospital, for guidance into the field of science and writing, for introducing me to RSA, for never-ending enthusiasm in spite of all engagements and for leading me through the path of this thesis.

Liz Tanner, assistant supervisor, Professor of Biomaterials, Queen Mary University of London, for all the instructive discussions of biomechanics and for invaluable help during manuscript preparation.

All my co-authors for participation and help along the way.

Lars Lidgren, Professor and chairman of Orthopedics, and Harald Roos, Associate Professor, and his precursor Gunnar Hägglund, Associate Professor, as heads of the Department of Orthopedics in Lund, for providing a creative and inspiring working environment on "the 8th floor" and in the labs, and for also letting us discover the orthopedic world outside Lund.

Krister Wulff, Associate Professor, former head of the Department of Orthopedics, Ystad County Hospital, for bringing me into the orthopedic world with an extraordinarily open-minded and non-prestigious attitude, which gave me and others a great chance to develop.

Anders Lindstrand, Associate Professor, head of the Arthroplasty Unit in Lund, for all his encouragement and for giving me opportunities for further development.

Urban Rydholm, Associate Professor, Lund, for his enthusiasm and orthopedic knowledge that got me hooked on orthopedics already as a medical student.

Sten Odenbring, Associate Professor, now at Kristianstad-Hässleholm Hospital, my clinical tutor in Ystad who among other things taught me the importance of seeing the person behind the arthrotic hip.

Kaj Knutson, Associate Professor, Lund, for expert help with the layout of this thesis and for all interesting discussions.

Håkan Leijon and Mark Donnerhall, RSA technicians, for all their work in the RSA-lab and for enjoyable discussions over a cup of coffee.

Maria Palm, secretary, for efficient help with questionnaire paper work and for keeping track of all patients.

Mats Christensson, technician, for his craftsmanship in making prototypes and equipment and fruitful interchange of technical ideas.

My parents, Kent and Lise, for unconditional love and support and for always being there. My father's linguistic feeling has led to many rewarding discussions.

Last but not least my beloved family, Gunilla, Carl and Emma for all their love and for being what really matters.

Grants were received from the Swedish Medical Research Council (project 09509), Stiftelsen för bistånd åt rörelsehindrade i Skåne, Greta and John Kock's stiftelse, Konung Gustav V´s 80-årsfond, Alfred Österlunds stiftelse, Region Skåne and the Medical Faculty of Lund University.

References

Askew M J, Steege J W, Lewis J L, Ranieri J R, Wixson R L. Effect of cement pressure and bone strength on polymethylmethacrylate fixation. J Orthop Res 1984; 1: 412-420.

Aspenberg P, Van der Vis H. Migration, particles, and fluid pressure. A discussion of causes of prosthetic loosening. Clin Orthop 1998; (352): 75-80.

Ballard W T, Callaghan J J, Sullivan P M, Johnston R C. The results of improved cementing techniques for total hip arthroplasty in patients less than fifty years old. A ten-year follow-up study. J Bone Joint Surg Am 1994; 76-A: 959-964.

Bellamy N, Buchanan W W, Goldsmith C H, Campbell J, Stitt L W. Validation study of WOMAC: a health status instrument for measuring clinically important patient relevant outcomes to antirheumatic drug therapy in patients with osteoarthritis of the hip or knee. J Rheumatol 1988; 15: 1833-1840.

Benjamin J B, Gie G A, Lee A J, Ling R S, Volz R G. Cementing technique and the effects of bleeding. J Bone Joint Surg Br 1987; 69-B: 620-624.

Bernoski F P, New A M, Scott R A, Northmore-Ball M D. An in vitro study of a new design of acetabular cement pressurizer. J Arthroplasty 1998; 13: 200-206.

Berry D J, Harmsen W S, Cabanela M E, Morrey B F. Twenty-five-year survivorship of two thousand consecutive primary Charnley total hip replacements: factors affecting survivorship of acetabular and femoral components. J Bone Joint Surg Am 2002; 84-A: 171-177.

Beverland D E, Kernohan W G, Nixon J R, Orr J F, Watson P. Pressurization of bone cement under standard, flanged and custom acetabular components for total hip replacement. Proc Inst Mech Eng [H] 1993; 207: 19-23.

Breusch S, Heisel C, Muller J, Borchers T, Mau H. Influence of cement viscosity on cement interdigitation and venous fat content under in vivo conditions: a bilateral study of 13 sheep. Acta Orthop Scand 2002; 73: 409-415.

Callaghan J J, Albright J C, Goetz D D, Olejniczak J P, Johnston R C. Charnley total hip arthroplasty with cement. Minimum twenty-five-year follow-up. J Bone Joint Surg Am 2000; 82-A: 487-497.

Carter D R, Vasu R, Harris W H. Periacetabular stress distributions after joint replacement with subchondral bone retention. Acta Orthop Scand 1983; 54: 29-35.

Chang R W, Pellisier J M, Hazen G B. A cost-effectiveness analysis of total hip arthroplasty for osteoarthritis of the hip. JAMA 1996; 275: 858-865.

Charnley J. Low friction arthroplasty of the hip. Theory and practice. Springer Verlag, Berlin, 1979.

Chen F S, Di Cesare P E, Kale A A, Lee J F, Frankel V H, Stuchin S A, Zuckerman J D. Results of cemented metal-backed acetabular components: a 10-year-average follow-up study. J Arthroplasty 1998; 13: 867-873.

Christie J, Robinson C M, Singer B, Ray D C. Medullary lavage reduces embolic phenomena and cardiopulmonary changes during cemented hemiarthroplasty. J Bone Joint Surg Br 1995; 77-B: 456-459.

Cornell C N, Ranawat C S. The impact of modern cement techniques on acetabular fixation in cemented total hip replacement. J Arthroplasty 1986; 1: 197-202.

Crites B M, Berend M E, Ritter M A. Technical considerations of cemented acetabular components: a 30-year evaluation. Clin Orthop 2000; (381): 114-119.

Dalstra M. Biomechanical aspects of the pelvic bone and design criteria for acetabular prostheses. Thesis, University of Nijmegen, The Netherlands 1993.

Davies J P, Harris W H. In vitro and in vivo studies of pressurization of femoral cement in total hip arthroplasty. J Arthroplasty 1993; 8: 585-591.

DeLee J G, Charnley J. Radiological demarcation of cemented sockets in total hip replacement. Clin Orthop 1976; (121): 20-32.

Dozier J K, Harrigan T, Kurtz W H, Hawkins C, Hill R. Does increased cement pressure produce superior femoral component fixation? J Arthroplasty 2000; 15: 488-495.

Eftekhar N S, Nercessian O. Incidence and mechanism of failure of cemented acetabular component in total hip arthroplasty. Orthop Clin North Am 1988; 19: 557-566.

Freeman M A, Plante-Bordeneuve P. Early migration and late aseptic failure of proximal femoral prostheses. J Bone Joint Surg Br 1994; 76-B: 432-438.

Garcia-Cimbrelo E, Diez-Vazquez V, Madero R, Munuera L. Progression of radiolucent lines adjacent to the acetabular component and factors influencing migration after Charnley low-friction total hip arthroplasty. J Bone Joint Surg Am 1997; 79-A: 1373-1380.

Grimm M J, Williams J L. Measurements of permeability in human calcaneal trabecular bone. J Biomech 1997; 30: 743-745.

Gruen T A, Markolf K L, Amstutz H C. Effects of laminations and blood entrapment on the strength of acrylic bone cement. Clin Orthop 1976; (119): 250-255.

Harris W H. Traumatic arthritis of the hip after dislocation and acetabular fractures: treatment by mold arthroplasty. An end-result study using a new method of result evaluation. J Bone Joint Surg Am 1969; 51: 737-755.

Hashemi-Nejad A, Birch N C, Goddard N J. Current attitudes to cementing techniques in British hip surgery. Ann R Coll Surg Engl 1994; 76: 396-400.

Havelin L I, Engesaeter L B, Espehaug B, Furnes O, Lie S A, Vollset S E. The Norwegian Arthroplasty Register: 11 years and 73,000 arthroplasties. Acta Orthop Scand 2000; 71: 337-353.

Havelin L I, Espehaug B, Engesaeter L B. The performance of two hydroxyapatite-coated acetabular cups compared with Charnley cups. From the Norwegian Arthroplasty Register. J Bone Joint Surg Br 2002; 84-B: 839-845.

Herberts P, Malchau H, Garellick G. Annual Report 2003. The Swedish National Hip Arthroplasty Register. http://www.jru.orthop.gu.se/archive/AnnualReport-2003-eng.pdf, 1-70. 2004. Ref Type: Internet Communication

Hilding M B, Backbro B, Ryd L. Quality of life after knee arthroplasty. A randomized study of 3 designs in 42 patients, compared after 4 years. Acta Orthop Scand 1997; 68: 156-160.

Hodgkinson J P, Maskell A P, Paul A, Wroblewski B M. Flanged acetabular components in cemented Charnley hip arthroplasty. Ten-year follow-up of 350 patients. J Bone Joint Surg Br 1993; 75-B: 464-467.

Hodgkinson J P, Shelley P, Wroblewski B M. The correlation between the roentgenographic appearance and operative findings at the bone-cement junction of the socket in Charnley low friction arthroplasties. Clin Orthop 1988; (228): 105-109.

Holm N J. The modulus of elasticity and flexural strength of some acrylic bone cements. Acta Orthop Scand 1977; 48: 436-442.

Huiskes R, Slooff T J. Thermal injury of cancellous bone, following pressurized penetration of acrylic cement. Trans Orthop Res Soc 1981; 6: 134.

Hultmark P, Hostner J, Herberts P, Kärrholm J. Radiographic evaluation of Charnley cups used in first-time revision: repeated observations for 7-15 years. J Arthroplasty 2003; 18: 1005-1015.

Jacob H A, Huggler A H, Dietschi C, Schreiber A. Mechanical function of subchondral bone as experimentally determined on the acetabulum of the human pelvis. J Biomech 1976; 9: 625-627.

Juliusson R, Arve J, Ryd L. Cementation pressure in arthroplasty. In vitro study of cement penetration into femoral heads. Acta Orthop Scand 1994; 65: 131-134.

Kärrholm J, Borssen B, Löwenhielm G, Snorrason F. Does early micromotion of femoral stem prostheses matter? 4-7-year stereoradiographic follow-up of 84 cemented prostheses. J Bone Joint Surg Br 1994; 76-B: 912-917.

Kärrholm J, Herberts P, Hultmark P, Malchau H, Nivbrant B, Thanner J. Radiostereometry of hip prostheses. Review of methodology and clinical results. Clin Orthop 1997; (344): 94-110.

Kobayashi S, Eftekhar N S, Terayama K, Iorio R. Risk factors affecting radiological failure of the socket in primary Charnley low friction arthroplasty. A 10- to 20-year followup study. Clin Orthop 1994; (306): 84-96.

Kobayashi S, Terayama K. Radiology of low-friction arthroplasty of the hip. A comparison of socket fixation techniques. J Bone Joint Surg Br 1990; 72-B: 439-443.

Krause W R, Krug W, Miller J. Strength of the cement-bone interface. Clin Orthop 1982; (163): 290-299.

Krismer M, Stockl B, Fischer M, Bauer R, Mayrhofer P, Ogon M. Early migration predicts late aseptic failure of hip sockets. J Bone Joint Surg Br 1996; 78-B: 422-426.

Lee A J, Ling R S, Vangala S S. Some clinically relevant variables affecting the mechanical behaviour of bone cement. Arch Orthop Trauma Surg 1978; (92): 1-18.

Lim T H, Hong J H. Poroelastic properties of bovine vertebral trabecular bone. J Orthop Res 2000; (18): 671-677.

MacDonald W, Swarts E, Beaver R. Penetration and shear strength of cement-bone interfaces in vivo. Clin Orthop 1993; (286): 283-288.

Majkowski R S, Miles A W, Bannister G C, Perkins J, Taylor G J. Bone surface preparation in cemented joint replacement. J Bone Joint Surg Br 1993; 75-B: 459-463.

Malchau H, Herberts P, Garellick G, Söderman P, Eisler T. Prognosis of total hip replacement. Update of results and risk-ratio analysis for revision and re-revision from the Swedish National Hip Arthroplasty Register. Poster at SICOT/SIROT 2002 XXII World Congress, San Diego, USA, August 23-30, 2002.

Malchau H, Herberts P, Ahnfelt L. Prognosis of total hip replacement in Sweden. Follow-up of 92,675 operations performed 1978-1990. Acta Orthop Scand 1993; 64: 497-506.

Mann K A, Ayers D C, Werner F W, Nicoletta R J, Fortino M D. Tensile strength of the cement-bone interface depends on the amount of bone interdigitated with PMMA cement. J Biomech 1997; 30: 339-346.

McCaskie A W, Barnes M R, Lin E, Harper W M, Gregg P J. Cement pressurisation during hip replacement. J Bone Joint Surg Br 1997; 79-B: 379-384.

Mjöberg B. Theories of wear and loosening in hip prostheses. Wear-induced loosening vs loosening-induced wear--a review. Acta Orthop Scand 1994; 65: 361-371.

Mjöberg B. Loosening of the cemented hip prosthesis. The importance of heat injury. Acta Orthop Scand (Suppl 221) 1986: 1-40.

Mjöberg B. The theory of early loosening of hip prostheses. Orthopedics 1997; 20: 1169-1175.

Mulroy R D, Jr., Harris W H. The effect of improved cementing techniques on component loosening in total hip replacement. An 11-year radiographic review. J Bone Joint Surg Br 1990; 72-B: 757-760.

Mulroy W F, Estok D M, Harris W H. Total hip arthroplasty with use of so-called second-generation cementing techniques. A fifteen-year-average follow-up study. J Bone Joint Surg Am 1995; 77-A: 1845-1852.

Mulroy W F, Harris W H. Acetabular and femoral fixation 15 years after cemented total hip surgery. Clin Orthop 1997; (337): 118-128.

Nercessian O A, Joshi R P, Martin G, Su B W, Eftekhar N S. Influence of demographic and technical variables on the incidence of osteolysis in Charnley primary low-friction hip arthroplasty. J Arthroplasty 2003; 18: 631-637.

Nilsson L T, Franzen H, Carlsson A S, Önnerfalt R. Early radiographic loosening impairs the function of a total hip replacement. The Nottingham Health Profile of 49 patients at five years. J Bone Joint Surg Br 1994; 76-B: 235-239.

Noble P C, Swarts E. Penetration of acrylic bone cements into cancellous bone. Acta Orthop Scand 1983; 54: 566-573.

Ochia R S, Ching R P. Hydraulic resistance and permeability in human lumbar vertebral bodies. J Biomech Eng 2002; 124: 533-537.

Odgaard A, Gundersen H J. Quantification of connectivity in cancellous bone, with special emphasis on 3-D reconstructions. Bone 1993; 14: 173-182.

Paul H A, Bargar W L. Histologic changes in the dog acetabulum following total hip replacement with current cementing techniques. J Arthroplasty 1987; 2: 71-76.

Ranawat C S, Deshmukh R G, Peters L E, Umlas M E. Prediction of the long-term durability of all-polyethylene cemented sockets. Clin Orthop 1995; (317): 89-105.

Ranawat C S, Peters L E, Umlas M E. Fixation of the acetabular component. The case for cement. Clin Orthop 1997; (344): 207-215.

Rey R M, Jr., Paiement G D, McGann W M, Jasty M, Harrigan T P, Burke D W, Harris W H. A study of intrusion characteristics of low viscosity cement Simplex-P and Palacos cements in a bovine cancellous bone model. Clin Orthop 1987; (215): 272-278.

Ritter M A. The cemented acetabular component of a total hip replacement. All polyethylene versus metal backing. Clin Orthop 1995; (311): 69-75.

Ritter M A. Acetabular options. J Arthroplasty 2003; 18: 80-81.

Ritter M A, Zhou H, Keating C M, Keating E M, Faris P M, Meding J B, Berend M E. Radiological factors influencing femoral and acetabular failure in cemented Charnley total hip arthroplasties. J Bone Joint Surg Br 1999; 81-B: 982-986.

Ryd L, Albrektsson B E, Carlsson L, Dansgard F, Herberts P, Lindstrand A, Regner L, Toksvig-Larsen S. Roentgen stereophotogrammetric analysis as a predictor of mechanical loosening of knee prostheses. J Bone Joint Surg Br 1995; 77-B: 377-383.

Saha S, Pal S. Mechanical properties of bone cement: a review. J Biomed Mater Res 1984; 18: 435-462.

Schmalzried T P, Kwong L M, Jasty M, Sedlacek R C, Haire T C, O'Connor D O, Bragdon C R, Kabo J M, Malcolm A J, Harris W H. The mechanism of loosening of cemented acetabular components in total hip arthroplasty. Analysis of specimens retrieved at autopsy. Clin Orthop 1992; (274): 60-78.

Selvik G. Roentgen stereophotogrammetry. A method for the study of the kinematics of the skeletal system. Acta Orthop Scand (Suppl 232) 1989: 1-51.

Sew Hoy A L, Hedley A K, Clarke I C, Gruen T A, Amstutz H C, Coster I, Moreland J R. The acetabular cement-bone interface in experimental arthroplasties in dogs. Clin Orthop 1981; (155): 231-243.

Shelley P, Wroblewski B M. Socket design and cement pressurisation in the Charnley low-friction arthroplasty. J Bone Joint Surg Br 1988; 70-B: 358-363.

Song Y, Goodman S B, Jaffe R A. An in vitro study of femoral intramedullary pressures during hip replacement using modern cement technique. Clin Orthop 1994; (302): 297-304.

Stocks G W, Freeman M A, Evans S J. Acetabular cup migration. Prediction of aseptic loosening. J Bone Joint Surg Br 1995; 77-B: 853-861.

Stone J J, Rand J A, Chiu E K, Grabowski J J, An K N. Cement viscosity affects the bone-cement interface in total hip arthroplasty. J Orthop Res 1996; 14: 834-837.

Sutherland A G, D'Arcy S, Smart D, Ashcroft G P. Removal of the subchondral plate in acetabular preparation. Int Orthop 2000; 24: 19-22.

Thanner J, Kärrholm J, Herberts P, Malchau H. Hydroxyapatite and tricalcium phosphate-coated cups with and without screw fixation: a randomized study of 64 hips. J Arthroplasty 2000; 15: 405-412.

Vasu R, Carter D R, Harris W H. Stress distributions in the acetabular region--I. Before and after total joint replacement. J Biomech 1982; 15: 155-164.

Volz R G, Wilson R J. Factors affecting the mechanical stability of the cemented acetabular component in total hip replacement. J Bone Joint Surg Am 1977; 59-A: 501-504.

Ware J E, Jr., Kosinski M, Keller S D. A 12-Item Short-Form Health Survey: construction of scales and preliminary tests of reliability and validity. Med Care 1996; 34: 220-233.

Ware J E, Jr., Sherbourne C D. The MOS 36-item short-form health survey (SF-36). I. Conceptual framework and item selection. Med Care 1992; 30: 473-483.

Weber B G. Pressurized cement fixation in total hip arthroplasty. Clin Orthop 1988; (232): 87-95.

Ziegler B S, Lachiewicz P F. Survivorship analysis of cemented total hip arthroplasty acetabular components implanted with second-generation techniques. J Arthroplasty 1996; 11: 750-756.