



LUND UNIVERSITY

Movement pattern of the Exeter femoral stem: A radiostereometric analysis of 22 primary hip arthroplasties followed for 5 years

Stefansdottir, Anna; Franzén, Herbert; Johnsson, Ragnar; Ornstein, Ewald; Sundberg, Martin

Published in:
Acta Orthopaedica Scandinavica

DOI:
[10.1080/00016470410001169-1](https://doi.org/10.1080/00016470410001169-1)

2004

[Link to publication](#)

Citation for published version (APA):

Stefansdottir, A., Franzén, H., Johnsson, R., Ornstein, E., & Sundberg, M. (2004). Movement pattern of the Exeter femoral stem: A radiostereometric analysis of 22 primary hip arthroplasties followed for 5 years. *Acta Orthopaedica Scandinavica*, 75(4), 408-414. <https://doi.org/10.1080/00016470410001169-1>

Total number of authors:
5

General rights

Unless other specific re-use rights are stated the following general rights apply:

Copyright and moral rights for the publications made accessible in the public portal are retained by the authors and/or other copyright owners and it is a condition of accessing publications that users recognise and abide by the legal requirements associated with these rights.

- Users may download and print one copy of any publication from the public portal for the purpose of private study or research.
- You may not further distribute the material or use it for any profit-making activity or commercial gain
- You may freely distribute the URL identifying the publication in the public portal

Read more about Creative commons licenses: <https://creativecommons.org/licenses/>

Take down policy

If you believe that this document breaches copyright please contact us providing details, and we will remove access to the work immediately and investigate your claim.

LUND UNIVERSITY

PO Box 117
221 00 Lund
+46 46-222 00 00

Movement pattern of the Exeter femoral stem

A radiostereometric analysis of 22 primary hip arthroplasties followed for 5 years

Anna Stefánsdóttir^{1,2}, Herbert Franzén³, Ragnar Johnsson², Ewald Ornstein¹ and Martin Sundberg¹

Departments of Orthopedics, ¹Hässleholm-Kristianstad County Hospital, ²Lund University Hospital, ³Ängelholm County Hospital, Sweden

Correspondence AS: anna.stefansdottir@ort.lu.se

Submitted 03-09-06. Accepted 04-01-13

Background The design of the Exeter stem may facilitate distal migration, but radiostereometric analysis (RSA) studies have been limited to 2 years of follow-up.

Patients and methods We followed migration of the Exeter femoral stems in 22 primary hip arthroplasties for 5 years with RSA.

Results All stems migrated distally and the median migration at 2 years was 1.34 mm, while at 5 years it was 1.77 mm. 7 stems migrated above accuracy between 3 and 5 years. (RSA) evaluation of the cement mantle could be performed in 14 cases, and in 5 slight migration was found. Most of the stems rotated towards retroversion and the median rotation at 2 years was 1.2°, while at 5 years it was 1.6°. We found 1 patient with impending clinical failure but no deviation in the RSA migration pattern, and 1 patient with unstable migration pattern but no clinical symptoms.

Interpretation We found a greater distal migration of the Exeter stem for longer periods of time than seen with other types of cemented implants.

The Exeter femoral stem is double-tapered, polished and has no collar. These features can facilitate distal stem migration within the cement mantle, a phenomenon first noticed on radiographs (Fowler et al. 1988) and later confirmed by radiostereometric analysis (RSA) (Huiskes et al. 1998, Alfaro-Adrián et al. 1999, Ornstein et al. 1999). Low revision rates have been reported for the Exeter prosthesis (Fowler et al. 1988, Havelin et

al. 2000, Williams et al. 2002) and the claim that early migration predicts later failure (Freeman and Plante-Bordeneuve 1994, Kärrholm et al. 1994) has not been confirmed for the Exeter stem. Here, we describe the distal migration and rotations of the Exeter stem in detail, with special emphasis on the interfaces at which the distal migration takes place and on what happens after the second year. To our knowledge, RSA studies with follow-up longer than 2 years have not been published.

Patients and methods

Patients

We intended to study 24 patients who were younger than 75 years with non-inflammatory hip arthritis, no prior hip surgery and who were in category A or B according to Charnley's (1979) classification. 2 patients had to be excluded due to uncertain RSA measurements, leaving 13 men and 9 women with a median age of 63 (33–74) years. The diagnosis was primary osteoarthritis in 19 hips, osteoarthritis secondary to avascular necrosis of the femoral head in 2 and secondary to Perthe's disease in 1 hip. Informed consent was obtained from each patient.

Surgical method

The operations were performed by one surgeon, with a posterolateral approach without osteotomy of the greater trochanter and using Exeter Uni-

versal instruments. Prechilled Palacos bone cement containing gentamicin was used with modern cement technique. Low-molecular weight heparin was given for 10 days.

One patient was diagnosed with a deep vein thrombosis 10 days after operation, and another patient was diagnosed with a deep vein thrombosis and lung embolism 19 days after operation. Both had an uneventful recovery after appropriate treatment.

RSA

To enable RSA follow-up according to the Selvik method (Selvik 1989, Kärrholm et al. 1997), we used stems marked with 0.8-mm tantalum balls at the proximal shoulder and distal tip. Balls were also implanted in the greater and lesser trochanters and in the medioproximal part of the cement mantle. The initial RSA examination was performed median 2 (1–4) days after surgery when most patients had been mobilized. RSA was then performed at 4 months, and after 1, 2, 3, and 5 years. At 4 months, 1 RSA examination could not be used due to uncertain measurement and 1 film was lost after 3 years. As the tantalum balls in the cement mantle were close to each other and to the stem, they could be difficult to visualize and measurements of the cement mantle could therefore only be performed in 12 cases at 4 months, in 14 cases at 1 and 2 years, and in 11 cases at 3 and 5 years.

We calculated the accuracy of the RSA method by repeat examinations of 19 patients at the initial RSA. The movement between these double examinations, expected to be zero within pairs, and the standard deviation ($SD = \sqrt{(\sum d^2)/(n-1)}$) for each direction of movement was calculated. Using the Student's *t* distribution, the 99% confidence limits for the smallest significant movement in each direction were determined. The results presented are segment movements.

Radiographs

Conventional radiographs were taken on the same

Table 1. Accuracy of RSA determined by 19 double examinations

	SD for the errors of measurement	Smallest significant movement ^a	Chosen level of significant movement (accuracy)
Distal migration (mm)			
stem relative to femur	0.055	0.138	0.2
cement relative to femur	0.062	0.165	0.2
Stem rotation (degree)			
-retroversion/anteversion	0.221	0.557	0.6
-valgus/varus	0.048	0.120	0.2
-anterior/posterior	0.170	0.429	0.5
^a 99% confidence limits according to Student's <i>t</i> -test			

occasion as RSA. The radiographic evaluation included assessment of stem alignment, cement mantle defects, cement fractures, radiolucent lines, localized endosteal femoral lysis, and cortical hypertrophy. Distal migration was measured on radiographs as the distance from the tip of the stem to the bottom of the hollow centralizer. At the time of evaluation, radiographs from 1 occasion were missing.

Clinical assessment

The clinical result was evaluated with the Charnley (1979) hip score.

Statistics

As the parameters were not normally distributed on most occasions, we used nonparametric methods. The Wilcoxon matched pairs signed rank sum test was used to compare movement on different occasions. Spearman rank correlation test was used to assess correlation.

Results

Accuracy

The 19 double examinations were used to calculate levels of significant migration and rotation of the stem. Measured migration of the stem and cement relative to bone was considered significant being at least 0.2 mm. Measured rotation towards retro- or anteversion was considered significant being at least 0.6°, towards valgus or varus at least 0.2° and in anterior or posterior direction at least 0.5° (Table 1).

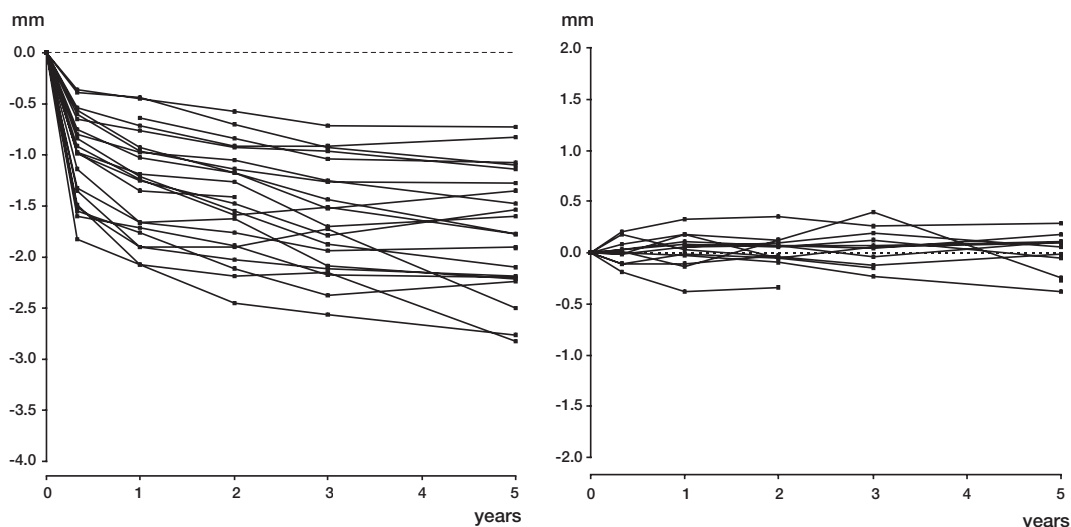


Figure 1. A. Distal migration of 22 Exeter stems relative to the femur. Accuracy 0.2 mm.

B. Distal and proximal migration of 14 cement mantles relative to the femur. Accuracy 0.2 mm.

Table 2. Distal migration of the stems and cement mantles relative to femur, in mm. Wilcoxon matched pairs signed rank sum test was used to compare migration with the preceding observation

	Stem				Cement			
	n	median (mm)	95% CI	migration > 0.2 mm (n)	n	median (mm)	95% CI	migration > 0.2 mm (n) distal/ proximal
4 months	21	-0.98 ^a	-1.20 to -0.81	21	12	0.00 ^c	-0.06 to 0.08	0 / 1
1 year	22	-1.23 ^a	-1.49 to -1.04	15	14	0.02 ^c	-0.07 to 0.11	0
2 years	22	-1.34 ^a	-1.64 to -1.12	8	14	0.06 ^c	-0.06 to 0.11	1 / 1
3 years	21	-1.52 ^b	-1.79 to -1.17	10	11	0.06 ^c	-0.07 to 0.18	2 / 0
5 years	22	-1.77 ^c	-2.01 to -1.48	8 ^d	11	0.06 ^c	-0.15 to 0.12	0 / 2

^a $p < 0.001$
^b $p = 0.03$
^c $p > 0.05$
^d 1 in proximal direction

Distal migration

All 22 stems migrated distally relative to the femur (Figure 1A) and a major part of the migration occurred within the first 4 months after surgery (Table 2). 7 stems still migrated distally above accuracy (0.2 mm) between 3 and 5 years. No correlation was found between weight and the distal migration of the stem relative to the femur at 2 and 5 years (Spearman's $\rho = -0.34$ and -0.39 , $p = 0.1$).

5 cement mantles migrated slightly above accuracy (0.2 mm) on some occasion during the study

period. One had migrated proximally 0.20 mm at 4 months, and was thereafter stable. 3 cement mantles migrated distally (0.23–0.38 mm), the migration value reaching above accuracy after 1, 3 and 5 years. At 3 years, one cement mantle had migrated 0.39 mm proximally and then migrated 0.64 mm in distal direction (Figure 1B).

Rotation

Most stems rotated towards retroversion and most of the retroversion occurred during the first year

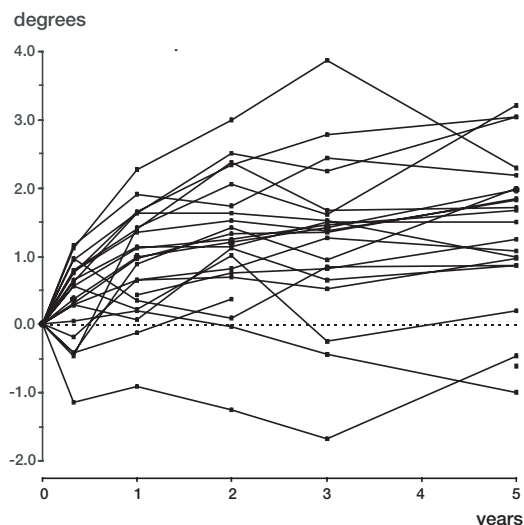
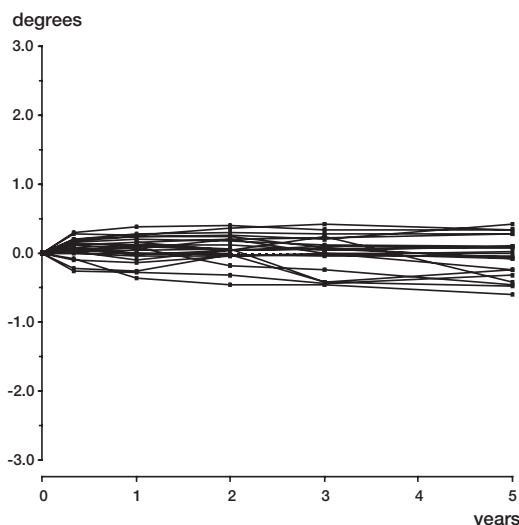
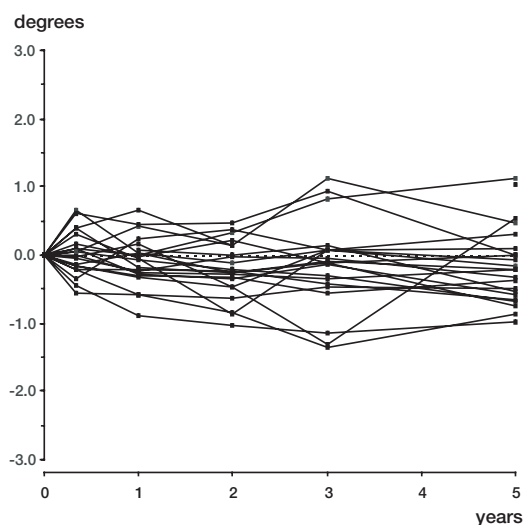


Figure 2. A. Rotation of 22 Exeter stems towards retroversion (+) and anteversion (-). Accuracy 0.6 degrees.



B. Rotation of 22 Exeter stems towards valgus (+) and varus (-). Accuracy 0.2 degrees.



C. Rotation of 22 Exeter stems anteriorly (+) and posteriorly (-). Accuracy 0.5 degrees.

after surgery (Figure 2A). 4 stems rotated towards retroversion above accuracy (0.6°) between 3 and 5 years. Table 3 shows the median retroversion. We found a correlation between distal migration and rotation towards anteversion/retroversion at 2 years (Spearman's $\rho = -0.46$, $p = 0.03$) but not on the other occasions of measurement.

At 5 years, 7 stems had tilted towards varus above accuracy (0.2°) up to 0.6° and 5 stems had

Table 3. Retroversion (+) and anteversion (-) of the stems relative to the femur, in degrees. Wilcoxon matched pairs signed rank sum test was used to compare rotation with the preceding observation

	n	Median	95% CI	> 0.6° retroversion/ anteversion
4 months	21	0.6 ^a	0.3–1.0	9 / 1
1 year	22	1.0 ^a	0.3–1.6	11 / 1
2 years	22	1.2 ^b	0.7–1.7	7 / 0
3 years	21	1.4 ^c	0.8–1.6	3 / 2
5 years	22	1.6 ^c	1.0–2.2	4 / 1

^a $p < 0.001$
^b $p = 0.004$
^c $p > 0.05$

tilted towards valgus up to 0.4° (Figure 2B). The median varus/valgus rotation at 2 years was 0.1° (95% CI 0.0 to 0.3) and at 5 years it was 0.0° (95% CI -0.2 to 0.1). Between 3 and 5 years, 1 stem had tilted 0.7° towards varus.

At 5 years, 3 stems had tilted anteriorly above accuracy (0.5°) up to 1.1° and 7 had tilted posteriorly up to 1.0° (Figure 2C). The median anterior/posterior rotation at 2 years was -0.2° (95% CI -0.5 to 0.1) and at 5 years -0.2° (95% CI -0.6 to 0.3). Between 3 and 5 years, 1 stem had tilted

Table 4. Distal migration of different types of cemented femoral stem at 2 years after primary arthroplasty, measured by RSA

Type of implant	mm	n	Type of migration measured	Index examination	Type of cement	Author	Year
Exeter	1.20 ^b	14	tip of stem	1–2 weeks	CMW	Alfaro–Adrián et al.	1999
Charnley Elite	0.38 ^b	12	tip of stem	1–2 weeks	CMW	Alfaro–Adrián et al.	1999
Charnley	0.40 ^c	62	center of femoral head	1 week	Palacos	Önsten et al.	1995
Lubinus SP2	0.1 ^a	20	center of stem	4–8 days	not reported	Nivbrant et al.	1999
Tifit	0.13 ^a	20	center of stem	7–10 days	not reported	Kärrholm et al.	1998
SHP	0.7 ^a	19	center of stem	4–8 days	not reported	Nivbrant et al.	1999

^a median^b mean^c mean for the 22 stems with detectable migration

anteriorly from -1.3° to 0.6° . This stem rotated most towards retroversion, 3.9° at 3 years and 2.3° at 5 years, and tilted towards varus between 3 and 5 years, from 0.3° to -0.4° . It migrated distally 0.78 mm between 3 and 5 years and the cement mantle was unstable, showing proximal migration at 3 years and distal migration of 0.64 mm thereafter.

Radiographic analysis

18 stems were aligned between 2° valgus and 2° varus. 4 stems were aligned $3-4^{\circ}$ varus. Cement filling defects were found in three hips postoperatively and in one of these localized endosteal bone lysis, as defined by Sporer et al. (1999), had developed at 5 years. The changes were multilobular and situated anterolaterally in Gruen regions 3 and 10, with extension into regions 2 and 9, and measured 3.7×1.1 cm on the anteroposterior radiograph and 3.0×0.6 mm on the lateral. The patient experienced thigh-pain after activity, but the migration pattern according to RSA did not deviate from the others. No cement fractures were seen. A radiolucent line in region 1 was a common finding and at 5 years it was seen in 17/22 hips. Cortical hypertrophy was seen in 2 asymptomatic cases. A significant correlation was found between radiographic measurement of distal migration and RSA-measured distal migration at 2 and 3 years (Spearman's $\rho = -0.49$ and -0.52 , $p = 0.04$), but not at 5 years.

Clinical evaluation

Preoperatively, the average Charnley score for pain

was 2.2 (SD 1.0), function 3.0 (SD 1.4) and ROM 3.8 (SD 0.7). At 1 year, the average score for pain was 5.8 (SD 0.6), function 5.7 (SD 1.5) and ROM 5.0 (SD 1.1). At 5 years, the average score for pain was 5.8 (SD 0.5), function 6.0 (SD 0.0) and ROM 5.0 (SD 0.4).

Discussion

The distal migration we found was larger than reported in previous RSA studies on cemented primary hip arthroplasties (Önsten et al. 1995, Kärrholm et al. 1997, Alfaro-Adrián et al. 1999, Nivbrant et al. 1999). Table 4 shows the distal migration at 2 years for different types of cemented stem. The time of index examination influences the results of RSA (Ornstein et al. 2000), and several other differences in methodology can complicate comparison. In 12 of 14 cases, the cement mantle was initially stable (over the first 2 years) and we conclude that the distal migration of the Exeter stem mainly occurs within the cement mantle. One third of the stems in our study still migrated distally above accuracy between 3 and 5 years. How much a stem can migrate distally without failing, and for how long, remain unanswered questions.

When comparing the performance of different types of stem, migration is just one consideration. Shape and surface finish are other important considerations. It has been stated that the distal migration of the Exeter stem is beneficial because radial compressive forces are created in the adja-

cent cement and transferred to bone as hoop stress (Shen 1998), and the stem-cement interface is sealed off, preventing access of fluid from the joint space (Williams et al. 2002).

The median retroversion at 2 years was comparable to the mean 1.1° retroversion reported by Alfaro-Adrián et al. (2001) in their study of Exeter stems, but lower than the 1.7° median retroversion reported by Kärrholm et al. (2000). For Charnley Elite, a mean retroversion of 1.3° has been reported at 2 years (Alfaro-Adrián et al. 2001). For Lubinus SPII, a 0.2° median retroversion has been reported (Nivbrant et al. 1999), and for Spectron EF, a median retroversion from 0.1° to 0.6° in different series was reported by Kärrholm et al. (2000).

The rotational tilt towards varus/valgus was small, and our results are contrary to the view that when a change in alignment occurs with distal migration, it is towards valgus (Fowler et al. 1988).

RSA did not detect the one case with impending clinical failure. One possible failure mechanism in this case may have been a cement filling defect becoming filled with fluid from the joint and then, with time, the pressure inducing osteolysis (Huddleston 1988, Robertsson et al. 1997). If this mechanism is true, then there is a limit to how forgiving the system would be, that is, how securely the distal migration seals the stem-cement interface. In one case, wobbling became apparent after the second year. This patient was asymptomatic at the most recent follow-up, and the radiographs revealed no abnormalities. Time will show whether this mid-term instability is a predictor of loosening and failure.

The migration of the Exeter stem cannot be measured reliably on radiographs, even though it is possible to gain some idea of the magnitude of distal migration by measuring the distance from the tip of the stem to the bottom of the hollow centralizer after 2 and 3 years.

In summary, we have described the migration pattern of the Exeter femoral stem up to 5 years after operation, and have found greater distal migration than seen with other types of cemented implant and for longer periods of time than previously described. The distal migration occurred mainly inside the cement mantle together with rotation towards retroversion that was equal

(Charnley) or larger (Lubinus SPII and Spectron) than has been reported for other types of implant. A minority of the stems rotated towards varus/valgus and anteriorly/posteriorly. It seems uncertain whether RSA can predict later failure in the case of the Exeter stem. It has, however, added to our understanding of the biomechanical behavior of the Exeter stem.

We wish to thank Agneta Nilsson and her colleagues for taking all the radiographs necessary for RSA, and Håkan Leijon for computerizing them.

No competing interests declared.

- Alfaro-Adrián J, Gill H S, Murray D W. Cement migration after THR. A comparison of Charnley Elite and Exeter femoral stems using RSA. *J Bone Joint Surg (Br)* 1999; 81 (1): 130-4.
- Alfaro-Adrián J, Gill H S, Murray D W. Should total hip arthroplasty femoral components be designed to subside? A radiostereometric analysis study of the Charnley Elite and Exeter Stems. *J Arthroplasty* 2001; 16 (5): 598-606.
- Charnley J. Low friction arthroplasty of the hip. Springer-Verlag, New York 1979.
- Fowler J L, Gie G A, Lee A J C, Ling R S M. Experience with the Exeter total hip replacement since 1970. *Orthop Clin North Am* 1988; 19 (3): 477-89.
- Freeman M A R, Plante-Bordeneuve P. Early migration and late aseptic failure of proximal femoral prostheses. *Bone Joint Surg (Br)* 1994; 76 (3): 432-8.
- Havelin L I, Engesaeter L B, Espehaug B, Furnes O, Lie S A, Vollset S E. The Norwegian Arthroplasty Register. 11 years and 73,000 arthroplasties. *Acta Orthop Scand* 2000; 71 (4): 337-53.
- Huddleston H D. Femoral lysis after cemented hip arthroplasty. *J Arthroplasty* 1988; 3: 285-97.
- Huiskes R, Verdonschot N, Nivbrant B. Migration, stem shape, and surface finish in cemented total hip arthroplasty. *Clin Orthop* 1998; (355): 103-12.
- Kärrholm J, Borssén B, Löwenhielm G, Snorrason F. Does early micromotion of femoral stem prostheses matter? 4-7 year stereoradiographic follow-up of 84 cemented prosthesis. *J Bone Joint Surg (Br)* 1994; 76 (6): 912-7.
- Kärrholm J, Herberts P, Hultmark P, Malchau H, Nivbrant B, Thanner J. Radiostereometry of hip prostheses. Review of methodology and clinical results. *Clin Orthop* 1997; (344): 94-110.
- Kärrholm J, Nivbrant B, Thanner J, Anderberg C, Börlin N, Herberts P, Malchau H. Radiostereometric evaluation of hip implant design and surface finish. Micromotion of cemented femoral stems. Scientific exhibition presented at the 67th Annual meeting of the American Academy of Orthopaedic Surgeons, March 15-19, 2000, Orlando, USA.

- Nivbrant B, Kärrholm J, Söderlund P. Increased migration of the SHP prosthesis. Radiostereometric comparison with the Lubinus SP2 design in 40 cases. *Acta Orthop Scand* 1999; 70 (6): 569-77.
- Ornstein E, Franzén H, Johnsson R, Löfqvist T, Stefánsdóttir A, Sundberg M. Early subsidence of the Exeter femoral stem within the cement mantle in primary arthroplasties and in revisions using impacted allografts and cement: a roentgen stereophotogrammetric analysis. *Hip International* 1999; 9 (3): 139-43.
- Ornstein E, Franzén H, Johnsson R, Sundberg M. Radiostereometric analysis in hip revision surgery - optimal time for index examination. *Acta Orthop Scand*, 2000; 71 (4): 360-4.
- Robertsson O, Wingstrand H, Kesteris U, Jonsson K, Önnarfält R. Intracapsular pressure and loosening of hip prostheses. Preoperative measurements in 18 hips. *Acta Orthop Scand* 1997, 68; 231-4.
- Selvik G. Roentgen stereophotogrammetry. A method for the study of the kinematics of the skeletal system. *Acta Orthop Scand (Suppl 232)* 1989; 232: 1-51.
- Shen G. Femoral stem fixation. An engineering interpretation of the long-term outcome of Charnley and Exeter stems. *J Bone Joint Surg (Br)* 1998; 80 (5): 754-6.
- Sporer S M, Callaghan J J, Olejniczak J P, Goetz D D, Johnston R C. The effects of surface roughness and polymethylmethacrylate precoating on the radiographic and clinical results of the Iowa hip prosthesis. *J Bone Joint Surg (Am)* 1999; 81 (4): 481-92.
- Williams H D W, Browne G, Gie G A, Ling R S M, Timperley A J, Wendover N A. The Exeter universal cemented femoral component at 8 to 12 years. A study of the first 325 hips. *J Bone Joint Surg (Br)* 2002; 84 (3): 324-34.
- Önsten I, Åkesson K, Besjakov J, Obrant K J. Migration of the Charnley stem in rheumatoid arthritis and osteoarthritis. A roentgen stereophotogrammetric study. *J Bone Joint Surg (Br)* 1995; 77 (1): 18-22.