



LUND UNIVERSITY

Ictal SPECT in clinical perisylvian syndrome.

Ahnlide, Jan Anders; Rosén, Ingmar; Källén, Kristina; Geijer, B

Published in:
Acta Neurologica Scandinavica

DOI:
[10.1046/j.1600-0404.2003.00225.x](https://doi.org/10.1046/j.1600-0404.2003.00225.x)

2004

[Link to publication](#)

Citation for published version (APA):

Ahnlide, J. A., Rosén, I., Källén, K., & Geijer, B. (2004). Ictal SPECT in clinical perisylvian syndrome. *Acta Neurologica Scandinavica*, 109(4), 280-283. <https://doi.org/10.1046/j.1600-0404.2003.00225.x>

Total number of authors:
4

General rights

Unless other specific re-use rights are stated the following general rights apply:

Copyright and moral rights for the publications made accessible in the public portal are retained by the authors and/or other copyright owners and it is a condition of accessing publications that users recognise and abide by the legal requirements associated with these rights.

- Users may download and print one copy of any publication from the public portal for the purpose of private study or research.
- You may not further distribute the material or use it for any profit-making activity or commercial gain
- You may freely distribute the URL identifying the publication in the public portal

Read more about Creative commons licenses: <https://creativecommons.org/licenses/>

Take down policy

If you believe that this document breaches copyright please contact us providing details, and we will remove access to the work immediately and investigate your claim.

LUND UNIVERSITY

PO Box 117
221 00 Lund
+46 46-222 00 00

Ictal SPECT in clinical perisylvian syndrome

Ahnlide JA, Källén K, Geijer B, Rosén I. Ictal SPECT in clinical perisylvian syndrome.
Acta Neurol Scand 2004; 109: 280–283. © Blackwell Munksgaard 2003.

In the congenital bilateral perisylvian syndrome, pseudobulbar symptoms, cognitive deficits and cortical malformations in the perisylvian region are typical features. We report two initially magnetic resonance imaging (MRI) negative patients from our epilepsy surgery program that shared the same seizure and ictal SPECT characteristics suggesting seizure onset localized in the perisylvian region. In one patient, reevaluation revealed perisylvian cortical malformation on MRI while in the other patient MRI was normal. In these patients, subtraction ictal SPECT coregistered with MRI (SISCOM) proved useful together with clinical data in diagnosing the patients with mild forms of perisylvian syndrome.

**J. A. Ahnlide¹, I. Rosén¹,
K. Källén², B. Geijer³**

¹Division of Clinical Neurophysiology, Department of Clinical Neuroscience, Departments of ²Neurology and Clinical Neuroscience, and ³Diagnostic Radiology, Lund University Hospital, Lund, Sweden

Key words: perisylvian syndrome; ictal SPECT; magnetic resonance imaging

Jan Anders Ahnlide, Department of Clinical Neurophysiology, Lund University Hospital, SE-22185 Lund, Sweden
E-mail: jan_anders.ahnlide@knflab.lu.se

Accepted for publication September 3, 2003

The congenital bilateral perisylvian syndrome (CBPS) is a neuronal migration disorder where pseudobulbar symptoms, cognitive deficits and cortical malformations in the perisylvian region are typical features. Thirty-one patients with congenital bilateral perisylvian syndrome reported by Kuzniecky et al. showed bilateral perisylvian cortical malformations on imaging studies (1). However, it is possible that in milder forms the malformation is not detectable with magnetic resonance imaging (MRI).

Epilepsy is present in the majority of cases of CBPS (2, 3). Subtraction ictal SPECT coregistered with MRI (SISCOM) accurately localizes information in the epileptogenic region (4). The method superimposes functional information on brain anatomy in three-dimensional MRI images. In selected cases, the technique does not only confirm results already visualized by other localizing techniques, but it also adds information of diagnostic value, which is illustrated by the two cases reported.

Materials and methods

Two patients were referred to our epilepsy surgery group for evaluation. Extracranial video-electroencephalography (EEG)-monitoring and MRI were performed in accordance with the protocol for intractable epilepsy. As there initially was no MRI-verified focal lesion convergent with the EEG-findings, the patients were further investigated with ictal SPECT coregistered with MRI.

Patient 1

A 21-year-old male, with epilepsy onset at age 13, had seizures characterized by peri-oral stiffness and speech difficulties because of impaired articulation, and an average seizure frequency of 1–5 per day. Seizures evolved to bilateral asymmetric tonic arm seizures and right or left head version, infrequently followed by generalized tonic-clonic seizures. Neurological performance was normal, with no speech impairment, dysarthria or signs of pseudobulbar palsy. Neuropsychological assessment showed cognitive functions within normal limits. Interictal EEG showed independent right or left temporal sharp waves, ictal EEG showed a non-localizable pattern with bilateral rhythmic theta waves at seizure onset. No cortical abnormalities were observed in the coronal magnetization-prepared rapid acquisition gradient echo (MP-RAGE) images.

Patient 2

A 20-year-old unemployed male with 12 years of education, had an epilepsy disorder diagnosed at 9 years of age. Seizure onset was characterized by a strange feeling in the mouth and tongue and inability to speak, followed by oral stiffness and drooling, evolving to bilateral asymmetric tonic seizures with frequent falls with injuries. The average seizure frequency was 10–12 times per day. Neurological examination showed mild dysarthria with slow speech and slightly impaired tongue-wiggling

capacity. Neuropsychological assessment showed impaired speed of problem solving, slightly impaired verbal memory and executive functions. Interictal EEG showed infrequent left-sided front-temporal sharp waves; ictal EEG showed rhythmic theta activity 10 s after clinical onset with maximum amplitude over the left posterior temporal region. MRI performed in accordance with the standard protocol for intractable epilepsy was normal.

Ictal SPECT

EEG monitoring was performed using a 32-channel digital EEG-system with synchronized video recording. Electrodes were placed according to the international 10–20-system with extended electrode coverage in the subtemporal region.

During EEG monitoring the monitoring nurse injected the radioisotope ^{99m}Tc -Exametazine stabilized with cobalt chloride immediately upon detecting a clinical seizure onset. Using synchronized video recording the temporal relation between injection and the onset of seizure activity and the seizure duration were recorded. The procedure was considered valid if injection was started after onset and before termination of clinical seizure symptoms, and if simultaneous seizure activity was recorded in EEG.

At least 24 h after the seizure an interictal ^{99m}Tc -Exametazine SPECT scan was obtained with simultaneous EEG recording. The SPECT images were recorded using a brain dedicated annular detector system (Ceraspect, Digital Scintigraphics Inc., Waltham, MA, USA) with a spatial resolution of 7 mm (FWHM). After scatter correction attenuation correction was applied with Chang-filtering (15%/cm) and a three-dimensional volume was constructed, suitable for coregistration with MRI. Ictal SPECT was performed during the patients' habitual seizures. In patient number one, the seizure lasted for 1 min and 5 s and the tracer was injected 30 s after clinical onset. In patient number two, the seizure lasted for 30 s and the tracer was injected 25 s after onset.

MRI

The MRI examinations were performed with a 1.5 T Siemens Magnetom Vision (Siemens, Erlangen, Germany). A special MRI protocol for examination of patients with drug-resistant epilepsy was used. This protocol consists of the following sequences: axial T1-weighted, T2-weighted images and FLAIR images, coronal 2D-FLASH (sensitive to minute amounts of hemosiderine), T1-weighted 3D MP-RAGE images (coronal acquisition) and

after contrast injection axial and coronal T1-weighted images. The high-resolutive 3D MP-RAGE sequence is suitable for discrimination between gray and white matter and provides a voxel size of $0.9 \times 0.9 \times 1.3$ mm. The coronal slices were positioned orthogonal to the hippocampus.

Subtraction SPECT and coregistration with MRI

The ictal and interictal SPECT image were coregistered using a surface matching technique (Analyze AVW, Mayo Clinic, Rochester, MN, USA). The images were normalized and the interictal image was subtracted from the ictal image. The cortical surface was defined from the MR image using a morphologic method (Analyze AVW) and the interictal image was coregistered with the patients' 3D-MPRAGE image using the surface matching technique above, generating a transformation matrix that was used to transform the difference image. To measure the statistical deviation from the normal random intensity difference between the images the standard deviation of the difference image was calculated in each cerebral hemisphere (excluding cerebellum), using volumes defined in the MR image and a mass significance (Bonferroni) correction based on a cubic voxel with 7 mm side was applied. The SD of the hemisphere with the least variance was used as normal reference. Thus, in the resulting statistical map voxels with values more than 3.5 times the reference SD were regarded as statistically significant.

Results

Patient 1

Subtraction images showed a marked ictal hyperperfusion (5.1 SD) in the left perisylvian region and a mild hyperperfusion in the corresponding region on the right side (Fig. 1B). Apart from a bilateral cerebellar hyperperfusion, no other significant hyperperfusion was seen. At reevaluation of the MRI examination, areas of cortical dysplasia outlining the Sylvian fissures bilaterally were identified (Fig. 1A). The Sylvian fissures were extended to the parietal regions. The MRI findings were consistent with a bilateral perisylvian syndrome.

Patient 2

Subtraction images showed a hyperperfusion (3.9 SD) in the left perisylvian region (Fig. 1D,F) and a mild hyperperfusion in the corresponding region on the right side. There was also a hyperperfusion in the left thalamus and a mild

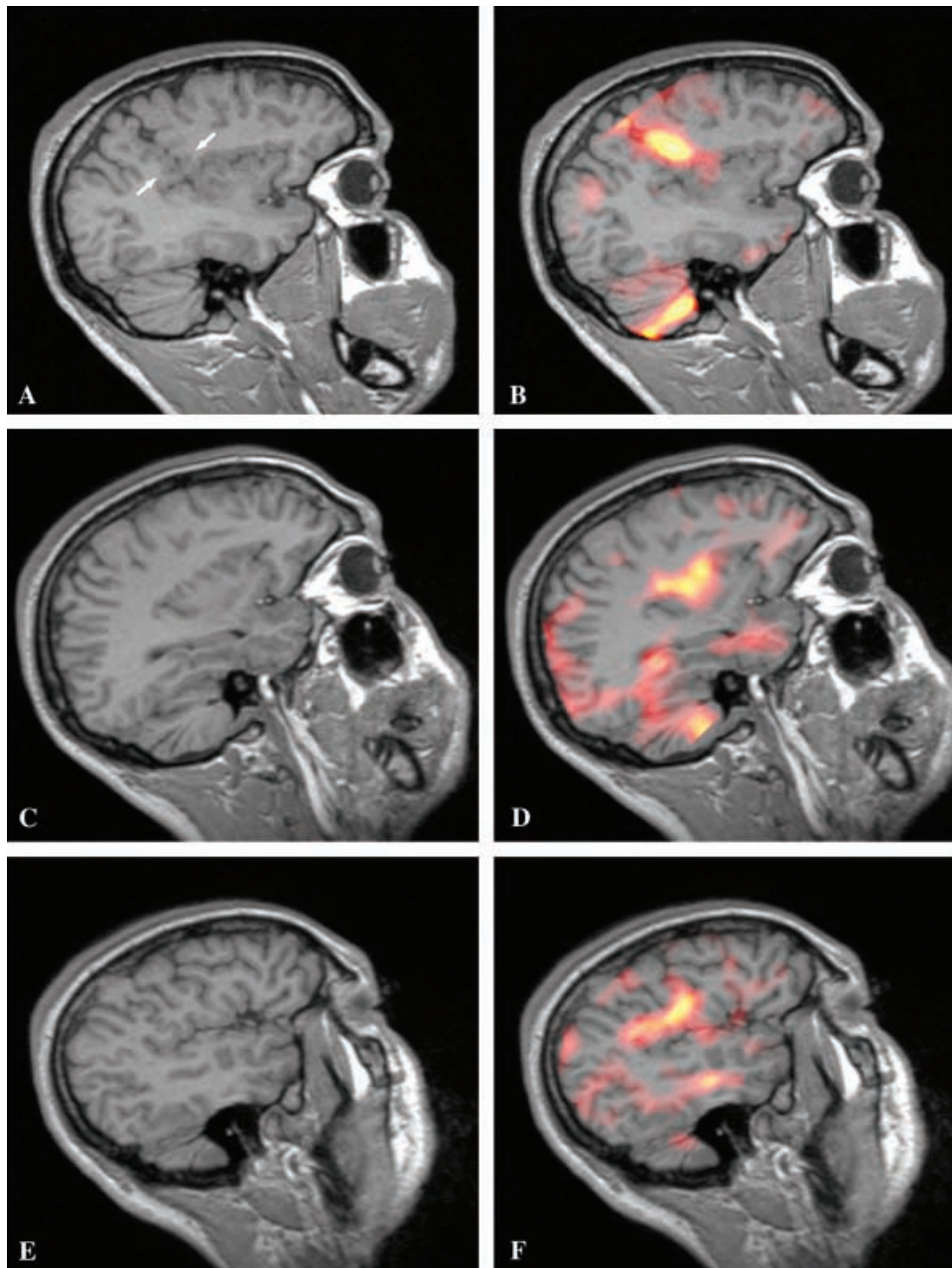


Figure 1. Patient 1 (A, B) and patient 2 (C–F). The sagittal T1-weighted 3D MP-RAGE (Siemens) MR sequence in patient 1 (A) demonstrates the pathological outlining of the left Sylvian fissure, which has multiple small areas of dysplastic gray matter organization mainly irregularly distributed along its course but with a focal concentration of dysplastic cortex at one location (arrows). The SISCOM-image (B) shows a hyperperfusion in the same region. In patient 2 no pathological changes could be identified on conventional MRI (C and E). SISCOM shows opercular and insular hyperperfusion (D and F) shown in sagittal images 31 and 45 mm from the midline).

hyperperfusion in the cerebellum with right predominance. Reevaluation of the MRI showed mild cerebellar atrophy, but no cerebral pathology (Fig. 1C,E).

Discussion

Congenital bilateral perisylvian syndrome is a rare neuronal migration disorder with bilateral perisyl-

vian dysplasia characterized by pseudobulbar palsy, epilepsy and mental retardation.

Kuzniecky et al. (1, 2) reported 31 patients with congenital bilateral perisylvian syndrome, all of whom had neurological abnormalities. All patients had facial, pharyngeal and masticatory muscle impairment and moderate to severe dysarthria and nasal speech. Epilepsy was present in 87% and seizures were poorly controlled in 55%. All

patients had perisylvian cortical malformations visible on MRI (1). In a multicenter study (5) report on 12 kindreds with familial perisylvian polymicrogyria, variable clinical and radiological patterns were shown among the patients.

Both our patients had similar seizure semiology with perioral tension, speech difficulties and tonic rising of the arms and in both patients SISCOM showed ictal hyperperfusion in the perisylvian region. One of the patients had normal cognitive and neurological functions, although SISCOM-guided reevaluation of MRI confirmed perisylvian cortical dysplasia. The other patient had mild bulbar symptoms and mild cognitive dysfunction but normal MRI findings. However, the neurological findings, cognitive deficit, seizure semiology and SISCOM result together strongly suggest that this patient suffers from a mild form of perisylvian syndrome.

It is reasonable to assume that some patients with mild forms of perisylvian syndrome have very subtle morphological changes, which makes the diagnosis difficult or impossible to confirm even with the latest MRI technology. This would implicate that the syndrome has a wider range than earlier shown, where the milder forms can have normal neurological and cognitive functions and epilepsy with simple partial seizures as the only clinical manifestation.

In conclusion, our findings indicate that perisylvian syndrome occurs in a wider range than previously described, where in its mildest forms,

simple partial seizures with articulation difficulty occur as the only clinical manifestation. Furthermore, we demonstrate that SISCOM can help identify subtle morphological abnormalities through guided reevaluation of MR-images, thereby playing a significant role in the presurgical investigation of intractable epilepsy patients.

Acknowledgement

Supported by the Swedish Research Council (K2002-04x-00084-38A).

References

1. KUZNIECKY R, ANDERMANN F, GUERRINI R. Congenital bilateral perisylvian syndrome: study of 31 patients. The CBPS Multicenter Collaborative Study. *Lancet* 1993;**341**:608–12.
2. KUZNIECKY R, ANDERMANN F, GUERRINI R. The epileptic spectrum in the congenital bilateral perisylvian syndrome. CBPS Multicenter Collaborative Study. *Neurology* 1994;**44**: 379–85.
3. BAYKAN-KURT B, SARP A, GOKYIGIT A, TUNCAY R, CALISKAN A. A clinically recognizable neuronal migration disorder: congenital bilateral perisylvian syndrome. Case report with long-term clinical and EEG follow-up. *Seizure* 1997;**6**: 487–93.
4. O'BRIEN TJ, SO EL, MULLAN BP et al. Subtraction ictal SPECT co-registered to MRI improves clinical usefulness of SPECT in localizing the surgical seizure focus. *Neurology* 1998;**50**:445–54.
5. GUERREIRO MM, ANDERMANN E, GUERRINI R et al. Familial perisylvian polymicrogyria: a new familial syndrome of cortical maldevelopment. *Ann Neurol* 2000;**48**:39–48.