



LUND UNIVERSITY

No augmentation of morselized and impacted bone graft by OP-1 in a weight-bearing model.

Tägil, Magnus; Jeppsson, Charlotte; Wang, Jian-Sheng; Aspenberg, Per

Published in:
Acta Orthopaedica Scandinavica

DOI:
[10.1080/00016470310018306](https://doi.org/10.1080/00016470310018306)

2003

[Link to publication](#)

Citation for published version (APA):

Tägil, M., Jeppsson, C., Wang, J.-S., & Aspenberg, P. (2003). No augmentation of morselized and impacted bone graft by OP-1 in a weight-bearing model. *Acta Orthopaedica Scandinavica*, 74(6), 742-748.
<https://doi.org/10.1080/00016470310018306>

Total number of authors:
4

General rights

Unless other specific re-use rights are stated the following general rights apply:
Copyright and moral rights for the publications made accessible in the public portal are retained by the authors and/or other copyright owners and it is a condition of accessing publications that users recognise and abide by the legal requirements associated with these rights.

- Users may download and print one copy of any publication from the public portal for the purpose of private study or research.
- You may not further distribute the material or use it for any profit-making activity or commercial gain
- You may freely distribute the URL identifying the publication in the public portal

Read more about Creative commons licenses: <https://creativecommons.org/licenses/>

Take down policy

If you believe that this document breaches copyright please contact us providing details, and we will remove access to the work immediately and investigate your claim.

LUND UNIVERSITY

PO Box 117
221 00 Lund
+46 46-222 00 00

No augmentation of morselized and impacted bone graft by OP-1 in a weight-bearing model

Magnus Tägil¹, Charlotte Jeppsson¹, Jian-Sheng Wang¹ and Per Aspenberg^{1,2}

Department of Orthopedics, ¹Lund University Hospital, Lund, Sweden, ²INR, Faculty of Health Sciences Linköping, Sweden
Correspondence: magnus.tagil@ort.lu.se
Submitted 01-06-12. Accepted 03-03-15

Introduction Impacted morselized bone allograft is thought to be remodeled to a great extent. We have previously shown that load-bearing increases the remodeling of impacted morselized bone allografts in a rabbit knee prosthesis model. Bone Morphogenic Proteins (BMPs) also stimulate bone formation and bone allograft remodeling. In this study, our aim was to determine whether it was possible to increase further the remodeling of impacted morselized bone allografts by combining load-bearing with a BMP.

Experiment A solution of Osteogenic Protein-1 (OP-1, also called BMP-7) was added to freeze-dried bone allograft chips before impaction grafting in our rabbit knee prosthesis model. 23 skeletally mature rabbits received an uncemented tibial knee prosthetic component inserted into a bed of impacted morselized bone allograft. 12 rabbits were given OP-1-treated allograft (50 µg OP-1 per gram allograft), and 11 rabbits vehicle-treated allograft. Each rabbit received mean 0.53 g graft. The rabbits were killed after 3 or 6 weeks and the grafted region was examined by histomorphometric assessment of the volume fraction of newly formed bone and remaining graft.

Results and interpretation We found that OP-1 did not increase the bone density (graft plus new bone) to any substantial extent. However, we can not exclude that this might be due to a carrier problem, since the OP-1 was added as a solution directly to the dry graft.

1991, Hamadouche et al. 2002). Structural bone allografts have also been reported to undergo resorption, leading to mechanical failure (Kwong et al. 1993, Shinar and Harris 1997). In contrast to structural nonmorselized bone allografts, the morselized and impacted allografts are thought to be totally remodeled, mainly based on their radiographic appearance (Gie et al. 1993, Nelissen et al. 1995). The clinical results are good also over a long period (Ling 1996, Schreurs et al. 2001). Since good early fixation of primary hip and knee prostheses affects the long-term results (Ryd et al. 1995, Kobayashi et al. 1997), it is tempting to see whether one can accelerate the remodeling of the graft into newly formed bone. The Bone Morphogenic Proteins provide an opportunity to achieve faster and more extensive remodeling of allografts with the formation of more new bone (Cook et al. 2000), but adverse effects have also been reported (Jeppsson et al. 1999, Laursen et al. 1999, Sciadini and Johnson 2000).

We have previously used a knee prosthetic model with morselized and impacted bone graft in rabbits to determine the effect of mechanical load on bone graft remodeling (Wang et al. 2000). We are now studying whether this remodeling can be further increased by also giving a BMP.

Experiment

Animals

We used 30 rabbits, with a mean weight of 2.8 (2.4–3.8) kg, aged 6–8 months. They were

Structural bone grafts seem to remodel sparsely and ingrowth of new bone into the graft rarely exceeds a few mm (Enneking and Mindell

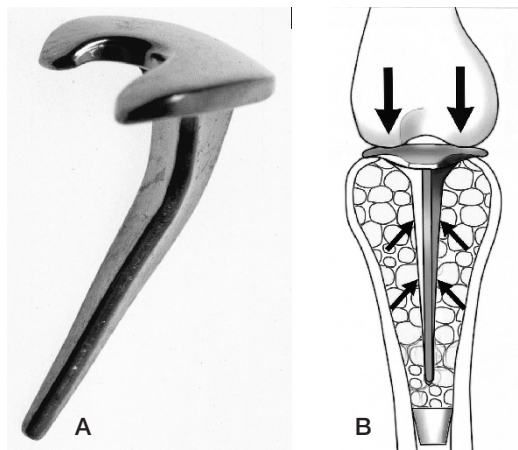


Figure 1. The load-bearing prosthesis implanted in the proximal tibia (A: photo, B: drawing showing load and graft).

skeletally mature and a crossbreed between lop-eared and New Zealand white rabbits. They were kept in our animal facility for 1 week before starting the experiment. All animal handling was approved by the regional animal research ethics committee.

Experimental design

The rabbits received a unilateral uncemented proximal tibial joint replacement (Wang et al. 2000) with a long tapered stem, inserted into morselized and impacted bone allograft containing OP-1 or control solution. Every other rabbit was given control solution and the others OP-1. The first 12 operated rabbits were killed after 6 weeks and the following 12 after 3 weeks. In the 6-week group, 5 animals were excluded due to joint dislocation or infection, and in the 3-week group, 1 rabbit was excluded due to joint dislocation. These animals were replaced with new ones, to yield 11 rabbits in the 6-week group and 12 in the 3-week group.

Bone grafts and implants

The tibial prosthesis consisted of a titanium plate replacing the tibial surface and a 25 mm long, tapered, unpolished stem. The surface roughness was 0.079 microns for the articular surface and 0.232 microns for the stem. The articular surface is convex in the sagittal plane and tilted posteriorly (Figure 1). No cement was used.

Bone grafts were taken from rabbit metaphyseal bone in the proximal tibia and distal femur under aseptic conditions and kept at -35°C for 6 months. These rabbits were outbred, and the grafts were pooled from several donor animals. The grafts were cut manually into bone fragments less than about 1.5 mm in diameter. They were freeze-dried and rehydrated with OP-1 or saline solution after thawing. The volume of solution was chosen to correspond to the weight loss of the graft during freeze-drying.

The OP-1 was a gift from Stryker Biotech (Hopkinton, MA, USA) and delivered as a 1.0-mg/mL solution. It was diluted to 0.25 mg/mL in a lactate buffer provided by the manufacturer, and added to the dry bone graft fragments before implantation. The OP-1 concentration achieved was calculated to be $50\ \mu\text{g}$ OP-1 per gram rehydrated bone graft and the mean total amount of OP-1 was $26\ \mu\text{g}$ in each rabbit.

Surgical procedure

The rabbits were anesthetized with intramuscular Hypnorm in a dose of 0.9 mg/kg and subcutaneous lidocaine 0.5 mL (20 mg/mL) locally. Streptocillin 0.1 mg/kg was given once on the day of operation. Buprenorphinum 0.015 mg/kg was given daily during the first 3 postoperative days to relieve pain.

Under aseptic conditions, a medial parapatellar incision was made and the patella was mobilized laterally. The anterior cruciate ligament was resected together with the menisci. The tibia was dislocated forwards, taking care not to injure the intra-articular portion of the anterior tibial tendon, which maintains the postoperative sagittal stability. The tibial articular surface was abraded over an area of 2 mm with a water-cooled electric reamer. A hole was made in the center of the tibial plateau and the bone marrow cavity was enlarged. All cancellous bone was removed. The cavity was irrigated with saline. A distal rubber plug, diameter 4.5 mm, was inserted into the marrow cavity to a depth of 25 mm. An impactor shaped like the prosthetic stem was used to compact the bone graft, which was placed in the tibial canal. The prosthesis was then introduced and hammered down to achieve additional compaction on the graft. The patella was reduced and the synovium and capsule were closed with 4-0 monofilament nylon. The skin was closed

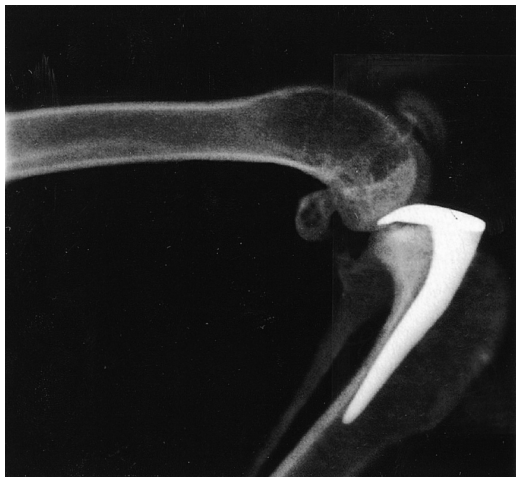

Figure 2. Lateral radiograph taken before killing the rabbit.

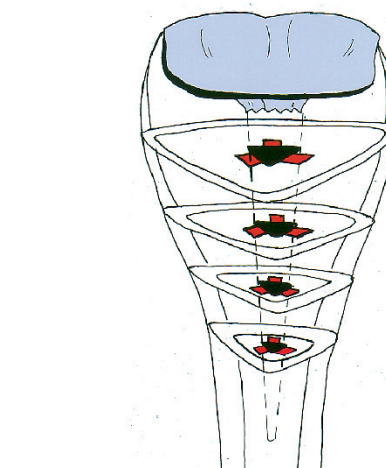


Figure 3. Schematic drawing of the histologically-evaluated regions (red) in sections 2, 4, 6 and 8.

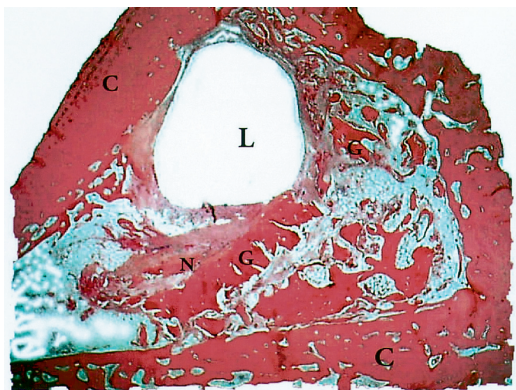


Figure 4. Transverse section of a control rabbit at 6 weeks. Allograft (G), new bone (N) and the lumen of the prosthesis (L). HE.

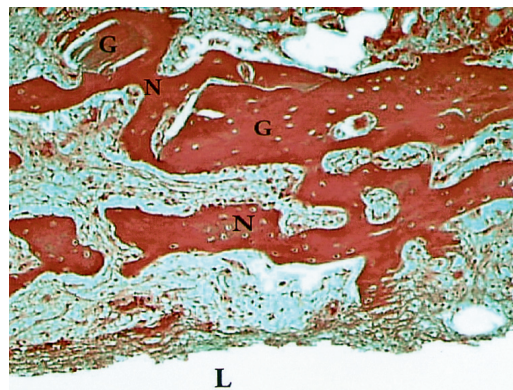


Figure 5. Transverse section of an OP-1-treated rabbit at 3 weeks. Allograft (G), new bone (N) and the lumen of the prosthesis (L). HE.

with continuous intracutaneous 4-0 monofilament nylon. The knees were checked daily the first week and the animals were killed in case of dislocation or other illness.

EvaluatŠn

Lateral (Figure 2) and anterior radiographs were taken before the rabbits were killed with an overdose of pentobarbital sodium after 3 or 6 weeks. The tibiae were retrieved and the prostheses extracted. Using a water-cooled diamond-edged precision saw, we cut the bone perpendicularly to the long axis of the tibia at 2-mm intervals from proximal to distal (a total of 9 sections). Sections 2, 4, 6 and 8 were used for the histological prepara-

tions (Figure 3). They were fixed in 4% formalin, decalcified and embedded in paraffin, then cut with a microtome into 6- μ m thick slide sections perpendicular to the long axis of the tibia and stained with hematoxylin and eosin (Figures 4 and 5). All histological slides were blinded and evaluated by one person (MT). The tissue surrounding the prosthesis was analyzed by histomorphometry, using a Merz grid at 4 \times 12.5 magnification. In all sections, measurements were made of 3 square areas, each measuring 1.8 \times 1.8 mm and bordering one of the three sides to the triangular stem void (Figure 3). All points superimposed on the endosteal compartment, excluding the cortices, were first counted. Then, points superimposed on new bone

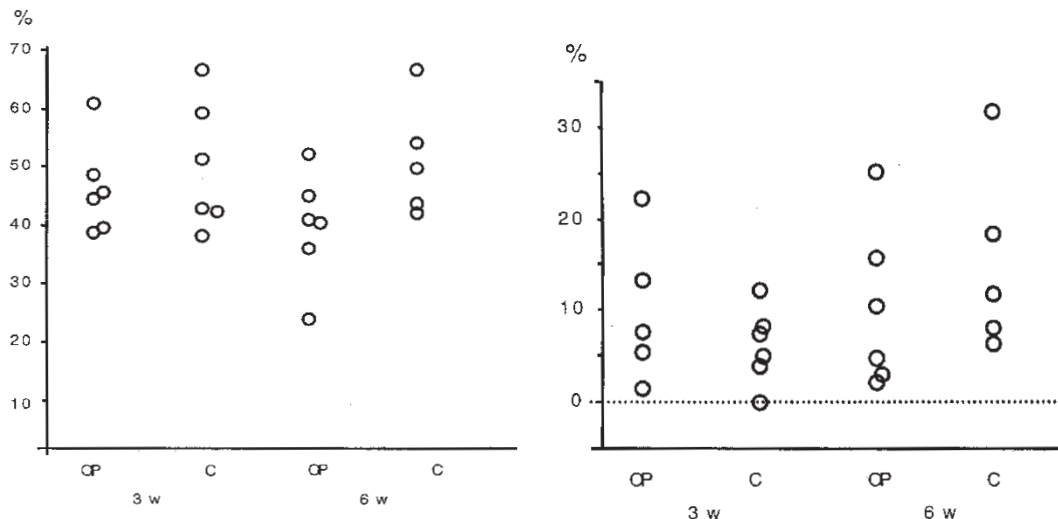


Figure 6. a. Bone (graft and new bone) expressed as a percentage of the total area of the specimen.

b. New bone expressed as a percentage of the total area of the specimen.

or dead graft were counted and recorded as “bone points”. Points superimposed on nonosseous tissue were mainly in fibrotic scar tissue, since no normal fatty marrow is seen at these early times. The total number of bone points on the slide was divided by the total number of endosteal compartment points. Thus, if the stem had been placed in direct contact with a cortical side in a section, the mean was calculated from the remaining 2 sides. The mean of all 4 sections was then used to yield a final value for each animal. The histomorphometric measurements were repeated by a second person and the error of measurement between the two persons making the measurements was 8% units. To distinguish between dead graft and new bone, we used a higher magnification. Therefore, 0.9×0.9 mm squares at the three sides of the triangular-shaped stem void (Figure 3) were examined by point counting as above, using a magnification of 63 times. The number of points superimposed on new bone per section was recorded and divided by the total number of points, as described above. Bone having osteocytes with normal nuclei and osteoblastic activity at the surface was classified as new bone. Bone fragments with sharp irregular borders and empty lacunae were described as dead grafts. In many areas, this classification depended on a combined interpretation of fragment shape, matrix staining, presence of osteocytes and osteoblasts.

The thickness of the soft tissue membrane between the prosthesis and the graft/new bone was measured on all slides used for the histomorphometric analysis. We calculated the mean for each animal.

Statistics

Nonparametric statistics (Mann-Whitney) was used for significance testing and the calculation of confidence intervals.

Results

After 6 weeks a layer of fibrous tissue was seen with a mean thickness of 230 (SD 62) μm in the experimental group and 210 (SD 71) μm in the controls in all specimens at the interface between the prosthesis and bone. The thickness of the membrane never exceeded 500 μm . We found no significant differences in bone density (graft plus new bone) (Figure 6a). At 3 weeks, the control median was 47% and the OP-1 median was 46%. The nonparametric 95% confidence interval for the difference (OP-1 minus control) ranged from -19 to 8% units. Thus, the probability that OP-1 would increase the bone density by more than 8% units was less than 2.5%. At 6 weeks, the control median was 50% and the OP-1 median 41%, with the same

confidence interval ranging from -27 to 2% units. The probability that OP-1 would increase the bone density by more than 2% units was less than 2.5% . Thus, we excluded that OP-1 increased the total amount of bone to any substantial extent in this model.

The percentage of the bone that seemed to be newly formed, as determined at higher magnification, was not significantly increased by OP-1 (Figure 6b). At 3 weeks, the control median was 6% and the OP-1 median 7% . The nonparametric 95% confidence interval for the difference (OP-1 minus control) ranged from -4 to 12% units. At 6 weeks, the control median was 12% and the OP-1 median 8% , with the same confidence interval ranging from -22 to 10% units. Thus, the amount of new bone was small, and OP-1 had caused no substantial increase.

Discussion

In an unloaded bone chamber in rats, the bone ingrowth at 6 weeks into densely impacted allografts was delayed by impaction, as compared to bone ingrowth into allografts that had not been impacted (Tägil and Aspenberg 1998). By adding OP-1 to the impacted bone grafts in the same unloaded chamber model, bone ingrowth increased dramatically (Tägil et al. 2000). In the present study, we tried a more clinically-oriented model, which had previously been successful in showing a positive effect of mechanical load on remodeling of impacted bone graft (Wang et al. 2000). However, we detected no positive effect of the OP-1 on bone remodeling after 3 and 6 weeks. We used an uncemented fixation of the prosthesis, which is not as stable as a cemented one. This caused micromotion and the formation of a thin layer of fibrous tissue at the interface. To minimize micromotion, we would have preferred cemented fixation, but the amount of graft would then have been too small because of the animal's size. However, at retrieval, the prostheses were not clinically loose, the soft tissue membrane between the prostheses and the bone was similar in the two groups and the conditions, as regards stability, therefore the same in the two groups. The number of animals in the previous study, which compared load and

absence of load (Wang et al. 2000), was sufficient to show a difference and the same sample size was chosen for this study. To evaluate the risk of a type two error by undersizing the experimental groups, we presented the final data as confidence intervals for the difference between the two groups. Large differences can be excluded, but the accuracy of the model and the histomorphometric analysis may not be sufficient to detect a small difference.

The amount of OP-1 protein in our study was chosen to correspond to one standard dose of OP-1 (one Novos device) for each femoral head graft. The OP-1 solution, however, was not added together with the commercially available collagen carrier with which it has been tested clinically. We can not exclude that the failure to detect an effect was related to an inferior carrier function of the allograft, but regard this as less likely, since BMPs seem to be effective not only with demineralized bone carriers, but also with various calcium phosphate carriers, including hydroxyapatite.

In structural bone allografts, new bone ingrowth is minimal (Enneking and Mindell 1991, Hooten et al. 1996, Hamadouche et al. 2002), and resorption can cause mechanical failure (Kwong et al. 1993). On the other hand, this does not seem to affect morselized and impacted allografts that seem radiographically largely remodeled into newly formed bone, with a thin cortical bone becoming gradually thicker (Gie et al. 1993, Nelissen et al. 1995). However, histological reports suggest that not all of the graft is remodeled (Nelissen et al. 1995, Buma et al. 1996, Ullmark and Linder 1998, Ullmark and Obrant 2002, van der Donk et al. 2002). Linder (2000), in a histological study of femurs from humans undergoing hip revision, found that what has been described as radiographic remodeling did not always correlate with the histological findings. Cortical healing and trabecular remodeling occurred to some extent, but the remaining bone allograft fragments were commonly surrounded by fibrous tissue with no newly formed bone.

This composite material of necrotic bone and new fibrous tissue apparently provides adequate load-bearing support for the prosthesis. Necrotic graft fragments in the fibrous stroma look like inert implants in a viable tissue, which do not cause an immune response (Linder 2000) and the fibrous

tissue armoring of the compacted unremodeled graft adds to its strength (Tägil and Aspenberg 2001). It has been speculated that it may be unnecessary for the graft to regenerate into normal bone to be able to function as a support for the prosthesis. Indeed, a total remodeling might even cause the prosthesis to loosen when the remodeling process reaches the bone-cement interface as it could then form a loosening membrane. Apart from stimulating bone formation (Tourimi et al. 1991, Yasko et al. 1992, Bostrom et al. 1996), BMPs can also stimulate the osteoclast lineage (Kanatani et al. 1995, Kaneko et al. 2000). An acceleration of the remodeling might also speed up the resorption, with the risk of mechanical weakening of the construct and re loosening. In a series of hip revisions with morselized impacted allograft supplemented with OP-1, severe bone resorption was encountered in 2 of 10 cases with concomitant loss of the position of the prosthesis (Höstner et al. 2000). This raises concerns about speeding up the remodeling. In conclusion, BMPs should be used with care as adjuncts to bone grafts, because their effect seems unpredictable in this situation. The role of BMPs in hip revision surgery may be to serve as a promoter of bone formation in combination with an unresorbable graft materia—e.g., titanium particles or bone allografts pretreated with a bisphosphonate.

We thank Inger Mårtensson, Carina Forslund and Mats Christensson for technical assistance. This study was financially supported by the Swedish Medical Research Council (project 2031), the Medical Faculty of Lund University, the Kung Gustaf V Jubileumsfond, the Greta och Johan Kocks and Alfred Österlund Foundations.

- Bostrom M, Lane J M, Tomin E. Use of bone morphogenetic protein-2 in the rabbit ulnar nonunion model. *Clin Orthop* 1996; 327: 272-82.
- Buma P, Lamerigts N, Schreurs B W, Gardeniers J, Versleyen D, Slooff T J. Impacted graft incorporation after cemented acetabular revision. Histological evaluation in 8 patients. *Acta Orthop Scand* 1996; 67: 536-40.
- Cook S D, Barrack R L, Santman M, Patron L P, Salkeld S L, Whitecloud T S 3rd. Strut allograft healing to the femur with recombinant human osteogenic protein-1. *Clin Orthop* 2000; 381: 47-57.
- Enneking W F, Mindell E R. Observations on massive retrieved human allografts. *J Bone Joint Surg (Am)* 1991; 73: 1123-42.
- Gie G A, Linder L, Ling R S, Simon J P, Slooff T J, Timperley A J. Impacted cancellous allografts and cement for revision total hip arthroplasty. *J Bone Joint Surg (Br)* 1993; 75: 14-21.
- Hamadouche M, Blanchat C, Meunier A, Kerboull L, Kerboull M. Histological findings in a proximal femoral structural allograft ten years following revision total hip arthroplasty: a case report. *J Bone Joint Surg (Am)* 2002; 84: 269-73.
- Hooten J P, Engh C A, Heekin R D, Vinh T N. Structural bulk allografts in acetabular reconstruction. *J Bone Joint Surg (Br)* 1996; 78: 270-5.
- Höstner J, Kärrholm J, Hultmark P. Early failures after femoral revisions using milled allograft bone mixed with OP-1. *Proc Svensk Ortopedisk Förening* 2000: 205-6 (Abstract).
- Jepsson C, Bostrom M, Aspenberg P. Intraosseous BMP implants in rabbits. Inhibitory effect on bone formation. *Acta Orthop Scand* 1999; 70: 77-83.
- Kanatani M, Sugimoto T, Kaij H, et al. Stimulatory effect of bone morphogenic protein-2 on osteoclast-like cell formation and bone resorbing activity. *J Bone Min Res* 1995; 10: 1681-90.
- Kaneko H, Arakawa T, Mano H, et al. Direct stimulation of osteoclastic bone resorption by Bone Morphogenic Protein (BMP-2) and expression of BMP receptors in mature osteoclasts. *Bone* 2000; 27: 479-86.
- Kobayashi A, Donnelly W J, Scott G, Freeman M A. Early radiological observations may predict the long-term survival of femoral hip prostheses. *J Bone Joint Surg (Br)* 1997; 79: 583-9.
- Kwong L M, Jasty M, Harris W H. High failure rate of bulk femoral head allografts in total hip acetabular reconstructions at 10 years. *J Arthroplasty* 1993; 8: 341-6.
- Laursen M, Hoy K, Hansen E S, Gelineck J, Christensen F B, Bünger C E. Recombinant bone morphogenic protein-7 as an intracorporal bone growth stimulator in thoracolumbar burst fractures in humans; preliminary results. *Eur Spine J* 1999; 8: 485-90.
- Linder L. Cancellous impaction grafting in the human femur. Histological and radiographic observations in 6 autopsy femurs and 8 biopsies. *Acta Orthop Scand* 2000; 71: 543-52.
- Ling R S. Cemented revision for femoral failure. *Orthopedics* 1996; 19: 763-4.
- Nelissen R G H H, Bauer T W, Weidenhielm L R A, Legolvan D P, Mikhail W E M. Revision hip arthroplasty with the use of cement and impaction grafting. Histological analysis of four cases. *J Bone Joint Surg (Am)* 1995; 77: 412-22.
- Ryd L, Albrektsson B E, Carlsson L, Dansgard F, Herberths P, Lindstrand A, Regner L, Toksvig-Larsen S. Roentgen stereophotogrammetric analysis as a predictor of mechanical loosening of knee prostheses. *J Bone Joint Surg (Br)* 1995; 77: 377-83.

- Schreurs B W, Slooff T J, Gardeniers J W, Buma P. Acetabular reconstruction with bone impaction grafting and a cemented cup: 20 years experience. *Clin Orthop* 2001; 393: 202-15.
- Sciadini M, Johnson K. Evaluation of recombinant human bone morphogenetic protein-2 as a bone-graft substitute in a canine segmental defect model. *J Orthop Res* 2000; 18: 289-302.
- Shinar A A, Harris W H. Bulk structural autogenous grafts and allografts for reconstruction of the acetabulum in total hip arthroplasty. *J Bone Joint Surg (Am)* 1997; 79: 159-68.
- Tourimi D M, Kotler H S, Luxenberg D P, Holtrop M E, Wang E A. Mandibular reconstruction with a recombinant bone-inducing factor. *Arch Otolaryngol Head Neck Surg* 1991; 117: 1101-12.
- Tägil M, Aspenberg P. Impaction of cancellous bone grafts impairs osteoconduction in titanium chambers. *Clin Orthop* 1998; 352: 231-8.
- Tägil M, Aspenberg P. Fibrous tissue armoring increases the mechanical strength of an impacted bone graft. *Acta Orthop Scand* 2001; 72: 78-82.
- Tägil M, Jeppsson C, Aspenberg P. Bone graft incorporation. Effects of Osteogenic Protein-1 and impaction. *Clin Orthop* 2000; 371: 240-5.
- Ullmark G, Linder L. Histology of the femur after cancellous impaction grafting using a Charnley prosthesis. *Arch Orthop Trauma Surg* 1998; 117: 170-2.
- Ullmark G, Obrant K J. Histology of impacted bone-graft incorporation. *J Arthroplasty* 2002; 17: 150-7.
- van der Donk S, Buma P, Slooff T J, Gardeniers J W, Schreurs B W. Incorporation of morselized bone grafts: a study of 24 acetabular biopsy specimens. *Clin Orthop* 2002; 396: 131-41.
- Wang J S, Tägil M, Aspenberg P. Load-bearing increases new bone formation in impacted and morselized allografts. *Clin Orthop* 2000; 378: 274-81.
- Yasko A W, Lane J M, Fellingner E J, Rosen V, Wozney J M, Wang E A. The healing of segmental bone defects, induced by recombinant human morphogenetic protein (rhBMP-2). *J Bone Joint Surg (Am)* 1992; 74: 659-70.