



# LUND UNIVERSITY

## **Gadolinium contrast media are more nephrotoxic than a low osmolar iodine medium employing doses with equal x-ray attenuation in renal arteriography: An experimental study in pigs(1).**

Elmståhl, Barbara; Leander, Peter; Chai, Chun-Ming; Frennby, Bo; Almén, Torsten

*Published in:*  
Academic Radiology

*DOI:*  
[10.1016/j.acra.2004.07.015](https://doi.org/10.1016/j.acra.2004.07.015)

2004

[Link to publication](#)

### *Citation for published version (APA):*

Elmståhl, B., Leander, P., Chai, C.-M., Frennby, B., & Almén, T. (2004). Gadolinium contrast media are more nephrotoxic than a low osmolar iodine medium employing doses with equal x-ray attenuation in renal arteriography: An experimental study in pigs(1). *Academic Radiology*, 11(11), 1219-1228.  
<https://doi.org/10.1016/j.acra.2004.07.015>

*Total number of authors:*  
5

### **General rights**

Unless other specific re-use rights are stated the following general rights apply:  
Copyright and moral rights for the publications made accessible in the public portal are retained by the authors and/or other copyright owners and it is a condition of accessing publications that users recognise and abide by the legal requirements associated with these rights.

- Users may download and print one copy of any publication from the public portal for the purpose of private study or research.
- You may not further distribute the material or use it for any profit-making activity or commercial gain
- You may freely distribute the URL identifying the publication in the public portal

Read more about Creative commons licenses: <https://creativecommons.org/licenses/>

### **Take down policy**

If you believe that this document breaches copyright please contact us providing details, and we will remove access to the work immediately and investigate your claim.

LUND UNIVERSITY

PO Box 117  
221 00 Lund  
+46 46-222 00 00

---

# Gadolinium Contrast Media are More Nephrotoxic Than a Low Osmolar Iodine Medium Employing Doses With Equal X-Ray Attenuation in Renal Arteriography: An Experimental Study in Pigs<sup>1</sup>

Barbara Elmståhl, MD, Ulf Nyman, MD, PhD, Peter Leander, MD, PhD, Chun-Ming Chai, MD, Bo Frennby, MD, PhD, Torsten Almén, MD, PhD,

---

**Rationale and Objectives.** To investigate in a unilaterally nephrectomized porcine model whether gadolinium contrast media (Gd-CM) are less nephrotoxic than iodine media (I-CM) in x-ray arteriography of a kidney made temporarily ischemic by arterial balloon occlusion.

**Materials and Methods.** In a noncrossover design, 3 mL of each test solution were injected in eight pigs (mean weight 19 kg) at a rate of 20 mL/min into the right renal artery at the start of a 10-minute period of ischemia. In group 1 (40 pigs) we injected 0.5 M gadopentetate, 0.5 M gadodiamide, 0.5 M iohexol (190 mg I/mL), 0.18 M iohexol (70 mg I/mL; with an x-ray attenuation equal to that of 0.5 M Gd-CM at 80 kV), and saline. In group 2 (24 pigs), we tested 0.18 M iohexol with ischemia and saline with and without ischemia. Gd- and iodine contrast media functioned as markers of glomerular filtration rate (GFR). When saline was tested, a low dose of iohexol (3 mL per pig; 300 mg I/mL) was injected as GFR marker intravenously in group 1 and into the renal artery in group 2. The plasma half-life elimination times of the CM 1–3 hours after injection were used to compare the effects of the different test solutions on GFR. Longer half-life means lower GFR.

**Results.** Group 1: median plasma half-life elimination time of the GFR marker was 3340 minutes after injection of 0.5 M gadopentetate, 256 after 0.5 M gadodiamide, 179 after 0.5 M iohexol, 143 after 0.18 M iohexol, and 133 minutes after saline. All differences except that between 0.18 M iohexol and saline were statistically significant ( $P < .01$ ). Group 2: median plasma half-life was 174 minutes after 0.18 M iohexol with ischemia, 196 minutes after saline with ischemia, and 195 minutes after saline without ischemia. There were no significant differences between the test solutions in group 2 ( $P > .05$ ).

**Conclusion.** In pigs, 0.5 M Gd-CM were more nephrotoxic than both equal-attenuating (70 mg I/mL) and equimolar (190 mg I/mL) concentrations of the I-CM iohexol. These results do not support the "off-label" use of Gd-CM for renal x-ray arteriography in man instead of commercially available concentrations of iodine contrast media at 140, 150 and 180 mg I/mL or diluted to 70 mg I/mL.

**Key Words.** Angiography; contrast media; toxicity; kidney; failure; gadolinium.

© AUR, 2004

---

*Acad Radiol* 2004; 11:1219–1228

<sup>1</sup> From the Department of Diagnostic Radiology, Malmö University Hospital, Lund University, SE-205 02 Malmö, Sweden (B.E., P.L., B.F., T.A.), Department of Radiology, Lasarettet Trelleborg, Sweden (J.N.), Department of Experimental Research (C-M.C.) Received March 17, 2004; accepted July 22, 2004. **Address correspondence to** B.E. e-mail: barbara.elmstahl@rontgen.mas.lu.se

© AUR, 2004  
doi:10.1016/j.acra.2004.07.015

The risk of contrast medium nephropathy (CMN) induced by iodine contrast media (I-CM) has been recognized for many years in patients with preexisting renal insufficiency, especially in combination with diabetes mellitus (1). The use of low-osmolar instead of high-osmolar I-CM has reduced this risk (2,3). CMN is still a burning issue because there is a tendency to expose an increasing number of patients to larger amounts of I-CM because of the expanding use of computed tomography, angiography,

and vascular interventions, which all require high doses of I-CM. Many of these procedures are performed in elderly patients with decreased renal function and diabetes. Thus it is necessary to adopt strategies to decrease the risk of CMN.

One strategy to decrease this risk has been to exchange I-CM to other CM such as carbon dioxide (4,5) or gadolinium CM (Gd-CM) (6–11). The assumed lower nephrotoxic effect of Gd-CM is partly based on one study (8) in which intraarterial and intravenous doses of I-CM for x-ray arteriography (XRA) and computed tomography, respectively, proved more nephrotoxic than Gd-CM for magnetic resonance angiography in the same patients. However, the two CM were compared at an extremely different x-ray attenuation capacity. Thus the “off-label” recommendation to use Gd-CM as a safer alternative than I-CM in azotemic patients in a variety of XRA examinations—including aortofemoral (12,13), renal (14–17), carotid (18), and coronary arteriography (19,20)—is, in our opinion, based on an incorrect comparison. The only reason for using I-CM or Gd-CM in XRA is to exploit their ability to attenuate x-rays. A recent review dealing with the toxicity of these agents and their ability to attenuate x-rays indicated that I-CM would probably show a lower renal toxicity than Gd-CM if compared in equal volumes in equal-attenuating concentrations (21). However, no such studies have been performed.

The aim of the present investigation was therefore to answer the following question: “Do Gd-CM really have a lower renal toxicity than a commonly used low-osmolar I-CM when compared in equal volumes of equal-attenuating concentrations during renal arteriography?” To answer the question the nephrotoxic effect of a nonionic low-osmolality I-CM (iohexol) was compared with two 0.5 M Gd-CM with different osmolalities (gadopentetate and gadodiamide) during arteriography of ischemic kidneys in pigs.

## MATERIALS AND METHODS

### Animals

Sixty-four Swedish landrace male pigs (Swedish University of Agricultural Sciences), with a mean weight of 19 kg (range 16–23 kg) were used. The study was approved by the local ethical committee. The pigs were acclimatized at the Experimental Department, Malmö University Hospital, for 4–6 days before

surgery. They had free access to food and water until 15 hours before the experiment and thereafter only free access to water. After the experiment, all animals were sacrificed by an overdose of pentobarbital sodium and 96% ethanol (Pentobarbital 100 mg/mL, Apoteket Produktion och Laboratorier, Gothenburg, Sweden).

### Anesthesia and Surgery

The pigs were premedicated with 8–10 mL ketamine (Ketalar 50 mg/mL, Warner Lambert Nordic AB, Parke-Davis, Solna, Sweden) intramuscularly 15 minutes before the anesthesia, which was induced with an intravenous (IV) injection of 0.5 mL/kg thiopental sodium (25 mg/mL; Pentothal sodium, Abbott, Abbott Park, Ill). After tracheal intubation, the pigs were connected to a volume controlled respirator (Servo-Ventilator 900, Elema-Schönander, Sweden) delivering a gas volume mixture of 70% nitrogen and 30% oxygen. The rectal temperature was continuously registered and kept close to 38°C by use of a heating pad. Surgical anesthesia was initiated and maintained by continuous IV infusion of 0.4–0.6 mL/min of a mixture of 10 mL midazolam (Dormicum 5 mg/mL, F. Hoffmann-La Roche AG, Basel, Switzerland), 40 mL ketamine (Ketalar 50 mg/mL, Park Davies, Barcelona, Spain), and 20 mL vecuronium bromide (Norcuron 2 mg/mL, Organon Teknika, Netherlands). During the entire experiment Ringers solution (2.5 mL/min; Ringer acetate, Fresenius Kabi, Uppsala, Sweden) was given.

The right femoral artery was dissected free and an 8 Fr introducer (Medikit Co., Ltd, Tokyo, Japan) was inserted and connected to a pressure transducer for continuous recording of the arterial pressure (Model MP 100, Biopac Systems Inc., Santa Barbara, Ca). Intraarterial pH, oxygen pressure, and carbon dioxide pressure (AVL Critical Care Analyzers, AVL Scientific Corp., Roswell, Ga) were also monitored during the experiment. A 14 Fr introducer was inserted into the right internal jugular vein for injection of heparin (5000 IU/mL, Leo, Denmark) and blood sampling. A bolus dose of heparin (30 IU/kg) was given and the introducers were flushed with heparinized saline (5000 IU in 1000 mL of saline) to prevent clotting.

A left-sided nephrectomy was performed through a subcostal incision. After surgery a 60-minute calibration period was used to monitor the pigs for hemodynamic stability. A 4 Fr Cobra catheter (Cordis, Oostende, Netherlands) was inserted via the right femoral artery introducer into the right renal artery. The catheter

**Table 1**  
**Concentration of Contrast Medium Molecules and Attenuating Atoms, Osmolality of the Test Solutions and Comments Regarding the Experimental Situation**

Test solution	Concentration of CM molecules (attenuating atoms)	Dose (mL/kg)	Osmolality* (osmol/kg)	Comment
Group 1				Ischemia
Dimeglumine gadopentetate	0.5M (0.5M; 79 mg Gd/mL)	3	1.96	Ischemia
Gadodiamide	0.5M (0.5M; 79 mg Gd/mL)	3	0.78	Ischemia
Iohexol	0.5M (1.5M; 190 mg I/mL)	3	0.40	Ischemia
				Iohexol 300 mg I/mL diluted with sterile water; 1 volume iohexol + 0.6 volume water
Iohexol	0.18M (0.55M; 70 mg I/mL)	3	0.29	Ischemia
				Iohexol 140 mg I/mL diluted with saline; 1 volume iohexol + 1 volume saline
Saline		3	0.29	Ischemia
				3 mL of iohexol 300 mg I/mL injected i.v. as GFR marker
Group 2				
Iohexol	0.18M (0.55M; 70 mg I/mL)	3	0.29	Ischemia
				Iohexol 140 mg I/mL diluted with saline; 1 volume iohexol + 1 volume saline
Saline		3	0.29	Ischemia
				3 mL of iohexol 300 mg I/mL added as GFR marker to the saline dose injected into the right renal artery
Saline		3	0.29	No ischemia
				3 mL of iohexol 300 mg I/mL added as GFR marker to the saline dose injected into the right renal artery

CM, contrast medium.

\* According to the manufacture

ter was then exchanged over a guide wire for a 5 Fr balloon occlusion catheter (Boston Scientific Mediatech, Watertown, Ma). Then an additional IV dose of 200 IU/kg heparin was given to prevent thrombotic occlusion of the renal artery during the subsequent balloon occlusion. The occlusion balloon was inflated for 10 minutes to produce both renal ischemia and prolonged contact between the test solution and the renal vessels.

#### Test Solutions

The test solutions, their doses, concentrations, and osmolalities are given in Table 1. The viscosity of 0.5 M gadopentetate (Magnevist, Schering AG, Berlin, Germany) is 2.9 mPas, gadodiamide (Omniscan, Amersham Health AS, Oslo, Norway) 1.9 mPas, and iohexol Omnipaque (Amersham Health AS) 140 mg I/mL 1.5

mPas at 37°C, according to the manufacturers. The viscosity of the noncommercially available concentrations of iohexol at 70 and 190 mg I/mL have not been measured.

#### Group 1

The nephrotoxic effect of 2 Gd-CM, 0.5 M gadopentetate, and 0.5 M gadodiamide were compared with that of (1) an equimolar concentration of 0.5 M iohexol (190 mg I/mL), (2) 0.18M iohexol (70 mg I/mL), roughly equal-attenuating with 0.5M Gd-CM at about 80 kV (21), and (3) saline. Each pig was subjected to only one of the test solutions, which was injected in eight animals at a dose of 3 mL/kg and a rate of 20 mL/min. The test solutions were randomly assigned to a total number of 40 pigs. All injections were made at the beginning of the 10-minute period of renal artery occlusion. In the animals

subjected to saline, a smaller total dose of 3 mL iohexol (300 mg I/mL) was injected intravenously as a glomerular filtration rate (GFR) marker.

#### Group 2

The nephrotoxic effect of 0.18 M iohexol (70 mg I/mL) with ischemia was compared with that of saline with ischemia and saline without ischemia. The same technique was used as in group 1 except that each dose of saline was enriched with 3 mL iohexol (300 mg I/mL) as the GFR marker. Each of the three procedures was performed in 8 animals and was randomly assigned to a total number of 24 pigs.

#### Plasma Half-Life of the Contrast Media

The pharmacokinetic properties of Gd-CM and I-CM are very similar, both demonstrating rapid extracellular distribution. Their body clearance from plasma is dominated by glomerular filtration with no significant tubular excretion or reabsorption (22–26). Hence, both types of CM function as markers of GFR and may as such be used to evaluate their own nephrotoxic effects (ie, their possible depression of GFR). The larger a CM-induced depression of GFR is, the lower the body clearance of the GFR marker (the contrast medium) from plasma will be, with subsequent prolongation of its plasma half-life elimination time. The plasma half-life of the contrast media was calculated by using a one-compartment model and linear regression analysis of logarithmic plasma concentrations (22) in the period 1–3 hours after injection.

#### Determination of CM Concentrations in Plasma

Ten blood samples of 4 mL each (LH tubes, Sarstedt Aktiengesellschaft & Co, Germany) were drawn 15, 30, 45, 60, 75, 90, 105, 120, 150, and 180 minutes after the start of test solution administration. The samples were centrifuged at 4000 r/min. The plasma was used to determine the concentration of the contrast media using x-ray fluorescence technique (92X-II Spectrum Master Gamma-Ray Spectrometer; EG & G Ortec, Tenn) (27–29). The system was calibrated with a standard of 3 mg I/mL or 2 mg Gd/mL and a sample of distilled water. The spectrometer consists of four principal ingredients: the radiation source, the sample, the detector, and the multichannel analyser.

The radiation source is an americium-241 isotope, which is used to irradiate the plasma samples with 59.5 keV photons. These photons eject the K-shell electrons of iodine or gadolinium atoms, so that the atoms enter an

excited state. The ejected K-shell electrons are immediately replaced by L-shell electrons. Thus the excited atoms return to their original energy level and emit x-rays with energies characteristic for iodine or Gd. The number of characteristic photons registered by the detector is proportional to the amount of iodine or Gd atoms in the sample. The plasma samples, 500  $\mu$ L each, were measured during 300 seconds; the analysis was repeated three times and the resulting mean value calculated.

#### Radiograms

Three radiographic images using a C-arm equipment (BV 300 PLUS, Philips, Holland) were obtained 3 (end of injection), 10 (end of ischemic period), and 30 minutes after the start of injection. The x-ray kilovoltage were set to 70 kV. In each animal the radiograms were evaluated by two of the authors (UN, TA), who were blinded to the CM used. The radiograms were compared in a semiquantitative fashion (ie, if the nephrographic radiodensity appeared similar or significantly different and if excretion to the collecting system was present or not).

#### Statistics

To evaluate any statistically significant nephrotoxic differences among the various test solutions, as indicated by any differences in plasma half-life elimination of the CM GFR-markers, the nonparametric Mann-Whitney U-test was used. *P* values of .05 or less were considered statistically significant.

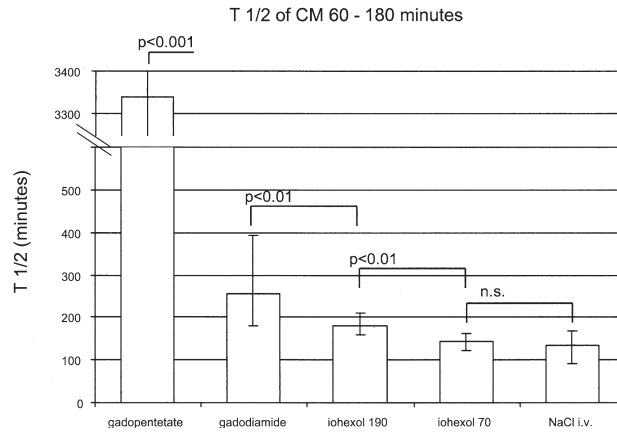
## RESULTS

#### Plasma Half-Life Elimination Time

The results are summarized in Fig 1 and 2.

##### Group 1

Pigs injected into the renal artery with saline got a median plasma half-life elimination time of 133 minutes of the GFR marker (range 92–167). The median plasma half-life elimination time after injection of 0.18 M iohexol (70 mg I/mL) was 143 minutes (range 121–160); the small difference compared with saline was not statistically significant. All other test solutions caused a statistically significant (*P* < .01) longer plasma half-life elimination time of the GFR marker than that caused by saline or 0.18 M iohexol. Compared with saline, 0.5 M iohexol (190 mg I/mL) increased median plasma half-life of the GFR marker by 35% (median time 179 minutes, range 158–211), 0.5 M gadodiamide by



**Figure 1.** Plasma half-life elimination time (median and range) of contrast medium clearance markers after injections into the occluded right renal artery of 0.5 M gadopentetate, 0.5 M gadodiamide, 0.5 M iohexol (190 mg I/mL), 0.18 M iohexol (70 mg I/mL), and saline after left-sided nephrectomy. Plasma concentrations measured between 60 and 180 minutes after the start of contrast medium administration. In the saline group the plasma clearance marker (3 mL iohexol 300 mg I/mL) was injected intravenously. *P* values are outlined. n.s., no statistically significant differences.

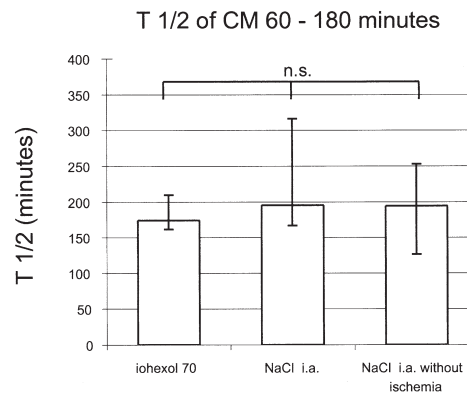
92% (median time 256 minutes, range 179–393), and 0.5 M gadopentetate 25 times (median time 3,340 minutes, range 1,008–∞). The difference in plasma half-life between 0.5 M gadodiamide and 0.5 M iohexol (190 mg I/mL) was also statistically significant ( $P < .01$ ), as was the difference in plasma half-life between gadopentetate and gadodiamide ( $P < .001$ ).

**Group 2**

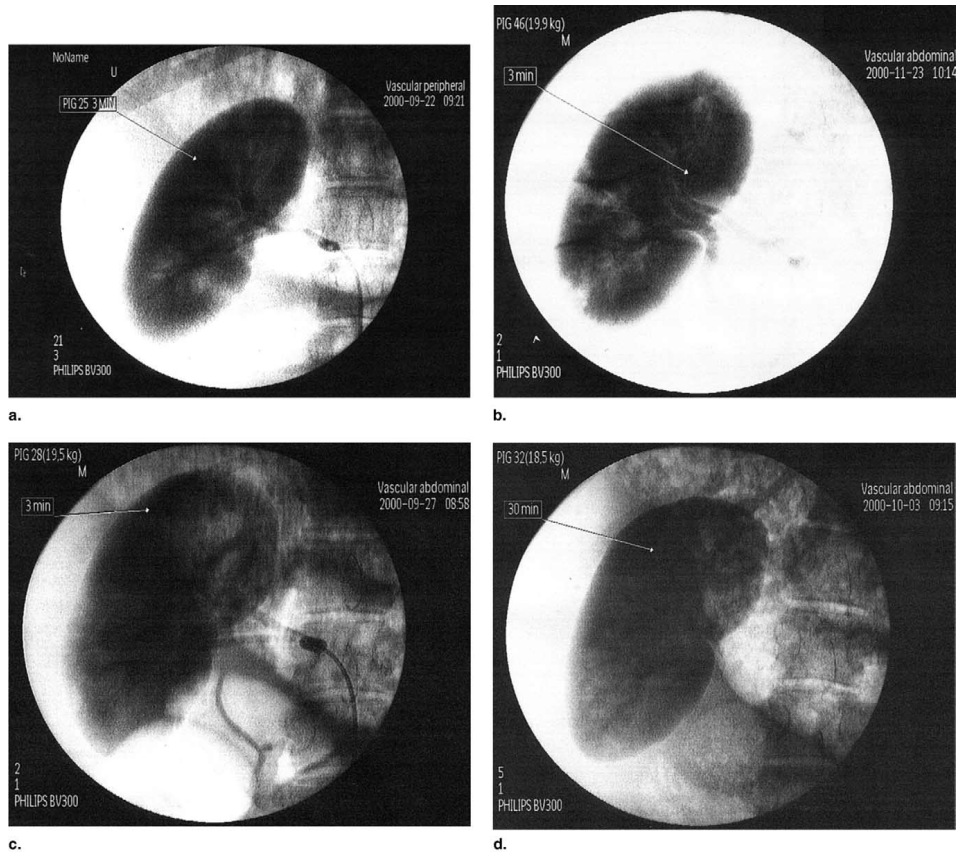
Again, there was no statistically significant difference between 0.18 M iohexol (70 mg I/mL; median time 174 minutes, range 162–210) and saline with ischemia (median time 196 minutes, range 167–316) regarding plasma half-life of the GFR markers. Nor was there any statistically significant difference between 0.18M iohexol (70 mg I/mL) with ischemia and saline without ischemia (median time 195 minutes, range 127–252).

**Radiograms**

Three and ten minutes after the start of CM injection, the use of 0.18 M iohexol (70 mg I/mL), gadodiamide, and gadopentetate resulted in a similar nephrographic attenuation, whereas 0.5 M iohexol (190 mg I/mL) cause a markedly higher radiodensity. Thirty minutes after the



**Figure 2.** Plasma half-life elimination time (median and range) of contrast medium clearance markers after injections into the occluded right renal artery of saline and 0.18 M iohexol (70 mg I/mL) and saline without occlusion of the renal artery after left-sided nephrectomy. Plasma concentrations were measured between 60 and 180 minutes after the start of contrast medium administration. In the saline group the plasma clearance marker (3 mL iohexol 300 mg I/mL) was injected together with saline into the renal artery. n.s., no statistically significant differences.



**Figure 3.** Radiographs showing the catheter placed in the renal artery and nephrograms obtained 3 minutes after the start of injection of (a) 0.18 M iohexol (70 mg I/mL), (b) 0.5 M iohexol (190 mg I/mL), (c) 0.5 M gadopentetate, and (d) 30 minutes after the injection of 0.5 M gadopentetate.

start of CM injection, excretion of the CM was visualized and there was no persisting nephrogram except for the animals that had received gadopentetate, which showed a persistent nephrogram (Fig 3).

## DISCUSSION

The present investigation was focused on comparing the nephrotoxicities of equal-attenuating concentrations of Gd-CM and I-CM, which in equal volumes were injected

into the renal artery. The concentration at which I-CM are equal-attenuating with 0.5 M Gd-CM may vary with the x-ray tube kilovoltage (kV) used (30), which, in turn, may depend on patient size. We therefore used a concentration of a commonly used nonionic monomeric I-CM causing roughly the same attenuation of x-rays as an 0.5 M Gd-CM at the commonly used 70–90 kV for XRA (ie, 0.18 M solution of iohexol [70 mg I/mL]) (21). We also used an 0.5 M iohexol solution (190 mg I/mL), which contains the same number of CM molecules as 0.5M Gd-

CM, but three times the number of attenuating atoms. Thus at 80 kV the attenuation of 0.5 M iohexol is almost three times that of 0.5 M Gd-CM. Iohexol (0.5 M) should also have a higher attenuation than 0.5 M Gd-CM at 96 kV, considered the optimal kV for Gd-CM (31), and at any higher used kV (110–120 kV) for angiography according to experimental results comparing the physical performances of different x-ray contrast agents (30,32).

The results of the present study support our previous assumption (21) that a plasma-isotonic solution (0.29 osmol/kg water) of a “low osmolality” 0.18 M I-CM is significantly less nephrotoxic than roughly equal-attenuating (at 80 kV) concentrations and doses of plasma-hypertonic solutions of two Gd-CM, 0.5 M gadodiamide (1.96 osmol/kg water), and gadopentetate (1.96 osmol/kg water) when injected into the renal artery. Iohexol 70 mg I/mL appeared to have no deleterious effect on renal function compared with saline. Although gadodiamide (2.7 times the osmolality human plasma) almost doubled the plasma half-life of the GFR marker compared with iohexol 70, gadopentetate (7 times the osmolality of human plasma) appeared to cause an almost complete cessation of renal function.

According to some advocates, 0.5 M Gd-CM (31) is equal-attenuating with I-CM in the 75–150 mg I/mL range when an x-ray tube voltage of 96 kV is applied. Applying the low-osmolality I-CM iohexol at an even higher iodine concentration (190 mg I/mL), which contains the same concentration of potentially nephrotoxic CM molecules as the 0.5 M Gd-CM, still resulted in a significantly shorter elimination half-life of the GFR marker than gadodiamide and gadopentetate in the present investigation. The osmolality of 0.5 M iohexol is only half that of 0.5 M gadodiamide (ie, 0.4 osmol/kg water). Thus, even in equimolar solutions, I-CM seem to cause less effect on renal function and at the same time improve diagnostic potentials through better radiographic contrast at all practically applied kilovoltages for angiography.

Determination of GFR as body clearance could not be calculated in the present experiment because the contrast media serving as GFR markers were injected directly into the renal arteries in most animals. Hence, an unknown fraction of the GFR markers never appeared in the general circulation but was filtered into the urine during their first pass through the kidneys. The amount of CM that escaped from the circulation through the glomerula into the renal tubules during the time of ischemia was not possible to account for and may have varied between different substances because of different degrees of renal inju-

ries. These factors should not affect the plasma CM half-life elimination time, because calculations of CM half-life are only dependent on relative changes in plasma concentration of CM over time. Therefore, calculated CM plasma half-lives in the present study have been used as an indicator of any difference in renal toxicity (ie, effect on GFR) of the various test solutions when calculated as body clearance. The volume of distribution (Vd) in the body of the various CM must be known or be reasonably estimated for calculation of body clearance (GFR) according to the formula in the appendix (33).

Vd could not be calculated in the present experiment for the two Gd-CM because they were only injected selectively into the renal artery with an unknown fraction escaping the general circulation. In spite of that, we think it is possible to make a reasonable comparison between the three CM with regard to their effect on total body clearance (representing GFR) according to the formula. Gadopentetate, gadodiamide, and iohexol all have high water-solubility, low binding to plasma proteins, main distribution in extracellular spaces, very small intracellular distribution, and a body clearance dominated by glomerular filtration (22–26). In man and several animal species, the plasma half-lives are shorter and the Vd tends to be smaller for the two Gd-CM than for I-CM (22–26). If the plasma half-lives in the present study should mean the same body clearance for the Gd-CM and the I-CM according to the formula, then the Vd in pigs for gadopentetate should be 23 times that of iohexol (3,340/143) and for gadodiamide 80% higher (256/143) than the Vd of iohexol. We think that these relations between the different CM with regard to Vd in pigs are very unlikely. We therefore conclude that, in our experimental model, Gd-CM caused more renal damage (reduction of body clearance) than the I-CM. This conclusion supports the position of the producers of Gd-CM that applying Gd-CM for XRA implies an “off-label” use.

Our results regarding the effect on renal function seems to be in accordance with another series of experiments (34,35). In an ischemic rat model it was found that intra-aortic injections of gadopentetate and diatrizoate, both with an osmolality of about 2.0 osmol/kg water, caused a similar decrease in GFR measured as creatinine clearance. However, the dose of iodine atoms appeared to have been 10 times higher than that needed to achieve the same attenuation as the Gd-CM during an XRA study at 80 kV (21). Thus if equal-attenuating doses had been used it seems reasonable to assume that the nephrotoxic effect of diatrizoate had been much less.



Radiographs of gadopentetate showed, unlike the other CM, a persistent nephrogram at 30 minutes after injection. It has been pointed out that a persistent nephrogram after administration of intravascular contrast media not only may be the result of a preexisting acute renal failure, but also may indicate renal impairment developed during the x-ray examination and caused by the applied CM, as in our pigs subjected to gadopentetate (36,37).

Several experimental animal models have been used to study CM-induced nephrotoxicity (1,34,35,38–40). We designed a porcine model with a high probability of CM nephrotoxicity by injecting high doses of CM selectively into the renal artery during a period of ischemia. The model was partly chosen because the use of Gd-CM has been advocated to guide treatment of renal artery stenoses with balloon angioplasty or stent placement (14–17), and such procedures will imply periods of renal ischemia. We also choose the pig because we were familiar with catheterization of porcine renal arteries from interventional training courses and because their kidneys are more like human kidneys with regard to anatomy and physiology than the kidneys of most other species (40–43). In an initial pilot study, we did not notice any effect on renal function when the CM were injected into patent renal arteries as had been found in an earlier canine study from our laboratory (44). Therefore, an ischemic period was added to the experiment, a well-established procedure to potentiate the nephrotoxic effect of CM (35,40,45,46). It is well known from both clinical and experimental studies that prior preconditioning is often necessary to make living species susceptible to CM-induced renal failure. Transient ischemia is only one of many models of experimental preconditioning (47,48).

The pathophysiologic mechanisms behind the noted effects on glomerular function in the present model may be multifactorial and dependent on chemotoxic and osmotic effects of the CM in combination with ischemia. It is noteworthy that the isotonic solution of iohexol 70 mg I/mL with 10 minutes of renal ischemia had no effect on plasma half-life elimination time of GFR markers—different from that of saline without ischemia. This may indicate that the 10-minute ischemic period per se did not immediately affect GFR.

The effect of balloon occlusion may instead of ischemia rather be due to prolongation of contact time between the more concentrated and hyperosmolar CM and red blood cells, vascular endothelial, and tubular cells. This may result in marked shrinkage and rigidification of red blood cells obstructing microcirculation (49–51) and

vascular endothelial injuries resulting in thrombotic occlusions (52,53). A nonosmolality-dependent release of vasoconstrictors has also been postulated (1). A direct toxic effect on tubular cells might also be possible (54).

Osmotic factors have been considered to play a significant role in the development of CMN (1) and may explain some of the differences noted between the various solutions in the present study. All hypertonic solutions significantly increased elimination half-life, increasing with the osmolality of the agents. Apart from the direct exposure of red blood cells, endothelial cells, and tubular cells to the hypertonic solutions injected into the renal artery, the CM also represent an osmotic load to the kidneys with secondary diuresis and natriuresis (1,55,56). Osmotic load may activate the tubuloglomerular feedback mechanism mediating vasoconstrictive agents, increase medullary oxygen demand for active reabsorption of the increased tubular sodium load resulting in hypoxic injuries, or increase intratubular pressure with elevation of interstitial pressure and secondary vascular compression beneath the rigid renal capsula.

There are also clinical studies (2,3,57) indicating that the use of CM causing a lower osmotic load on the kidneys will reduce the risk of the CMN in azotemic patients. When low-osmolality CM (eg, iohexol) was compared with high-osmolality CM (eg, diatrizoate) the CM representing the lower osmotic load reduced the risk of CMN (2,3). In a recent study comparing iohexol with the iso-osmolar iodixanol, a nonionic dimer representing an osmotic load still lower than that of iohexol, iodixanol caused less deterioration of renal function (57). Gadopentetate has an osmolality similar to that of diatrizoate 370 mg I/mL (76%) and gadodiamide the same as iohexol 350 mg I/mL. Thus, when equal volumes of the CM in the present study are compared, the Gd-CM represented a significantly higher osmotic load to the porcine kidneys than the iohexol solutions used (ie, 190 and 70 mg I/mL).

## CONCLUSION

To the best of our knowledge the present investigation represents the first comparison, including both experimental and human studies, between Gd- and I-CM regarding their nephrotoxic effects during XRA using equal-attenuating and equimolar concentration and doses. The results do not support the “off-label” use of Gd-CM for XRA in man instead of commercially available concentrations of

low-osmolality I-CM at 140, 150, and 180 mg I/mL or diluted to a concentration of about 70 mg I/mL.

## REFERENCES

- Morcos SK. Contrast medium-induced nephrotoxicity. In: Dawson P, Cosgrove DO, Grainger RG, eds. *Textbook of contrast media*. Oxford, UK: Isis Medical Media Ltd, 1999; 135-148.
- Rudnick MR, Goldfarb S, Wexler L, et al. Nephrotoxicity of ionic and nonionic contrast media in 1196 patients: a randomized trial. *Kidney Int* 1995; 47:254-261.
- Barrett BJ, Carlisle EJ. Metaanalysis of the relative nephrotoxicity of high- and low-osmolality iodinated contrast media. *Radiology* 1993; 188:171-178.
- Kerns SR, Hawkins IF. Carbon dioxide digital subtraction angiography: expanding applications and technical evolution. *AJR Am J Roentgenol* 1995; 164:735-741.
- Hawkins IF, Caridi JG. Carbon dioxide (CO<sub>2</sub>) digital subtraction angiography: 26-years experience at the University of Florida. *Eur Radiol* 1998; 8:391-402.
- Kaufman JA, Geller, Waltman AC. Renal insufficiency: gadopentate dimeglumine as a radiographic contrast agent during peripheral vascular interventional procedures. *Radiology* 1996; 198:579-581.
- Matchett JW, McFarland DR, Russell DK, Sailors DM, Moursi MM. Azotemia: gadopentate dimeglumine as contrast agent at digital subtraction angiography. *Radiology* 1996; 201:569-571.
- Prince RN, Arnoldus C, Frisoli JK. Nephrotoxicity of high-dose gadolinium compared with iodinated contrast. *J Magn Reson Imaging* 1996; 5:162-166.
- Spinosa DJ, Matsumoto AH, Hagspiel KD, Angle JF, Hartwell GD. Gadolinium-based contrast agents in angiography and interventional radiology. *AJR Am J Roentgenol* 1999; 173:1403-1409.
- Hammer FD, Goffette PP, Malaise J, Mathurin P. Gadolinium dimeglumine: an alternative contrast agent for digital subtraction angiography. *Eur Radiol* 1999; 9:128-136.
- Gemmete JJ, Forauer AR, Kazanjian S, Dasika N, Williams DM, Cho K. Safety of large volume gadolinium angiography. *J Vasc Interv Radiol* 2001; 12:S28.
- Spinosa DJ, Angle JF, Hagspiel KD, Kern JA, Hartwell GD, Matsumoto AH. Lower extremity arteriography with use of iodinated contrast material or gadodiamide to supplement CO<sub>2</sub> angiography in patients with renal insufficiency. *J Vasc Interv Radiol* 2000; 11:35-43.
- Sam AD 2nd, Morasch MD, Collins J, Song G, Chen R, Pereles FS. Safety of gadolinium contrast angiography in patients with chronic renal insufficiency. *J Vasc Surg* 2003; 38:313-318.
- Spinosa DJ, Matsumoto AH, Angle JF, Hagspiel KD. Use of gadopentate dimeglumine as a contrast agent for percutaneous transluminal renal angioplasty and stent placement. *Kidney Int* 1998; 53:503-507.
- Spinosa DJ, Matsumoto AH, Angle JF, et al. Gadolinium-based contrast and carbon dioxide angiography to evaluate renal transplants for vascular causes of renal insufficiency and accelerated hypertension. *J Vasc Interv Radiol* 1998; 9:909-916.
- Spinosa DJ, Matsumoto AH, Angle JF, Hagspiel KD, McGraw JK, Ayers C. Renal insufficiency: usefulness of gadodiamide-enhanced to supplement CO<sub>2</sub>-enhanced renal angiography for diagnosis and percutaneous treatment. *Radiology* 1999; 210:663-672.
- Spinosa DJ, Matsumoto AH, Angle JF, et al. Safety of CO<sub>2</sub>- and gadodiamide-enhanced angiography for the evaluation and percutaneous treatment of renal artery stenosis in patients with chronic renal insufficiency. *AJR Am J Roentgenol* 2001; 176:1305-1311.
- Erlly WK, Zaetta J, Borders GT, et al. Gadopentate dimeglumine as a contrast agent in common carotid arteriography. *Am J Neuroradiol* 2000; 21:964-967.
- Sarkis A, Badaoui G, Azar R, Sleilaty G, Bassil R, Jebara VA. Gadolinium-enhanced coronary angiography in patients with impaired renal function. *Am J Cardiol* 2003; 91:974-975.
- Bokhari SW, Wen YH, Winters RJ. Gadolinium-based percutaneous coronary intervention in a patient with renal insufficiency. *Catheter Cardiovasc Interv* 2003; 58:358-361.
- Nyman U, Elmståhl B, Leander P, Nilsson M, Golman K, Almén T. Are gadolinium-based contrast media really safer than iodinated media for digital subtraction angiography in patients with azotemia. *Radiology* 2002; 223:311-318.
- Almén T, Frennby B, Sterner G. Determination of glomerular filtration rate with contrast media. In: Thomsen HS, Muller RN, Mattrey RF, eds. *Medical radiology. Diagnostic imaging and oncology. Trends in contrast media*. Berlin: Springer-Verlag, 1999:81-94.
- Weinmann HJ. Gadolinium chelates: physico-chemical properties, formulation and toxicology. In: Dawson P, Cosgrove DO, Grainger RG, eds. *Textbook of contrast media*. Isis Oxford, UK: Medical Media Ltd, 1999:297-321.
- Weinmann HJ, Laniado M, Mützel W. Pharmacokinetics of GDTPA/dimeglumine after intravenous injection into healthy volunteers. *Physiol Chem Phys Med NMR* 1984; 16:167-172.
- Van Wagener M, Worah D. Gadodiamide injection. First human experience with the non-ionic magnetic resonance imaging enhancement agent. *Invest Radiol* 1993; 28:S44-S48.
- Olsson B, Aulie A, Sveen K, Andrew E. Human pharmacokinetics of iohexol: a new non-ionic contrast medium. *Invest Radiol* 1983; 18:177-182.
- Grönberg T, Almén T, Golman K, Liden K, Mattsson S, Sjöberg S. Noninvasive estimation of kidney function by x-ray fluorescence analysis. Method for in vivo measurements of iodine-containing contrast media in rabbits. *Phys Med Biol* 198; 26:501-506.
- Grönberg T, Sjöberg S, Almén T, Golman K, Mattsson S. Noninvasive estimation of kidney function by x-ray fluorescence analysis. Elimination rate and clearance of contrast media injected for urography in man. *Invest Radiol* 1983; 18:445-452.
- Lorusso V, Arbughi T, Tirone P, de Haen C. Pharmacokinetics and tissue distribution in animals of gadobenate ion, the magnetic resonance imaging contrast enhancing component of gadobenate dimeglumine 0.5 M solution for injection (MultiHance). *J Comput Assist Tomogr* 1999; 23:S181-S194.
- Cardinal HN, Holdsworth DW, Drangova M, Hobbs BB, Fenster A. Experimental and theoretical x-ray imaging performance comparison of iodine and lanthanide contrast agents. *Med Phys* 1993; 20:15-31.
- Spinosa DJ, Kaufmann JA, Hartwell GD. Gadolinium chelates in angiography and interventional radiology: a useful alternative to iodinated contrast media for angiography. *Radiology* 2002; 223:319-325.
- Sandborg M, Christofferson JO, Carlsson GA, Almén T, Dance DR. The physical performance of different x-ray contrast agents: calculations using a Monte Carlo model of the imaging chain. *Phys Med Biol* 1995; 40:1209-1224.
- Greenblatt DJ, Shader RI. In: *Pharmacokinetics in clinical practice*. Philadelphia: W.B. Saunders Company, 1985; 7-20, 33-42.
- Brillet G, Dubois M, Beaufils H, Bourbouze R, Deray G. Renal tolerance of gadolinium-DOTA and gadolinium-DTPA in rats. *Invest Radiol* 1994; 29:352-354.
- Deray G, Dubois M, Martinez F, et al. Renal effects of radiocontrast agents in rats: a new model of acute renal failure. *Am J Nephrol* 1990; 10:507-513.
- Older R, Miller J, Jackson D, Johusrude I, Thompson W. Angiographically induced renal failure and its radiographic detection. *AJR Am J Roentgenol* 1976; 126:1039-1045.
- Older RA, Korbkin M, Cleve DM, Schaaf R, Thompson W. Contrast-induced acute renal failure: persistent Nephrogram as a clue to early detection. *AJR Am J Roentgenol* 1980; 134:339-342.
- Thomsen HS, Dorph S, Larsen S, et al. Urine profiles and kidney histology after intravenous injection of ionic and nonionic radiologic and magnetic resonance contrast media in rats with cisplatin nephropathy. *Acad Radiol* 1995; 2:675-682.
- Obrez I, Abrams H L. Temporary occlusion of the renal artery: effects and significance. *Radiology* 1972; 104:545-556.
- Idée JM, Bonnemain B. Reliability of experimental models of iodinated contrast media-induced acute renal failure. From methodological considerations to pathophysiology. *Invest Radiol* 1996; 31:230-241.
- Bokhari SW. Swine as a model in renal physiology and nephrology: an overview. In: Tumblesone ME, ed. *Swine in biomedical research, Vol II*. New York: Plenum Press, 1986:1673-1690.

42. Swindle MM, Smith AC. Comparative anatomy and physiology of the pig. *Scand J Lab Anim Sci* 1998; 25(Suppl. 1):11-21.
43. Dondelinger RF, Ghysels MP, Brisbois D, et al. Relevant radiological anatomy of the pigs as a training model in interventional radiology. *Eur Radiol* 1998; 8:1254-1273.
44. Törnquist C, Almén T, Golman K, Holtås S. Renal function following nephroangiography with metrizamide and iohexol. Effects on renal blood flow, glomerular permeability and filtration rate and diuresis in dogs. *Acta Radiol* 1985; 26:483-489.
45. Almén T, Bergquist D, Cederholm C, et al. Interactive effects on renal function between ischemia and intravascular contrast media. *Invest Radiol* 1988; 23:S161-S163.
46. Lund G, Einzig S, Rysavy J R, et al. Role of ischemia in contrast-induced renal damage: an experimental study. *Circulation* 1984; 69:783-789.
47. Heyman S, Rosen S, Brezis M. Radiocontrast nephropathy: a paradigm for the synergism between toxic and hypotoxic insult in the kidney. *Exp Nephrol* 1994; 2:153-157.
48. Heyman S N, Brezis M, Reubinoff CA, et al. Acute renal failure with selective medullary injury in the rat. *J Clin Invest* 1988; 82:401-412.
49. Garber GL, Read RC. Red cell factor in renal damage from hypertonic solutions. *Proc Soc Exp Biol Med* 1961; 107:165-168.
50. Aspelin P. Effect of ionic and non-ionic contrast media on red cell deformability in vitro. *Acta Radiol* 1979; 20:1-12.
51. Aspelin P, Nilsson PE, Schmid-Schonbein H, Schroder S, Simon R. Effect of four non-ionic contrast media on red blood cells in vitro. III. Deformability. *Acta Radiol Suppl* 1987; 370:89-91.
52. Nyman U, Almén T. Effects of contrast media on aortic endothelium. Experiments in the rat with non-ionic and ionic monomeric and monomeric dimeric contrast media. *Acta Radiol Suppl* 1980; 362:65-71.
53. Almén T, Bergentz S-E, Törnquist C, Öystese B. Selective nephroangiography in the dog causing renal platelet aggregation and irregular nephrographic phase. *Acta Radiol* 1985; 26:627-634.
54. Barrett BJ. Contrast nephrotoxicity. *J Am Soc Nephrol* 1994; 5:125-137.
55. Heyman SN, Reichman J, Brezis M. Pathophysiology of radiocontrast nephropathy. A role for medullary ischemia. *Invest Radiol* 1999; 34:685-691.
56. Katzberg, Richard W. Urography into the 21st century: new contrast media, renal handling, imaging characteristics, and nephrotoxicity. *Radiology* 1997; 204:297-312.
57. Aspelin P, Aubry P, Fransson S-G, Strasser R, Willenbrock R, Berg K-J. Nephrotoxic effects in high-risk patients undergoing angiography. *N Engl J Med* 2003; 348:491-499.

## APPENDIX

Formula regarding the relation between total body clearance, volumes of distribution, and plasma half-life:

Total body clearance (mL/min) =  $\ln 2 \times V_d / \text{plasma half-life}$ .

In, natural logarithm; V<sub>d</sub>, volume of distribution in mL; T, half-life elimination time (minutes) of GFR marker.