



# LUND UNIVERSITY

## Local Infusion of the Nitric oxide Donor Sin-1 After Angioplasty: Effects on intimal hyperplasia in porcine coronary arteries

Harnek, Jan; Zoucas, E.; Sjuve, R.; Arner, Anders; Ekblad, E.; Schou, Henning; Perez de Sá, Valéria; Stenram, Unne

*Published in:*  
Acta Radiologica

*DOI:*  
[10.1034/j.1600-0455.2003.00079.x](https://doi.org/10.1034/j.1600-0455.2003.00079.x)

2003

[Link to publication](#)

### *Citation for published version (APA):*

Harnek, J., Zoucas, E., Sjuve, R., Arner, A., Ekblad, E., Schou, H., Perez de Sá, V., & Stenram, U. (2003). Local Infusion of the Nitric oxide Donor Sin-1 After Angioplasty: Effects on intimal hyperplasia in porcine coronary arteries. *Acta Radiologica*, 44(4), 395-402. <https://doi.org/10.1034/j.1600-0455.2003.00079.x>

*Total number of authors:*  
8

### General rights

Unless other specific re-use rights are stated the following general rights apply:

Copyright and moral rights for the publications made accessible in the public portal are retained by the authors and/or other copyright owners and it is a condition of accessing publications that users recognise and abide by the legal requirements associated with these rights.

- Users may download and print one copy of any publication from the public portal for the purpose of private study or research.
- You may not further distribute the material or use it for any profit-making activity or commercial gain
- You may freely distribute the URL identifying the publication in the public portal

Read more about Creative commons licenses: <https://creativecommons.org/licenses/>

### Take down policy

If you believe that this document breaches copyright please contact us providing details, and we will remove access to the work immediately and investigate your claim.

LUND UNIVERSITY

PO Box 117  
221 00 Lund  
+46 46-222 00 00



# LOCAL INFUSION OF THE NITRIC OXIDE DONOR SIN-1 AFTER ANGIOPLASTY

## Effects on intimal hyperplasia in porcine coronary arteries

J. HARNEK<sup>1</sup>, E. ZOUCAS<sup>2</sup>, R. SJUVE<sup>3</sup>, A. ARNER<sup>3</sup>, E. EKBLAD<sup>3</sup>, H. SCHOU<sup>4</sup>, V. PEREZ DE SÁ<sup>4</sup> and U. STENRAM<sup>5</sup>

<sup>1</sup>Heart Lung Division, Heart Radiology, Departments of <sup>2</sup>Surgery, <sup>3</sup>Physiological Sciences, <sup>4</sup>Pediatric Anesthesiology and

<sup>5</sup>Pathology, University Hospital Lund, Lund, Sweden.

### Abstract

**Purpose:** To investigate the development of intimal hyperplasia in response to percutaneous transluminal coronary angioplasty (PTCA) followed by local delivery of the nitric oxide (NO) donor 3-morpholino-sydnimine (SIN-1).

**Material and Methods:** Overdilation PTCA was performed in coronary arteries in 20 healthy pigs. One of the dilated segments was additionally treated with local delivery of SIN-1 for 10 min. Segments distal to the treated part of the arteries served as controls. Arteries were radiographically depicted and analyzed after 1 and 8 weeks for actin, myosin and intermediate filaments (IF), nitric oxide synthetase (NOS) and histological evaluation.

**Results:** Segments treated with PTCA+SIN-1 showed a significantly ( $p=0.03$ ) larger luminal diameter compared with PTCA only treated segments. The luminal loss after SIN-1 was not significant compared with the diameter prior to treatment. Endothelial NOS content was significantly lower in the PTCA+SIN-1 group compared with the PTCA group after 1 ( $p=0.03$ ) and 8 weeks ( $p=0.013$ ). IF/actin ratio after 1 week was significantly increased in PTCA-treated segments compared with untreated controls ( $p=0.004$ ), and compared with PTCA+SIN-1-treated segments ( $p=0.004$ ).

**Conclusion:** PTCA-induced intimal hyperplasia was potently inhibited by local delivery of the NO donor SIN-1. Momentary events at the time of injury play a significant role in the development of intimal hyperplasia and long-lasting down-regulation of the endothelial NOS expression after SIN-1 exposure is suggested. The IF/actin ratio can be useful as an early marker of intimal hyperplasia.

**Key words:** Angioplasty; endothelial factors; nitric oxide; remodeling; restenosis; experimental.

**Correspondence:** Jan Harnek, Heart Radiology, Heart Lung Division, University Hospital SE-22185 Lund, Sweden.

FAX +46 46 211 69 56.

E-mail: jan.harnek@skane.se

Accepted for publication 20 February 2003.

Occlusive disease of the coronary arteries is the most common problem in the spectrum of cardiovascular disease. Percutaneous transluminal coronary angioplasty (PTCA) is the preferred treatment in more than 50% of these patients. However, the high incidence of restenosis after balloon angioplasty, in several studies reaching 30–50%, limits the long-term success of the procedure (13). Constrictive remodeling and smooth muscle cell (SMC) proliferation are the most important mechanisms behind restenosis after angioplasty (18).

Endothelial injury after PTCA is extensive and the remaining damaged cells and denuded basal membrane facilitates adhesion and aggregation of platelets. Over-dilatation of the arterial wall has been shown to damage about 20% of the SMCs in the treated area (15). Signal substances from the injured arterial wall, such as basic fibroblast growth factor (bFGF), initiate proliferation and factors such as platelet-derived growth factor (PDGF) stimulate migration of SMC to the intima (12), contributing to formation of intimal hyperplasia.

Nitric oxide (NO) reduces these events, and modulates several physiological processes in the vasculature, including vascular tone, platelet aggregation and adhesion, leukocyte adhesion to the endothelium besides reducing SMC migration and proliferation after PTCA (16).

Data from animal studies showed the inhibitory effect of dietary administration of the amino acid L-arginine, the substrate for NO production, on the development of restenosis. Besides, local drug delivery with L-arginine (23), and a multicenter study (17) suggested a promising role for NO donors in the prevention of intimal hyperplasia in humans.

The aim of the present study was to evaluate the effect of local delivery of SIN-1, which releases NO by spontaneous degradation, on the development of intimal hyperplasia after PTCA.

### Material and Methods

The investigation conformed to the Guide for the Care and Use of Laboratory Animals (NIH Publication no. 85-23, revised 1996) and the study was approved by the local committee for animal research. Twenty domestic pigs of both sexes weighing  $20.1 \pm 0.9$  kg were fasted overnight with free access to water and were premedicated with azaperone (Stresnil Vet., Leo),  $2 \text{ mg kg}^{-1}$  intramuscularly 30 min before the procedure. After induction of anesthesia with thiopental  $5\text{--}25 \text{ mg kg}^{-1}$  (Pentothal, Abbott), the animals were orally intubated with cuffed endotracheal tubes. A slow infusion of Fentanyl (Pharmalink AB) in Ringer acetate at a rate of  $1.25 \mu\text{g ml}^{-1}$  was started at a rate of  $1.5 \text{ ml min}^{-1}$  and adjusted as required. Mechanical ventilation was then established with a Siemens-Eléma 300B ventilator in the volume-controlled mode. Initial settings were a respiratory rate of 15 per minute, a tidal volume of  $10 \text{ ml kg}^{-1}$ , and positive end-expiratory pressure of  $5 \text{ cm H}_2\text{O}$ . Minute volume was subsequently adjusted in order to obtain normocapnia ( $35\text{--}40 \text{ mm Hg}$ ). The animals were ventilated with a mixture of nitrous oxide (70%) and oxygen (30%). Hypnosis was complemented with small intermittent doses of  $5 \text{ mg}$  meprobamat (Mebumal, DAK), if required.

An 8 F introducer sheath (Onset, Cordis Co.) was inserted into the surgically exposed left carotid artery and  $10,000 \text{ IU}$  of heparin given. The side port of the introducer was connected to a pressure transducer and balanced to atmospheric pressure with zero reference at the mid-axillary level for continuously monitoring of the arterial pressure. Cardiac rhythm and rate were monitored simultaneously. An angiogram of the coronary arteries was

obtained via an 8 F JL 3.0 guide catheter with perfusion ports (Pink Power, Schneider, Bülach, Switzerland) using  $5\text{--}8 \text{ ml}$  of contrast medium (Omnipaque  $300 \text{ mg I/ml}^{-1}$ , Amersham Health).

Overdilation PTCA was randomly performed in either the left anterior descending artery (LAD) ( $n = 8$ ) or in the left circumflex artery (LCX) ( $n = 4$ ) and in 1 pig in the right coronary artery (RCA) followed by injection of SIN-1. Finally, overdilation PTCA was performed in the corresponding still untreated LAD ( $n = 4$ ) or LCX ( $n = 8$ ) for 30 s. The diameters of the vessels were estimated from a video recording of the fluoroscopic image, the guide catheter being used as a reference. The medial part of the LAD or the LCX after the first marginal branch was dilated at 6 atm with a  $2.5\text{--}3.5 \times 20 \text{ mm}$  dilatation balloon (Viva, Scimed Inc., Maple Grove, MN, USA) inserted over a 0.014-inch floppy guide-wire (Choice Plus, Scimed Inc.). The balloons were oversized by 0.5 mm in diameter. Inflation time was 30 s, and immediately after deflation a corresponding  $3 \text{ or } 3.5 \times 20 \text{ mm}$  drug delivery catheter (Dispatch, Scimed Inc.) was inserted into the PTCA-treated site and inflated at  $8\text{--}10 \text{ atm}$ . Efforts were made to minimize the time from balloon angioplasty to the time of drug treatment (approximately 1 min), in order to avoid thrombus formation and adverse effects. Injection of  $7.2 \pm 0.6 \text{ ml } 10^{-4} \text{ M SIN-1}$  was given manually at a rate of  $0.5\text{--}1 \text{ ml min}^{-1}$  for 10 min. SIN-1 was injected manually because in this way it could be determined from the resistance of the syringe, whether a major side-branch was draining the drug from the drug delivery balloon.

During coronary artery occlusion, perfusion pressure was increased by a dopamine infusion and small doses of norepinephrine ( $10 \mu\text{g}$ ). Xylocain  $10 \text{ mg kg}^{-1}$  was injected i.v. before releasing the occlusion to prevent the occurrence of malignant arrhythmias during reperfusion, and nitroglycerine (Perlinganite, Orion Pharma),  $100 \mu\text{g}$ , was given if needed as an intracoronary injection both before and after occlusion.

The catheters were withdrawn after a final angiogram to ensure patency of the vessels. The left carotid artery was surgically reconstructed, and the skin sutured. Post-operatively, the pigs received  $0.15 \text{ mg}$  buprenorphine (Temgesic, Reckitt & Colman, Hull, England) and  $5 \text{ ml}$  Streptocillin Vet. (Boehringer Ingelheim).

One week after the angioplasty, one group of 6 pigs was sedated and euthanized with an intracardiac injection of  $40 \text{ mmol}$  potassium chloride (Addex-Kalium, Pharmacia & Upjohn). The treated arteries were harvested immediately, using a microsurgical technique. A segment was obtained distal

to the treated area and served as a control. The vessel segments were analyzed electrophoretically for protein content and with NADPH diaphorase histochemistry in order to visualize the presence of NOS.

Eight weeks post-operatively, a second group of 7 pigs was euthanized as described above. The arteries were ligated distal to the treated segments, angiograms obtained and the arteries perfusion-fixed at 100 mmHg with 4% formaldehyde before harvesting and evaluating using routine histology and NADPH histochemistry. A perfusion-fixed vessel segment distal to each of the treated areas was harvested as well and served as a control.

**Angiographic examination:** Fluoroscopic video recordings and angiographic stills were examined. Using the guide catheter as a reference, the luminal diameter was calculated before, immediately after treatment, and after 8 weeks.

**Electrophoretic examination:** To investigate the relative content of actin, myosin and intermediate filament protein (IF), the proteins were separated on one-dimensional sodium dodecyl sulfate-polyacrylamide gel electrophoresis (SDS-PAGE). The vascular preparations were homogenized in an SDS buffer [composition: 25 mM tris (hydroxymethyl) aminomethane HCl (pH 6.8), 2% SDS, 5% mercaptoethanol and 10% glycerol] at a concentration of  $50 \mu\text{g mg}^{-1}$  tissue wet weight. The homogenate was then boiled for 2 min and centrifuged at 10,000 r.p.m. for 5 min. The supernatant was removed and stored at  $-20^{\circ}\text{C}$  before electrophoretic analysis. The SDS-PAGE was performed essentially as described by MALMQVIST et al. (20) using 8% polyacrylamide gels in a Bio Rad minigel system. The gels were stained with Coomassie blue, destained and scanned using a GS-300 densitometer (Hoeffer Scientific Instruments, San Francisco, CA, USA). The areas under the myosin heavy chains, actin and IF bands were evaluated. The ratios of actin/myosin and IFs/actin were calculated from these areas. Western blot analysis was performed using the proteins from the 8% polyacrylamide gels transferred to nitrocellulose (Hybond-C, Amersham). The nitrocellulose was blocked with milk powder and incubated with antibodies to the IF proteins desmin and vimentin. After incubation with a secondary peroxidase-conjugated antibody (anti-rabbit IgG, Sigma) the antibody-antigen reaction was visualized on an photographic film, using enhanced chemiluminescence (ECL, Amersham) and then scanned desitometrically (Fig. 1).

**NADPH histochemistry:** The vascular segments were fixed overnight in a mixture of 2% formaldehyde and 0.2% picric acid in phosphate buffer (pH 7.2) or in buffered 4% formaldehyde, followed by thorough rinsing in Tyrode solution containing 10% sucrose.

Specimens were then frozen on dry ice and cut in a cryostat at a thickness of  $10 \mu\text{m}$ . NADPH diaphorase activity was rendered visible by incubation of the sections for 45 min at  $37^{\circ}$  in 0.1 M tris-HCl (pH 7.2) containing 1 mM NADPH (Sigma), and 0.2% Triton X-100, followed by washing in tris-HCl (11).

Each segment was cut into three sections, examined under a light microscope and photographed with maximum of light, creating a completely yellow photograph in which only NADPH cells stained dark blue. The images obtained were transferred to a CD-ROM (Kodak format) and imported into Photoshop 4.0 (Adobe Inc.). These photographs were subtracted into black and white images. Due to the gray scale practically only the NADPH-stained endothelial cells were black. A  $45 \times 15 \text{ mm}$  representative portion of the cross-sectional area consisting of endothelium and media was selected. From the histogram menu, the percentage of black pixels in the photo was registered as a percentage of the total number of pixels in the selection.

**Histomorphological examination:** Each sample was cut further into 4–14 sections, which were stained with hematoxylin-eosin for routine histological evaluation. A similar number of sections was cut and stained with van Gieson elastica and used for the morphological measurements. The measurements were performed without knowledge of the treatment to the segments.

The intimal (I), medial (M), and luminal (L) areas as well as the internal elastic lamina (IEL) circumference and the IEL fracture length (F) were measured using computerized digital planimetry with a video microscope (Olympus BX 50 F4) and customized software (Analysis 3.0; Soft Imaging System). Vessel size was assessed by measuring the area circumscribed by the outer border of the external elastic lamina (EEL area). The extent of injury was represented by the fracture length (F) of the IEL, normalized for the size of the artery by the circumference of the IEL: injury index =  $F/\text{IEL}$ . Intimal hyperplasia was also normalized for the total artery wall area:  $I/(I+M)$ . The restenosis index =  $[I/(I+M)]/(F/\text{IEL})$  (3) could then be established taking into account the degree of injury. Changes in vessel geometry after injury and repair were reflected as the residual lumen and defined as  $L/(L+I)$ .

**Statistics:** Mann-Whitney's test was used for statistical evaluation.  $p$ -values  $<0.05$  were considered significant. Data are presented as mean  $\pm$  SEM.

## Results

Seven pigs died due to ventricular fibrillation, which was resistant to cardiac resuscitation, and these animals were excluded from further analysis. One

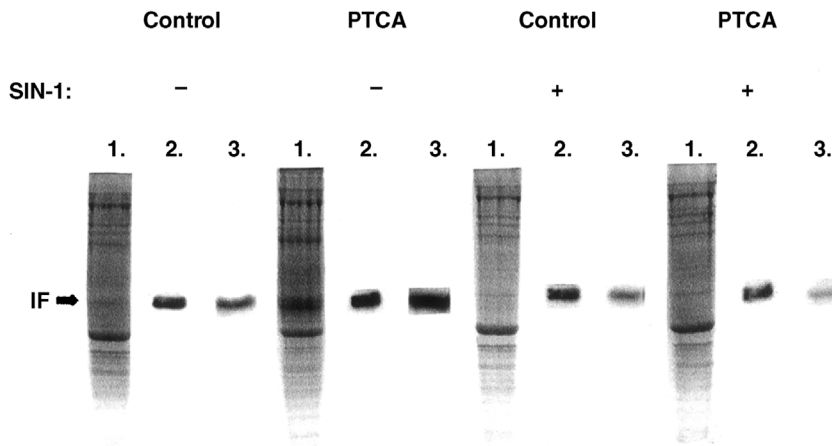


Fig. 1. Coomassie-stained SDS-PAGE (lane 1) of preparations from control and PTCA-treated segments and Western blot analysis using vimentin (lane 2) and desmin (lane 3) antibodies. Segments subjected to treatment with SIN-1 are denoted +. Note the increase in lane 3 “-” of PTCA compared with the other lanes describing the antibody-antigen reaction to desmin.

of these pigs died before catheterization, 2 after PTCA was performed, 3 immediately after PTCA and PTCA+SIN-1 and 1, 30 min after the procedure. The response to treatment did not differ between the LAD and the LCX.

**Blood pressure and heart rate measurements:** Heart rate was significantly ( $p = 0.041$ ) increased when SIN-1 was infused ( $112.2 \pm 11.5$  b.p.m.), compared with the heart rate before the procedure ( $85.8 \pm 6.3$  b.p.m.).

The systolic blood pressure before the procedure was  $81.5 \pm 3.2$  mm Hg and increased during PTCA to  $94.1 \pm 4.4$  mm Hg ( $p = 0.012$ ), and during SIN-1  $95.0 \pm 2.5$  mm Hg ( $p = 0.026$ ). The blood pressure after PTCA was  $94.6 \pm 5.0$  mm Hg ( $p = 0.007$ ) and after SIN-1  $95.0 \pm 2.8$  mm Hg ( $p = 0.024$ ). However, both heart rate and blood pressure were equal in the PTCA and the PTCA-SIN-1 groups during treatment.

**Angiographic examination of the luminal diameter:** The immediate posttreatment angiograms showed signs of non-occlusive thrombus formation in 2 arteries and in 10 arteries signs of dissection and spasm; these findings were equally distributed among groups, and might be due to the lack of premedication with an antiplatelet agent. After 8 weeks, all treated arteries were open.

At the treatment day the balloon angioplasty resulted in an increased luminal diameter, in the PTCA group from  $2.21 \pm 0.07$  mm to  $2.47 \pm 0.11$  mm and in the PTCA-SIN-1 group from  $2.21 \pm 0.11$  mm to  $2.45 \pm 0.11$  mm.

After 8 weeks the PTCA group had a significantly ( $p = 0.03$ ) smaller luminal diameter ( $1.91 \pm 0.18$  mm), compared with the PTCA-SIN-1 group ( $2.45 \pm 0.10$  mm), and had developed a significant luminal loss compared with the diameter immediately after angioplasty ( $p = 0.018$ ).

**Biochemical analysis of the effect of SIN-1 on IF proteins 1 week after treatment:** Photographs of gel

separations of proteins are shown in Fig. 1. A dramatic increase in IF proteins (lane 1) in arteries treated with PTCA in the absence of SIN-1 was observed. Western blot analysis revealed that the increase in IF in PTCA-treated arteries not receiving SIN-1 was mainly due to an increase in desmin.

Figure 2 depicts the ratio of IF to actin in treated and control segments. PTCA caused a significant increase in the ratio compared with the control, which was not present after exposure to SIN-1.

We could not detect any statistically significant changes in the relative amount of myosin heavy chain normalized to actin. The corresponding values for myosin/actin were PTCA:  $0.39 \pm 0.13$  and PTCA+SIN-1:  $0.43 \pm 0.10$  and their corresponding controls  $0.38 \pm 0.04$  and  $0.46 \pm 0.08$ .

**NADPH histochemistry of NOS contents 1 and 8 weeks after treatment:** NOS content in the endothelium was significantly lower in the treated segments of the PTCA-SIN-1 group  $0.34 \pm 0.03\%$ , compared with the PTCA group,  $0.51 \pm 0.03\%$  ( $p = 0.030$ ) 1 week postoperatively. After 8 weeks there was still significantly less NOS in the endothelium in the segments treated with PTCA-SIN-1,  $0.37 \pm 0.05\%$ , than in segments treated with PTCA alone,  $0.60 \pm 0.05\%$  ( $p = 0.013$ ) (Fig. 3a, b).

In control segments distal to the treated segments no significant difference in NADPH content was found between the groups either 1 week after PTCA,  $0.49 \pm 0.05\%$  and PTCA+SIN-1,  $0.42 \pm 0.03\%$ , or after 8 weeks (Fig. 3c).

**Morphological examination of the development of intimal hyperplasia after 8 weeks:** The histopathological characteristics of the coronary arteries are summarized in the Table.

Arteries treated with SIN-1 after PTCA showed a significantly reduced intimal area, intimal

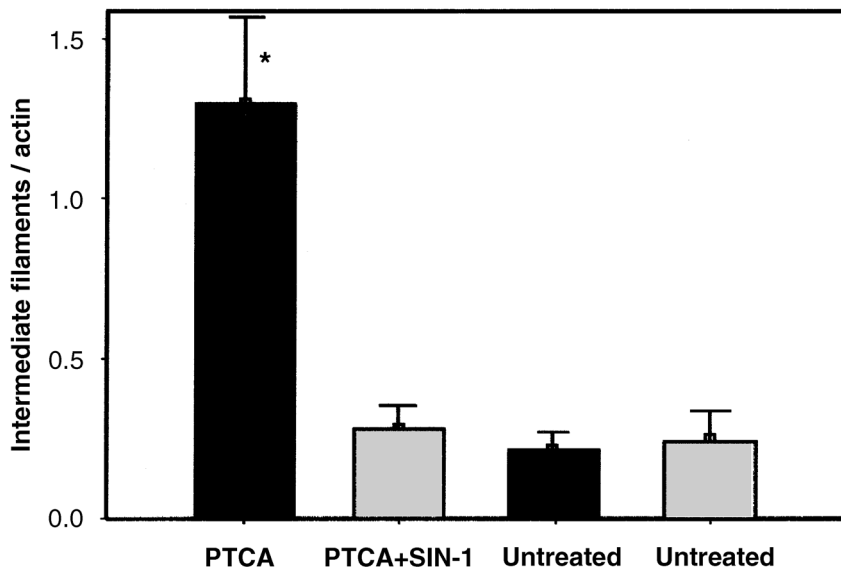


Fig. 2. One week after treatment. Ratio of IF proteins to actin in coronary arteries subjected to PTCA, PTCA and a brief exposure to SIN-1. Corresponding segments of the same vessels were used as controls 1 and 2, respectively. A statistically significant inhibition of the PTCA-induced increase in the IF/actin ratio was observed in the arteries exposed to SIN-1 (\* $p = 0.004$ ). All groups summarize data from 6 animals. Data are presented as mean  $\pm$  SEM.

hyperplasia and restenosis index as well as a significantly increased residual lumen compared with arteries treated with PTCA alone.

There was no difference between the untreated control segments, so those segments were incorporated into a single group. Arteries treated with SIN-1 after PTCA showed a significantly reduced intimal area ( $p = 0.002$ ), restenosis index ( $p = 0.018$ ) and intimal hyperplasia ( $p = 0.001$ ) compared with PTCA alone-treated arteries. Besides the residual lumen was significantly larger in PTCA+SIN-1-treated segments compared with PTCA alone-treated segments ( $p = 0.001$ ).

The correlation between fracture length and development of intimal hyperplasia is shown in Fig. 4.

### Discussion

This study shows that if the NO donor SIN-1 is delivered at the site of PTCA injury for 10 min, restenosis is significantly decreased. We found that intimal thickening after vessel injury can be halted or changed in a way that might prevent increased amounts of myofibroblasts in the media and which maintains the content of NOS in the intima up to 8 weeks after injury.

Application of a NO donor was chosen in the present study, as NO may interfere with the process of restenosis at several levels. NO has inhibitory effects on platelet adhesion and aggregation (9), and reduces the synthesis of DNA in SMCs and has an inhibitory effect on SMC proliferation (1). High NO concentrations induce endothelial apoptosis, whereas low NO concentrations contribute to human endothelial cell survival (4). Finally, NO has a beneficial effect on arterial remodeling (7).

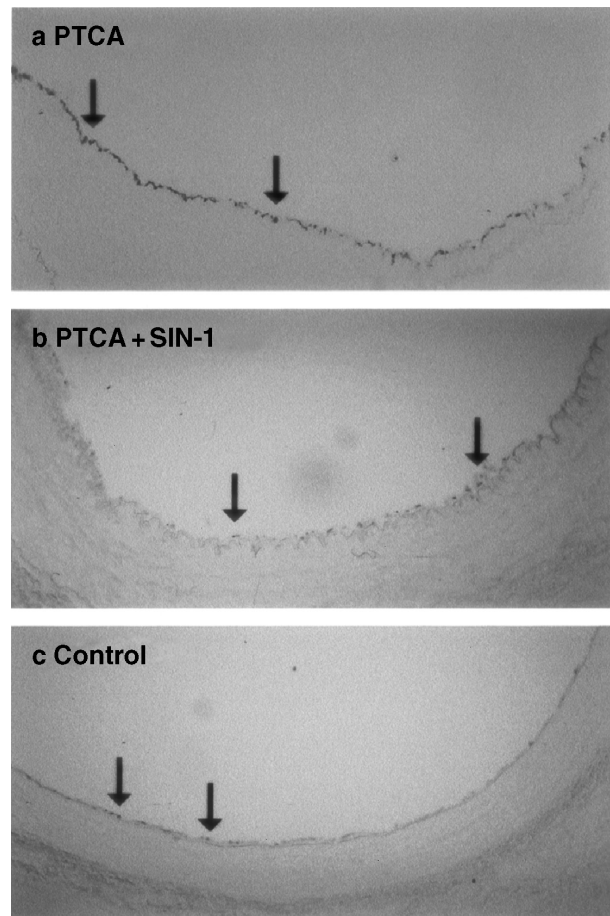


Fig. 3. a) PTCA, b) PTCA+SIN-1, c) control. Diaphorase histochemistry demonstrating (16 $\times$ ) NOS content (black arrows) in the endothelium 8 weeks after injury.

The biological half-life of NO is less than 1 s *in vivo*, which could explain the modest effect of i.v. or oral administration of sydnonimines on restenosis

Table

*Histopathological characteristics of coronary arteries 8 weeks after treatment with PTCA+SIN-1 and PTCA and the control segment*

8 weeks after treatment	SIN-1 Mean $\pm$ SEM	PTCA Mean $\pm$ SEM	Distal control	<i>p</i> -value SIN-1 vs. PTCA
External elastic lamina (EEL), mm <sup>2</sup>	2.51 $\pm$ 0.32	2.80 $\pm$ 0.30	2.09 $\pm$ 0.31	NS
Medial area (M), mm <sup>2</sup>	0.90 $\pm$ 0.07	0.97 $\pm$ 0.13	0.69 $\pm$ 0.13	NS
Intimal area (I), mm <sup>2</sup>	0.27 $\pm$ 0.03	0.93 $\pm$ 0.18	0.07 $\pm$ 0.02	0.002
Luminal area (L), mm <sup>2</sup>	1.34 $\pm$ 0.25	0.91 $\pm$ 0.13	1.33 $\pm$ 0.20	NS
Internal elastic lamina length (IEL), mm	3.60 $\pm$ 0.33	3.18 $\pm$ 0.20	3.03 $\pm$ 0.22	NS
Fracture length (F), mm	1.07 $\pm$ 0.09	1.10 $\pm$ 0.14	0.00 $\pm$ 0.00	NS
Injury index*	0.36 $\pm$ 0.07	0.38 $\pm$ 0.06	0.00 $\pm$ 0.00	NS
Residual lumen†	0.80 $\pm$ 0.04	0.52 $\pm$ 0.06	0.94 $\pm$ 0.01	0.001
Restenosis index‡	0.80 $\pm$ 0.13	1.49 $\pm$ 0.20		0.018
Intimal hyperplasia§	0.23 $\pm$ 0.03	0.46 $\pm$ 0.05	0.08 $\pm$ 0.01	0.001

Mann-Whitney test was used for statistical evaluation. \*Injury index: IEL fracture length/IEL circumference. †Residual lumen:  $L/(L+I)$ . ‡Restenosis index:  $(I/I+M)/(F/IEL)$ . §Intimal hyperplasia:  $I/(I+M)$ .

after PTCA in the ACCORD study (17). Due to immediate degradation of NO to nitrate when exposed to oxyhemoglobin (2), we chose a site-specific delivery of SIN-1 with the Dispatch balloon. SIN-1, although administered locally, probably escaped into the systemic circulation, but without negative side-effects on blood pressure and heart rate. The ischemic response from the myocardium during occlusion with expected lowering of blood pressure was probably over-adjusted by the dopamine infusion and intermittent boluses of norepinephrine, because we found a similar but significant increase in heart rate and mean blood

pressure during occlusion time in both treatment groups.

Dilatation with oversized balloon catheters causes trauma to the vessel wall with almost total loss of endothelial cells (10). Because only additional damage could be the result of the drug delivery catheter, we found that in controls using saline as a vehicle would not be as elucidating as in the vessel distally to the treated segment. Several studies have shown that PTCA after saline infusion with the drug delivery catheter increases neointimal formation, reduces thrombolysis in myocardial infarction (TIMI) (8) flow and increases thrombus formation (21). In this study even though the arteries treated with SIN-1 were dilated with slightly higher pressure and for a longer time, they still showed less intimal hyperplasia due to SIN-1. The use of the high-profile Dispatch catheter in humans is not recommendable, but use can be justified with an efficient drug such as SIN-1. A drug-eluting stent coated with SIN-1 could be another alternative.

One week after PTCA we evaluated the vascular response with biochemical analysis of arterial wall proteins, as histomorphological and angiographic examinations are less sensitive to detect neointimal formation at this stage. Macroscopically, all the arteries were open at sacrifice. The IF constitutes the cytoskeleton and can be found in all types of cells. In SMCs two main types of IF are present, desmin and vimentin (14). Myofibroblasts from the adventitia also have a large amount of IF, mainly of the vimentin type (25). The function of the IF in the SMC is unknown although IF proteins increase during hypertrophy and hyperplasia (14). It has been reported that the content of actin is decreased in aortic SMCs after endothelial injury, whereas IF proteins (vimentin) increase (14). Actin is not changed in smooth muscle of intimal thickening when

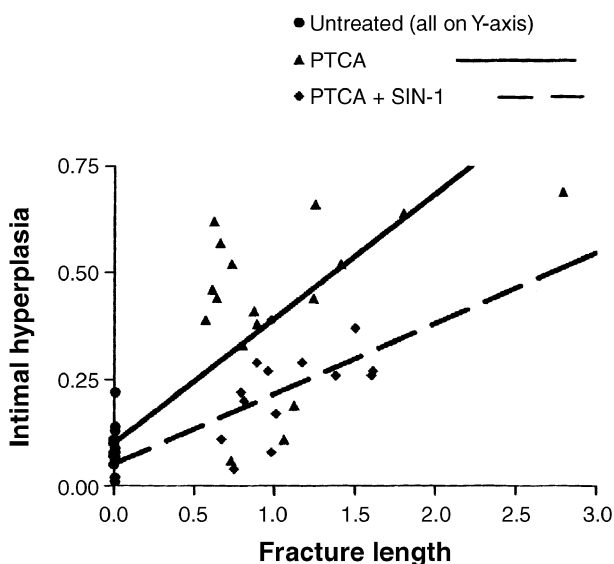


Fig. 4. Correlation between the development of intimal hyperplasia and fracture length in PTCA and PTCA+SIN-1 and their distal untreated controls shows that arteries subjected to SIN-1 after PTCA depict less intimal hyperplasia ( $R^2 = 0.26$  and  $p = 0.001$ ), despite the same fracture length as arteries treated with PTCA alone ( $R^2 = 0.27$  and non-significant). All groups summarize data from 6 animals. Data are presented as mean  $\pm$  SEM.



related to total tissue weight (6). Because SMC adaptation is associated with an increase in proteins while the amount of actin is decreased, or unchanged, we chose to use the IF/actin ratio as a measurement of PTCA-induced adaptation of the vessel intima and media. Western blot analysis showed that the increase in IF observed in the present study was mainly due to an increase in desmin, which also has been found by others (5). We have thus found that PTCA affects the structural IF system in the cells of the vascular wall in a pronounced way. The increase in IF after 7 days indicates a rapid turnover of IF proteins and cell growth. Whether this is due to injury of the SMCs after PTCA, or to the increased load on the muscle it is not known. At present it cannot be excluded that the increase in IF reflects an increase in the number of non-SMCs, possibly activated during injury. However, the results indicate a possible role for NO in smooth muscle remodeling in response to injury, as exposure to the NO donor SIN-1 significantly reduced the ratio of IF/actin in the vascular tissue. NO interferes with most intercellular messengers because it diffuses rapidly and isotropically through most tissues, with reactions such as nitration of structural proteins including neurofilaments and actin, which could disrupt filament assembly with major consequences (2). Such a reaction may account for either a diminished appearance of myofibroblasts or a change in their function. It could also explain the positive results on the remodeling process of restenosis as indicated in the significantly reduced IF/actin ratio observed after treatment with SIN-1. The IF/actin ratio seems to be a sensitive marker for smooth muscle growth and/or vascular injury, as it correlates with the degree of neointimal formation found at the histological examination at 8 weeks.

In the heart, NOS is found almost entirely in the vessels (24). Practically none is found in the endocardium, valves or the cardiac muscle fibers. Most of the NOS in the heart is in the endothelial isoform (eNOS). The inducible isoform (iNOS) can only be found after vascular injury (24). In an attempt to observe the amount of NOS in the endothelium after PTCA treatment with and without SIN-1, NADPH diaphorase histochemistry of the vessels was performed. Although NADPH also marks other enzymes such as cytochrome P450 reductase, NADPH oxidase and non-specific phosphatases, these enzymes are predominately found in the liver (22). One and 8 weeks after PTCA significantly increased NADPH diaphorase activity was found in the endothelial lining of arteries. This response was inhibited by simultaneous treatment with SIN-1, resulting in levels of NOS similar to those of non-

treated segments. It is suggested that SIN-1 down-regulates the expression of NOS in the newly formed endothelium lining the vessel wall after 1 week compared with the normal response after angioplasty. It is remarkable that the lower (compared with PTCA alone) or normalized (compared with control segments) NOS content after SIN-1 treatment persisted 8 weeks post-operatively, implying a long-lasting change in the messenger ribonucleic acid (mRNA) expression of the endothelial cells (4).

These findings indicate that events at the onset of injury are crucial to the process of neointimal formation. It was shown that the negative events leading to neointimal formation could be minimized by local delivery of SIN-1. The mechanisms behind this are still unknown. NO at high concentrations, as in the present study, has previously been shown to inhibit platelet aggregation and adhesion on the basal membrane of the denuded vascular wall (9). NO modulates the expression of apoptotic receptors and proteins (19). It is therefore possible that in the present study SIN-1 delivery triggered an apoptotic mechanism in the vascular wall.

*In conclusion*, the vessel content of IF proteins is an early marker of neo-intimal formation. Events at the onset of injury are crucial for the development of intimal hyperplasia and can be modified by application of NO.

## ACKNOWLEDGMENTS

The study was supported by the Professor Olle Olsson Foundation, the Swedish Medical Research Council (04X-8268 and 04X-13406), The Royal Swedish Physiographic Society and The Pahlsson's Foundation. Material was granted by Scimed, Boston Scientific Co, Boston, MA, USA. We are grateful to Mrs Christina Persson for expert help with the biochemical assays.

## REFERENCES

1. Assender JW, Southgate KM, Newby AC. Does nitric oxide inhibits smooth muscle proliferation? *Circulation* 1993; 87: 590-97.
2. Beckman JS, Koppenol WH. Nitric oxide, superoxide and peroxynitrite. The good, the bad, and the ugly. *Am. J. Physiol.* 1996; 271:C1424-37.
3. Bonan R, Paiment P, Scortichini D, Cloutier MJ, Leung TK. Coronary restenosis: Evaluation of a restenosis injury index in a swine model. *Am. Heart J.* 1993; 126: 1334-40.
4. Brune B, Sandau K, Knethen A. Apoptotic cell death and nitric oxide: activating and antagonistic transducing pathways. *Biochemistry (Mosc.)* 1998; 63: 817-25.
5. Christen T, Verin V, Bochaton-Piallat ML et al. Mechanism of neointimal formation and remodeling in the porcine coronary artery. *Circulation* 2001; 103: 882-8.
6. Gabbiani G, Kocher O, Bloom WS, Vandekerckhove J, Weber K. Actin expression in smooth muscle cells of rat aortic intimal thickening, human atheromatos plaque, and cultured rat aortic media. *J. Clin. Invest.* 1984; 73: 148-52.

7. Gibbons GH, Dzau VJ. The emerging concept of vascular remodeling. *N. Engl. J. Med.* 1994; 330: 1431–38.
8. Gibson CM, Ryan KA, Kelley M et al. Methodologic drift in the assessment of TIMI grade 3 flow and its implications with respect to the reporting of angiographic trial results. The TIMI Study Group. *Am. Heart J.* 1999; 137: 1179–84.
9. Groves PH, Lewis MJ, Cheadle HA, Penny WJ. SIN-1 reduces platelet adhesion and platelet thrombus formation in a porcine model of balloon angioplasty. *Circulation* 1993; 87: 590–97.
10. Harnek J, Zoucas E, Carlemalm E, Cwikiel W. Differences in endothelial injury after balloon angioplasty, insertion of balloon-expanded stents or release of self-expanding stents: An electron microscopic experimental study. *Cardiovasc. Intervent. Radiol.* 1999; 22: 56–61.
11. Hope B, Michael GJ, Knigge KM, Vincent SR. Neuronal NADPH diaphorase is a nitric oxide synthase. *Proc. Natl. Acad. Sci. USA* 1991; 88: 2811–14.
12. Jawien A, Bowen-Pope DF, Lindner V, Schwartz SM, Clowes AW. Platelet derived growth factor promotes smooth muscle migration and intimal thickening in a rat model of balloon angioplasty. *J. Clin. Invest.* 1992; 89: 507–11.
13. Kastrati A, Schomig A., Schulen H, Wilhelm M, Dirschinger J. Interlesion dependence of the risk of restenosis in patients with coronary stent placement in multiple lesions. *Circulation* 1998; 97: 2396–401.
14. Kocher O, Gabbianani G. Cytoskeletal features of normal and atheromatous human arterial smooth muscle cells. *Hum. Pathol.* 1986; 17: 875–80.
15. Kohler TR, Clowes AW. Response of artery to injury. The role of intimal hyperplasia in the failure of vascular reconstruction. *In: Vascular Diseases. Surgical and Interventional Therapy*, p. 17. Edited by D. E. Strandness Jr. Churchill Livingstone 1994.
16. Kurose I, Wolf R, Cerwinka W, Granger DN. Microvascular responses to ischemia/reperfusion in normotensive and hypertensive rats. *Hypertension* 1999; 34: 212–16.
17. Lablanche JM, Grollier G, Lussan JR et al. Effect of the direct nitric oxide donors linsidomine and molsidomine on angiographic restenosis after coronary balloon angioplasty. The ACCORD study. *Circulation* 1997; 95: 83–9.
18. Lafont A, Guzman L, Whitlow PL, Goormastic M, Cornhill JF, Chrischold GM. Restenosis after successful angioplasty: intimal medial and adventitial changes associated with constrictive remodeling. *Circ. Res.* 1995; 76: 996–1002.
19. Lopez-Farre A, Rodriguez-Feo JA, Sanchez de Miguel L, Rico L, Casado S. Role of nitric oxide in the control of apoptosis in the microvasculature. *Int. J. Biochem. Cell Biol.* 1998; 30: 1095–106.
20. Malmqvist U, Arner A, Uvelius B. Contractile and cytoskeletal proteins in smooth muscle during hypertrophy and its reversal. *Am. J. Physiol.* 1991; 260: C1085–93.
21. Mitchel JF, Fram DB, Palme DF et al.. Enhanced intracoronary thrombolysis with urokinase using a novel, local drug delivery system. *In vitro, in vivo* and clinical studies. *Circulation* 1995; 91: 785–93.
22. Persson K, Poljakovic M, Johansson K, Larsson B. Morphological and biochemical investigation of nitric oxide synthase and related enzymes in the rat and pig urothelium. *J. Histochem. Cytochem.* 1999; 47:739–49.
23. Suzuki T, Hayase M, Hibi K et al. Effect of local delivery of L-arginine on in-stent restenosis in humans. *Am. J. Cardiol.* 2002; 89: 363–67.
24. Ursell PC, Mayes M. Anatomic distribution of nitric oxide synthetase in the heart. *Int. J. Cardiol.* 1995; 50: 217–23.
25. Wilcox JN, Cipolla GD, Martin FH et al. Contribution of adventitial myofibroblast to vascular remodelling and lesion formation after experimental angioplasty in pig coronary arteries. *Ann. N Y Acad. Sci.* 1997; 15: 437–47.