LUND UNIVERSITY

Effects of vacuum-assisted closure therapy on inguinal wound edge microvascular blood flow.

Wackenfors, Angelica; Sjögren, Johan; Gustafsson, Ronny; Algotsson, Lars; Ingemansson, Richard; Malmsjö, Malin

Published in:
Wound Repair and Regeneration

DOI:
10.1111/j.1067-1927.2004.12602.x

2004

Link to publication

Citation for published version (APA):
Wackenfors, A., Sjögren, J., Gustafsson, R., Algotsson, L., Ingemansson, R., & Malmsjö, M. (2004). Effects of vacuum-assisted closure therapy on inguinal wound edge microvascular blood flow. *Wound Repair and Regeneration*, *12*(6), 600-606. https://doi.org/10.1111/j.1067-1927.2004.12602.x

Total number of authors:
6

General rights
Unless other specific re-use rights are stated the following general rights apply:
Copyright and moral rights for the publications made accessible in the public portal are retained by the authors and/or other copyright owners and it is a condition of accessing publications that users recognise and abide by the legal requirements associated with these rights.
• Users may download and print one copy of any publication from the public portal for the purpose of private study or research.
• You may not further distribute the material or use it for any profit-making activity or commercial gain
• You may freely distribute the URL identifying the publication in the public portal

Read more about Creative commons licenses: https://creativecommons.org/licenses/

Take down policy
If you believe that this document breaches copyright please contact us providing details, and we will remove access to the work immediately and investigate your claim.

LUND UNIVERSITY

PO Box 117
221 00 Lund
+46 46-222 00 00

Effects of vacuum-assisted closure therapy on inguinal wound edge microvascular blood flow

ANGELICA WACKENFORS, MSc[a]; JOHAN SJÖGREN, MD[b]; RONNY GUSTAFSSON, MD[b]; LARS ALGOTSSON, MD, PhD[c]; RICHARD INGEMANSSON, MD, PhD[b]; MALIN MALMSJÖ, MD, PhD[a]

Vacuum-assisted closure (VAC) therapy has been shown to facilitate wound healing. Data on the mechanisms are scarce, although beneficial effects on blood flow and granulation tissue formation have been presented. In the current study, laser Doppler was used to measure microvascular blood flow to an inguinal wound in pigs during VAC therapy (−50 to −200 mmHg), including consideration of the different tissue types and the distance from the wound edge. VAC treatment induced an increase in microvascular blood flow a few centimeters from the wound edge. The increase in blood flow occurred closer to the wound edge in muscular as compared to subcutaneous tissue (1.5 cm and 3 cm, at −75 mmHg). In the immediate proximity to the wound edge, blood flow was decreased. This hypoperfused zone was increased with decreasing pressure and was especially prominent in subcutaneous as compared to muscular tissue (0–1.9 cm vs. 0–1.0 cm, at −100 mmHg). When VAC therapy was terminated, blood flow increased multifold, which may be due to reactive hyperemia. In conclusion, VAC therapy affects microvascular blood flow to the wound edge and may thereby promote wound healing. A low negative pressure during treatment may be beneficial, especially in soft tissue, to minimize possible ischemic effects. Intermittent VAC therapy may further increase blood flow.
(WOUND REP REG 2004;12:600–606)

Vacuum assisted closure (VAC) therapy is a newly established technique that has been shown to promote wound healing.[1,2] VAC therapy provides a negative pressure, which is distributed over the wound surface by an airtight covered foam. The vacuum sealing facilitates the drainage of excessive fluid and debris, which has been shown to lead to a decline in bacterial counts, decreased interstitial edema, and increased capillary blood flow.[3,4] The technique provides both adequate wound drainage and a humid environment necessary for wound healing, and thus combines the benefits of both open and closed (moist) wound healing.[5]

ATP	Adenosine triphosphate
VAC	Vacuum-assisted closure

The physiological and molecular biological mechanisms by which VAC therapy accelerates wound healing are to a large extent unknown. It is generally believed that blood perfusion and oxygenation are crucial to ensure proper healing.[6] Granulation tissue formation, which is limited by the available vascular supply, has been shown to increase during VAC therapy.[7,8] This may be a result of facilitated microcirculation around the wound due to removal of excessive interstitial fluid, decompressing small blood vessels, and restoring perfusion.

Microvascular blood flow can be measured by laser Doppler, in which the sum of motion of all the red blood cells is quantified in a volume of 1 mm^3[9,10] Thus, it is now feasible to perform reliable measurements in small, closely spaced skin areas. This technique has been applied extensively to measure blood flow during plastic surgery procedures such as in placement of skin flaps.[11,12] Analysis of blood flow

From the Department of Internal Medicine[a], Cardiothoracic Surgery[b] and Cardiothoracic Anesthesia[c], Lund University Hospital, Lund, Sweden.
Manuscript received: December 19, 2003
Accepted in final form: July 15, 2004
Reprint requests: Angelica Wackenfors, MSc, Experimental Vascular Research, BMC A13, SE-221 84 Lund, Sweden. Fax: +46 46 222 0616; Email: angelica.wackenfors@med.lu.se.
Copyright © 2004 by the Wound Healing Society.
ISSN: 1067-1927 $15.00 + 0.

to a VAC-treated wound was performed in 1997 by Morykwas et al.[13] It was shown that microvascular blood flow increases four times baseline values with negative pressures of − 125 mmHg, while blood flow was inhibited at − 400 mmHg and above,[13] although the distance from the wound edge or in-between tissue differences were not evaluated at this time. In the present study, a detailed analysis of microvascular blood flow to a pig inguinal wound was performed, using increasing negative pressures (− 50 to − 200 mmHg), with consideration of the tissue type and the distance from the wound edge. Furthermore, blood flow responses in the immediate vicinity to the wound edge were characterized during intermittent VAC therapy.

MATERIALS AND METHODS

Seven domestic Landrace pigs of both genders, with a mean body weight of 70 kg, were fasted overnight with free access to water. The experimental protocol for this study was approved by the Ethics Committee for Animal Research, Lund, Sweden, which conforms to the principles outlined in the Declaration of Helsinki. All of the animals received humane care in compliance with the *Guide for the Use and Care for Laboratory Animals* as promulgated by the Council of the American Physiologic Society and published by the National Institutes of Health, 1985.

Anesthesia and surgical preparation

An intramuscular injection of ketamine (Ketalar; Parke-Davis, Morris Plains, NJ), 30 mg/kg, was used for premedication. Anesthesia was induced with intravenous sodium thiopental (Penthotal; Abbot Scandinavia, Stockholm, Sweden), 4 mg/kg, and maintained with a continuous infusion of 6 mg/kg/hour pentobarbital (Apoteksbolaget, Umeå, Sweden) in combination with 10 μg/kg/hour fentanyl (Alpharma AB, Stockholm, Sweden). In addition, nitrous oxide (65%) in oxygen (35%) was administered during mechanical ventilation. Pancuronium (Pavulon; Organon Teknika, Boxtel, The Netherlands) was given intravenously (0.35 mg/kg/hours) to achieve muscle paralysis. A Servo Ventilator 900 (Elema-Schönander, Sweden) was used for mechanical ventilation. Identical settings were used in all animals, namely volume-controlled, pressure-regulated ventilation; 10 l/minute and 20 breaths/minute. A continuous infusion of Ringer's acetate, at a rate of 5 ml/kg/hour, was maintained throughout the experiment. A Foley catheter (Norta, Beiersdorf AG, Hamburg, Germany) was inserted into the urinary bladder through a suprapubic cystostomy. After the experiments were finished, the animals were euthanized by a lethal dose of potassium (Addex-Kalium; FreseniusKabi AB, Stockholm, Sweden) injected into the heart.

Experimental design

Animals were prepared for surgery as described above. A 15-cm-long skin incision was made bilaterally in the inguinal region, at the hind leg of the pig. Through the incision, a 10-cm-deep wound was created, in which a polyurethane foam (KCI, Copenhagen, Denmark) with an open pore structure of 400–600 μm was fitted. The foam was trimmed one and a half times broader than the wound dimensions to allow volume reduction during vacuum application. The volume of foam that was introduced into the wound filled the entire wound depth of 10 cm. A drainage tube (KCI, Copenhagen, Denmark) was inserted into the foam and connected to a purpose-built vacuum source (VAC® pump unit; KCI, Copenhagen, Denmark). In the wound with active therapy, the unit delivered a continuous negative pressure of 125 mmHg. The contralateral wound was used as control, without application of negative pressure, and was termed "sham therapy." The wound was sealed with transparent adhesive drape (KCI, Copenhagen, Denmark), which overlapped the wound margins by 5 cm. The pig core temperature, monitored by a probe in the esophagus, only varied between 35 °C and 37 °C during the entire experiments. To stabilize the surface temperature, the pig was covered by a blanket.

Blood flow determinations

Microvascular blood flow was measured by laser Doppler, using the multichannel PeriFlux System 5000 (Perimed, Stockholm, Sweden). In this method, a beam of laser light is carried by a fiber-optic probe. Light hitting moving blood cells undergoes a change in wavelength (Doppler shift), while light hitting static objects is unchanged. The magnitude and frequency distribution of these changes in wavelength are directly related to the number and velocity of blood cells. The information is picked up by a returning fiber, converted into an electronic signal, and analyzed. In the current experiments, filament probes (Probe 418–1; Perimed, Stockholm, Sweden) were inserted into subcutaneous and deep muscular tissue in 0.5 cm increments (range 0.5–4.5 cm) from the wound edge. A skin probe (Probe 418–1; Perimed), was placed 10 cm from the wound. Negative pressures of − 50, − 75, − 100, − 125, − 175, and − 200 mmHg were applied to the wound randomly and microvascular blood flow was measured continuously. After measuring blood flow responses at all pressures and distances, one filament probe was placed 0.5 cm from the wound edge subcutaneously. Different time periods of VAC therapy at − 125 mmHg was applied to evaluate the blood flow responses in the hypoperfused zone during intermittent treatment. The "on" periods, during which the negative pressure was applied, ranged from 1 to 15 minutes. The experiments were finished by administering 0.5 mg/kg adenosine

triphosphate (ATP; Sigma-Aldrich, St. Louis, MO) intravenously and blood flow was measured by the skin probe (Probe 418–1; Perimed), and in subcutaneous tissue and muscular tissue by the filament probe (Probe 418–1; Perimed) for testing the probes and equipment. Microvascular blood flow was expressed as "perfusion units," and the output was continuously monitored by the PeriSoft software.

Statistical analysis

Calculations and statistics were performed using GraphPad 3.02 software (San Diego, CA). The experiments were performed on seven pigs for each tissue and negative pressure and statistical significance was accepted when $p < 0.05$, using Wilcoxon signed rank test. All differences referred to in the text have been statistically verified. Values are presented as means ± S.E.M.

RESULTS

The basal blood flow was 27 ± 5 perfusion units in the skin, 47 ± 12 perfusion units in subcutaneous tissue, and 121 ± 16 perfusion units and in muscular tissue. Adjacent to the wound edge, VAC treatment induced an increase in microvascular blood flow (Figure 1A). In muscular tissue, the distance from the wound edge to where the blood flow was increased was shorter (1.5 cm, at − 75 mmHg, Figure 2), as compared to in subcutaneous tissue (3 cm, at − 75 mmHg, $p < 0.05$, Figure 2). The blood flow increased with increasing subatmospheric pressure in both subcutaneous and muscular tissue (Figure 2). In subcutaneous tissue, the flow at − 50 mmHg was 77 ± 46%, while at − 150 mmHg the flow was increased 94 ± 6% (3.0 cm from the edge, $p < 0.05$, Figure 2). In muscular tissue, the flow at − 50 mmHg was 11 ± 8%, while at − 200 mmHg the flow was increased 158 ± 85% (2.5 cm from the edge, $p < 0.05$, Figure 2).

In immediate proximity to the wound, microvascular blood flow was decreased following application of subatmospheric pressure in both muscular and subcutaneous tissue (Figures 1B and 2). The hypoperfused zone was larger at high negative pressures and especially prominent in subcutaneous as compared to muscular tissue (reaching 1.8 cm at − 50 mmHg and 2.5 cm at − 200 mmHg in subcutaneous tissue, respectively, 1.0 cm at − 50 mmHg and 1.7 cm at − 200 mmHg in muscular tissue, $p < 0.05$, Figure 2). Further away from the wound (> 3.5 cm in muscular tissue and > 4.5 cm in subcutaneous tissue), microvascular blood flow was not affected by subatmospheric pressure (− 50 to − 200 mmHg, Figures 1C and 2).

Intermittent VAC therapy, in which a subatmospheric pressure of − 125 mmHg is turned on and off repeatedly, is used clinically. To study the effect on microcirculation in the zone where blood flow is decreased during application of negative pressure, a filament probe was placed subcutaneously, 0.5 cm from the wound edge, with increasing duration of "VAC on" periods of − 125 mmHg. As expected, when the VAC was turned on, the blood flow decreased and when it was turned off, it increased. However, after turning the VAC off, the blood flow did not return to baseline immediately, but increased 40–50% and then returned to baseline (Figure 3). The peak flow after the VAC was turned off was not affected by the duration of the "VAC on" periods (40 ± 5% after 1 minute "VAC on" and 46 ± 7% after 15 minutes of "VAC on", p = n.s., Figure 4A). Extension of the "on" periods resulted in longer lasting blood flow increases. "On" periods of 1 minute resulted in blood flow increases that lasted for 7 ± 1 minutes, while "on" periods of 10 minutes resulted in an 11 ± 1 minute increase ($p < 0.001$, Figure 4B). "On" periods longer than 10 minutes did not further extend the duration of increased blood flow (15 minutes "on" resulted in a 10 ± 1 minute increase, p = n.s., Figure 4B).

As a positive control, ATP (0.5 mg/kg) was administered intravenously and microvascular blood flow was recorded with a probe on the skin, in subcutaneous and in muscular tissue. ATP first induced a decrease in blood flow (− 58 ± 15% in the skin, − 41 ± 17% in the subcutaneous and − 66 ± 25% in the muscular tissue), followed by an increase in blood flow (200 ± 68% in the skin, 96 ± 23% in the subcutaneous and 89 ± 26% in the muscular tissue), indicating functioning probes and equipment. A skin probe, which was attached to the skin 10 cm from the wound edge, was used as a negative control to monitor microvascular blood circulation during the entire experiment. The baseline blood flow in the skin was 27 ± 5 perfusion units, and no significant changes in blood flow could be seen when the subatmospheric pressure was applied to the wound, indicating that the blood flow alterations were localized to the wound and no systemic effects contributed.

DISCUSSION

The present study is the first to examine how VAC therapy affects microvascular blood flow, considering the tissue type and the distance from the wound edge. The results show that microvascular blood flow is increased adjacent to the defect. Closer to the wound, VAC therapy induces hypoperfusion that increases with increasing subatmospheric pressure. Microvascular blood flow also depends on the tissue involved. Soft subcutaneous tissue is more vulnerable to hypoperfusion than stiff muscular tissue, which may be of consideration when setting the negative pressure value for VAC therapy. Intermittent treatment may be beneficial

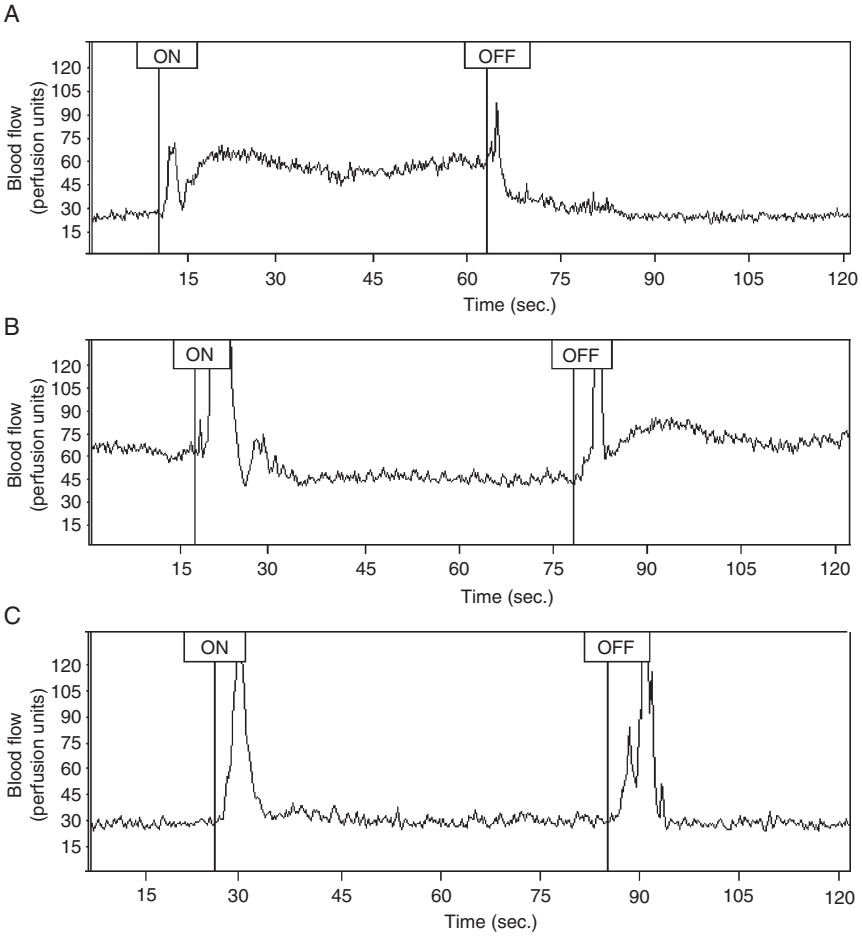

FIGURE 1. Representative examples of microvascular blood flow changes after application of VAC therapy (−125 mmHg) in subcutaneous tissue at (A) 3.0 cm, (B) 0.5 cm, and (C) 5 cm from the wound edge.

because it allows repeated blood flow to the otherwise hypoperfused tissues. Our results show an increase in blood flow 40–50% above baseline that lasts for 10 minutes after the VAC is turned off. This may be due to reactive hyperemia following the hypoperfusion.

VAC therapy has become a widely accepted treatment modality and has proved to accelerate wound healing in chronic and difficult wounds. The physiological and molecular biological mechanisms by which VAC therapy acts are to a large extent unknown. Elevated blood flow may be one mechanism responsible for the increase in granulation tissue formation seen during VAC therapy, because the rate of wound healing is limited by the vascular supply, the rate of formation of new capillaries and matrix molecules.[14] Blood flow increases continuously when subatmospheric pressure is increased. Morykwas et al. showed that the greatest increase in wound edge blood flow occurred at −125 mmHg,[3] which was the pressure selected for further studies and is now the pressure of choice in clinical practice, although the distance from the wound edge or in-between tissue differences were not considered at that time. In the present study, we show that the peak in blood flow increase varies at different distances from the wound edge. A few centimeters away from the wound edge, blood flow increases when subatmospheric pressure is applied. Conversely, in immediate proximity to the wound, the negative pressure induces hypoperfusion. We show that the alterations in blood flow is localized to the wound and no systemic effects contribute because microvascular blood flow, measured by a skin probe 10 cm away from the wound, is not changed by VAC therapy. In addition to the amount of pressure applied, microvascular blood flow also depends on the tissue treated. In muscular tissue, the distance from the wound edge to where the blood flow is increased is shorter (1.5 cm, at −75 mmHg), as compared to in subcutaneous tissue (3 cm, at −75 mmHg). The explanation for this finding may be that soft tissue more easily collapses during pressure, which results in a large zone of hypoperfusion proximal to the wound. In subcutaneous tissue, the hypoperfused zone reaches 1.9 cm from the wound edge at −100 mmHg, while at the same pressure it only reaches 1.0 cm in muscular tissue. The size of the hypoperfused zone depends on the subatmospheric pressure applied, and grows larger with decreasing pressure.

To ensure proper wound healing, adequate blood perfusion and oxygenation of the wound site are critical.[15] Therefore, why would hypoperfusion close

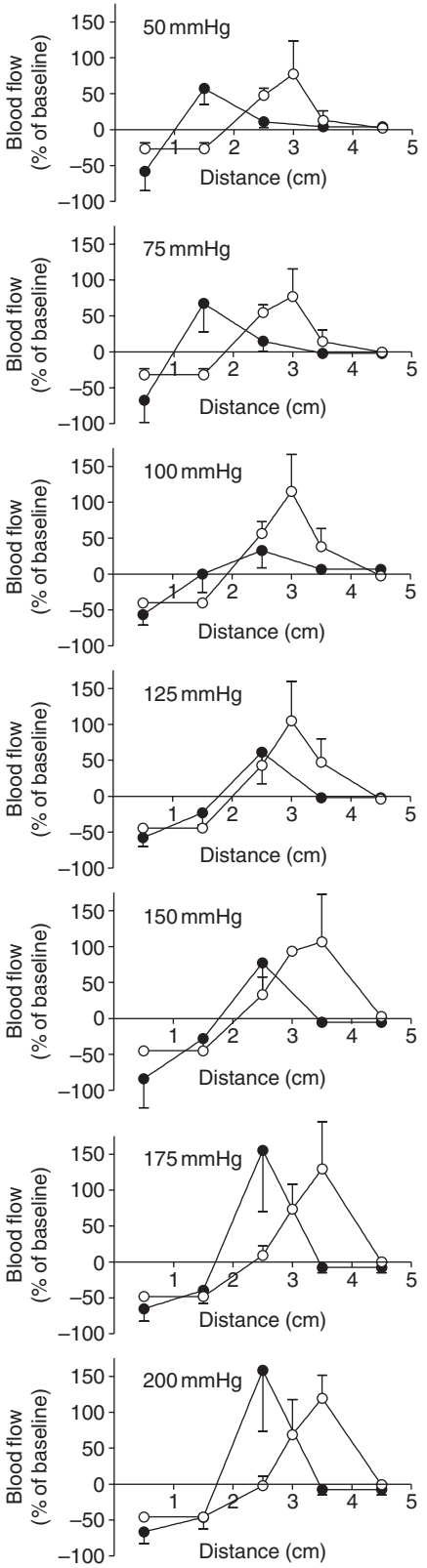

FIGURE 2. Microvascular blood flow in subcutaneous (○) and muscular tissue (●), at increasing distance from an inguinal wound edge in seven domestic pigs after application of a subatmospheric pressure of −50 to −200 mmHg. Changes in blood flow were calculated as percent of baseline flow and are presented as means ± S.E.M.

to the wound be beneficial? The concept of using negative pressure to create a suction force, enabling the drainage of wounds in order to promote healing, is well-documented.[16,17] Also, pressure against the wound wall may tamponade superficial bleedings.[18] To balance these effects, a negative pressure that does not cause a large ischemic zone but still eliminates interstitial fluid accumulation and bleeding may be preferable. An optimal negative pressure for VAC therapy has been suggested on the basis of blood flow measurements in a wound, with a peak increase at −125 mmHg.[3] Furthermore, granulation tissue formation was measured in a wound treated with −25, −125, and −500 mmHg.[7] The rate of granulation tissue increase was greatest at −125 mmHg.[7] Currently, the pressure in the VAC tubing guides the VAC therapy. We suggest that the pressure in the tissue is of greater importance because pressure is transduced differently in soft as compared to stiff tissue, resulting in a VAC effect that varies according to wound tissue composition. The VAC pressure could be tailored to balance the negative effects of hypoperfusion and subsequent ischemia, close to the wound edge, with the positive effects of hyperperfusion, further away from the wound. Our results indicate that when treating stiff tissue such as muscle, a negative pressure of −100 mmHg may be reasonable, thereby limiting the extent of the hypoperfused zone to 1 cm from the wound edge. When treating softer tissue that is more vulnerable for hypoperfusion, such as subcutaneous tissue and fat, the application of a lower negative pressure (e.g., −75 mmHg) may be more beneficial.

In the current work, an acute wound model was used, while VAC therapy is mainly used clinically for the treatment of chronic wounds. Most likely the results from the present study can be applied to chronic wound, because the level of negative pressure is the same. The duration of the treatment in a chronic wound is longer compared to the current experiments. Hypothetically, when treating patients for a longer period of time, the tissue may adapt to the negative pressure environment by, for example, initiating angiogenesis in the hypoperfused wound margins and other remodeling processes. Furthermore, a chronic wound is different in appearance as compared to an acute wound. A chronic wound is more edematous, which may affect how the pressure is distributed in the wound tissue, and thereby the microvascular blood flow. In addition, the suction force applied to the wound surface results in the removal of fluid, edema, and decreasing bacterial counts, which may create a wound surface similar to the acute wound model, making our experiments relevant.

Our observation that the intermittent treatment appears more effective than continuous therapy is interesting, although the reason for this is not fully

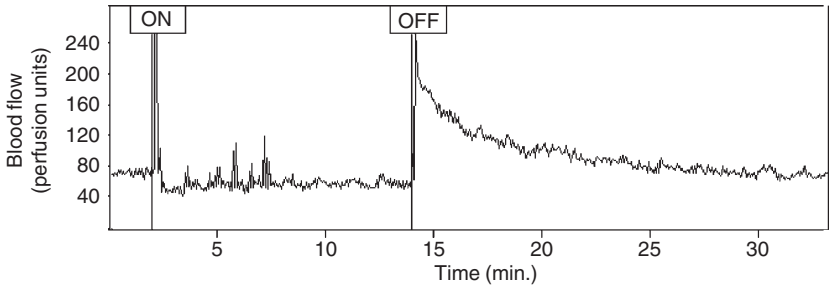

FIGURE 3. Representative example of microvascular blood flow changes in subcutaneous tissue when the VAC was first turned on for 10 minutes (−125 mmHg) and then turned off. The duration of the blood flow increase after the VAC was turned off lasted for 11 ± 1 minutes and reached 45 ± 6% of baseline blood flow.

understood. Two possible mechanisms were advanced by Philbeck et al.[19] They suggested that intermittent therapy results in rhythmic perfusion of the tissue and stimulates cells to undergo mitosis. For this reason it has been suggested that intermittent negative pressure can be used clinically. On the basis of peak blood flow responses it was suggested that 5 minutes of "VAC on" and 2 minutes of "VAC off" cycles were optimal.[3] The present study was performed to analyze the effects of intermittent negative pressure in the hypoperfused tissue zone. The probes were placed subcutaneously, 0.5 cm from the wound edge, which is a zone where hypoperfusion most likely develops. As expected, when the VAC was turned on, blood flow decreased and when the VAC was turned off, a transient increase in blood flow, 40–50% above baseline, was seen. The peak flow after the VAC was turned off was not affected by the duration of the "VAC on" periods. Extension of the "on" periods resulted in longer lasting blood flow increases, reaching a maximum of 11 minutes after 10 minutes of VAC therapy. A possible explanation for this transient increase in blood flow may be reactive hyperemia due to local vasodilatation that occurs in response to oxygen debt and accumulation of metabolic waste products due to the interruption of blood flow.[20,21] Prominent superficial blood vessels and a reddish color of the wound wall were observed during the experiments in the negative pressure-treated as compared to the sham-treated wounds, further supporting this hypothesis.

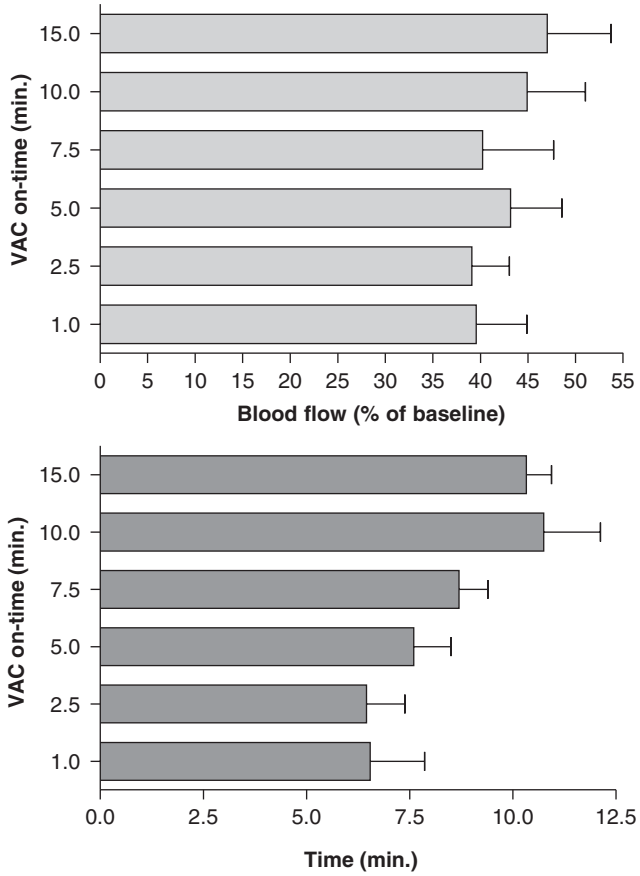

FIGURE 4. Microvascular blood flow in subcutaneous tissue 0.5 cm from an inguinal wound in domestic pigs at atmospheric tissue pressure after VAC therapy (−125 mmHg) for 1–15 minutes. (A) The peak in blood flow increase was calculated as percent of baseline flow before the VAC was turned on. (B) The duration of blood flow increase (minutes). Values are presented as means ± S.E.M. ($n = 7$).

Intermittent VAC therapy may be beneficial in two respects. Firstly, the hypoperfused areas close to the VAC foam will not develop chronic ischemia because the pressure is released repeatedly. Secondly, blood flow when the VAC is turned off increases above baseline, which may be beneficial for the transportation of oxygen and nutrients and removal of waste products from the otherwise hypoperfused tissue and thereby facilitate the healing process. Intermittent VAC therapy thus results in a "rescue" of the hypoperfused tissue and a higher negative pressure may be used for intermittent as compared to continuous VAC therapy.

In conclusion, VAC therapy elicits an increase in microvascular blood flow a few centimeters from the wound edge, which may accelerate granulation tissue formation and the healing process. Conversely, in the immediate vicinity to the wound, hypoperfusion is induced, which may result in ischemic tissue damage. Our results indicate that the pressure applied could be tailored depending on the wound tissue composition, considering the tissue volume with expected hypoperfusion, and the pressure that results in the greatest blood flow increase. The hypoperfusion is especially prominent in subcutaneous tissue, which is why the application of a lower negative pressure may be more beneficial when treating wounds in soft tissue. On the

other hand, a high negative pressure creates a reduction in wound edema and tamponades superficial bleeding.[18] During intermittent VAC therapy the negative effects of hypoperfusion are reduced and the advantage of the following hyperemia is utilized, which is why a higher negative pressure may be used for intermittent as compared to continuous VAC therapy.

ACKNOWLEDGMENTS

This study was supported by the Swedish Hypertension Society, the Swedish Medical Association, the Royal Physiographic Society (Lund), the Swedish Medical Research Council Grant 5958, the Medical Society in Lund, the Crafoord Foundation, the Swedish Heart Lung Foundation and the Swedish Government Grant for Clinical Research.

REFERENCES

1. Clare MP, Fitzgibbons TC, McMullen ST, Stice RC, Hayes DF, Henkel L. Experience with the vacuum assisted closure negative pressure technique in the treatment of non-healing diabetic and dysvascular wounds. Foot Ankle Int 2002;23:896–901.
2. Domkowski PW, Smith ML, Gonyon DL Jr, Drye C, Wooten MK, Levin LS, Wolfe WG. Evaluation of vacuum-assisted closure in the treatment of poststernotomy mediastinitis. J Thorac Cardiovasc Surg 2003;126:386–90.
3. Morykwas MJ, Argenta LC, Shelton-Brown EI, McGuirt W. Vacuum-assisted closure: a new method for wound control and treatment: animal studies and basic foundation. Ann Plast Surg 1997;38:553–62.
4. Argenta LC, Morykwas MJ. Vacuum-assisted closure. a new method for wound control and treatment: clinical experience. Ann Plast Surg 1997;38:563–76; discussion 577.
5. Field FK, Kerstein MD. Overview of wound healing in a moist environment. Am J Surg 1994;167:2S–6S.
6. LaVan FB, Hunt TK. Oxygen and wound healing. Clin Plast Surg 1990;17:463–72.
7. Morykwas MJ, Faler BJ, Pearce DJ, Argenta LC. Effects of varying levels of subatmospheric pressure on the rate of granulation tissue formation in experimental wounds in swine. Ann Plast Surg 2001;47:547–51.
8. Giovannini D, Teot L. Interest of negative pressure therapy in the treatment of postoperative sepsis in cardiovascular surgery. Wounds 2001;13:82–7.
9. Bonner R, Nossal R. Model for laser doppler measurements of blood-flow in tissue. Appl Optics 1981;20:2097–107.
10. Borgos J. Laser doppler monitoring of cerebral blood flow. Neurol Res 1996;18:251–5.
11. Larrabee WF Jr, Holloway GA Jr, Sutton D. Wound tension and blood flow in skin flaps. Ann Otol Rhinol Laryngol 1984;93:112–5.
12. Zografos GC, Martis K, Morris DL. Laser Doppler flowmetry in evaluation of cutaneous wound blood flow using various suturing techniques. Ann Surg 1992;215:266–8.
13. Morykwas MJ, Argenta LC. Nonsurgical modalities to enhance healing and care of soft tissue wounds. J South Orthop Assoc 1997;6:279–88.
14. Hunt TK. Wound fluid: the growth environment. Prog Clin Biol Res 1991;365:223–30.
15. Jonsson K, Jensen JA, Goodson WH 3rd, Scheuenstuhl H, West J, Hopf HW, Hunt TK. Tissue oxygenation, anemia, and perfusion in relation to wound healing in surgical patients. Ann Surg 1991;214:605–13.
16. Fox JW 4th, Golden GT. The use of drains in subcutaneous surgical procedures. Am J Surg 1976;132:673–4.
17. Fay MF. Drainage systems. Their role in wound healing. AORN J 1987;46:442–55.
18. Sjögren J, Gustafsson R, Koul B, Ingemansson R. Selective mediastinal tamponade to control coagulopathic bleeding. Ann Thorac Surg 2003;75:1311–3.
19. Philbeck TE Jr, Whittington KT, Millsap MH, Briones RB, Wight DG, Schroeder WJ. The clinical and cost effectiveness of externally applied negative pressure wound therapy in the treatment of wounds in home healthcare Medicare patients. Ostomy Wound Manage 1999;45:41–50.
20. Patterson GC, Whelan RF. Reactive hyperaemia in the human forearm. Clin Sci (Lond) 1955;14:197–211.
21. Bliss MR. Hyperaemia. J Tissue Viability 1998;8:4–13.