



LUND UNIVERSITY

Physeolysis of the Hip. Epidemiology and hip function.

Herngren, Bengt

2018

Document Version:

Publisher's PDF, also known as Version of record

[Link to publication](#)

Citation for published version (APA):

Herngren, B. (2018). *Physeolysis of the Hip. Epidemiology and hip function*. [Doctoral Thesis (compilation), Department of Clinical Sciences, Lund]. Lund University: Faculty of Medicine.

Total number of authors:

1

General rights

Unless other specific re-use rights are stated the following general rights apply:

Copyright and moral rights for the publications made accessible in the public portal are retained by the authors and/or other copyright owners and it is a condition of accessing publications that users recognise and abide by the legal requirements associated with these rights.

- Users may download and print one copy of any publication from the public portal for the purpose of private study or research.
- You may not further distribute the material or use it for any profit-making activity or commercial gain
- You may freely distribute the URL identifying the publication in the public portal

Read more about Creative commons licenses: <https://creativecommons.org/licenses/>

Take down policy

If you believe that this document breaches copyright please contact us providing details, and we will remove access to the work immediately and investigate your claim.

LUND UNIVERSITY

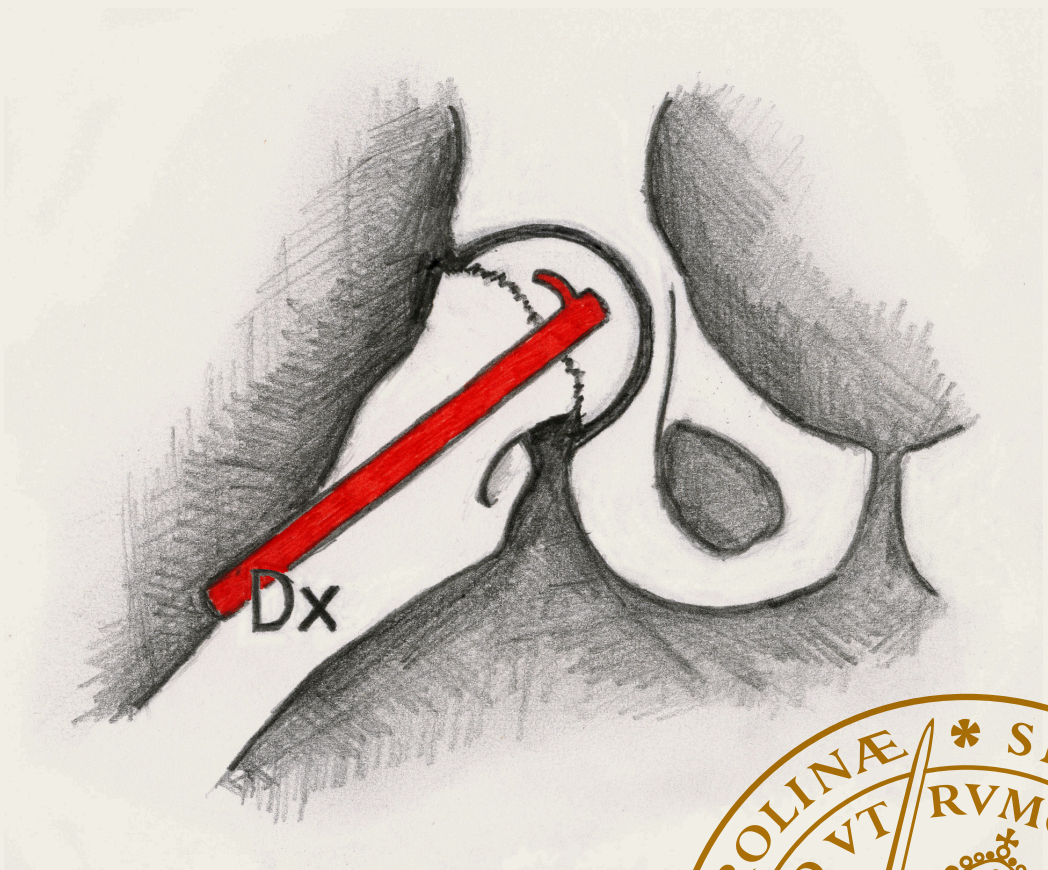
PO Box 117
221 00 Lund
+46 46-222 00 00

Physiolysis of the hip

Epidemiology and hip function

BENGT HERNGREN

DEPARTMENT OF CLINICAL SCIENCES, LUND | LUND UNIVERSITY



Physiolysis of the hip: epidemiology and hip function

Physiolysis of the hip

Epidemiology and hip function

Bengt Herngren



LUND
UNIVERSITY

DOCTORAL DISSERTATION

by due permission of the Faculty of Medicine, Lund University, Sweden.
To be defended at Lecture Hall Originalet, House B4, Ryhov county hospital,
Jönköping.

Friday November 2, 2018 at 1.00 p.m.

Faculty opponent
Professor Ivan Hvid

University of Oslo, Institute of Clinical Medicine, Faculty of Medicine,
Department of Orthopaedics – Rikshospitalet, Norway

Organization LUND UNIVERSITY Department of Clinical Sciences, Lund Section of Orthopaedics Lund university, Sweden Author: Bengt Herngren		Document name DOCTORAL DISSERTATION
		2018-11-02
		Sponsoring organization
Title: Physiolysis of the hip - Epidemiology and hip function		
Abstract Background Physiolysis of the hip (POH), also called slipped capital femoral epiphysis, is one of the most common hip disorders in children. The overall purpose of the work described in this thesis was to provide further information about the demographics of children who develop POH, to describe the early outcomes after treatment for POH including patient-reported outcome measures (PROMs), and to assess the reliability of the measurement methods used for radiographic assessment of POH.		
Methods The total Swedish population of 379 children (162 girls and 217 boys), who had POH in their index hip between 2007 and 2013, was used as the study cohort for all papers included. Early outcomes, radiographic and patient-reported, 36 months after primary surgery were analysed. A Swedish version of a hip function instrument (Barnhöft) was developed. Inter- and intra-observer reliability of the methods used to assess the slip severity on 77 radiographs was analysed by four observers with different levels of experience in radiographic measurement techniques.		
Results A cumulative incidence of POH of 40.6 per 100,000 girls and 52.2 per 100,000 boys 9-15 years old for the period studied (Paper I). The Swedish Barnhöft instrument for hip function showed good stability and construct validity (Paper II). Both intra- and inter-observer measurements for the different methods of slip angle assessment used on routine lateral hip radiographs showed good reliability (Paper III). Avascular necrosis (AVN) developed in 25 of 449 hips (379 children): 14 cases occurred in the 61 unstable hips, five in the 380 primary stable hips treated with percutaneous fixation, two in the eight stable hips treated with capital realignment, two in the four hips treated with reconstructive capital realignment and two secondary to a peri-implant femur fracture. After prophylactic fixation (n = 151) POH developed despite fixation in one hip and two children had a peri-implant femur fracture (Paper IV).		
Conclusions The male-to-female ratio was 1.3:1. The majority of Swedish hospitals treat fewer than two children with POH annually. The Barnhöft instrument can be used to identify children with a limited hip function or severe pain as sequelae after POH. In situ fixation is a valid primary treatment option for stable POH. For unstable POH, a very gentle reduction of the acute component followed by in situ fixation may be justified. The number of patients who developed AVN after capital realignment is of concern. Prophylactic fixation effectively prevents the development of a subsequent POH in the contralateral hip and is a safe method when performed correctly.		
Key words: physiolysis, hip, slipped capital femoral epiphysis, epidemiology, outcome, reliability, validation, health-related quality of life		
Classification system and/or index terms (if any)		
Supplementary bibliographical information Lund University, Faculty of Medicine, Doctoral Dissertation Series 2018: 119		Language: English
ISSN and key title: 1652-8220		ISBN: 978-91-7619-687-8
Recipient's notes	Number of pages	Price
	Security classification	

I, the undersigned, being the copyright owner of the abstract of the above-mentioned dissertation, hereby grant to all reference sources permission to publish and disseminate the abstract of the above-mentioned dissertation.

Signature

Date 2018-09-19

Physiolysis of the hip

Epidemiology and hip function

Bengt Herngren



LUND
UNIVERSITY

Contact information

Bengt Hergren

Tel. +46 10 2421500

Mail: bengt.hergren@med.lu.se

Cover front page illustration by Andreas Gunnmo

Cover photo by Charlotta Sjöstedt

Copyright pp 1-103 Bengt Hergren

Paper 1 © BioMed Central

Paper 2 © Springer Open

Paper 3 © Taylor & Francis

Paper 4 © Bone & Joint Publishing

Lund University, Faculty of Medicine Doctoral Dissertation Series 2018:119
Department of Clinical Sciences, Section of Orthopaedics

ISBN 978-91-7619-687-8

ISSN 1652-8220

Printed in Sweden by Media-Tryck, Lund University
Lund 2018



MADE IN SWEDEN 

Media-Tryck is an environmentally certified and ISO 14001 certified provider of printed material. Read more about our environmental work at www.mediatryck.lu.se

*You are never too old to set another
goal or to dream a new dream*
C.S. Lewis

To my family

Table of contents

Abstract	11
Background	11
Methods	11
Results	11
Conclusions	12
Populärvetenskaplig sammanfattning	13
Höftfyseolys – epidemiologi och höftfunktion	13
<i>Bakgrund:</i>	13
<i>Resultat:</i>	13
List of Papers	16
Acknowledgement	17
Abbreviations and definitions	20
The thesis at a glance	22
The purposes of this thesis	23
Introduction	25
Review of the literature	27
Aetiology	27
Slip severity	27
Epidemiology	29
Incidence	29
Sex and age	30
Height and weight	30
Seasonal variation	30
Left-sided predominance	30
Stability of the physis	30
Delay in diagnosis	31
Diagnostic imaging	31
Valgus SCFE	36
Bilateral POH	37
Histopathology	37
Single or multiple devices for fixation?	39

Position of implant	40
Is a physiodesis or continued growth of the femoral neck the goal when treating children with POH?	40
Treatment of severe and/or unstable POH.....	44
Can we lower the rate of AVN in unstable POH?	48
Post-operative care	48
Early reconstructive surgery after POH.....	48
Management of the contralateral hip in unilateral POH.....	50
PROMs	51
Materials and methods.....	53
Design	53
Recruitment of patients	53
Study populations	55
Study methods.....	57
Follow-up	57
Questionnaires	58
Subsequent procedures.....	58
Measurement of slip severity.....	59
Clinical classification	59
Reduction of an unstable slip	59
Accuracy of implant positioning	60
Body mass index (BMI)	60
Statistics	60
Paper I.....	60
Paper II	60
Paper III.....	61
Paper IV.....	61
Ethical considerations	62
Results	65
Paper I	65
Slipped capital femoral epiphysis: a population-based study.....	65
Paper II.....	69
Barnhöft: a hip specific 6-item questionnaire for children	69
Paper III.....	70
Good inter- and intra-observer reliability for assessment of the slip angle in 77 radiographs of children with a slipped capital femoral epiphysis.....	70
Paper IV	72
Outcomes after slipped capital femoral epiphysis – a population-based study with 3-years follow-up	72

Discussion	75
Limitations.....	81
Paper I.....	81
Paper II	81
Paper III.....	82
Paper IV.....	82
Conclusions	85
Further research.....	86
Errata	86
References	87

Abstract

Background

Physiolytic of the hip (POH), also called slipped capital femoral epiphysis (SCFE), is one of the most common hip disorders in children. The overall purpose of the work described in this thesis was to provide further information about the demographics of children who develop POH, to describe the early outcomes after treatment for POH including patient-reported outcome measures (PROMs), and to assess the reliability of the measurement methods used for radiographic assessment of POH.

Methods

The total Swedish population of 379 children (162 girls and 217 boys), who had POH in their index hip between 2007 and 2013, was used as the study cohort for all papers included. Early outcomes, radiographic and patient-reported, 36 months after primary surgery were analysed. A Swedish version of a hip function instrument (Barnhöft) was developed. Inter- and intra-observer reliability of the methods used to assess the slip severity on 77 radiographs was analysed by four observers with different levels of experience in radiographic measurement techniques.

Results

A cumulative incidence of POH of 40.6 per 100,000 girls and 52.2 per 100,000 boys 9 – 15 years old for the period studied (Paper I).

The Swedish Barnhöft instrument for hip function showed good stability and construct validity (Paper II).

Both intra- and inter-observer measurements for the different methods of slip angle assessment used on routine lateral hip radiographs showed good reliability (Paper III).

Avascular necrosis (AVN) developed in 25 of 449 hips (379 children): 14 cases occurred in the 61 unstable hips, five in the 380 primary stable hips treated with percutaneous fixation, two in the eight stable hips treated with capital realignment, two in the four hips treated with reconstructive capital realignment and two secondary to a peri-implant femur fracture. After prophylactic fixation (n = 151) POH developed despite fixation in one hip and two children had a peri-implant femur fracture (Paper IV).

Conclusions

The male-to-female ratio of POH was 1.3:1. The majority of Swedish hospitals treat fewer than two children with POH annually. The Barnhöft instrument can be used to identify children with a limited hip function or severe pain as sequelae after POH. In situ fixation is a valid primary treatment option for stable POH. For unstable POH, a very gentle reduction of the acute component followed by in situ fixation may be justified. The number of patients who developed AVN after capital realignment is of concern. Prophylactic fixation effectively prevents the development of a subsequent POH in the contralateral hip and is a safe method when performed correctly.

Populärvetenskaplig sammanfattning

Höftfyseolys – epidemiologi och höftfunktion.

Bakgrund:

Orsaken till sjukdomen Höftfyseolys är inte känd. Drygt 50 barn drabbas av höftfyseolys i Sverige per år. Vanligtvis är de mellan 9 och 15 år när de insjuknar. Höftens ledhuvud glider på sned (genom tillväxtzonen) i förhållande till lårbenshalsen. En kraftigare glidning medför en större begränsning av rörligheten i höftleden och förmågan att sitta bekvämt, cykla och t.ex. knyta skorna påverkas. I mycket uttalade fall kan även blodcirkulationen till ledhuvudet påverkas.

Vi vet att övervikt är vanligare hos dessa barn och vissa hormonella rubbningar ökar risken för att utveckla höftfyseolys. Båda höftlederna riskerar att drabbas hos ungefär hälften av barnen.

Alla barn med höftfyseolys behöver opereras tidigt för att den gradvisa ökningen av ledhuvudets felställning ska stoppas. Det görs oftast genom att en spik eller skruv fixerar ledhuvudets läge mot lårbenshalsen. Fördröjd diagnos och behandling försämrar prognosen.

Metod:

Samtliga barn- och ungdomar som opererats för höftfyseolys i Sverige under åren 2007 -2013 kunde spåras och inkluderas i den studiepopulation som utgjorde grunden för samtliga fyra delarbeten i avhandlingen. Med utgångspunkt i detta material kunde vi beskriva sjukdomsutbredning, riskfaktorer samt eventuella tidiga komplikationer inom tre år efter första behandlingen.

Tillförlitligheten av de mätmetoder vi använde undersöktes. Hur stor felställning som uppkommit kan man mäta på en röntgenbild. Fyra läkare, med olika lång erfarenhet av sådana mätmetoder, fick oberoende av varandra mäta på samma röntgenbilder. Självskattad upplevelse av livskvalitet, smärta samt höftfunktion hos barnen analyserades med hjälp av två enkäter. Den engelska enkät vi använde för värdering av höftfunktion och smärta fick först översättas och sedan anpassas utifrån svenska förhållanden för att passa barnen i de aktuella åldrarna.

Resultat:

Vi fann att i genomsnitt insjuknade i Sverige varje år 54 barn vilket motsvarar en årlig risk att insjukna om 7 per 100 000 barn i åldrarna 9 -15 år. Nästan hälften av de som insjuknade var flickor.

I genomsnitt hade barnen symtom i minst tre månader innan de sökte sjukvård. Ju längre tid med symptom desto större glidning hade hunnit utvecklas. Om knäsmärta var det symptom som ledde till en första kontakt med sjukvården så var det betydligt färre som fick rätt diagnos jämfört med om de sökte på grund av höft- eller ljumsksmärta.

Behandlingen som gavs var i mer än 90% en operation med fixation av ledhuvudet mot lårbenshalsen med en skruv eller spik. För knappt hälften av barnen gjordes en förebyggande operation samtidigt av den än så länge friska andra höftleden. Sjukdomen uppkom på båda sidor hos en fjärdedel av barnen.

Övervikt var mycket vanligt hos de pojkar som drabbades men förekom endast hos ca hälften av flickorna.

Den enkät (Barnhöft) som togs fram för detta arbete fungerade väl för att identifiera barn med svår smärta eller uttalad funktionsnedsättning i höftleden.

De mätmetoder som användes för att värdera svårighetsgraden av sjukdomen utifrån en röntgenbild hade hög tillförlitlighet och visade jämförbara resultat oberoende av erfarenhet hos den som genomförde mätningen. De gav också väldigt lika utfall när samma bedömare mätte på samma bild vid två olika tillfällen.

En majoritet av svenska sjukhus behandlar färre än två barn med höftfyseolys per år. En mer komplicerad behandlingsteknik, som använts vid ett par sjukhus för barn med mycket svåra felställningar, uppvisade en relativt hög komplikationsrisk.

Sammanfattning

I Sverige drabbas varje år i genomsnitt 54 barn av sjukdomen höftfyseolys. Det är nästan lika vanligt bland flickor som hos pojkar men pojkarna är i större utsträckning överviktiga.

Hälta, höft/ljumsksmärta, lår- eller knäsmärta utan föregående olycksfall hos barn 9-15 år måste undersökas noga avseende eventuell reducerad böj- eller inåtrötationsrörlighet för att inte fördröja korrekt diagnostik. Endast med en korrekt tagen röntgen, inkluderande en sidobild av båda höftlederna, kan sedan diagnosen fastställas. Muskelsträckning i ljumskan hos växande individer är mer ovanligt än höftfyseolys.

Barn med höftfyseolys, med en liten eller måttlig felställning i höftleden, har två år efter operationen en ganska liten påverkan på livskvalitet och höftfunktion samt oftast ingen eller endast lite smärta från höftleden vid ansträngning.

Vi noterade för några barn att kirurgen haft vissa tekniska svårigheter i samband med operationen. Dessa hade sannolikt i stor utsträckning kunnat undvikas och därmed minskat andelen svåra komplikationer efter höftfyseolys.

God kunskap om diagnostik och lämpligt val av behandlingsmetod för det enskilda barnet som drabbas av höftfyseolys är en förutsättning för att ge ett så gott slutresultat som möjligt.

De mätmetoder vi använder för att värdera sjukdomens svårighetsgrad är tillförlitliga och kan, med tillgång till bra instruktionsmaterial och korrekt tagna röntgenbilder, på ett mycket tillfredsställande sätt även göras av bedömare med mer begränsad erfarenhet av sådana metoder.

List of Papers

- I **Herngren B, Stenmarker M, Vavruch L, Hägglund G.** Slipped capital femoral epiphysis: a population-based study. *BMC Musc Disord* 2017;18(1): 304- 316.
- II **Herngren B, Stenmarker M, Enskär K.** Barnhöft: a hip specific 6-item questionnaire for children. *J Patient Rep Outcomes* 2017;1(1):16- 24.
- III **Herngren B, Lindell M, Hägglund G.** Good inter- and intraobserver reliability for assessment of the slip angle in 77 hip radiographs of children with a slipped capital femoral epiphysis. *Acta Orthop* 2018;89(2):217- 221.
- IV **Herngren B, Stenmarker M, Enskär K, Hägglund G.** Outcomes after slipped capital femoral epiphysis - a population-based study with 3-year follow-up. *J Child Orthop* 2018;12. Published online 29 August 2018. <https://doi.org/10.1302/1863-2548.12.180067>

The articles have been reprinted with the kind permission of the respective journals.

Acknowledgement

My sincere gratitude to all those who made this thesis possible. Special thanks to:

Gunnar Hägglund, my supervisor. I chose you because I had the clear impression that you would allow me a certain amount of freedom within the project and at the same time be able to support me as a senior colleague who was about to recommence my scientific career at 48 years old. This thesis could finally be compiled and presented thanks to the patience and guidance you have shown to me over the years, not least during the time-consuming period of collecting all data parallel with my intention to keep myself up-to-date in my clinical practice.

Margaretha Stenmarker, co-supervisor. You are not only a very competent scientific mentor but have been a close friend for many years. That combination has been of the utmost value to me throughout this project. With great enthusiasm and proficiency, you have guided me through some of the parts where I, as a paediatric orthopaedic surgeon, often tended to get lost. Many times, you helped me to keep focused and to be able to steer the project in the right direction.

Karin Enskär, co-supervisor. We only had a nodding acquaintance before this project started 12 years ago. Your encouraging enthusiasm and knowledge in the field of self-rated outcome measures for children have been of great value to me throughout the implementation of this work. We actually never fully agreed upon the number of items and domains to be used for the purpose of this project. However, when I called to your attention the fact that 81% of the children had responded to the questionnaires distributed by regular mail, I think that you finally came to accept my views to some extent. Your willingness to always discuss and try to solve problems that were somewhat difficult for me to grasp has been a true inspiration.

Bo Rolander, statistician. Thanks for your willingness to always be of assistance. I realize that my knowledge in statistics has improved “significantly” during these years. You always supported me in my clinical experience that “it’s not all about p-values – it must at the same time be of some clinical relevance”.

Mats P Nilsson, epidemiologist and statistician. You have taught me some of the secrets of epidemiology and what a total population such as ours means when it comes to the statistical presentation. Thanks to you, I finally came to understand and emphasize the use of cumulative incidence instead of other incidence calculations.

Ludek Vavruch, specialist in neurosurgery, co-author of paper I.

Mikael Lindell, specialist in orthopaedics, co-author of Paper III.

Lennart Landin, paediatric orthopaedic surgeon and former chairman of the Swedish Paediatric Orthopaedic Society (SBOF). You gave me early encouragement to implement a quality register with the capacity to use it also for scientific purposes. “If you want to become immortal, then epidemiology is always the foundation of clinical science”. During your period as the chairman of our society, you helped me resolve the doubts of our members about “another registration to make”.

My colleagues in the SBOF. Without your assistance, this project would never have been possible.

My colleagues in the Department of Orthopaedics in Jönköping, with special thanks to my colleagues and friends in the paediatric orthopaedic unit: Piotr Michno, Stefan Lind, Olof Risto, Anna Aspberg-Ahl, Johannes Eriksson, Mikael Lindell and Bakir Kadum. Thanks to your support and encouragement, I could finally make one of my dreams come true.

Camilla Wilkman and Heléne Schelin, two very devoted care administrators. With an effortless smile, you have assisted me throughout the years with all the time-consuming work of collecting radiographs and medical records from all hospitals in Sweden that treat children with POH.

My friends and close relations for being there; even if we don't talk or see each other on a daily basis, it's always the same when we do.

My parents, Inga and Rune, for your support to me in life, for always believing in me and making me believe in myself.

My sister, Barbro, and her husband Göran; as my older sister you have always been supportive and encouraging to your “little” brother. With your great linguistic expertise, you were also a most valuable member of the expert committee we used in Paper II. Göran, you are a person who has allowed some of your dreams in life to come true. That has truly inspired me over the years even if I will probably never obtain a pilot certificate or be able to handle an excavator like you.

My wife, Inger, the best, most understanding and loving person I have ever met. How you have been able to cope with me, especially during the sometimes very strained periods of completing this project, is beyond my imagination: ‘til death do us part’.

My children, Mattias and his wife Christin and Elin and her husband Andreas, together with our grandchildren **Natanael, Ingrid, Vilhelmina and Ruben**. Thank you for all the joy and love you have brought to our family. I have probably been preoccupied with various scientific ideas and work projects too often during the past couple of years been, but you have accepted me the way I am. I love you all.

This thesis was supported by grants from **Futurum – Academy for Health and Care, Jönköping County Council**

‘Everyone should look out not only for his own interests, but also for the interests of others’

Philippians 2:4

Abbreviations and definitions

AVN	Avascular necrosis (of the femoral head)
AP	Antero-posterior
CF	Calcar femorale
CHOHES	Children's Hospital Oakland Hip Evaluation Score
CT	Computed tomography
EQ-5D-VAS	Visual Analogue Scale that records the respondent's self-rated health (0-100) where 100 is the best health you can imagine and 0 is the worst health you can imagine (www.euroqol.org).
EQ-5D-Y	The child-friendly version of EQ-5D, a health-related quality of life instrument with five dimensions: mobility, self-care, usual activities, discomfort and depression (www.euroqol.org).
FAI	Femoroacetabular impingement
HRQoL	Health-related quality of life
HSA	Head-shaft angle
ICC	Intra-class correlation coefficient
Index hip	First hip to be diagnosed with POH. When bilateral POH was diagnosed at first presentation the hip with the longest duration of symptoms was identified as the index hip. If there was an equal duration of symptoms for both hips, then the hip with the most severe slip was considered the index hip.
ITO	Intertrochanteric osteotomy
MDS	Multi-dimensional Scaling, which is used for the analysis and visualization of categorical data.
MRI	Magnetic resonance imaging
NHS	National Health Service (UK)
NPR	Swedish National Patient Register
PIN	Personal identity number
POH	Physiolysis of the hip
PROM	Patient-reported outcome measures
PSA	Posterior slope angle

SBOF	Svensk Barn Ortopedisk Förening (Swedish Paediatric Orthopaedic Society)
SCFE	Slipped capital femoral epiphysis
SPOQ	Swedish Paediatric Orthopaedic Quality register
WHO	World Health Organization
UN	United Nations

The thesis at a glance

	Questions	Methods	Results	Conclusions
I	<p>What is the cumulative incidence of physiolysis of the hip (POH) in Sweden?</p> <p>Is a high BMI a risk factor for POH?</p>	<p>Prospective cohort study of 379 children with POH in their index hip between 2007 and 2013.</p>	<p>The cumulative incidence for POH in children 9-15 years old in Sweden was 40.6 per 100,000 girls and 52.2 per 100,000 boys for the period studied; 76% of the boys and 56% of the girls had a high BMI.</p>	<p>The cumulative incidence was similar to previous regional reports from Sweden. A high BMI is more common among children who have a POH than in the general population.</p>
II	<p>Can we develop a hip-specific patient reported instrument to identify children with a functional limitation or severe pain as sequelae of POH?</p>	<p>A Swedish version, Barnhöft, was developed based on an existing american paediatric instrument. Translation and cultural validation was performed.</p>	<p>The Swedish Barnhöft instrument for hip function showed good stability and construct validity.</p>	<p>Barnhöft can be used to identify children with a considerable functional limitation or with severe pain as sequelae of POH.</p>
III	<p>Are the methods used in Papers I and IV for the radiographic measurement of the slip angle in POH justified?</p>	<p>Conventional radiographs from 94 consecutively registered children with POH were assessed by two paediatric radiologists, one fourth-year resident in orthopaedics and one senior paediatric orthopaedic surgeon.</p>	<p>The inter- and intraobserver reliability analysis showed high intra class correlation coefficients for all the measurement methods used in Papers I and IV.</p>	<p>All methods analysed are justified for the assessment of the slip angle on routine preoperative lateral hip radiographs.</p>
IV	<p>How many children develop avascular necrosis (AVN) after POH?</p>	<p>Prospective cohort study of 379 children with 449 hips affected by POH. Inclusion period 2007-2013; 36 months follow-up.</p>	<p>AVN developed in 25 of the 449 hips. Six of 15 hips treated with capital realignment developed AVN.</p>	<p>The number of patients who developed AVN after capital realignment is of concern.</p>

The purposes of this thesis

The overall purposes of this thesis were to provide further information about the demographics of children who develop physiolyis of the hip (POH), risk factors for the development of POH, the subsequent risk of a contralateral POH, the early outcomes after treatment for POH including PROMs, and to propose an algorithm for the management of these children in a Swedish context.

- Paper I:** To describe the epidemiology of POH in Sweden using a prospective cohort study including all Swedish children treated for POH between 2007 and 2013.
- Paper II:** To translate into Swedish, culturally adapt, and validate a hip-specific questionnaire that could be used in children aged 8 years old or older.
- Paper III:** To assess the reliability of the measurement methods used for radiographic assessment of POH.
- Paper IV:** To describe the early functional outcomes, and complications after treatment for POH or a prophylactic fixation of the contralateral hip.

Introduction

Physiolysis of the hip (POH) is, together with Perthe's disease and developmental dysplasia, the three most common hip disorders in children. In 1957, Howorth suggested that the first medical description of POH was that by Ambroise Paré in the sixteenth century [1].

A number of different names have been used for this condition, with the earlier ones being based upon beliefs of a possible aetiology (e.g., tuberculosis or rickets). More recently, the terms slipped capital femoral epiphysis (SCFE) or slipped upper femoral epiphysis (SUFE) are mostly used in publications. However, both these commonly used terms are misnomers.

The deformity that develops with the disease is that the proximal femoral metaphysis and the femoral shaft rotate externally, going into varus and in extension [2-5]. The epiphysis of the proximal femur remains in the acetabulum, has not "slipped" outside its normal position, and the ligamentum teres remains intact [6]. Therefore, to use the term physiolysis of the hip [7-9] makes sense. The term used in scientific reports, originating outside Scandinavia, that comes closest to this is probably "idiopathic capital femoral physiolysis" as proposed by Kumar in 2002 [10]. However, although they are misnomers, the terms SCFE or SUFE are most widely accepted in the literature and SCFE has therefore been used in the four papers that constitute the foundation for this thesis.

Untreated POH has been reported to have a poor outcome [11, 12]. Surgical treatment is therefore recommended with the goal of minimizing impaired hip function and pain. From a long-term perspective, the main goal is to reduce the risk of degenerative joint disease (osteoarthritis). In situ fixation to stop further slippage has been the preferred method of treatment, although an immediate corrective osteotomy to restore the hip anatomy has recently been proposed as an alternative treatment regime. However, in situ fixation is still considered the gold standard for primary treatment of POH by most paediatric orthopaedic surgeons [13, 14].

Review of the literature

Aetiology

The aetiology of POH appears to be multifactorial. Identified biomechanical factors are obesity, increased femoral and/or acetabular retroversion, and increased physal obliquity, which all result in increased shear forces in the capital physis [15-21]. However, an increased acetabular coverage has not been shown to be associated with POH [20, 22, 23]. POH is also known to be associated with endocrine disorders, for example, hypothyroidism, hypogonadism, and hypopituitarism [24-26]. Children with renal failure osteodystrophy [27] or children who have undergone radiation therapy to the pelvis [28, 29] are also known to have a higher risk of developing POH.

Slip severity

The severity of the slip in POH is known to increase with a longer duration of symptoms, that is, a longer period with the disorder before a diagnosis is established and appropriate treatment is offered to the child [12, 30-34]. The recommended method of treatment [35, 36] and the outcome [33, 37, 38] depend on the severity of the slip. A more severe slip has a higher likelihood of leading to the development of osteoarthritis [39, 40]

The literature reports a number of different methods for measuring slip severity. The most commonly used are the lateral Southwick head-shaft angle (HSA) [41] (Figure 1) and the similar posterior slope angle (PSA) [42]. For the PSA, the intersection of the plane of the physis and a line perpendicular to the longitudinal neck-diaphysal axis is used rather than the femoral-shaft axis used in Southwick lateral HSA. Most authors have used the categories for slip severity described by Southwick [41, 43], namely, a mild slip (< 30 degrees), a moderate slip (30- 50 degrees), and a severe slip (> 50 degrees).

In Sweden, two other measurement methods have gained popularity: the calcar femorale (CF) technique on a Lauenstein view [44] (Figure 2) and the lateral Billing view [45] (Figure 3). One advantage with the CF method is that it can also be used after physal closure has occurred [44, 46, 47].

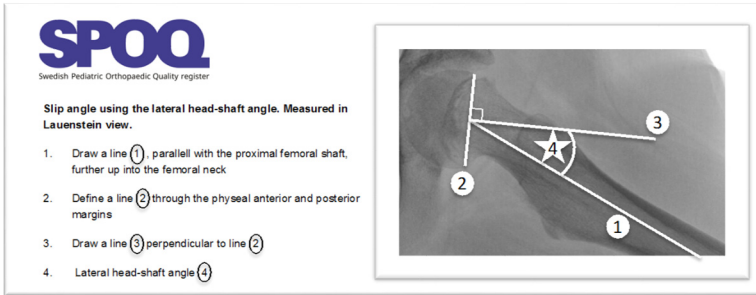


Figure 1. Southwick lateral head shaft angle (lateral HSA) method for assessment of slip angle.

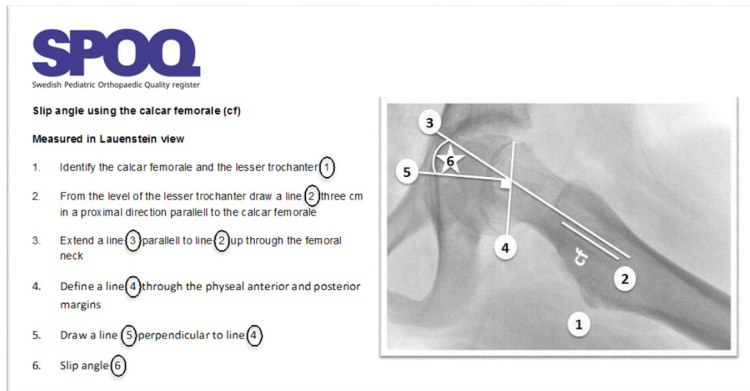


Figure 2. Calcar femorale method for assessment of slip angle.

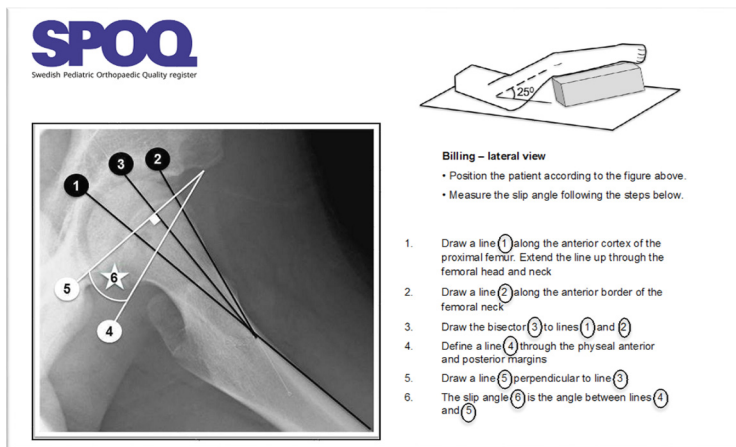


Figure 3. Billing method for assessment of slip angle.

Epidemiology

Although epidemiological data for SCFE have been reported from a number of countries, only a few studies were based on a total national population [48-53]. The latter are based on data from national registers, for example, the Kids' Inpatient Database in the USA [48], the national hospital registration system of the Netherlands [49] and Clinical Practice Research Datalink and Hospital Episode Statistics from the UK National Health Service (NHS) [53]. However, the latter report by Perry et al. was based on a database that in 2017 covered only 8% of the UK population.

Incidence

The incidence of POH is difficult to compare between studies because published reports have used different methods to present the incidence rate, including (1) attack rate calculated as the sum of annual incidence rate for every age group (7- 17 years) over the risk age range [9], (2) incidence rates for children aged 9-16 years (inclusive) using combined data for two years [48], (3) overall incidence for children aged 7-18 years over a 12-year period in relation to the total number of children of those age groups during one year in the middle of the study period [54], (4) the total number of surgical procedures for POH over a 13-year period for children aged 5-19 years related to the average number of boys and girls in that age cohort during the study period [49], (5) annual age-specific incidence rates calculated as the number of new cases of POH per 100,000 paediatric population (9-16 years, inclusive) [37], (6) incidence of the number of patients born in the same year related to the number of births during that year [55] and (7) the overall crude incidence rate [53] where the total number of children aged 6-16 years with POH is divided by the total number of persons in the population during the study period.

It is also difficult to compare reports of incidence of POH because incidence is related to ethnicity [56]. There is on-going debate about whether ethnicity should be reported unless prior studies have found race or ethnicity to be relevant to the topic under study [57]. In Sweden today, the Regional Ethical Board in Lund would not approve the recording of ethnicity in scientific work unless this is stated to be of critical importance for the fulfilment of the aims of the study (personal communication, 2017).

However, the incidence rate found during analysis of a large database (Kids' Inpatient Database) reflecting 6.7 million paediatric discharges in 1997 and 7.3 million discharges in 2000 was coupled with the US Census Bureau data to elicit the epidemiology of POH in children aged 9-16 years. The overall incidence for POH in the USA for these years was 10.8 per 100,000 children [48]. In a Dutch study, using the national hospitalization registration system between 1998 and 2010,

the total number of surgical procedures for POH in children 5-19 years old translated into an incidence of 8.8 surgical procedures per 100,000 children over that period [49].

Sex and age

The male-to-female ratio of POH has been reported to vary between 4.1:1 and 1.1:1 [48, 49, 51, 53, 55, 56, 58, 59]. In Sweden, the sex difference gradually diminished during the twentieth century [7]. A study by Perry et al. published in 2017, based on data from the UK NHS databases [53], reported a male-to-female ratio of 1.7:1. However, a Dutch study from 2013 [49] found no statistically significant difference between sexes. The majority of children with POH in these two latter series were 9-15 years old when the diagnosis was made.

Height and weight

The typical child with POH has been an overweight or obese boy [48, 60]. An interesting subgroup of underweight children with a relatively high risk of unstable POH has recently been described [14, 61].

Seasonal variation

Although a seasonal variation for the onset of symptoms in POH has been described, uncertainty remains concerning its role in the aetiology [48, 55, 56, 62-65].

Left-sided predominance

A left-sided predominance in unilateral SCFE has been reported [9, 66, 67]. This might be due to the fact that the left lower limb is the chief pivotal point for right-handed persons [66].

Stability of the physis

A clinical classification based upon the capacity to ambulate was introduced by Loder et al. [68]. Children with an unstable hip have such severe pain that they cannot ambulate even with crutches, regardless of the duration of the symptoms. This classification has now replaced the previously used classification (acute, acute-on-chronic, chronic) that was based on a combination of the radiographic appearance together with the duration of symptoms [43, 69]. However, some reports have questioned the use of a clinical classification of physal stability based only

upon the ability to ambulate. Within the group of unstable slips identified using this classification, the degree of stability of the physis has been shown to vary [6, 70-74]. Routine implementation of other investigations, for example, magnetic resonance imaging (MRI) or ultrasonography, might need to be considered to be able to identify those children with a truly unstable slip.

Delay in diagnosis

Most children seek medical care because of limping or hip/groin pain, which hopefully leads the health personnel towards the correct diagnosis. However, there are children who describe ipsilateral knee pain as their initial symptom of POH [53, 75], and these children are particularly at risk for a delayed diagnosis.

A considerable delay in diagnosis has been described in several studies [2, 33, 43, 53, 75-80]. The causes for such a delay are (1) the patient does not seek immediate medical attention after the onset of symptoms or (2) the health care personnel (doctors, physiotherapists or others) do not reach the correct diagnosis and/or do not order necessary radiological investigations, thus causing a further delay in diagnosis. It is also crucial to recognize that groin pulls are rare in adolescents [81], and that the much more common POH should be ruled out first using the appropriate radiological investigations.

When a radiographic examination is ordered, a lateral radiograph of the hip is a minimum requirement, because a mild POH cannot be identified on a plain antero-posterior (AP) pelvic view [9, 14, 44, 82-84]. Bomer et al. [85] even suggested the use of a frog-leg lateral view as the only radiological investigation in a child with a painful hip.

Diagnostic imaging

The typical radiological characteristics of POH have been described [67, 86, 87]. Already in the very early stage of POH, the surfaces of the epiphysis and metaphysis become irregular and no longer fit together.

In plain radiographs, “this is seen as an irregularity and a widening of the epiphysial line” [67]. An ordinary pelvic AP view together with a lateral view will reveal the diagnosis for most children (Figure 4). With time, a variable degree of metaphysial local resorption and apposition of bone along the superior and anterior femoral neck can be seen on plain radiographs [69, 88].

In a stable slip, a Lauenstein/frog-leg lateral view [89] or a Billing lateral view is preferable [45]; in an unstable slip, often only a cross-table lateral view can be obtained because of the severe pain and discomfort experienced by the child [90].

The importance of obtaining standardized views has been highlighted in the Swedish Paediatric Orthopaedic Quality register (SPOQ, www.spoq.se). Instructions for the radiology departments in Swedish hospitals are presented on their website. For a correct Lauenstein/frog-leg lateral view, the following criteria should be fulfilled.

- Supine position (i.e. the posterior aspect towards the picture-plate X-ray)
- Digital film cassette beneath the patient
- The symphysis pubis should be aligned with the contour of the sacrum
- Knees are bent at a right angle
- Abduction of the hips with the soles of the feet kept together
- The central beam through the upper part of the symphysis pubis
- A minimum of 5 cm of the femur visualized below the lesser trochanter
- Protection for the gonads should be used in boys
- Girls aged over 15 years should routinely be asked about pregnancy

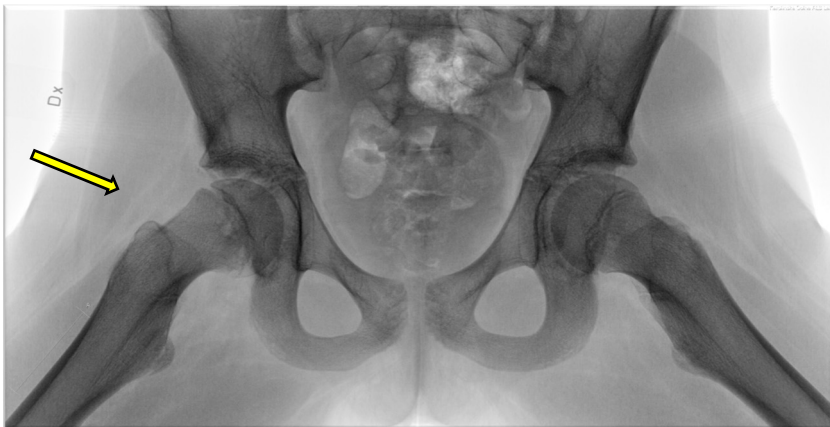

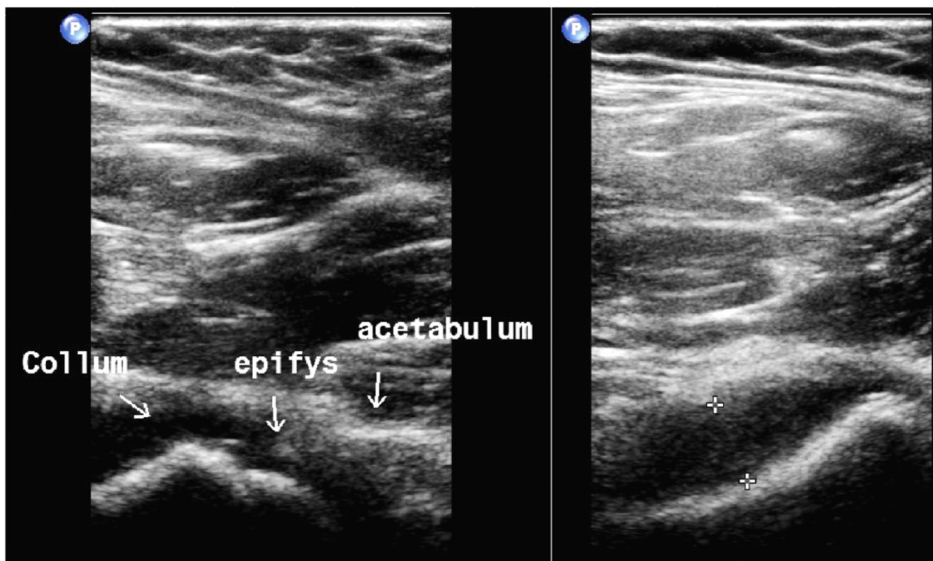
Figure 4. Lauenstein view of a mild POH in the right hip.

Pre-slip stage of POH. This classification has been used by some authors to define a child with occult hip pain without radiographic evidence of POH (i.e., the slip angle measurement has not reached the threshold level) who, if left untreated, would progress to POH. A plain radiograph would show a physal widening but no evidence of slipping of the epiphysis [9, 45, 91, 92]. Lalaji et al. [92] described two children with occult hip pain in whom repeat radiographs did not detect a slipping

of the epiphysis, although MRI demonstrated morphological distortion of the physis and bone-marrow oedema in the adjacent metaphysis and epiphysis. Both were true cases of POH that could be described as being at the pre-slip stage. In the past, a bone scan was sometimes used to demonstrate radionuclide uptake [93, 94], thereby identifying a pre-slip condition, but the evidence for the existence of a pre-slip has also been refuted by some authors [95]. In clinical practice, MRI [92] or ultrasonography [96, 97] of the hip might be useful when a child presents with hip/groin pain with difficulty in ambulation, and repeat plain radiographs do not show any evidence of a distorted morphology.

Radiostereometric analysis measures skeletal movements with high resolution. It is based on the use of implantation of tantalum markers during surgery and simultaneous radiographic exposure of the hip with the use of two X-ray tubes and a calibration system [98]. Radiostereometric analysis can be used during follow-up to understand and measure the degree of remodelling after “growth-sparing” fixation of POH [99].

Ultrasonography has been reported to visualize both a widening of the physis together with a joint effusion and a metaphysial alteration [96, 97] (Figure 5). Ultrasonography can also be used to assess severity and physal stability [73, 96, 100], and a slip with no sonographic effusion is very unlikely to be unstable [73].



A step is visualized by ultrasonography between the collum and epiphysis.

An effusion of the hip joint is also seen which is associated with an unstable POH

Figure 5. Ultrasonography that visualizes a mild deformity with a hip joint effusion.

Multiplanar computed tomography (CT) is probably the most reproducible method to assess the slip angle in POH [17, 20, 101-105] (Figure 6). It is already recognized as very useful when planning for corrective surgery or for understanding the true plane of deformity in more severe POH, but it has not been implemented for routine preoperative use for all children diagnosed with a POH in Sweden.

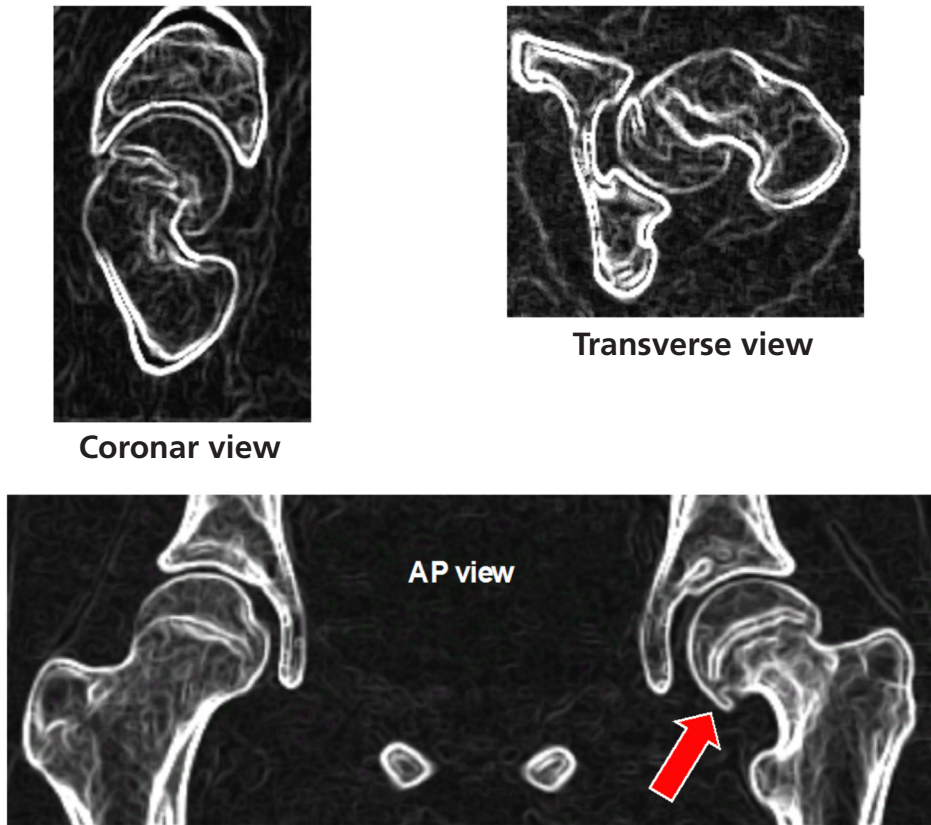
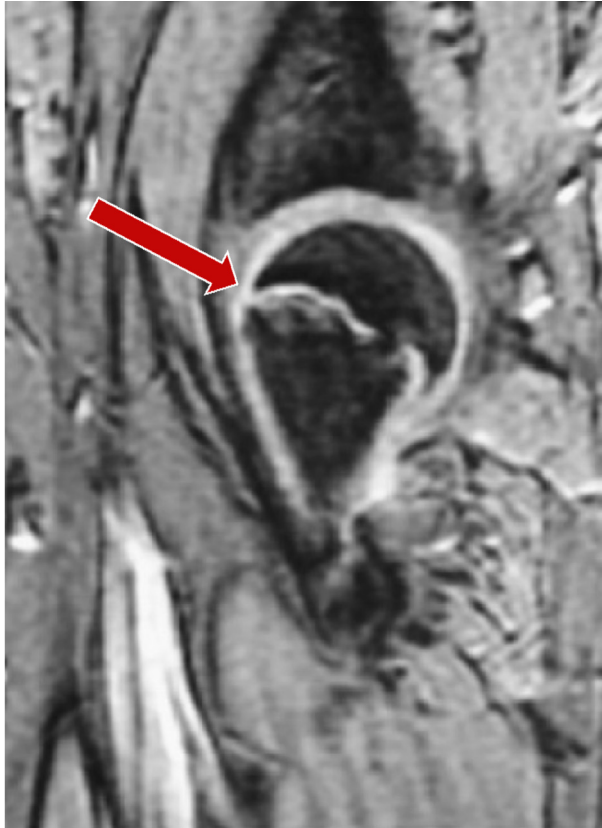

Figure 6. Computed tomography of a left hip with a severe POH.

Magnetic resonance imaging (MRI) has been shown to be able to visualize an unstable POH but can also be of great value to assess the vascular viability of the femoral head in POH, especially before surgical implants are introduced [74]. MRI can also visualize very early signs of POH (Figure 7) with oedema-like changes around the growth plate before the growth plate fails [91, 92, 106].



MRI coronar view shows an effusion of the hip joint and a mild displacement of the metaphysis versus the epiphysis.

Figure 7. MRI of a mild POH.

Bone scan has long been the method of choice for the evaluation of the vascular viability of the femoral head in POH, before and after surgery. It can be used as a reasonably sensitive predictor of the development of AVN, and also for evaluation of interventional treatment for AVN associated with POH [107].

Positron emission tomography has also been shown to have good sensitivity for detection of AVN [23, 108]. However, it remains an expensive and time-consuming investigation.

Single photon emission computed tomography (SPECT) is another modern imaging technique that was recently reported by Dos Santos et al. [109] to be able to assess the viability of the femoral head with a possibly higher diagnostic accuracy than a bone scan.

Delayed gadolinium-enhanced magnetic resonance imaging of cartilage (dGEMRIC) has recently been reported to be a useful tool for the early detection of cartilage degeneration after POH [40].

Valgus SCFE

This a very rare entity where the proximal femoral epiphysis slips laterally and posteriorly (Figure 8), usually in children who are younger than average for POH [32, 110-116]. Correct recognition of this condition is of great importance because the treatment can be much more challenging than that for classic POH. A more medial and caudal approach, closer to the neurovascular bundle, is needed than for the more classic POH.

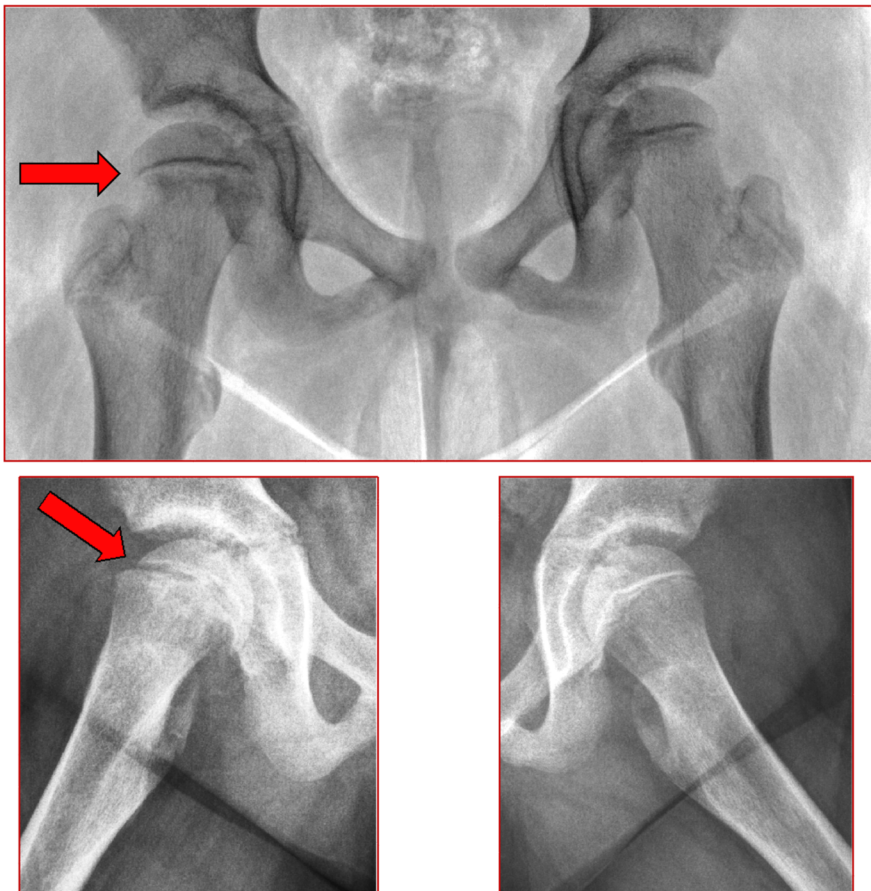


Figure 8. Valgus POH in the right hip.

Bilateral POH

The incidence of bilateral POH was reported to vary considerably before the implementation of prophylactic fixation [9]. This variability was found to depend mainly on whether the reports were based on the diagnosis of a bilateral POH during adolescence or on long-term follow-up studies where previously asymptomatic or mild POH did not cause the child to seek medical attention or the condition was not properly investigated. The highest incidences of bilateral POH reported with long-term follow-up including a cohort of at least 100 patients were 61% from southern Sweden [117], 59% from western Sweden [118] and 65% from Germany [119].

There are several reports on the proportion of children who are diagnosed with bilateral POH at their initial presentation. In a series from southern Sweden, including patients treated for POH between 1910 and 1960, the rate of bilateral POH diagnosed on primary admission was 9% (23/260) [117]. In a series from western Sweden with 100 patients treated for POH between 1946 and 1959, the incidence of bilateral POH on primary admission was 23% (23/100) [118]. In a report from a population-based analysis of 51 patients treated for POH between 1965 and 2005 in Olmsted County, USA, 6% (3/51) were found to have bilateral POH on primary admission [37]. In a large international multicentre study [56] including 1630 children, 14% (221/1630) were diagnosed with bilateral POH on primary admission. In a study from South Australia [19], 9% (23/244) had a simultaneous bilateral POH at their initial presentation.

Histopathology

Several studies have reported the histopathology of POH. The primary function of the physis is skeletal growth. The chondrocytes of the physis are located in three separate layers based on the maturation stage and function (Figure 9).

- The germinal layer (resting zone), adjacent to the epiphysis. These chondrocytes have a low rate of proliferation. Injury to this zone can easily create growth arrest.
- The proliferative zone. The chondrocytes are organized in well-defined columns. These cells are responsible for the longitudinal growth of the bone.
- The hypertrophic zone, adjacent to the metaphysis. This is where the final cell death and subsequent ingrowth of osteoblasts occur. No growth occurs in this layer. This is the weakest part of the physis and the slippage in POH or physal fractures occur in this zone.

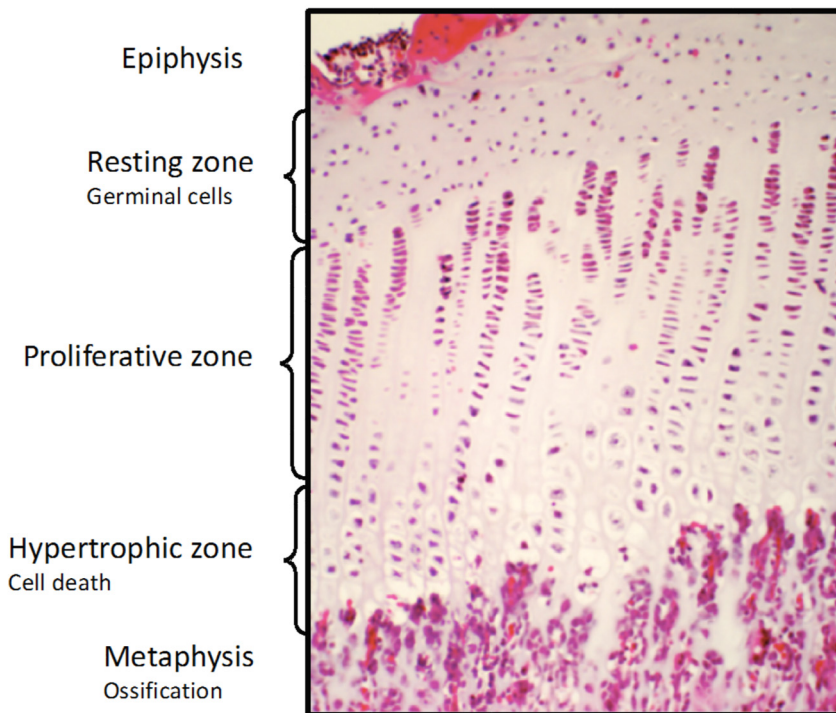


Figure 9. The cellular layers of the physis. Photo: Anders Bergström.

In 1977, Mickelson et al. [120] performed an electron microscopic study of the growth plate using core biopsies from three patients with POH. Core biopsies were obtained at surgery where a physodesis procedure was performed. The authors postulated that a change in composition of the cartilage matrix in the hypertrophic zone of the distal region of the growth plate may predispose to slippage. Ippolito et al. [121] also used core biopsies from patients with POH and proposed that a possible mechanism of the slippage was a change in the chondrocyte metabolism with consequently altered synthesis of extracellular collagen and scanty mineralization of the abnormal cartilage matrix. In 2003, Guzzanti et al. [122] compared chondro-epiphysial biopsies from nine children with a stable POH and nine with an unstable POH before and after internal fixation. They demonstrated an improvement in the histopathological appearance of specimens from unstable POH after internal fixation. Using basically the same technique with core biopsies, Tresoldi et al. [123] processed the specimens for either histological, histochemical

or ultrastructural studies. They found several changes, for example, loss of solidity of the cellular matrix and the disarrangement of the normal architecture of the physis, that very likely cause the consequent slipping of the proximal femoral physis. Chondrocytes of the proliferating and hypertrophic zones were arranged in large clusters rather than in columns. They also noted that the collagen fibrils of the longitudinal septae were thinner than those in normal-plate collagen fibrils and that the extracellular matrix of the resting zone had a different histochemical reaction compared with that of normal growth plates. In 2016, Johnson et al. [124] analysed core biopsies from two patients with POH and two age matched control specimens from children without POH. They used microarray technology to compare the gene expression patterns within the proximal femoral physis in children with POH and healthy children. They found a different regulation of inflammatory and immune responses in specimens from children with POH and concluded that this was related to mechanical displacement of the physis.

Single or multiple devices for fixation?

Can a single device prevent further slippage? The major disadvantage of using multiple pins or screws for internal fixation is an unrecognized penetration into the joint [9, 125-128]. An inadvertent positioning of a screw in the supero-posterior part of the femoral head is also thought to increase the risk of AVN or the development of a segmental collapse [129-131].

Using a model of unstable POH, Kishan et al. [128] demonstrated favourable in vitro stability using two screws rather than one over the physis. However, Karol et al. [132] also used an in vitro study to test stability after internal fixation for POH and proposed single-screw fixation because the addition of a second screw gave very little extra stability. Jerre et al. in [31] reported a follow-up of 212 hips with POH that were treated with a single device and concluded that this gave stability and prevented further slippage. Many other reports have also argued that a single device for internal fixation gives enough stability in POH [30, 125-127, 133-138].

In addition, Stambough et al. [130] and Morrissey [139] stressed that the risk of penetration of the joint was related to the number of inserted devices.

An explanation for why a single device inserted in the central part of the femoral epiphysis is sufficient to confer stability in POH was suggested by Jerre [9]. In the sagittal plane, the physis forms an arc [131, 140, 141] and the metaphyseal surface of the growth plate may be represented as one-quarter of a cylinder. Therefore, the fixation need only stabilize in one direction, and a single device inserted in the central part of the epiphysis and the physis will be adequate.

Position of implant

The implant used for internal fixation, should ideally be positioned as centrally as possible to ensure optimal stability and to avoid focal epiphysial necrosis [142]. Senthil et al. [143] compared intra-operative radiographs with post-operative CT and concluded that a screw-tip location within 6 mm of the subchondral bone in an AP view and within 4 mm on the lateral radiograph could result in penetration of the subchondral bone. Pring et al. [144] defined the achievement of a correct implant position when the implant was placed within the central 50% of the physal width, with the tip of the implant ≥ 5 mm across the physis, at least 5 mm from the subchondral bone, and at an angle of 70- 90 degrees to the capital physis (Figure 10).

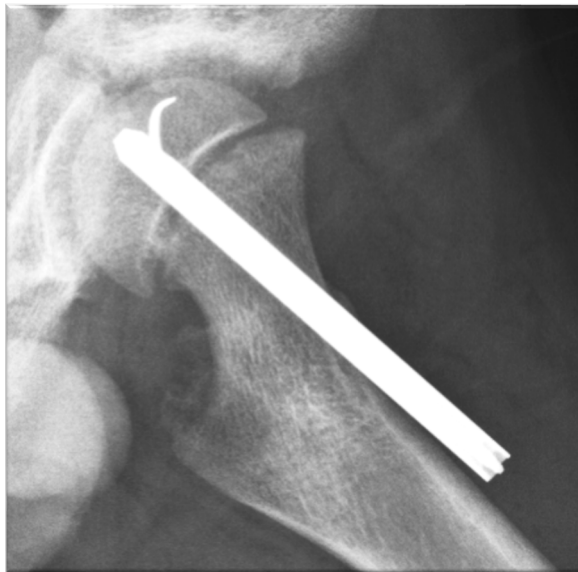

Figure 10. Correct implant position (Accuracy "A") according to Pring et al. [144].

Is a physiodesis or continued growth of the femoral neck the goal when treating children with POH?

The routine treatment goal for POH in many centres has been to achieve a physiodesis to prevent further slippage [81, 145-147]. This has the advantage of safely preventing a further slip, but the disadvantage of resulting in the development of a short femoral neck that decreases the femoral offset. This may cause subsequent problems, especially for a child who has several years of growth of the femoral neck remaining, as it can lead to a subsequently shorter lever arm for the abductor

muscles, thereby affecting the functional outcomes in adult life [148-150]. A shorter femoral neck in a hip with POH might also be a risk factor for femoro-acetabular impingement (FAI) in flexion and internal rotation [151-153], with the possible secondary development of osteoarthritis [154-156].

Continued growth after fixation for POH was first described by Key in 1926 [157]. Several fixation principles that allow for further growth of the femoral neck can be used [133, 158-162]. Hägglund et al. [163] measured the longitudinal growth of the femoral neck and reported up to 15 mm of growth after pinning with a smooth hook pin. A leg-length discrepancy can be avoided, and continued growth of the femoral neck may also have a positive effect on the long-term outcome [43, 88, 135, 163-167]. A recent study reported the use of a dynamic epiphysal telescopic screw in 20 children with POH without any early complications [160].

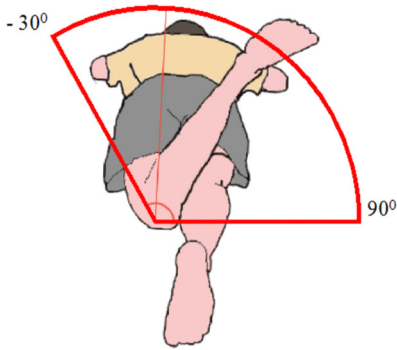
Treatment of a stable mild or moderate POH.

For mild or moderate stable POH, many authors favour in situ fixation [11, 13, 30, 43, 168-170].

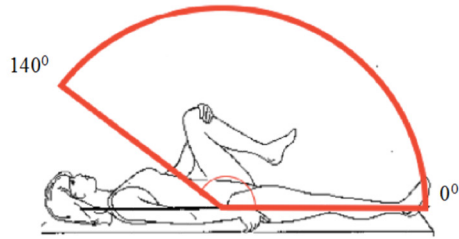
Several studies have supported the idea that metaphysal remodelling can be expected with time [43, 88, 166, 171, 172]. Already in 1959, Billing and Severin [173] concluded that remodelling occurred, reporting metaphysal bone resorption, and that the protruding metaphysis may be completely smoothed off even for a slip of up to 50 degrees. Schai et al. [174] used the term remodelling to describe the “rounding off” of the femoral head, including resorption of the cranial aspect of the metaphysis [165, 172, 175].

However, in 1991 Wong-Chung and Strong [165] described in a series of 55 hips with POH that there was not only a “rounding off” in the femoral neck metaphysis with time, but also that the physal-shaft angle changed. This was also noted for all 11 hips with severe POH in their series that were treated with internal fixation. Jones et al. [172] argued that remodelling from epiphysal growth cannot be expected in a hip with a more severe slip because the growth plate is often damaged [176]. They also argued that there was an inverse relationship between the severity of the slip at presentation and the degree of remodelling that could be expected.

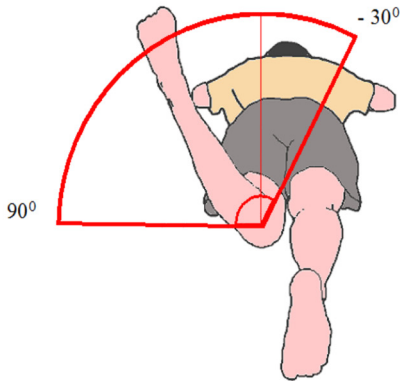
In 1988, Hansson et al. [177] analysed the range of motion of the hip in 43 patients with SCFE treated with in situ fixation. They concluded that the long-term loss of hip motion after fixation in situ was small: all 59 hips re-examined were classified as having a mild or moderate preoperative slip. For the evaluation of impaired hip rotation, the prone position has superior sensitivity over the supine or sitting positions and is therefore recommended [178, 179]. Within the Swedish Paediatric Orthopaedic Quality (SPOQ) register, we have standardized how the measurements for flexion and rotation of the hip should be performed (Figure 11).



External rotation is measured in the prone position. A goniometer is always used. Values are given in tens.



Flexion is measured in the supine position. A goniometer is always used. Values are given in tens.



Internal rotation is measured in the prone position. A goniometer is always used. If the internal rotation capacity is lost completely, as could happen in POH, the value will be 0° . Even a negative value can be found e.g. when there is only an external rotation possible from 10° or more. Values are given in tens.

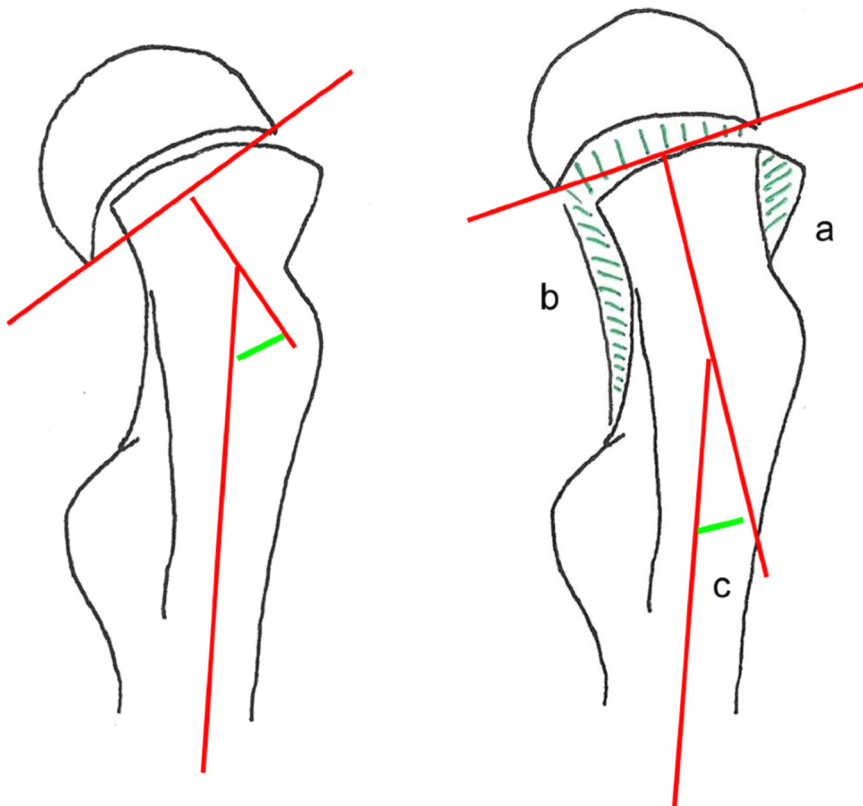


Figure 11. Measurement of hip motion.

Siegel et al. [176] analysed the gait of 39 children two years after treatment for POH. Although they concluded that early return of motion occurred, they could not demonstrate any corresponding change in the epiphysial-shaft angle on plain lateral radiographs.

Using the alpha angle as described by Nötzli et al. [180] as a parameter for the radiological evaluation of FAI, Örtengren et al. [166] reported a greater improvement of the alpha angle in patients with a greater degree of remaining growth. The most probable explanation for this finding is that during the continued longitudinal

growth of the femoral neck, the anterior “bump” in the head-neck junction will gradually move distally. Örtegren et al. [166] described this as the femoral head “growing away” from the FAI. They also found that a reduction of the lateral HSA occurred after internal fixation and proposed that the longitudinal growth over the proximal physis may also be asymmetrical, thus causing a re-orientation of the epiphysis in relation to the axis of the proximal femoral shaft (Figure 12). The Hueter-Volkman Law states that growth is highly influenced by mechanical stresses [181], but it also requires a proximal femoral physis that is not permanently damaged because of the severity of the disorder affecting the physis. Most remodelling will occur within two years after diagnosis and treatment of POH [165].



Remodelling after slipped capital femoral epiphysis with bone resorption anteromedially (a), bone deposition posteromedially (b), and asymmetric longitudinal growth measured as a reduced head-shaft angle (c).

Figure 12. Remodelling including “rounding off” and a true reorientation of the physis.

Treatment of severe and/or unstable POH.

The treatment of choice for an unstable POH [134, 182, 183], a severe POH or a combination of the two remains controversial. According to many proponents, a stable severe slip could be treated in the same way as mild and moderate stable POH (i.e., in situ fixation). This has long been the routine method in most paediatric orthopaedic units in Scandinavia [9, 135, 170, 184, 185].

However, a *modified capital realignment* procedure has recently been introduced for the treatment of POH, either as primary treatment or as reconstructive surgery [186]. Reports since 2000 from highly specialized centres have described encouraging short-term outcomes [71, 187-192] (Figure 13).

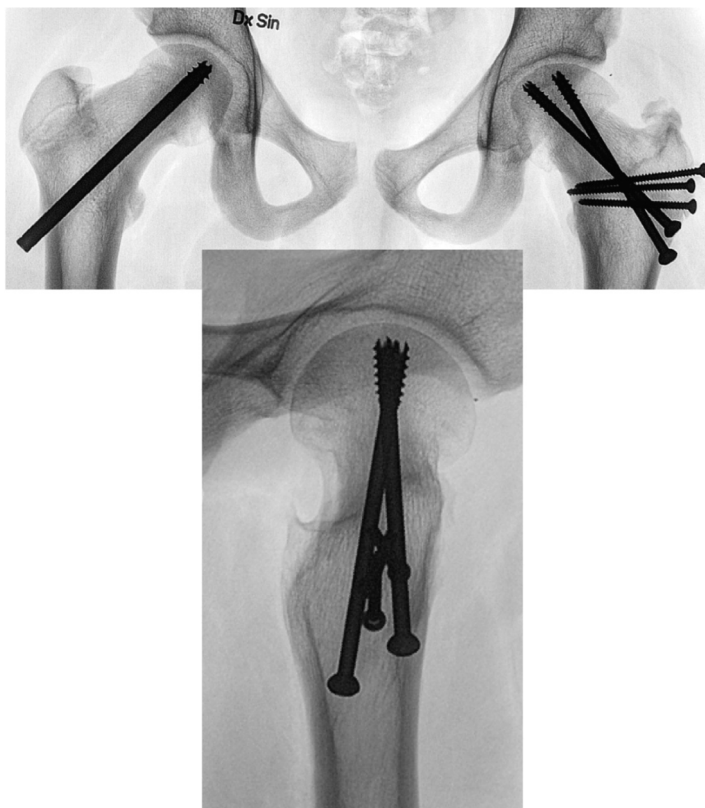


Figure 13. A successful capital realignment procedure in the left hip without AVN.

However, in 2017 Davis et al. [193] highlighted an increased risk for AVN in stable POH treated with a capital realignment procedure, and Sikora-Klak et al. [194]

advised against the capital realignment procedure in stable POH. Several recent reports have described a higher rate of complications than the more encouraging results reported in earlier studies [35, 194-198]. Despite the very promising early Swiss reports [71, 187] concerning the AVN rate and outcomes after a capital realignment procedure, the experience from North American tertiary centres for paediatric orthopaedics has not been able to reproduce the same low AVN rates, for either a stable POH or unstable POH.

Hip instability after capital realignment. The devastating complication of hip instability after a capital realignment procedure has been reported [199-201]. This rare but severe complication must also be considered among the other reported complications when a decision is made about a capital realignment procedure for POH.

Treatment for an unstable POH remains controversial according to the results of a questionnaire distributed to members of the Pediatric Orthopedic Society of North America (response rate, 33%) published in 2005 [202]. A similar survey was conducted among members of the European Paediatric Orthopaedic Society in 2009 (response rate, 25%) with similar results [203].

Vascular supply to the femoral head in children was studied by Chung in 1976 [204]. The epiphysal plate constitutes a barrier to blood flow between the epiphysis and the metaphysis. The posterior-superior retinacular vessels provide the major blood supply to the epiphysis [3, 205]. If these vessels are disrupted by abrupt displacement of the epiphysis (e.g., an unstable POH), this may result in the

subsequent development of AVN, regardless of the treatment offered to that child. If these retinacular vessels are kinked or twisted, but otherwise intact within a sleeve of posterior retinaculum, this might cause a compromised blood flow to the epiphysis that could be restored with a timely and gentle restoration of the anatomy. The return of a normal blood flow after the open reduction of an unstable POH has been demonstrated by perioperative angiography [205, 206]. Novais et al. [207] described that perioperative monitoring of the blood flow during a capital realignment procedure – either by the use of a catheter anchored in the epiphysis for intracranial pressure measurement or through monitoring of active bleeding from drilled holes in the epiphysis - was an effective method to identify children who would subsequently develop AVN.

Elevated intraarticular pressure has also been studied in unstable POH. Herrera-Soto et al. [208] measured the intracapsular pressure in 13 unstable hips. The mean intracapsular joint pressure of the unstable hips measured 48 mmHg, which increased to 75 mmHg after manipulative reduction, and dropped to 17 mmHg after capsulotomy and decompression. However, a systematic review and meta-analysis by Ibrahim et al. [209] found no support for hip decompression in unstable hips.

Timing of surgery in unstable POH has been proposed as crucial for the development of AVN [3, 210-212]. It has also been stressed that surgery for an unstable POH would ideally be performed within 24 hours after the onset of symptoms. In 1997, Peterson et al. [3] presented a large series of 91 cases of acute POH, defined as a sudden onset of usually severe symptoms with a duration of symptoms of less than three weeks [68], where closed reduction under general anaesthesia was performed. All cases were reduced to less than one-third of the diameter of the epiphysis. They grouped all 91 cases with respect to time interval between presentation to the emergency department and reduction in the operating room. For the 49 hips reduced more than 24 hours after presentation, the AVN rate was 20% (10/49 hips). For the 42 hips reduced within 24 hours, the AVN rate was 7% (3/42 hips). The presence of an intact posterior retinaculum sleeve with the superior-posterior vessels during open surgery and internal fixation was found by Peterson et al. [3] to be a favourable prognostic factor.

Preoperative traction with delayed definitive surgery has been used by some centres to treat unstable POH. Various AVN rates have been described in mostly small retrospective series of hips with unstable POH. Three of 11 hips developed AVN in a series by Thomsen et al. [213] and three of 14 hips in a series by Dietz et al. [214]. Matsushita et al. [146] used traction with flexion of the hip until the effusion settled. This was based on a report by Vegter et al. [215] in hips with Perthe's disease where the intra-articular pressure was lowered in flexion of the hip joint because of synovitis with effusion. Matsushita et al. [146] reported that one hip of 11 developed AVN. Preoperative traction was also included in the treatment algorithm for unstable POH presented by Uglow and Clarke in 2004 if the delay from onset of symptoms to surgery was more than 24 hours [168]. Preoperative traction might be an option for severe unstable POH that presents more than 24 hours after the onset of symptoms. While waiting for the effusion and the pain to subside, a preoperative investigation to assess the femoral head viability could be valuable to assist the decision about treatment.

In situ fixation of an unstable POH. The opponents of reduction contend that in situ fixation usually provides acceptable functional results with a lower risk for the development of AVN [7, 9, 30, 216-218], and that the risks of secondary architectural disorders such as a FAI with a risk of early osteoarthritis do not outweigh the risks of the development of AVN. Sailhan et al. [217] presented a series of 23 cases with mild or moderate unstable POH treated with in situ fixation, without any attempt at reduction, within 12 hours after presentation to the emergency department, none of which developed AVN. However, in situ fixation might not always be possible in very severe POH unless a very gentle reduction manoeuvre is implemented or an open reduction is performed (Figure 14).

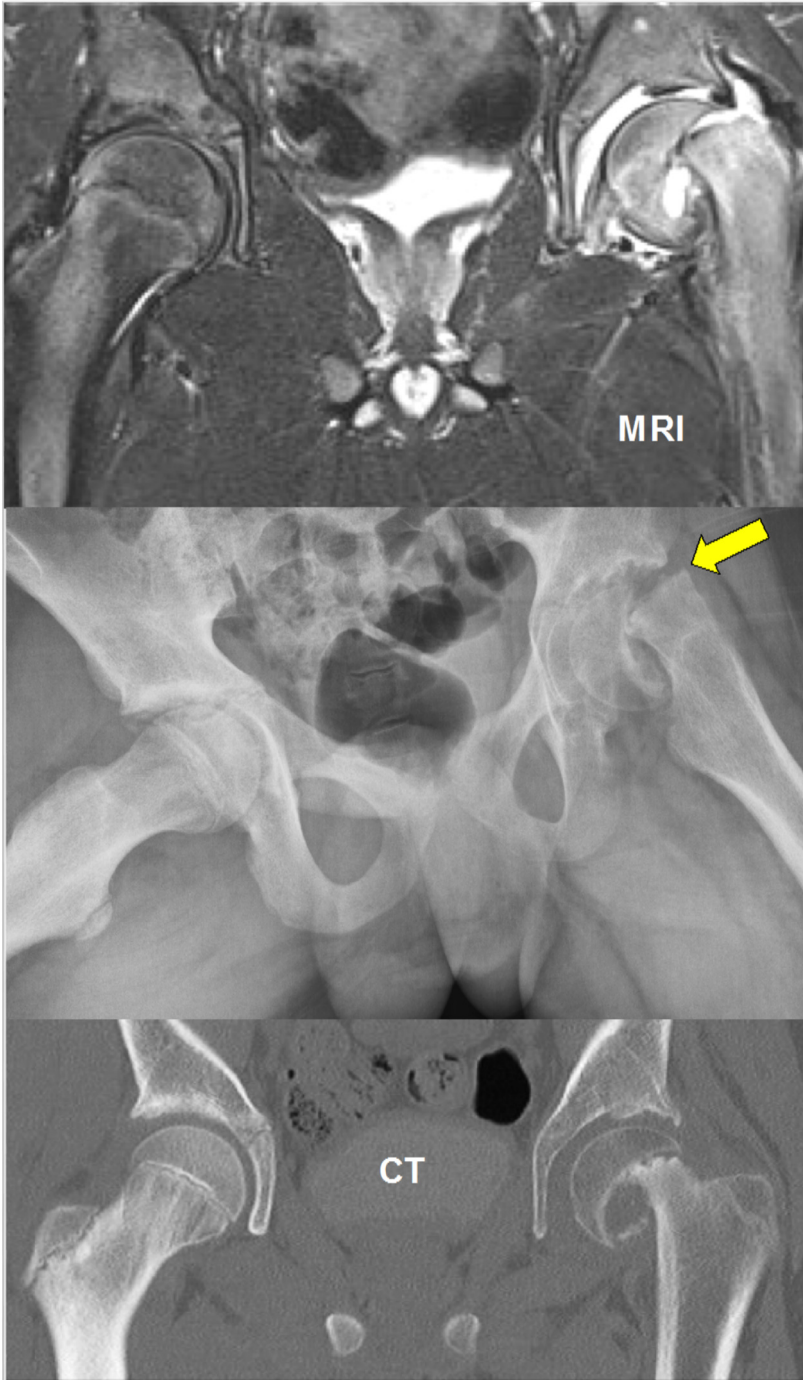


Figure 14. Unstable severe POH left hip. Right hip is normal.

Can we lower the rate of AVN in unstable POH?

If vascular kinking and an elevated intracapsular pressure are the major causes of AVN, then an urgent but very gentle reduction of the unstable part of the POH together with joint decompression may be the ultimate procedure.

Chen et al. [219] presented a series of 28 children with unstable POH where an urgent reduction, internal fixation and decompressive arthrotomy were performed within 24 hours, with the result that four of 28 hips developed AVN.

Parsch et al. [220] reported 64 cases of clinically unstable POH where an urgent arthrotomy was performed within 24 hours of onset of symptoms. They performed an open gentle manipulation of the epiphysis followed by internal fixation with smooth K-wires; three of the 64 cases subsequently developed AVN. However, it must be noted that Parsch et al. used slightly different criteria to define unstable POH compared with the original classification by Loder et al. [68] namely, an unstable POH must present with a sudden onset of pain together with a sanguine or clear effusion in the joint at surgery.

Post-operative care

The reported postoperative interval until weight-bearing is allowed varies from a few days to three months. There is no proof that prolonged prevention of weight-bearing in stable POH confers an advantage [139, 185]. In unstable POH, many authors advocate prevention of weight-bearing for at least six weeks after surgery, but the rationale for this time period has not been presented. Therefore, it is likely that gradual weight-bearing with the support of crutches could be initiated once the effusion in the joint has been verified to have normalized.

Early reconstructive surgery after POH

This procedure may be an option in selected cases. Salvage procedures (e.g., hip replacement, pelvic support osteotomy or arthrodesis) are not discussed here.

A modified capital realignment procedure has already been discussed. I will make a few additional comments about other procedures that might be appropriate in selected patients during adolescence to manage problems such as a decreased range of motion in the hip that affects hip function or hip/groin pain that has been identified to be caused by a FAI.

Femoral neck osteoplasty was described in 1965 by Wilson [66]. It has been included as a supplementary procedure during trochanteric osteotomy or has been used alone, performed either through an open approach with a surgical dislocation [221] or as an arthroscopically assisted procedure.

Trochanteric osteotomies do not realign the proximal femur, as occurs in a capital realignment procedure, but they have the great advantage of being potentially safer with regard to vascular complications. Trochanteric osteotomies are preferably performed after physal closure has occurred. Favourable results were reported by Cherkasskiy et al. [4] using a three-dimensional triplane trochanteric osteotomy; they also used three-dimensional printing models and surgery in the laboratory prior to surgery in the operating room. In 2014, Bali et al. [222] presented their results in a small series of 20 hips where they performed a supplementary osteo-chondroplasty in 13 hips that gave better range of motion compared with the seven hips in which a three-dimensional trochanteric corrective osteotomy alone was performed. No instance of AVN was reported. Erickson et al. [223] and Spencer et al. [224] reported favourable results after a combined Imhäuser trochanteric osteotomy [225] with a simultaneous osteo-chondroplasty performed for POH using the surgical hip dislocation procedure as described by Ganz et al. in 2001 [221]. They reported no instances of AVN in these two small studies (n = 25). There are also reports where an Imhäuser intertrochanteric osteotomy (ITO) in a child with POH was used alone without any supplementary surgery. AVN rates of 2- 5% were reported after treating hips with an ITO for moderate and stable POH [226], severe and stable POH [227] and moderate to severe stable POH [228]. Figure 15 shows an ITO performed as a reconstructive procedure.

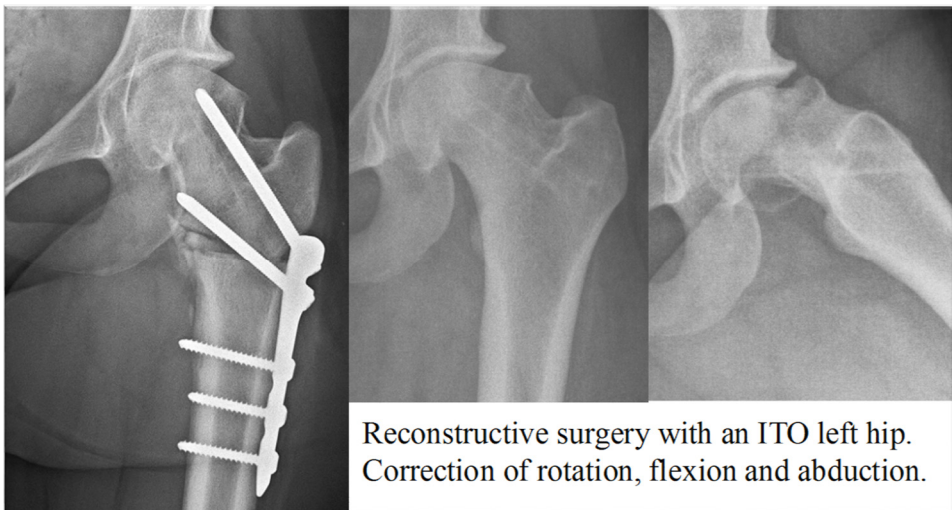


Figure 15. Intertrochanteric osteotomy after physal closure as reconstructive surgery, left hip.

Management of the contralateral hip in unilateral POH

Prophylactic fixation for unilateral POH remains a controversial issue. However, there is no controversy about the need for prophylactic fixation in children with a concomitant endocrine disorder [229].

Proponents of prophylactic fixation stress the risks of a subsequent contralateral slip with functional limitations if an unstable slip develops; there is a risk of AVN and/or later development of osteoarthritis, and at the same time, a reasonably low risk of iatrogenic complications associated with modern techniques [184, 229-231].

Others support the idea of clinical and radiographic follow-up until physeal closure [94, 232-235]).

Some authors have attempted to develop an algorithm in which prophylactic fixation is offered to children at higher risk of developing a sequential slip in the contralateral hip based on skeletal immaturity [32, 50, 236-238], sex [184, 236] and modified Oxford bone-age score [239]. Compliance regarding the family's ability to return for regular follow-up visits has also been proposed as a factor to consider [234].

Using a threshold of 15 degrees, PSA has been proposed as the criterion for prophylactic fixation in the asymptomatic contralateral hip [240]. Other reports have proposed PSA thresholds of 14 degrees PSA [241], 13 degrees [242] or 12 degrees [42]. Southwick [41] reported a normal variation of the lateral HSA measurement of 0- 25 degrees. Other authors have used a similar approach, using the Billing angle or the CF measurement [44, 233, 243] with 13 degrees as the threshold to define an asymptomatic hip with SCFE that needs treatment.

Zenios et al. [244] conducted an inter-rater reliability test with four surgeons measuring the PSA in 47 unaffected contralateral hips after unilateral POH. They achieved a good intraclass-correlation coefficient (ICC) of 0.83 and proposed a threshold of 14.5 degrees PSA for prophylactic pinning. Using this cut-off value, they calculated the number needed to treat to avoid one future slip to be 1.9.

Novais et al. [245] described anterior plane reference values for the epiphysial tilt using CT. Monazzam et al. [246] reported normal values by measuring the axial oblique plane, using both MRI and CT. Kienle et al. [247] presented similar normal values for asymptomatic children (aged 9- 17 years) using MRI in the axial plane. However, further research is needed to identify a threshold for the risk of later development of POH using these newer imaging modalities.

Castro et al. [248] summarized data from 45 eligible studies. They calculated that a child with unilateral POH is 2335 times more likely to present with a contralateral POH than an age- and sex-matched child.

Bidwell and Stott [237] reported a single-unit series of 171 children with unilateral POH treated between 1998 and 2000. They identified 56 of the 171 patients (31%)

who re-presented with a later contralateral POH. They also noted differences between ethnic groups concerning the risk of development of a subsequent contralateral POH.

A later development of POH in the contralateral hip has been reported as less likely to be a severe or unstable slip [37, 50, 232, 238, 249].

Using a database of 192 CT scans of abdomens/pelvises of patients aged 5- 19 years with no known orthopaedic issues, Monazzam et al. [246] compared these with CT scans of patients treated for FAI. They noted a difference in the growth-plate tilt angle and concluded that the majority of idiopathic cam morphology are not the result of subclinical POH.

To summarize the discussion about whether prophylactic fixation should be offered, it could be argued that for an otherwise healthy child (i.e., no concomitant endocrine disorder) with a unilateral POH at the initial presentation, the choice should be either prophylactic fixation or implementation of a structured follow-up programme with repeat radiographs together with repeat and thorough information to the family about the necessity for urgent radiographic examination whenever symptoms occur on the contralateral hip, provided that the family is judged to be compliant with such a programme.

PROMs

The UN Convention on the Rights of the Child [250] states that every child should have equal rights and the right to live as normal a life as possible regardless of their prerequisites. Consequently, children should be consulted about their goals for treatment to maximize their participation in the encounter. When health care professionals have access to information about the child's health-related quality of life (HRQoL) assessment, it is more likely that they will discuss the issues with the child [251]. The Swedish Patient Health and Medical Services Act (SFS 2014:821) stresses that health care should be designed so that patients, including children, participate in their own care and treatment [252].

Health has been described by the World Health Organization (WHO) as follows: *“Health is a state of complete physical, mental and social well-being and not merely the absence of disease or infirmity”* [253]. It has been found that from a child's perspective, it is important to discuss a range of issues about health [254]. The instruments used should preferably be completed by the person (child) alone, without interpretation from others, for example, health care professionals [255]. Children relate more to “here and now” whereas parental perspectives often reflect more abstract elements such as the future [256].

Generic measures for children and disease-specific instruments have been developed [257]. HRQoL-instruments have been used for adults in a long-term follow-up study after POH [258]. For children, the EQ-5D-Y [259, 260], a simple and short instrument for the assessment of HRQoL, has been developed and translated into Swedish. In adults, the EQ-5D instrument has been shown to have problems because of a high ceiling effect and a bimodal distribution that make evaluation difficult [261]. However, in a study by Burström et al. [260], the relatively high ceiling effect seen in a general population [262] was reduced in a patient sample and found to be manageable in a Swedish population of children and adolescents with functional disability. The Swedish EQ-5D-Y has no algorithm for evaluation other than at the item level.

A 2015 literature review by D'Entremont et al. [263] aimed to identify a hip-specific PROM that was validated for children. They found that several adult hip scores (e.g., Harris hip score, Iowa hip score) had been applied in paediatric hip impingement disorders without evidence of validation in any paediatric population. However, they identified one validated hip function score for children, the Children's Hospital Oakland Hip Evaluation Scale (CHOHES), which was originally used in a population with AVN in sickle cell disease [264]. The only published application of this scale was in a population of children with osteonecrosis secondary to the treatment of developmental dysplasia of the hip [265], which was not the population for which it was originally validated [264].

Materials and methods

Design

Papers I and IV were based on a prospective cohort study including all children treated in Sweden for POH in their index hip between 2007 and 2013.

Paper II included 25 children from the prospective cohort study described in Papers I and IV. Thirty-five healthy children were selected as a control group. The procedure of translation into Swedish of an established US paediatric hip-specific questionnaire was described together with its cultural adaptation and the validation process for the instrument.

Paper III utilized lateral hip radiographs of 94 children from the same prospective cohort study as in Papers I and IV, to analyse intra- and inter-rater reliability for three different methods for measurement of slip severity.

Recruitment of patients

A Swedish national quality register (Svenska Höftfyseolysregistret) was initiated in January 2007 to identify and analyse data for children with POH. Svenska Höftfyseolysregistret was to be used as a basis for quality assessment of routine care in Sweden and for future scientific work. This objective was presented to the Board of the Swedish Paediatric Orthopaedic Society (SBOF) in 2006. It was given full support by the SBOF Board and all members of the society were then personally informed. By that time, there were 39 orthopaedic departments (or orthopaedic units within a surgical department in smaller hospitals) where children with POH were treated. All medical directors of the concerned departments or units were personally contacted and they all agreed to participate. A care administrator together with an orthopaedic surgeon were selected in each hospital by the medical director to work as contact persons for this register. Documents to be used to provide written information to the children and a parent or guardian of each child, together with processes for documentation of informed consent in the medical records were established and distributed. The annual meeting of the SBOF confirmed that this quality register would commence on January 1, 2007.

Consecutive registrations were made for each child with POH. *Inclusion criteria* were children living in Sweden and registered in the Swedish Population Register with a Swedish personal identity number (PIN). *Exclusion criteria* were slipped epiphysis caused by a high-energy trauma or septic coxitis.

Medical records, school health records and radiographs were analysed by the director of the register (BH). A follow-up of each participating hospital was made at least twice annually to ensure that all established procedures had been followed and that all children treated for POH had been offered the opportunity to participate in this register. The purposes of the register were to assess and describe the quality of medical care for children with POH in Sweden together with analyses of group-level data for scientific publication.

The scientific database was established in 2013. It included all variables recorded in the quality register database plus some additional variables (e.g., PROMs). Data for children with POH in their index hip between 2007 and 2013 were included in the scientific database. For purposes of monitoring the completeness of the database, we were retrospectively provided with individual-based data from the Swedish National Board of Health and Welfare. All children in Sweden treated for POH of the index hip between 2007 and 2013 were admitted to hospital. It is established by Swedish regulations that all hospitals must register all admissions using diagnostic codes (WHO classification ICD-10) and treatment codes according to the Nordic Medico Statistical Committee - Nordic Classification of Surgical Procedures. It was therefore possible for this analysis to compare the in-patient records in the scientific database and the Swedish National Patient Register (NPR) using the PIN. This comparison between the different databases identified 35 children with a POH of the index hip during the study period who were registered in the Swedish NPR but not in the scientific database. Through written contact with the concerned children and with the parents or a guardian for each child, all 35 children were included in the scientific database following the receipt of their informed consent to participate. Therefore, database completeness and a coverage of 100% were finally achieved (i.e., all children treated in Sweden for POH of their index hip between 2007 and 2013 were included).

In 2014, Svenska Höftfyseolysregistret was made part of the newly established SPOQ register (www.spoq.se).

Study populations

The population used for **Papers I and IV** is outlined in Figure 16. The epidemiology of POH in Sweden was described in a prospective cohort study including all 379 children treated for POH in their index hip between 2007 and 2013.

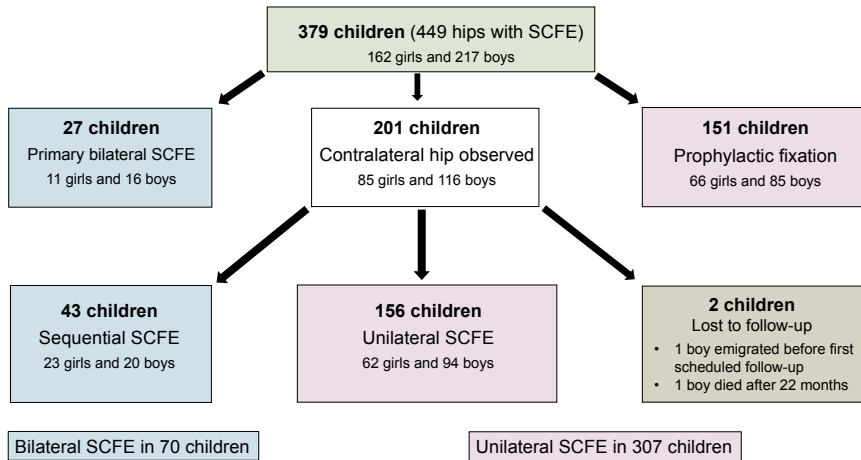


Figure 16. Study population in Paper I and IV

In **Paper II**, the study population comprised 25 children registered in the scientific database for POH together with 35 healthy children (Figure 17). The 35 healthy children, aged 8- 15 years, were selected for this study via organizations offering weekly organized sport activities within the city of Jönköping, Sweden.

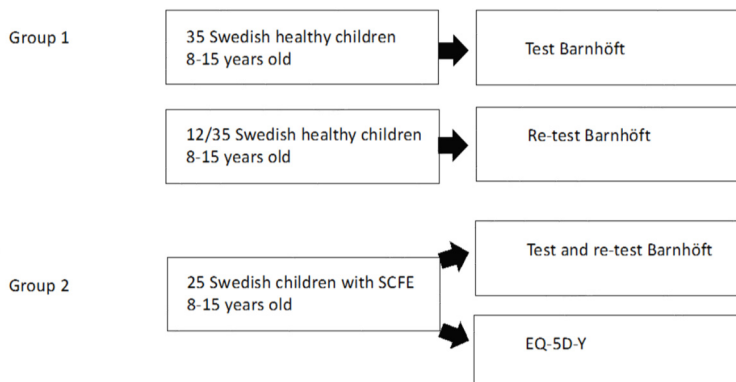


Figure 17. Study population in Paper II.

In **Paper III**, we used radiographs from 94 children with POH from the scientific database. The study material is described in Figure 18. Analysis was conducted of inter- and intra-observer reliability of three different methods to measure slip severity as assessed by two paediatric radiologists, one senior orthopaedic surgeon (this doctoral candidate), and one fourth-year year resident in orthopaedic surgery

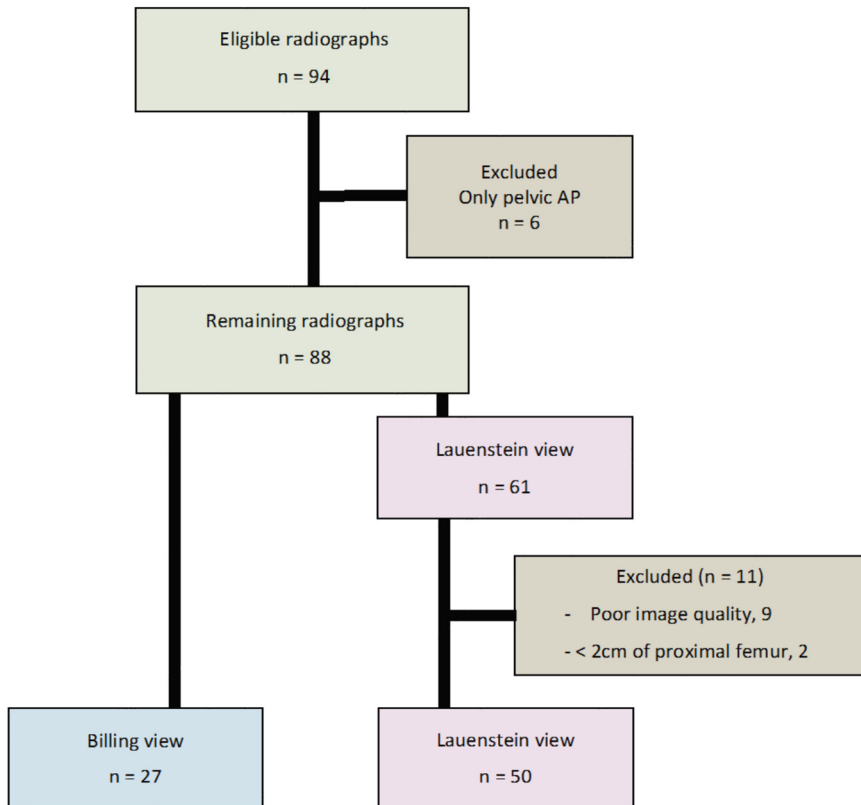


Figure 18. Study material in Paper III.

In **Paper IV**, we used the same prospective cohort of 379 children with 449 hips as in Paper I. We conducted a follow-up after 36 months to identify radiographic complications and subsequent surgery performed. Figure 19 presents the children who completed the PROM two years after the primary surgery reported in Paper I.

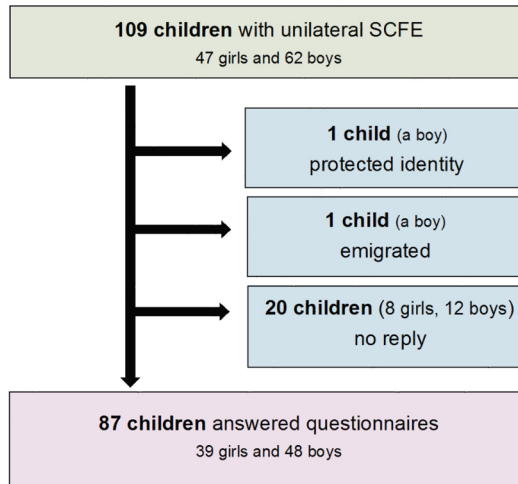


Figure 19. Children who answered prospectively distributed questionnaires in Paper IV.

Study methods

Follow-up

Consecutive annual follow-ups were conducted for each child included in Papers I and IV, up to 36 months after the primary surgery. This was carried out through the selected contact persons at the hospital where the primary surgery or follow-up was performed. All reported events within 36 months from the date of the primary surgery were registered based on an analysis of medical records, school health records and radiographs by one of the authors (BH).

Careful monitoring was regularly conducted utilizing the Swedish Population Register, where everyone who has been given a Swedish PIN is registered with information about their address. We could thus identify children who had moved to another area of Sweden since the primary surgery, emigrated or died. For those children who seemed to have dropped out from the follow-up regime, the relevant hospital in the new area where the child lived at the time of follow-up was contacted to obtain supplementary information concerning the radiographic follow-up and medical records.

In a small number of hospitals, children were only scheduled for follow-up for 12 months after POH of the index hip and thereafter instructed to make immediate contact if any symptoms should appear in the contralateral hip. However, for the majority of the hospitals, children were followed until physial closure could be verified on a radiograph.

Following this rigorous protocol, we identified one child who had emigrated (a boy who emigrated almost immediately after the primary surgery for the index hip) and one child who had died (22 months after the primary surgery). For this boy the index hip at 16 months after the primary surgery on a radiograph showed physial closure but there was no record of the contralateral hip being examined radiographically at that time.

Questionnaires

In Papers II and IV PROMs were used. Written approval was received from the EuroQol group (www.euroqol.org) to utilize the EQ-5D-Y and EQ-5D-VAS [259]. EQ-5D-Y is a general five-dimension instrument for the assessment of HRQoL. The EQ-5D-VAS [266], a visual analogue scale that is rated 0- 100 with 100 as the best health, was used as a quantitative measure of health outcome as judged by the individual respondents.

Written approval was obtained from the original developer of CHOHES [264], for both the cultural adaptation and validation process to be implemented in Paper II. We also received approval from the original developer to use the name Barnhöft as the Swedish name for the questionnaire. In Paper IV, the validated Swedish Barnhöft questionnaire for children aged 8 years or older was used. The Barnhöft questionnaire includes a pain domain (one item) together with a hip function domain (five items). Barnhöft was based on CHOHES, which was originally a 100-point item questionnaire, but without the physical examination domain originally included in CHOHES. The pain scale in Barnhöft includes a rating for each hip with a maximum of 40 points. The function domain is based on daily activities, including dressing, sitting, walking, and stair climbing, with a maximum of 32 points. For the study reported in Paper IV, the questionnaires were distributed to 107 consecutive children diagnosed with a unilateral POH by regular mail 24 months after the primary surgery. Two reminders were sent by regular mail to those who had not returned the questionnaires.

Subsequent procedures

In **Paper IV**, subsequent surgery during the follow-up time of 36 months was analysed. When calculating the number of subsequent procedures performed, the

development of AVN was considered to be the end point for that specific hip; hence, no subsequent operations for these hips were included in the results. Scheduled procedures for implant extraction after physical closure were included in the results.

Measurement of slip severity

Slip severity was graded using the categories described by Southwick [41], namely, a mild slip (< 30 degrees), a moderate slip (30-50 degrees), and a severe slip (> 50 degrees). In **Papers I, III and IV**, the CF method [44] or the Billing method [45] was used for assessment of lateral radiographs, with the Southwick HSA used for AP views [41] when it was not possible to obtain a lateral view (unstable POH). In Paper III, in addition to these methods for assessment of lateral radiographs, the Southwick lateral HSA [41] was also used for the inter- and intra-observer reliability testing. In Papers I and IV, we used the threshold of 13 degrees for an asymptomatic hip to be diagnosed with a POH [44, 233, 243]. In a small number of children with a unilateral unstable POH, it was only possible to achieve an AP view of the pelvis, because of the pain experienced by the child. In those children, we rated a Southwick HSA (in the AP view) of less than or equal to 110 degrees as a severe slip [41].

Clinical classification

The clinical classification of stability described by Loder et al. [68] was used in Papers I and IV. An unstable POH was defined as one causing severe pain that made walking impossible even with crutches, regardless of the duration of the symptoms. MRI or ultrasonography was not routinely used during the study period to verify an effusion of the hip.

Reduction of an unstable slip

In Papers I and IV the postoperative radiographs were analysed by subtracting the slip angle of the preoperative film from that in the immediate postoperative film to determine whether a reduction had been achieved. We used the same criteria as Kennedy et al. [267], in which a difference of > 10 degrees was considered a reduction, which was then classified further into an intentional or incidental reduction based on the surgical reports. There were five children with hips that were clinically classified as stable but where the assessment of pre- and postoperative radiographs showed that an obvious incidental reduction had been obtained. These hips were thus classified as unstable hips.

Accuracy of implant positioning

In Paper IV, the accuracy of implant positioning within the epiphysis was graded according to the method of Pring et al. [144] using AP and lateral radiographs. For a *correct implant position* (“A” accuracy), the implant had to be placed within the central 50% of the physial width, with the screw tip ≥ 5 mm across the physis, at least 5 mm from the subchondral bone, and the screw at an angle of 70- 90 degrees to the capital physis. *Poor implant position* (“C” accuracy) was identified when the implant was located outside the central 75% of the physial width, with the screw tip ≤ 2.5 mm across the physis, the tip of implant located ≤ 2.5 mm from the subchondral bone, or the implant was introduced at an angle of < 50 degrees to the physis. “B” accuracy of pinning occurred when the implant was placed outside the “A” area but not in the “C” area.

Body mass index (BMI)

In Papers I, II and IV age- and sex-adjusted BMI (ISO-BMI) was calculated using the method of Karlberg et al. [268]. An ISO-BMI of ≥ 25 was defined as overweight and an ISO-BMI of ≥ 30 as obese.

Statistics

All statistical analyses in this thesis were performed using SPSS Statistics for Windows (versions 22 or 24; IBM Corp, Armonk, NY).

Paper I

Continuous data were reported as the median with minimum and maximum values. Discrete data were reported as frequencies and/or percentages. For non-parametric tests between two independent groups, we used a Mann-Whitney U test. To compare proportions between two independent groups we used a cross-table and a chi-square test. The significance threshold was set at .05. A comparison of the Mann-Whitney U test and chi-square test was made using a Fisher’s exact test that produced identical results.

Paper II

The analysis in this paper used multidimensional scaling (MDS) [269] for analysis of categorical data, a weighted Cohen’s kappa [270, 271] with confidence interval

(CI) together with percentage agreement as described by Svensson for stability testing of the instrument [272], and Spearman's rank order correlation coefficient for construct validity testing [273].

The number of children per item was not sufficient to allow a factor analysis, a test to identify the dimensions of a test [274]. MDS for categorical data in an ordinal scale [269, 275] was instead used to scale health-state similarity data. This methodology is based on the ranking of differences between health states combined with an associated scaling model that transforms the individual rank data into group values on the interval level. We used MDS to visualize whether certain items were more closely related than others, that is, whether the different items under the domain function covered different aspects of functional capacity of the children in group two (children with POH).

Paper III

A t-distribution was assumed for a sample size of < 50 and a normal distribution for a sample size of ≥ 50 . The effect size was set to 3 degrees with 90% power and with a confidence level of 99%. The expected standard deviation was derived from a similar study [276].

Intra-observer variation for each of the measurements was assessed using the mean difference, with its 95% limits of agreement [277, 278]. For the purpose of graphic presentation, the differences were plotted against the mean measurements (Bland-Altman plots).

Inter-observer variation for two observers measuring Southwick lateral HSA [41] was assessed using the ICC and 95% CI with two-way random and absolute agreement for single measures. The first measurements were used for both observers [279]. For the four observers using the Billing [45] and CF methods [44], inter-observer reliability was evaluated using the ICC and 95% CI with two-way random and absolute agreement for average measures. The first measurements were used for all observers [279, 280].

When comparing the lateral HSA using the CF method, we included the first measurements for both methods. For statistical analysis, the variability was described using the Bland-Altman method, with its 95% limits of agreement [281].

Paper IV

Continuous data were checked for normality, using the Kolmogorov-Smirnov test together with an analysis of the histograms, and were reported as the median with minimum and maximum values. Discrete data were reported as frequencies and/or

percentages. An independent sample t test was used to compare mean values for continuous data between two groups that were normally distributed. To compare proportions between two independent groups, a cross-table and chi-square test were used. The significance threshold was set at .05.

Ethical considerations

Ethical approval for work described in the papers presented in this doctoral thesis was given by the Regional Ethical Review Board in Lund, Sweden (ref. 2013/87 and 2015/320). The studies described in all four papers were conducted in accordance with the ethical principles of the 1964 Declaration of Helsinki for medical research involving humans and its later amendments.

Informed consent was obtained from all individual participants and one parent or guardian of both healthy and sick children included in the work described in the four papers that constitute this thesis.

According to the UN Convention on the Rights of the Child [250], all children should be consulted on their own goals of treatment to maximize their participation in the encounter. It was important to consider the protection of the child's interests as well as risks or benefit calculations together with respect for the dignity and value of each child, and the views expressed by each child during both the planning and the implementation phases of the work described in this thesis

Overweight and obesity are known to be more common among children with POH [60]. However, we thought that the collection of data for BMI outside of the hospital medical records might be something that the child and/or the family would consider a delicate subject. For children for whom this information was not found in the medical records from the hospital, we sent one letter to the child and one letter to the parent or guardian with information about why this information was valuable for the interpretation of data. An inquiry was sent by regular mail asking for their written permission to request the school health personnel to provide us with this information. The enclosed informed consent document required the signature and approval of both the child and a parent or guardian. No reminder was sent to the families that did not respond to this inquiry and no contact was made through telephone or other media.

Children want to answer questions about their health status if they understand the reason behind the questions, if they feel that the questions are relevant, and when they notice that their answers are received and commented upon [282]. We chose instruments that would not include questions that could cause the children to be adversely affected. Because the children in these studies were from all over Sweden, for practical reasons we could not arrange for their answers to be commented upon

immediately after receipt. However, we encouraged all children to make further comments in their reply letter if there was anything they wanted to inform us about that was not properly covered by the questionnaires, or if there were questions that were difficult for them to understand. We received some comments that were very much appreciated and valuable for this thesis and all children received a personal letter of appreciation after the receipt of their answers.

For the participating children, there were no direct benefits included because the aim was to analyse routine care for children with POH in Sweden. However, through the consecutive registration of children treated for POH, we were able to identify children for whom the clinician responsible for the treatment had omitted to take a radiograph of the contralateral hip during the primary hospital admission. Following the receipt of our comments on this situation, the children concerned were thereafter followed according to the appropriate treatment guidelines in the relevant hospitals.

Following the consecutive registration of children for POH, we were able to identify one hospital where children with a mild POH were not treated according to a modern treatment regime, that is, they were only given instructions about analgesics and to use crutches while walking with partial weight-bearing, but no surgical treatment was offered despite a correct diagnosis of POH being confirmed. After an immediate contact with the director of the hospital concerned, the children were urgently referred to a paediatric orthopaedic unit for appropriate surgical treatment.

Results

Paper I

Slipped capital femoral epiphysis: a population-based study

In the prospective cohort study conducted during a 7-year period between 2007 and 2013, 379 children treated for POH in their index hip were identified. The cumulative incidence of POH in the index hip for children aged 9- 15 years in Sweden was 40.6 per 100,000 girls and 52.2 per 100,000 boys during the period studied. The median age was 11.7 (7.2- 15.4) years for the 162 girls and 13 (3.8- 17.7) years for the 217 boys. The age distribution is presented in Figure 20.

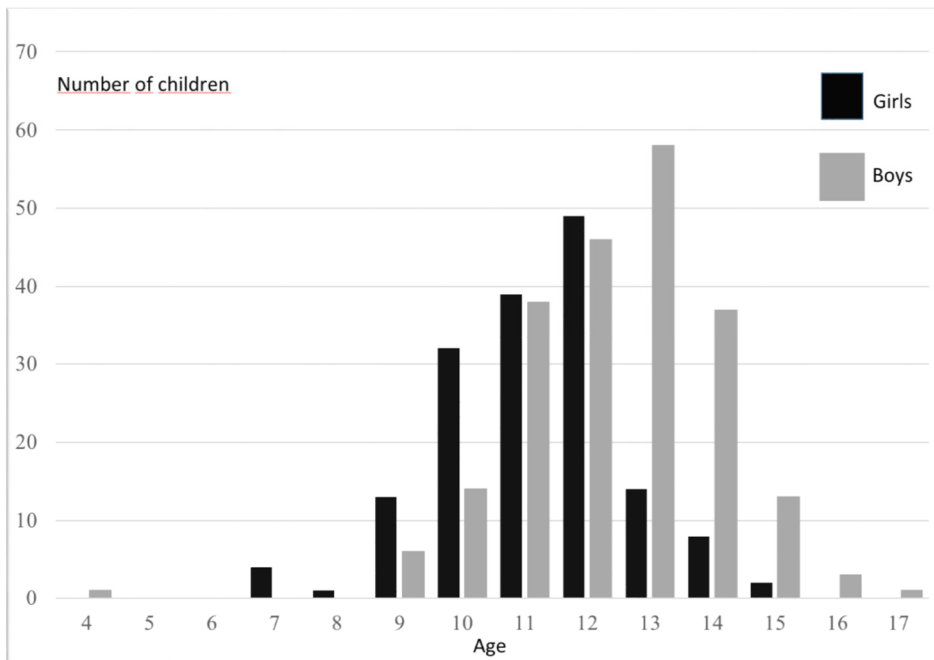


Figure 20. Age distribution.

Obesity or overweight was identified in 56% of the girls and in 76% of the boys.

The majority of patients had hip/groin pain as an initial symptom. For the 44 children (12%) with knee pain as the main symptom, the median duration from the onset of symptoms until diagnosis of POH was 4 (0.5 - 18) months whereas for the 250 children (66%) with hip/groin pain as the main symptom, the median duration was 2 (0.25 - 48) months.

There was a statistically significant difference ($p = 0.033$) between the proportion of children with knee pain that were sent for a radiographic hip examination by the initial care provider (12/44) compared with that of children with hip/groin pain as the main symptom (180/250).

The severity of the slip was associated with an increase in median duration of symptoms (Figure 21). There were 89/379 severe slips, 125/379 moderate slips and 165/379 mild slips.

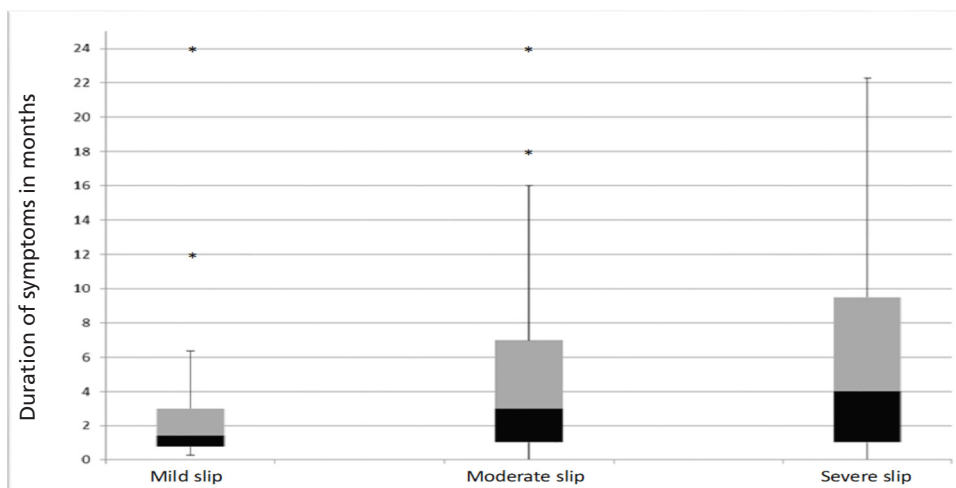


Figure 21. Severity of the slip in relation to duration of symptoms (missing data, n = 5).
Outliers with duration of symptoms > 24 months: mild (n = 1), moderate (n = 1), and severe (n = 2).

A left-sided predominance was observed in the index hip of the 379 children: 238 were left-sided and 141 were right-sided (unpublished data).

The majority of children underwent percutaneous internal fixation. Table 1 presents the different methods of treatment in relation to slip severity.

Between 2007 and 2013, the most common implants allowed for further growth of the femoral neck (Figure 22).

Most hospitals in Sweden treat fewer than two children annually for POH.

The most common diagnosis of co-morbidity in this population was neuropsychiatric disorders (15/379). Endocrine disorders were identified in very few children.

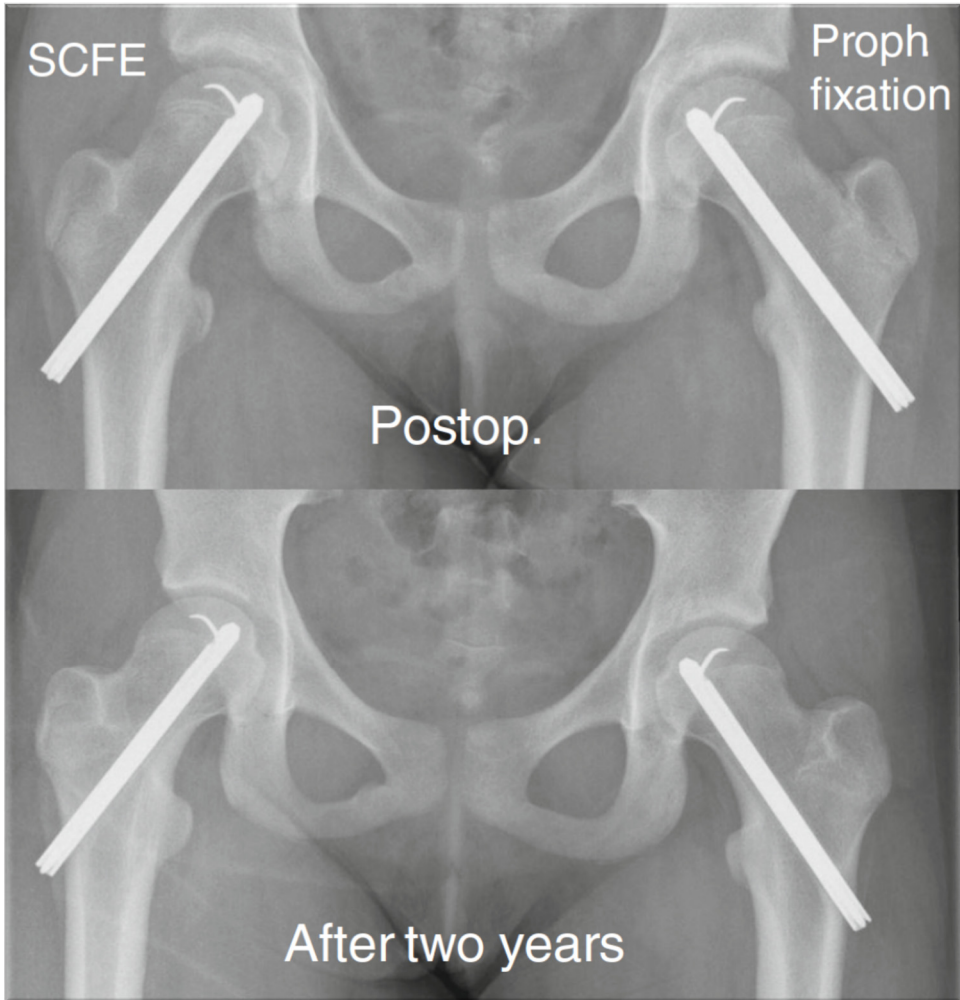


Figure 22. Implant for fixation that allows for further growth of the femoral neck (Hansson pin).

Table 1.
Method of treatment related to severity of POH

Surgical treatment	Mild	Moderate	Severe	Total
Hansson hook pin	96	71	38	205
Cannulated screw with extra ¹ short thread length	58	43	32	133
Cannulated screw with short ² thread length	10	10	4	24
Multiple cannulated screws (diameter <6 mm)	---	1	---	1
Multiple pins (diameter <3 mm)	1	---	2	3
Capital realignment procedure with surgical dislocation of the hip	---	---	8	8
Capital realignment procedure without surgical dislocation of the hip	---	---	3	3
Open reduction and fixation without surgical dislocation of the hip (Parsch)	---	---	2	2

¹ Specially designed screws with extra short thread length that will allow further growth of the femoral neck

² Ordinary short thread length i.e. approximately 16 mm

At initial presentation, 27 children had a bilateral POH. The contralateral hip was treated with prophylactic fixation in 151 children. The 151 children selected for this treatment regime were younger (median – range) than the 201 children scheduled for regular follow-up (median -range). This difference was statistically significant and of clinical relevance. Of the 201 children scheduled for regular follow-up, another 43 children developed bilateral POH. The time interval between the slip in the first and the second hip was median 8.5 (0.4- 59) months. There was only one child who was diagnosed with a sequential POH after more than 24 months.

Paper II

Barnhöft: a hip specific 6-item questionnaire for children

The test-retest method, with a weighted Cohen's kappa and the percentage agreement method, showed good stability for the instrument (Table 2).

Table 2.
Stability test of Barnhöft.

Item	Weighted Cohen's kappa (95% CI)	Percentage agreement
Pain (v48)	0.88 (0.74- 1.01)	99
Dressing (v49)	0.91 (0.73- 1.09)	99
Walking aid (v50)	1.00 (1.00- 1.00)	100
Walking capacity (v52)	0.88 (0.66- 1.10)	96
Sitting capacity (v53)	1.00 (1.00- 1.00)	100
Stair climbing (v54)	1.00 (1.00- 1.00)	100

The construct validity for the pain domain (1 item) in EQ-5D-Y compared with the pain domain in Barnhöft showed a Spearman's rank order correlation coefficient of 0.73. It was noted that severe pain affected the score for the function domain in Barnhöft and we therefore compared the degree of hip pain in Barnhöft with the item "doing usual activities" in EQ-5D-Y and found a Spearman's rank order correlation coefficient of 0.67.

Using the MDS for categorical data on an ordinal scale, we could visualize that the different items under the function domain covered different aspects of functional capacity for the children with POH (Figure 23).

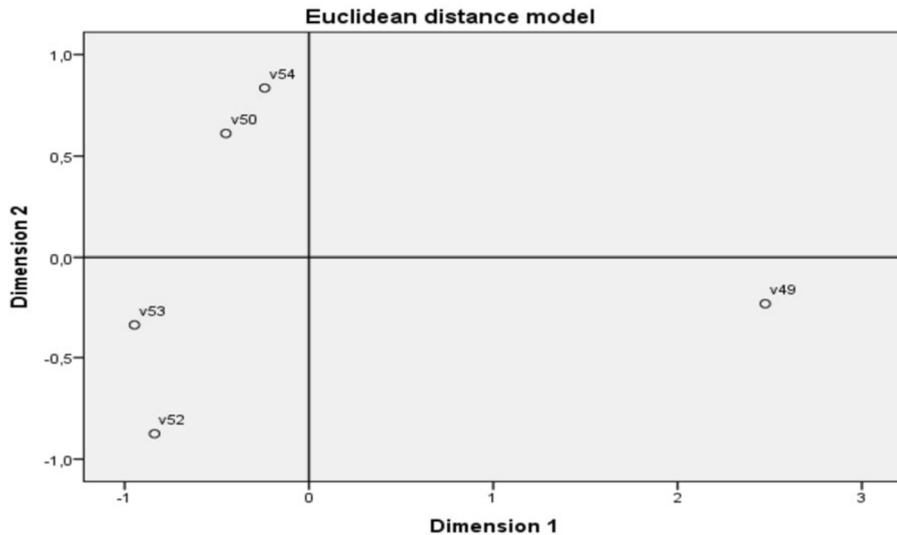


Figure 23. Multidimensional scaling (MDS) for the function domain items in Barnhöft in children with POH. V49, ability to put on socks or shoes; V50, walking aid used; V52, walking capacity; V53, sitting capacity; V54, stair climbing capacity.

Using the EQ-5D-VAS, children with POH scored a mean of 88 which was equal to that of a Swedish general population [260].

Paper III

Good inter- and intra-observer reliability for assessment of the slip angle in 77 radiographs of children with a slipped capital femoral epiphysis

The inter-observer reliability analysis for four observers showed an ICC of 0.99 (95% CI 0.97-0.99) for the CF measurement method and an ICC of 0.99 (95% CI 0.98-0.99) for the Billing measurement method.

The inter-observer reliability analysis for two observers showed an ICC of 0.98 (95% CI 0.97-0.99) for the Southwick lateral HSA measurement method.

Bland-Altman plots for lateral HSA and CF illustrate the reproducibility between the first and second measurements (Figures 24 and 25).

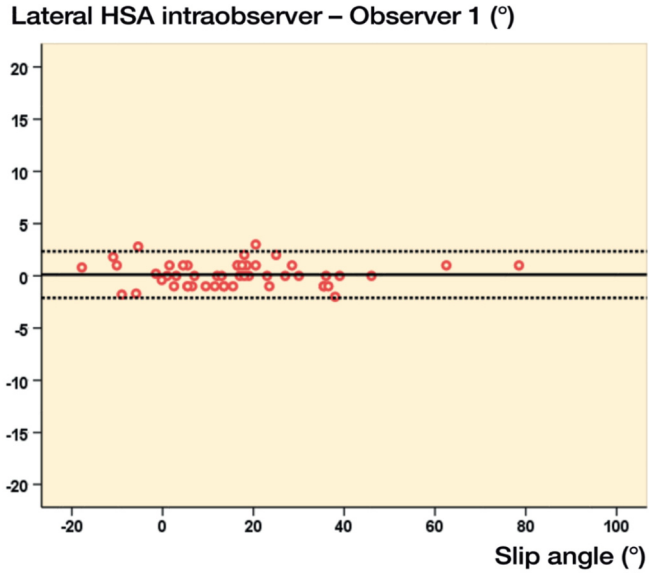


Figure 24. Intra-observer variation (degrees) for lateral HSA: Observer 1.
 The solid line represents the mean value and the dotted lines show the limits for two standard deviations above and below the mean value.

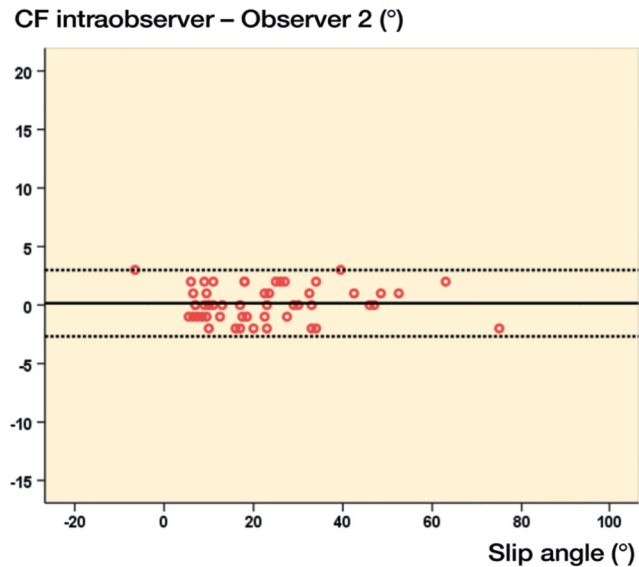


Figure 25. Intra-observer variation (degrees) for CF: Observer 2.
 The solid line represents the mean value and the dotted lines show the limits for two standard deviations above and below the mean value.

The intra-observer reliability analysis for two observers showed a mean difference between the first and second measurement of less than one degree for all three methods (Table 3).

Table 3.

Intra-observer variation between first and second measurements of slip angle (degrees).

Intraobserver	Subjects	Difference mean (SD)	95% limits of agreement
Observer 1 - Billing	27	-0.8 (2.9)	-6.5 to 5.0
Observer 2 - Billing	27	-0.2 (1.9)	-4.0 to 3.5
Observer 1 - CF	50	0.0 (2.6)	-5.1 to 5.1
Observer 2 - CF	50	0.2 (1.4)	-2.3 to 3.0
Observer 1 - HSA	50	0.1 (1.1)	-2.1 to 2.3
Observer 2 - HSA	50	0.4 (3.3)	-6.0 to 6.8

The mean difference between the first measurements of lateral HSA and CF was less than 6 degrees for the two observers (Table 4).

Table 4.

Difference (degrees) between lateral HSA and CF measurements.

HSA - CF	Subjects	Difference mean (SD)	95% limits of agreement
Observer 1	50	5.9 (4.8)	-3.5 to 15.3
Observer 2	50	3.4 (4.8)	-6.1 to 12.9

Paper IV

Outcomes after slipped capital femoral epiphysis – a population-based study with 3-years follow-up

In this study cohort of 379 children with 449 hips affected by POH, 61 hips were classified as unstable (60 in the index hip) and 90 were graded as severe (89 in the index hip).

The 151 children with a unilateral POH who received prophylactic fixation were younger than the 201 children with a unilateral POH selected for scheduled radiographic and clinical follow-up ($p = 0.001$). This difference was considered of clinical relevance. However, the groups did not differ significantly in the severity of the slip, clinical classification (stable/unstable) or age-adjusted BMI. None of the 151 hips treated with a prophylactic fixation developed AVN.

A total of 25 of 449 hips developed AVN within 36 months after the primary surgery for POH (Table 5).

Table 5.

Development of AVN in 449 hips treated for POH.

Surgical procedure	Hips (N)	AVN (N)
Percutaneous internal fixation for stable SCFE	380	5 ¹
Percutaneous internal fixation for unstable SCFE	56	11 ²
Capital realignment as primary surgery for stable SCFE	8 ³	2
Capital realignment as primary surgery for unstable SCFE	3 ³	2
Open reduction and internal fixation for unstable SCFE (Parsch) ⁴	2 ³	1
Capital realignment as reconstructive surgery before physeal closure	4 ⁵	2
Surgery for a peri-implant femur fracture	3 ⁵	2
Total		25

¹ Two of five hips had a severe SCFE.² Eight of 11 hips had a severe SCFE. Six of 11 hips had an intentional reduction manoeuvre and four had an incidental reduction.³ All of these hips had a severe SCFE⁴ Parsch et al. 2009 [220]⁵ Subsequent surgical procedures

Of the 56 unstable hips treated with percutaneous internal fixation, an intentional reduction manoeuvre (traction, internal rotation and mild flexion) was performed in 32 hips and an incidental reduction from simple positioning on the operating table was described and/or was visualized on postoperative radiographs in 14 hips. Six of the 11 unstable hips that developed AVN had an intentional reduction manoeuvre performed and four had an incidental reduction. An arthrocentesis was performed in seven of the 56 unstable hips. No AVN was identified in these seven hips. However, there were no statistically significant differences between the groups with regard to the development of AVN, either when an intentional reduction had been performed or when the joint was decompressed.

A peri-implant femur fracture occurred in five hips (two hips with prophylactic fixation performed). For three of the five hips, technical difficulties were described in the surgical reports. One hip (treated for POH) developed AVN secondary to this event.

Implant position was graded as poor (“C” accuracy) in 38 (10%) of the 380 stable hips treated with in situ fixation for POH.

Of the 436 slipped hips treated with percutaneous fixation, the implant was extracted after physal closure as a routine procedure in 156 hips. For 22 of the 156 hips, the percutaneous procedure had to be converted to a more extensive approach. Of the 151 hips treated with prophylactic fixation, the implant was similarly extracted as a routine procedure in 51 hips (five of these 151 procedures had to be converted to a more extensive approach).

Slip progression despite internal fixation occurred in eight hips (five with an initial poor implant position, “C” accuracy). Development of POH despite prophylactic fixation occurred in one hip (correct initial implant position, “A” accuracy).

Children with a stable severe POH or who developed AVN scored lower in Barnhöft and EQ-5D-VAS compared with children with a stable mild or moderate POH.

Discussion

This thesis is based on a prospective cohort study with a total national population in Sweden of 379 children (162 girls and 217 boys) who had a POH in their index hip between 2007 and 2013. A population of children aged 9- 15 years in Sweden in the beginning of the study period was used as the population at risk when calculating the cumulative incidence of POH during the study period. The inclusion period for new cases of POH in the index hip was seven years because the majority of children will be treated for POH in the index hip at 9- 15 years of age (i.e., seven age groups). We excluded five girls < 9 years old and one boy aged 3.8 years together with four boys aged 16 years or older when calculating the cumulative incidence.

A cumulative incidence of 40.6 per 100,000 girls and 52.2 per 100,000 boys was found during the period studied. The median age at diagnosis was 11.7 (7.2- 15.4) years for the 162 girls and 13 (3.8- 17.7) years for the 217 boys.

The male-to-female ratio was 1.3:1. This could be compared with a recent study on a national population from the Netherlands by Witbreuk et al. in 2013, which showed no sex difference [49]. This reduced predominance of POH in boys in reports from two northern European countries needs to be considered when children present with a limp together with hip, thigh or knee pain.

Around 50% of adults in Sweden are overweight or obese according to the Public Health Agency of Sweden (www.folkhalsomyndigheten.se). Obesity is one of the five main factors in Sweden causing loss of healthy years of life. In Swedish children who were 12 years old in 2011, 12.8% of the girls and 16% of the boys were found to be overweight or obese [283, 284]. In Paper I, we reported that 56% of the girls and 76% of the boys with POH in their index hip between 2007 and 2013 were overweight or obese. Higher BMI was found by Escott et al. in 2015 to be the only clinical predictor of patient-reported poor outcomes in their 20-year follow-up study of patients with POH during childhood [258].

Paper I show that the severity of the slip increases with a longer duration of symptoms, that is, a longer period with the disorder before a diagnosis is established and appropriate treatment offered to the child. This is consistent with other reports [12, 30, 31, 33, 285].

It is important to reduce delays in diagnosis of POH that depend on the competence of the health personnel who assess the child at their initial presentation. The

knowledge that groin pulls are rare in adolescents [81] and that the more common POH must be ruled out first by requisite radiological investigations must be further disseminated. Children with normal BMI but with knee pain because of POH are at higher risk of delayed diagnosis. All children who describe knee or hip/groin pain and/or have a limp must have a thorough examination of the whole extremity, including at least one joint above the specified location of pain. This means, for example, that if the child complains of hip/groin pain, then the pelvis and lumbar spine must also be examined and if there is a complaint of knee pain, then the hip must be thoroughly examined.

A co-morbid neurocognitive disorder (attention deficit disorder, attention deficit hyperactivity disorder, autism) was noted in 15 of the 379 children (4%) included in Paper I. This frequency is similar to that recently reported for the general population by the Swedish National Board of Health and Welfare where 6.4% of the boys and 2.7% of the girls aged 10-17 years between 2006 and 2015 were under regular medication for attention deficit and hyperactivity disorders [286].

With the assistance of the validated Swedish instrument Barnhöft (Papers II and IV), children with POH who had either severe pain or a considerable limitation of their hip function were identified. The instrument can be used as a PROM from 8 years old. It is preferably collected and commented upon during a regular follow-up visit for POH, but it can also be used for distribution by regular mail. We used the instrument for children with a unilateral POH. However, in a long-term follow-up study using PROMs, subjects with a bilateral slip had outcomes similar to those with unilateral disease [258].

The measurement methods used to assess radiographs in Papers I and IV were shown in Paper III to have good inter- and intra-observer reliability. Following this work, these methods are now routinely used in the SPOQ register (www.SPOQ.se) and a new manual explaining how a correct Lauenstein view (frog-leg lateral view) should be achieved for radiology has been developed.

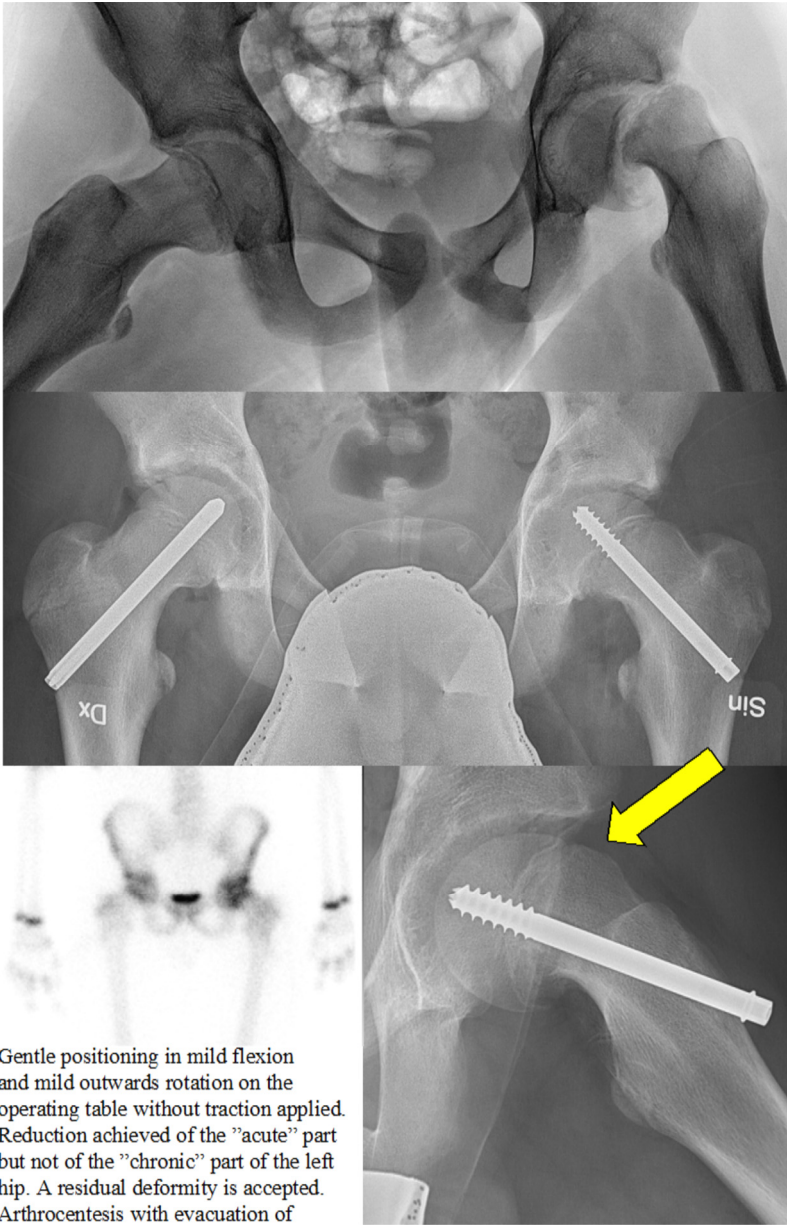
In Papers I and IV, bilateral disease at initial presentation was diagnosed in 27 of the 379 children (7%). This incidence is consistent with other reports [19, 37, 117, 118].

Papers I and IV describe that 43 of 201 children who were scheduled for a regular follow-up developed POH [137, 216]. In the group of 151 children who received prophylactic fixation of the contralateral hip, one hip developed a slip despite internal fixation with a correct initial implant position (“A” accuracy) [144]. The median time interval between the slip in the first and the second hip was 8.5 months. Only one child was diagnosed with a sequential POH after more than 24 months. A later development of POH in the contralateral hip was shown as less likely to be a

severe or unstable slip. This has also been described in other reports [37, 50, 232, 238, 249].

In Paper IV, the outcomes of the capital realignment procedures performed in Sweden in children with POH in their index hip between 2007 and 2013 are described. Few procedures were performed (n = 15), mainly in two tertiary centres for paediatric orthopaedics. However, the number of cases of AVN was similar to those recently reported from US tertiary centres, where a higher rate of complications than reported for earlier more encouraging studies was described for both stable and unstable POH [35, 193-198].

Is there a role for gentle reduction of an unstable POH? The challenge involves determining the part played by the acute and chronic components. The treating surgeons need to have appropriate knowledge about the historical classification, using the terms “acute”, “acute-on-chronic” and “chronic” [43, 69]. They should preferably make a very gentle manipulative reduction and reduce the epiphysis only to the point where it had been located just before the acute event but not attempt a more forceful reduction of the chronic part of the slip. A variable degree of metaphyseal remodelling is seen on the radiograph along the superior and anterior femoral neck for the “chronic” part of a slip [69], which must be identified with the assistance of fluoroscopy in the operating room. The surgeons must carefully monitor this during a gentle reduction attempt, open or closed, by using fluoroscopy with both AP and lateral views available [3, 168, 220, 287, 288]. Decompression of the joint would preferably also follow this procedure. In Figure 26, a case report is shown as an example of how such a procedure could be performed.



Gentle positioning in mild flexion and mild outwards rotation on the operating table without traction applied. Reduction achieved of the "acute" part but not of the "chronic" part of the left hip. A residual deformity is accepted. Arthrocentesis with evacuation of a hematoma. Fixation due to age 13 years old (boy) with an intentional physeodesis. Prophylactic fixation of the right hip. A bone scan showed normal nuclide uptake as a sign of maintained circulation to the left hip after 7 days. A "rounding off" occurred within six months post surgery (yellow arrow).

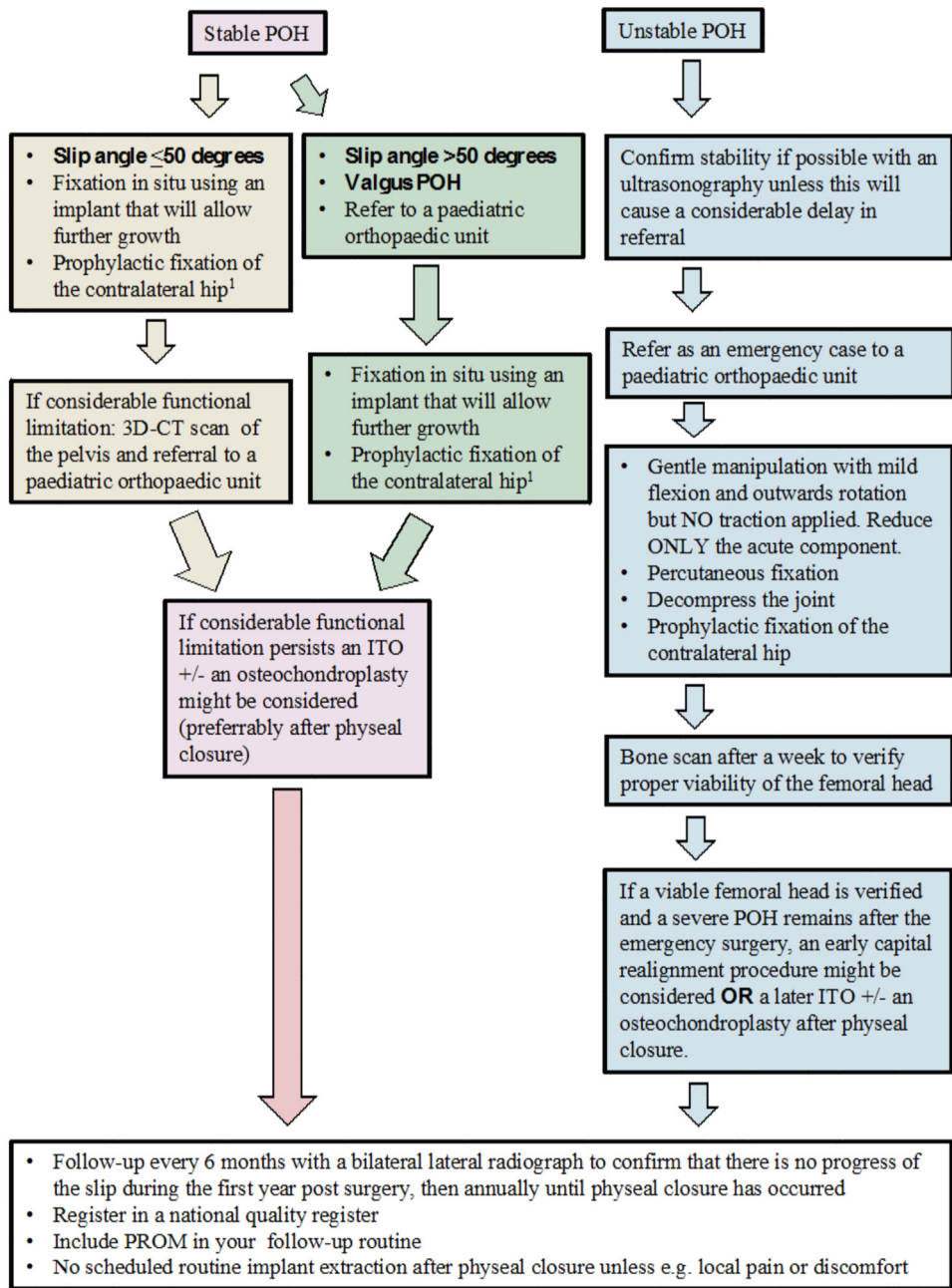
Figure 26. Unstable POH left hip treated with gentle reduction of the acute component and arthrocentesis.

The best treatment for the contralateral hip in children with a unilateral POH is still controversial. In Paper IV, the pros and cons of prophylactic fixation are presented. If treatment with prophylactic fixation is not routinely offered to a child with a unilateral POH, then skeletal immaturity, sex, and the family's compliance regarding attendance for regular follow-up visits should be considered when a decision is made about the management of the contralateral hip. There were obvious peri-operative technical difficulties for one of the two children reported in paper IV who sustained a peri-implant femur fracture after prophylactic fixation. One deep infection occurred after surgical treatment for a peri-implant femur fracture in the group of 151 children with a prophylactically treated contralateral hip. It may be possible to minimize the incidence of these two complications with correct surgical technique during primary surgery. Prophylactic fixation is a safe procedure when performed with a correct technique.

The value of routine extraction of an implant after physial closure, in the absence of any local pain or discomfort reported by the child, could be questioned [289-292]. In Paper IV, it is shown that this procedure is reasonably widespread in Sweden and contributes to a considerable number of scheduled surgeries performed after POH.

In 2007, there were 39 hospitals where children were primarily treated for POH. By the end of 2013, this number was reduced to 34. Based upon the 379 children with 449 hips studied in Paper I and IV and the 34 hospitals that had actually treated children with POH during the 7-year study period, we determined that the majority of Swedish hospitals treat fewer than two children annually for POH. In January 2018 the number of hospitals in Sweden that treat children with POH was further reduced to 28 in a country with approximately 700,000 children aged 9- 15 years and 50-55 children with a new diagnosis of POH in the index hip every year. This situation needs thorough consideration concerning where children should be treated for POH. The knowledge that POH is not an adolescent or paediatric hip fracture but a paediatric orthopaedic disorder, together with the competence to treat both stable and unstable POH accordingly, must be a prerequisite for the units taking care of these children. A child with a typical mild-to-moderate stable POH (i.e., the metaphysis together with the femoral shaft goes in external rotation, into varus and in extension) could probably receive their initial treatment in more hospitals than a child with an unstable POH, a valgus POH, or a severe POH [39, 195].

Based upon the literature review in this thesis and the results presented in Papers I-IV, I would like to propose a treatment protocol for POH in Sweden (Figure 27).



¹ Unless physael closure is verified.

Figure 27. A proposal for a treatment algorithm for POH.

Limitations

Paper I

In the analysis of the duration of symptoms, we were not able to separate the patient-related delay from the doctor-related delay. We also used the history that was presented on hospital admission.

For the analysis of the initial health care provider and the rate of referral for a diagnostic hip examination, we were not able to collect all medical records from outpatient visits at various health care providers prior to the primary surgery for POH. We used the history that was presented on hospital admission.

A small number of hospitals routinely followed children treated for POH with regular radiographs for only 12 months postoperatively. However, during our annual follow-up we counterchecked whether the child still lived in the catchment area of that hospital where he/she was treated primarily or had the last registered follow-up. A few children had moved to another region of Sweden. We then contacted the relevant hospital with a catchment area that covered the new place of residence for that particular child, and managed to obtain medical records from outpatient visits and surgical reports, and we were also able to analyse the most recent available hip radiographs.

Paper II

Based on epidemiological data in Paper I, we assumed that children treated for POH were comparable with “hip-healthy” children in their comprehension of Barnhöft.

As a control group (“healthy children”) in this study we used children participating in weekly organized sport-activities in Jönköping with the intention of using children that were not physically restricted due to hip problems (i.e. we did not use a sex- and age matched control group as a reference).

Despite written instructions to both the child and the caretaker, we could not control for any possible caretaker bias.

What matters to children differs across gender, age, as well as cultural background [282]. There might be other questions than those included in Barnhöft that would appear more relevant and important for children with a hip disorder.

In this study, we did not analyse interpretability, that is, the degree to which one can assign clinical or commonly understood connotations to an instrument's quantitative scores or change in scores.

We did not analyse whether the literacy of children with a hip disorder was adequate for their age.

We assumed that the children treated for a POH who undertook the test for a second time (re-test) after six weeks had an unchanged health status compared with when they were first exposed to the instrument. However, only children with a unilateral POH (i.e., still without a diagnosis of POH in the contralateral hip after 24 months) were included.

For the reliability test, that is, the test of the stability of the instrument, the sample size of healthy children ($n = 12$) was small, which might affect the results.

For the further testing of Barnhöft, we did not recruit a completely new group of healthy children, that is, 10/35 healthy children also participated in the cognitive interview part of this study.

Paper III

The severity of the slips in our study was slightly less than that previously reported in similar studies. This may have influenced our results for both the intra- and interobserver variability.

We could not blind the radiographs to PINs because of the need for secure storage of patient information. To compensate, the radiographs were all given a unique number in a list that did not follow any alphabetical order or pattern according to age, date, or sex. We also used an interval of six weeks between the radiographic assessments.

Paper IV

Because of the limited follow-up of 36 months for each child, late complications or surgeries were not included.

The 379 children were treated with routine care in 34 hospitals and it was not possible to confirm clinically unstable hips with ultrasonography or MRI.

The surgical reports might not have covered all technical difficulties, such as the use of multiple entry points for the guide wire before the implant insertion was accomplished.

PROMs were not used over the entire study period. The questionnaires used were developed in Swedish for children aged 8 years and older after the inclusion period started.

Only children with a unilateral POH were included. We used questionnaires distributed by regular mail together with an information letter, one to the child and one to the family. However, we advocate that questionnaires preferably be used during a scheduled follow-up so that the child can receive an immediate response to any pending questions and also achieve a better understanding of how the instrument is actually used as an important part of the information collected that will constitute the foundation of the further management of that child.

Conclusions

- The cumulative incidence of POH in the index hip for children aged 9- 15 years in Sweden was 40.6 per 100,000 girls and 52.2 per 100,000 boys in the period studied.
- The male-to-female ratio of 1.3:1 for POH of the index hip was lower than previous regional data from Sweden.
- Overweight or obesity was found in 76% of the boys and in 56% of the girls with POH in the index hip.
- The use of fixation in situ to remain as the primary treatment of choice in a stable POH is justified.
- In an unstable POH, a very gentle reduction (without traction or forceful inwards rotation) while positioning the child on the operating table might be justified.
- Barnhöft could be used in children aged 8 years and older as a simple 6-item questionnaire to identify children with considerable pain and/or functional limitations because of sequelae related to hip disease during childhood.
- We found good reliability for both intra- and inter-observer measurements for all three methods used for the assessment of the slip angle on routine lateral hip radiographs.
- Prophylactic fixation is a safe procedure when performed using a correct technique.
- The number of patients who developed AVN after capital realignment is of concern.
- Joint decompression might be valuable when treating an unstable POH.

Further research

Within the framework of the SPOQ register, we will investigate further the following aspects of treatment for POH.

- The delay caused by health professionals before a diagnosis of POH is established.
- Outcomes after POH at age 18 years including PROMs.
- The possibilities for register randomized controlled trials, to evaluate further the treatment of unstable POH and reconstructive surgery for sequelae to POH.
- Analysis of the outcomes after a prophylactic fixation at age 18 years.

Errata

In Paper I, we described the incidence of POH in the index hip. The expression “annual average incidence” should be replaced with “incidence rate”.

In Paper I, we reported that most children were initially examined by their general practitioner. This is correct, but the numbers within parentheses should be 205/379.

In Paper I, we reported that: “The girls who received prophylactic surgery were younger than girls who were scheduled for regular radiographic follow-up. We found no such difference for the boys.” The last sentence should instead read: “We found a similar difference for the boys”.

In Paper II, the abbreviation for multidimensional scaling should be MDS and not MSD.

References

1. Howorth, B., *Slipping of the upper femoral epiphysis*. Clin Orthop Relat Res, 1957. **10**: p. 148-73.
2. Cowell, H.R., *The significance of early diagnosis and treatment of slipping of the capital femoral epiphysis*. Clin Orthop Relat Res, 1966. **48**: p. 89-94.
3. Peterson, M.D., et al., *Acute slipped capital femoral epiphysis: the value and safety of urgent manipulative reduction*. J Pediatr Orthop, 1997. **17**(5): p. 648-54.
4. Cherkasskiy, L., et al., *Patient-specific 3D models aid planning for triplane proximal femoral osteotomy in slipped capital femoral epiphysis*. J Child Orthop, 2017. **11**(2): p. 147-153.
5. Loder, R.T., et al., *Slipped capital femoral epiphysis*. Instr Course Lect, 2001. **50**: p. 555-70.
6. Lykissas, M.G. and J.J. McCarthy, *Should all unstable slipped capital femoral epiphysis be treated open?* J Pediatr Orthop, 2013. **33 Suppl 1**: p. S92-8.
7. Hägglund, G., *Physiolysis of the hip : epidemiology, etiology and therapy*. Thesis.1986, Lund.
8. Ordeberg, G., *Physiolysis of the hip : epidemiology, natural history and long term results after closed treatment*. Thesis.1986, Lund.
9. Jerre, R., *Physiolysis of the hip : epidemiology, diagnosis and long-term follow-up*. Thesis. 1995, Gothenburg.
10. Kumar, K., *Should slipped capital femoral epiphysis (SCFE), a misnomer, be renamed as idiopathic capital femoral physiolysis (ICFP)*. J Bone Joint Surg Br, 2002. **84**(6): p. 932.
11. Ordeberg, G., L.I. Hansson, and S. Sandstrom, *Slipped capital femoral epiphysis in southern Sweden. Long-term result with no treatment or symptomatic primary treatment*. Clin Orthop Relat Res, 1984(191): p. 95-104.
12. Carney, B.T. and S.L. Weinstein, *Natural history of untreated chronic slipped capital femoral epiphysis*. Clin Orthop Relat Res, 1996(322): p. 43-7.
13. Naseem, H., et al., *Treatment of stable slipped capital femoral epiphysis: systematic review and exploratory patient level analysis*. J Orthop Trauma, 2017. **18**(4): p. 379-394.
14. Millis, M.B., *SCFE: clinical aspects, diagnosis, and classification*. J Child Orthop, 2017. **11**(2): p. 93-98.
15. Galbraith, R.T., et al., *Obesity and decreased femoral anteversion in adolescence*. J Orthop Res, 1987. **5**(4): p. 523-8.

16. Murray, A.W. and N.I. Wilson, *Changing incidence of slipped capital femoral epiphysis: a relationship with obesity?* J Bone Joint Surg Br, 2008. **90**(1): p. 92-4.
17. Gelberman, R.H., et al., *The association of femoral retroversion with slipped capital femoral epiphysis.* J Bone Joint Surg Am, 1986. **68**(7): p. 1000-7.
18. Pritchett, J.W. and K.D. Perdue, *Mechanical factors in slipped capital femoral epiphysis.* J Pediatr Orthop, 1988. **8**(4): p. 385-8.
19. Nguyen, A.R., et al., *Slipped capital femoral epiphysis: rising rates with obesity and aboriginality in South Australia.* J Bone Joint Surg Br, 2011. **93**(10): p. 1416-23.
20. Monazzam, S., J.R. Dwek, and H.S. Hosalkar, *Multiplanar CT assessment of femoral head displacement in slipped capital femoral epiphysis.* Pediatr Radiol, 2013. **43**(12): p. 1599-605.
21. Bauer, J.P., D.R. Roy, and S.S. Thomas, *Acetabular retroversion in post slipped capital femoral epiphysis deformity.* J Child Orthop, 2013. **7**(2): p. 91-4.
22. Kordelle, J., et al., *Development of the acetabulum in patients with slipped capital femoral epiphysis: a three-dimensional analysis based on computed tomography.* J Pediatr Orthop, 2001. **21**(2): p. 174-8.
23. Hesper, T., et al., *Imaging modalities in patients with slipped capital femoral epiphysis.* J Child Orthop, 2017. **11**(2): p. 99-106.
24. Loder, R.T., B. Wittenberg, and G. DeSilva, *Slipped capital femoral epiphysis associated with endocrine disorders.* J Pediatr Orthop, 1995. **15**(3): p. 349-56.
25. Wells, D., et al., *Review of slipped capital femoral epiphysis associated with endocrine disease.* J Pediatr Orthop, 1993. **13**(5): p. 610-4.
26. Wilcox, P.G., D.S. Weiner, and B. Leighley, *Maturation factors in slipped capital femoral epiphysis.* J Pediatr Orthop, 1988. **8**(2): p. 196-200.
27. Loder, R.T. and R.N. Hensinger, *Slipped capital femoral epiphysis associated with renal failure osteodystrophy.* J Pediatr Orthop, 1997. **17**(2): p. 205-11.
28. Loder, R.T., et al., *Slipped capital femoral epiphysis associated with radiation therapy.* J Pediatr Orthop, 1998. **18**(5): p. 630-6.
29. Libshitz, H.I. and B.S. Edeiken, *Radiotherapy changes of the pediatric hip.* Am J Roentgenol, 1981. **137**(3): p. 585-8.
30. Carney, B.T., S.L. Weinstein, and J. Noble, *Long-term follow-up of slipped capital femoral epiphysis.* J Bone Joint Surg Am, 1991. **73**(5): p. 667-74.
31. Jerre, R., et al., *Does a single device prevent further slipping of the epiphysis in children with slipped capital femoral epiphysis?* Arch Orthop Trauma Surg, 1997. **116**(6-7): p. 348-51.
32. Loder, R.T., T. Starnes, and G. Dikos, *Atypical and typical (idiopathic) slipped capital femoral epiphysis. Reconfirmation of the age-weight test and description of the height and age-height tests.* J Bone Joint Surg Am, 2006. **88**(7): p. 1574-81.
33. Kocher, M.S., et al., *Delay in diagnosis of slipped capital femoral epiphysis.* Pediatrics, 2004. **113**(4): p. e322-5.
34. Fedorak, G.T., et al., *Increased time between diagnosis and surgery in slipped capital femoral epiphysis results in increased radiographic deformity.* J Child Orthop, 2018. **12**(3): p. 232-235.

35. Souder, C.D., J.D. Bomar, and D.R. Wenger, *The role of capital realignment versus in situ stabilization for the treatment of slipped capital femoral epiphysis*. J Pediatr Orthop, 2014. **34**(8): p. 791-8.
36. Loder, R.T., *Slipped capital femoral epiphysis: a spectrum of surgical care and changes over time*. J Child Orthop, 2017. **11**(2): p. 154-159.
37. Larson, A.N., et al., *Incidence of slipped capital femoral epiphysis: a population-based study*. J Pediatr Orthop B, 2010. **19**(1): p. 9-12.
38. Terjesen, T. and A. Wensaas, *Prognostic factors for long-term outcome of chronic slipped capital femoral epiphysis treated with fixation in situ*. J Child Orthopaedics, 2017. **11**(2): p. 114-119.
39. de Poorter, J.J., et al., *Long-term outcomes of slipped capital femoral epiphysis treated with in situ pinning*. J Child Orthop, 2016.
40. Ortegren, J., et al., *Persisting CAM deformity is associated with early cartilage degeneration after Slipped Capital Femoral Epiphysis: 11-year follow-up including dGEMRIC*. Osteoarthritis Cartilage, 2018. **26**(4): p. 557-63.
41. Southwick, W.O., *Osteotomy through the lesser trochanter for slipped capital femoral epiphysis*. J Bone Joint Surg Am, 1967. **49**(5): p. 807-35.
42. Barrios, C., et al., *Posterior sloping angle of the capital femoral physis: a predictor of bilaterality in slipped capital femoral epiphysis*. J Pediatr Orthop, 2005. **25**(4): p. 445-9.
43. Boyer, D.W., M.R. Mickelson, and I.V. Ponseti, *Slipped capital femoral epiphysis. Long-term follow-up study of one hundred and twenty-one patients*. J Bone Joint Surg Am, 1981. **63**(1): p. 85-95.
44. Hansson, L.I., et al., *The calcar femorale as a landmark in hip physiolysis*. Acta Orthop Scand, 1988. **59**(2): p. 134-8.
45. Billing, L., H.G. Bogren, and J. Wallin, *Reliable X-ray diagnosis of slipped capital femoral epiphysis by combining the conventional and a new simplified geometrical method*. Pediatr Radiol, 2002. **32**(6): p. 423-30.
46. Hartly, M., *The calcar femorale and the femoral neck*. J Bone Joint Surg Am, 1957. **39-A**(3): p. 625-30.
47. Griffin, J.B., *The calcar femorale redefined*. Clin Orthop Relat Res, 1982(164): p. 211-4.
48. Lehmann, C.L., et al., *The epidemiology of slipped capital femoral epiphysis: an update*. J Pediatr Orthop, 2006. **26**(3): p. 286-90.
49. Witbreuk, M.M., et al., *Incidence and gender differences of slipped capital femoral epiphysis in the Netherlands from 1998-2010 combined with a review of the literature on the epidemiology of SCFE*. J Child Orthop, 2013. **7**(2): p. 99-105.
50. Loder, R.T., D.D. Aronson, and M.L. Greenfield, *The epidemiology of bilateral slipped capital femoral epiphysis. A study of children in Michigan*. J Bone Joint Surg Am, 1993. **75**(8): p. 1141-7.
51. Song, K.S., et al., *Epidemiology and demographics of slipped capital femoral epiphysis in Korea: a multicenter study by the Korean Pediatric Orthopedic Society*. J Pediatr Orthop, 2009. **29**(7): p. 683-6.

52. Lim, Y.J., et al., *Demographics and clinical presentation of slipped capital femoral epiphysis in Singapore: comparing the East with the West*. J Pediatr Orthop B, 2008. **17**(6): p. 289-92.
53. Perry, D.C., et al., *A nationwide cohort study of slipped capital femoral epiphysis*. Arch Dis Child, 2017. **102**(12): p. 1132-36.
54. Benson, E.C., et al., *A new look at the incidence of slipped capital femoral epiphysis in new Mexico*. J Pediatr Orthop, 2008. **28**(5): p. 529-33.
55. Hagglund, G., L.I. Hansson, and G. Ordeberg, *Epidemiology of slipped capital femoral epiphysis in southern Sweden*. Clin Orthop Relat Res, 1984(191): p. 82-94.
56. Loder, R.T., *A worldwide study on the seasonal variation of slipped capital femoral epiphysis*. Clin Orthop Relat Res, 1996(322): p. 28-36.
57. Leopold, S., et al., *Editorial: The complexity of Reporting Race and Ethnicity in Orthopaedic Research*. Clin Orthop Relat Res, 2018. **0**: p. 1-4.
58. Jerre, R., J. Karlsson, and B. Henrikson, *The incidence of physioliysis of the hip: a population-based study of 175 patients*. Acta Orthop Scand, 1996. **67**(1): p. 53-6.
59. Kelsey, J.L., K.J. Keggi, and W.O. Southwick, *The incidence and distrubition of slipped capital femoral epiphysis in Connecticut and Southwestern United States*. J Bone Joint Surg Am, 1970. **52**(6): p. 1203-16.
60. Loder, R.T., *Slipped capital femoral epiphysis*. Am Fam Physician, 1998. **57**(9): p. 2135-42, 2148-50.
61. Goldstein, R.Y., et al., *The "Skinny" SCFE*, in *AAP National Conference & Exhibition*. 2015, American Academy of Pediatrics: Washington, DC.
62. Andren, L. and K.E. Borgstrom, *Seasonal variation of epiphysiolysis of the hip and possibility of causal factor*. Acta Orthop Scand, 1958. **28**(1): p. 22-6.
63. Loder, R.T., D.D. Aronson, and R.O. Bollinger, *Seasonal variation of slipped capital femoral epiphysis*. J Bone Joint Surg Am, 1990. **72**(3): p. 378-81.
64. Brown, D., *Seasonal variation of slipped capital femoral epiphysis in the United States*. J Pediatr Orthop, 2004. **24**(2): p. 139-43.
65. Maffulli, N. and A.S. Douglas, *Seasonal variation of slipped capital femoral epiphysis*. J Pediatr Orthop B, 2002. **11**(1): p. 29-33.
66. Wilson, P.D., B. Jacobs, and L. Schecter, *Slipped Capital Femoral Epiphysis: An End-Result Study*. J Bone Joint Surg Am, 1965. **47**: p. 1128-45.
67. Jerre, T., *A study in slipped upper femoral epiphysis: with special reference to the late functional and roentgenological results and to the value of closed reduction*. Acta Orthop Scand, 1950. **Suppl 6**.
68. Loder, R.T., et al., *Acute slipped capital femoral epiphysis: the importance of physeal stability*. J Bone Joint Surg Am, 1993. **75**(8): p. 1134-40.
69. Aadalen, R.J., et al., *Acute slipped capital femoral epiphysis*. J Bone Joint Surg Am, 1974. **56**(7): p. 1473-87.
70. Ziebarth, K., et al., *Clinical stability of slipped capital femoral epiphysis does not correlate with intraoperative stability*. Clin Orthop Relat Res, 2012. **470**(8): p. 2274-9.

71. Slongo, T., et al., *Treatment of slipped capital femoral epiphysis with a modified Dunn procedure*. J Bone Joint Surg Am, 2010. **92**(18): p. 2898-908.
72. Huber, H., et al., *Adolescent slipped capital femoral epiphysis treated by a modified Dunn osteotomy with surgical hip dislocation*. J Bone Joint Surg Br, 2011. **93**(6): p. 833-8.
73. Kallio, P.E., et al., *Slipped capital femoral epiphysis. Incidence and clinical assessment of physeal instability*. J Bone Joint Surg Br, 1995. **77**(5): p. 752-5.
74. Tins, B., V. Cassar-Pullicino, and I. McCall, *The role of pre-treatment MRI in established cases of slipped capital femoral epiphysis*. Eur J Radiol, 2009. **70**(3): p. 570-8.
75. Matava, M.J., et al., *Knee pain as the initial symptom of slipped capital femoral epiphysis: an analysis of initial presentation and treatment*. J Pediatr Orthop, 1999. **19**(4): p. 455-60.
76. Rahme, D., et al., *Consequences of diagnostic delays in slipped capital femoral epiphysis*. J Pediatr Orthop B, 2006. **15**(2): p. 93-7.
77. Schur, M.D., et al., *Continuing Delay in the Diagnosis of Slipped Capital Femoral Epiphysis*. J Pediatr, 2016. **177**(Oct): p. 250-254.
78. Green, D.W., et al., *The delay in diagnosis of slipped capital femoral epiphysis: a review of 102 patients*. HSS J, 2005. **1**(1): p. 103-6.
79. Rattey, T., F. Piehl, and J.G. Wright, *Acute slipped capital femoral epiphysis. Review of outcomes and rates of avascular necrosis*. J Bone Joint Surg Am, 1996. **78**(3): p. 398-402.
80. Hosseinzadeh, P., et al., *Delay in the Diagnosis of Stable Slipped Capital Femoral Epiphysis*. J Pediatr Orthop, 2015.
81. Gholve, P.A., D.B. Cameron, and M.B. Millis, *Slipped capital femoral epiphysis update*. Curr Opin Pediatr, 2009. **21**(1): p. 39-45.
82. Rab, G.T., *The geometry of slipped capital femoral epiphysis: implications for movement, impingement, and corrective osteotomy*. J Pediatr Orthop, 1999. **19**(4): p. 419-24.
83. Loder, R.T., *Correlation of radiographic changes with disease severity and demographic variables in children with stable slipped capital femoral epiphysis*. J Pediatr Orthop, 2008. **28**(3): p. 284-90.
84. Lehmann, T.G., et al., *Radiological findings that may indicate a prior silent slipped capital femoral epiphysis in a cohort of 2072 young adults*. Bone Joint J, 2013. **95-B**(4): p. 452-8.
85. Bomer, J., F. Klerx-Melis, and H.C. Holscher, *Painful paediatric hip: frog-leg lateral view only!* Eur Radiol, 2014. **24**(3): p. 703-8.
86. Klein, A., et al., *Slipped capital femoral epiphysis; early diagnosis and treatment facilitated by normal roentgenograms*. J Bone Joint Surg Am, 1952. **34-A**(1): p. 233-9.
87. Waldenstrom, H., *On necrosis of the joint cartilage by epiphyseolysis capitis femoris*. Acta Chir. Scand, 1930. **67**: p. 936-946.

88. Bellemans, J., et al., *Slipped capital femoral epiphysis: a long-term follow-up, with special emphasis on the capacities for remodeling*. J Pediatr Orthop B, 1996. **5**(3): p. 151-7.
89. Lauenstein, C., *Nachweis der "Kocher'schen Verbiegung" des Schenkelhalses bei der Coxa vara durch Röntgen-Strahlen*. Fortschr. Geb. Röntgenstrahlen, 1901(4): p. 61-64.
90. Loder, R.T., *Unstable slipped capital femoral epiphysis*. J Pediatr Orthop, 2001. **21**(5): p. 694-9.
91. Umans, H., et al., *Slipped capital femoral epiphysis: a physeal lesion diagnosed by MRI, with radiographic and CT correlation*. Skeletal Radiol, 1998. **27**(3): p. 139-44.
92. Lalaji, A., et al., *MRI features of confirmed "pre-slip" capital femoral epiphysis: a report of two cases*. Skeletal Radiol, 2002. **31**(6): p. 362-5.
93. Weinstein, S.L., *Background on slipped capital femoral epiphysis*. Instr Course Lect, 1984. **33**: p. 310-8.
94. Crawford, A.H., *Slipped capital femoral epiphysis*. J Bone Joint Surg Am, 1988. **70**(9): p. 1422-7.
95. Klein, A., et al., *Roentgenographic features of slipped capital femoral epiphysis*. Am J Roentgenol Radium Ther, 1951. **66**(3): p. 361-74.
96. Kallio, P.E., et al., *Ultrasonography in slipped capital femoral epiphysis. Diagnosis and assessment of severity*. J Bone Joint Surg B, 1991. **73**(6): p. 884-9.
97. Kallio, P.E., et al., *Remodeling in slipped capital femoral epiphysis: sonographic assessment after pinning*. J Pediatr Orthop, 1992. **12**(4): p. 438-43.
98. Valstar, E.R., et al., *Guidelines for standardization of radiostereometry (RSA) of implants*. Acta Orthop, 2005. **76**(4): p. 563-72.
99. Holmdahl, P., et al., *Continued growth after fixation of slipped capital femoral epiphysis*. J Child Orthop, 2016. **10**(6): p. 643-650.
100. Terjesen, T., *Ultrasonography for diagnosis of slipped capital femoral epiphysis*. Acta Orthopaedica Scandinavica, 1992. **63**(6): p. 653-657.
101. Datti, I.P., et al., *A comparison study of radiographic and computerized tomographic angles in slipped capital femoral epiphysis*. Rev Bras Ortop, 2017. **52**(5): p. 528-534.
102. Cooper, A.P., et al., *The oblique plane deformity in slipped capital femoral epiphysis*. J Child Orthop, 2014. **8**(2): p. 121-7.
103. Richolt, J.A., et al., *Quantitative evaluation of angular measurements on plain radiographs in patients with slipped capital femoral epiphysis: a 3-dimensional analysis of computed tomography-based computer models of 46 femora*. J Pediatr Orthop, 2008. **28**(3): p. 291-6.
104. Guzzanti, V. and F. Falciglia, *Slipped capital femoral epiphysis: comparison of a roentgenographic method and computed tomography in determining slip severity*. J Pediatr Orthop, 1991. **11**(1): p. 6-12.
105. Cohen, M.S., et al., *Slipped capital femoral epiphysis: assessment of epiphyseal displacement and angulation*. J Pediatr Orthop, 1986. **6**(3): p. 259-64.
106. Montenegro, N.B., et al., *Magnetic Resonance Imaging for Diagnosing the Pre-Slip Stage of the Contralateral Proximal Femoral Epiphysis in Patients with Unilateral*

- Epiphysiolyis*. Revista Brasileira de Ortopedia (English Edition), 2011. **46**(4): p. 439-443.
107. Rhoad, R.C., et al., *Pretreatment bone scan in SCFE: a predictor of ischemia and avascular necrosis*. J Pediatr Orthop, 1999. **19**(2): p. 164-8.
 108. Dasa, V., et al., *F-18 fluoride positron emission tomography of the hip for osteonecrosis*. Clin Orthop Relat Res, 2008. **466**(5): p. 1081-6.
 109. Dossantos, A., et al., *Incremental Value of SPECT/CT in the Detection of Viable Femoral Head in Slipped Upper Femoral Epiphysis (S.U.F.E)*. J Nucl Med Technol, 2018. **46**: p. 153-54.
 110. Finch, A.D. and W.M. Roberts, *Epiphyse coxa valga; report of two cases*. J Bone Joint Surg Am, 1946. **28**(4): p. 869-72.
 111. Skinner, S.R. and G.A. Berkheimer, *Valgus slip of the capital femoral epiphysis*. Clin Orthop Relat Res, 1978(135): p. 90-2.
 112. Yngve, D.A., D.L. Moulton, and E. Burke Evans, *Valgus slipped capital femoral epiphysis*. J Pediatr Orthop B, 2005. **14**(3): p. 172-6.
 113. Shea, K.G., et al., *Valgus slipped capital femoral epiphysis without posterior displacement: two case reports*. J Pediatr Orthop B, 2007. **16**(3): p. 201-3.
 114. Shank, C.F., E.J. Thiel, and K.E. Klingele, *Valgus slipped capital femoral epiphysis: prevalence, presentation, and treatment options*. J Pediatr Orthop, 2010. **30**(2): p. 140-6.
 115. Venkatadass, K., A.P. Shetty, and S. Rajasekaran, *Valgus slipped capital femoral epiphysis: report of two cases and a comprehensive review of literature*. J Pediatr Orthop B, 2011. **20**(5): p. 291-4.
 116. Amiraian, D.E., et al., *Valgus slipped capital femoral epiphysis with contralateral pre-slip*. Skeletal Radiol, 2017. **46**(9): p. 1261-65.
 117. Hagglund, G., et al., *Bilaterality in slipped upper femoral epiphysis*. J Bone Joint Surg Br, 1988. **70**(2): p. 179-81.
 118. Jerre, R., et al., *Bilaterality in slipped capital femoral epiphysis: importance of a reliable radiographic method*. J Pediatr Orthop B, 1996. **5**(2): p. 80-4.
 119. Schreiber, A., *[Epiphysiolyis of the femur head. Contribution to the problem of bilaterality. Simultaneous occurrence of spinal changes]*. Z Orthop Ihre Grenzgeb, 1963. **97**: p. 4-11.
 120. Mickelson, M.R., et al., *The ultrastructure of the growth plate in slipped capital femoral epiphysis*. J Bone Joint Surg Am, 1977. **59**(8): p. 1076-81.
 121. Ippolito, E., et al., *An ultrastructural study of slipped capital femoral epiphysis: pathogenetic considerations*. J Orthop Res, 1989. **7**(2): p. 252-9.
 122. Guzzanti, V., et al., *Slipped capital femoral epiphysis: physeal histologic features before and after fixation*. J Pediatr Orthop, 2003. **23**(5): p. 571-7.
 123. Tresoldi, I., et al., *Histological, histochemical and ultrastructural study of slipped capital femoral epiphysis*. J Child Orthop, 2017. **11**(2): p. 87-92.
 124. Johnson, J.S., et al., *Microarray analysis of slipped capital femoral epiphysis growth plates*. J Pediatr Endocrinol Metab, 2016. **29**(8): p. 971-8.

125. Stevens, D.B., B.A. Short, and J.M. Burch, *In situ fixation of the slipped capital femoral epiphysis with a single screw*. J Pediatr Orthop B, 1996. **5**(2): p. 85-9.
126. Aronson, D.D. and W.E. Carlson, *Slipped capital femoral epiphysis. A prospective study of fixation with a single screw*. J Bone Joint Surg Am, 1992. **74**(6): p. 810-9.
127. Upasani, V., et al., *Biomechanical analysis of single screw fixation for slipped capital femoral epiphysis: are more threads across the physis necessary for stability?* J Pediatr Orthop, 2006. **26**(4): p. 474-8.
128. Kishan, S., et al., *Biomechanical stability of single-screw versus two-screw fixation of an unstable slipped capital femoral epiphysis model: effect of screw position in the femoral neck*. J Pediatr Orthop, 2006. **26**(5): p. 601-5.
129. Brodetti, A., *The blood supply of the femoral neck and head in relation to the damaging effects of nails and screws*. J Bone Joint Surg B, 1960. **42**(4): p. 794-801.
130. Stambough, J.L., et al., *Slipped capital femoral epiphysis: an analysis of 80 patients as to pin placement and number*. J Pediatr Orthop, 1986. **6**(3): p. 265-73.
131. Nguyen, D. and R.T. Morrissy, *Slipped capital femoral epiphysis: rationale for the technique of percutaneous in situ fixation*. J Pediatr Orthop, 1990. **10**(3): p. 341-6.
132. Karol, L.A., et al., *Single versus double screw fixation for treatment of slipped capital femoral epiphysis: a biomechanical analysis*. J Pediatr Orthop, 1992. **12**(6): p. 741-5.
133. Hansson, L.I., *Osteosynthesis with the hook-pin in slipped capital femoral epiphysis*. Acta Orthop Scand, 1982. **53**(1): p. 87-96.
134. de Sanctis, N., et al., *Is gentle manipulative reduction and percutaneous fixation with a single screw the best management of acute and acute-on-chronic slipped capital femoral epiphysis? A report of 70 patients*. J Pediatr Orthop B, 1996. **5**(2): p. 90-5.
135. Ortegren, J., et al., *Unthreaded Fixation of Slipped Capital Femoral Epiphysis Leads to Continued Growth of the Femoral Neck*. J Pediatr Orthop, 2016. **36**(5): p. 494-8.
136. Loder, R.T., *Slipped capital femoral epiphysis in children*. Curr Opin Pediatr, 1995. **7**(1): p. 95-7.
137. Sanders, J.O., et al., *Progressive slippage after pinning for slipped capital femoral epiphysis*. J Pediatr Orthop, 2002. **22**(2): p. 239-43.
138. Mulgrew, E., et al., *Single screw fixation in stable and unstable slipped upper femoral epiphysis*. J Pediatr Orthop B, 2011. **20**(3): p. 147-51.
139. Morrissy, R.T., *Slipped capital femoral epiphysis technique of percutaneous in situ fixation*. J Pediatr Orthop, 1990. **10**(3): p. 347-50.
140. Billing, L., *Roentgen examination of the proximal femur end in children and adolescents; a standardized technique also suitable for determination of the collum-, anteversion-, and epiphyseal angles; a study of slipped epiphysis and coxa plana*. Acta Radiol Suppl, 1954. **110**: p. 1-80.
141. Griffith, M.J., *Slipping of the capital femoral epiphysis*. Ann R Coll Surg Engl, 1976. **58**(1): p. 34-42.
142. Abu Amara, S., J. Leroux, and J. Lechevallier, *Surgery for slipped capital femoral epiphysis in adolescents*. Orthop Traumatol Surg Res, 2014. **100**(1 Suppl): p. S157-67.

143. Senthil, S., et al., *Screw placement after pinning of slipped capital femoral epiphysis: a postoperative CT scan study*. J Pediatr Orthop, 2011. **31**(4): p. 388-92.
144. Pring, M., et al., *In situ screw fixation of slipped capital femoral epiphysis with a novel approach: a double-cohort controlled study*. J Child Orthop, 2010. **4**(3): p. 239-244.
145. Ward, W.T., et al., *Fixation with a single screw for slipped capital femoral epiphysis*. J Bone Joint Surg Am, 1992. **74**(6): p. 799-809.
146. Matsushita, M., et al., *Percutaneous pinning after prolonged skeletal traction with the hip in a flexed position for unstable slipped capital femoral epiphysis: A case series of 11 patients*. Medicine (Baltimore), 2017. **96**(19): p. e6662.
147. Peck, K. and J. Herrera-Soto, *Slipped capital femoral epiphysis: what's new?* Orthop Clin North Am, 2014. **45**(1): p. 77-86.
148. Sariali, E., et al., *The effect of femoral offset modification on gait after total hip arthroplasty*. Acta Orthop, 2014. **85**(2): p. 123-7.
149. Cassidy, K.A., et al., *Effect of femoral offset on pain and function after total hip arthroplasty*. J Arthroplasty, 2012. **27**(10): p. 1863-9.
150. McGrory, B.J., et al., *Effect of femoral offset on range of motion and abductor muscle strength after total hip arthroplasty*. J Bone Joint Surg Br, 1995. **77**(6): p. 865-9.
151. Abraham, E., et al., *Clinical implications of anatomical wear characteristics in slipped capital femoral epiphysis and primary osteoarthritis*. J Pediatr Orthop, 2007. **27**(7): p. 788-95.
152. Mamisch, T.C., et al., *Femoral morphology due to impingement influences the range of motion in slipped capital femoral epiphysis*. Clin Orthop Relat Res, 2009. **467**(3): p. 692-8.
153. Hosalkar, H.S., et al., *Hip impingement in slipped capital femoral epiphysis: a changing perspective*. J Child Orthop, 2012. **6**(3): p. 161-72.
154. Agricola, R., et al., *Cam impingement causes osteoarthritis of the hip: a nationwide prospective cohort study (CHECK)*. Ann Rheum Dis, 2013. **72**(6): p. 918-23.
155. Nicholls, A.S., et al., *The association between hip morphology parameters and nineteen-year risk of end-stage osteoarthritis of the hip: a nested case-control study*. Arthritis Rheum, 2011. **63**(11): p. 3392-400.
156. Beaulé, P.E., et al., *Can the alpha angle assessment of cam impingement predict acetabular cartilage delamination?* Clin Orthop Relat Res, 2012. **470**(12): p. 3361-7.
157. Key, J., *Epiphyseal coxa vara or displacement of the capital epiphysis of the femur in adolescence*. J Bone Joint Surg Am, 1926. **8**: p. 53-117.
158. Kumm, D.A., et al., *Prophylactic dynamic screw fixation of the asymptomatic hip in slipped capital femoral epiphysis*. J Pediatr Orthop, 1996. **16**(2): p. 249-53.
159. Wensaas, A. and S. Svenningsen, *[Slipped capital femoral epiphysis treated with a specially designed screw]*. Tidsskr Nor Laegeforen, 2005. **125**(20): p. 2788-90.
160. Schumann, E., et al., *[Treatment of chronic slipped capital femoral epiphysis : Use of dynamic epiphyseal telescopic screws]*. Orthopade, 2016. **45**(7): p. 597-606.

161. Leblanc, E., et al., *Biomechanical considerations in slipped capital femoral epiphysis and insights into prophylactic fixation*. J Child Orthop, 2017. **11**(2): p. 120-127.
162. Guzzanti, V., F. Falciglia, and C.L. Stanitski, *Slipped capital femoral epiphysis in skeletally immature patients*. J Bone Joint Surg Br, 2004. **86**(5): p. 731-6.
163. Hagglund, G., et al., *Bone growth after fixing slipped femoral epiphyses: brief report*. J Bone Joint Surg Br, 1988. **70**(5): p. 845-6.
164. DeLullo, J.A., et al., *Femoral remodeling may influence patient outcomes in slipped capital femoral epiphysis*. Clin Orthop Relat Res, 2007. **457**: p. 163-70.
165. Wong-Chung, J. and M.L. Strong, *Physcal remodeling after internal fixation of slipped capital femoral epiphyses*. J Pediatr Orthop, 1991. **11**(1): p. 2-5.
166. Ortegren, J., et al., *Continued Growth of the Femoral Neck Leads to Improved Remodeling After In Situ Fixation of Slipped Capital Femoral Epiphysis*. J Pediatr Orthop, 2018. **38**(3): p. 170-175.
167. Falciglia, F., et al., *Fixation in slipped capital femoral epiphysis avoiding femoral-acetabular impingement*. J Orthop Surg Res, 2017. **12**(1): p. 163.
168. Uglow, M.G. and N.M. Clarke, *The management of slipped capital femoral epiphysis*. J Bone Joint Surg Br, 2004. **86**(5): p. 631-5.
169. Hagglund, G., L.I. Hansson, and S. Sandstrom, *Slipped capital femoral epiphysis in southern Sweden. Long-term results after nailing/pinning*. Clin Orthop Relat Res, 1987. Apr;(217): p. 190-200.
170. Wensaas, A., S. Svenningsen, and T. Terjesen, *Long-term outcome of slipped capital femoral epiphysis: a 38-year follow-up of 66 patients*. J Child Orthop, 2011. **5**(2): p. 75-82.
171. Accadbled, F., et al., *In situ pinning in slipped capital femoral epiphysis: long-term follow-up studies*. J Child Orthop, 2017. **11**(2): p. 107-109.
172. Jones, J.R., et al., *Remodelling after pinning for slipped capital femoral epiphysis*. J Bone Joint Surg Br, 1990. **72**(4): p. 568-73.
173. Billing, L. and E. Severin, *Slipping epiphysis of the hip; a roentgenological and clinical study based on a new roentgen technique*. Acta Radiol Suppl, 1959. **174**: p. 1-76.
174. Schai, P.A., G.U. Exner, and O. Hansch, *Prevention of secondary coxarthrosis in slipped capital femoral epiphysis: a long-term follow-up study after corrective intertrochanteric osteotomy*. J Pediatr Orthop B, 1996. **5**(3): p. 135-43.
175. O'Brien, E.T. and J.J. Fahey, *Remodeling of the femoral neck after in situ pinning for slipped capital femoral epiphysis*. J Bone Joint Surg Am, 1977. **59**(1): p. 62-8.
176. Siegel, D.B., et al., *Slipped capital femoral epiphysis. A quantitative analysis of motion, gait, and femoral remodeling after in situ fixation*. J Bone Joint Surg Am, 1991. **73**(5): p. 659-66.
177. Hansson, G., et al., *Long-term results after nailing in situ of slipped upper femoral epiphysis. A 30-year follow-up of 59 hips*. J Bone Joint Surg Br, 1998. **80**(1): p. 70-7.
178. Han, H., et al., *Hip rotation range of motion in sitting and prone positions in healthy Japanese adults*. J Phys Ther Sci, 2015. **27**(2): p. 441-5.

179. Kouyoumdjian, P., et al., *Clinical evaluation of hip joint rotation range of motion in adults*. Orthop Traumatol Surg Res, 2012. **98**(1): p. 17-23.
180. Notzli, H.P., et al., *The contour of the femoral head-neck junction as a predictor for the risk of anterior impingement*. J Bone Joint Surg Br, 2002. **84**(4): p. 556-60.
181. Stokes, I.A., *Mechanical effects on skeletal growth*. J Musculoskelet Neuronal Interact, 2002. **2**(3): p. 277-80.
182. Aronsson, D.D. and R.T. Loder, *Treatment of the unstable (acute) slipped capital femoral epiphysis*. Clin Orthop Relat Res, 1996(322): p. 99-110.
183. Gordon, J.E., et al., *Early reduction, arthrotomy, and cannulated screw fixation in unstable slipped capital femoral epiphysis treatment*. J Pediatr Orthop, 2002. **22**(3): p. 352-8.
184. Hagglund, G., *The contralateral hip in slipped capital femoral epiphysis*. J Pediatr Orthop B, 1996. **5**(3): p. 158-61.
185. Lehmann, T.G., et al., *In situ fixation of slipped capital femoral epiphysis with Steinmann pins*. Acta Orthop, 2011. **82**(3): p. 333-8.
186. Leunig, M., et al., *Subcapital correction osteotomy in slipped capital femoral epiphysis by means of surgical hip dislocation*. Oper Orthop Traumatol, 2007. **19**(4): p. 389-410.
187. Ziebarth, K., et al., *High Survivorship and Little Osteoarthritis at 10-year Followup in SCFE Patients Treated With a Modified Dunn Procedure*. Clin Orthop Relat Res, 2017. **475**(4): p. 1212-1228.
188. Novais, E.N., et al., *Modified Dunn Procedure is Superior to In Situ Pinning for Short-term Clinical and Radiographic Improvement in Severe Stable SCFE*. Clin Orthop Relat Res, 2015. **473**(6): p. 2108-17.
189. Persinger, F., et al., *Treatment of Unstable Slipped Capital Epiphysis Via the Modified Dunn Procedure*. J Pediatr Orthop, 2018. **38**(1): p. 3-8.
190. Abu Amara, S., et al., *Severe slipped capital femoral epiphysis: A French multicenter study of 186 cases performed by the SoFOP*. Orthop Traumatol Surg Res, 2015. **101**(6 Suppl): p. S275-9.
191. Madan, S.S., et al., *The treatment of severe slipped capital femoral epiphysis via the Ganz surgical dislocation and anatomical reduction: a prospective study*. Bone Joint J, 2013. **95-B**(3): p. 424-9.
192. Novais, E.N., et al., *The modified Dunn procedure provides superior short-term outcomes in the treatment of the unstable slipped capital femoral epiphysis as compared to the inadvertent closed reduction and percutaneous pinning: a comparative clinical study*. Int Orthop, 2018, May 24, Epub.
193. Davis, R.L., 2nd, et al., *Treatment of Unstable Versus Stable Slipped Capital Femoral Epiphysis Using the Modified Dunn Procedure*. J Pediatr Orthop, 2017.
194. Sikora-Klak, J., et al., *Comparison of Surgical Outcomes Between a Triplane Proximal Femoral Osteotomy and the Modified Dunn Procedure for Stable, Moderate to Severe Slipped Capital Femoral Epiphysis*. J Pediatr Orthop, 2017.
195. Wenger, D.R. and J.D. Bomar, *Acute, unstable, slipped capital femoral epiphysis: is there a role for in situ fixation?* J Pediatr Orthop, 2014. **34 Suppl 1**: p. S11-7.

196. Sankar, W.N., et al., *The modified Dunn procedure for unstable slipped capital femoral epiphysis: a multicenter perspective*. J Bone Joint Surg Am, 2013. **95**(7): p. 585-91.
197. Vanhegan, I.S., et al., *Outcomes following subcapital osteotomy for severe slipped upper femoral epiphysis*. Bone Joint J, 2015. **97-B**(12): p. 1718-25.
198. Upasani, V.V., et al., *Complications after modified Dunn osteotomy for the treatment of adolescent slipped capital femoral epiphysis*. J Pediatr Orthop, 2014. **34**(7): p. 661-7.
199. Leunig, M., et al., *Femoral and acetabular re-alignment in slipped capital femoral epiphysis*. J Child Orthop, 2017. **11**(2): p. 131-137.
200. Upasani, V.V., et al., *Iatrogenic Hip Instability Is a Devastating Complication After the Modified Dunn Procedure for Severe Slipped Capital Femoral Epiphysis*. Clin Orthop Relat Res, 2017. **475**(4): p. 1229-1235.
201. Loder, R.T., *CORR Insights((R)): Iatrogenic Hip Instability Is a Devastating Complication After the Modified Dunn Procedure for Severe Slipped Capital Femoral Epiphysis*. Clin Orthop Relat Res, 2017. **475**(4): p. 1236-1238.
202. Mooney, J.F., 3rd, et al., *Management of unstable/acute slipped capital femoral epiphysis: results of a survey of the POSNA membership*. J Pediatr Orthop, 2005. **25**(2): p. 162-6.
203. Sonnega, R.J., et al., *Management of slipped capital femoral epiphysis: results of a survey of the members of the European Paediatric Orthopaedic Society*. J Child Orthop, 2011. **5**(6): p. 433-8.
204. Chung, S.M., *The arterial supply of the developing proximal end of the human femur*. J Bone Joint Surg Am, 1976. **58**(7): p. 961-70.
205. Maeda, S., et al., *Vascular supply to slipped capital femoral epiphysis*. J Pediatr Orthop, 2001. **21**(5): p. 664-7.
206. Jackson, J.B., 3rd, et al., *Restoration of Blood Flow to the Proximal Femoral Epiphysis in Unstable Slipped Capital Femoral Epiphysis by Modified Dunn Procedure: A Preliminary Angiographic and Intracranial Pressure Monitoring Study*. J Pediatr Orthop, 2018. **38**(2): p. 94-99.
207. Novais, E.N., et al., *Is Assessment of Femoral Head Perfusion During Modified Dunn for Unstable Slipped Capital Femoral Epiphysis an Accurate Indicator of Osteonecrosis?* Clin Orthop Relat Res, 2016. **474**(8): p. 1837-44.
208. Herrera-Soto, J.A., et al., *Increased intracapsular pressures after unstable slipped capital femoral epiphysis*. J Pediatr Orthop, 2008. **28**(7): p. 723-8.
209. Ibrahim, T., et al., *Hip decompression of unstable slipped capital femoral epiphysis: a systematic review and meta-analysis*. J Child Orthop, 2015. **9**(2): p. 113-20.
210. Kalogrianitis, S., et al., *Does unstable slipped capital femoral epiphysis require urgent stabilization?* J Pediatr Orthop B, 2007. **16**(1): p. 6-9.
211. Phillips, S.A., W.E. Griffiths, and N.M. Clarke, *The timing of reduction and stabilisation of the acute, unstable, slipped upper femoral epiphysis*. J Bone Joint Surg Br, 2001. **83**(7): p. 1046-9.

212. Kohno, Y., et al., *Is the timing of surgery associated with avascular necrosis after unstable slipped capital femoral epiphysis? A multicenter study.* J Orthop Sci, 2017. **22**(1): p. 112-115.
213. Thomsen, L., et al., *The progressive longitudinal traction reduction of unstable slipped capital femoral epiphysis: preliminary results in 11 patients.* J Child Orthop, 2007. **1**(2): p. 121-5.
214. Dietz, F.R., *Traction reduction of acute and acute-on-chronic slipped capital femoral epiphysis.* Clin Orthop Relat Res, 1994(302): p. 101-10.
215. Vegter, J., *The influence of joint posture on intra-articular pressure. A study of transient synovitis and Perthes' disease.* J Bone Joint Surg Br, 1987. **69**(1): p. 71-4.
216. Carney, B.T., P. Birnbaum, and C. Minter, *Slip progression after in situ single screw fixation for stable slipped capital femoral epiphysis.* J Pediatr Orthop, 2003. **23**(5): p. 584-9.
217. Sailhan, F., et al., *Continued growth of the hip after fixation of slipped capital femoral epiphysis using a single cannulated screw with a proximal threading.* J Child Orthop, 2011. **5**(2): p. 83-8.
218. Palocaren, T., et al., *Outcome of in situ pinning in patients with unstable slipped capital femoral epiphysis: assessment of risk factors associated with avascular necrosis.* J Pediatr Orthop, 2010. **30**(1): p. 31-6.
219. Chen, R.C., et al., *Urgent reduction, fixation, and arthrotomy for unstable slipped capital femoral epiphysis.* J Pediatr Orthop, 2009. **29**(7): p. 687-94.
220. Parsch, K., S. Weller, and D. Parsch, *Open reduction and smooth Kirschner wire fixation for unstable slipped capital femoral epiphysis.* J Pediatr Orthop, 2009. **29**(1): p. 1-8.
221. Ganz, R., et al., *Surgical dislocation of the adult hip a technique with full access to the femoral head and acetabulum without the risk of avascular necrosis.* J Bone Joint Surg Br, 2001. **83**(8): p. 1119-24.
222. Bali, N.S., J.O. Harrison, and C.E. Bache, *A modified Imhauser osteotomy: an assessment of the addition of an open femoral neck osteoplasty.* Bone Joint J, 2014. **96-B**(8): p. 1119-23.
223. Erickson, J.B., W.P. Samora, and K.E. Klingele, *Treatment of chronic, stable slipped capital femoral epiphysis via surgical hip dislocation with combined osteochondroplasty and Imhauser osteotomy.* J Child Orthop, 2017. **11**(4): p. 284-288.
224. Spencer, S., M.B. Millis, and Y.J. Kim, *Early results of treatment of hip impingement syndrome in slipped capital femoral epiphysis and pistol grip deformity of the femoral head-neck junction using the surgical dislocation technique.* J Pediatr Orthop, 2006. **26**(3): p. 281-5.
225. Imhauser, G., *[Late results of Imhauser's osteotomy for slipped capital femoral epiphysis (author's transl)].* Z Orthop Ihre Grenzgeb, 1977. **115**(5): p. 716-25.
226. Schai, P.A. and G.U. Exner, *Corrective Imhauser intertrochanteric osteotomy.* Oper Orthop Traumatol, 2007. **19**(4): p. 368-88.

227. Kartenbender, K., W. Cordier, and B.D. Katthagen, *Long-term follow-up study after corrective Imhauser osteotomy for severe slipped capital femoral epiphysis*. J Pediatr Orthop, 2000. **20**(6): p. 749-56.
228. Maussen, J.P., P.M. Rozing, and W.R. Obermann, *Intertrochanteric corrective osteotomy in slipped capital femoral epiphysis. A long-term follow-up study of 26 patients*. Clin Orthop Relat Res, 1990(259): p. 100-10.
229. MacLean, J.G. and S.K. Reddy, *The contralateral slip. An avoidable complication and indication for prophylactic pinning in slipped upper femoral epiphysis*. J Bone Joint Surg Br, 2006. **88**(11): p. 1497-501.
230. Dewnany, G. and P. Radford, *Prophylactic contralateral fixation in slipped upper femoral epiphysis: is it safe?* J Pediatr Orthop B, 2005. **14**(6): p. 429-33.
231. Schultz, W.R., et al., *Prophylactic pinning of the contralateral hip in slipped capital femoral epiphysis : evaluation of long-term outcome for the contralateral hip with use of decision analysis*. J Bone Joint Surg Am, 2002. **84-A**(8): p. 1305-14.
232. Baghdadi, Y.M., et al., *The fate of hips that are not prophylactically pinned after unilateral slipped capital femoral epiphysis*. Clin Orthop Relat Res, 2013. **471**(7): p. 2124-31.
233. Jerre, R., et al., *The contralateral hip in patients primarily treated for unilateral slipped upper femoral epiphysis. Long-term follow-up of 61 hips*. J Bone Joint Surg Br, 1994. **76**(4): p. 563-7.
234. Kocher, M.S., et al., *Prophylactic pinning of the contralateral hip after unilateral slipped capital femoral epiphysis*. J Bone Joint Surg Am, 2004. **86-A**(12): p. 2658-65.
235. Hansson, G. and J. Nathorst-Westfelt, *Management of the contralateral hip in patients with unilateral slipped upper femoral epiphysis: to fix or not to fix--consequences of two strategies*. J Bone Joint Surg Br, 2012. **94**(5): p. 596-602.
236. Riad, J., G. Bajelidze, and P.G. Gabos, *Bilateral slipped capital femoral epiphysis: predictive factors for contralateral slip*. J Pediatr Orthop, 2007. **27**(4): p. 411-4.
237. Bidwell, T.A. and N. Susan Stott, *Sequential slipped capital femoral epiphyses: who is at risk for a second slip?* ANZ J Surg, 2006. **76**(11): p. 973-6.
238. Koenig, K.M., et al., *Does skeletal maturity predict sequential contralateral involvement after fixation of slipped capital femoral epiphysis?* J Pediatr Orthop, 2007. **27**(7): p. 796-800.
239. Popejoy, D., K. Emara, and J. Birch, *Prediction of contralateral slipped capital femoral epiphysis using the modified Oxford bone age score*. J Pediatr Orthop, 2012. **32**(3): p. 290-4.
240. Bellemore, J.M., et al., *Biomechanics of Slipped Capital Femoral Epiphysis: Evaluation of the Posterior Sloping Angle*. J Pediatr Orthop, 2016. **36**(6): p. 651-5.
241. Phillips, P.M., et al., *Posterior sloping angle as a predictor of contralateral slip in slipped capital femoral epiphysis*. J Bone Joint Surg Am, 2013. **95**(2): p. 146-50.
242. Park, S., et al., *The utility of posterior sloping angle in predicting contralateral slipped capital femoral epiphysis*. J Pediatr Orthop, 2010. **30**(7): p. 683-9.

243. Billing, L. and O. Eklof, *Slip of the capital femoral epiphysis: revival of a method of assessment*. *Pediatr Radiol*, 1984. **14**(6): p. 413-8.
244. Zenios, M., et al., *Posterior sloping angle of the capital femoral physis: interobserver and intraobserver reliability testing and predictor of bilaterality*. *J Pediatr Orthop*, 2007. **27**(7): p. 801-4.
245. Novais, E.N., et al., *Age- and gender-specific variations of the epiphyseal tilt and epiphyseal angle in adolescents without hip pathology*. *J Child Orthop*, 2018. **12**(2): p. 152-159.
246. Monazzam, S., J.D. Bomar, and A.T. Pennock, *Idiopathic Cam Morphology Is Not Caused by Subclinical Slipped Capital Femoral Epiphysis: An MRI and CT Study*. *Orthop J Sports Med*, 2013. **1**(7): p. 2325967113512467.
247. Kienle, K.P., et al., *Femoral morphology and epiphyseal growth plate changes of the hip during maturation: MR assessments in a 1-year follow-up on a cross-sectional asymptomatic cohort in the age range of 9-17 years*. *Skeletal Radiol*, 2012. **41**(11): p. 1381-90.
248. Castro, F.P., Jr., J.T. Bennett, and K. Doulens, *Epidemiological perspective on prophylactic pinning in patients with unilateral slipped capital femoral epiphysis*. *J Pediatr Orthop*, 2000. **20**(6): p. 745-8.
249. Hurley, J.M., et al., *Slipped capital femoral epiphysis. The prevalence of late contralateral slip*. *J Bone Joint Surg Am*, 1996. **78**(2): p. 226-30.
250. Nations, G.A.U., *Convention on the Rights of the Child, in Article 49*, U. Nations, Editor. 1989, Office of the High Commissioner: Geneva.
251. Marshall, S., K. Haywood, and R. Fitzpatrick, *Impact of patient-reported outcome measures on routine practice: a structured review*. *J Eval Clin Pract*, 2006. **12**(5): p. 559-68.
252. 2014:821, S., *Patientlag [Patient health and medical act]*, S.M.o.S. Affairs], Editor. 2014: Stockholm.
253. *WHO constitution*, in *Basic Documents, Forty-fifth edition*, WHO, Editor. October 2006, WHO: New York, USA. p. 1-20.
254. Davies, A. and D. Randall, *Perceptions of Children's Participation in Their Healthcare: A Critical Review*. *Issues Compr Pediatr Nurs*, 2015. **38**(3): p. 202-21.
255. Valderas, J.M. and J. Alonso, *Patient reported outcome measures: a model-based classification system for research and clinical practice*. *Qual Life Res*, 2008. **17**(9): p. 1125-35.
256. Nicholas, D.B., et al., *Experiences and barriers to Health-Related Quality of Life following liver transplantation: a qualitative analysis of the perspectives of pediatric patients and their parents*. *Health Qual Life Outcomes*, 2010. **8**: p. 150.
257. Meadows, K.A., *Patient-reported outcome measures: an overview*. *Br J Community Nurs*, 2011. **16**(3): p. 146-51.
258. Escott, B.G., et al., *Patient-Reported Health Outcomes After in Situ Percutaneous Fixation for Slipped Capital Femoral Epiphysis: An Average Twenty-Year Follow-up Study*. *J Bone Joint Surg Am*, 2015. **97**(23): p. 1929-34.

259. Wille, N., et al., *Development of the EQ-5D-Y: a child-friendly version of the EQ-5D*. Qual Life Res, 2010. **19**(6): p. 875-86.
260. Burstrom, K., et al., *EQ-5D-Y as a health-related quality of life measure in children and adolescents with functional disability in Sweden: testing feasibility and validity*. Acta Paediatr, 2014. **103**(4): p. 426-35.
261. Ranstam, J., et al., [*EQ-5D--a difficult-to-interpret tool for clinical improvement work*]. Lakartidningen, 2011. **108**(36): p. 1707-8.
262. Ravens-Sieberer, U., et al., *Feasibility, reliability, and validity of the EQ-5D-Y: results from a multinational study*. Qual Life Res, 2010. **19**(6): p. 887-97.
263. d'Entremont, A.G., et al., *What clinimetric evidence exists for using hip-specific patient-reported outcome measures in pediatric hip impingement?* Clin Orthop Relat Res, 2015. **473**(4): p. 1361-7.
264. Aguilar, C.M., et al., *Clinical evaluation of avascular necrosis in patients with sickle cell disease: Children's Hospital Oakland Hip Evaluation Scale--a modification of the Harris Hip Score*. Arch Phys Med Rehabil, 2005. **86**(7): p. 1369-75.
265. Roposch, A., et al., *Functional outcomes in children with osteonecrosis secondary to treatment of developmental dysplasia of the hip*. J Bone Joint Surg Am, 2011. **93**(24): p. e145.
266. Feng, Y., D. Parkin, and N.J. Devlin, *Assessing the performance of the EQ-VAS in the NHS PROMs programme*. Qual Life Res, 2014. **23**(3): p. 977-89.
267. Kennedy, J.G., et al., *Osteonecrosis of the femoral head associated with slipped capital femoral epiphysis*. J Pediatr Orthop, 2001. **21**(2): p. 189-93.
268. Karlberg, J., Z.C. Luo, and K. Albertsson-Wikland, *Body mass index reference values (mean and SD) for Swedish children*. Acta Paediatr, 2001. **90**(12): p. 1427-34.
269. Arons, A.M. and P.F. Krabbe, *Quantification of health by scaling similarity judgments*. PLoS One, 2014. **9**(2): p. e89091.
270. Tang, W., et al., *Kappa coefficient: a popular measure of rater agreement*. Shanghai Arch Psychiatry, 2015. **27**(1): p. 62-7.
271. Ngo, T., et al., *A study of the test-retest reliability of the self-perceived general recovery and self-perceived change in neck pain questions in patients with recent whiplash-associated disorders*. Eur Spine J, 2010. **19**(6): p. 957-62.
272. Svensson, E., et al., *Reliability of the balanced inventory for spinal disorders, a questionnaire for evaluation of outcomes in patients with various spinal disorders*. J Spinal Disord Tech, 2012. **25**(4): p. 196-204.
273. Mukaka, M.M., *Statistics corner: A guide to appropriate use of correlation coefficient in medical research*. Malawi Med J, 2012. **24**(3): p. 69-71.
274. Tavakol, M. and R. Dennick, *Making sense of Cronbach's alpha*. Int J Med Educ, 2011. **2**: p. 53-55.
275. Krabbe, P.F., J.A. Salomon, and C.J. Murray, *Quantification of health states with rank-based nonmetric multidimensional scaling*. Med Decis Making, 2007. **27**(4): p. 395-405.
276. Carney, B.T. and J. Liljenquist, *Measurement variability of the lateral head-shaft angle in slipped capital femoral epiphysis*. J Surg Orthop Adv, 2005. **14**(4): p. 165-7.

277. Bland, J.M. and D.G. Altman, *Statistical methods for assessing agreement between two methods of clinical measurement*. Lancet, 1986. **1**(8476): p. 307-10.
278. Lehmann, T.G., et al., *Intra- and inter-observer repeatability of radiographic measurements for previously slipped capital femoral epiphysis at skeletal maturity*. Acta Radiol, 2013. **54**(5): p. 587-91.
279. McGraw, K.O. and S.P. Wong, *Forming inferences about some intraclass correlation coefficients*. Psychological Methods, 1996. **1**(1): p. 30-46.
280. Hermanson, M., et al., *Inter- and intra-rater reliability of the head-shaft angle in children with cerebral palsy*. J Child Orthop, 2017. **11**(4): p. 256-262.
281. Sedgwick, P., *Limits of agreement (Bland-Altman method)*. BMJ, 2013. **346**: p. f1630.
282. Petersson, C., *Using health-related quality of life instruments for children with long-term conditions*, in *School of Health and Welfare. Thesis*. 2017, Dissertation Series No. 77, Jönköping University: Sweden.
283. Sjoberg, A., et al., *Overweight and obesity in a representative sample of schoolchildren - exploring the urban-rural gradient in Sweden*. Obes Rev, 2011. **12**(5): p. 305-14.
284. de Munter, J.S., et al., *Stability in the prevalence of Swedish children who were overweight or obese in 2003 and 2011*. Acta Paediatr, 2016. **105**(10): p. 1173-80.
285. Loder, R.T., et al., *Demographic predictors of severity of stable slipped capital femoral epiphyses*. J Bone Joint Surg Am, 2006. **88**(1): p. 97-105.
286. Welfare, T.S.N.B.o.H.a., *Förskrivning av ADHD-läkemedel 2016 - utvecklingen av incidens och prevalens*, N. Borg, Editor. 2017: www.socialstyrelsen.se.
287. Rostoucher, P., et al., *Slipped capital femoral epiphysis: evaluation of different modes of treatment*. J Pediatr Orthop B, 1996. **5**(2): p. 96-101.
288. Lim, Y.J., et al., *Management outcome and the role of manipulation in slipped capital femoral epiphysis*. J Orthop Surg (Hong Kong), 2007. **15**(3): p. 334-8.
289. Raney, E.M., et al., *Evidence-based analysis of removal of orthopaedic implants in the pediatric population*. J Pediatr Orthop, 2008. **28**(7): p. 701-4.
290. Crandall, D.G., K.R. Gabriel, and B.A. Akbarnia, *Second operation for slipped capital femoral epiphysis: pin removal*. J Pediatr Orthop, 1992. **12**(4): p. 434-7.
291. Jago, E.R. and C.J. Hindley, *The removal of metalwork in children*. Injury, 1998. **29**(6): p. 439-41.
292. Kahle, W.K., *The case against routine metal removal*. J Pediatr Orthop, 1994. **14**(2): p. 229-37.

Paper I



RESEARCH ARTICLE

Open Access



Slipped capital femoral epiphysis: a population-based study

Bengt Herngren^{1*}, Margaretha Stenmarker², Ludek Vavrch³ and Gunnar Hagglund⁴

Abstract

Background: Slipped capital femoral epiphysis (SCFE) is the most common hip disorder in children 9–15 years old. This is a population-based study in Sweden presenting the epidemiology for SCFE.

Methods: In a prospective cohort study, we analysed pre- and postoperative radiographs, medical records for all children treated for SCFE in Sweden 2007–2013, demographic data, severity of slip and surgical procedures performed.

Results: We identified 379 Swedish children with primary SCFE 2007–2013; 162 girls, median age 11.7 (7.2–15.4) years, and 217 boys, median age 13 (3.8–17.7) years. The average annual incidence was 4.4/10000 for girls and 5.7/10000 for boys 9–15 years old. Obesity or overweight was found in 56% of the girls and in 76% of the boys. As an initial symptom, 66% of the children had hip/groin pain and 12% knee pain. At first presentation, 7% of the children had bilateral SCFE. Prophylactic fixation was performed in 43%. Of the remaining children, 21% later developed a contralateral slip. Fixation with implants permitting further growth was used in >90% of the children. Femoral neck osteotomy was performed for 11 hips.

Conclusions: The annual average incidence 2007–2013 in Sweden showed a mild increase for girls. The male-to-female ratio was lower than previous regional data from Sweden. Overweight or obesity is one major characteristic for boys with SCFE but to a less extent for girls. Knee pain as initial symptom cause a delay in diagnosis. Most hospitals in Sweden treat <2 children annually.

Keywords: Epidemiology, Slipped capital femoral epiphysis, Incidence, Hip, Slipped upper femoral epiphysis

Background

Slipped capital femoral epiphysis (SCFE) is the most common hip disorder in children 9–15 years old [1, 2]. The aetiology appears to be multifactorial. Identified biomechanical factors are obesity, increased femoral retroversion and increased physeal obliquity that all result in increased shear forces in the capital physis [3–5]. SCFE is known to be associated with endocrine disorders, e.g. hypothyroidism, hypogonadism, and hypopituitarism [6–8]. Children with renal failure osteodystrophy [9] or children who have acquired radiation therapy to the pelvis [10, 11] are also known to have a higher risk to develop SCFE.

SCFE is a separation between the epiphysis and the metaphysis of the proximal femur. The epiphysis remains in the acetabulum while the femur usually rotates outwards and in extension [12, 13]. The duration of symptoms is correlated with increased severity of the slip [14–20]. A more severe slip is associated with increased pain and a further limitation in the range of motion [18, 21, 22]. Epidemiological data for SCFE from different countries have been presented, but only a few are based on a total national population [2, 23–26]. The incidence reported is related to ethnicity and sex. A seasonal variation has also been described but with uncertainty concerning the role in the ethiology of SCFE [2, 27–32]. A male-to-female ratio between 1.1:1 and up to 4.1:1 has been reported [1, 2, 23, 25, 28, 33, 34]. Previous reports with a total national population are based on data from national registers, e.g. Kids' Inpatient database in the USA [2] or the national hospital registration system of The Netherlands [23].

* Correspondence: Bengt.Herngren@med.lu.se

¹Department of Clinical Sciences Lund, Orthopaedics Department of Orthopaedics, Ryhov county hospital, Lund University, SE-551 85 Jonkoping, Sweden

Full list of author information is available at the end of the article



© The Author(s). 2017 **Open Access** This article is distributed under the terms of the Creative Commons Attribution 4.0 International License (<http://creativecommons.org/licenses/by/4.0/>), which permits unrestricted use, distribution, and reproduction in any medium, provided you give appropriate credit to the original author(s) and the source, provide a link to the Creative Commons license, and indicate if changes were made. The Creative Commons Public Domain Dedication waiver (<http://creativecommons.org/publicdomain/zero/1.0/>) applies to the data made available in this article, unless otherwise stated.

The aim of this study was to describe the epidemiology for SCFE in Sweden and to identify the demographic characteristics of children, type and degree of SCFE, and the surgical procedures performed.

We hypothesized that: (1) there is a difference in incidence between boys and girls, (2) knee pain as presenting symptom will cause a difference compared to hip/groin pain when you compare to what extent an acute hip disorder would be suspected at the first health care contact, (3) age at diagnosis has not changed compared to previous regional epidemiological data from Sweden, and (4) overweight or obesity are predominating characteristics for children with SCFE in Sweden.

Methods

This is a prospective cohort study of the total population of children treated for SCFE of the index hip in Sweden 2007–2013. All children were consecutively reported to a national quality register with one of the authors (BH) as director.

Inclusion criteria were: children living in Sweden, registered in the Swedish Population Register with a Swedish personal identity number, with SCFE in the index hip during the study period. Exclusion criteria were: SCFE because of high energy trauma or septic coxitis.

All children treated for SCFE were admitted to hospital for primary treatment. For control purpose of the completeness achieved in this study we were retrospectively provided with individual-based data from the Swedish National Board of Health and Welfare, and compared our database with the Swedish National Patient Register. All hospitals are directed by Swedish regulations to register all admissions with codes for diagnosis (WHO classification ICD-10) and treatment codes according to the NOMESCO - NCSP classification of surgical procedures (NOMESCO - Nordic Medico-Statistical Committee, NCSP - Nordic classification of surgical procedures). All hospitals that treated SCFE in Sweden participated.

Population data was collected through official statistics for Sweden (Statistics Sweden). The number of children 9–15 years old with a Swedish personal identity number was slightly higher for both girls and boys at the beginning of the study period, see Table 1. For that reason, we chose to use the average population of children 9–15 years old as the average population at risk when calculating the

average annual incidence for SCFE during the study period. We excluded the five girls <9 years old and the boy of 3.8 years together with the four boys ≥ 16 years old when calculating the average annual incidence.

Medical records together with pre- and postoperative radiographs were obtained for all patients and were analysed consecutively. Missing data were completed by contact with the hospital involved or the family. A follow-up was made after 24 months through an assigned contact person in each hospital to identify any additional surgery performed for SCFE on the contralateral hip.

From the medical records, we obtained information about: sex, place of residence, type of initial symptoms, initial health care provider, duration of symptoms, age at diagnosis, whether the SCFE was acute or not, type of surgical treatment, reduction manoeuvres applied [35–38], implant used and whether prophylactic surgery was performed on the contralateral hip. For osteotomies, we recorded whether a capital realignment procedure [39–41] was performed, with or without surgical dislocation of the hip [40]. Other specific surgical treatment methods registered were open reduction and internal fixation according to Parsch [42] and whether joint aspiration [43, 44] was performed for unstable SCFE.

The medical records revealed that height and weight were not routinely measured in the paediatric departments and therefore not reported to us. We then retrospectively asked the families for an additional informed consent to be signed to be able to obtain the growth curves from the school health nurse. We accepted a value for age adjusted BMI according to Karlberg 2001 [45] within 12 months before or after the primary surgery was performed for the index hip.

For both the analysis of the duration of symptoms and initial health care provider, we used the history that was presented on hospital admission for primary surgery for SCFE. The total duration of symptoms, i.e. time from initial presenting symptom until primary surgery was performed, was calculated in months. Surgery performed on the first day with symptoms was equal to 0 months; ≥ 1 day, but ≤ 1 week was equal to 0.25 months; >1 week, but ≤ 2 weeks was equal to 0.50 months; >2 weeks, but ≤ 3 weeks was equal to 0.75 months and so forth.

For the analysis of seasonal variation we excluded the children with >24 months duration of symptoms [30].

Table 1 Number of girls and boys, 9–15 years old, living in Sweden in 2007–2013

Year	2007	2008	2009	2010	2011	2012	2013	2007–2013 average
Girls	386,372	371,151	357,163	346,664	337,959	336,135	339,852	353,614
Boys	406,293	390,426	375,523	365,425	357,094	354,890	359,177	372,690
Total	792,665	761,577	732,686	712,089	695,053	691,025	699,029	726,304

In children with bilateral SCFE at primary admission the index hip was the one with the longest duration of symptoms. When the duration of symptoms was equal for both hips, we designated the hip with the largest slip angle to be the hip with primary SCFE. For bilateral cases, only the data for the index hip were used except when comparing the parameters for the first and second slipped capital femoral epiphysis [1].

The radiographic analysis included measurement of the slip angle on a Lauenstein view using the calcar femorale method [46] (Fig. 1). If a Billing lateral view was obtained the Billing method [47] was used (Fig. 2). For both these methods a minimum slip angle of 13° was required for diagnosis [12, 46, 48]. If no lateral view was obtained, because of an unstable SCFE [49], the Southwick head-shaft angle HSA [50] on the anteroposterior (AP) view was used. There is no cut off value described for SCFE in the literature using the HSA in the AP view. We, therefore, used the following criteria: HSA on an AP view of $\leq 110^\circ$ together with a broken Klein's line [51, 52] and clinical findings/symptoms of a hip disease, e.g. limping or groin/hip pain.

Hips with a slip angle of 13° to $<30^\circ$ were classified as mild, 30° to $<50^\circ$ as moderate, and $\geq 50^\circ$ as severe [12, 17, 53, 54]. HSA of $\leq 110^\circ$ on AP view was classified as severe.

A valgus SCFE was defined as a superior/lateral and posterior displacement of the proximal femoral epiphysis in relation to the femoral neck with an increased prominence of the lateral femoral epiphysis in relation to the lateral femoral neck (Klein's line) on an anteroposterior view. For a unilateral valgus SCFE an increased HSA was also noted compared to the contralateral hip [55, 56].

The clinical classification described by Loder et al. [49] was used where the SCFE was either stable or unstable (not being able to ambulate with two crutches). Information from the medical records on admission to the hospital or from the description of the surgical procedure performed was used for the clinical classification.

All statistical analyses were performed using SPSS Statistics for Windows (version 22.0; IBM Corp, Armonk, NY). Continuous data were reported as the median with minimum and maximum values. Discrete data were reported as frequencies and/or percentages. For nonparametric tests between two independent groups we used a Mann-Whitney U-test. To compare proportions between two independent groups we used a cross-table and a chi-square test. A comparison of the Mann-Whitney U and chi-square tests was made using a Fischer exact test that found identical results.

Results

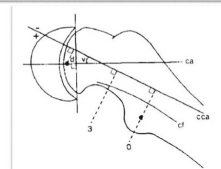
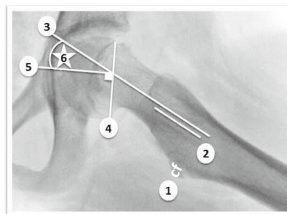
The annual average incidence

A total of 379 Swedish children with primary SCFE in 2007–2013 were identified. Of these, 35 were retrospectively identified through the Swedish National Patient Register. The average number of children 9–15 years old in Sweden in 2007–2013 was 726,304 (353,614 girls and 372,690 boys). Calculating the average annual incidence for children 9–15 years old we excluded the five girls and the one boy <9 years old together with the four boys ≥ 16 years old. The average annual incidence of SCFE was 4.4 per 10,000 girls and 5.7 per 10,000 boys 9–15 years old.

Slip angle using the Calcar femorale (cf)

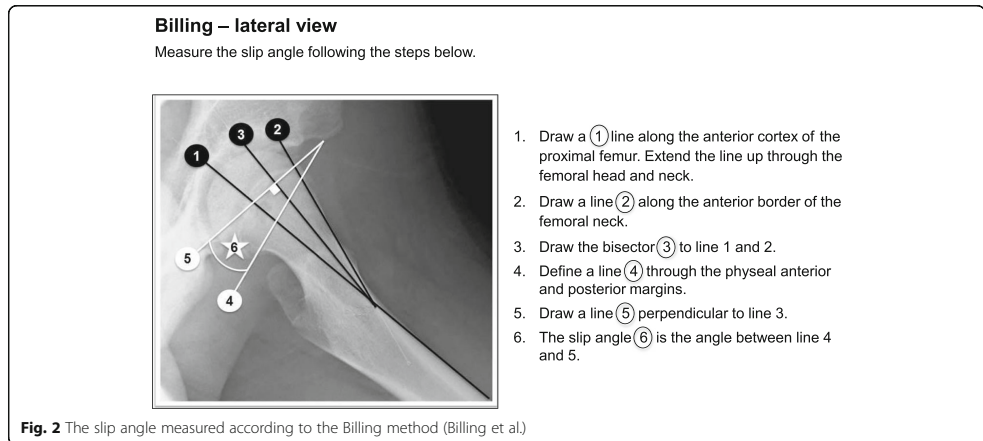
- Lauenstein view

1. Identify the calcar femorale and the lesser trochanter (1).
2. From the level of the lesser trochanter draw a line (2) three cm in a proximal direction parallel to the calcar femorale ("O till 3" in the small figure).
3. Extend a line (3) parallel to line 2 up through the femoral neck.
4. Define a line (4) through the physal anterior and posterior margins.
5. Draw a line (5) perpendicular to line 4.
6. Slip angle (6) ("v" in the small figure).



Permission granted for reproduction of Figure 2
Acta Orthop Scand 1988;59(2): 135.

Fig. 1 The slip angle measured according to the calcar femorale method (Hansson et al.)¹. ¹Permission has been obtained to use the figure from Hansson et al. 1988



Primary SCFE

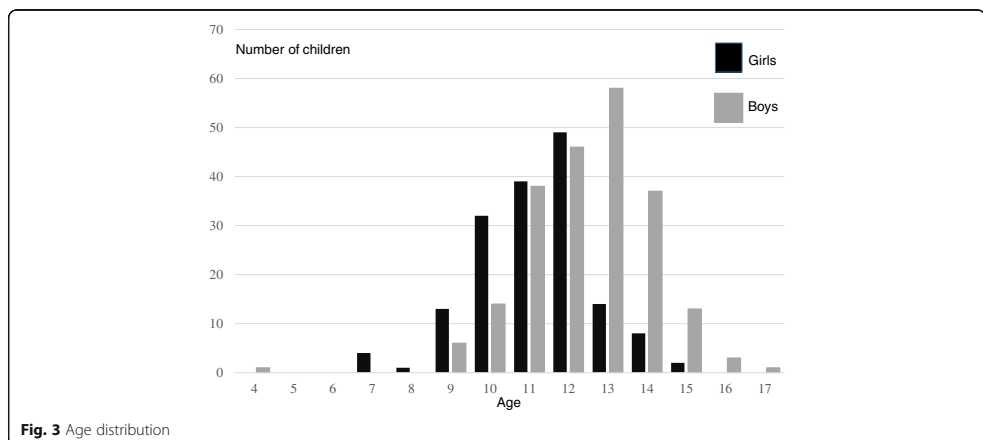
The median age at diagnosis for the 162 girls was 11.7 (7.2–15.4) with a mean of 11.6 years and for the 217 boys, it was 13.0 (3.8–17.7) with a mean of 12.9 years (Fig. 3). The youngest boy (3.8 years old) had a comorbidity of microcephaly together with cerebral palsy.

Age-adjusted body mass index

We obtained data for 131 of the 162 girls and for 176 of the 217 boys i.e. for 81% of the cohort population. For the girls 74 of 131 (56%) and for the boys 133 of 176 (76%) were overweight or obese.

Symptoms and duration (missing data, n = 4)

Most children had hip/groin pain as an initial symptom, but mixed symptoms and knee pain were also frequent. The median duration from onset of symptoms until diagnosis of SCFE was 2 months (0 to 48 months; missing data, n = 5). For the 44 children (15 girls and 29 boys) with knee pain as the main symptom, the median duration was 4 months (0.5 to 18 months) whereas for the 250 children with hip/groin pain as main symptom the median duration was 2 months (0.25 to 48 months). The difference in median duration of symptoms between knee and hip/groin pain as an initial symptom was statistically significant for



the whole population ($p = 0.004$) but when the same analysis was made for boys and girls separately the difference was only statistically significant for boys ($p = 0.004$).

Initial health care provider (missing data, $n = 4$)

Most children (250/379) were initially examined by their general practitioner. Eighty-five children were seen at the emergency care room in a hospital initially. The remaining children were primarily seen in an outpatient setting either by a paediatrician, a physician in school health or by a physiotherapist or a chiropractor/naprapath. For 247 of the 379 children (65%), a hip disorder was suspected with referral for a radiographic hip examination at first presentation to a health care provider. Of the 44 children with knee pain as their main symptom, 12 (27%) were sent for a radiographic hip examination at first consultation. Of the 250 children with hip or groin pain as their main symptom, 180 (72%) were sent for a radiographic hip examination at first consultation. There was a statistically significant difference between the proportion of children with knee pain that were sent for a radiographic hip examination compared with children with hip/groin pain as an initial symptom ($p = 0.033$).

Duration of symptoms and slip severity

The severity of the slip was associated with an increase in median duration of symptoms (Fig. 4).

Of the 89 *severe slips*; 36 were in girls with a median age of 12 (9–15) years, 53 were in boys with a median age of 13 (10–16) years.

Of the 125 *moderate slips*; 66 were in girls with a median age of 12 (8–14) years, 59 were in boys with a median age of 13 (9–16) years. Two slips were in valgus SCFE.

Of the 165 *mild slips*; 60 were in girls with a median age of 11 (7–15) years, 105 were in boys with a median age of 12 (4–17) years. Two slips were in valgus SCFE.

Seasonal variation

The month of onset of symptoms was used to describe the seasonal variation of SCFE (Fig 5). Four children were excluded due to duration of symptom >24 months.

Urban/rural location

One child had a protected residence and two children temporarily resided in an urban area but it was not possible to find any information for their ordinary place of domicile. For 64% of the children an urban area and for 35% a rural area was found for their place of domicile. Using the same definition of rural area, i.e. <5000 inhabitants, according to Statistics Sweden 26% of children (0–19 years old) lived in a rural area during the study period.

Co-morbidity

In Table 2 the associated disorders are listed.

Age adjusted body mass index

Data was available for 81% of the cohort population concerning age-adjusted Body Mass Index. For the boys 76% and for the girls 56% were either obese or had overweight.

Surgical procedure and implants

The implants that were chosen and the surgical procedures performed are presented in Table 3. All mild and moderate slips were treated with a screw or pin fixation. Screws and pins were predominantly inserted using a percutaneous approach. Fixation with an implant permitting

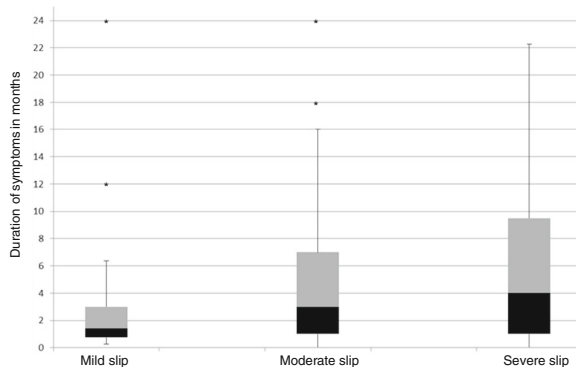
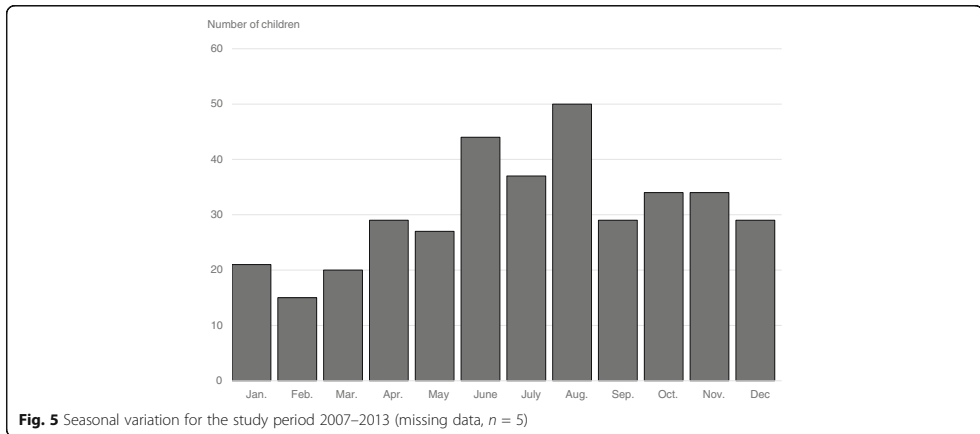


Fig. 4 Severity of the slip in relation to duration of symptoms (missing data, $n = 5$)¹. ¹Outliers with duration of symptoms >24 months: Mild ($n = 1$). Moderate ($n = 1$). Severe ($n = 2$)



further growth of the femoral neck, e.g. Hansson hook pin (Fig. 6) or a screw with an extra short thread length, was used for >90% of the patients for both surgery for the index hip and when prophylactic pinning was performed. Twelve of these percutaneous procedures for the index hip had to be extended to a more invasive surgical approach because of difficulties in finding the correct entry point.

Unstable SCFE

Sixty hips were unstable at surgery: 40 of these were severe, and 20 were mild or moderate slips (one of these was a valgus SCFE). Two of the 60 unstable SCFE had

an open reduction with internal fixation, and three had a capital realignment procedure with a surgical dislocation performed, all with a severe SCFE.

Fifty-five of the 60 unstable slips were treated with internal fixation without open reduction.

For 31 of the 55 unstable slips treated without an open reduction, an intentional closed reduction manoeuvre was also performed. Nine of these had a mild or moderate slip, whereas 22 had a severe slip.

For 7 of the 55 unstable SCFE treated without an open reduction a joint aspiration was performed.

The contralateral hip

The study population is described in Fig. 7. A total of 27 children had bilateral SCFE at initial presentation. Prophylactic fixation was performed in 151 of the remaining 352 children (43%). For the 43 children with a later slip in the contralateral hip we observed a mean interval of 10.8 months between surgery for the index and the contralateral hip. Apart from an outlier with 59.8 months' interval, the second largest interval was 24 months. The child with only a 0.5-month interval had no symptoms but had a lateral view radiograph analysed during the first admission. This child was then re-admitted only after 2 weeks, now with symptoms from the contralateral hip and with a contralateral SCFE diagnosed. Twelve of the 43 contralateral slips were diagnosed more than 1 year after the index slip.

For the 156 children with no contralateral hip affection during the follow-up we had a mean follow-up of 30.6 months and a median of 26.9 months (6.5–93 months). Ninety five children had 24 months or more follow-up for their second hip. Forty six children were followed for their second hip between 12 and 24 months. The 15 children that were followed for their second hip less

Table 2 Co-morbidity

Disorder	Number
Neurocognitive disorder (ADD, ADHD, Autism)	15
Thyroid insufficiency	2
Down's syndrome	2
Other chromosome abnormalities	3
Hypopituitarism	1
Early onset of puberty	1
Late onset of puberty	1
Adrenoleukodystrophy	1
Short stature (treated with growth hormone)	1
Vitamin D deficiency	1
Diabetes mellitus	1
Osteopetrosis	1
Marfan's syndrome	1
Cerebral palsy (with concomitant microcephaly)	1
Embryonal rhabdomyosarcoma (irradiation to pelvic area)	1
Fibrous dysplasia of proximal femur	1

Table 3 Method of treatment related to severity of SCFE

Surgical treatment	Mild	Moderate	Severe	Total
Hansson hook pin	96	71	38	205
Cannulated screw with extra ^a short thread length	58	43	32	133
Cannulated screw with short ^b thread length	10	10	4	24
Multiple cannulated screws (diameter < 6 mm)	–	1	–	1
Multiple pins (diameter < 3 mm)	1	–	2	3
Capital realignment procedure with surgical dislocation of the hip	–	–	8	8
Capital realignment procedure without surgical dislocation of the hip	–	–	3	3
Open reduction and fixation without surgical dislocation of the hip (Parsch)	–	–	2	2
Total	165	125	89	379

^aSpecially designed screws with extra short thread length that will allow further growth of the femoral neck

^bOrdinary short thread length i.e. approximately 16 mm

than 12 months all had a radiographically confirmed closure of the capital physis.

The boy who emigrated did so within 6 weeks after surgery for the index hip. Another boy died 22 months' post index hip surgery.

The median age at surgery for the girls in this group was 11.2 (7.2–15.1) years and for the boys, it was 13.0 (9.5–17.7) years.

Among the 201 children treated without prophylactic surgery 43 (21%) later developed SCFE in the contralateral hip within the follow-up time of 24 months. For the group of 201 children treated without prophylactic surgery, the median age when diagnosed with SCFE in the index hip for the girls was 12.1 (8.4–14.7) years and for the boys it was 13.4 (3.8–16.7) years.

Hospitals

When the study period started in 2007 there were 39 hospitals in Sweden that treated children with SCFE. During the study period, five hospitals changed their treatment protocol and referred children with SCFE for surgical treatment. Between 2007 and 2013 there were 20 hospitals that on average treated >1 child with SCFE per year, four of these on average treated >2 children per year, and three treated on average >3 children per year.

Discussion

To our knowledge, this is the first prospective cohort study that describes the epidemiology for SCFE based on a total national population. It was possible to reach 100% completeness using the definition: the proportion of all children treated for SCFE that were registered in the population covered by the Swedish National Patient Register (NPR). The Swedish NPR database does not allow for the assessment of bilateral disease and cannot discriminate between first-time admission for the treatment of SCFE versus readmission for complications, hardware removal, or contralateral disease.

A thorough retrospective comparison for personal identity numbers registered in NPR with surgery performed for SCFE and the corresponding medical records was made where we found 35 children that were initially not reported but that could be retrospectively included after informed consent was obtained.

The median age at diagnosis was similar to that reported previously from Southern Sweden 1960–1969 [28] and Gothenburg, Sweden, 1946–1992 [12]. During the twentieth century, a gradual decrease in age at onset of SCFE was seen, but this trend has now stopped [57, 58].

In this study, the male-to-female ratio was 1.3:1. Previous reports have shown a ratio with variations from 1.1:1 up to 4.1:1 [1, 2, 23, 25, 28, 33, 34], but the difference between boys and girls has gradually levelled out with time.

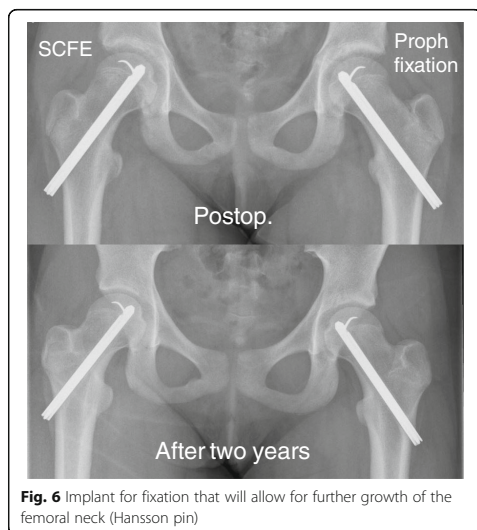
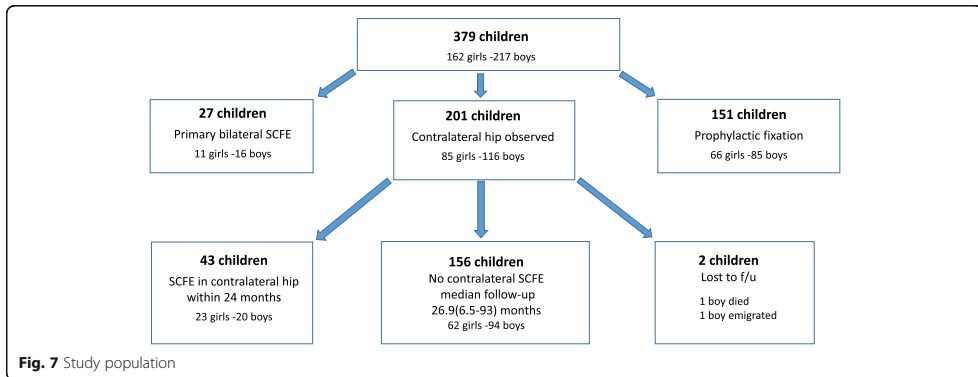


Fig. 6 Implant for fixation that will allow for further growth of the femoral neck (Hansson pin)



We managed to obtain figures for 81% of the cohort population concerning age-adjusted Body Mass Index (BMI). For the boys 76% had overweight or were obese whereas for the girls this was only true for 56%. In a recent population-based study in Sweden it was found that 17% of boys and 18% of girls 15 years old had overweight or were obese [59]. The increase in incidence for SCFE has been proposed in Scotland to be linked to an increase in BMI among children [60]. We had 43% girls in this population-based study for SCFE of the index hip and we believe that overweight or obesity should still be considered as a major characteristic for boys but not necessarily for girls. This will be important information to distribute to all professions who primarily attend children with hip or knee pain.

The average annual incidence calculated in this study was for children that were 9–15 years old in Sweden during the period 2007–2013. It is difficult to compare reports of incidence of SCFE because the disorder is related to ethnicity [1]. Other authors have used different methods to present the incidence rate: (1) attack rate calculated as the sum of annual incidence rate for every age group (7–17 years) over the age group of risk [12], (2) incidence rates for children aged ≥ 9 to ≤ 16 with combined data for 2 years [2], (3) overall incidence for children aged 7–18 years during a 12-year period in relation to the total number of children of those age groups during 1 year in the middle of the study period [61], (4) the total number of surgical procedures for SCFE over 13 years for children between 5 and 19 years related to the average number of boys and girls in that age cohort during the study period [23], (5) annual age-specific incidence rates calculated as the number of new cases of SCFE per 100,000 paediatric population (aged 9–16 years, inclusive) [22] or (6) incidence of the number of patients born in the same year related to the number of births during that year [28]. Despite the various methods used

to calculate incidence, if we compare our data with the incidence previously reported from Southern Sweden [28], 6.1/10000 living born for boys and 3.0/10000 living born for girls, there seems to be an increase in incidence for girls, but not for boys. We have no explanation for this.

The severity of the slip was correlated with the duration of symptoms [14–18]. The 44 children with knee pain as presenting symptom had a 2 months longer median duration of symptoms until diagnosis compared with children having initial hip/groin pain. The children with knee pain also had a lower rate of referral for a radiographic hip examination at the initial health care contact than the children with hip/groin pain [62].

We used the clinical classification according to Loder [49] for the stability of the capital physis because this did not require any new preoperative diagnostic methods to be implemented. When this study was initiated in 2007 this classification was widely accepted [37, 42, 63–67] but there are reports that argue against this classification because even within this group the degree of stability of the physis has been shown to vary [41, 68–72].

There was a minor peak of incidence during our summer (Jun-Aug) and the lowest incidence was found in the winter (Jan-Mar) but the explanation for this remains uncertain [27–30].

Concerning the co-morbidity issue, the most common diagnosis in this study was neuropsychiatric disorders (15 of 379). These children might have a different risk behaviour in recreational activities that could contribute to this situation [73]. All children below 2 years in Sweden are routinely offered supplementary Vitamin D and parents are encouraged to allow their children to be exposed to the sun that might explain our very low number of co-existing Vitamin D deficiency in this cohort.

Most children were treated with a percutaneous method using an implant that will allow further growth of the femoral neck [74]. Only 11 capital realignment procedures were performed in Sweden during 2007–2013 as primary treatment for SCFE in the index hip. There are different treatment protocols for unstable SCFE where an intentional closed reduction manoeuvre was used for 31/55 children, but joint aspiration of the hip in an unstable SCFE with the attempt to further reduce the intracapsular pressure [43, 44, 75] was only used for 5/55.

In the present study, 43% of the contralateral hips had a prophylactic fixation performed. The rationale for a programme where prophylactic fixation is always performed is controversial [76–84] except for children with metabolic or endocrine disorders [6, 9] and for the very young [85, 86]. Most hospitals in Sweden where prophylactic fixation is not routinely performed have a follow-up programme with repeat radiographic examinations of both hips until physal closure of the proximal femur has occurred. The girls who received prophylactic surgery on the contralateral hip were younger (median age 11.2 years) than girls who were scheduled for regular radiographic follow-up (median age 12.1 years). We found no such difference for the boys. Menarche might be used in some hospitals as a cut-off point for the girls after which routine prophylactic fixation is not performed, whereas for the boys there is no such clear pubertal start point.

Loder et al. [87] reported that 80–90% of later SCFE in the contralateral hip developed within 18 months. We chose to follow up 24 months after the index hip was treated. Studies with follow-up into adulthood report the incidence of bilaterality to be as high as 63% [23, 24, 76, 77, 81, 87–94]. We advocate that all children, who have not undergone prophylactic surgery, should be scheduled for regular radiographic follow-up until closure of the capital physis.

The number of hospitals in Sweden treating SCFE has decreased from 39 to 34 since January 2007. Only three hospitals treat on average > 3 children per year for SCFE in the index hip. Sweden has areas that are not so densely populated and a referral to an orthopaedic centre with more experience of surgical treatment in paediatric orthopaedics might not be appropriate for all children with a stable mild or moderate SCFE. Continuous education will be of utmost importance for surgeons in hospitals that annually receive a low volume of children with SCFE. Probably children with a severe and/or unstable SCFE should be considered for a referral to a paediatric orthopaedic centre.

Limitations

The children included in this study were followed for 24 months for any contralateral slip, but not all were followed until closure of the capital physis. A small

number of hospitals followed their paediatric patients with regular radiographs routinely for only 12 months postoperatively, thus the true incidence of bilateral involvement might have been slightly underestimated.

In the analysis for the duration of symptoms in months, we were not able to separate the duration of patient's delay versus doctor's delay.

For the analysis of initial health care provider and the rate of referral for a diagnostic hip examination, we were not able to collect all medical records from outpatient visits prior to the primary surgery for SCFE at various health care providers. We used the history that was presented on hospital admission for primary surgery for SCFE.

Children in this cohort study might have had their surgery for SCFE in the index hip performed abroad during a vacation. They have therefore not automatically been included in this study. To our knowledge, only one child with a Swedish personal identity number during the study period was followed up in Sweden after such an event. There were no children treated for their second hip during the study period where the index hip had been treated before the family immigrated to Sweden. Families with children prone to develop SCFE might have emigrated during the study period, but only one child with SCFE in the index hip during the study period emigrated during the follow-up of 24 months for a contralateral slip.

Conclusion

The average annual incidence of SCFE was 4.4 per 10,000 girls and 5.7 per 10,000 boys 9–15 years old. Most children were treated with percutaneous pin or screw fixation with an implant that would allow further growth of the femoral neck. Prophylactic fixation of the contralateral hip was performed in 43% of the children. Overweight or obesity is one major characteristic for boys with SCFE but to a less extent for girls. Knee pain as initial symptom cause a delay in diagnosis.

We recommend that all hospitals, where prophylactic surgery is not advocated for the contralateral hip, should implement a programme that includes regular radiographic follow-up until the closure of the proximal femoral physis has been verified. The number of hospitals that perform surgery for SCFE has been reduced, but still most of the hospitals in Sweden treat less than two children per year.

Abbreviations

AP: Anteroposterior

Acknowledgements

The Academy for Health and Care, Jonkoping County Council, Sweden for financial support to this study. Elin Sward, MD, for her work to compile data for duration of symptoms and initial health care provider. Bo Rolander, PhD, statistician, Futurum Academy for Health and Care Jonkoping County Council for assistance with statistical analysis. Mats E Nilsson, PhD, statistician and epidemiologist, Futurum Academy for Health and Care Jonkoping County Council for advice on study design and statistical analysis.

Availability of data and materials

The datasets used and/or analysed during the current study are available from the corresponding author on reasonable request.

Authors' contributions

BH has, in close cooperation with GH, designed the study, has been responsible for all collection of data together with the corresponding analysis and interpretation of all data, has drafted the manuscript and has given final approval of the version to be published. MS has given substantial contribution to the analysis and interpretation of data, has been involved in revising the manuscript and has given final approval of the version to be published. LV has given substantial contribution to the analysis and interpretation of data, has been involved in revising the manuscript and has given final approval of the version to be published. GH has made substantial contribution to the concept and design of this study together with giving substantial contribution to the analysis and interpretation of data, has been involved in revising the manuscript and has given final approval of the version to be published.

Ethics approval and consent to participate

Ethical approval for the study was authorized by the Regional Ethical Review Board in Lund, Sweden with registration numbers 2013/87 and 2015/320. The study was in accordance with the ethical principles of the 1964 Declaration of Helsinki for medical research involving humans and its later amendments. Informed consent was obtained from all individual participants included in the study and one parent or guardian.

Consent for publication

No individual person's data is used.

Competing interests

The authors declare that they have no competing interests.

Publisher's Note

Springer Nature remains neutral with regard to jurisdictional claims in published maps and institutional affiliations.

Author details

¹Department of Clinical Sciences Lund, Orthopaedics Department of Orthopaedics, Ryhov county hospital, Lund University, SE-551 85 Jonkoping, Sweden. ²Futurum Academy for Health and Care Jonkoping County Council, Department of Paediatrics, Ryhov county hospital, SE-551 85 Jonkoping, Sweden. ³Faculty of Medicine and Health Sciences, Linkoping university, SE-581 83 Linkoping, Sweden. ⁴Department of Clinical Sciences, Lund, Orthopaedics, Lund University, Box 117, SE-221 00 Lund, Sweden.

Received: 18 January 2017 Accepted: 10 July 2017

Published online: 18 July 2017

References

- Loder RT. The demographics of slipped capital femoral epiphysis. An international multicenter study. *Clin Orthop Relat Res.* 1996;322:8–27.
- Lehmann CL, Arons RR, Loder RT, Vitale MG. The epidemiology of slipped capital femoral epiphysis: an update. *J Pediatr Orthop.* 2006;26(3):286–90.
- Galbraith RT, Gelberman RH, Hajek PC, Baker LA, Sartoris DJ, Rab GT, Cohen MS, Griffin PP. Obesity and decreased femoral anteverision in adolescence. *J Orthop Res.* 1987;5(4):523–8.
- Gelberman RH, Cohen MS, Shaw BA, Kasser JR, Griffin PP, Wilkinson RH. The association of femoral retroversion with slipped capital femoral epiphysis. *J Bone Joint Surg Am.* 1986;68(7):1000–7.
- Pritchett JW, Perdue KD. Mechanical factors in slipped capital femoral epiphysis. *J Pediatr Orthop.* 1988;8(4):385–8.
- Loder RT, Wittenberg B, DeSilva G. Slipped capital femoral epiphysis associated with endocrine disorders. *J Pediatr Orthop.* 1995;15(3):349–56.
- Wells D, King JD, Roe TF, Kaufman FR. Review of slipped capital femoral epiphysis associated with endocrine disease. *J Pediatr Orthop.* 1993;13(5):610–4.
- Wilcox PG, Weiner DS, Leighley B. Maturation factors in slipped capital femoral epiphysis. *J Pediatr Orthop.* 1988;8(2):196–200.
- Loder RT, Hensinger RN. Slipped capital femoral epiphysis associated with renal failure osteodystrophy. *J Pediatr Orthop.* 1997;17(2):205–11.
- Loder RT, Hensinger RN, Alburger PD, Aronsson DD, Beaty JH, Roy DR, Stanton RP, Turker R. Slipped capital femoral epiphysis associated with radiation therapy. *J Pediatr Orthop.* 1998;18(5):630–6.
- Libshitz HI, Edeiken BS. Radiotherapy changes of the pediatric hip. *AJR Am J Roentgenol.* 1981;137(3):585–8.
- Jerre R. Physioliysis of the hip : epidemiology, diagnosis and long-term follow-up. Göteborg; 1995.
- Loder RT. Unstable slipped capital femoral epiphysis. *J Pediatr Orthop.* 2001;21(5):694–9.
- Carney BT, Weinstein SL, Noble J. Long-term follow-up of slipped capital femoral epiphysis. *J Bone Joint Surg Am.* 1991;73(5):667–74.
- Carney BT, Weinstein SL. Natural history of untreated chronic slipped capital femoral epiphysis. *Clin Orthop Relat Res.* 1996;322:43–7.
- Jerre R, Karlsson J, Romanus B, Wallin J. Does a single device prevent further slipping of the epiphysis in children with slipped capital femoral epiphysis? *Arch Orthop Trauma Surg.* 1997;116(6–7):348–51.
- Loder RT, Starnes T, Dikos G, Aronsson DD. Demographic predictors of severity of stable slipped capital femoral epiphyses. *J Bone Joint Surg Am.* 2006;88(1):97–105.
- Kocher MS, Bishop JA, Weed B, Hresko MT, Millis MB, Kim YJ, Kasser JR. Delay in diagnosis of slipped capital femoral epiphysis. *Pediatrics.* 2004; 113(4):e322–5.
- Schur MD, Andras LM, Broom AM, Barrett KK, Bowman CA, Luther H, Goldstein RY, Fletcher ND, Millis MB, Runner R, et al. Continuing Delay in the Diagnosis of Slipped Capital Femoral Epiphysis. *J Pediatr.* 2016;
- Ordeberg G, Hansson LI, Sandstrom S. Slipped capital femoral epiphysis in southern Sweden. Long-term result with closed reduction and hip plaster spica. *Clin Orthop Relat Res.* 1987;220:148–54.
- Jerre R, Billing L, Karlsson J. Loss of hip motion in slipped capital femoral epiphysis: a calculation from the slipping angle and the slope. *J Pediatr Orthop B.* 1996;5(3):144–50.
- Larson AN, Yu EM, Melton LJ 3rd, Peterson HA, Stans AA. Incidence of slipped capital femoral epiphysis: a population-based study. *J Pediatr Orthop B.* 2010;19(1):9–12.
- Witbreuk MM, van Royen BJ, Van Kemenaede FJ, Witte BI, van der Sluijs JA. Incidence and gender differences of slipped capital femoral epiphysis in the Netherlands from 1998–2010 combined with a review of the literature on the epidemiology of SCFE. *J Child Orthop.* 2013;7(2):99–105.
- Loder RT, Aronson DD, Greenfield ML. The epidemiology of bilateral slipped capital femoral epiphysis. A study of children in Michigan. *J Bone Joint Surg Am.* 1993;75(8):1141–7.
- Song KS, Oh CW, Lee HJ, Kim SD. Multicenter Study Committee of the Korean Pediatric Orthopedic S: Epidemiology and demographics of slipped capital femoral epiphysis in Korea: a multicenter study by the Korean Pediatric Orthopedic Society. *J Pediatr Orthop.* 2009;29(7):683–6.
- Lim YJ, Kagda F, Lam KS, Hui JH, Lim KB, Mahadev A, Lee EH. Demographics and clinical presentation of slipped capital femoral epiphysis in Singapore: comparing the East with the West. *J Pediatr Orthop B.* 2008;17(6):289–92.
- Andren L, Borgstrom KE. Seasonal variation of epiphysiolysis of the hip and possibility of causal factor. *Acta Orthop Scand.* 1958;28(1):22–6.
- Hagglund G, Hansson LI, Ordeberg G. Epidemiology of slipped capital femoral epiphysis in southern Sweden. *Clin Orthop Relat Res.* 1984;191:82–94.
- Loder RT, Aronson DD, Bollinger RO. Seasonal variation of slipped capital femoral epiphysis. *J Bone Joint Surg Am.* 1990;72(3):378–81.
- Loder RT. A worldwide study on the seasonal variation of slipped capital femoral epiphysis. *Clin Orthop Relat Res.* 1996;322:28–36.
- Brown D. Seasonal variation of slipped capital femoral epiphysis in the United States. *J Pediatr Orthop.* 2004;24(2):139–43.
- Maffulli N, Douglas AS. Seasonal variation of slipped capital femoral epiphysis. *J Pediatr Orthop B.* 2002;11(1):29–33.
- Jerre R, Karlsson J, Henrikson B. The incidence of physioliysis of the hip: a population-based study of 175 patients. *Acta Orthop Scand.* 1996;67(1):53–6.
- Kelsey JL, Keggi KJ, Southwick WO. The incidence and distribution of slipped capital femoral epiphysis in Connecticut and Southwestern United States. *J Bone Joint Surg Am.* 1970;52(6):1203–16.
- Peterson MD, Weiner DS, Green NE, Terry CL. Acute slipped capital femoral epiphysis: the value and safety of urgent manipulative reduction. *J Pediatr Orthop.* 1997;17(5):648–54.
- Tokmakova KP, Stanton RP, Mason DE. Factors influencing the development of osteonecrosis in patients treated for slipped capital femoral epiphysis. *J Bone Joint Surg Am.* 2003;85-A(5):798–801.

37. Palocaren T, Holmes L, Rogers K, Kumar SJ. Outcome of in situ pinning in patients with unstable slipped capital femoral epiphysis: assessment of risk factors associated with avascular necrosis. *J Pediatr Orthop*. 2010;30(1):31–6.
38. Rattey T, Piehl F, Wright JG. Acute slipped capital femoral epiphysis. Review of outcomes and rates of avascular necrosis. *J Bone Joint Surg Am*. 1996; 78(3):398–402.
39. Ziebarth K, Zilkens C, Spencer S, Leunig M, Ganz R, Kim YJ. Capital realignment for moderate and severe SCFE using a modified Dunn procedure. *Clin Orthop Relat Res*. 2009;467(3):704–16.
40. Ganz R, Gill TJ, Gautier E, Ganz K, Krugel N, Berlemann U. Surgical dislocation of the adult hip a technique with full access to the femoral head and acetabulum without the risk of avascular necrosis. *The Journal of bone and joint surgery British*. 2001;83(8):1119–24.
41. Slongo T, Kakaty D, Krause F, Ziebarth K. Treatment of slipped capital femoral epiphysis with a modified Dunn procedure. *J Bone Joint Surg Am*. 2010;92(18):2898–908.
42. Parsch K, Weller S, Parsch D. Open reduction and smooth Kirschner wire fixation for unstable slipped capital femoral epiphysis. *J Pediatr Orthop*. 2009;29(1):1–8.
43. Beck M, Siebenrock KA, Affolter B, Notzli H, Parvizi J, Ganz R. Increased intraarticular pressure reduces blood flow to the femoral head. *Clin Orthop Relat Res*. 2004;424:149–52.
44. Herrera-Soto JA, Duffy MF, Birnbaum MA, Vander Have KL. Increased intracapsular pressures after unstable slipped capital femoral epiphysis. *J Pediatr Orthop*. 2008;28(7):723–8.
45. Karlberg J, Luo ZC, Albertsson-Wikland K. Body mass index reference values (mean and SD) for Swedish children. *Acta Paediatr*. 2001;90(12):1427–34.
46. Hansson LI, Hagglund G, Ordeberg G, Sandstrom S. The calcare femorale as a landmark in hip physiolyis. *Acta Orthop Scand*. 1988;59(2):134–8.
47. Billing L, Bogren HG, Wallin J. Reliable X-ray diagnosis of slipped capital femoral epiphysis by combining the conventional and a new simplified geometrical method. *Pediatr Radiol*. 2002;32(6):423–30.
48. Billing L. Roentgen examination of the proximal femur end in children and adolescents; a standardized technique also suitable for determination of the collum-, anteversion-, and epiphyseal angles; a study of slipped epiphysis and coxa plana. *Acta Radiol Suppl*. 1954;110:1–80.
49. Loder RT, Richards BS, Shapiro PS, Reznick LR, Aronson DD. Acute slipped capital femoral epiphysis: the importance of physical stability. *J Bone Joint Surg Am*. 1993;75(8):1134–40.
50. Southwick WO. Osteotomy through the lesser trochanter for slipped capital femoral epiphysis. *J Bone Joint Surg Am*. 1967;49(5):807–35.
51. Klein A, Joplin RJ, Reidy JA, Hanelin J. Slipped capital femoral epiphysis; early diagnosis and treatment facilitated by normal roentgenograms. *J Bone Joint Surg Am*. 1952;34-A(1):233–9.
52. Green DW, Mogeckwu N, Scher DM, Handler S, Chalmers P, Widmann RF. A modification of Klein's Line to improve sensitivity of the anterior-posterior radiograph in slipped capital femoral epiphysis. *J Pediatr Orthop*. 2009;29(5):449–53.
53. Hansson G, Billing L, Hogstedt B, Jerre R, Wallin J. Long-term results after nailing in situ of slipped upper femoral epiphysis. A 30-year follow-up of 59 hips. *The Journal of bone and joint surgery British*. 1998;80(1):70–7.
54. Bellemore JM, Carpenter EC, Yu NY, Birke O, Little DG. Biomechanics of Slipped Capital Femoral Epiphysis: Evaluation of the Posterior Sloping Angle. *J Pediatr Orthop*. 2016;36(6):651–5.
55. Shank CF, Thiel EJ, Klingele KE. Valgus slipped capital femoral epiphysis: prevalence, presentation, and treatment options. *J Pediatr Orthop*. 2010; 30(2):140–6.
56. Loder RT, O'Donnell PW, Didelot WP, Kayes KJ. Valgus slipped capital femoral epiphysis. *J Pediatr Orthop*. 2006;26(5):594–600.
57. Hagglund G, Hansson LI, Ordeberg G, Sandstrom S. Slipped capital femoral epiphysis in southern Sweden. Long-term results after femoral neck osteotomy. *Clinical orthopaedics and related research*. 1986;210:152–9.
58. Loder RT, Skopelja EN. The epidemiology and demographics of slipped capital femoral epiphysis. *ISRN Orthop*. 2011;2011:486512.
59. Fahraeus C, Wendt LK, Nilsson M, Isaksson H, Alm A, Andersson-Gare B. Overweight and obesity in twenty-year-old Swedes in relation to birthweight and weight development during childhood. *Acta Paediatr*. 2012;101(6):637–42.
60. Murray AW, Wilson NI. Changing incidence of slipped capital femoral epiphysis: a relationship with obesity? *The Journal of bone and joint surgery British*. 2008;90(1):92–4.
61. Benson EC, Miller M, Bosch P, Szalay EA. A new look at the incidence of slipped capital femoral epiphysis in new Mexico. *J Pediatr Orthop*. 2008; 28(5):529–33.
62. Matava MJ, Patton CM, Luhmann S, Gordon JE, Schoenecker PL. Knee pain as the initial symptom of slipped capital femoral epiphysis: an analysis of initial presentation and treatment. *J Pediatr Orthop*. 1999;19(4):455–60.
63. Gholve PA, Cameron DB, Millis MB. Slipped capital femoral epiphysis update. *Curr Opin Pediatr*. 2009;21(1):39–45.
64. Zaltz I, Baca G, Clohisey JC. Unstable SCFE: review of treatment modalities and prevalence of osteonecrosis. *Clin Orthop Relat Res*. 2013;471(7):2192–8.
65. Mulgrew E, Wells-Cole S, Ali F, Joshy S, Siddique I, Zenios M. Single screw fixation in stable and unstable slipped upper femoral epiphysis. *J Pediatr Orthop B*. 2011;20(3):147–51.
66. Alves C, Steele M, Narayanan U, Howard A, Alman B, Wright JG. Open reduction and internal fixation of unstable slipped capital femoral epiphysis by means of surgical dislocation does not decrease the rate of avascular necrosis: a preliminary study. *J Child Orthop*. 2012;6(4):277–83.
67. Jackson JB, 3rd, Frick SL, Brighton BK, Broadwell SR, Wang EA, Casey VF. Restoration of Blood Flow to the Proximal Femoral Epiphysis in Unstable Slipped Capital Femoral Epiphysis by Modified Dunn Procedure: A Preliminary Angiographic and Intracranial Pressure Monitoring Study. *J Pediatr Orthop* 2016.
68. Lykissas MG, McCarthy JJ. Should all unstable slipped capital femoral epiphysis be treated open? *J Pediatr Orthop*. 2013;33(Suppl 1):S92–8.
69. Ziebarth K, Domayer S, Slongo T, Kim YJ, Ganz R. Clinical stability of slipped capital femoral epiphysis does not correlate with intraoperative stability. *Clin Orthop Relat Res*. 2012;470(8):2274–9.
70. Huber H, Dora C, Ramseier LE, Buck F, Dierauer S. Adolescent slipped capital femoral epiphysis treated by a modified Dunn osteotomy with surgical hip dislocation. *The Journal of bone and joint surgery British*. 2011;93(6):833–8.
71. Kallio PE, Mah ET, Foster BK, Paterson DC, LeQuesne GW. Slipped capital femoral epiphysis. Incidence and clinical assessment of physical instability. *The Journal of bone and joint surgery British*. 1995;77(5):752–5.
72. Tins B, Cassar-Pullicino V, McCall I. The role of pre-treatment MRI in established cases of slipped capital femoral epiphysis. *Eur J Radiol*. 2009;70(3):570–8.
73. Kroonen LT, Herman M, Pizzutillo PD, Macewen GD. Prader-Willi Syndrome: clinical concerns for the orthopaedic surgeon. *J Pediatr Orthop*. 2006;26(5):673–9.
74. Ortgren J, Bjorklund-Sand L, Engbom M, Tiderius CJ. Continued Growth of the Femoral Neck Leads to Improved Remodeling After In Situ Fixation of Slipped Capital Femoral Epiphysis. *J Pediatr Orthop* 2016.
75. Kobayakawa M, Rydholm U, Wingstrand H, Pettersson H, Lidgren L. Femoral head necrosis in juvenile chronic arthritis. *Acta Orthop Scand*. 1989;60(2):164–9.
76. Jerre R, Billing L, Hansson G, Wallin J. The contralateral hip in patients primarily treated for unilateral slipped upper femoral epiphysis. Long-term follow-up of 61 hips. *The Journal of bone and joint surgery British*. 1994;76(4):563–7.
77. Castro FP Jr, Bennett JT, Douzens K. Epidemiological perspective on prophylactic pinning in patients with unilateral slipped capital femoral epiphysis. *J Pediatr Orthop*. 2000;20(6):745–8.
78. Dewnany G, Radford P. Prophylactic contralateral fixation in slipped upper femoral epiphysis: is it safe? *J Pediatr Orthop B*. 2005;14(6):429–33.
79. Clement ND, Vats A, Duckworth AD, Gaston MS, Murray AW. Slipped capital femoral epiphysis: is it worth the risk and cost not to offer prophylactic fixation of the contralateral hip? *The bone & joint journal*. 2015;97-B(10):1428–34.
80. Sankar WN, Novais EN, Lee C, Al-Omari AA, Choi PD, Shore BJ. What are the risks of prophylactic pinning to prevent contralateral slipped capital femoral epiphysis? *Clin Orthop Relat Res*. 2013;471(7):2118–23.
81. Hagglund G. The contralateral hip in slipped capital femoral epiphysis. *J Pediatr Orthop B*. 1996;5(3):158–61.
82. Woelfle JV, Fraitzl CR, Reichel H, Nelitz M. The asymptomatic contralateral hip in unilateral slipped capital femoral epiphysis: morbidity of prophylactic fixation. *J Pediatr Orthop B*. 2012;21(3):226–9.
83. Hansson G, Nathorst-Westfelt J. Management of the contralateral hip in patients with unilateral slipped upper femoral epiphysis: to fix or not to fix—consequences of two strategies. *The Journal of bone and joint surgery British*. 2012;94(5):596–602.
84. Bhattacharjee A, Freeman R, Roberts AP, Kiely NT. Outcome of the unaffected contralateral hip in unilateral slipped capital femoral epiphysis: a report comparing prophylactic fixation with observation. *J Pediatr Orthop B*. 2016;25(5):454–8.
85. Riad J, Bajelidze G, Gabos PG. Bilateral slipped capital femoral epiphysis: predictive factors for contralateral slip. *J Pediatr Orthop*. 2007;27(4):411–4.

86. Stasikelis PJ, Sullivan CM, Phillips WA, Polard JA. Slipped capital femoral epiphysis. Prediction of contralateral involvement. *J Bone Joint Surg Am.* 1996;78(8):1149–55.
87. Loder RT, Aronsson DD, Weinstein SL, Breur GJ, Ganz R, Leunig M. Slipped capital femoral epiphysis. *Instr Course Lect.* 2008;57:473–98.
88. Hagglund G, Hansson LI, Ordeberg G, Sandstrom S. Bilaterality in slipped upper femoral epiphysis. *The Journal of bone and joint surgery British.* 1988;70(2):179–81.
89. Jerre R, Billing L, Hansson G, Karlsson J, Wallin J. Bilaterality in slipped capital femoral epiphysis: importance of a reliable radiographic method. *J Pediatr Orthop B.* 1996;5(2):80–4.
90. Kocher MS, Bishop JA, Hresko MT, Millis MB, Kim YJ, Kasser JR. Prophylactic pinning of the contralateral hip after unilateral slipped capital femoral epiphysis. *J Bone Joint Surg Am.* 2004;86-A(12):2658–65.
91. Lehmann TG, Engesaeter IO, Laborie LB, Rosendahl K, Lie SA, Engesaeter LB. In situ fixation of slipped capital femoral epiphysis with Steinmann pins. *Acta Orthop.* 2011;82(3):333–8.
92. Schultz WR, Weinstein JN, Weinstein SL, Smith BG. Prophylactic pinning of the contralateral hip in slipped capital femoral epiphysis : evaluation of long-term outcome for the contralateral hip with use of decision analysis. *J Bone Joint Surg Am.* 2002;84-A(8):1305–14.
93. Wensaas A, Svenningsen S, Terjesen T. Long-term outcome of slipped capital femoral epiphysis: a 38-year follow-up of 66 patients. *J Child Orthop.* 2011;5(2):75–82.
94. Yildirim Y, Bautista S, Davidson RS. Chondrolysis, osteonecrosis, and slip severity in patients with subsequent contralateral slipped capital femoral epiphysis. *J Bone Joint Surg Am.* 2008;90(3):485–92.

Submit your next manuscript to BioMed Central
and we will help you at every step:

- We accept pre-submission inquiries
- Our selector tool helps you to find the most relevant journal
- We provide round the clock customer support
- Convenient online submission
- Thorough peer review
- Inclusion in PubMed and all major indexing services
- Maximum visibility for your research

Submit your manuscript at
www.biomedcentral.com/submit



Paper II



RESEARCH

Open Access



Barnhöft: a hip specific 6-item questionnaire for children

Bengt Herngren^{1,2*} , Margaretha Stenmarker^{3,4} and Karin Enskär⁵

Abstract

Background: Health-related quality of life instruments, both general and more disease specific, would ideally be included in the evaluation of outcome in paediatric orthopaedics. The aim of this study was to translate and culturally adapt an instrument measuring hip function and pain for Swedish children 8-15 years old with a hip disorder.

Methods: Translation of an established questionnaire for hip disorder in children, CHOHES, was performed and called Barnhöft. Retrospective and cognitive debriefing interviews were conducted with 15 healthy children to test for the comprehensibility of the instrument. Children with slipped capital femoral epiphysis ($n = 25$) and healthy children ($n = 35$) participated in further testing through test-retest and with the comparison of answers given in a general health-related quality of life test, EQ-5D-Y (www.euroqol.org). A multi-professional expert committee supervised the process and judged the content validity.

Results: The test-retest method with a weighted Cohen's kappa showed a good stability of the instrument. The construct validity for the pain domain (1-item) in EQ-5D-Y compared to the pain domain in Barnhöft showed a Spearman's correlation coefficient of 0.73. The degree of hip pain in Barnhöft was also compared with the item "doing usual activities" in EQ-5D-Y with a Spearman's correlation coefficient of 0.67.

Conclusion: Barnhöft could be used as a simple 6-item questionnaire to identify children with pain and/or functional limitations due to sequelae related to a hip disease in childhood.

Keywords: Questionnaire, Children, Hip disease, Health status, Quality of life

Background

Children with disorders affecting the hip are primarily seen by school health personnel, physiotherapists, paediatricians or paediatric orthopaedic surgeons. Limp, reduced range of motion together with pain are often found during the clinical assessment. Our knowledge about the natural history for disorders like slipped capital femoral epiphysis (SCFE), Perthe's disease and developmental dysplasia of the hip (DDH) together with long-term outcome after treatment has increased a lot during the last 50 years even though the aetiology has

remained unclear [1–3]. The evaluation of treatment in paediatric orthopaedics has usually focused on assessment of morbidity based on clinical examination and radiographic outcome. However, outcome focusing on the impact of a disease on everyday life may be as important as the clinical findings and the radiographic appearance. The concept of health-related quality of life (HRQOL) is multidimensional and the goal is to capture the individual sense of well-being including physical, psychological, social, emotional and behavioural aspects [4]. To be able to more thoroughly evaluate surgical and/or medical treatment offered to children with hip specific disorders there is a need for data with both general and more disease specific health-related quality of life instruments to include various aspects of the impact of the disease [5].

* Correspondence: bengt.herngren@med.lu.se

¹Department of Clinical Sciences, Lund, Orthopaedics, Lund University, SE-221 00 Lund, Sweden

²Futurum Academy for Health and Care Jonkoping County Council, Department of Orthopaedics, Ryhov county hospital, SE-551 85 Jonkoping, Sweden

Full list of author information is available at the end of the article



© The Author(s). 2017 **Open Access** This article is distributed under the terms of the Creative Commons Attribution 4.0 International License (<http://creativecommons.org/licenses/by/4.0/>), which permits unrestricted use, distribution, and reproduction in any medium, provided you give appropriate credit to the original author(s) and the source, provide a link to the Creative Commons license, and indicate if changes were made.

In the literature, only one hip specific questionnaire has been validated for children [6] although several scores, designed and validated for adults, have been used in publications also for the paediatric population. The Children's Hospital Oakland Hip Evaluation Scale (CHOHES), originally developed by Aguilar et al. in Oakland, California [7], was found to be suitable for our purpose. It was primarily designed for hip function evaluation in children with sickle-cell disease with the development of avascular necrosis of the femoral head due to the disease. The score was developed based on the Harris Hip Score for adults [8]. It was validated to use for children from 8 years of age and shown to have both good reliability and validity. The questionnaire has later also been used in England, UK, for the evaluation of hip function in children with osteonecrosis of the femoral head secondary to treatment for developmental dysplasia of the hip [9].

The aim of this study was to establish an instrument in Swedish for children 8-15 years old measuring hip function and pain in children diagnosed with a hip disorder based on the work of Aguilar et al. [7]. A cultural adaptation process together with tests for reliability and validity would then be required and the instrument possible to send by mail.

Methods

Study participants

Healthy children (i.e. children without any known hip disorder) and children with SCFE participated in the procedure of cultural adaptation and validation. We chose 35 healthy children, 8-15 years old, for this study through organisations offering various weekly organized sport activities within the city of Jonköping, Sweden. Both the children and at least one parent/guardian gave their informed consent to participate.

The original developer of the instrument used 26 children with a hip disorder [7]. We chose the same number of healthy children where all but one accepted to participate. Twenty-five children, 8-15 years old, with a hip disorder were included through their consecutive registration to a Swedish national quality register for children with SCFE with surgery performed during 2011 for the index hip. A majority of Swedish hospitals treat less than two children with SCFE per year [10]. Children with SCFE in Sweden have, apart from a larger proportion of overweight and obesity, no other known comorbidities compared to a normal Swedish paediatric population [10]. We therefore for practical reasons accepted to include only healthy children in the cognitive debriefing interviews.

Psychometric instruments

EQ-5D-Y [11] was used as a general instrument for HRQOL. The choice of instrument was based on a

clinical interview study of a non-selected Swedish paediatric population with similar age groups that would be possible to use for comparison [12]. Our aim was to send the questionnaires by mail with the intention of using a general health questionnaire that did not have a disproportionately larger number of items than the CHOHEs-instrument i.e. with the consequent risk of a lower response rate. Permission was obtained from the Eurocol group (www.eurocol.org) to use the Swedish version in this study.

EQ-5D-VAS records the respondent's self-rated health on a 20-cm vertical, visual analogue scale with endpoints labelled 'the best health you can imagine' and 'the worst health you can imagine' (0-100 where 100 is the best health). The EQ-5D-VAS [13] refer to the actual situation on that very day the instrument is answered. This information can be used as a quantitative measure of health as judged by the individual respondents.

The CHOHEs [7] is a 100-point, 27-item questionnaire that can be divided into 3 domains: pain, function and physical examination. The pain domain (1-item) together with the hip function domain (5-items) was used in this study. The pain scale consists of a rating for each hip with a maximum of 40 points. The function domain is based on daily activities including dressing, sitting, walking and stair climbing. This portion of the scale is scored from 0 to 32 points. We had to exclude a demonstration by the child of functional ring sitting, step height and ambulation, with the intention of using the CHOHEs through mailed questionnaires. Separate written child and parental instructions were distributed. CHOHEs also includes a part with evaluation by physical examination however this was not used in our study.

Procedure of translation, cultural adaptation and validation

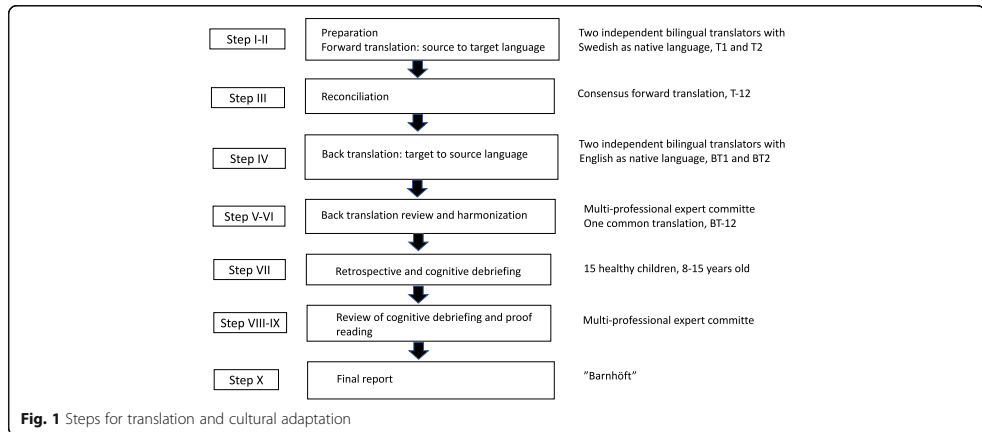
The development of the Swedish version of the CHOHEs, called "Barnhöft", was performed based on the ISPOR TCA task force principles of good practice for translation and cultural adaptation for PRO [14], (Fig. 1).

Step 1. Preparation. Project manager together with in-country persons in close cooperation with and after approval by the original developer to utilise their instrument.

Step 2. Forward translation. Both translators were aware of the concepts being examined in the questionnaire and professionally had long experience working with a Swedish paediatric population.

Step 3. Reconciliation. This was made by the project manager, the key in-country person and both translators.

Step 4. Back translation. We chose a conceptual style. Both translators were blinded for the original English version of CHOHEs as well as for the two different forward translations. They both had a professional experience from the medical field.



Step 5. Back translation review. Project manager together with the key in-country person based upon both the consensus version (BT12) made by the two translators and each individual back translation (BT1 and BT2).

Step 6. Harmonization. A multi-professional expert committee was established with a methodologist (project manager), health professionals with experience from a paediatric population, a language professional together with the translators (T1, T2, BT1 and BT2 in Fig. 1). The expert committee analysed all steps in the translation process. Decisions were made concerning semantic, idiomatic and conceptual equivalence [15]. *Face validity*, i.e. the degree to which the items of an instrument indeed looks as though they are an adequate reflection of the construct to be measured [16], was also implemented during this assessment. After consolidation of all the versions the committee developed a pre-final version of CHOHES for field testing, called the 1st version of "Barnhöft".

Step 7. Retrospective and cognitive debriefing. During the test of the pre-final version we used *retrospective debriefing interviews* [17] as a qualitative method to test for understanding. This was accomplished with the assistance of 15 healthy children, 8-15 years old boys and girls with Swedish as their native language, together with two trained researchers present. After the completion of the questionnaire the interviewer checked for missing data or other problems. Then the interviewer asked if there were any items that were difficult to understand, irrelevant or offensive and if the child had any other comments to make in general. The questionnaire was adjusted accordingly and thereafter again approved by the expert committee as the 2nd version of "Barnhöft".

Cognitive debriefing interviews [17] were then used with an interval of 3 months with the same group of 15 healthy children. They filled out the 2nd version

of "Barnhöft". To ensure that the meaning of the translation was equivalent to the source a debriefing process was performed individually. On an item-by-item basis each participant was asked to express the item in his or her own words which also provided interpretations for items that were problematic in translation. Emphasis was put on identification of any areas of concern in the instrument: There were no new items developed.

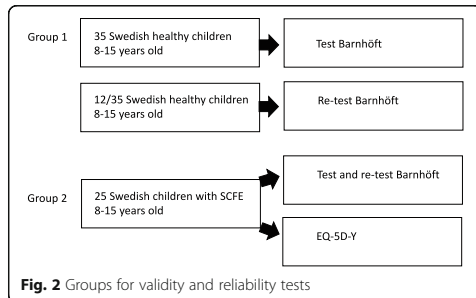
The questionnaire was then again adjusted accordingly.

Step 8 and 9. Review of cognitive debriefing and proof reading. This was made by the expert committee to assure cultural relevance. To ensure a last quality control step the original developer of the instrument participated in a meeting with the key in-country person where the whole translation and cultural adaptation process was evaluated.

Step 10. Final report. The expert committee established the final version of Barnhöft.

Further testing

Further testing of the final version of Barnhöft was then made with both healthy children and children with a hip disease (Fig. 2). We used a time interval of 3 months before the instrument was again presented to the children for this further testing period. In *Group one*, 10/35 were selected among the same children that were initially involved in the debriefing procedures. The reason for this selection was to utilize the positive experience of participation from the first group of children in order to minimize any difficulties to recruit another 25 healthy children. We had no children that refused to participate. For the test of the stability of the instrument, i.e. the test



and re-test method, we chose 12 randomly selected children from the group of 35 healthy children.

The test and re-test method was used to evaluate the stability of the questionnaire [18] and with an equal interval of 6 weeks between the first and the second test in both groups. The intention was to keep a re-test interval of 4 weeks [19] but due to practical reasons, e.g. school vacation or abruptly postponed weekly sport activities, a majority of the healthy children (*Group one*) answered the re-test questionnaire after 6 weeks. The mailed questionnaires (*Group two*) were then distributed with the same re-test interval of 6 weeks. For those who answered the same questionnaire a second time after 6 weeks, an assumption was made that the children were in the same state regarding their hip when answering the questionnaire, a second time. This assumption was supported by the fact that 90% of children who develop bilateral SCFE do so within 18 months after the index hip was diagnosed [20] and we chose in group two to use only children with unilateral SCFE 24 months after the index hip was treated. However, we could not control whether any complications to SCFE had occurred between the first and second set of the questionnaire was distributed.

Group one answered the Barnhöft questionnaire with one or two researchers present to give assistance whenever necessary but they did not answer any general health-related quality of life instrument for children.

Group two. From a Swedish national quality register for children with a hip disease, slipped capital femoral epiphysis (SCFE), an invitation was sent by mail to 26 consecutively registered children, 8-15 years old boys and girls, that had their primary surgery performed for SCFE 24 months earlier, i.e. in 2011. Only children with unilateral SCFE were invited. Data was collected through a self-administered questionnaire. The questionnaires together with information about the study were posted to the children with a return-addressed and stamped envelope. We used not more than two reminders. Information about the study was posted separately to the caretaker stating the reason

for this questionnaire to be sent to their child. The caretaker was encouraged to give assistance whenever necessary but the importance of receiving the experience and opinion from the child was very much stressed. One child did not respond to this invitation and finally 25 children participated in both the test and re-test procedure. For group two we also used the Swedish version of the general child health-related quality of life instrument, EQ-5D-Y (www.euroqol.org), during the first test but not for the re-test. The reasons for this additional questionnaire (EQ-5D-Y) to be used here were to; (1) compare their answers in Barnhöft concerning pain and motion with the answers given in EQ-5D-Y and (2) compare the answers for this group with the answers from a general population of Swedish children [21].

Psychometric properties

Reliability is the extent to which scores for a patient whose problems have not changed are the same for repeated measurement [16]. For test of the stability we used the test-retest method and a weighted Cohen's kappa analysis for ordinal data [22] together with the percentage agreement method [18], a nonparametric statistical test for ordinal data.

Validity. The *content validity* - the degree to which the content of a health-related patient reported outcome (HR-PRO) instrument is an adequate reflection of the construct to be measured [16]. The relevance of items was judged by the expert committee and the comprehensibility was evaluated through cognitive interviews. *Construct validity* - the degree to which the scores of a measurement are consistent with hypotheses, e.g. relationships with scores of other instruments [16], based on the assumption that the HR-PRO instrument validly measures the construct to be measured. This was evaluated by the Spearman's rank order correlation coefficient [23] comparing Barnhöft domains with the corresponding domains of the EQ-5D-Y questionnaire and the Multi-Dimensional Scaling (MSD) for ordinal scales was used to visualize to what extent the subparts within a domain measure the same characteristics [24]. We hypothesized that the pain domain of Barnhöft would have moderate to high (0.50 to 0.80) Spearman's rank order correlation coefficient values with the corresponding domain of pain in EQ-5D-Y [25] and that the degree of pain in Barnhöft would correlate to the score for possibility of doing usual activities in EQ-5D-Y.

Patient characteristics

We analysed the severity of the disease and whether a complication to the disease had occurred or not e.g. avascular necrosis.

Data analysis

All descriptive statistical analyses were performed using SPSS Statistics for Windows (version 24.0; IBM Corp, Armonk, NY): Multi-dimensional scaling (MDS) for analysis of categorical data [24], a weighted Cohen's kappa [22, 26] with confidence interval (CI) together with percentual agreement (PA) as described by Elisabeth Svensson for stability test of the instrument [18], and Spearman's rank order correlation coefficient for construct validity test [23].

Results

General observations made during the cognitive and retrospective debriefing interviews

The pain domain scale

During the retrospective debriefing interviews, we found that for the children below age 11 years the term "incapacitating pain" was not so easily understood and therefore the final translation version of the questionnaire was adjusted accordingly and changed to "So much pain that I cannot even play or move around".

The function domain scale

Dressing The aim was to check for any problem with daily dressing that required a certain degree of flexion in the hip. In the original questionnaire, the word "discomfort" was used. We found that the corresponding most proper Swedish word was not a well-defined condition for our study population. Some children had problem with the combination of asking for "Pain, discomfort or difficulty" in the same question. They stated that pain or difficulty were hard to properly distinguish since pain itself causes difficulty. On the other hand, this did not cause them any problem to choose the best alternative for their answer but it gave them some minor initial confusion when answering the question. Therefore, we adjusted the question into "Do you have problem when putting on or taking off socks or shoes".

Sitting In the original version one item is formulated "Can sit comfortably at a table or at movies". We revealed minor difficulties for the children below age 11 years to fully interpret the term. This part was initially adjusted already during the translation and back-translation process and the Swedish version was "Can sit comfortably at a table or in an easy chair but not on the floor". Still, children below age 11 years had some problem to interpret this alternative properly, especially the word "comfortably". Therefore, we further adjusted the final version and changed the first alternative to "Can sit without any problem on the floor" and the second alternative to "Can sit without any problem at a table or in an easy chair but not on the floor".

Stair climbing The term "Stair climbing: foot over foot without a railing" (or "with a railing") was also a bit confusing to fully understand for the same age group of children below 11 years. In the Swedish version, the text was translated into "Can walk with only one foot on each step without holding (or "but must hold") on to the staircase banisters". A few children reported that they were unsure of their own routines and first had to go to a staircase and test themselves to be sure of which alternative they should choose.

Cultural adaptation of language The term "mild pain" could not be used in Swedish since that easily could be misunderstood for something positive and therefore in the Swedish version we instead used the term "just a little pain".

Missing data

All questionnaires for this study were obtained without any missing data.

Reliability

For the *stability of the instrument* the test-retest method with a weighted Cohen's kappa with confidence interval (CI) [22] together with percentual agreement (PA) as described by Elisabeth Svensson [18] for group two (children with a hip disorder) were used, see Table 1.

The 12 healthy children (group one) were too few for such a statistical evaluation. Nevertheless, the only difference registered was that 3 of 12 children chose different alternatives for walking capacity varying between "unlimited" or "long distances but limited".

Construct validity

This was only possible for group two since the healthy children (group one) did not answer EQ-5D-Y. Spearman's rank order correlation coefficient was used. We compared the answers for the pain domain (1-item) in EQ-5D-Y with the pain domain in Barnhöft and found a Spearman's rank order correlation coefficient of 0.73. It was noticed that severe pain affected the score for the function domain in Barnhöft and we therefore compared the degree of hip pain in Barnhöft with the item "doing usual activities" in

Table 1 Stability test of Barnhöft

Item	Weighted Cohen's kappa	Percentual agreement
Pain (v48)	0,88 (CI 0,74-1,01)	99
Dressing (v49)	0,91 (CI 0,73-1,09)	99
Walking aid (v50)	1,00 (CI 1,00-1,00)	100
Walking capacity (v52)	0,88 (CI 0,66-1,10)	96
Sitting capacity (v53)	1,00 (CI 1,00-1,00)	100
Stair climbing (v54)	1,00 (CI 1,00-1,00)	100

EQ-5D-Y and found a Spearman's rank order correlation coefficient of 0.67. Since the questions in the function domain of Barnhöft did not test for the same level of function as used in EQ-5D-Y it was not possible to make a comparison.

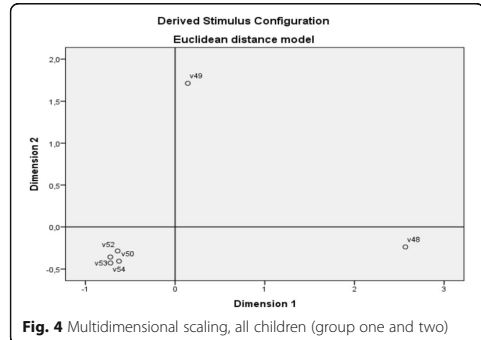
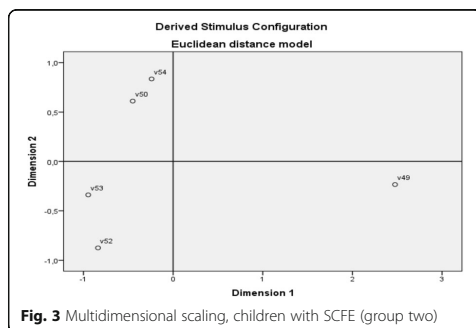
The number of children per item was not enough to make a factor analysis, a test to identify the dimensions of a test [27]. Multi-dimensional scaling (MDS) for categorical data in an ordinal scale [24, 28] was instead used to scale health-state similarity data. This methodology is based on the ranking of differences between health states combined with an associated scaling model that transforms the individual rank data into group values on the interval level. Information contained in a set of data is then represented by a set of points in a multidimensional space. We used Multi-dimensional scaling to visualize whether certain items were more closely related than others i.e. whether the different items under the domain function covered different aspects of functional capacity for the children in group two.

In Table 1 the different variables used (v48-v54) are listed. We found that the capacity for stair climbing (v54) and the need for a walking aid (v50) were linked together as were also walking (v52) and sitting (v53) capacity whereas the ability to dress (v49) was found to measure a separate functional capacity (Fig. 3).

Combining the healthy children (group one) with the children with a hip disorder (group two) we found that pain (v48) and the ability to dress (v49) still answered different aspects of the health status of the children whereas the different items for walking and sitting capacity tested for the same ability to move around (Fig. 4).

Function domain (5-items)

The healthy children (group one) showed for the function domain (maximum score of 32) a median value of 32 (26-32). The children with a hip disorder (group two)



had a similar median value of 32 but with a broader range (11-32). The child in group two with the lowest score had neither a severe SCFE nor a complication with avascular necrosis or chondrolysis of the femoral head but described "incapacitating" pain. The scores for this child did not change during the re-test situation.

Pain domain (1-item)


The children in group two (children with a hip disorder) had a median score of 4 (1-5) with a lower quartile of 3.5 and an upper quartile of 5 whereas the healthy children all scored 5.

The EQ-5D VAS

The results in group two (children with a hip disorder) showed that the children scored a mean of 88 which was equal to a Swedish general population [21].

Group comparison EQ-5D-Y (SCFE) and general population

The Swedish EQ-5D-Y has no algorithm for evaluation other than on an item-level. We therefore chose to compare the results for EQ-5D-Y for group two (children with a hip disorder) with the 399 Swedish children from a general population published by Burström et al. [21] and their health profiles. An estimated health profile of at least '11122' would then include most healthy children i.e. 'no' problems in the dimensions 'mobility (walking about)', 'looking after myself' and 'doing usual activities' and some or no problems in the dimensions 'having pain or discomfort' and 'feeling worried, sad or unhappy'. This calculation showed that 375/399 (93%) of the children in the general population compared to 17/25 (68%) among children with SCFE reached this level of the health profile.



Barnhöft

Frågor om smärta och funktion till barn från 8 års ålder med en sjukdom som påverkar höftleden

Frågor som gäller **Din höft**.
Tänk på den höft som du har mest ont i då du svarar på frågorna.
Sätt ett kryss för det svar som passar bäst.

- 1. Hur ont har Du i Din höft**
 Så ont att jag inte ens kan leka eller röra mig som jag vill (0)
 Mycket ont (10)
 Ganska ont (20)
 Bara lite ont (30)
 Inte ont alls (40)
- 2. Har Du problem med att sätta på eller ta av strumpor eller skor**
 För det mesta (0)
 Ibland (2)
 Aldrig (4)
- 3. Hjälpmedel** som Du använt under de senaste veckorna för att kunna gå
 Inget (8)
 Käpp, krycka, rollator, rullstol (0)
- 4. Hur långt kan du gå utan att behöva stanna för att vila**
 Så långt jag vill eller behöver (8/11)
 Ganska långt (7)
 Bara korta sträckor utomhus (5)
 Bara inomhus (3)
 Kan inte gå själv - behöver rullstol (0)
- 5. Sittande:**
 Kan sitta utan problem på golvet (5)
 Kan sitta utan problem vid ett bord eller i en fåtölj men inte på golvet (3)
 Kan inte sitta i mer än ett par minuter utan att behöva ändra ställning (0)
- 6. Gå i trappor:**
 Kan gå med bara en fot på varje trappsteg, utan att hålla i trappträcket (4)
 Kan gå med bara en fot på varje trappsteg, men måste hålla i trappträcket (2)
 Måste gå med båda fötterna på varje trappsteg (1)
 Kan inte gå i trappor (0)

Förklaring:
Fråga 4: 11 poäng förutsätter gående utan gå-hjälpmedel, annars 8 poäng max.

Pat ID:
Barnhöft

Fig. 5 Barnhöft questionnaire

Discussion

A hip specific questionnaire for children from age 8, Barnhöft, is now available in Swedish. The original CHOHES was used for children from age 8 years where they had a physiotherapist guiding the children through the questions while attending a re-visit in the hospital out-patient department. It is our experience that the questionnaire "Barnhöft" can be sent as a postal letter with a paper format questionnaire to the participant but with the recommendation that a parent/caretaker or a close relative should be giving assistance, especially for the children below 11 years of age.

The pain domain in Barnhöft showed a different result between healthy children (group one) and children with SCFE (group two), i.e. as one would have expected.

The children in group two (SCFE) were for the hip function domain comparable to children in the original publication by Aguilar et al. [7] with children with sickle-cell disease without any apparent avascular necrosis of the hip. We also compared children with SCFE with children with developmental dysplasia of the hip (DDH) as described by Reposch et al. [9]. We found that children with SCFE, following the score of the function domain, were comparable to children with DDH with

secondary avascular necrosis grade I-II as described by Bucholtz-Ogden [29] whereas for pain the scores were comparable with grade III-IV.

We chose to follow the ISPOR task force principles of good practice for translation and cultural adaptation of PRO [14]. The need to strictly follow this sometimes costly and time-consuming methodology has been questioned [30, 31]. Epstein et al. [32] have recently stated that an expert committee is much more valuable than the procedure where back translation is included.

The original developer of the instrument [7] only included three healthy children together with 40 children with sickle-cell disease though not all of them with evidence of avascular necrosis of the hip.

In the article by Aguilar [7] both the pain and the function domain quartiles showed evidence of a ceiling effect for all children tested which was not shown when used by Roposch et al. [9] for children with avascular necrosis due to hip dysplasia. “Barnhöft” or CHOHES was never intended to be an instrument useful for healthy children so the ceiling effect seen for healthy children was expected.

When we compared the results for EQ-5D-Y with a general population (16) the calculation showed that approximately 70% of children with SCFE reached the health profile level compared to more than 90% of children in the general population. These results indicate that reduced hip function influences quality of life in the everyday life of children diagnosed with SCFE.

Conclusion

To our knowledge, this is the only validated instrument in Swedish that assess the health status in children with a hip disorder from age 8. We would argue that the combination of a general HRQOL instrument with the 6-item hip specific instrument Barnhöft would be able to identify children with a hip disorder that have an impaired health status due to either pain, functional limitations or a combination of the two.

Limitations

Content validity was not evaluated by the original developer using any qualitative analysis. The adult Harris Hip Score was their source when identifying items to be used for children. Face validity by experts was then used when the CHOHES items were finally established. In our study we made the assumption, based on epidemiological data [10], that children with SCFE were comparable to “hip-healthy” children concerning their comprehensibility of Barnhöft.

For children in *Group two* (one hip affected by SCFE) the questionnaires were distributed and answers collected by mail. In spite of written instructions, to both the child and the caretaker, we could not control for any possible caretaker bias.

Responsiveness – the ability of an instrument to detect change over time in the construct to be measured [16] was evaluated by the original developer but not in this study.

Interpretability – the degree to which one can assign clinical or commonly understood connotations to an instrument’s quantitative scores or change in scores [16] was not analysed in this study.

Criterion validity – the degree to which the scores of a measurement instrument constitute an adequate reflection of a gold standard [16] was not possible to evaluate due to the lack of such standard.

We used no independent measure of clinical status before the first and second presentation of the instrument to the children. We assumed that the children with SCFE who answered the test a second time (re-test) had an unchanged health status compared to when they were first exposed to the instrument. The healthy children (group one) were asked about any change in their health and functional status before presented to the re-test situation but this was unfortunately not possible to evaluate for the children in group two.

We did not recruit a completely new group of healthy children for the further testing of Barnhöft i.e. 10/35 healthy children also participated in the cognitive interviewing part of this study.

The healthy children in our study did not fill in the forms for EQ-5D-Y so we were not able to evaluate if they were giving similar answers as healthy children in a general population [21].

For the reliability test, i.e. the test of the stability of the instrument, we chose to randomly select only 12 of the 35 healthy children in Group one. This is a small sample size which might affect the results. However, in the original study only three healthy children participated together with 14 children with sickle-cell disease but without known affection of the hips [7].

For group two (children with a hip disorder) we made no analysis whether the literacy among the participants was adequate to their age [33].

There is no other Swedish disease or hip specific questionnaire available to compare the results for “Barnhöft”. The “Barnhöft” 6-item score (Fig. 5) therefore needs to be further evaluated in a larger series of children with a hip specific disorder. To confirm the capacity to reflect the true level of pain and functional limitations for these children in relation to the severity of their disorder.

Acknowledgements

Christina Peterson, RN, PhD, at Jonköping University for assistance with the retrospective and cognitive debriefing. Laura Darcy, RN, PhD, at Jonköping University for assistance with retrospective and cognitive debriefing together with the translation process. Barbro Svensson, M.Phil., for valuable linguistic assistance during the translation and cultural adaptation process. Bo Rolander, PhD, statistician, Futurum Academy for Health and Care Jonköping County Council for assistance with statistical analysis.

Funding

This study was supported by grants from the Futurum Academy for Health and Care, Jonkoping County Council, Sweden.

Authors' contributions

Study design: BH and KE; Data collection: BH and KE; Data analysis: BH, MS and KE; Manuscript preparation: BH, MS and KE. All authors have read and approved the final manuscript.

Ethics approval and consent to participate

Ethical approval for the study was authorized by the Regional Ethical Review Board in Lund, Sweden with registration number 2013/87. The study was in accordance with the ethical principles of the 1964 Declaration of Helsinki for medical research involving humans and its later amendments.

Informed consent was obtained from all individual participants and one parent or guardian, both for healthy and sick children, during the test of the pre-final version and the further testing of the questionnaire.

Approval to utilize questionnaires for scientific purposes: We received a written approval from the EuroQol group (www.euroqol.org) to utilize the Swedish EQ-5D-Y for this study.

From the original developer of CHOHES [7] their written approval was obtained for both the cultural adaptation and validation process to be implemented together with the chosen Swedish name for the questionnaire, Barnhöft.

Competing interests

The authors declare that they have no competing interest.

Publisher's Note

Springer Nature remains neutral with regard to jurisdictional claims in published maps and institutional affiliations.

Author details

¹Department of Clinical Sciences, Lund, Orthopaedics, Lund University, SE-221 00 Lund, Sweden. ²Futurum Academy for Health and Care Jonkoping County Council, Department of Orthopaedics, Ryhov county hospital, SE-551 85 Jonkoping, Sweden. ³Futurum Academy for Health and Care Jonkoping County Council, Department of Paediatrics, Ryhov county hospital, SE-551 85 Jonkoping, Sweden. ⁴Institute for Clinical Sciences, Department of Paediatrics, Gothenburg University, SE-405 30 Gothenburg, Sweden. ⁵Department of Nursing, School of Health and Welfare, CHILD research group, Jonkoping University, P.O. Box 1026, SE-551 11 Jonkoping, Sweden.

Received: 25 May 2017 Accepted: 6 December 2017

Published online: 19 December 2017

References

- Loder, R. T., Wittenberg, B., & DeSilva, G. (1995). Slipped capital femoral epiphysis associated with endocrine disorders. *Journal of Pediatric Orthopaedics*, *15*(3), 349–356.
- Hailer, Y. D., & Nilsson, O. (2014). Legg-Calve-Perthes disease and the risk of ADHD, depression, and mortality. *Acta Orthopaedica*, *85*(5), 501–505.
- Imrie, M., et al. (2010). Is ultrasound screening for DDH in babies born breech sufficient? *Journal of Children's Orthopaedics*, *4*(1), 3–8.
- Bullinger, M. (2002). Assessing health related quality of life in medicine. An overview over concepts, methods and applications in international research. *Restorative Neurology and Neuroscience*, *20*(3–4), 93–101.
- Beaton, D. E., & Schemitsch, E. (2003). Measures of health-related quality of life and physical function. *Clinical Orthopaedics and Related Research*, *413*, 90–105.
- d'Entremont, A. G., et al. (2015). What clinimetric evidence exists for using hip-specific patient-reported outcome measures in pediatric hip impingement? *Clinical Orthopaedics and Related Research*, *473*(4), 1361–1367.
- Aguilar, C. M., et al. (2005). Clinical evaluation of avascular necrosis in patients with sickle cell disease: Children's hospital Oakland hip evaluation scale—a modification of the Harris hip score. *Archives of Physical Medicine and Rehabilitation*, *86*(7), 1369–1375.
- Harris, W. H. (1969). Traumatic arthritis of the hip after dislocation and acetabular fractures: Treatment by mold arthroplasty. An end-result study using a new method of result evaluation. *The Journal of Bone and Joint Surgery, American Volume*, *51*(4), 737–755.
- Roposch, A., et al. (2011). Functional outcomes in children with osteonecrosis secondary to treatment of developmental dysplasia of the hip. *The Journal of Bone and Joint Surgery, American Volume*, *93*(24), e145.
- Herngren, B., et al. (2017). Slipped capital femoral epiphysis: A population-based study. *BMC Musculoskeletal Disorders*, *18*(1), 304.
- Wille, N., et al. (2010). Development of the EQ-5D-Y: A child-friendly version of the EQ-5D. *Quality of Life Research*, *19*(6), 875–886.
- Burstrom, K., et al. (2011). A Swedish child-friendly pilot version of the EQ-5D instrument—the development process. *European Journal of Public Health*, *21*(2), 171–177.
- Feng, Y., Parkin, D., & Devlin, N. J. (2014). Assessing the performance of the EQ-VAS in the NHS PROMs programme. *Quality of Life Research*, *23*(3), 977–989.
- Wild, D., et al. (2005). Principles of good practice for the translation and cultural adaptation process for patient-reported outcomes (PRO) measures: Report of the ISPOR task force for translation and cultural adaptation. *Value in Health*, *8*(2), 94–104.
- Price, V. E., et al. (2009). Measuring disease-specific quality of life in rare populations: A practical approach to cross-cultural translation. *Health and Quality of Life Outcomes*, *7*, 92.
- Mokkink, L. B., et al. (2010). The COSMIN study reached international consensus on taxonomy, terminology, and definitions of measurement properties for health-related patient-reported outcomes. *Journal of Clinical Epidemiology*, *63*(7), 737–745.
- Eremenco, S. L., Cella, D., & Arnold, B. J. (2005). A comprehensive method for the translation and cross-cultural validation of health status questionnaires. *Evaluation & the Health Professions*, *28*(2), 212–232.
- Svensson, E., et al. (2012). Reliability of the balanced inventory for spinal disorders, a questionnaire for evaluation of outcomes in patients with various spinal disorders. *Journal of Spinal Disorders & Techniques*, *25*(4), 196–204.
- Spencer, F. H., Bornholt, L. J., & Ouvrier, R. A. (2003). Test reliability and stability of children's cognitive functioning. *Journal of Child Neurology*, *18*(1), 5–11.
- Loder, R. T., et al. (2008). Slipped capital femoral epiphysis. *Instructional Course Lectures*, *57*, 473–498.
- Burstrom, K., et al. (2014). EQ-5D-Y as a health-related quality of life measure in children and adolescents with functional disability in Sweden: Testing feasibility and validity. *Acta Paediatrica*, *103*(4), 426–435.
- Tang, W., et al. (2015). Kappa coefficient: A popular measure of rater agreement. *Shanghai Archives of Psychiatry*, *27*(1), 62–67.
- Mukaka, M. M. (2012). Statistics corner: A guide to appropriate use of correlation coefficient in medical research. *Malawi Medical Journal*, *24*(3), 69–71.
- Arons, A. M., & Krabbe, P. F. (2014). Quantification of health by scaling similarity judgments. *PLoS ONE*, *9*(2), e89091.
- Paulsen, A., Odgaard, A., & Overgaard, S. (2012). Translation, cross-cultural adaptation and validation of the Danish version of the Oxford hip score: Assessed against generic and disease-specific questionnaires. *Bone & Joint Research*, *1*(9), 225–233.
- Ngo, T., et al. (2010). A study of the test-retest reliability of the self-perceived general recovery and self-perceived change in neck pain questions in patients with recent whiplash-associated disorders. *European Spine Journal*, *19*(6), 957–962.
- Tavakol, M., & Dennick, R. (2011). Making sense of Cronbach's alpha. *International Journal of Medical Education*, *2*, 53–55.
- Krabbe, P. F., Salomon, J. A., & Murray, C. J. (2007). Quantification of health states with rank-based nonmetric multidimensional scaling. *Medical Decision Making*, *27*(4), 395–405.
- Bucholtz, R., & Ogden, J. (1978). *Patterns of ischemic necrosis of the proximal femur in nonoperatively treated congenital hip disease*. St. Louis: CV Mosby Co.
- Perneger, T. V., Leplege, A., & Etter, J. F. (1999). Cross-cultural adaptation of a psychometric instrument: Two methods compared. *Journal of Clinical Epidemiology*, *52*(11), 1037–1046.
- da Mota Falcao, D., Ciconelli, R. M., & Ferraz, M. B. (2003). Translation and cultural adaptation of quality of life questionnaires: An evaluation of methodology. *The Journal of Rheumatology*, *30*(2), 379–385.
- Epstein, J., et al. (2015). Cross-cultural adaptation of the health education impact questionnaire: Experimental study showed expert committee, not back-translation, added value. *J Clin Epidemiol*, *68*(4), 360–369.
- El-Daly, I., et al. (2016). Are patient-reported outcome measures in orthopaedics easily read by patients? *Clinical Orthopaedics and Related Research*, *474*(1), 246–255.

Paper III



Good inter- and intraobserver reliability for assessment of the slip angle in 77 hip radiographs of children with a slipped capital femoral epiphysis

Bengt HERNGREN^{1,2}, Mikael LINDELL², and Gunnar HÄGGLUND¹

¹ Department of Orthopedics, Lund University, Lund, Sweden; ² Department of Orthopedics, Ryhov County Hospital, Jönköping, Sweden
Correspondence: bengt.herngren@med.lu.se
Submitted 2017-07-30. Accepted 2017-10-30.

Background and purpose — The decision on and the outcome of treatment for a slipped capital femoral epiphysis (SCFE) depend on the severity of the slip. In 2015, web-based registration was introduced into the Swedish Pediatric Orthopedic Quality (SPOQ) register. To determine whether the inclusion of commonly used methods in Sweden for radiographic measurement of SCFE (the calcar femorale [CF] method and the Billing method) is justified, we measured the inter- and intraobserver reliability of these 2 measurements. We also evaluated the internationally more commonly used head-shaft angle (HSA) method.

Material and methods — 4 observers with different levels of experience with radiographic measurements analyzed 77 routine preoperative hip radiographs of children with SCFE. Inter- and intraobserver reliability was evaluated.

Results — The interobserver reliability analysis for the 4 observers showed for CF an ICC of 0.99 (CI 0.97–0.99) and for Billing an ICC of 0.99 (CI 0.98–0.99). The interobserver reliability analysis for 2 observers showed for HSA an ICC of 0.98 (CI 0.97–0.99).

Intraobserver reliability (2 observers) showed a mean difference below 1° for all 3 methods and with a 95% limit of agreement not exceeding ±6.8°.

Interpretation — We found good reliability for both intra- and interobserver measurements of all 3 methods used for the assessment of the slip angle on routine preoperative lateral hip radiographs.

ann et al. 2006). SCFE is caused by the displacement between the epiphysis and the metaphysis of the proximal femur. The epiphysis remains in the acetabulum while the femur usually rotates outward and in extension (Jerre 1995, Loder 2001). The recommended method of treatment (Souder et al. 2014, Loder 2017) and the outcome (Kocher et al. 2004, Larson et al. 2010, Terjesen and Wensaas 2017) depend on the severity of the slip. The reliability of the methods used to measure the slip angle is therefore important.

Begun in 2015, the Swedish Pediatric Orthopedic Quality register (SPOQ, www.spoq.se) is now a web-based registration tool for 5 pediatric orthopedic conditions. For SCFE, the surgeon is requested to register certain variables including the preoperative slip angle. 2 methods for measurement of the slip angle in SCFE are used in the SPOQ register: the calcar femorale (CF) method (Hansson et al. 1988) and the Billing method (Billing et al. 2002). The aim of this study was to determine whether the reliability of the CF and Billing methods justifies their use in the register. We hypothesized that the intraobserver and interobserver reliability for these methods would warrant their use in SPOQ. We also included a comparison between the CF and the internationally more commonly used head–shaft angle (HSA) method (Southwick 1967).

Material and methods

Conventional radiographs from 94 consecutively registered children with SCFE included in the SPOQ register during 2013 and 2014 were assessed. The radiographs used were routine preoperative examinations from all Swedish hospitals

Slipped capital femoral epiphysis (SCFE) is the most common hip disorder in children aged 9–15 years (Loder 1996, Lehm-

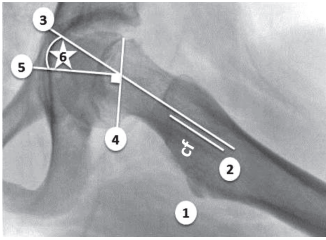


Figure 1. Slip angle measured using the calcar femorale method in a Lauenstein view.

1. Identify the calcar femorale (cf) and the lesser trochanter ①.
2. From the level of the lesser trochanter draw a line ② three cm in a proximal direction parallel to the calcar femorale.
3. Extend a line ③ parallel to line ② up through the femoral neck.
4. Define a line ④ through the physeal anterior and posterior margins.
5. Draw a line ⑤ perpendicular to line ④.
6. Slip angle ⑥.

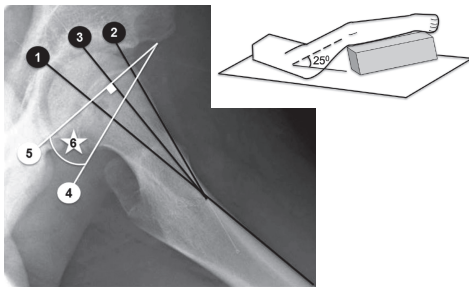


Figure 2. Slip angle measured using the Billing method in Billing lateral view with the patient positioned according to the figure to the right.

1. Draw a line ① along the anterior cortex of the proximal femur. Extend the line up through the femoral head and neck.
2. Draw a line ② along the anterior border of the femoral neck.
3. Draw the bisector ③ to lines ① and ②.
4. Define a line ④ through the physeal anterior and posterior margins.
5. Draw a line ⑤ perpendicular to line ③.
6. The slip angle ⑥ is the angle between lines ④ and ⑤.

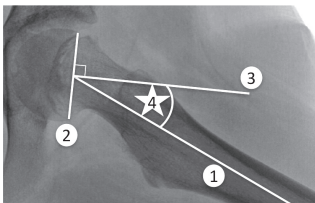


Figure 3. Slip angle measured using the lateral head-shaft angle method in a Lauenstein view.

1. Draw a line ①, parallel with the proximal femoral shaft, further up into the femoral neck.
2. Define a line ② through the physeal anterior and posterior margins.
3. Draw a line ③ perpendicular to line ②.
4. Lateral head-shaft angle ④.

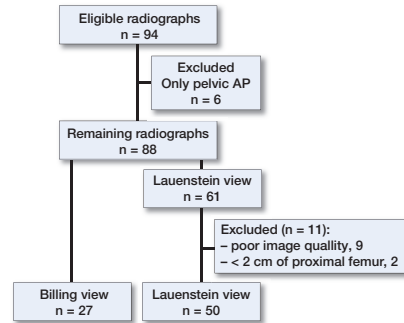


Figure 4. Study material.

that treated children with SCFE during this period. 1 fourth-year resident in orthopedics (ML – Observer 1), 1 specialist in orthopedics (BH – Observer 2), and 2 specialists in pediatric radiology (Observers 3 and 4) acted as observers.

To obtain both presumptive normal hips and hips with SCFE in the study material, we chose the right hip for assessment for every second radiograph in the consecutive list irrespective of whether it was a hip with SCFE or a normal hip. The web-based instructions, available through the SPOQ, were used (Figures 1 and 2) together with a similar instruction on how to measure the lateral HSA (Figure 3).

For the Lauenstein view (both hips), horizontal rotational alignment with an obturator index between 0.7 and 1.8 (Tönnis 1976) and at least 2 cm of the proximal femur below the lesser trochanter had to be included (Lehmann et al. 2013). For the Billing lateral view, radiographs were accepted if the lesser trochanter was not protruding posteriorly or anteriorly. A correct rotational alignment was emphasized by the developer of this method to be a crucial factor (Billing et al. 2002). According to these criteria, 50 radiographs in the Lauenstein view and 27 in the Billing lateral view were included in the analysis (Figure 4).

Interobserver reliability

The orthopedic resident and the orthopedic specialist (Observers 1 and 2), respectively, used their standard picture archiving and communication system (PACS). The orthopedic specialist was experienced in the use of both the CF and Billing methods. The orthopedic resident had no previous experience in any method. The pediatric radiologists (Observers 3 and 4) assessed all radiographs using their standard PACS. They were both experienced in using the Billing method but not the CF or HSA methods.

The radiographs were all given a unique number in a list that did not follow any alphabetical order or pattern according to age, date, or sex. The observers were blinded to the measurements made by the other observers, radiographic reports,

information from medical records, or their own previous measurements. They were allowed to use their own preferred screen settings. Standardization of the measurements was performed before the study by thorough discussion and interpretation of the instructions. The orthopedic resident measured 20 different pelvic radiographs under supervision of Observer 2.

We used these instructions for a single measurement for all 4 readers for the Billing and CF methods.

Intraobserver reliability

Observers 1 and 2 also measured the lateral HSA and assessed the radiographs twice each following the Billing method, the CF method, and the HSA. An interval of at least 6 weeks was used between the repeated measurements for analysis of intraobserver reliability.

Statistics

We assumed a t-distribution for a sample size of < 50 and a normal distribution for a sample size of ≥ 50 . The effect size was set to 3° with 90% power and with a confidence level of 99%. The expected standard deviation was derived from a similar study (Carney and Liljenquist 2005).

Intraobserver variation for each of the measurements was assessed using the mean difference, with its 95% limits of agreement (Bland and Altman 1986, Lehmann et al. 2013). For the purpose of graphic presentation, we plotted the differences against the mean measurements (Bland–Altman plots).

Interobserver variation for 2 observers measuring HSA was assessed using the intraclass correlation coefficient (ICC) and 95% confidence interval (CI) with 2-way random and absolute agreement for single measures. The first measurements were used for both observers (McGraw and Wong 1996). For the 4 observers measuring Billing and CF, interobserver reliability was evaluated using the intraclass correlation coefficient (ICC) and CI with 2-way random and absolute agreement for average measures. The first measurements were used for all observers (McGraw and Wong 1996, Hermanson et al. 2017).

When comparing the HSA with the CF method, we used the first measurements for both methods. For statistical analysis, the variability was described using the Bland–Altman method, with its 95% limits of agreement (Sedgwick 2013).

IBM SPSS Statistics for Windows version 24 (IBM Corp, Armonk, NY, USA) was used for the statistical analyses.

Ethics, funding, and potential conflicts of interest

Ethical approval was authorized by the Regional Ethical Review Board in Lund, Sweden (registration number 2013/87). Informed consent was obtained from all participants and from one parent or guardian.

Funding was received from the Swedish Association of Local Authorities and Regions (SKL), and the Futurum Academy for Health and Care, Jönköping County Council, Jönköping.

The authors declare no conflicts of interest.

Table 1. Intraobserver variation between first and second measurements of slip angle ($^\circ$)

Intraobserver	Subjects	Difference mean (SD)	95% limits of agreement
Observer 1 – Billing	27	–0.8 (2.9)	–6.5 to 5.0
Observer 2 – Billing	27	–0.2 (1.9)	–4.0 to 3.5
Observer 1 – CF	50	0.0 (2.6)	–5.1 to 5.1
Observer 2 – CF	50	0.2 (1.4)	–2.3 to 3.0
Observer 1 – HSA	50	0.1 (1.1)	–2.1 to 2.3
Observer 2 – HSA	50	0.4 (3.3)	–6.0 to 6.8

Table 2. Difference ($^\circ$) between HSA and CF measurement

HSA – CF	Subjects	Difference mean (SD)	95% limits of agreement
Observer 1	50	5.9 (4.8)	–3.5 to 15.3
Observer 2	50	3.4 (4.8)	–6.1 to 12.9

Results

The mean slip angles for the different methods used were: 23° (3° to 59°) for the Billing method, 23° (-8° to 81°) for the CF method, and 26° (-7° to 89°) for the HSA method.

The interobserver reliability analysis for 4 observers showed for CF an ICC of 0.99 (CI 0.97–0.99) and for Billing an ICC of 0.99 (CI 0.98–0.99). The interobserver reliability analysis for 2 observers showed for HSA an ICC of 0.98 (CI 0.97–0.99).

Intraobserver reliability analysis for 2 observers showed a mean difference between the first and second measurement of less than one degree for all three methods. The 95% limits of agreement ranged between -6.5° and 6.8° (Table 1). Bland–Altman plots for HSA and CF visualize the proximity achieved between the first and second measurements (Figures 5 and 6).

The mean difference between the first measurements of HSA and CF was below 6° for 2 observers (Table 2).

Discussion

We found good inter- and intraobserver reliability for all 3 methods for assessing the slip angle on routine preoperative hip radiographs.

The HSA method showed an acceptable inter- and intraobserver reliability. The HSA method produced on average a higher value for the slip angle compared with the CF method. The 95% limit of agreement between the 2 methods also showed a rather wide range of 19° for both observers. On the other hand, the HSA method for observer 1 together with the CF method for observer 2 showed the highest intraobserver

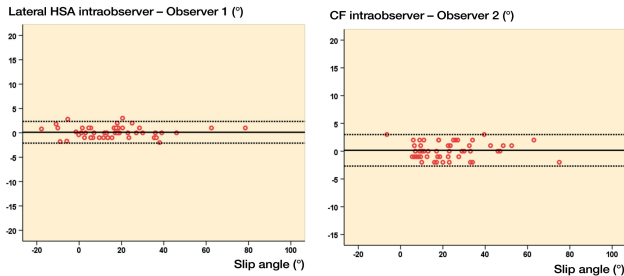


Figure 5. Intraobserver variation (°) for HSA – Observer 1 (left panel). The solid line represents the mean value and the dotted lines show the limits for 2 standard deviations above and below the mean value.

Figure 6. Intraobserver variation (°) for CF – Observer 2 (right panel). The solid line represents the mean value and the dotted lines show the limits for 2 standard deviations above and below the mean value.

reliability. These aspects should all be considered when comparing reports using either of these methods.

In Sweden, the Billing method (Billing et al. 2002) and the CF method (Hansson et al. 1988) are frequently used even though the accuracy of the Billing method for the measurement of a severe slip has been questioned (Loder 2001). An advantage of the CF method is that the CF remains in an unchanged position after remodeling and is identifiable even in adulthood (Harty 1957, Griffin 1982, Hansson et al. 1988); this provides a method for detecting SCFE after growth plate closure (Hansson et al. 1988).

Variability in the radiographic technique can affect the measurement of the slip angle on the Lauenstein view (Jerre 1950, Loder 2001, Carney and Liljenquist 2005). Multiplanar computerized tomography is probably the most reproducible method to assess the slip angle in SCFE (Cohen et al. 1986, Gelberman et al. 1986, Guzzanti and Falciglia 1991, Monazzam et al. 2013) but this technique is not currently an established routine examination in Swedish hospitals for children suspected to have SCFE.

Loder et al. (1999) used Lauenstein radiographs of 48 hips with SCFE (38 children), and 4 observers measured the lateral HSA. They reported no influence of observer experience, no statistically significant difference between the observers and an interobserver variability of ± 12 degrees. Carney and Liljenquist (2005) used 3 observers to test the variability of the lateral HSA using Lauenstein radiographs of 108 hips (55 with SCFE and 53 normal). They reported an intraobserver variability for the HSA of ± 5.9 degrees and concluded that a single observer should document at least a 12-degree change between 2 radiographs to ensure a true change. We found an inter- and intraobserver variability that was comparable with these previous results.

In our study, 11 Lauenstein radiographs did not meet the technical image criteria. Other investigators have also described an inability to obtain reproducible radiographs because of variability in limb position caused by osseous deformities through the physis and/or children experiencing pain (Cohen et al. 1986). Jones et al. (2017) showed by comparing Lauenstein views with 361 simulated models from CT scans that a small

error in positioning could cause a greater than 10° error in the reported lateral HSA.

Clear instructions for the measurement procedure can probably compensate for differences in professional experience provided that the radiographic technique is of acceptable quality. As a consequence of our study, the 4 observers together prepared an updated instruction for all Swedish hospitals on how to achieve a correct Lauenstein view: the hips should be in maximal abduction, the knees flexed to 90° , the plantar aspects of the feet placed together with the lateral aspects of the feet resting against the table, absence of significant asymmetry in the appearance of the obturator foramina (Tönnis 1976), the central beam through the most cranial part of the pubic symphysis, and with a minimum of 5 cm of the femur below the lesser trochanter included in the radiograph.

Our findings indicate that, independent of the experience of the observer, the inter- and intraobserver reliability values for the methods in this study are acceptable for routine use in a national quality register for SCFE. We will consider the inclusion of the HSA as an alternative measurement method for the SPOQ register.

Limitations

The severity of the slips in our study was less than that previously reported in similar studies (Loder et al. 1999, Carney and Liljenquist 2005, Lehmann et al. 2013) and this may have influenced our results for both the intra- and interobserver variability.

We could not blind the radiographs to personal identity numbers because of the need for secure storage of patient information. To compensate, the radiographs were all given a unique number in a list that did not follow any alphabetical order or pattern according to age, date, or sex. We also used a minimum of 6 weeks between the radiographic assessments. Fewer Billing lateral views than Lauenstein views (27 and 50, respectively) were included in this study.

Acknowledgements: Bo Rolander, statistician at the Futurum Academy for Health and Care, Jönköping County Council, Sweden. Håkan Bostrom and Hanna Hebelka Bolminger, specialists in pediatric radiology at Drottning Silvias Barn- och Ungdomssjukhus, Göteborg, Sweden.

Study design: BH and ML; data collection: BH and ML; data analysis: BH, ML, and GH; manuscript preparation: BH, ML, and GH.

Acta thanks Anders Wensaas and other anonymous reviewers for help with peer review of this study.

Billing L, Bogren H G, Wallin J. Reliable X-ray diagnosis of slipped capital femoral epiphysis by combining the conventional and a new simplified geometrical method. *Pediatric Radiol* 2002; 32 (6): 423-30.

Bland J M, Altman D G. Statistical methods for assessing agreement between two methods of clinical measurement. *Lancet* 1986; 1 (8476): 307-10.

Carney B T, Liljenquist J. Measurement variability of the lateral head–shaft angle in slipped capital femoral epiphysis. *J Surg Orthop Adv* 2005; 14 (4): 165-7.

Cohen M S, Gelberman R H, Griffin P P, Kasser J R, Emans J B, Millis M B. Slipped capital femoral epiphysis: Assessment of epiphyseal displacement and angulation. *J Pediatr Orthop* 1986; 6 (3): 259-64.

Gelberman R H, Cohen M S, Shaw B A, Kasser J R, Griffin P P, Wilkinson R H. The association of femoral retroversion with slipped capital femoral epiphysis. *J Bone Joint Surg Am* 1986; 68 (7): 1000-7.

Griffin J B. The calcar femorale redefined. *Clin Orthop Relat Res* 1982; (164): 211-14.

Guzzanti V, Falciglia F. Slipped capital femoral epiphysis: Comparison of a roentgenographic method and computed tomography in determining slip severity. *J Pediatr Orthop* 1991; 11 (1): 6-12.

Hansson L I, Häggglund G, Ordeberg G, Sandstrom S. The calcar femorale as a landmark in hip physiolysis. *Acta Orthop Scand* 1988; 59 (2): 134-8.

Harty M. The calcar femorale and the femoral neck. *J Bone Joint Surg Am* 1957; 39 (3): 625-30.

Hermanson M, Häggglund G, Riad J, Rodby-Bousquet E. Inter- and intra-rater reliability of the head–shaft angle in children with cerebral palsy. *J Child Orthop* 2017; 11 (4): 256-62.

Jerre T. A study in slipped upper femoral epiphysis: With special reference to the late functional and roentgenological results and to the value of closed reduction [thesis]. *Acta Orthop Scand* 1950; Suppl 6.

Jerre R. Physiolysis of the hip: Epidemiology, diagnosis and long-term follow-up [thesis]. Institute of Surgical Sciences, Gothenburg 1995.

Jones C E, Cooper A P, Doucette J, Buchan L L, Wilson D R, Mulpuri K, d'Entremont A G. Southwick angle measurements and SCFE slip severity classifications are affected by frog-lateral positioning. *Skeletal Radiol* 2017 Aug 24 [Epub ahead of print].

Kocher M S, Bishop J A, Weed B, Hresko M T, Millis M B, Kim Y J, Kasser J R. Delay in diagnosis of slipped capital femoral epiphysis. *Pediatrics* 2004; 113 (4): e322-5.

Larson A N, Yu E M, Melton L J, Peterson H A, Stans A A. Incidence of slipped capital femoral epiphysis: A population-based study. *J Pediatr Orthop B* 2010; 19 (1): 9-12.

Lehmann C L, Arons R R, Loder R T, Vitale M G. The epidemiology of slipped capital femoral epiphysis: an update. *J Pediatr Orthop* 2006; 26 (3): 286-90.

Lehmann T G, Vetti N, Laborie L B, Engesaeter I O, Engesaeter L B, Rosendahl K. Intra- and inter-observer repeatability of radiographic measurements for previously slipped capital femoral epiphysis at skeletal maturity. *Acta Radiol* 2013; 54: 587-91.

Loder R T. The demographics of slipped capital femoral epiphysis: An international multicenter study. *Clin Orthop Relat Res* 1996; (322): 8-27.

Loder R T. Effect of femur position on the angular measurement of slipped capital femoral epiphysis. *J Pediatr Orthop* 2001; 21 (4): 488-94.

Loder R T. Slipped capital femoral epiphysis: A spectrum of surgical care and changes over time. *J Child Orthop* 2017; 11 (2): 154-9.

Loder R T, Blakemore L C, Fairley F A, Laidlaw A T. Measurement variability of slipped capital femoral epiphysis. *Journal of Orthopaedic Surgery* 1999; 7 (1): 33-42.

McGraw K O, Wong S P. Forming inferences about some intraclass correlation coefficients. *Psychological Methods* 1996; 1 (1): 30-46.

Monazzam S, Dwek J R, Hosalkar H S. Multiplanar CT assessment of femoral head displacement in slipped capital femoral epiphysis. *Pediatric Radiol* 2013; 43 (12): 1599-605.

Sedgwick P. Limits of agreement (Bland–Altman method). *BMJ* 2013; 346: f1630.

Souder C D, Bomar J D, Wenger D R. The role of capital realignment versus in situ stabilization for the treatment of slipped capital femoral epiphysis. *J Pediatr Orthop* 2014; 34 (8): 791-8.

Southwick W O. Osteotomy through the lesser trochanter for slipped capital femoral epiphysis. *J Bone Joint Surg Am* 1967; 49 (5): 807-35.

Terjesen T, Wensaas A. Prognostic factors for long-term outcome of chronic slipped capital femoral epiphysis treated with fixation in situ. *J Child Orthop* 2017; 11 (2): 114-9.

Tönnis D. Normal values of the hip joint for the evaluation of X-rays in children and adults. *Clin Orthop Relat Res* 1976; (119): 39-47.

Paper IV



Outcomes after slipped capital femoral epiphysis: a population-based study with three-year follow-up

B. Herngren^{1,2}
M. Stenmarker^{2,3}
K. Enskär⁴
G. Hägglund⁵

Abstract

Purpose To evaluate outcomes three years after treatment for slipped capital femoral epiphysis (SCFE): development of avascular necrosis (AVN), subsequent surgery, hip function and the contralateral hip.

Methods This prospective cohort study included a total national population of 379 children treated for SCFE between 2007 and 2013. A total of 449 hips treated for SCFE and 151 hips treated with a prophylactic fixation were identified. The Barnhöft questionnaire, a valid patient-reported outcome measure (PROM), was used.

Results In all, 90 hips had a severe slip, 61 of these were clinically unstable. AVN developed in 25 of the 449 hips. Six of 15 hips treated with capital realignment developed AVN. A peri-implant femur fracture occurred in three slipped hips and in two prophylactically pinned hips. In three of these five hips technical difficulties during surgery was identified. In 43 of 201 hips scheduled for regular follow-up a subsequent SCFE developed in the contralateral hip. Implant extraction after physeal closure was performed in 156 of 449 hips treated for SCFE and in 51 of 151 prophylactically fixed hips. Children with impaired hip function could be identified using the Barnhöft questionnaire.

Conclusion Fixation *in situ* is justified to remain as the primary treatment of choice in SCFE. Overweight is more common in children with SCFE than in the average population.

¹Lund University, Department of Clinical Sciences, Lund, Sweden

²Futurum - Academy for Health and Care, Jonkoping County Council, Department of Orthopaedics, Ryhov County hospital, Jonkoping, Sweden

³Institute for Clinical Sciences, Department of Paediatrics, Gothenburg University, Gothenburg, Sweden

⁴Department of Nursing, School of Health and Welfare, CHILD Research Group, Jonkoping University, Jonkoping, Sweden

⁵Department of Orthopaedics, Skane University Hospital, Lund, Sweden

Correspondence should be sent to B. Herngren, Department of Orthopaedics, Ryhov County Hospital, S-551 85 Jonkoping, Sweden. E-mail: bengt.herngren@med.lu.se

Prophylactic fixation is a safe procedure when performed using a correct technique. The number of patients who developed AVN after capital realignment is of concern. We recommend rigorous follow-up of both hips, including PROM evaluation, until physeal closure.

Level of Evidence II - prospective cohort study

Cite this article: Herngren B, Stenmarker M, Enskär K, Hägglund G. Outcomes after slipped capital femoral epiphysis: a population-based study with three-year follow-up. *J Child Orthop* 2018;12. DOI: 10.1302/1863-2548.12.180067

Keywords: slipped capital femoral epiphysis; outcome; complications; patient-reported outcome measures

Introduction

Slipped capital femoral epiphysis (SCFE) is the most common orthopaedic condition causing groin pain at the time of the adolescent growth spurt. In SCFE, the epiphysis remains in the acetabulum while the femur usually rotates outwards and in extension.^{1,2}

The aetiology of SCFE is thought to be multifactorial. Obesity is a known risk factor.^{3,4} The severity of the slip can affect the range of hip movement and increasing loss of internal rotation and flexion capacity can follow a more severe slip.⁵ In children with a unilateral SCFE at first presentation the contralateral hip is at risk of developing a sequential slip until the proximal femoral physis is closed.⁶⁻⁸ Depending on the degree of physeal stability,⁹ severe complications such as avascular necrosis (AVN) are more common in association with unstable SCFE.¹⁰

Ideally, health-related quality of life (HRQoL) instruments, both general and disease specific, are included in the evaluation of outcomes in paediatric orthopaedic patients. In 2013, a validated Swedish hip-specific patient-reported outcome measure (PROM), called the Barnhöft questionnaire, became available.¹¹

The aim of this study was to describe the outcomes within 36 months from the primary surgery in a prospective cohort study of a total national population of children with SCFE. Analysis included complications in hips treated for SCFE and prophylactically fixed hips, subsequent surgery needed and development of a sequential SCFE. A PROM was used to measure hip function and HRQoL.

Methods

Study design

This was a prospective cohort study of a total national population of 379 children treated for SCFE between 2007 and 2013.

Inclusion criteria were: children living in Sweden, who were registered in the Swedish Population Register with a Swedish personal identity number, with SCFE in the index hip during the study period. Exclusion criteria were: SCFE because of high energy trauma or septic coxitis.

All 34 hospitals that treated SCFE in Sweden participated. The study population is described in Figure 1.

Data collection

Consecutive follow-ups were made annually for each child up to 36 months after the primary surgery, through contact with the hospital where the primary surgery or follow-up was performed.

All reported events within 36 months from the date of the primary surgery were registered based on analysis of medical records, school health records and radiographs by one of the authors (BH). Radiographic evidence of progression of the slip severity, loss of fixation, accuracy of implant placement,¹² AVN of Ficat stage III and IV osteonecrosis with at least collapse of a sequestered area into the femoral head¹³ or chondrolysis (joint space narrowing of 3 mm)^{14,15} was registered.

Re-operations and radiographic complications that did not require subsequent surgery were analyzed for all 379 children. This also included routinely scheduled surgery (e.g. extraction of implants after physal closure).

When calculating the number of subsequent procedures performed, the development of AVN was considered the end point for that specific hip; that is, no subsequent operations for these hips were included in the results.

Slip severity was graded as mild (13° to 29°), moderate (30° to 49°) or severe (> 50°).^{1,16–18} To measure slip severity, we used the calcar femorale method on a Lauenstein view¹⁹ or the Billing method on a lateral Billing view.²⁰ For both methods a minimum slip angle of 13° was required for diagnosis.^{1,19–21}

The clinical classification of stability described by Loder et al⁹ was used. An unstable SCFE was defined as one causing severe pain that makes walking impossible even with crutches, regardless of the duration of the symptoms. The postoperative radiographs were re-analyzed by one of the authors (BH), subtracting the slip angle of the preoperative film from the immediate postoperative film to determine whether a reduction had been achieved. We used the same criteria as Kennedy et al,²² in which a difference of > 10° was considered a reduction which was then classified further into intentional or incidental reductions based on the surgical reports. When the clinical classification made by the surgeon indicated a stable SCFE, this was altered in the study protocol if an obvious reduction could be visualized on postoperative radiographs.

The accuracy of implant placement within the epiphysis was graded according to the method of Pring et al¹² using anteroposterior and lateral radiographs. For a 'correct implant position', the implant had to be placed within the central 50% of the physal width, with the screw tip > 5 mm across the physis and at an angle of 70° to 90° to the capital physis. 'Poor implant position' was identified when the implant was located outside the central 75% of

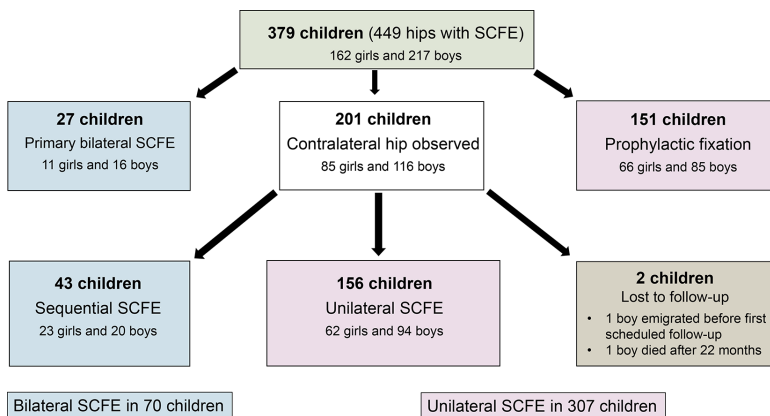


Fig. 1 Study population (SCFE, slipped capital femoral epiphysis).

the physal width, with the screw tip < 2.5 mm across the physis, tip of the implant located within < 2.5 mm from the subchondral bone, or the implant was introduced at an angle of < 50° to the physis.

All radiographs were re-analyzed by one of the authors (BH). Both inter- and intraobserver reliability of radiographic measurements for slip severity were found to be good according to the procedure of Hergren et al.²³

Body mass index (BMI)

Age-adjusted BMI was calculated using the method of Karlberg et al²⁴ for 307 of the 379 children (81%). We accepted data from within 12 months before or after the date of the primary surgery.

PROM

PROM-instruments are used to capture generic and disease-specific HRQoL issues.²⁵ The validated Barnhöft questionnaire includes a pain domain (one-item) together with a hip function domain (five-items). The pain scale in the Barnhöft questionnaire¹¹ includes a rating for each hip with a maximum of 40 points, which is equal to 'no pain at all'. The function domain is based on daily activities, including dressing, sitting, walking and stair climbing, with a maximum of 32 points. A high score indicates good hip function. From the youth version of the five-dimension EuroQol instrument (EQ-5D-Y),²⁶ a general instrument for assessing HRQoL, we chose the domain 'Feeling worried, sad, or unhappy' to be complementary to the domains covered by the Barnhöft questionnaire. The EQ-5D-VAS,²⁷ a visual analogue scale which is rated as 0 to 100 with 100 as the best health, was used as a quantitative measure of health outcome as judged by the individual respondents. Permission was obtained from the EuroQol group to use the Swedish version of the EQ-5D-Y in this study.

The questionnaires were distributed consecutively through ordinary mail 24 months after the primary surgery to 107 children diagnosed with unilateral SCFE. Two reminders were sent to those who had not returned the questionnaires.

Statistical analysis

Continuous data were checked for normality using the Kolmogorov-Smirnov test together with an analysis of the histogram and are reported as the median with minimum and maximum values. Discrete data are reported as frequencies and/or percentages. An independent sample *t*-test was used to compare mean values for continuous data between two groups that were normally distributed. To compare proportions between two independent groups, we used a cross-table and chi-squared test. The significance threshold was set at 0.05.

IBM SPSS Statistics for Windows (version 24; IBM Corp, Armonk, New York) was used for the statistical analyses.

Results

This study cohort included a total of 61 unstable hips (60 in the index hip) and 90 severe slips (89 in the index hip).

The characteristics for each subgroup of the study population are presented in Table 1. The 151 children with unilateral SCFE who received prophylactic fixation were younger than the 201 children with unilateral SCFE who were selected for scheduled radiographic and clinical follow-up ($p = 0.001$). This statistical difference was considered of clinical relevance. However, the groups did not differ significantly in the severity of the slip, clinical classification (stable/unstable) or age-adjusted BMI.

AVN

A total of 25 of 449 hips (6%) developed AVN within 36 months from the primary surgery for SCFE (Table 2). Of the 380 hips with a stable slip treated with *in situ* fixation, only five developed AVN, compared with 11 of the 56 unstable slips treated with a percutaneous fixation.

Of the 56 unstable hips treated with percutaneous internal fixation, an intentional reduction manoeuvre (traction, internal rotation and mild flexion) was performed in 32 hips and an incidental reduction from simple positioning on the operating table was described and was visualized on the postoperative radiographs in 14 hips.

Of the 41 severe unstable hips, 8/36 treated with pinning and 3/5 treated with open reduction and internal fixation (i.e. capital realignment or open reduction according to Parsch et al²⁸) developed AVN. This difference was not statistically significant.

Of the 24 unstable hips treated with percutaneous internal fixation without intention of reduction, 5/24 hips developed AVN, whereas 6/32 hips where an intentional reduction was performed developed AVN. This difference was not statistically significant.

An arthrocentesis was made in seven of the 56 unstable hips. An intentional reduction manoeuvre was performed in one and an incidental reduction occurred in five. No AVN was identified in these seven hips. Among the unstable 49 hips, where no arthrocentesis was performed, 11 hips developed AVN. This difference was not statistically significant.

Peri-implant femur fractures

In hips treated for SCFE, three peri-implant femur fractures occurred, all in the index hip. For two of these three hips, technical problems were described in the surgical reports. During the operation, either multiple entry points were

Table 1 Characteristics for the study population of 449 hips (379 children) (SCFE, slipped capital femoral epiphysis)

Group	Sex	N	Median age at surgery (range), yrs	Unstable (n)	Severe slip (n)	High BMI* (n)
27 hips	F	11	11.9 (10.6 to 15.4)	2	6	5
Index hip						
Bilateral SCFE at first presentation	M	16	12.2 (9.6 to 14.8)	3	7	9
27 hips	F	11	11.9 (10.6 to 15.4)	0	0	5
Second hip						
Bilateral SCFE at first presentation	M	16	12.2 (9.6 to 14.8)	0	0	9
43 hips	F	23	11.4 (8.4 to 14.7)	4	2	11
Index hip						
Sequential bilateral SCFE	M	20	12.3 (9.5 to 15.1)	4	3	14
43 hips	F	23	12.3 (9.8 to 14.8)	0	0	11
Second hip						
Sequential bilateral SCFE	M	20	13.2 (10.7 to 15.8)	1	1	14
156 hips	F	62	12.2 (9.1 to 14.6)	10	14	28
Unilateral SCFE						
No prophylactic fixation	M	94	13.5 (3.9 to 16.8)	19	26	56
151 hips	F	66	11.1 (7.2 to 15.1)	7	14	31
Unilateral SCFE						
Prophylactic fixation	M	85	13 (9.5 to 17.7)	11	17	54
2 hips	M†	1	14.5	0	0	1
Lost to follow-up						
Unilateral SCFE	M‡	1	13.5	0	0	1
TOTAL	F	196	11.7 (7.2 to 15.4)	23	36	91
449 hips With SCFE	M	253	13 (3.9 to 17.7)	38	54	156

*Age-adjusted body mass index (BMI) according to Karlberg et al²⁴ of 25 or above
Values were available for only 81% of the children

†one boy emigrated before the first scheduled follow-up

‡one boy died after 22 months

Table 2 Development of avascular necrosis (AVN) in 449 hips treated for slipped capital femoral epiphysis (SCFE)

Surgical procedure	Hips (n)	AVN (n)
Percutaneous internal fixation for stable SCFE	380	5 [†]
Percutaneous internal fixation for unstable SCFE	56	11 [†]
Capital realignment as primary surgery for stable SCFE	8 [‡]	2
Capital realignment as primary surgery for unstable SCFE	3 [‡]	2
Open reduction and internal fixation for unstable SCFE (Parsch et al) ²⁵	2 [‡]	1
Capital realignment as reconstructive surgery before physal closure	4	2
Surgery for a subsequent peri-implant femur fracture	3	2
Total		25

*two of five hips had a severe SCFE

†eight of 11 hips had a severe SCFE; six of 11 hips had an intentional reduction manoeuvre and four had an incidental reduction

‡all of these hips had a severe SCFE

used for guide wire insertion before the implant was introduced or the first drill bit used was blunt and did not penetrate the cortex completely. One of these three hips developed AVN secondary to this event.

In prophylactically treated hips a peri-implant femur fracture occurred in two hips. For one of these hips, the surgical report described technical problems during surgery requiring multiple guide wire insertion attempts before a correct entry point was achieved. In the other hip, a subsequent deep infection developed that necessitated surgical wound debridement.

Chondrolysis

Chondrolysis developed in three stable severe slipped hips. Subsequent AVN later developed in two of the three hips. Penetration of the joint with an intra-articular position of the implant was observed in one of the hips.

Poor implant position

The implant position was assessed as poor in 38 of the 380 stable hips treated with *in situ* fixation for SCFE. Two

Table 3 Re-operations in 449 hips treated for slipped capital femoral epiphysis (SCFE)

Surgical procedure	Hips (n)
Routine extraction of implant after closure of the proximal physis	156
Extraction of implant after primary capital realignment	2
Early re-operation because of poor implant position (before discharge after primary surgery)	15 [*]
Exchange of implant because of growth	13
Osteochondroplasty because of femoroacetabular impingement, closed proximal physis	9 [†]
Change in implant because of slip progress despite internal fixation	8 [‡]
Physiodesis around the contralateral knee because of leg-length discrepancy	5
Deep infection requiring surgical wound debridement	4 ^{**}
Capital realignment procedure	4
Trochanteric overgrowth treated with apophysiodesis of the greater trochanter	2
Intertrochanteric corrective osteotomy because of limited range of movement	2 ^{††}
Fixation of a peri-implant femur fracture	3

*implant position too anterior or completely outside the epiphysis

†seven of the procedures were arthroscopy assisted

‡five hips with a poor implant position, a physiodesis as a secondary procedure was performed in one of these five hips

**the hip treated with an intertrochanteric corrective osteotomy that later developed a deep infection is not counted here

††one hip treated with an intertrochanteric corrective osteotomy developed a deep infection that required surgical wound debridement

of the 38 hips developed AVN; one was diagnosed early and one after subsequent reconstructive surgery.

A poor implant position was also identified in 14 of the 56 unstable hips treated with percutaneous internal fixation for SCFE. Four of the 14 hips developed AVN, all of them were diagnosed early after the initial procedure.

Subsequent surgery

Of the 436 slipped hips treated with percutaneous fixation the implant was extracted as a routine procedure in 156 hips (for 22 hips the procedure had to be converted from a percutaneous to a more extensive approach). Another 67 hips were subsequently operated on for various reasons (Table 3). Of the 151 hips treated with prophylactic fixation, the implant was extracted as a routine procedure in 51 hips (five of these procedures were converted to a more extensive approach). Five of the 151 hips required further surgery for other reasons (Table 4).

PROM

A total of 87 of 107 children (81%) with a unilateral SCFE returned the questionnaires (Fig. 2). Age, gender, severity of the slip and clinical classification did not differ significantly between the non-responders (n = 20) and responders. Of the 75 children with a stable SCFE, two developed AVN and of the 12 children with an unstable SCFE, three developed AVN.

Children with a stable mild or moderate SCFE at the initial presentation (n = 66) scored a median of 30 (0 to 40) for the Barnhöft pain domain and a median of 32 (11 to 32) for the function domain. In the EQ-5D-VAS, they

Table 4 Re-operations in 151 hips treated with prophylactic fixation (SCFE, slipped capital femoral epiphysis)

Surgical procedure	Hips (n)
Routine extraction of implant after physeal closure	51
Exchange of implant because of growth	2
Re-fixation because of loss of fixation and development of a mild SCFE	1 [*]
Fixation of a peri-implant femur fracture	2 [†]

*the implant was placed in the correct position in the primary surgery †the hip subsequently developed a deep infection that required surgical wound debridement

scored a median of 88 (30 to 100). In response to the EQ-5D-Y item 'Feeling worried, sad, or unhappy', two children answered that they were 'very' worried, sad or unhappy, 12 answered that they were 'a bit' worried, sad or unhappy and 52 that they were 'not' worried, sad or unhappy.

Children with a stable severe SCFE at the initial presentation (n = 9) scored a median of 20 (0 to 40) for the Barnhöft pain domain and a median of 26 (20 to 32) for the function domain. In the EQ-5D-VAS, they scored a median of 80 (30 to 100). In response to the EQ-5D-Y item 'Feeling worried, sad, or unhappy' no child answered that he or she was 'very' worried, sad or unhappy, whereas five answered that they were 'a bit' worried, sad or unhappy, and four that they were 'not' worried, sad or unhappy.

Children who developed AVN (n = 5) scored a median of 20 (10 to 20) for the Barnhöft pain domain and a median of 24 (16 to 28) for the function domain. In the EQ-5D-VAS, they scored a median of 60 (35 to 100). In response to the EQ-5D-Y item 'Feeling worried, sad, or unhappy', two children answered that they were 'very' worried, sad or unhappy, one answered that he or she was 'a bit' worried, sad or unhappy and two that they were 'not' worried, sad or unhappy.

Discussion

The strength of this study is that all children treated for SCFE in Sweden during a seven-year period were identified and gave their informed consent to participate. The cumulative incidence for SCFE in the index hip for children 9 to 15 years old in Sweden was 40.6 per 100 000 for girls and 52.2 per 100 000 for boys for the period studied.²⁹ The male-to-female ratio was 1.3:1 and 76% of the boys and 56% of the girls were overweight or obese.²⁹ In comparison with a Swedish population of 12-year-old school children, 16% of the boys and 13% of the girls were overweight.³⁰ All participants were followed for 36 months after the primary surgery for SCFE; the only exception was one child who emigrated and another child who died. We used a hip-specific instrument for self-assessment, the Barnhöft questionnaire, which has been validated for children from eight years of age together with a general

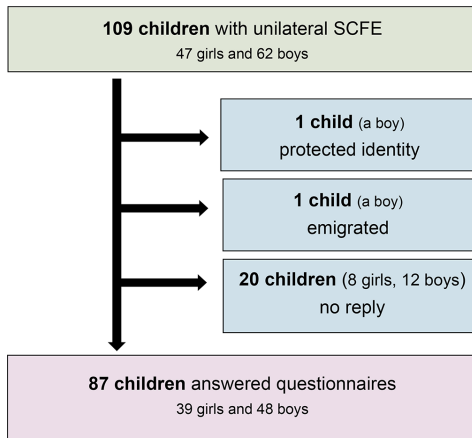


Fig. 2 Responders and non-responders to questionnaires (SCFE, slipped capital femoral epiphysis).

health status questionnaire, the EQ-5D-Y including the EQ-5D-VAS. Outcome studies for children with orthopaedic disorders should include aspects beyond radiographic findings or surgical complications.

AVN

AVN is the most devastating complication of SCFE. Unstable SCFE increases the risk of AVN, and the risk increases further with slip severity.^{31,32} Loder et al⁹ found AVN in 47% of the cases in their series of 55 patients with unstable SCFE treated with internal fixation. Chen et al³³ reported that four of 30 unstable hips treated with gentle positioning and internal fixation developed AVN. In a recent review of the literature, Loder³⁴ estimated the historical average of AVN as 21% but found that more recent studies show promising results with a lower AVN rate after urgent reduction, decompression and fixation or open reduction and fixation. However, Loder³⁴ noted some concerns about the accuracy of the definition of an 'unstable SCFE' used in some of the studies. In the present study, AVN occurred in 25 of 449 hips (6%). In all, 14 of these 25 AVN occurred in the group of 61 unstable hips.

Kinking of the retinacular vessels was reported in an angiographic study of unstable SCFE with restoration of blood supply after reduction.³⁵ Jackson et al³⁶ used perioperative angiography in nine patients who underwent a capital realignment procedure. They showed that blood flow was restored after reduction for four of six patients who did not have arterial flow to the femoral head on the preoperative angiogram. Novais et al³⁷ used different techniques in the perioperative setting for 29 patients with unstable SCFE who underwent a capital realignment

procedure to evaluate the restoration of blood flow to the femoral head during the operation. They concluded that assessment of femoral head blood perfusion can be used as a predictor of the later development of AVN. In our study, only three capital realignment procedures were performed as primary surgery for unstable hips with SCFE, and different techniques were used to assess blood flow to the femoral head at surgery. However, two of these three hips developed AVN.

Partial reduction to the position before the acute component of the slip, using an open approach for hip joint decompression and reduction on a regular operating table, is associated with AVN rates of less than 5% at five years.²⁸ Kennedy et al²² analyzed the outcomes for 27 unstable hips with SCFE. Four of the 27 unstable hips developed AVN, but no association was found with the reduction or magnitude of the slip. Chen et al³³ used gentle positioning only and no forceful reduction for 30 unstable hips followed for a minimum of two years. They performed arthrocentesis or open capsulotomy in 21 hips. Four of the 30 hips developed AVN. Using the surgical reports in our study, we were able to determine whether an intentional or an incidental reduction was achieved. We found no statistically significant difference of the development of AVN between the group (n = 32) where an intentional reduction manoeuvre and percutaneous internal fixation was performed compared with the group (n = 24) where only an incidental reduction or no reduction was implemented.

The presence of an increased intracapsular hip pressure and the effect of joint decompression has been studied in unstable hips with SCFE with divergent conclusions.^{38,39} In the present study, we analyzed the development of AVN after joint decompression (n = 7) versus no joint decompression (n = 49) in 56 unstable hips treated with percutaneous internal fixation. The number of hips that had a joint decompression procedure was limited and we found no statistically significant difference between the groups.

Timing of surgery is thought to be crucial to the development of AVN. It is also thought that surgery should be performed within 24 hours from the onset of symptoms.⁴⁰⁻⁴² In the present study, no preoperative traction or prolonged bed rest was used. All patients with an unstable hip intended for percutaneous internal fixation were brought to the operating room within 24 hours after admission to hospital. However, it was not possible to analyze the data regarding the exact onset of symptoms counted in hours.

Routine extraction of an implant after physeal closure

For most of the 156 hips treated with implant extraction after physeal closure, the procedure was performed without any reason outlined in the medical reports other than a scheduled routine procedure. There is little evidence to

support this as a routine procedure in a child without any symptoms related to the implant.^{43–46} The appearance of complications after removal of hardware in hips treated for SCFE depends on the implant used.^{47,48}

For 51 of the 151 hips treated with a prophylactic fixation in this study, a similar subsequent routine extraction was performed.

Some of these children might have had localized pain around a protruding implant but for 22 hips treated for SCFE and five hips treated with prophylactic fixation the extraction procedure had to be converted from a percutaneous procedure to a more extensive approach due to technical difficulties. However, there were no secondary complications reported to these procedures. There is a risk that future surgery might be more difficult and require a two-stage approach but the evidence supporting routine removal of all hip implants in children treated for SCFE is limited.⁴³

Prophylactic fixation

Prophylactic fixation remains a controversial issue for unilateral SCFE. However, there is no controversy about the need for prophylactic fixation in children with a concomitant endocrine disorder.⁶

Proponents of prophylactic fixation stress the risks for a subsequent contralateral slip with functional limitations or AVN if an unstable slip develops, risk of osteoarthritis and a low risk of iatrogenic complications associated with modern techniques.^{6,49,50} Others support the idea of clinical and radiographic follow-up until physeal closure.^{8,51–53} Some have tried to present an algorithm in which prophylactic fixation is offered to children with a higher risk of developing a sequential slip in the contralateral hip based on skeletal immaturity,^{54,55} gender^{50,55} and modified Oxford bone age score.⁵⁶ Compliance regarding the family's ability to return for regular follow-up visits has also been proposed as a factor to consider.⁵²

In this cohort study, after excluding one hip with obvious technical difficulties observed during surgery leading to a peri-implant femur fracture, we identified no AVN in this group of 151 hips and only one peri-implant femur fracture occurred. However, we question the routine use of implant extraction after physeal closure.^{43–46} The low number of complications within 36 months from surgery involving prophylactic fixation in this study does not show that this routine is linked to serious complications. Use of a correct technique (i.e. a satisfactory entry point established and maintained with the aid of optimal fluoroscopy views and sharp drill bits) is crucial. We note that, for the 70 children with a bilateral SCFE (27 had bilateral SCFE at the initial presentation), only one child developed a severe and unstable SCFE in the other hip (one of the 43 sequential hips with SCFE); this rate is similar to that in some

reports^{51,57} but contrasts with that of other reports.^{6,58–60} A regular follow-up schedule, with repeated radiographs together with repeated and thorough information given to the family about the necessity for an urgent radiographic examination whenever symptoms occur in the contralateral hip, might explain the difference between reports.

In this cohort study the group selected for prophylactic fixation ($n = 151$) included younger children than those scheduled for regular follow-up, but no differences were found concerning age-adjusted BMI, clinical classification or slip severity. There was one child who developed SCFE in spite of a prophylactic fixation. The number of children that were selected for scheduled follow-up (for most children with an interval of three to four months) with available data at follow-up were 199 (initially 201 but two were lost to follow-up). We could then calculate the absolute risk reduction: 21.6% (43/199) minus 0.7% (1/151) which equals 20.9%. The 'Number Needed to Treat' would then become 4.8 (1/0.209). If a prophylactic fixation would have been offered to all 352 children with a primarily unilateral SCFE, then 74 children of the 352 would have been prevented from a subsequent SCFE in the contralateral hip. The consequence would then be that 5/352 children would have to change implant due to further growth of the femoral neck, five would develop a peri-implant femur fracture and of these five, two would develop a deep infection secondary to a peri-implant femur fracture. However, extraction of implants after physeal closure would in most cases not be necessary and we believe that the number of peri-implant femur fractures could be further reduced using a correct technique.

In summary, this calculation gives us a total risk of 2/352 deep infections (0.5%) and 5/352 (1.4%) peri-implant femur fractures if all 352 children with a unilateral SCFE had received a prophylactic fixation of the contralateral hip. These figures are similar to what has been reported previously^{49,61,62} and prophylactic fixation has been found to be a cost-effective procedure that limits the morbidity from the complications of a further slip.^{8,63}

Peri-implant femur fractures

Five hips with a peri-implant femur fracture were identified in this study. Two of these complications occurred in hips after prophylactic fixation. Technical difficulties might have been the cause for these complications in three of five hips. In obese children it might be more difficult to obtain an optimal fluoroscopic view. Therefore, specific precautions ought to be considered even while positioning the child on a suitable operating table so that a correct lateral view can be obtained at surgery during insertion of the implant. The subsequent use of sharp drill-bits together with a surgical technique that creates access at the first attempt to the correct entry point for the guide

wire are both crucial for high-quality surgery. The number of peri-implant femur fractures in this study was similar to that in other reports.^{61,64,65}

PROM

From the child's perspective, it has been found that a range of issues about health are important to discuss.⁶⁶ When healthcare professionals have access to information about the child's HRQoL assessment, it is more likely that they will discuss the issues with the child.⁶⁷ Children also want to answer questions about their health status if they understand the reason behind the questions, if they feel that the questions are relevant and when they notice that their answers are received and commented upon.⁶⁸ To increase the number of domains used for comparison, we chose to use one dimension ('Feeling worried, sad, or unhappy') in the EQ-5D-Y that addresses problems that are more common in children's lives than impairment of mobility, self-care or everyday activities.²⁶ The previous validation study of the Barnhöft questionnaire¹¹ proposed that this questionnaire could be used together with the EQ-5D-Y as a screening tool to identify children with a complication of SCFE or a more severe slip. The results in this study confirm these preliminary results. There was one child in each group of stable mild-moderate and stable severe SCFE, respectively, that had no complications to SCFE but still scored very low in the pain domain of the Barnhöft questionnaire, thus indicating the need for a clinical follow-up to be able to analyze the actual health status in more detail.

We suggest that a child with a score of < 20 for the pain domain of the Barnhöft questionnaire and a score of < 26 for the function domain or a score of < 60 in the EQ-5D-VAS needs a more thorough analysis together with a clinical follow-up. Children who unexpectedly report a lower hip function or severe pain (e.g. without the development of AVN or an initial severe slip) need an individualized assessment.

Conclusions

It is justified that fixation *in situ* should remain as the primary treatment of choice in stable SCFE. A gentle incidental reduction performed together with a percutaneous internal fixation gives acceptable results in unstable SCFE. Being overweight or obese is more common in children with SCFE than the average population. Prophylactic fixation is a safe procedure when performed using the correct technique. The number of patients who developed AVN after capital realignment is of concern. The Barnhöft instrument could be used as a screening tool to identify children with severe pain or with a considerable limitation of hip function after being treated for SCFE. We recommend rigorous follow-up, including PROM evaluation, until physeal closure.

Limitations

Because of the limited follow-up of 36 months for each child, late complications or surgeries were not included.

The 379 children were treated with routine care in 34 different hospitals and it was not possible to confirm hip effusion with ultrasonography or magnetic resonance tomography for clinically unstable hips.

The surgical reports might not have covered all technical difficulties, such as the use of multiple entry points for the guide wire before the implant insertion was accomplished.

We could not evaluate the time from the onset of symptoms to surgery for the 61 unstable hips with SCFE (i.e. the actual timing of surgery counted in hours).

A PROM was not used during the entire study period. The questionnaires were developed in Swedish for children from eight years of age after the inclusion period started. Only children with a unilateral SCFE were included. Unlike the setup used by the original developer of the Children's Hospital Oakland Hip Evaluation Scale (CHOHES),⁶⁹ the questionnaires were not distributed during a scheduled follow-up visit but through ordinary mail. We did not consider it possible for all children, from eight years of age, to comply with the Barnhöft hip-specific questionnaire if both hips were affected without professional assistance for guidance.

Received 24 April 2018; accepted after revision 19 July 2019.

COMPLIANCE WITH ETHICAL STANDARDS

FUNDING STATEMENT

This study was funded only by institutional grants: Futurum - Academy for Health and Care, Jönköping County Council, Sweden, grant number F-767911.

OA LICENCE TEXT

This article is distributed under the terms of the Creative Commons Attribution-Non Commercial 4.0 International (CC BY-NC 4.0) licence (<https://creativecommons.org/licenses/by-nc/4.0/>) which permits non-commercial use, reproduction and distribution of the work without further permission provided the original work is attributed.

ETHICAL STATEMENT

Ethical approval: Ethical approval for the study was authorized by the Regional Ethical Review Board. The study was in accordance with the ethical principles of the 1964 Declaration of Helsinki for medical research involving humans and its later amendments.

Informed consent: Informed consent was obtained from all individual participants included in the study and one parent or guardian of each child.

Availability of data and materials: The datasets used and/or analyzed during the current study are available from the corresponding author on reasonable request.

ICMJE CONFLICT OF INTEREST STATEMENT

None declared.

REFERENCES

- Jerre R.** Physiolsis of the hip: epidemiology, diagnosis and long-term follow-up [unpublished doctoral dissertation]. Department of Orthopaedics, Institute of Surgical Sciences, Gothenburg University, Gothenburg, Sweden, 1995.
- Loder RT.** Unstable slipped capital femoral epiphysis. *J Pediatr Orthop* 2001;21:694-699.
- Nasreddine AY, Heyworth BE, Zurakowski D, Kocher MS.** A reduction in body mass index lowers risk for bilateral slipped capital femoral epiphysis. *Clin Orthop Relat Res* 2013;471:2137-2144.
- Nguyen AR, Ling J, Gomes B, et al.** Slipped capital femoral epiphysis: rising rates with obesity and aboriginality in South Australia. *J Bone Joint Surg [Br]* 2011;93-B:1416-1423.
- Schoenecker PL, Gordon JE, Luhmann SJ, et al.** A treatment algorithm for stable slipped capital femoral epiphysis deformity. *J Pediatr Orthop* 2013;33:5103-5111.
- MacLean JG, Reddy SK.** The contralateral slip. An avoidable complication and indication for prophylactic pinning in slipped upper femoral epiphysis. *J Bone Joint Surg [Br]* 2006;88-B:1497-1501.
- Schur MD, Andras LM, Broom AM, et al.** Continuing Delay in the Diagnosis of Slipped Capital Femoral Epiphysis. *J Pediatr* 2016;177:250-254.
- Baghdadi YM, Larson AN, Sierra RJ, Peterson HA, Stans AA.** The fate of hips that are not prophylactically pinned after unilateral slipped capital femoral epiphysis. *Clin Orthop Relat Res* 2013;471:2124-2131.
- Loder RT, Richards BS, Shapiro PS, Reznick LR, Aronson DD.** Acute slipped capital femoral epiphysis: the importance of physeal stability. *J Bone Joint Surg [Am]* 1993;75-A:1134-1140.
- Sankar WN, McPartland TG, Millis MB, Kim YJ.** The unstable slipped capital femoral epiphysis: risk factors for osteonecrosis. *J Pediatr Orthop* 2010;30:544-548.
- Herngren B, Stenmarker M, Enskär K.** Barnhöft: a hip specific 6-item questionnaire for children. *J Patient Rep Outcomes* 2017;1:16-24.
- Pring M, Adamczyk M, Hosalkar HS, et al.** In situ screw fixation of slipped capital femoral epiphysis with a novel approach: a double-cohort controlled study. *J Child Orthop* 2010;4:239-244.
- Ficat RP.** Idiopathic bone necrosis of the femoral head. Early diagnosis and treatment. *J Bone Joint Surg [Br]* 1985;67-B:3-9.
- Ingram AJ, Clarke MS, Clarke CS Jr, Marshall WR.** Chondrolysis complicating slipped capital femoral epiphysis. *Clin Orthop Relat Res* 1982;165:99-109.
- Tudisco C, Caterini R, Farsetti P, Potenza V.** Chondrolysis of the hip complicating slipped capital femoral epiphysis: long-term follow-up of nine patients. *J Pediatr Orthop B* 1999;8:107-111.
- Loder RT, Starnes T, Dikos G, Aronson DD.** Demographic predictors of severity of stable slipped capital femoral epiphyses. *J Bone Joint Surg [Am]* 2006;88-A:97-105.
- Hansson G, Billing L, Högstedt B, Jerre R, Wallin J.** Long-term results after nailing in situ of slipped upper femoral epiphysis. A 30-year follow-up of 59 hips. *J Bone Joint Surg [Br]* 1998;80-B:70-77.
- Bellemore JM, Carpenter EC, Yu NY, Birke O, Little DG.** Biomechanics of slipped capital femoral epiphysis: evaluation of the posterior sloping angle. *J Pediatr Orthop* 2016;36:651-655.
- Hansson LI, Häggglund G, Ordeberg G, Sandström S.** The calcar femorale as a landmark in hip physiolsis. *Acta Orthop Scand* 1988;59:134-138.
- Billing L, Bogren HG, Wallin J.** Reliable X-ray diagnosis of slipped capital femoral epiphysis by combining the conventional and a new simplified geometrical method. *Pediatr Radiol* 2002;32:423-430.
- Billing L.** Roentgen examination of the proximal femur end in children and adolescents; a standardized technique also suitable for determination of the collum-, anteversion-, and epiphyseal angles; a study of slipped epiphysis and coxa plana. *Acta Radiol Suppl* 1954;110:7-80.
- Kennedy JG, Hresko MT, Kasser JR, et al.** Osteonecrosis of the femoral head associated with slipped capital femoral epiphysis. *J Pediatr Orthop* 2001;21:189-193.
- Herngren B, Lindell M, Häggglund G.** Good inter- and intraobserver reliability for assessment of the slip angle in 77 hip radiographs of children with a slipped capital femoral epiphysis. *Acta Orthop* 2018;89:217-221.
- Karlberg J, Luo ZC, Albertsson-Wikland K.** Body mass index reference values (mean and SD) for Swedish children. *Acta Paediatr* 2001;90:1427-1434.
- Meadows KA.** Patient-reported outcome measures: an overview. *Br J Community Nurs* 2011;16:146-151.
- Wille N, Badia X, Bonsel G, et al.** Development of the EQ-5D-Y: a child-friendly version of the EQ-5D. *Qual Life Res* 2010;19:875-886.
- Feng Y, Parkin D, Devlin NJ.** Assessing the performance of the EQ-VAS in the NHS PROMs programme. *Qual Life Res* 2014;23:977-989.
- Parsch K, Weller S, Parsch D.** Open reduction and smooth Kirschner wire fixation for unstable slipped capital femoral epiphysis. *J Pediatr Orthop* 2009;29:1-8.
- Herngren B, Stenmarker M, Vavruch L, Häggglund G.** Slipped capital femoral epiphysis: a population-based study. *BMC Musculoskelet Disord* 2017;18:304.
- de Munter JS, Friedl A, Lind S, et al.** Stability in the prevalence of Swedish children who were overweight or obese in 2003 and 2011. *Acta Paediatr* 2016;105:1173-1180.
- Tokmakova KP, Stanton RP, Mason DE.** Factors influencing the development of osteonecrosis in patients treated for slipped capital femoral epiphysis. *J Bone Joint Surg [Am]* 2003;85-A:798-801.
- Palocaren T, Holmes L, Rogers K, Kumar SJ.** Outcome of in situ pinning in patients with unstable slipped capital femoral epiphysis: assessment of risk factors associated with avascular necrosis. *J Pediatr Orthop* 2010;30:31-36.
- Chen RC, Schoenecker PL, Dobbs MB, et al.** Urgent reduction, fixation, and arthroscopy for unstable slipped capital femoral epiphysis. *J Pediatr Orthop* 2009;29:687-694.
- Loder RT.** What is the cause of avascular necrosis in unstable slipped capital femoral epiphysis and what can be done to lower the rate? *J Pediatr Orthop* 2013;33:588-591.
- Maeda S, Kita A, Funayama K, Kokubun S.** Vascular supply to slipped capital femoral epiphysis. *J Pediatr Orthop* 2001;21:664-667.
- Jackson JB III, Frick SL, Brighton BK, et al.** Restoration of blood flow to the proximal femoral epiphysis in unstable slipped capital femoral epiphysis by modified Dunn procedure: a preliminary angiographic and intracranial pressure monitoring study. *J Pediatr Orthop* 2018;38:94-99.

37. **Novais EN, Sink EL, Kestel LA, et al.** Is assessment of femoral head perfusion during modified Dunn for unstable slipped capital femoral epiphysis an accurate indicator of osteonecrosis? *Clin Orthop Relat Res* 2016;474:1837-1844.
38. **Herrera-Soto JA, Duffy MF, Birnbaum MA, Vander Have KL.** Increased intracapsular pressures after unstable slipped capital femoral epiphysis. *J Pediatr Orthop* 2008;28:723-728.
39. **Ibrahim T, Mahmoud S, Riaz M, Hegazy A, Little DG.** Hip decompression of unstable slipped capital femoral epiphysis: a systematic review and meta-analysis. *J Child Orthop* 2015;9:113-120.
40. **Kalogrianitis S, Tan CK, Kemp GJ, Bass A, Bruce C.** Does unstable slipped capital femoral epiphysis require urgent stabilization? *J Pediatr Orthop B* 2007;16:6-9.
41. **Phillips SA, Griffiths WE, Clarke NM.** The timing of reduction and stabilisation of the acute, unstable, slipped upper femoral epiphysis. *J Bone Joint Surg [Br]* 2001;83-B:1046-1049.
42. **Kohno Y, Nakashima Y, Kitano T, et al.** Is the timing of surgery associated with avascular necrosis after unstable slipped capital femoral epiphysis? A multicenter study. *J Orthop Sci* 2017;22:112-115.
43. **Raney EM, Freccero DM, Dolan LA, et al.** Evidence-based analysis of removal of orthopaedic implants in the pediatric population. *J Pediatr Orthop* 2008;28:701-704.
44. **Crandall DG, Gabriel KR, Akbarnia BA.** Second operation for slipped capital femoral epiphysis: pin removal. *J Pediatr Orthop* 1992;12:434-437.
45. **Jago ER, Hindley CJ.** The removal of metalwork in children. *Injury* 1998;29:439-441.
46. **Kahle WK.** The case against routine metal removal. *J Pediatr Orthop* 1994;14:229-237.
47. **Ilchmann T, Parsch K.** Complications at screw removal in slipped capital femoral epiphysis treated by cannulated titanium screws. *Arch Orthop Trauma Surg* 2006;126:359-363.
48. **Gruber MA, Starkweather KD, Healy WA III, Haralabatos S.** Percutaneous screw removal in slipped upper femoral epiphysis. *J Bone Joint Surg [Br]* 1996;78-B:137-139.
49. **Dewnany G, Radford P.** Prophylactic contralateral fixation in slipped upper femoral epiphysis: is it safe? *J Pediatr Orthop B* 2005;14:429-433.
50. **Hägglund G.** The contralateral hip in slipped capital femoral epiphysis. *J Pediatr Orthop B* 1996;5:158-161.
51. **Jerre R, Billing L, Hansson G, Wallin J.** The contralateral hip in patients primarily treated for unilateral slipped upper femoral epiphysis. Long-term follow-up of 61 hips. *J Bone Joint Surg [Br]* 1994;76-B:563-567.
52. **Kocher MS, Bishop JA, Hresko MT, et al.** Prophylactic pinning of the contralateral hip after unilateral slipped capital femoral epiphysis. *J Bone Joint Surg [Am]* 2004;86-A:2658-2665.
53. **Hansson G, Nathorst-Westfelt J.** Management of the contralateral hip in patients with unilateral slipped upper femoral epiphysis: to fix or not to fix—consequences of two strategies. *J Bone Joint Surg [Br]* 2012;94-B:596-602.
54. **Loder RT, Starnes T, Dikos G.** Atypical and typical (idiopathic) slipped capital femoral epiphysis. Reconfirmation of the age-weight test and description of the height and age-height tests. *J Bone Joint Surg [Am]* 2006;88-A:1574-1581.
55. **Riad J, Bajelidze G, Gabos PG.** Bilateral slipped capital femoral epiphysis: predictive factors for contralateral slip. *J Pediatr Orthop* 2007;27:411-414.
56. **Popejoy D, Emara K, Birch J.** Prediction of contralateral slipped capital femoral epiphysis using the modified Oxford bone age score. *J Pediatr Orthop* 2012;32:290-294.
57. **Castro FP Jr, Bennett JT, Doulens K.** Epidemiological perspective on prophylactic pinning in patients with unilateral slipped capital femoral epiphysis. *J Pediatr Orthop* 2000;20:745-748.
58. **Nowicki PD, Silva S, Toelle L, et al.** Severity of asynchronous slipped capital femoral epiphyses in skeletally immature versus more skeletally mature patients. *J Pediatr Orthop* 2017;37:e23-e27.
59. **Yildirim Y, Bautista S, Davidson RS.** Chondrolysis, osteonecrosis, and slip severity in patients with subsequent contralateral slipped capital femoral epiphysis. *J Bone Joint Surg [Am]* 2008;90-A:485-492.
60. **Hägglund G, Hansson LI, Ordeberg G, Sandström S.** Bilaterality in slipped upper femoral epiphysis. *J Bone Joint Surg [Br]* 1988;70-B:179-181.
61. **Sankar WN, Novais EN, Lee C, et al.** What are the risks of prophylactic pinning to prevent contralateral slipped capital femoral epiphysis? *Clin Orthop Relat Res* 2013;471:2118-2123.
62. **Kumm DA, Schmidt J, Eisenburger SH, Rütt J, Hackenbroch MH.** Prophylactic dynamic screw fixation of the asymptomatic hip in slipped capital femoral epiphysis. *J Pediatr Orthop* 1996;16:249-253.
63. **Clement ND, Vats A, Duckworth AD, Gaston MS, Murray AW.** Slipped capital femoral epiphysis: is it worth the risk and cost not to offer prophylactic fixation of the contralateral hip? *Bone Joint J* 2015;97-B:1428-1434.
64. **Seller K, Raab P, Wild A, Krauspe R.** Risk-benefit analysis of prophylactic pinning in slipped capital femoral epiphysis. *J Pediatr Orthop B* 2001;10:192-196.
65. **Canale ST, Azar F, Young J, et al.** Subtrochanteric fracture after fixation of slipped capital femoral epiphysis: a complication of unused drill holes. *J Pediatr Orthop* 1994;14:623-626.
66. **Davies A, Randall D.** Perceptions of children's participation in their healthcare: a critical review. *Issues Compr Pediatr Nurs* 2015;38:202-221.
67. **Marshall S, Haywood K, Fitzpatrick R.** Impact of patient-reported outcome measures on routine practice: a structured review. *J Eval Clin Pract* 2006;12:559-568.
68. **Petersson C.** Using health-related quality of life instruments for children with long-term conditions [PhD thesis]. *Jönköping University, Sweden: Dissertation Series* 2017;77.
69. **Aguilar CM, Neumayr LD, Eggleston BE, et al.** Clinical evaluation of avascular necrosis in patients with sickle cell disease: Children's Hospital Oakland Hip Evaluation Scale—a modification of the Harris Hip Score. *Arch Phys Med Rehabil* 2005;86:1369-1375.

Physiolysis of the Hip

Epidemiology and Hip Function



Being a grandfather, my most valued title ever, to four wonderful grandchildren, it is my sincere wish that this thesis will add a few extra details to the knowledge you will need as a paediatric orthopaedic surgeon.

Whenever I take a ride with my wife on our motorbike or go diving, I remind myself about how privileged I am. I pray every day that it will be possible for me to continue yet another time to give service to children with orthopaedic disorders, not only in Sweden but also in low-income countries.



FACULTY OF
MEDICINE

Section of Orthopaedics
Department of Clinical Sciences, Lund

Lund University, Faculty of Medicine
Doctoral Dissertation Series 2018:119
ISBN 978-91-7619-687-8
ISSN 1652-8220

