



# LUND UNIVERSITY

## BMP implants in bone formation. Studies in rabbits and rats

Jeppsson, Charlotte

2003

[Link to publication](#)

*Citation for published version (APA):*

Jeppsson, C. (2003). *BMP implants in bone formation. Studies in rabbits and rats*. [Doctoral Thesis (compilation), Orthopaedics (Lund)]. Charlotte Jeppsson, Deptm of Orthopedics, Lund University Hospital, SE-221 85 Lund,.

*Total number of authors:*

1

### General rights

Unless other specific re-use rights are stated the following general rights apply:

Copyright and moral rights for the publications made accessible in the public portal are retained by the authors and/or other copyright owners and it is a condition of accessing publications that users recognise and abide by the legal requirements associated with these rights.

- Users may download and print one copy of any publication from the public portal for the purpose of private study or research.
- You may not further distribute the material or use it for any profit-making activity or commercial gain
- You may freely distribute the URL identifying the publication in the public portal

Read more about Creative commons licenses: <https://creativecommons.org/licenses/>

### Take down policy

If you believe that this document breaches copyright please contact us providing details, and we will remove access to the work immediately and investigate your claim.

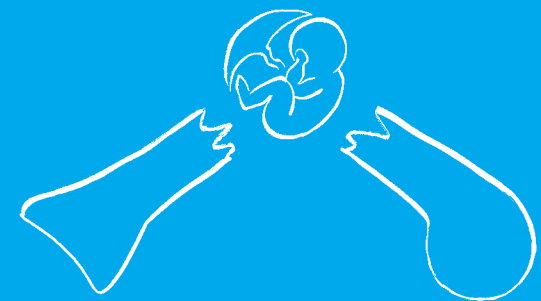
LUND UNIVERSITY

PO Box 117  
221 00 Lund  
+46 46-222 00 00

# **BMP implants in bone formation Studies in rabbits and rats**

Charlotte Jeppsson

Charlotte Jeppsson



Department of Orthopedics  
Lund University, 2003

BMP implants in bone formation. Studies in rabbits and rats



From the Department of Orthopedics  
Lund University Hospital,  
Lund, Sweden

# **BMP implants in bone formation**

## **Studies in rabbits and rats**

### **AKADEMISK AVHANDLING**

som med vederbörligt tillstånd av Medicinska Fakulteten vid Lunds Universitet  
för avläggande av doktorsexamen i medicinsk vetenskap kommer att offentligen  
försvaras i föreläsningssal F1, Centralblocket, Lunds Universitetssjukhus,  
fredagen den 16 maj 2003, kl 09.15

av

**Charlotte Jeppsson**

Fakultetsopponent:  
Professor Olle Svensson,  
Umeå

Handledare:  
Professor Per Aspenberg,  
Linköping

Organization LUND UNIVERSITY  Department of Orthopedics Lund University Hospital SE-221 85 Lund	Documentname DOCTORAL DISSERTATION	
	Date of issue 2003-05-16	
	Sponsoring organization	
Author(s) Charlotte Jeppsson		
Title and subtitle BMP implants in bone formation-studies in rabbits and rats		
Abstract <p>Bone morphogenic proteins, BMPs, are a group of endogenous proteins that are highly conserved through evolution. The amino acid sequences of about 15 different BMPs are now known and recombinant human BMPs are commercially available. Implantation of an individual BMP is sufficient to induce bone formation even at a subcutaneous site.</p> <p>Our initial studies discovered inhibition of bone formation by BMP-2 implanted in a titanium chamber model in rabbit tibia. This paradoxical effect was previously unknown, and lead to studies trying to elucidate the required conditions for BMPs to induce bone formation. Inhibition of bone formation was still found, despite testing different doses of BMP-2, another BMP (OP-1), a different carrier, and altered microenvironment. Stimulation of bone formation by BMP-2 was finally shown in a similar titanium chamber model by adding micromotion. The used titanium model induces minimal fracture surfaces when implanting the BMP and thus a minimal trauma unless micromotion was added. Therefore, we conclude that a certain amount of trauma probably is a prerequisite for BMP induction of bone formation.</p> <p>Impaction of morselized allografts in art titanium chamber models slowed down new bone ingrowth. This delay was overcome by adding OP-1 to the impacted graft. A marrow-like cavity forms by resorption behind the bone ingrowth frontier in impacted bone allografts. In situations where the graft must resist deformation during remodeling, this resorption might compromise the final result. Bisphosphonates bind to the mineral phase of bone and induce cell death to osteoclasts resorbing the bone. By treating impacted allografts in rats with a bisphosphonate we greatly increased the bone density (both new bone and remaining graft) after 6 weeks. When treating allograft with both a bisphosphonate and a BMP (OP-1) the previous increase in new bone ingrowth by OP-1 was lost, suggesting that, at least in some grafting situations, resorption may be a prerequisite for stimulation of bone ingrowth by a BMP.</p>		
Keywords: BMP, TGF- $\beta$ , titanium chamber, rabbit, rat, bisphosphonate, collagen, hydroxyapatite, bone formation, bone graft, graft resorption.		
Classification system and/or index terms (if any):		
Supplementary bibliographical information:		Language English
ISSN and key title:		ISBN 91-628-5614-6
Recipient's notes	Number of pages 71	Price
	Security classification	

Distribution by (name and address)

I, the undersigned, being the copyright owner of the abstract of the above-mentioned dissertation, hereby grant to all reference sources permission to publish and disseminate the abstract of the above-mentioned dissertation.

Signature 

Date 2003-03-21

# **BMP implants in bone formation**

## **Studies in rabbits and rats**

by

Charlotte Jeppsson



Department of Orthopedics  
Lund University Hospital  
Lund  
Sweden

Cover illustration: Per Aspenberg  
Layout: Ortonova AB, Lund  
Copyright 2003 Charlotte Jeppsson  
Printed in Sweden  
Wallin & Dalholm, Lund  
ISBN 91-628-5614-6

# Contents

**List of Papers, 2****Abstract, abbreviations and definitions, 3****Introduction, 4**

- Clinical background, 4
- Bone and bone formation, 6
- BMPs, 7
- TGF- $\beta$ s, 9
- BMPs on collagen, 10
- Bisphosphonates, 10

**State of knowledge when we started, and reasons for the studies, 12****Material and methods, 13**

- Animals, 13
- Titanium implants, 13
- Associated instruments, 15
- TGF- $\beta$ , BMP and bisphosphonate implants, 15
- Evaluation, 16

**Methodological considerations, 18****Summary of Papers, 19**

- Paper I. Transforming growth factor  $\beta$  and bone morphogenetic protein 2 for bone ingrowth: A comparison using bone chambers in rats, 19
- Paper II. BMP-2 can inhibit bone healing. Bone-chamber study in rabbits, 19

Paper III. Intraosseous BMP implants in rabbits.

Inhibitory effect on bone formation, 20

Paper IV. Enhancement of bone formation in the setting of repeated tissue deformation, 20

Paper V. Bone graft incorporation. Effects of osteogenic protein-1 and impaction, 21

Paper VI. Combination of bisphosphonate and BMP additives to impacted bone allografts, 22

**Discussion, 25**

TGF- $\beta$ 1, 25

Inhibition of bone formation by BMP-2, 25

Bone grafts and remodeling, 26

**Sammanfattning på svenska, 28**

Frakturläkning, 28

BMP, TGF- $\beta$  och bisfosfonater, 28

Metoder och delarbeten, 28

Sammanfattning, 29

**Thesis at a glance, 30****Acknowledgement, 32****References, 33****Paper I–VI**

## List of Papers

This thesis is based on the following Papers:

**I. Aspenberg P, Jeppsson C, Wang J-S and Boström M.**

Transforming growth factor beta and bone morphogenetic protein 2 for bone ingrowth –a-comparison using bone chambers in rats. *Bone* 1996; 19(5): 499-503.

**II. Jeppsson C and Aspenberg P.**

BMP-2 can inhibit bone healing. Bone-chamber study in rabbits. *Acta Orthop Scand* 1996; 67(6): 589-92.

**III. Jeppsson C, Boström M and Aspenberg P.**

Intraosseous BMP implants in rabbits. Inhibitory effect on bone formation. *Acta Orthop Scand* 1999; 70(1): 77-83.

**IV. Boström MP, Aspenberg P, Jeppsson C and Salvati EA.**

Enhancement of bone formation in the setting of repeated tissue deformation. *Clin Orthop* 1998; May(350): 221-8.

**V. Tägil M, Jeppsson C and Aspenberg P.**

Bone graft incorporation. Effects of osteogenic protein-1 and impaction. *Clin Orthop* 2000; Feb(371): 240-5.

**VI. Jeppsson C, Åstrand J, Tägil M and Aspenberg P.**

A combination of bisphosphonate and BMP additives in impacted bone allografts. Accepted for publication in *Acta Orthop Scand*.



## Abstract, abbreviations and definitions

### Abstract

Bone morphogenic proteins, BMPs, are a group endogenous proteins that are highly conserved through evolution. The amino acid sequences of about 15 different BMPs are now known and recombinant human BMPs are commercially available. Implantation of an individual BMP protein is sufficient to induce bone formation even at a subcutaneous site.

Our initial studies discovered inhibition of bone formation by BMP-2 implanted in a titanium chamber model in rabbit tibia. This paradoxical effect was previously unknown, and led to studies trying to elucidate the required conditions for BMPs to induce bone formation. Inhibition of bone formation was still found, despite testing different doses of BMP-2, another BMP (OP-1), a different carrier, and altered microenvironment. Stimulation of bone formation by BMP-2 was finally shown in a similar titanium chamber model by adding micromotion. The used titanium model induces minimal fracture surfaces when implanting the BMP and thus a minimal trauma unless micromotion was added. Therefore, we conclude that a certain amount of trauma probably is a prerequisite for BMP induction of bone formation.

Impaction of morselized allografts in rat titanium chamber models slowed down new bone ingrowth. This delay was overcome by adding OP-1 to the impacted graft. A marrow-like cavity forms by resorption behind the bone ingrowth frontier in impacted bone allografts. In situations where the graft must resist deformation during remodeling, this resorption might compromise the final result.

Bisphosphonates bind to the mineral phase of bone and induce cell death to osteoclasts resorbing the bone. By treating impacted allografts in rats with a bisphosphonate we greatly increased the bone density (both new bone and remaining graft) after 6 weeks. When treating allograft with both a bisphosphonate and a BMP (OP-1) the previous increase in new bone ingrowth by OP-1 was lost, suggesting that, at least in some grafting situations, resorption may be a prerequisite for stimulation of bone ingrowth by a BMP.

### Abbreviations and definitions

<b>Allograft</b>	grafts transferred between genetically different subjects of the same species
<b>Autograft</b>	grafts transferred within one subject
<b>BCC</b>	bone conduction chamber, used in rats
<b>BHC</b>	bone harvest chamber, used in rabbits
<b>BMP-2</b>	bone morphogenetic protein-2
<b>BMPR</b>	bone morphogenetic protein receptor
<b>CSD</b>	critical size defect
<b>DBM</b>	demineralized bone matrix
<b>HA</b>	hydroxyapatite
<b>MBHC</b>	micromotion bone harvest chamber, used in rabbits
<b>OP-1</b>	osteogenin protein-1 (bone morphogenetic protein 7)
<b>TGF-<math>\beta</math></b>	transforming growth factor- $\beta$ , three isoforms in mammals
<b>VBHC</b>	vertical bone harvest chamber, used in rabbits
<b>Xenograft</b>	tissue grafted between species

# Introduction

## Clinical background

Bone is the only tissue in the body able to heal without microscopical scarring. On the other hand fracture healing is a slow process causing long immobilization periods with consequently high social costs. The annual incidence of long bone fractures is nearly 1.5 millions per year in the United States (Zhang et al. 2002). In 5–10%, fracture healing fails (Bostrom and Camacho 1998; Bouxsein et al. 2001) giving rise to delayed healing, fibrous healing or nonhealing with subsequent problems for both the patient and the orthopedic surgeon.

The use of bone graft in orthopedic surgery greatly improves the outcome when risk of bone loss or nonhealing is the problem. Autografts are harvested from the patient, normally from the iliac crest, prolonging the operation procedure and giving rise to post operative morbidity in 8–25% of the patients (Summers and Eisenstein 1989; Younger and Chapman 1989). Allografts are harvested primarily from patients undergoing a primary hip arthroplasty, where the femoral head is removed, frozen and then re-used after testing for diseases. A small risk for viral disease transmission exists and theoretically host versus graft reactions might occur. Promoting fracture healing or replacing the need for bone grafting by adding agents like bone morphogenetic proteins would be desirable.

Bone morphogenic proteins have shown positive effects on bone formation in several animal studies (Table 1). They are now approved for clinical use and promising results are reported when introducing BMP-2 into open tibia fractures (Govender et al. 2002) showing a 44% reduction in the risk of failure and significantly higher fracture healing frequency at 12 months compared to standard treatment. The results in the treatment of tibia pseudarthrosis (Friedlaender et al. 2001) and spinal fusions (Johnsson et al. 2002) equals the standard treatment using bone autografts.

Joint arthroplasties are frequent procedures in orthopedic surgery. About one million primary

hip arthroplasties are performed annually worldwide and approximately 2% of the population in the western world over the age of 60 are subject to a total hip replacement (Murray 1998). The ten-year prosthetic survival rate in cemented hip arthroplasties due to osteoarthritis is 95% in Sweden (Malchau et al. 2002). Many of the initial problems associated with joint arthroplasties have essentially been solved, but aseptic loosening still remains the cause of 75% of the revisions (Malchau et al. 2002). Loosening might lead to osteolysis of the surrounding bone which often has to be replaced at the revision procedure. Impaction of morselized bone allograft is a way to deal with the lack of bone in hip revisions (Slooff et al. 1984; Gie et al. 1993). This impacted bone allograft was initially considered to be resorbed and replaced by new host bone (Gie et al. 1993; Nelissen et al. 1995). Recent results suggest that in part, the impacted bone allograft fragments become surrounded by ingrown fibrous tissue forming a composite that remains inert, after an initial short time of remodeling (Linder 2000). The bone allograft fragments could be regarded as foreign bodies around the implant. The indication for re-revisions shows a trend towards higher frequency for infection than the first revision (Malchau et al. 2002). Therefore, it might be desirable to increase the remodeling of the allograft and promote new bone formation after the first revision, to minimize the foreign material. The addition of bone morphogenic proteins has been tried to achieve an increased remodeling of the allograft and the formation of new autologous bone around a hip implant (Höstner et al. 2000). This resulted in pronounced distal graft resorption with concomitantly distal prosthetic migration and fracture of the cement mantle in two out of ten patients. A plausible explanation may be that the BMP not only stimulated bone formation, but also bone resorption. By perioperative systemic administration of bisphosphonates, hereby inhibiting bone resorption, the migration of knee prosthesis is diminished at one-year follow-up (Hilding et al. 2000). The combination of bone morphogenic

Table 1. Literature survey on animal studies with BMP-2 or -7.

Author/ year	BMP/ carrier	Animal / exp. time	Exp. model	Treatment groups	Results
Blokhuis et al. 2001 or den Boer et al. 2002	BMP-7/ collagen	Goat (n=40) 2, 4 w	Unilat closed tibia fracture	1 mg BMP only/ on collagen/ collagen/ untreated. Injection only. V = 2 cm <sup>3</sup>	BMP group: stiffness + torsion index increased at 2 w. All groups equal at 4 w
Grauer et al. 2001	BMP-7/ collagen	Rabbit (n=31) 5 w	Spinal fusion	1.2 mg BMP on collagen/ collagen/ autograft. V = 1-1.5 cm <sup>3</sup>	Fusion rate: BMP group 100%, collagen group 0%, autograft group 63%
Bouxsein et al. 2001	BMP-2/ collagen	Rabbit (n=96) 2, 3, 4, 6 w	Mid-ulna bilateral osteotomies	40 µg BMP on collagen/ collagen/ untreated. Sponge 8 x 20 mm	BMP increases callus and mechanical strength at 3 and 4 w. All groups equal at 6 w
Salkeld et al. 2001	BMP-7 on collagen/ autograft/ allograft	Dogs (n=24) 12 w	Ulna bilateral CSD	Allo- or autograft mixed with 0, 33, 67 or 100% BMP on collagen. V = 3 cm <sup>3</sup>	BMP group increased radiographic, histological and mechanical scores. Autograft + 33% BMP (=1.8 mg) was best
Patel et al. 2001	BMP-7 on collagen / autograft	Rabbit (n=18) 5 w	Spinal fusion / nicotine	1.2 mg BMP on collagen vs autograft. All nicotine exposed. V = 1-1.5 cm <sup>3</sup>	Fusion rate: BMP + nicotine 100%. Autograft + nicotine 25%
Tågil et al. 2000	BMP-7 on impacted allografts	Rats (n=10) 6 w	Titanium chamber tibia bilaterally	1 µg BMP on allograft vs allografts. V = 22 mm <sup>3</sup>	BMP increases bone ingrowth
Sciadini and Johnson 2000	BMP-2 on collagen / autografts	Dogs (n=27) 12, 24 w	Bilateral radial CSD	0, 0.15, 0.6 or 2.4 mg BMP on collagen vs autograft. V = 3 cm <sup>3</sup>	BMP equals autograft. High BMP dose induces cysts
Cook et al. 2000	BMP-7/ collagen	Dogs (n=14) 4, 6, 8 w	Femoral onlay strut allografts bilateral	1.25 mg BMP on collagen vs untreated.	BMP increases union, histological and radiographic scores
Lamerights et al. 1999)	BMP-2 on allografts	Goat	Titanium chambers	0, 1, 5 µg BMP on allograft. V = 50 mm <sup>3</sup>	5 µg BMP increases bone ingrowth and osteoclasts
Welch et al. 1998	BMP-2/ collagen	Goat (n=16) 6 w	Closed tibia bilateral fractures	0.86 mg BMP on collagen/ collagen. V = 8 cm <sup>3</sup> a	BMP increases callus. Torsion resistance equals controls
Hollinger et al. 1998	BMP-2 / collagen/ autograft	Rabbit (n=32) 4, 8 w	Unilateral radial CSD	35 µg BMP on collagen/ autograft/ collagen/ untreated. V = 1 cm <sup>3</sup> a	BMP or autograft heals the defect equally
Koempel et al. 1998	BMP-2 on HA	Rabbit (n=19) 4 w	3 subperiosteal skull pockets per animal	25 or 100 µg BMP on HA/ HA/ HA + drill. V = 0.1 cm <sup>3</sup> a	BMP increases adherence and histological bone ingrowth
Aspenberg et al. 1996b	BMP-2 on HA	Rats (n=21) 6 w	Ti-chamber tibia bilaterally	1, 33 or 1000 ng BMP on HA vs HA. V = 22 mm <sup>3</sup>	BMP increases bone ingrowth
Yasko et al. 1992	BMP-2 on DBM	Rats (n=45) 9 w	Femoral CSD	0, 1.4 or 11 µg BMP on DBM. V = 24 mm <sup>3</sup> a	11 µg BMP increases callus and torsion index
Tourimi et al. 1991	BMP-2 on DBM	Dogs (n=26) 3, 6 mo	Mandibular CSD	250 µg BMP on DBM (n=12)/ DBM (n=10)/ empty (n=4). V = 10 cm <sup>3</sup> a	BMP + DBM group, healed at 3 months. DBM or empty groups, fibrous healing

CSD – critical size defect. DBM – guanidinium chloride extracted demineralized bone matrix. All BMPs are recombinant human bone morphogenetic proteins. Collagen – collagen type I. n – total number of animals in the study. w – weeks. mo – months. HA – hydroxyapatite. V – volume. <sup>a</sup> Approximation from information in article by author of this table.

proteins and bisphosphonates to achieve increased bone remodeling, yet sustain high bone density in the area is therefore theoretically interesting.

## Bone and bone formation

Bone is a tissue consisting of minerals, proteins, water, cells and macromolecules like fat and sugar. The mineral, or inorganic, part is analogue to crystalline hydroxyapatite,  $(\text{Ca}_{10}(\text{PO}_4)_6(\text{OH})_2)$  and corresponds to 60-70% of the bone. 5-8% of the bone weight is water, depending on factors like age, skeletal part and diet. The rest, approximately 25% of the bone, is referred to as the organic part of the bone and consists to 90% of collagen type I and to 10% of cells, noncollagenous matrix proteins, minor collagen types, lipids and macromolecules.

There are mainly three different kinds of bone cells: *osteoblasts*, *osteocytes*, and *osteoclasts*. Osteoblasts and osteocytes are responsible for bone formation, and their main difference is their location. Osteoblasts outline the surface of the bone and are dedicated to the process of bone matrix synthesis while osteocytes are surrounded by a mineralized matrix. Osteoblasts and osteocytes develop from mesenchymal stem cells while osteoclasts develop from the hematopoietic stem cell lineage. A concomitant disposal and removal of bone is synchronized in the Bone Modeling Units (BMU) where osteoclasts in a frontal cutting cone digest the bone and following osteoblasts deposit new bone. In cortical bone this BMU measures approximately 2 mm with a diameter of 0.2 mm enclosing the nerve and vascular supply and after disposal of new bone a new Haversian canal or osteon is formed. Osteocytes can live for several decades while osteoblasts have a lifespan of 3 months, osteoclasts 2 weeks and the BMU unit 6-12 months (Parfitt 1994). The ongoing concomitant removal and disposal of bone in mature bone is referred to as remodeling. *Lining cells* are flattened cells outlining the bone surfaces and one of the two modes of terminal differentiation for the osteoblasts. They act as gatekeepers, able to be informed of the need for remodeling, and then to either execute or mediate preparation of the bone site, recruit mononuclear preosteoclasts and

preosteoclasts to the site where these fuse into multinuclear osteoclasts (Parfitt 1994).

*Microscopically*, bone is either woven or lamellar. Woven bone is the bone first formed in embryonal life and in newborns as well as in fracture callus, in the metaphyseal region of growing bone, osteogenesis imperfecta, Pagets disease and in tumors. Lamellar bone formation starts at about 1 month after birth, and at 4 years most bone in the skeleton is lamellar.

*Structurally*, bone is either cancellous (trabecular or spongy) or compact (dense or cortical). Compact bone has a mass four times cancellous bone. Remodeling is an ongoing surface phenomenon on periosteal, endosteal and trabecular surfaces as well as in Haversian canals causing regeneration of the whole adult skeleton every ten years (Manolagas 2000). Since remodeling is a surface event, and surface area in cancellous bone is larger, metabolic turnover in cancellous bone is five to ten times higher than in cortical bone.

Bone formation is either *intramembranous* or *endochondral*. In intramembranous bone formation, the osteoblasts form a calcified osteoid (bone matrix) within a collagenous framework, while in endochondral bone formation the osteoid is formed within a cartilaginous framework. Intramembranous bone formation occurs at the periosteal surface of all bone and in parts of the pelvis, scapula, clavicles and skull, while endochondral bone formation occurs at the growth plates and within fracture callus. Fracture healing proceeds concurrently through both the endochondral and the intramembranous pathways. Bone healing heals fractures, arthrodeses and osteotomies. It is a sequential cascade, including: 1) hematoma, 2) the formation of a granulation tissue including an inflammatory phase with subsequent angiogenesis and cartilage formation, 3) the replacement of the granulation tissue by a temporary callus (cartilage calcification, cartilage removal and bone formation), 4) the replacement of the temporary callus by well-oriented lamellar bone, and 5) the reshaping of the bone by remodeling (Frost 1989a; Einhorn 1998; Barnes et al. 1999; Frost 2001). Osteoblasts and osteoclast for this cascade have to be recruited from stem cells. This is mediated by creating physical and biochemical signals to cells in local and multicellular mediator mechanisms in the

fracture region (Frost 1989b). Several members of the TGF- $\beta$  superfamily, a family of closely related secreted signaling molecules, are actively involved in fracture healing. Although these members are closely related, both structurally and functionally, each one has a distinct temporal expression pattern and potentially unique role in fracture healing (Si et al. 1997; Cho et al. 2002). TGF- $\beta$ 1 mRNA is found in high levels in unfractured bone, peaks on day 1 after fracture and then declines to levels equal to unfractured bone again, whereas TGF- $\beta$ 2 and - $\beta$ 3 mRNA is not detectable in unfractured bone but peaks during chondrogenesis. BMP-2 mRNA peaks initially on day 1 suggesting an early role in the cascade, and elevated levels are also found during day 14–21 while BMP-7 shows a restricted period of expression day 14–21 when the resorption of the calcified cartilage and the maximal recruitment of osteoblasts occurs (Cho et al. 2002). Different concentrations also seem to elicit different answers; BMP-4 is found to stimulate chemotaxis of human peripheral blood monocytes at femtomolar concentrations (Cunningham et al. 1992), act as a mitogen on mesenchymal cells at picomolar concentrations and initiate *in vitro* chondrogenesis at a slightly higher concentration (Reddi 2001).

Bone formation induced by demineralized bone matrix follows the endochondral bone formation pattern. First, plasma fibronectin binds to the implanted DBM. This attracts and attaches mesenchymal stem cells that proliferate with a maximum on day 3. There is evidence of chondroblast differentiation on day 5 and maximum chondrogenesis is found on day 7–8. Hypertrophy of the cartilage with signs of mineralization of the cartilage matrix is found on day 9 and angiogenesis and vascular ingrowth, a prerequisite for osteoblast differentiation, is evident on day 10–11. The newly formed bone is then remodeled (Reddi 2001).

## BMPs

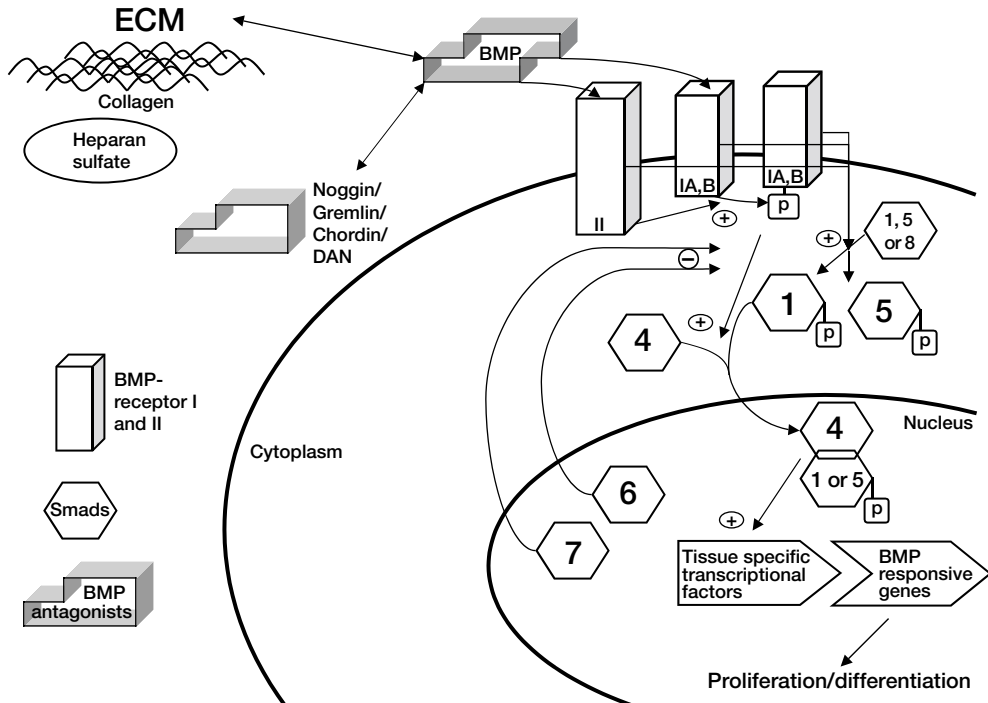
Hippocrates (460–370 BC) was the first to consider the skeletons enormous potential for healing and also formulated the possibility of responsible endogenous substances (Reddi 1997). Over 2000 years elapsed before the idea of an existing bone

morphogenic protein was again formulated, first by Levander 1938 (Levander 1938) and later by Lacroix, who in 1945 referred to it as an “osteogenin” substance capable of initiating bone growth (Lacroix 1945). The breakthrough was not made until 1965 by Urist, who showed that segments of demineralized, lyophilized rabbit bone matrix, DBM, induced new bone when implanted intramuscularly in rabbits (Urist 1965).

The bone formation cascade induced by demineralized bone matrix is identical to the bone formation in fracture healing in adults and in embryonal limb buds. Therefore, the signal substances responsible for fracture repair were to be found in the demineralized bone matrix.

Approximately 3% of the organic part of the bone (the demineralized bone matrix) are dissolvable proteins while the remaining residue consists mainly of insoluble collagen type I. Of the soluble extract, only fractions with a molecular weight less than 50 kD consistently produced bone after reconstitution with allogenic insoluble collagen. Estimatedly only 1  $\mu$ g of an active osteogenic fraction is present in a kilogram of bovine bone (Wozney et al. 1988) and over a ton of bone was needed to be able to figure out the amino acid sequence (Reddi 1998) which led to the cloning of recombinant human BMP-2 and -3 (Wozney et al. 1988) and subsequently the possibility to produce the BMPs by recombinant DNA techniques using chinese hamster ovary cell lines (Wang et al. 1990).

At present, about 16 BMPs are identified named BMP 1–15 (Barnes et al. 1999; Kirker-Head 2000). Except for BMP-1, which is a pro-collagen C protease, they are all members of a family of secreted signaling molecules referred to as the TGF- $\beta$  superfamily (Wozney and Rosen 1998; Reddi 2001). The TGF- $\beta$  superfamily consists of 43 members of structurally related proteins that are found in different kinds of organisms from fruit fly to human, including bone morphogenic proteins (BMPs), growth and differentiation factors (GDFs), decapentaplegic (DPP), activin, Nodal, together with several forms of TGF- $\beta$ s (Shore et al. 1998). The BMPs are phylogenetically highly conserved members of the TGF- $\beta$  superfamily, and genes with the highest degree of similarity to the mammalian BMP family have been found in the fruit fly (Kaplan and Shore 1998). The bone



**Figure 1.** Bone morphogenetic protein receptors, BMPR, and signaling cascade. Extracellular matrix (ECM) molecules like collagen and heparan sulfate bind BMPs and determine bioavailability to the BMP receptors. Also, specific BMP antagonists e.g. noggin, gremlin, chordin, and DAN bind to the BMP with similar affinity as the BMP-receptors. BMPs interact with both BMPR-I and II. The signaling cascade is initiated by interaction between BMPR type I and II which starts the phosphorylation of Smad 1, 5, and 8. Phosphorylated Smads 1 and 5 interact with Smad 4 and these complexes enter the nucleus activating the transcriptional machinery. Smads 6 and 7 reside mainly in the nucleus and inhibit the activated phosphorylation of Smads 1, 5 and 8.

morphogenetic proteins are dimeric molecules consisting of two polypeptide chains of about 120 to 140 amino acids each with three intrachain disulfide bonds. A single interchain sulfide bond is very important as the BMP loses all its activity without it (Griffith et al. 1996). In the post-natal skeleton, BMPs are distributed along the collagen fibers, in periosteal cells and in mesenchymal cells of marrow stroma (Kirker-Head 2000).

The BMPs bind to specific BMP cell receptors named type BMPR-IA, -IB and -II. They are serine/threonine protein kinases and when BMPs bind to them, proteins inside the cell named Smads are activated by phosphorylation. There are eight different Smads, of which Smad 1, 5 and 8 are affected by the BMP-receptor. After phosphorylation Smad 1 and 5 bind to Smad 4, creating a complex that enters the nucleus and activates the BMP-responsive genes. Inside the nucleus, Smad 6 and 7 mainly reside and act by turning off the

phosphorylation of Smads 1, 5 and 8 by the BMP-receptor type I showing its intricate self-regulation (Kirker-Head 2000; Reddi 2001)(Figure 1). Specific BMP antagonists, such as noggin (Zimmerman et al. 1996), chordin, DAN and gremlin, also regulate the BMP-effect. They bind to BMP with the same affinity as BMP-receptors, and are interesting in diseases showing dysregulation or overexpression of BMP pathways such as fibrodysplasia ossificans progressiva (Kaplan and Shore 1998). Once released from their carriers, both BMPs and TGF- $\beta$ s are rapidly cleared from the circulation by the liver (Winn et al. 1998).

Many BMPs have a multiplicity of different biological actions. BMPs are involved in embryonal development playing an important role in cell proliferation and mesoderm formation, neural patterning, tooth formation, skeletal development, bone marrow formation and limb morphogenesis (Winnier et al. 1995) (Shore et al. 1998; Guha et al.

Table 2. Summary of BMP subfamilies and effect in gene dysfunction or overexpression (Wozney and Rosen 1998; Reddi 2001; Wozney 2002).

Subfamily	BMP	Knockout mice	Overexpression
BMP 2/ 4	BMP-2 (BMP-2a)	Lethal, defects in amnion, chorion and cardiac development <sup>a</sup>	E –changes skeletal pattern A – induces bone
	BMP-4 (BMP-2b)	Lethal, defects in mesoderm <sup>b</sup>	Same as BMP-2. (Overexpression in FOP (Shore et al. 1998))
BMP-3	BMP-3/ osteogenin	Viable, increased trabecular bone density <sup>c</sup>	
OP-1/ BMP-7	BMP-3b (GDF-10)		
	BMP-5	Viable, missing skeletal elements. Impaired fracture repair <sup>d</sup>	A – induces bone
	BMP-6	Viable, slight delay in sternal ossification <sup>e</sup>	Same as BMP-2
	BMP-7 (OP-1)	Lethal, defects in kidney, eye, rib, skull, limbs <sup>f</sup>	A: induces bone
	BMP-8 (OP-2)	Defect in spermatogenesis or placenta development <sup>g</sup>	
others	BMP-8B (OP-3) (mouse)	Infertile <sup>g</sup>	
	BMP-9 (GDF-2)		
	BMP-10		
CDMP	BMP-11 (GDF-11)		
	BMP-12 (CDMP-3 or GDF-7) BMP-13 (CDMP-2 or GDF-6)		A – induces tendon ligaments A – induces cartilage, tendons/ ligaments
	BMP-14 (CDMP-1 or GDF-5)	Viable mice and humans with short limbs and joint defects <sup>h</sup>	A – induces cartilage, tendons/ ligaments
others	BMP-15 BMP-16		

Knockout mice = no gene for producing the BMP, GDF = growth/differentiation factor, CDMP = cartilage-derived morphogenetic protein, E = in embryos, A = in adults.

<sup>a</sup> Zhang and Bradley 1996, <sup>b</sup> Winnier et al. 1995, <sup>c</sup> Daluiski et al. 2001, <sup>d</sup> Kingsley et al. 1992, <sup>e</sup> Solloway et al. 1998, <sup>f</sup> Jena et al. 1997, <sup>g</sup> Zhao et al. 1998, <sup>h</sup> Storm et al. 1994.

2002) (Table 2). For example, spatial distribution of chicken and duck embryo interdigital rays and interdigital spaces during limb bud development is controlled by the BMPs through programmed cell death in the mesenchyme of the interdigital spaces (Zou and Niswander 1996). BMPs are able to stimulate the steps in bone formation—hemotaxis and mitosis, differentiation into cartilage and subsequently the replacement by bone. BMP in bone formation is now extensively investigated in animals, generally showing increased bone formation or healing of critical size defects (Table 1).

### TGF-βs

TGF-βs are ubiquitous in the body and their functions include regulation of regenerative processes in tissues of mesenchymal origin (Wahl 1992; 1994). They also interact in the regulation of

growth, inflammation and host defense, development, tissue repair and tumorigenesis. The most concentrated natural source of TGF-βs are the platelets, which release their stock early in the inflammatory phase. TGF-βs are then generated by inflammatory cells themselves, promoting differentiation of undifferentiated leukocytes, and subsequently facilitate resolution of the inflammation and promote tissue repair. Excess levels of TGF-βs within a lesion have been associated with unresolved inflammation with fibrotic events, and accumulation in the circulation is associated with serious infections (Centrella et al. 1991; Border and Ruoslahti 1992; McCartney-Francis and Wahl 1994). Five isoforms of TGF-β are identified. TGF-β1, 2 and 3 are found in many species including humans, TGF-β4 is found in chickens and TGF-β5 in amphibians, sharing 64–82% similarity of the amino acid sequence (Centrella et al. 1991). Of these, TGF-β1 and TGF-β2 have received most

attention regarding fracture repair (Barnes et al. 1999). The effect of exogenous TGF- $\beta$  on bone formation in animal studies has been both stimulation (Lind et al. 1993; Sumner et al. 1995; Ripamonti et al. 1997). However, inhibition/ no effect on bone formation is also found (Aufdemorte et al. 1992; Lind et al. 1994; Critchlow et al. 1995) perhaps reflecting their pluripotency in the organism.

### BMPs on collagen

BMPs have a natural absorbance to collagen, which is the major component of the extracellular matrix (Winn et al. 1998). Commercially available collagens are usually derived from bovine tendon but can also be derived from bone (whose mineral component is removed) or skin (Winn et al. 1998; Kirker-Head 2000). Collagen can be purified in large scale, and the purification process yields a collagen dispersion, which can be fabricated into macroporous scaffolds. Immunogenicity is reduced by enzymatic and crosslinking treatments (Khor 1997; Winn et al. 1998). Collagenous xenograft has been used since the 60s (Khor 1997) and based on experience generated in preclinical animal studies, collagen has provided a satisfactory delivery system independent of implantation site, providing a permissive substrate for attachment and differentiation of cells (Winn et al. 1998). Antibodies to bovine collagen were found in 17% of the patients treated with BMP-2 on a collagen sponge, but also in 6% of the patients not receiving any collagen at all (Govender et al. 2002) without any relation to adverse events.

BMPs are rapidly cleared from the circulation once released from the implant site (Winn et al. 1998; Bouxsein et al. 2001) and, like other growth factors, this is probably caused by liver uptake and catabolism (Kirker-Head 2000). There are indications that BMP implant devices with higher BMP retention elicit more bone formation (Winn et al. 1998; Kirker-Head 2000; Uludag et al. 2001). Collagen binding of BMP is sensitive to various changes in vitro. BMP binding increases with collagen mass, time after soaking—mainly the first 5 minutes, and has an optimal pH range between 4.5 and 5.1 (Freiss et al. 1999). Crosslinking, by formaldehyde treatment, which is used to reduce

immunogenicity and to provide control over in vivo biodegradation of the collagen (Winn et al. 1998), also decreases BMP-binding whereas ethylene oxide sterilization does not interfere (Freiss et al. 1999). Despite decrease in BMP-binding capacity by crosslinking, retention of BMP at the implant site is increased if the collagen has been subjected to crosslinking or sterilization, but these changes are minor.

Radiolabeled BMP on collagen sponges implanted in critical size defects in ulna in rabbits reveals that immediately after implantation, only 73% of the BMP soaked on the collagen is found at the implantation site, and there is an exponential clearance from the site, with 37% remaining after 1 week and only 8% after 2 weeks (Bouxsein et al. 2001). When analyzing the presence of antibodies to rhBMP-2 in humans, 4% of patients treated with rhBMP-2 developed antibodies without any relation to adverse events or allergic response (Govender et al. 2002). However, 1% of the control group also had antibodies without being exposed to the BMP-2 device.

### Bisphosphonates

Bisphosphonates are stable analogs of naturally occurring pyrophosphates that adsorb to bone. Inorganic pyrophosphate prevents ectopic calcification in vivo and may play a role in mineral dissolution and deposition in the organism. It also has a strong affinity to calcium phosphate and therefore for bone mineral. The P–O–P bond in inorganic pyrophosphate is changed into a P–C–P bond in the synthetic bisphosphonate analogs. The binding of bisphosphonates to hydroxyapatite bone mineral is almost permanent and is considered to last until the bone is resorbed. During resorption, osteoclasts internalize the bisphosphonate, which interferes with cellular mechanisms leading to impaired osteoclast function and finally apoptosis (Russell and Rogers 1999; Manolagas 2000; Rogers et al. 2000). There is some evidence that bisphosphonates also affect the osteoblasts making them release a minor factor (<10 kD) that indirectly inhibits osteoclast activity or formation (Rogers et al. 2000). Many bisphosphonates are used in clinical disorders like Pagets disease,



myeloma, bone metastases or osteoporosis. By treating bone allograft with a bisphosphonate, it is possible to increase the amount of remaining graft after remodeling without affecting new bone

ingrowth in a titanium rat model (Aspenberg and Åstrand 2002) and hereby the mechanical strength of the graft is probably improved.

## State of knowledge when we started, and reasons for the studies

When the first two experiments were planned, the expectations on BMPs potential as a miracle drug for bone healing problems were high and generally accepted. In 1992, Per Aspenberg had received a small amount of BMP-2 as a gift from the Genetics Institute and implanted it in some rabbit chambers. He surprisingly found empty chambers instead of bone formation, and due to lack of more BMP-2 and self-confidence in possible results, no further experiments were performed. 1995 reports of cyst formation by BMPs (Sciadini et al. 1995) made us curious about the old results, leading us to initiate the evaluation of BMP in our titanium chamber models. The inhibitory effect in the bone harvest chamber led to many new experiments trying to elucidate the conditions required to achieve positive response, summarized in Paper III. Simultaneously we came in contact with Dr Mathias

Boström, orthopedic surgeon at the Hospital for Special Surgery, New York, also conducting animal experiments with BMP-2 and interested in the chamber technique which lead to the micromotion study in Paper IV.

Studies in our lab group on impacted morselized bone allografts had shown unexpected inhibition in new bone ingrowth by impaction in the rat chamber model (Tägil and Aspenberg 1998). As we knew that BMP stimulated bone ingrowth into this chamber on a collagen- or a hydroxyapatite carrier (Paper I and III), we now proceeded on this track in Paper V. Clinical reports of bone resorption and failure when mixing BMP-7 and impacted morselized bone allografts in hip revisions (Höstner et al. 2000) then led to experiments on allograft pretreated with combinations of bisphosphonate and BMPs in order to avoid resorption.

## Material and methods

### Animals

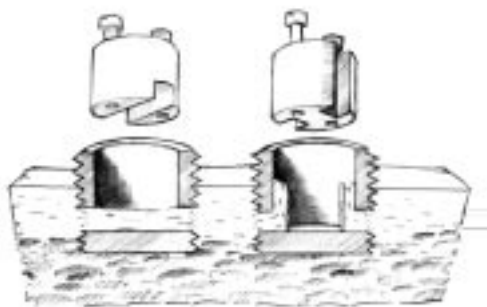
Totally 21 rabbits, a destination raised crossbreed between lop-eared and white native breed, were used. They are easy to handle as being less aggressive than the white native breed, yet not as expensive, big or hard to find as the lop-eared breed. All the rabbits were minimum 9 months old and considered skeletally mature at the start of experiments. Both female and male rabbits were used.

Rats used in the studies were outbred destination raised male Sprague-Dawley rats (320–370 g) except for the ones used in the immunological study in Paper V where inbred Sprague-Dawley (180–390 g) and Wistar (155–180 g) rats were used. Female rats were used as graft donors in Paper V and VI. The Sprague-Dawley rat is big, growing to a weight of 300–350 g in three months, and is sexually mature at 6 weeks of age. The great size of the rat is a prerequisite for inserting the titanium chambers into the tibiae. Totally 298 rats were used for Paper I, III, V, and VI.

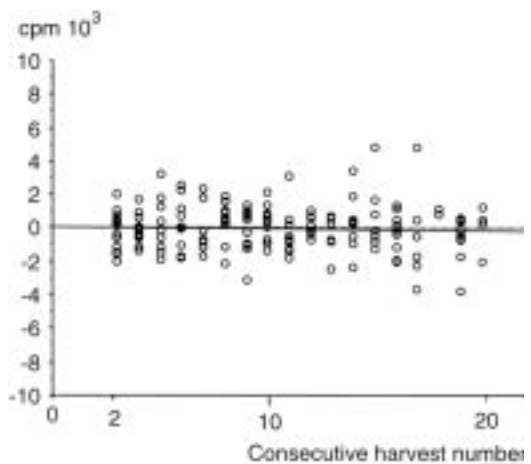
Institutional guidelines for treatment and care of experimental animals were followed.

### Titanium implants

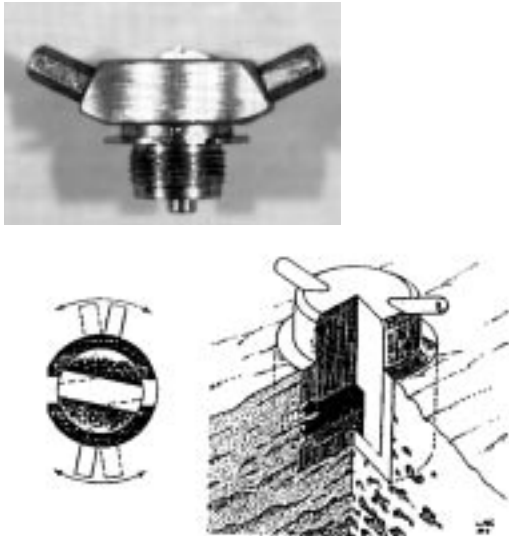
In Paper II and III we used the *Bone Harvest Chamber* (Figure 2), a 7-mm high and 6-mm wide titanium cylinder, threaded so that it can be screwed into the proximal medial tibia metaphysis of adult rabbits (Albrektsson et al. 1983). It provides a standardized spontaneously healing skeletal defect. The cylinder contains a piston-like core with a 1×1×5 mm groove facing the bottom of the cylinder. This groove is co-axial with holes in the outer cylinder, providing a continuous canal through the entire device for tissue ingrowth. The cylinder will osseointegrate with the surrounding bone in a period of 6 weeks, but one end sticks out of the bone. From this end the core can be pulled out, thus exposing the tissue inside the ingrowth canal which can be harvested without disturbing the surrounding bone. The chamber can be used for repeated harvesting, and bone formation in the chamber has been shown to be quite sensitive to various forms of disturbance (Goodman 1994), yet bone ingrowth remains stable over as many as 20 consecutive harvests (Thorén 1994) (Figure 3).



**Figure 2.** The rabbit bone harvest chamber, BHC, to the left, with the osseointegrated part inside cortical bone, and the removable inner core lifted. The vertical bone harvest chamber, VBHC, to the right has a modification of the inner core allowing contact with extraosseous tissue.




**Figure 3.** Scintimetric values for 170 harvested bone pairs. Bone rods were formed after 5 weeks in empty rabbit BHC. The horizontal axis shows how many times the BHC has been harvested. The vertical axis shows the difference in scintimetric activity from the mean value in the same animal. Reprinted with permission from author (Thorén 1994).



**Figure 4.** The rabbit Micromotion Bone Harvest Chamber, MBHC. Top; photograph, bottom; schematic drawing with cross section showing the ad latus deformation exerted by micromotion.

In Paper III we also used *The Vertical Bone Harvest Chamber* (Figure 2). It was created by replacing the piston-like core in the bone harvest chamber by a core in which the horizontal groove was replaced by two parallel vertical grooves measuring  $1 \times 1 \times 7$  mm. These two vertical grooves connect the ingrowth openings in the bottom of the chamber with the subcutaneous tissue outside the top. Thus, the ingrowth openings are not connected to each other but cells from the surrounding tissue may enter the chamber.

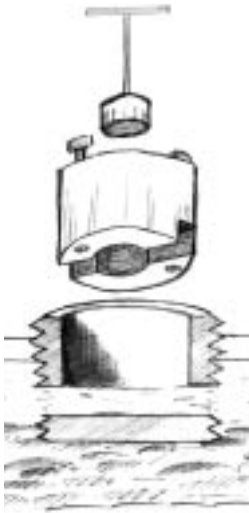
In Paper IV we used the *Micromotion Bone Harvest Chamber* (Figure 4). It is a modification of the bone harvest chamber also consisting of a cylindrical titanium implant with a central removable core. Round holes in the cylinder correspond to a cylindrical canal through the core, creating a 5-mm long, diameter 1 mm, transverse canal for tissue ingrowth. The core has two horns at the top that can be grasped through the skin, so that the core can be rotated to create an ad latus motion on the canal at the interface between the cylinder and the core. The tissue becomes slightly deformed and considerably squeezed at the ends of the canal. The magnitude of movement at the interface is predetermined to 0.25 mm in each direction by the size of a stop screw. The subcutaneous horns act as lever arms and the resistance created by tissue in the canal was easily



**Figure 5.** The rat Bone Conduction Chamber, BCC. Left; photograph of BCC parts, scale in mm. Right; BCC inoperated in bone allowing tissue to grow into the interior space.

overcome. The chamber can be used for repeated harvesting of the ingrown tissue.

*The Bone Conduction Chamber* (Figure 5) is a rat chamber used in Paper I, III, V, and VI. It consists of a threaded titanium cylinder, formed from two half cylinders held together by a hexagonal closed screw cap. One end of the implant is screwed into the bone. The cylindrical space inside the implant has a diameter of 2 mm, and is 7 mm long. There are two ingrowth openings located at the bone end of the chamber and ingrowing tissues enter the cylindrical space at the cortical level. This space extends far out into the subcutaneous region, and the ingrown bone-derived tissue has the possibility to fill the chamber without competing with other tissues. Without an osteoconductive material in the space, new tissue, mostly bone, will fill a small portion of the chamber within 6 weeks (Aspenberg and Wang 1993). The chamber can be filled with porous materials with possible osteoconductive properties, and the ingrowth of new bone or other tissues into the material can be measured on histological slides. The advantage of this model is that bone ingrowth can be measured in millimeters. Different osteoconductive materials have shown different ingrowth distances (Aspenberg and Wang 1993) where bone ingrowth distances at 6 weeks were; 0.8 mm into



**Figure 6.** Specially designed core and hole-cutter to allow removal of only the central third of the ingrown tissue at the bottom of the BCH canal for the adjacent bone study in Paper III.

empty chambers, 1.4 mm into hydroxyapatite and 2.4 mm into allografts.

In Paper II we used a 5 mm long *titanium tube*; open at both ends and with an inner diameter of 1 mm. It was designed to mimic the ingrowth canal of the BHC, and was used for subfascial implantation of collagen carrier with or without BMP. The tubes were used to ensure that we harvested the area of interest after implantation in soft tissue, as the rabbits were not to be killed at the end of the experiment. The tubes had two external circumferential grooves enabling them to be sutured to a specific site.

### Associated instruments

In Paper III, we used a specially designed *core and hole cutter* (Figure 6) in order to resect only the central third of the ingrown bone rod crossing the bottom of the opened BHC. We implanted the collagen into this created defect in the bone rod with and without BMP-2 in order to study the borders between existing ingrown tissue and implanted collagen with and without BMP-2.

In Paper V and VI bone grafts were harvested from donor rats using specially designed *hole cutter* with an inner diameter and length corresponding to



**Figure 7.** Histology of impacted bone allograft, not implanted. Bone density 65%.

the size of the bone conduction chamber interior space where they were to be fitted. Impacted grafts were produced using a specially designed *impactor* in which two cancellous bone cylinders from the same donor animal were compressed into approximately the size of one (Figure 7). The impactor had a cylindrical interior of the same diameter as the inside of the bone conduction chamber. A piston could then be inserted into the cylinder to impact the graft along its longitudinal axis. The piston did not fill the whole inner diameter. A constant force of 80 N was applied on the free end of the piston for one or two minutes during which, fat and fluid could escape between the piston and the cylinder wall. Applied pressure was calculated to be 25 MPa. The impactor was opened opposite the piston and the graft could be removed as a bone pellet.

### TGF- $\beta$ , BMP and bisphosphonate implants

The recombinant human TGF- $\beta$ 1, BMP-2 and buffer solutions used in Paper I, II, III, and IV were gifts from the Genetics Institute (Cambridge, MA, USA). The recombinant human BMP-7 used in Paper III, V, and VI was a gift from Stryker Biotech (Natick, Massachusetts, USA). The clodronate used in Paper VI was a commercially

available [60 mg/ml] infusion substance (Bonefos<sup>®</sup>, Astra, Sweden).

Coralline hydroxyapatite used in Paper I was "Interpore IP 200", from Interpore International (Irvine, CA, USA), manufactured to fit precisely into the chambers.

Helistat<sup>®</sup> C collagen carrier was used in the BMP-2 experiments. It is prepared in proprietary manner by Colla-Tech, Inc. from bovine tendon and is a crosslinked atelopeptide product that is nonimmunogenic and composed of type I collagen.

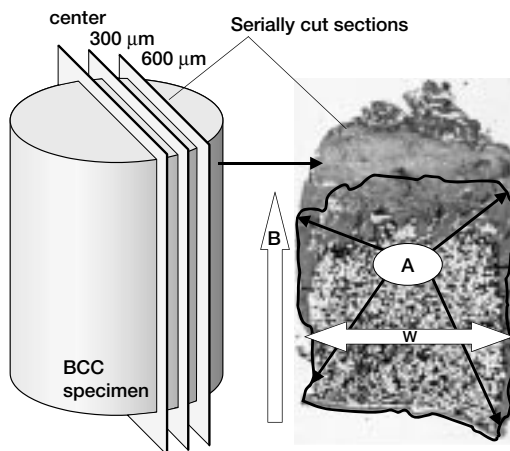
## Evaluation

### Histology

All handling and evaluation of specimens were blinded for treatment. Specimens in Paper I, II, III, V, and VI were fixed in 4% phosphate buffered formalin, decalcified in Parengy's or EDTA solution and paraffin embedded. They were cut parallel to the long axis of the chamber with a microtome and stained with hematoxylin and eosin. All histological measurements were performed using a computerized video system (Videoplan<sup>™</sup> Kontron Bildanalyse, Esching, Germany) attached to the microscope, by drawing on a digital table.

In the *rat Bone Conduction Chamber* studies in Paper I, III, V, VI, and in the *rabbit vertical bone harvest chamber* study in Paper III, sections were taken in the center and at 300 and 600  $\mu\text{m}$  from the center of the specimen, each section 5  $\mu\text{m}$  thick (Figure 8). Measurements were performed on these three sections in each specimen. The area of the new ingrown bone was measured by circumscribing it on the digitizing table using the Videoplan<sup>™</sup> equipment at 31–40 $\times$  screen magnification. This area includes marrow cavities and carrier/graft remnants that have been surrounded by new bone. The mean bone ingrowth distance in each slide was calculated by dividing the new bone area with the width of the specimen. The mean of the three sections yielded as a value for the specimen. The total tissue ingrowth distance, which is the distance from the ingrowth end of the chamber to the fibrous ingrowth frontier, was measured in the same way as bone ingrowth.

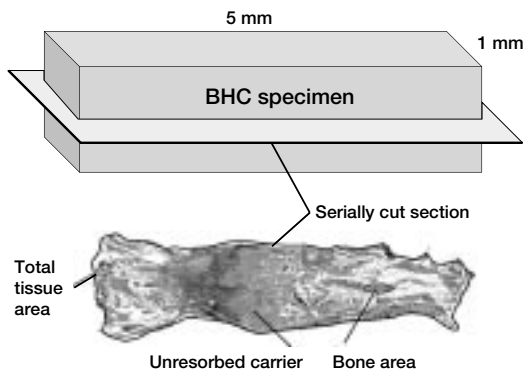
In Paper VI, bone density was measured by



**Figure 8.** Histological measurement of rat BCC and rabbit VBHC specimens. A –circumscribed bone area, W –width of the specimen, B –bone ingrowth distance achieved by calculating  $A/W$ . The mean of the three sections at 0, 300, and 600  $\mu\text{m}$  from the center yields as a value for the specimen. Similar measurement for total tissue ingrowth, but area then includes whole specimen.

manual point counting of an area of interest ranging from the bottom of the chamber (at the ingrowth end) to the frontier of the advancing new bone formation. This area of interest only comprised the central third of the specimen so that the bone close to the titanium side walls was not included. Points superimposing new bone or dead graft were counted and registered as "bone points". The number of bone points on the slide was divided by the sum of bone points plus remaining points and yielded as a mean for that slide. The mean of all three slides was then used to yield one final value for each chamber.

In the *rabbit Bone Harvest Chamber* studies in Paper II and III (except the vertical BHC), the whole specimens were serially cut and measurements were performed on one section per specimen (Figure 9). Histomorphometric analyses were performed using a microscope connected to a computerized video digital table system at a screen magnification of  $\times 125$ . The entire specimen and the bone areas were circumscribed with a pen on the digitizing table and the bone area was expressed as the percentage of the total area of the section. All measurements were performed by one person only. In Paper III, the "adjacent bone" specimens were studied by morphology only.



**Figure 9.** Histological measurements for rabbit BHC and MBHC. Bone area is calculated by summarizing all circumscribed bone areas in one section.

In Paper IV, specimens were fixed in 10% buffered formalin and embedded in JB-4 (Electron Microscopy Science, Fort Washington, PA, USA).

Undecalcified 5  $\mu\text{m}$  sections, trichrome- (colors bone blue) and von Kossa-stained (colors bone dark black) were measured using an image analysis system (Image 1, Universal Imaging Group, West Chester, PA, USA). Three longitudinal sections were measured for each specimen and a mean was calculated to yield for each specimen.

#### ***Additional evaluative tools***

In Paper II and the experiment with low BMP-2 dose in Paper III, 99-technetium methylene diphosphonate was administered intravenously as a bolus dose prior to harvesting the specimens. Gamma emission from the specimens was measured and corrected for time dependent delay.

In Paper III, low BMP-2 dose experiment, after decalcification, the decalcifying-solution was sent for  $\text{Ca}^{2+}$  analysis by atom absorption spectrometry (Dept. of Plant Ecology, Lund University, Sweden).

## Methodological considerations

### Animals

Animal experiments provide methods by which many variables can be controlled; they are generally obtained from the same breed and living environment, not subjected to systemic agents and do not have known pathologic conditions. Surgical intervention is controlled, keeping local conditions consistent and outcome can be precisely measured, providing relatively reproducible and quantifiable information that is difficult to obtain from human subjects, cadaver studies, or simulations such as finite element analysis.

Homogenous populations of rats are available at low costs, but their bone physiology differs from humans. The organic bone matrix in humans consists to 90% of collagen, whereas in rats only 60% (Jorgensen et al. 1991). Cortical bone in rats consists of an inner layer of irregular oriented nonlamellar bone and an outer layer of concentric lamellar bone which occurs first at the age of three months (Danielsen et al. 1993). Rats in our studies were circa 9 weeks old, which may have interfered with the bone formation as at that stage the rat tibia still undergoes modeling due to growth.

Harversian remodeling is sparse in rats and the degree of neatly oriented cortical osteons is lower than in humans, this may be but minor interference when testing effects on intramembranous bone formation. Despite the rat being a rodent, the cellular mechanisms involved in bone formation are much the same as in humans, and rat skeleton provides an appropriate model for studying bone formation and induction by morphogens (Frost and Jee 1992; Sandhu and Khan 2002).

The rabbit, also being a rodent, was the initial animal used to show ectopic bone formation by demineralized bone matrix (Urist 1965), and has since been widely used as a model effectively closing critical size defects treated with BMP (Table 1). Since the rabbit is larger than the rat, more expensive to buy and keep in facilities, the number of animals in our studies was kept to a minimum.

### Chamber models

The chambers are fabricated from pure titanium, well known to readily osseointegrate, and bone ingrowth into the rabbit BHC is not affected negatively by small titanium alloy particles (Goodman et al. 1995). Both the rabbit BHC and rat BCC models can be viewed as “bone cultures” in vivo. The ingrowth openings are situated intra- and sub-cortically and ingrown tissue can invade the chambers without competition from other tissues. No load is put on the ingrown tissue and bone formation occurs through membranous ossification (Aspenberg et al. 1996a; Tägil and Aspenberg 1998).

The rabbit bone harvest chamber is an osseointegrated model and can be used for repeated harvests without compromising new bone formation. There is no sign of exhaustion of bone formation even after 20 repeated harvests (Thoren 1994) (Figure 3). Active treatment of the tissue in the chamber from one harvest to the next might theoretically “spill-over”, affecting the bone formation of the following period. Such spill-over effects have been looked for but never found. Still, all studies were performed with a rest period between experimental periods, for any such effect to wear off. Addition of growth factors into the chamber might also change the ability to respond to later treatment. However, we did not find an overt change in bone formation response over time.

The micromotion bone harvest chamber has been extensively evaluated. The deformation setting used in Paper IV significantly inhibits bone formation, but by changing the frequency, amplitude or shape of the bone ingrowth openings it is also possible to stimulate bone formation (Goodman 1994; Aspenberg et al. 1996a). In general, the stimulus needed to decrease bone ingrowth is larger than the stimulatory stimulus. This is the case for amplitude and duration of motion, and for number of motion episodes per day.



## Summary of Papers

### Paper I. Transforming growth factor $\beta$ and bone morphogenetic protein 2 for bone ingrowth—a comparison using bone chambers in rats

At the time of this study, no comparison between TGF- $\beta$  and BMP had been performed and TGF- $\beta$  was considered a potential stimulator of bone formation. Three different doses of TGF- $\beta$ 1 and BMP-2 (1, 33 or 1000 ng) versus control solution on a hydroxyapatite carrier were tested in bilateral bone conduction chambers in rats. After 6 weeks the rats were killed and histological evaluation was performed. Totally 44 rats distributed in 6 groups (n 8, 8, 8, 6, 7, 7) were evaluated. TGF- $\beta$ 1 showed a tendency to inhibit bone ingrowth into the chamber and there was a dose dependent negative correlation between dose and bone ingrowth distance ( $r^2 = 0.29$ ,  $p < 0.01$ ) and total tissue ingrowth ( $r^2 = 0.31$ ,  $p < 0.01$ ). With the highest TGF- $\beta$ 1 dose, bone ingrowth distance was 1.11 mm less than controls (confidence interval 0.01–2.22) corresponding to a 48% decrease. BMP-2 showed increased bone and total tissue ingrowth distances compared to controls ( $p < 0.001$ ), mostly due to the highest dose in which the bone ingrowth distance was increased by a factor of more than 2.5.

*Summarized results:* TGF- $\beta$ 1 inhibits and BMP-2 stimulates bone formation dose dependently on a hydroxyapatite carrier in the rat BCC.

### Paper II. BMP-2 can inhibit bone healing. Bone-chamber study in rabbits

Two doses (12 and 0.6  $\mu$ g) of BMP-2 versus control were tested in bilateral rabbit bone harvest chambers. Harvest was performed after 2 weeks, and totally 5 rabbits were tested in each group. Evaluation was performed by histological evaluation and gamma emission from the specimen (an intravenous injection of 99-technetium methylene diphosphonate was given pre-harvest).

Statistical analysis was made by one-way ANOVA based on the assumption that these groups were not dependent, which they are. We realized this after publication. The statistics were therefore re-checked using Wilcoxon's signed rank test for each group (Table 3) which still supports the conclusion that BMP-2 inhibits bone formation in this model. As these results were contradictory to common expectations at the time, we also implanted bilateral titanium tubes sub-fascially loaded with BMP-2 (12  $\mu$ g on collagen) versus control in 4 animals. One animal received one BMP-2 (12  $\mu$ g on collagen) loaded tube only. Evaluation was performed by qualitative histology. This showed bone formation in 4 out of 5 BMP-2 loaded tubes but in none of the controls, indicating that the BMP used could indeed induce bone formation in these animals.

*Summarized results:* BMP-2 inhibits bone and total tissue ingrowth into the rabbit BHC.

**Table 3.** New statistical evaluation on data from Paper II using Wilcoxon's signed rank test for paired results. Comparisons between bilateral chambers (BMP vs carrier, or no implant vs no implant). Significance levels support inhibition by BMP-2.

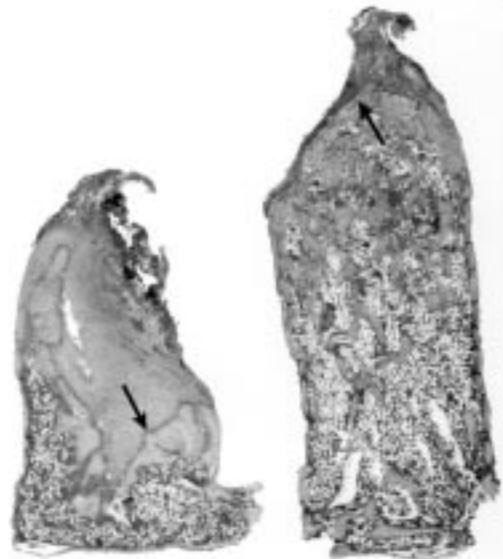
	% bone	Tc-emission	Summary
BMP-2 12 $\mu$ g vs carrier control	$p=0.08^a$	$p=0.04$	BMP-2 inhibits <sup>a</sup>
Empty vs empty chambers <sup>b</sup>	$p=0.08$	$p=0.9$	No difference
BMP-2 0.6 $\mu$ g vs carrier control	$p=0.04$	$p=0.04$	BMP-2 inhibits
Empty vs empty chambers <sup>b</sup>	$p=0.5$	$p=0.9$	No difference

<sup>a</sup> 1 BMP-2 specimen showed slightly higher histological values than carrier control despite lower Tc values. <sup>b</sup> Rest period after 12 and 0.6  $\mu$ g, respectively.

### Paper III. Intraosseous BMP implants in rabbits. Inhibitory effect on bone formation

This Paper tried to elucidate the inhibition of bone formation by BMP-2 found in Paper II. It contains 6 experimental settings:

- 1) To elucidate whether the BMP-2 dose used in Paper II was too high, we tested a low dose, 30 ng on collagen vs control, in the rabbit bone harvest chamber in 10 rabbits. Despite as low dose as 30 ng, there was still a significant inhibition of total tissue formation ( $p = 0.04$ ) and a tendency to inhibit bone formation.
- 2) To compare with another BMP preparation, OP-1 was tested in 5 rabbits using the rabbit bone harvest chamber model, 2.5  $\mu\text{g}$  on collagen versus control. OP-1 inhibited total tissue formation ( $p = 0.02$ ) and bone formation ( $p = 0.03$ ).
- 3) To see if the carrier might interfere with bone formation we changed from collagen carrier to a hydroxyapatite carrier with BMP-2 in 6 rabbits using the rabbit bone harvest chamber, 2.4  $\mu\text{g}$  versus control. This setting also inhibited total tissue formation ( $p = 0.003$ ) and bone formation ( $p = 0.001$ ).
- 4) As the rabbit bone harvest chamber is strictly intraosseous, no cells of extraosseous origin have access, and diffusion of the BMP out of the chamber is restricted. We therefore designed the vertical bone harvest chamber and tested collagen with BMP-2;  $2 \times 2.4 \mu\text{g}$  versus control in 7 rabbits. No effect was found on bone ingrowth distances.
- 5) Some reports of cyst formation in association with high BMP-doses suggested that BMP induced a too strong differentiation response (premature bone formation), so that not enough proliferation could occur to fill the gap. We therefore resected only the middle third of the bone rod formed in the chamber, and introduced a collagen carrier bridging the defect with 4 or 0.8  $\mu\text{g}$  BMP-2. This was compared to similar treatment without BMP in contralateral implants, totally 10 rabbits. We found no tendency to premature bone formation. However, in some cases the preexisting bone was resorbed, which is consistent with the resorptive



**Figure 10.** Histology of paired specimens from rat BCC, paper III. Left: collagen carrier with control. Right: collagen carrier with OP-1. Arrow indicates bone ingrowth front.

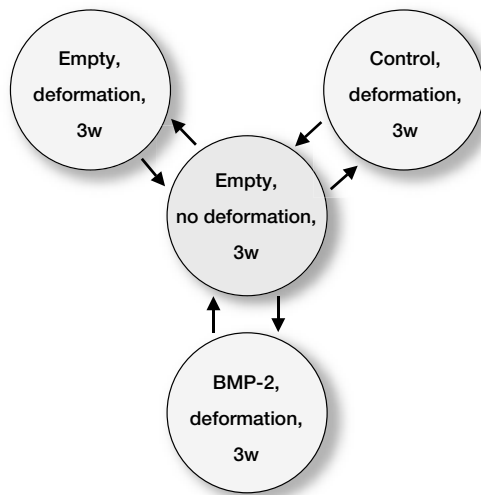
effects of BMPs that were unknown when this Paper was written (Laursen et al. 1999; Hstner et al. 2000).

- 6) To exclude defects of the collagen-BMP-2 implant itself we also tested it versus control in 10 rats receiving the bone conduction chamber bilaterally, known to respond to BMP with increased ingrowth. The BMP-2 dose was 2  $\mu\text{g}$ . We found increased bone ( $p = 0.0001$ ) and total tissue ingrowth ( $p = 0.0005$ ) (Figure 10).

*Summarized results:* Inhibition of bone and total tissue formation in the rabbit BHC is sustained despite very low BMP-2 dose, change of carrier, microenvironment or type of BMP.

### Paper IV. Enhancement of bone formation in the setting of repeated tissue deformation

Micromotion bone harvest chambers were in operated unilaterally in 6 rabbits and tested by a) no micromotion with empty chambers or b) micromotion with chambers implanted with 1) nothing, 2) collagen carrier alone or 3) collagen with BMP-2 0.6  $\mu\text{g}$  (Figure 11). Deformation (micromotion) frequency was 20 displacements in 120 s. All rab-



**Figure 11.** Treatment groups for Paper IV. The rabbits were exposed to treatments in a random order following arrows. A rest period (center) without deformation interrupted treatment periods.

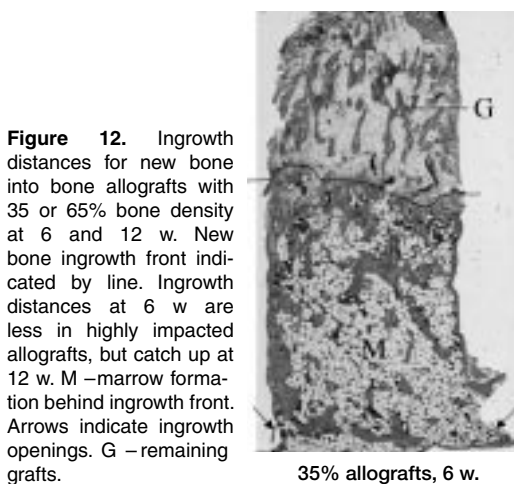
bits were tested for the combinations in 3-week test periods, followed by 3-week rest periods in random order (Figure 11). Histology showed that in empty chambers or chambers with collagen, deformation produced small amounts of fibrous tissue with minor bone. Bone formation in chambers with BMP-2 exposed to micromotion was greater than chambers with collagen, exposed to micromotion ( $p < 0.01$ ). Bone formation in chambers with BMP-2 exposed to micromotion, was equal to the amount of bone in empty chambers without micromotion.

*Summarized results:* Addition of deformation to the rabbit BHC loaded with BMP-2, alters previously found inhibition (Paper II and III) into stimulation of bone formation.

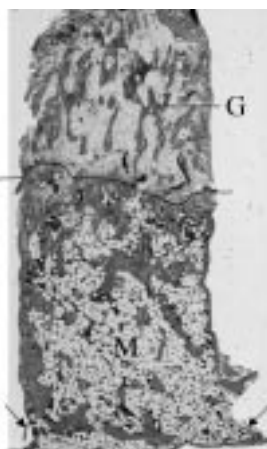
### Paper V. Bone graft incorporation. Effects of osteogenic protein-1 and impaction

Impaction of cancellous bone allografts in the rat bone conduction chamber decreased the ingrowth of new bone into the graft at 6 weeks (Tägil and Aspenberg 1998). This finding contradicts the general assumption that morselized impacted bone allografts remodels better than structural grafts.

- 1) To see if the decrease of new bone ingrowth into impacted allografts was a cessation or only a time dependent delay we studied impacted versus unimpacted grafts in the rat BCC at 6 ( $n = 9$ ) and 12 ( $n = 9$ ) weeks. At 6 weeks bone ingrowth distance into impacted grafts was less than into the unimpacted ( $p = 0.01$ ), but at 12 weeks bone ingrowth distances were similar ( $p = 0.6$ )(Figure 12).
- 2) To see if immunological factors influenced bone ingrowth into allografts, we studied impacted isografts ( $n = 10$ ) and allografts ( $n = 9$ ) versus unimpacted controls. Bone ingrowth distance into both allogenic ( $p = 0.03$ ) and isogenic ( $p = 0.007$ ) was less in the impacted side compared to their unimpacted controls at 6 weeks.



**Figure 12.** Ingrowth distances for new bone into bone allografts with 35 or 65% bone density at 6 and 12 w. New bone ingrowth front indicated by line. Ingrowth distances at 6 w are less in highly impacted allografts, but catch up at 12 w. M –marrow formation behind ingrowth front. Arrows indicate ingrowth openings. G –remaining grafts.



35% allografts, 6 w.



65% allografts, 6 w.



65% allografts, 12 w.

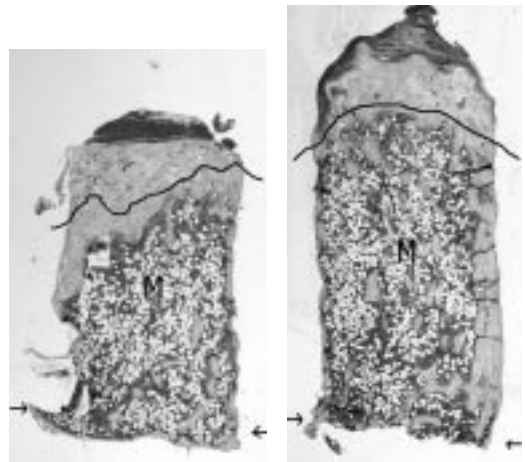
No difference was found between the allo- and isogenic groups.

- 3) To see if it was possible to stimulate new bone ingrowth into impacted bone allografts, OP-1, 1  $\mu\text{g}$  vs control was tested in bilat impacted allografts in the rat BCC. The addition of OP-1 to the impacted grafts increased the bone ingrowth distance compared to impacted grafts without OP-1 ( $p = 0.02$ ) and showed a greater bone ingrowth distance than all unimpacted controls together ( $p = 0.02$ ).

*Summarized results:* Impaction of allografts delays bone ingrowth into the rat BCC, and this can be reversed by addition of OP-1 (BMP-7).

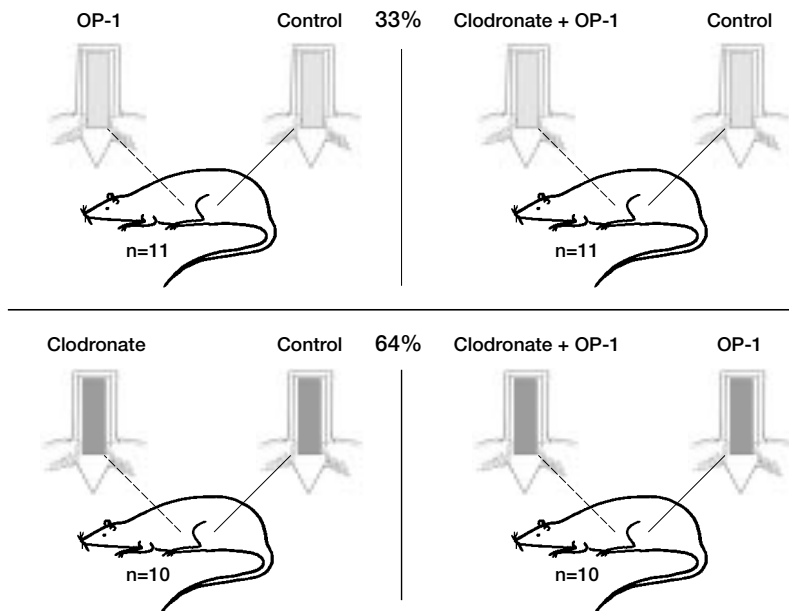
#### Paper VI. Combination of bisphosphonate and BMP additives to impacted bone allografts

The addition of a bisphosphonate to a bone allograft increases bone density after incorporation (Aspenberg and Åstrand 2002). We investigated two different degrees of graft density (33 and 64%) and evaluated if treatment with a combination of a bisphosphonate (clodronate) and OP-1 would maintain a high bone density and yet increase

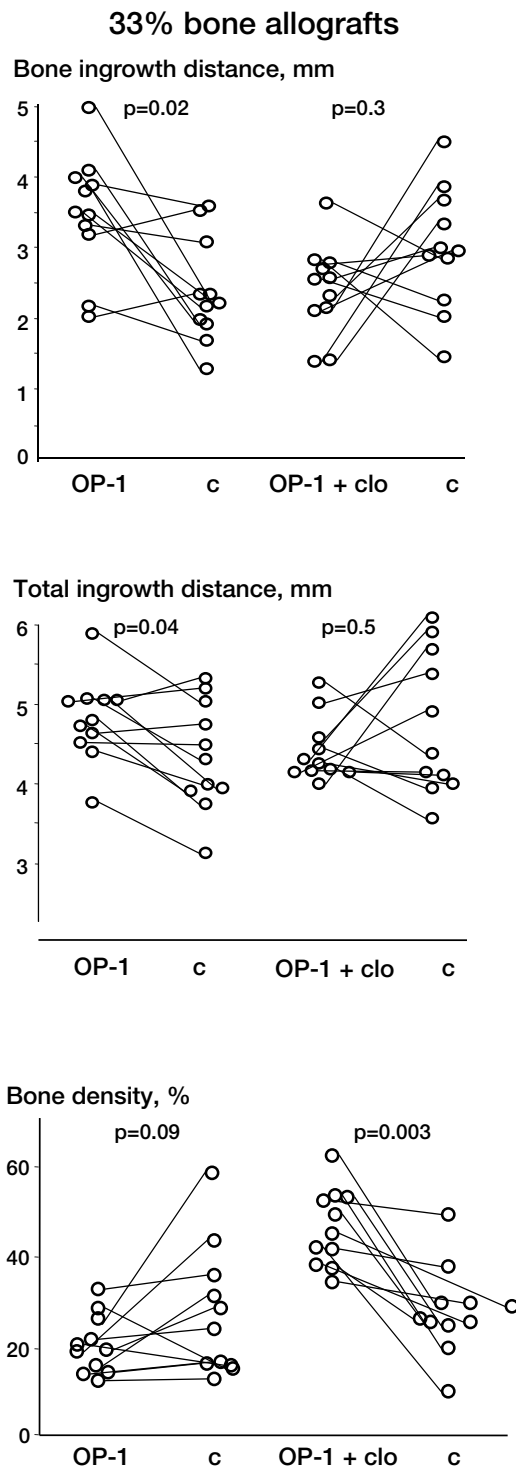


**Figure 14.** Histology of paired bone allograft specimens after 6 weeks, control (left) vs OP-1 (right). Bone allograft density 33% when implanted in rat BCC. New bone ingrowth front indicated by line. Marrow formation behind ingrowth front, M. Arrows indicate ingrowth openings.

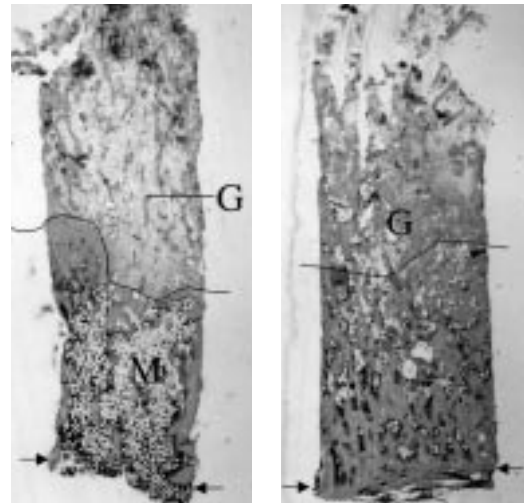
the ingrowth distance of new bone into the graft, using the rat bone conduction chamber model. Four groups were included (Figure 13). In 33% density allografts, OP-1 increased bone ingrowth ( $p = 0.02$ ) and total tissue ingrowth ( $p = 0.04$ ) but no significant effect on bone density was found ( $p = 0.09$ ) (Figure 14 and 15). By combining OP-1 with clodronate the increased bone and total



**Figure 13.** Treatment groups with bilateral allografts implanted in the rat BCC, Paper VI. Top: 33% bone allografts, bottom: 64% bone allografts.



**Figure 15.** 33% density allografts, Paper VI. Paired results connected by line.



**Figure 16.** Histology of paired 33% bone allograft specimens in rat BCC, control (left) vs OP-1+clodronate (right) treatment. New bone ingrowth front indicated by line. M –marrow formation behind ingrowth front. Arrows indicate ingrowth openings. G –remaining grafts.

ingrowth distances were neutralized but a significant increase in final bone density ( $p = 0.003$ ) was achieved (Figure 15 and 16). In 64% density impacted bone allografts (Figure 17) treatment with clodronate decreased new bone ingrowth distance ( $p = 0.05$ ) and total tissue ingrowth distance ( $p = 0.02$ ) but increased the final bone density ( $p = 0.01$ ) compared to untreated controls. By combining clodronate with OP-1 and comparing them to OP-1, bone ingrowth distance is not affected but total ingrowth distance is decreased by clodronate ( $p = 0.02$ ), yet bone density remains increased ( $p = 0.005$ ).

*Summarized results:* The stimulatory effect by OP-1 on bone ingrowth into allografts with clinically relevant bone density (33%) is abolished by the addition of a bisphosphonate (Table 4).

**Table 4.** General interpretation of OP-1 and bisphosphonate effects on morselized bone allografts with 34% bone density in the rat BCC model, based on results in Paper VI and earlier results <sup>a</sup>

	OP-1	Bisphosphonate <sup>a</sup>	Bisphosphonate + OP-1
Ingrowth distance	+	0	0
Density	0	+	+

<sup>a</sup> Aspenberg and Åstrand 2002

64% bone allografts

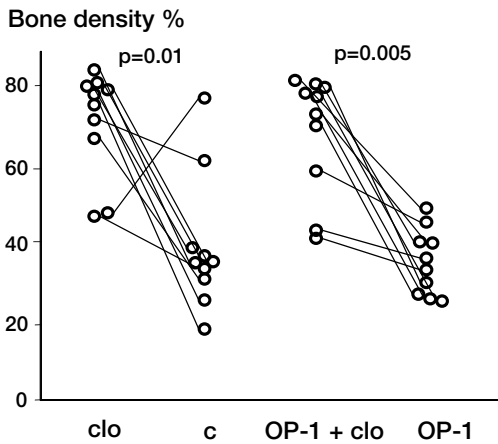
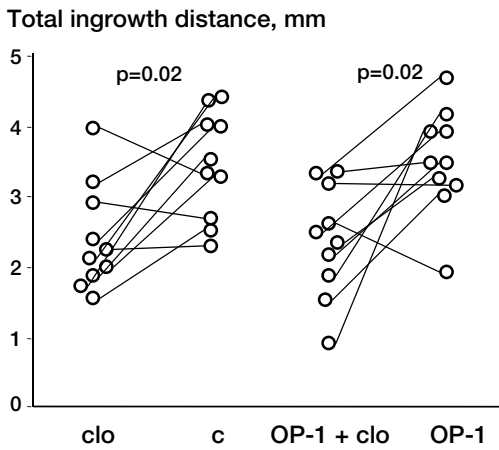
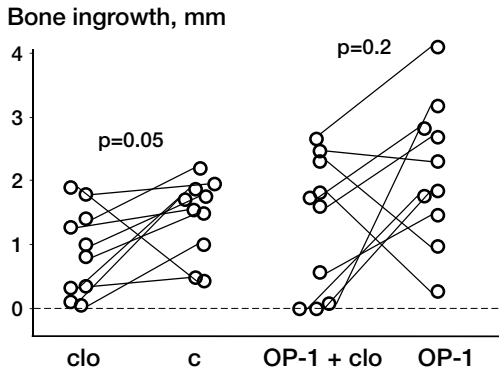


Figure 17. 64% density allografts, Paper VI. Paired results connected by line.

## Discussion

### TGF- $\beta$ 1

When the first Paper was planned there were no comparisons between TGF- $\beta$  and a BMP in the literature. The stimulatory result of BMP-2 was expected according to previous reports (Wang et al. 1990; Cook et al. 1994; Muschler et al. 1994; Cook et al. 1995), while the negative effects of TGF- $\beta$ 1 were subject to discussion.

TGF- $\beta$  is a ubiquitous molecule in the body, interfering in tissue repair and modulating inflammatory response (Wahl 1992; Wahl 1994). TGF- $\beta$  is one of the first detectable factors, released by platelets, in the immediate response to injury, closely followed by infiltrating macrophages and other inflammatory cells that secrete additional TGF- $\beta$  (Joyce et al. 1990; Barnes et al. 1999).

In early fracture repair stages TGF- $\beta$  can be immunolocalized in regions of periosteal proliferation and intramembranous bone formation producing the hard callus. TGF- $\beta$  peaks again during endochondral bone formation (Joyce et al. 1990). The first studies reporting positive effect on bone formation of a single administration of TGF- $\beta$ 1 came from studies on critical size defects in rabbit skull (Beck et al. 1991), representing intramembranous bone formation. Positive results in long bone healing were demonstrated in rabbit midtibial osteotomies treated with continuous infusion of high TGF- $\beta$  doses (Lind et al. 1993) and rat tibia fractures treated with intermittent injection of TGF- $\beta$  every second day for 40 days (Nielsen et al. 1994). These rather rigorous administration schedules would have limited clinical utility. Failure to show stimulation has been reported after single dose regime of TGF- $\beta$ 1 in adult baboon calvarial defects (Ripamonti et al. 1996) and TGF- $\beta$  in femoral condylar defects in rabbits (Lind et al. 1994). When injecting a single dose of TGF- $\beta$ 2 on day 4 in rabbit tibia fractures (Critchlow et al. 1995), no effect on fracture healing was found in stable fractures while impairment was found when introduced into unstable ones. These divisive results may mirror the pleiotropy of TGF- $\beta$ . The

BMP effect on bone formation seems to be greater than that of TGF- $\beta$ .

### Inhibition of bone formation by BMP-2

In Paper II and III we found inhibition of bone formation and total tissue formation by BMP-2 in the rabbit bone harvest chamber. This was unexpected.

The BMP-2 preparation was not compromised. BMP-2 from the same batch stimulated bone and tissue ingrowth into the BCC in rats and in subfascial titanium implants in the same rabbits. This excludes any major defect of the BMP-2 or the animals' ability to respond. The inhibition is not a matter of choosing the wrong dose. The 3 doses tested in Paper II and III (12, 0.6 and 0.03  $\mu$ g) all showed inhibition of tissue ingrowth, and an inhibition of both bone and total tissue ingrowth was still found when testing BMP-2 2.4  $\mu$ g on a hydroxyapatite carrier and another BMP, OP-1, 2.5  $\mu$ g on a collagen carrier. These doses cover a range from doses that should hardly have any effect, to very high doses in a 5 mm<sup>3</sup> volume.

The inhibition is not due to loss of diffusion out of the chamber or minimal contact with cells from the surrounding tissue. The implant put in the rabbit bone harvest chamber model is enclosed by titanium walls plus two openings endostally measuring 1 mm<sup>2</sup>. This could theoretically decrease diffusion out of the chamber causing toxic concentrations that are otherwise not reached, e.g. in critical size defects. Therefore, the enclosed chamber might restrict target cells for the growth factor to intraosseous cells, excluding cells in the periosteum and surrounding tissues. Despite altering the model to allow diffusion out of the chamber and contact with extraosseous cells, an inhibitory tendency by BMP was still found.

In 1995, cyst formation centrally in dog femoral critical size defects treated with high doses of BMP-2 was reported (Sciadini et al. 1995; Sciadini and Johnson 2000). We speculated that a BMP

could speed up the bone formation cascade so that all osteoblastic precursor cells differentiated very fast into mature osteoblasts, before proliferating to a sufficient number of cells that would be required for closing the gap. Our inhibitory effect by BMP would then mimic the formation of a cyst. This made us examine the border between the BMP-2 implant and host bone in order to find mature bone. These studies were hard to perform and the results not conclusive, but the higher BMP-2 dose, 4  $\mu$ g, made the whole bone rod disappear after 2 weeks in some cases, and we did not find premature bone formation.

BMPs also stimulate osteoclasts (Kanatani et al. 1995; Kaneko et al. 2000). After our experiments were performed this has been demonstrated in vivo as resorption of fractured vertebrae (Laursen et al. 1999) and of allografts around hip prosthesis (Höstner et al. 2000). This could explain why the whole rod in the BHC disappeared in some cases when only the middle third was replaced by a BMP implant in Paper III. Also, the inhibitory effect by BMP on bone formation in the BHC chambers might be explained by an increased initial osteoclastic resorption of the bone outside the chamber openings, an area not visualized in our specimens.

The inhibition of bone formation by BMP in the rabbit BHC was changed to stimulation by adding deformation. The used deformation protocol inhibits bone formation in empty chambers (Aspenberg et al. 1996a). This degree of deformation probably releases unknown substances, that normally make the progenitor cells differentiate into fibroblasts and hence the formation of fibrous tissue. The combination of these unknown substances and an exogenously added BMP redirected this cascade into bone formation.

Cyclooxygenase-2, COX-2, is a stress response gene responsible for high levels of prostaglandin during inflammation. A recent study (Zhang et al. 2002) shows that COX-2 null mice, lacking the ability to produce prostaglandin  $E_2$ , have significantly delayed tibia fracture healing characterized by persistence of undifferentiated mesenchyme and reduction in osteoblastogenesis leading to increased rate of nonunion compared to wild mice. When culturing bone marrow stromal cells from these COX-2 null mice, bone nodule formation was reduced by 50% compared to the wild type,

and this defect was completely rescued by adding prostaglandin  $E_2$  to the cultures. By introducing BMP-2 instead to these cultures, bone nodule formation was rescued to levels exceeding those obtained by prostaglandin  $E_2$  in both COX-2 null and wild type cultures, indicating that BMP-2 acts downstream of prostaglandins. When combining prostaglandin  $E_2$  and BMP-2 in these cultures the effect was additive, supporting COX-2's involvement in achieving maximal induction of osteogenesis. This can explain the positive effects of BMP in bone formation achieved in models with a great trauma, such as animal critical size defects (Table 1) and human fractures (Govender et al. 2002), while yet quite mediocre results are found in clinical studies associated with less trauma (Jeppsson et al. 1999; Friedlaender et al. 2001; Boden et al. 2002; Johnsson et al. 2002). The previously mentioned unknown substances released by the deformation in the micromotion chamber model might be prostaglandin  $E_2$  found in the initial inflammatory answer to the trauma. A minimum level of the inflammatory response may be a prerequisite for the positive effect of BMPs on bone formation.

### Bone grafts and remodeling

New bone ingrowth into structural bone allografts is usually limited to 2–3 mm (Enneking and Mindell 1991; Hooten et al. 1996) but impacted morselized allografts were considered to remodel totally, at least by radiography (Gie et al. 1993). However, later reports on histology from retrieved or reoperated impacted allograft areas round hip prosthesis (Linder 2000; Ullmark and Obrant 2002) show limited new bone ingrowth distances. One patient showed total remodeling of the allograft at 48 months postoperatively (Ullmark and Obrant 2002), but this patient had been reoperated 1 month after the hip revision procedure with new bone allografting plus a longer stem implant because of a femur fracture.

The achieved bone density of the allograft is not known, when impacting morselized bone allograft around a hip prosthesis. Bone density in unremodeled areas in histological specimens from Linder's series (Linder 2000) varied between 20–30%. Also, personal discussion with K Obrant who did the



histology of Ullmark's series (Ullmark and Obrant 2002), affords that bone density in these areas rarely exceeds 30%. In our model, 65% bone density is achieved by compressing the rat bone grafts with 25 MPa, and no further increase is achieved despite applying 2500 MPa (Tägil and Aspenberg 1998). This degree of bone density is probably extremely high and may not reflect the clinically achieved bone density after impaction. Therefore we also studied allografts with 33% density in Paper VI. In Paper V, we found no differences in new bone ingrowth into iso- or allogenic impacted bone grafts. Histology of these extremely impacted grafts before implantation showed very few cells, and the impaction procedure per se, possibly squeezed away immuno-compromising factors to a degree equalizing allografts with isografts.

Extreme impaction of allograft delays new bone ingrowth in our model (Tägil and Aspenberg 1998), but OP-1 treatment of these grafts was found to stimulate bone ingrowth, exceeding the ingrowth in their impacted controls at 6 weeks in Paper V. Bone quality was marrow-like behind the new bone ingrowth frontier in these high density OP-1 treated grafts. This may be caused by a simultaneous stimulation of the osteoclast lineage (Kanatani et al. 1995; Kaneko et al. 2000). Increased osteoclastic activity may also explain the early failure in hip revision cases where the morselized bone graft was mixed with OP-1 (Höstner et al. 2000) or in vertebral compression fractures that lost correction after OP-1 instillation in the bone defect (Laursen et al. 1999).

By combining OP-1 and clodronate we desired to stimulate the osteoblast lineage and inactivate

the osteoclast lineage, hereby increasing new bone ingrowth while maintaining resistance to deformation of the graft. In a previous (Aspenberg and Åstrand 2002) series using the same model and bone grafts with a density similar to clinically impacted morselized allograft (around 33%), the final bone density was dramatically increased by a bisphosphonate, but new bone ingrowth was not affected. In Paper VI we found that OP-1 increased new bone ingrowth into similar grafts. When combining OP-1 with clodronate the final bone density was still dramatically increased compared to untreated controls, but the OP-1-stimulation of new bone ingrowth distance was lost. This blocking of the OP-1 effect by clodronate indicates that resorption of the allograft is a prerequisite for new bone formation.

According to these results, clodronate seems to counteract the positive effect on bone ingrowth distance by OP-1 in grafts with a bone density similar to clinically impacted bone allografts. There might however remain a smaller positive effect of OP-1 that we have missed due to a type 2 error. Moreover, alternation of the bisphosphonate and OP-1 doses would be interesting to explore.

In our study, the effect on the graft by OP-1, clodronate, or combinations of the two, seem to depend partly on the bone density of the graft. Graft treatment choice has to be based on the demands of the graft. If one wants to stimulate new bone formation, OP-1 could be useful. In situations where the end result depends on the resistance of the graft to transient resorption, a bisphosphonate treatment could be of value.

## Sammanfattning på svenska

### Frakturläkning

I ben finns tre olika sorters celler, osteoblaster, osteocyter och osteoklaster. Osteoblaster och osteocyter härstammar från stamceller som kallas stödjevävnadens stamceller och svarar för uppbyggnad och upprätthållande av benvävnaden medan osteoklasterna härstammar från de blodbildande stamcellerna och står för nedbrytning av ben. Ben är den enda vävnaden i kroppen som har förmågan att läka helt utan mikroskopiskt synliga ärr, men frakturläkning är en långsam process som leder till långa immobiliseringstider med obehag för patienten och sjukskrivning. Benläkningsprocessen styrs och regleras via ett förutbestämt schema som utlöses i frakturögonblicket. Detta är delvis känt och innefattar bla frisättning av s.k. benmorfogena proteiner.

### BMP, TGF- $\beta$ och bisfosfonater

1965 visade Urist att ben, där mineralen tagits bort (demineraliserat benmatrix, DBM), bildade ben när det inopererades i muskel på kanin och råtta. Detta ledde till jakten på ämnet som skulle frälsa världen från ortopediska problemsituationer såsom utebliven frakturläkning, bindvävsläkning istället för benläkning och dålig omvandling av icke kroppseget transplanterat bengraft till kroppseget ben.

Ett ton koben gick åt för att fastställa aminosyrasekvensen av dessa första proteiner som döptes till "benmorfogena proteiner", BMP, och sedermera visade sig tillhöra en större grupp proteiner som kallas "transforming growth factor beta", TGF- $\beta$ . TGF- $\beta$  familjen är en stor grupp proteiner med många olika effekter, bl.a. modulerar de immunsystemet. TGF $\beta$ -1, 2 och 3 har visat sig kunna stimulera benbildning i vissa studier, men hämmar den i andra och det verkar som om effekten beror på vilken experimentmodell som används. Olika BMPs aminosyrasekvens är mycket lika mellan olika djurarter och den största överensstämmelsen med däggdjurens återfinns i bananflugan. Idag har man identifierat ca

15 BMP som visat sig ha många olika effekter. Frånsett benbildning är olika BMP även delaktiga i fosterutveckling vid anläggandet av armar, ben, hjärta, njurar, testiklar, hjärna och tänderna.

Bisfosfonater är läkemedel som används inom osteoporosbehandlingen och skelettmetastasbehandling bl. a. De binder starkt till mineraldelen av ben och inducerar celledöd i de osteoklaster som bryter ner benet. Vid situationer när bengraft inopereras vill man att graftet ska omvandlas till kroppseget levande ben, vilket innebär att både nedbrytningen av graft och uppbyggnaden av nytt ben skall ske parallellt. Ibland är man beroende av graftet för hållfasthetens skull och om då nedbrytningen föregår uppbyggnaden kan den mekaniska hållfastheten riskeras.

Det är visat att både stödjevävnadens och de blodbildande stamcellerna kan stimuleras av BMP så att de bildar osteoblaster respektive osteoklaster. Båda är delaktiga i frakturläkningsprocessen och denna avhandling har i huvudsak undersökt två olika BMPs förmåga att påverka benbildningen utifrån olika förutsättningar.

### Metoder och delarbeten

Vi har använt titankammare inopererade i skenbenen på råtta och kanin. Kamrarna har kontakt med de benbildande cellerna i skenbenet och ben växer in i kammaren. Efter en viss tid skördas den inväxta benvävnaden. Man kan därefter histologiskt studera och mäta mängden ben som vuxit in i kammaren. Kaninkammaren (Figure 2) växer fast i benet under 6 veckor. Den kan sedan öppnas via en liten hudincision och man kan på så sätt skörda och inplantera, t.ex. proteiner man önskar studera. Det kan göras upprepade gånger. Kaninkammaren finns också som en variant vilken kan ruckas från utsidan och man kan då efterlikna en instabil fraktursituation (Figure 4). Råttkammaren (Figure 5) opereras däremot in samtidigt med det material man önskar studera och råttan avlivs när preparaten uttages. Vi har studerat effekten av proteiner (BMP-2, BMP-7,

TGF $\beta$ -1) samt en bisfosfonat vad avser beninväxt in i olika material såsom hydroxylapatit, kollagen typ-I och bengraft.

I delarbete I använde vi råttkammaren som fylldes med hydroxylapatit behandlat med antingen TGF $\beta$ -1 eller BMP-2 i olika doser och fann att TGF $\beta$ -1 hämmade benbildningen med stigande doser medan BMP-2 ökade benbildningen.

I delarbete II lades BMP-2 på en kollagenbit, in i den rigida kaninkammaren varvid vi fann hämning av benbildningen.

Delarbete III består av 6 delstudier där vi försökte att klargöra varför den annars förväntade benbildningsstimuleringen av BMP, hämmade benbildningen i den rigida kaninkammaren i delarbete II. Vi konstaterade att hämningen kvarstod trots a) lägre doser, b) utbyte av BMP-2 mot BMP-7 och c) byte av kollagenbäraren mot hydroxylapatitbärare. d) Vi modifierade kammaren för att celler utanför också skulle få tillträde utan att finna stimulering och e) vi lyckades inte identifiera cystbildning. f) BMP-2 på kollagen stimulerade dock beninväxten kraftigt i råttkammaren.

I delarbete IV upprepade vi försöket med BMP-2 på kollagen, men denna gång i den ruckbara kaninkammaren, som utsattes för dagliga vridningar i 3 veckor. Benbildningen stimulerades då ånyo.

I delarbete V studerade vi bengraft i kammaren, och fann att hårt packade graft fördröjer ny beninväxt. Vi kunde inte påvisa att det berodde på immunologiskt ofördelaktiga faktorer. Däremot kunde denna fördröjning helt elimineras och faktiskt vändas till stimulering av beninväxtdistansen av BMP-7.

I delarbete VI studerade vi bengraft med 2 olika bendensitetsnivåer som behandlats med bisfosfonat eller BMP-7 samt kombinationer av de båda. Bendensiteten i graftet vid experimentets slut ökade kraftigt efter behandling med bisfosfonat. Kombinationsbehandling med BMP-7 plus bisfosfonat åstadkom en hög bendensitet men den positiva effekten på beninväxtdistansen av BMP-7 försvann i graft med ursprungsdensitet 33%.

## Sammanfattning

Den hämmande effekten av tillsatt BMP i den rigida kaninkammaren är oväntad och därför intressant.

Att vi kunnat vända hämningen till stimulering i en instabil kaninkammare, där dagliga vridningar kan likställas med tillfogad skada, antyder att benbildningsförmågan har att göra med traumat eller något som traumat utlöser, ev. en inflammatorisk reaktion. Situationer med stort vävnadstrauma är de vanligaste modelluppställningarna när det gäller att påvisa positiv effekt på benbildningen av BMP i djurmodeller (Tabell 1). Modeller med minimalt vävnadstrauma, som vår rigida kaninkammare, där det enda trauma som tillförs består i att ta ut en benbit och på så sätt åstadkomma en frakturyta på  $2 \times 1 \text{ mm}^2$  är ovanliga. I situationer med moderat vävnadstrauma har BMP-7 inte överträffat gängse behandling (Jeppsson et al. 1999; Laursen et al. 1999; Friedlaender et al. 2001; Johnsson et al. 2002). Vid stora trauma, har BMP-7 visat lovande resultat i en stor multicenterstudie där man behandlar öppna underbensfrakturer med BMP-2 (Govender et al. 2002).

Om graden av trauma likställs med den inflammatoriska process som sätts igång, föreligger nu data för att prostaglandin E2 är essentiell för normal rekrytering och utmognad av osteoblaster från bindvävens stamcellspopulation (Zhang et al. 2002) vilket därmed skulle kunna förklara de varierande svaren på tillfört BMP. BMP stimulerar även osteoklaster (Kanatani et al. 1995; Kaneko et al. 2000) och man skulle kunna tänka sig att BMP-effekten på osteoklasterna kvarstår trots utebliven stimuli på osteoblasterna vid minimalt vävnadstrauma. Dessa båda kan förklara hämningen av BMP i vår modell.

Omvandlandet av icke kroppseget graft till eget ben förlångsammats av att man packar graftet hårt. Vi har inte kunnat visa att det spelar någon roll om graftet är immunokompatibelt eller ej, men vid tillsättande av BMP-7 fann vi att beninväxtdistansen överträffade t.o.m. den som hittas i icke packade graft. Dock fann vi att benkvaliteten bakom beninväxtfronten var mörglignande, med låg bendensitet och det är möjligt att detta även kan bero på BMPs förmåga att stimulera osteoklaster. För att kompensera för BMP-stimuleringen av osteoklasterna vid tillfällen då mekanisk integritet är nödvändig under hela remodeleringen, provade vi kombinationsbehandling med BMP och bisfosfonat på graft med varierande bendensitet. Detta gav mycket hög densitet av benet efter 6 veckor men bisfosfonateffekten slår ut positiva effekter av BMP-7 förutom i mycket kraftigt packade graft.

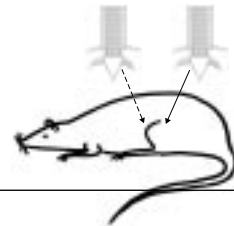
## Thesis at a glance

### Paper I

**Hypothesis** TGF- $\beta$ 1 and BMP-2 stimulate bone ingrowth.

**Method** bilateral *rat* BCC, 6 weeks, n=44:  
 – TGF- $\beta$ 1, 1, 33, 1000 ng vs control  
 – BMP-2, 1, 33, 1000 ng vs control

**Conclusion** BMP-2 stimulates but TGF- $\beta$ 1 inhibits bone ingrowth dose dependently.

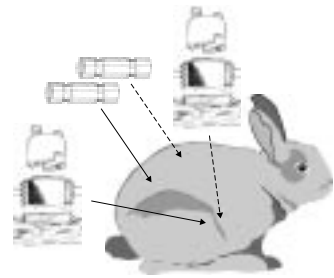


### Paper II

**Hypothesis** BMP-2 inhibits bone formation.

**Method** bilateral *rabbit* BHC and subfascial tubes, 2 weeks:  
 – BMP-2, 12 and 0.6  $\mu$ g vs control on collagen in tibia (n=5).  
 – BMP-2, 12  $\mu$ g (n=5) vs control (n=4) subfascially.

**Conclusion** BMP-2 inhibited intraosseous bone formation, but induced bone formation subfascially.

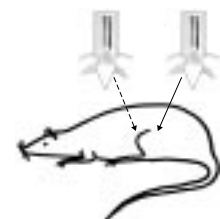
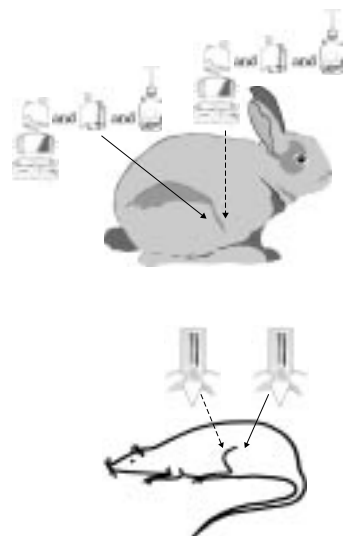


### Paper III

**Aim** Define conditions where BMP-2 inhibits bone formation.

**Method** Bilateral *rabbit* chambers, 2 weeks:  
 – BMP-2, 30 ng vs control on collagen in BHC, n=10.  
 – BMP-2, 2.4  $\mu$ g vs control on hydroxyapatite in BHC, n=6.  
 – OP-1, 2.5  $\mu$ g vs control on collagen in BHC, n=5.  
 – BMP-2, 2.4  $\mu$ g vs control on collagen in VBHC, n=7.  
 – BMP-2, 4 or 8  $\mu$ g vs control on collagen in midsegment BHC, n=10.  
 Bilateral titanium chambers in *rats*, 6 weeks:  
 – BMP-2, 2  $\mu$ g vs control on collagen in BCC, n=10.

**Conclusion** BMP inhibited bone formation despite changes in dose, carrier, type of BMP, or microenvironment in *rabbit* chambers. BMP stimulated bone formation in *rat* BCC.

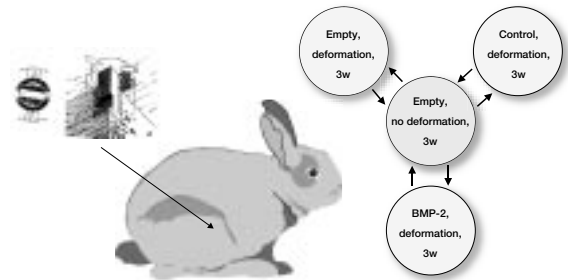


## Paper IV

**Hypothesis** Trauma (deformation) redirects inhibition of bone formation by BMP-2 into stimulation.

**Method** Unilateral *rabbit* MBHC, 3 weeks:  
–BMP-2, 0.6 µg on collagen with or without deformation.

**Conclusion** Trauma (deformation) turns on stimulatory effect of BMP-2.

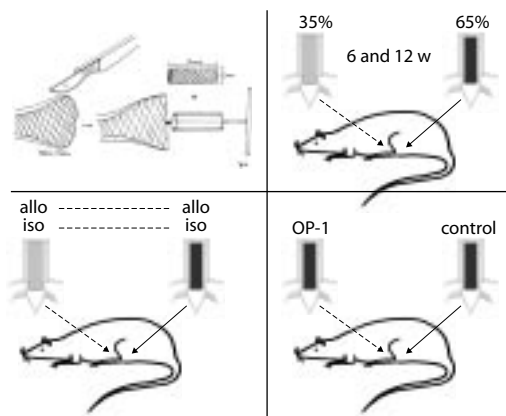


## Paper V

**Aim** Describe and ameliorate inhibition of bone ingrowth caused by compaction.

**Method** Bilateral *rat* BCC.  
– Time study: 65% vs 35% density allografts, 6 or 12 w (n=18).  
– Immunocompatibility study: 65% vs 35% density isografts, 6 w (n=10).  
65% vs 35% density allografts, 6 w (n=10).  
– OP-1 study: OP-1 1 µg vs control on 65% density allografts, 6 w (n=10).

**Conclusion** Ingrowth is delayed in 65% density allografts. No effect of immunocompatibility. OP-1 increased ingrowth into 65% density allografts at 6 w.

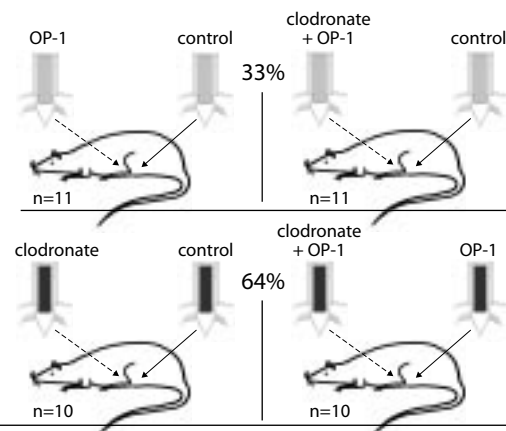


## Paper VI

**Hypothesis** Combinations of bisphosphonate and BMP increase bone ingrowth and final bone density of impacted allografts.

**Method** Bilateral *rat* BCC. Impacted 33% or 65% bone allografts bilaterally with clodronate, OP-1, or combinations of such.

**Conclusion** The stimulatory effect by OP-1 on bone ingrowth into 33% allografts was abolished by the addition of a bisphosphonate.



## Acknowledgement

I would like to express my sincere gratitude to all those who have contributed to my thesis in various ways and in particular to:

Per Aspenberg, my tutor – a man with innumerable ideas, a lot of energy and minor patience – for always being enthusiastic and finding new paths to follow in the scientific forest!

My colleges at the laboratory: Magnus Tägil for enjoyable co-work and for planting the idea to go ahead and write this thesis, Jörgen Åstrand for always keeping Per Aspenberg off my back on uphill slopes and reminding me of the world outside, Jian-Sheng Wang for teaching me laboratory surgical skills, Inger Mårtensson for inviolable laboratory help and becoming a good friend, Carina Forslund for all her help, lots of fun and for introducing the “no problem” attitude, and Ralf Skripitz for speeding things up.

Mats Christensson for technical assistance and for producing the devices.

Kaj Knutson for layout, and sharing sometimes understandable computer advises.

Gun-Britt Nyberg for dissertation support.

My colleges and staff at the Orthopedic department in Lund for all sparring, support, and advice shared.

The Hand Surgery department in Malmö for their generous support.

My whole big family for being just the way they are!

Per Ederoth, my sparring partner, and beloved husband-to-be, for all support (Verbier week excluded) during this process and for always reminding me that “– the kids can make it several hours without you...”

Hugo, 3 years old and Otto, 2 for believing in and accepting the lie, that their mother is writing a book about Teletubbies.

Agnieszka Janczak for invaluable help.

Stryker Biotech for the OP-1 solutions, the Genetics Institute for the BMP-2 plus TGF- $\beta$ 1 supply, and Interpore International for hydroxyapatite rods.

This study was financially supported by the Medical Faculty of Lund University, the Swedish Medical Research Council (project 2031) and the “Stiftelsen för bistånd åt rörelsehindre i Skåne”, the Kung Gustav V jubileumsfond, Alfred Österlund, Greta och Johan Kock, Trygg-Hansa and Tore Nilsson foundations.

## References

- Aspenberg P, Åstrand J. Bone allografts pretreated with a bisphosphonate are not resorbed. *Acta Orthop Scand* 2002; 73 (1): 20-23.
- Aspenberg P, Goodman SB, Wang JS. Influence of callus deformation time. Bone chamber study in rabbits. *Clin Orthop* 1996a; (322): 253-61.
- Aspenberg P, Jeppsson C, Wang J-S, Boström M. Transforming growth factor beta and bone morphogenic protein 2 for bone ingrowth. *Bone* 1996b; 19(5) 499-503.
- Aufdemorte TB, Fox WC, Holt GR, McGuff HS, Ammann AJ, Beck LS. An intraosseous device for studies of bone-healing. The effect of transforming growth-factor beta. *J Bone Joint Surg Am* 1992; 74 (8): 1153-61.
- Barnes GL, Kostenuik PJ, Gerstenfeld LC, Einhorn TA. Growth factor regulation of fracture repair. *J Bone Miner Res* 1999; 14 (11): 1805-15.
- Beck LS, Deguzman L, Lee WP, Xu Y, McFatrige LA, Gillett NA, Amento EP. Rapid publication. TGF-beta 1 induces bone closure of skull defects. *J Bone Miner Res* 1991; 6 (11): 1257-65.
- Blokhuis TJ, den Boer FC, Bramer JA, Jenner JM, Bakker FC, Patka P, Haarman HJ. Biomechanical and histological aspects of fracture healing, stimulated with osteogenic protein-1. *Biomaterials* 2001; 22 (7): 725-30.
- Boden SD, Kang J, Sandhu H, Heller JG. Use of recombinant human bone morphogenetic protein-2 to achieve posterolateral lumbar spine fusion in humans: a prospective, randomized clinical pilot trial: 2002 Volvo award in clinical studies. *Spine* 2002; 27 (23): 2662-73.
- Border WA, Ruoslahti E. Transforming growth factor-beta in disease: the dark side of tissue repair. *J Clin Invest* 1992; 90 (1): 1-7.
- Bostrom MP, Camacho NP. Potential role of bone morphogenetic proteins in fracture healing. *Clin Orthop* 1998; (355 Suppl): S274-82.
- Bouxsein ML, Turek TJ, Blake CA, D'Augusta D, Li X, Stevens M, et al. Recombinant human bone morphogenetic protein-2 accelerates healing in a rabbit ulnar osteotomy model. *J Bone Joint Surg [Am]* 2001; 83-A (8): 1219-30.
- Centrella M, McCarthy TL, Canalis E. Transforming growth factor-beta and remodeling of bone. *J Bone Joint Surg Am* 1991; 73 (9): 1418-28.
- Cho TJ, Gerstenfeld LC, Einhorn TA. Differential temporal expression of members of the transforming growth factor beta superfamily during murine fracture healing. *J Bone Miner Res* 2002; 17 (3): 513-20.
- Cook SD, Baffes GC, Wolfe MW, Sampath KT, Rueger DC, Whitecloud TS. The effect of Recombinant Human Osteogenic Protein-1 on healing of large segmental bone defects. *J Bone Joint Surg [Am]* 1994; 76-A (6): 827-838.
- Cook SD, Barrack RL, Santman M, Patron LP, Salkeld SL, Whitecloud TS. Strut allograft healing to the femur with recombinant human osteogenic protein-1. *Clin Orthop* 2000; (381): 47-57.
- Cook SD, Wolfe MW, Salkeld SL, Rueger DC. Effect of recombinant human osteogenic protein-1 on healing of segmental defects in non-human primates. *J Bone Joint Surg [Am]* 1995; 77-A (5): 734-750.
- Critchlow MA, Bland YS, Ashhurst DE. The effect of exogenous transforming growth factor-beta 2 on healing fractures in the rabbit. *Bone* 1995; 16 (5): 521-7.
- Cunningham NS, Paralkar V, Reddi AH. Osteogenin and recombinant bone morphogenetic protein 2B are chemotactic for human monocytes and stimulate transforming growth factor beta 1 mRNA expression. *Proc. Natl. Acad. Sci. USA*. 1992; Dec 15; 89 (24): 11740-11744.
- Daluisi A, Engstrand T, Bahamonde ME, Gamer LW, Agius E, Stevenson SL, Cox K, Rosen V, Lyons KM. Bone morphogenetic protein-3 is a negative regulator of bone density. *Nat Genet* 2001; 27 (1): 84-8.
- Danielsen CC, Mosekilde L, Svenstrup B. Cortical bone mass, composition, and mechanical properties in female rats in relation to age, long-term ovariectomy, and estrogen substitution. *Calcif Tissue Int* 1993; 52 (1): 26-33.
- den Boer FC, Bramer JA, Blokhuis TJ, Van Soest EJ, Jenner JM, Patka P, et al. Effect of recombinant human osteogenic protein-1 on the healing of a freshly closed diaphyseal fracture. *Bone* 2002; 31 (1): 158-64.
- Einhorn TA. The cell and molecular biology of fracture healing. *Clin Orthop* 1998; (355 Suppl): S7-21.
- Enneking WF, Mindell ER. Observations on massive retrieved human allografts. *J Bone Joint Surg [Am]* 1991; 73-A (8): 1123-1142.
- Freiss W, Uludag H, Foskett S, Biron R, Sargeant C. Characterization of absorbable collagen sponges as recombinant human morphogenetic protein-2 carriers. *Int J Pharm* 1999; 185 51-60.
- Friedlaender GE, Perry CR, Cole JD, Cook SD, Cierny G, Muschler GF, et al. Osteogenic protein-1 (bone morphogenetic protein-7) in the treatment of tibial nonunions. *J Bone Joint Surg [Am]* 2001; 1 (Pt 2): S151-8.
- Frost HM. The biology of fracture healing. An overview for clinicians. Part I. *Clin Orthop* 1989a; (248): 283-93.
- Frost HM. The biology of fracture healing. An overview for clinicians. Part II. *Clin Orthop* 1989b; (248): 294-309.
- Frost HM. From Wolff's law to the Utah paradigm: insights about bone physiology and its clinical applications. *Anat Rec* 2001; 262 (4): 398-419.
- Frost HM, Jee WS. On the rat model of human osteopenias and osteoporoses. *Bone Miner* 1992; 18 (3): 227-36.
- Gie GA, Linder L, Ling RS, Simon JP, Slooff TJ, Timperley AJ. Impacted cancellous allografts and cement for revision total hip arthroplasty. *J Bone Joint Surg [Br]* 1993; 75-B: 14-21.

- Goodman S, Aspenberg P, Song Y, Doshi A, Regula D, Lidgren L. Effects of particulate high-density polyethylene and titanium alloy on tissue ingrowth into bone harvest chamber in rabbits. *J Appl Biomater* 1995; 6 (1): 27-33.
- Goodman SB. The effects of micromotion and particulate materials on tissue differentiation. Bone chamber studies in rabbits. Thesis. *Acta Orthop Scand* 1994; 65 (Suppl. 258).
- Govender S, Csimma C, Genant HK, Valentin-Opran A, Amit Y, Arbel R, et al. Recombinant human bone morphogenetic protein-2 for treatment of open tibial fractures: a prospective, controlled, randomized study of four hundred and fifty patients. *J Bone Joint Surg [Am]* 2002; 84-A (12): 2123-34.
- Grauer JN, Patel TC, Erulkar JS, Troiano NW, Panjabi MM, Friedlaender GE. 2000 Young Investigator Research Award winner. Evaluation of OP-1 as a graft substitute for intertransverse process lumbar fusion. *Spine* 2001; 26 (2): 127-33.
- Griffith DL, Keck PC, Sampath TK, Rueger DC, Carlson WD. Three-dimensional structure of recombinant human osteogenic protein 1; Structural paradigm for transforming growth factor  $\beta$  superfamily. *Proc. Natl. Acad. Sci. USA* 1996; 93 878-883.
- Guha U, Gomes WA, Kobayashi T, Pestell RG, Kessler JA. In vivo evidence that BMP signaling is necessary for apoptosis in the mouse limb. *Dev Biol* 2002; 249 (1): 108-20.
- Hilding M, Ryd L, Toksvig-Larsen S, Aspenberg P. Clodronate prevents prosthetic migration: a randomized radiostereometric study of 50 total knee patients. *Acta Orthop Scand* 2000; 71 (6): 553-7.
- Hollinger JO, Schmitt JM, Buck DC, Shannon R, Joh SP, Zegzula HD, Wozney J. Recombinant human bone morphogenetic protein-2 and collagen for bone regeneration. *J Biomed Mater Res* 1998; 43 (4): 356-64.
- Hooten JP, Engh CA, Heekin RD, Vinh TN. Structural bulk allografts in acetabular reconstruction. *J Bone Joint Surg [Br]* 1996; 78-B: 270-275.
- Höstner J, Kärrholm J, Hultmark P. Early failures after femoral revisions using milled allograft bone mixed with OP-1. Poster presentation 2000; SOF 2000: 205-206.
- Jena N, Martin-Seisdedos C, McCue P, Croce CM. BMP7 null mutation in mice: developmental defects in skeleton, kidney, and eye. *Exp Cell Res* 1997; 230 (1): 28-37.
- Jepsson C, Saveland H, Rydholm U, Aspenberg P. OP-1 for cervical spine fusion: bridging bone in only 1 of 4 rheumatoid patients but prednisolone did not inhibit bone induction in rats. *Acta Orthop Scand* 1999; 70 (6): 559-63.
- Jonsson R, Strömqvist B, Aspenberg P. Randomized radiostereometric study comparing osteogenic protein-1 (BMP-7) and autograft bone in human noninstrumented posterolateral lumbar fusion: 2002 Volvo Award in clinical studies. *Spine* 2002; 27 (23): 2654-61.
- Jorgensen PH, Bak B, Andreassen TT. Mechanical properties and biochemical composition of rat cortical femur and tibia after long-term treatment with biosynthetic human growth hormone. *Bone* 1991; 12 (5): 353-9.
- Joyce ME, Jingushi S, Bolander ME. Transforming growth factor-beta in the regulation of fracture repair. *Orthop Clin North Am* 1990; 21 (1): 199-209.
- Kanatani M, Sugimoto T, Kaij H, Kobayashi T, Nishiyama K, Fukase M, et al. Stimulatory effect of bone morphogenetic protein-2 on osteoclastlike cell formation and bone resorbing activity. *J Bone Miner Res* 1995; 10 (11): 1681-1690.
- Kaneko H, Arakawa T, Mano H, Kaneda T, Ogasawara A, Nakagawa M, et al. Direct stimulation of osteoclastic bone resorption by Bone Morphogenetic Protein (BMP-2) and expression of BMP receptors in mature osteoclasts. *Bone* 2000; 27 (4): 479-486.
- Kaplan FS, Shore EM. Encrypted morphogens of skeletogenesis: biological errors and pharmacologic potentials. *Biochem Pharmacol* 1998; 55 (4): 373-82.
- Khor E. Methods for the treatment of collagenous tissues for bioprotheses. *Biomaterials* 1997; 18 (2): 95-105.
- Kingsley DM, Bland AE, Grubber JM, Marker PC, Russell LB, Copeland NG, Jenkins NA. The mouse short ear skeletal morphogenesis locus is associated with defects in a bone morphogenetic member of the TGF beta superfamily. *Cell* 1992; 71 (3): 399-410.
- Kirker-Head CA. Potential applications and delivery strategies for bone morphogenetic proteins. *Adv Drug Deliv Rev* 2000; 43 (1): 65-92.
- Koempel JA, Patt BS, O'Grady K, Wozney J, Toriumi DM. The effect of recombinant human bone morphogenetic protein-2 on the integration of porous hydroxyapatite implants with bone. *J Biomed Mater Res* 1998; 41 (3): 359-63.
- Lacroix. Recent investigations on the growth of bone. *Nature* 1945; 156: 576.
- Lamerights N, Buma P, Aspenberg P, Schreurs W, Slooff T. Role of growth factors in the incorporation of unloaded bone allografts in the goat. *Clin Orthop* 1999; (368): 260-270.
- Laursen M, Hoy K, Hansen ES, Gelineck J, Christensen FB, Bünger CE. Recombinant bone morphogenetic protein-7 as an intracorporeal bone growth stimulator in thoracolumbar burst fractures in humans; preliminary results. *Eur Spine J* 1999; 8: 485-490.
- Levander G. A study of bone regeneration. *Surgery Gynecology and Obstetrics* 1938; 67 (6): 705-714.
- Lind M, Frøkjær J, Søballe K, Bünger C. Inability of local application of transforming growth factor- $\beta$  to promote healing of defects in rabbit femoral condyles. *Eur J Exp Musculoskel Res* 1994; 3: 131-136.
- Lind M, Schumacker B, Søballe K, Keller J, Melsen F, Bünger C. Transforming growth factor-beta enhances fracture healing in rabbit tibiae. *Acta Orthop Scand* 1993; 64 (5): 553-6.
- Linder. Cancellous impaction grafting in the human femur. Histological and radiographic observations in 6 autopsy femurs and 8 biopsies. *Acta Orthop Scand* 2000; 71 (6): 543-552.
- Malchau H, Herberts P, Eisler T, Garellick G, Söderman P. The Swedish Total Hip Replacement Register. *J Bone Joint Surg [Am]* 2002; 84-A (Suppl 2): 2-20.



- Manolagas SC. Birth and death of bone cells: basic regulatory mechanisms and implications for the pathogenesis and treatment of osteoporosis. *Endocr Rev* 2000; 21 (2): 115-37.
- McCartney-Francis NL, Wahl SM. Transforming growth factor beta: a matter of life and death. *J Leukoc Biol* 1994; 55 (3): 401-9.
- Murray D. Surgery and joint replacement for joint disease. *Acta Orthop Scand* 1998; 69 (Suppl 281): 17-20.
- Muschler GF, Hyodo A, Manning T, Kambic H, Easley K. Evaluation of human bone morphogenetic protein 2 in a canine spinal fusion model. *Clin Orthop* 1994; 308 229-240.
- Nelissen RG, Bauer TW, Weidenhielm LR, LeGolyan DP, Mikhail WE. Revision hip arthroplasty with the use of cement and impaction grafting. Histological analysis of four cases. *J Bone Joint Surg [Am]* 1995; 77 (3): 412-22.
- Nielsen HM, Andreassen TT, Ledet T, Oxlund H. Local injection of TGF-beta increases the strength of tibial fractures in the rat. *Acta Orthop Scand* 1994; 65 (1): 37-41.
- Parfitt AM. Osteonal and hemi-osteonal remodeling: the spatial and temporal framework for signal traffic in adult human bone. *J Cell Biochem* 1994; 55 (3): 273-86.
- Patel TC, Erulkar JS, Grauer JN, Troiano NW, Panjabi MM, Friedlaender GE. Osteogenic protein-1 overcomes the inhibitory effect of nicotine on posterolateral lumbar fusion. *Spine* 2001; 26 (15): 1656-61.
- Reddi AH. Bone Morphogenic proteins: an unconventional approach to isolation of first mammalian morphogens. *Cytokine Growth Factor Rev* 1997; 8 (1): 11-20.
- Reddi AH. Role of morphogenetic proteins in skeletal tissue engineering and regeneration. *Nat Biotechnol* 1998; 16 247-252.
- Reddi AH. Bone Morphogenic Proteins: From basic science to clinical applications. *J Bone Joint Surg [Am]* 2001; 83-A Suppl 1 (Pt 1): 1-6.
- Ripamonti U, Bosch C, van den Heever B, Duneas N, Melsen B, Ebner R. Limited chondro-osteogenesis by recombinant human transforming growth factor-beta 1 in calvarial defects of adult baboons (*Papio ursinus*). *J Bone Miner Res* 1996; 11 (7): 938-45.
- Ripamonti U, Duneas N, Van den Heever B, Bosch C, Crooks J. Recombinant transforming growth factor- $\beta$ 1 induces endochondral bone in the baboon and synergizes with recombinant osteogenic protein-1 (bone morphogenic protein-7) to initiate rapid bone formation. *J Bone Miner Res* 1997; 12 (10): 1584-95.
- Rogers MJ, Gordon S, Benford HL, Coxon FP, Luckman SP, Monkkonen J, Frith JC. Cellular and molecular mechanisms of action of bisphosphonates. *Cancer* 2000; 88 (12 Suppl): 2961-78.
- Russell RGG, Rogers MJ. Bisphosphonates: From the laboratory to the clinic and back again. *Bone* 1999; 25 (1): 97-106.
- Salkeld SL, Patron LP, Barrack RL, Cook SD. The effect of osteogenic protein-1 on the healing of segmental bone defects treated with autograft or allograft bone. *J Bone Joint Surg [Am]* 2001; 83-A (6): 803-16.
- Sandhu HS, Khan SN. Animal models for preclinical assessment of bone morphogenetic proteins in the spine. *Spine* 2002; 27 (16 Suppl 1): S32-8.
- Sciadini M, Dawson J, Berman L, Johnson K. Dose response characteristics of recombinant human bone morphogenetic protein -2 (rhBMP-2) in a canine segmental defect model (abstract). *Trans Orthop Res Society* 1995; 20: 594.
- Sciadini M, Johnson K. Evaluation of recombinant human bone morphogenetic protein-2 as a bone -graft substitute in a canine segmental defect model. *J Orthop Res* 2000; 18: 289-302.
- Shore EM, Xu M, Shah PB, Janoff HB, Hahn GV, Dearth MA, et al. The human bone morphogenetic protein 4 (BMP-4) gene: molecular structure and transcriptional regulation. *Calcif Tissue Int* 1998; 63 (3): 221-9.
- Si X, Jin Y, Yang L, Tipoe GL, White FH. Expression of BMP-2 and TGF-beta 1 mRNA during healing of the rabbit mandible. *Eur J Oral Sci* 1997; 105 (4): 325-30.
- Slooff TJ, Huiskes R, Schimmel JW, van Horn J, Lemmens AJ. Bone grafting in total hip replacements for acetabular protrusions. *Acta Orthop Scand* 1984; 55: 593-596.
- Solloway MJ, Dudley AT, Bikoff EK, Lyons KM, Hogan BL, Robertson EJ. Mice lacking *Bmp6* function. *Dev Genet* 1998; 22 (4): 321-39.
- Storm EE, Huynh TV, Copeland NG, Jenkins NA, Kingsley DM, Lee SJ. Limb alterations in brachypodism mice due to mutations in a new member of the TGF beta-superfamily. *Nature* 1994; 368 (6472): 639-43.
- Summers BN, Eisenstein SM. Donor site pain from the ilium. *J Bone Joint Surg [Br]* 1989; 71-B (4): 677-680.
- Sumner DR, Turner TM, Purchio AF, Gombotz WR, Urban RM, Galante JO. Enhancement of bone ingrowth by transforming growth factor-beta. *J Bone Joint Surg [Am]* 1995; 77-A (8): 1135-47.
- Thorén K. Lipid-extracted bone grafts. Thesis 1994.
- Tourimi DM, Kotler HS, Luxenberg DP, Holtrop ME, Wang EA. Mandibular Reconstruction With a Recombinant Bone-Inducing Factor. *Arch Otolaryngol Head Neck Surg* 1991; 117: 1101-1112.
- Tägil M, Aspenberg P. Impaction of cancellous bone grafts impairs osteoconduction in titanium chambers. *Clin Orthop* 1998; (352): 231-238.
- Tägil M, Jeppsson C, Aspenberg P. Bone graft incorporation. Effects of Osteogenic Protein-1 and impaction. *Clin Orthop* 2000; (371): 240-245.
- Ullmark G, Obrant KJ. Histology of impacted bone-graft incorporation. *J Arthroplasty* 2002; 17 (2): 150-7.
- Uludag H, Gao T, Porter TJ, Friess W, Wozney JM. Delivery systems for BMPs: factors contributing to protein retention at an application site. *J Bone Joint Surg [Am]* 2001; 1 (Pt 2): S128-35.
- Urist MR. Bone: formation by autoinduction. *Science* 1965; 150 (698): 893-9.
- Wahl SM. Transforming growth factor beta (TGF-beta) in inflammation: a cause and a cure. *J Clin Immunol* 1992; 12 (2): 61-74.
- Wahl SM. Transforming growth factor beta: the good, the bad, and the ugly. *J Exp Med* 1994; 180 (5): 1587-90.

- Wang EA, Rosen V, Alessandro JS, Bauduy M, Cordes P, Harada T, et al. Recombinant human bone morphogenetic protein induces bone formation. *Proc. Natl. Acad. Sci. USA* 1990; 87: 2220-2224.
- Welch RD, Jones AL, Bucholz RW, Reinert CM, Tjia JS, Pierce WA, et al. Effect of recombinant human bone morphogenetic protein-2 on fracture healing in a goat tibial fracture model. *J Bone Miner Res* 1998; 13 (9): 1483-90.
- Winn SR, Uludag H, Hollinger JO. Sustained release emphasizing recombinant human bone morphogenetic protein-2. *Adv Drug Deliv Rev* 1998; 31 (3): 303-318.
- Winnier G, Blessing M, Labosky PA, Hogan BL. Bone morphogenetic protein-4 is required for mesoderm formation and patterning in the mouse. *Genes Dev* 1995; 9 (17): 2105-16.
- Wozney JM. Overview of bone morphogenetic proteins. *Spine* 2002; 27 (16 Suppl 1): S2-8.
- Wozney JM, Rosen V. Bone morphogenetic protein and bone morphogenetic protein gene family in bone formation and repair. *Clin Orthop* 1998; (346): 26-37.
- Wozney JM, Rosen V, Celeste AJ, Mitsock LM, Whitters MJ, Kriz RW, et al. Novel regulators of bone formation: Molecular clones and activities. *Science* 1988; 242 (4885): 1528-1534.
- Yasko AW, Lane JM, Fellingner EJ, Rosen V, Wozney JM, Wang EA. The Healing of Segmental Bone Defects, Induced by Recombinant Human Bone Morphogenic Protein (rhBMP-2). *J Bone Joint Surg [Am]* 1992; 74 (A): 659-670.
- Younger EM, Chapman MW. Morbidity at bone graft donor sites. *J Orthop Trauma* 1989; 3 (3): 192-5.
- Zhang H, Bradley A. Mice deficient for BMP2 are nonviable and have defects in amnion/chorion and cardiac development. *Development* 1996; 122 (10): 2977-86.
- Zhang X, Schwarz EM, Young DA, Puzas JE, Rosier RN, O'Keefe RJ. Cyclooxygenase-2 regulates mesenchymal cell differentiation into the osteoblast lineage and is critically involved in bone repair. *J Clin Invest* 2002; 109 (11): 1405-15.
- Zhao GQ, Liaw L, Hogan BL. Bone morphogenetic protein 8A plays a role in the maintenance of spermatogenesis and the integrity of the epididymis. *Development* 1998; 125 (6): 1103-12.
- Zimmerman LB, De Jesus-Escobar JM, Harland RM. The Spemann organizer signal noggin binds and inactivates bone morphogenetic protein 4. *Cell* 1996; 86 (4): 599-606.
- Zou H, Niswander L. Requirement for BMP signaling in interdigital apoptosis and scale formation. *Science* 1996; 272: 738-741.