



# LUND UNIVERSITY

## Clinical detection studies of Barrett's metaplasia and oesophageal adenocarcinoma by means of laser-induced fluorescence

Nilsson, AMK; von Holstein, CS; Andersson-Engels, Stefan; Willen, R; Walther, Bruno; Svanberg, Katarina

*Published in:*  
OPTICAL BIOPSIES, PROCEEDINGS OF

*DOI:*  
[10.1117/12.228903](https://doi.org/10.1117/12.228903)

1995

[Link to publication](#)

### *Citation for published version (APA):*

Nilsson, AMK., von Holstein, CS., Andersson-Engels, S., Willen, R., Walther, B., & Svanberg, K. (1995). Clinical detection studies of Barrett's metaplasia and oesophageal adenocarcinoma by means of laser-induced fluorescence. In R. Cubeddu, SR. Mordon, K. Svanberg, & A. Katzir (Eds.), *OPTICAL BIOPSIES, PROCEEDINGS OF* (Vol. 2627, pp. 49-56). SPIE. <https://doi.org/10.1117/12.228903>

*Total number of authors:*  
6

### **General rights**

Unless other specific re-use rights are stated the following general rights apply:  
Copyright and moral rights for the publications made accessible in the public portal are retained by the authors and/or other copyright owners and it is a condition of accessing publications that users recognise and abide by the legal requirements associated with these rights.

- Users may download and print one copy of any publication from the public portal for the purpose of private study or research.
- You may not further distribute the material or use it for any profit-making activity or commercial gain
- You may freely distribute the URL identifying the publication in the public portal

Read more about Creative commons licenses: <https://creativecommons.org/licenses/>

### **Take down policy**

If you believe that this document breaches copyright please contact us providing details, and we will remove access to the work immediately and investigate your claim.

LUND UNIVERSITY

PO Box 117  
221 00 Lund  
+46 46-222 00 00

# **Clinical detection studies of Barrett's metaplasia and oesophageal adenocarcinoma by means of laser-induced fluorescence**

**Annika M. K. Nilsson<sup>1</sup>, Christer Staël von Holstein<sup>2</sup>, Stefan Andersson-Engels<sup>1</sup>, Roger Willén<sup>3</sup>, Bruno Walther<sup>2</sup>, and Katarina Svanberg<sup>4</sup>**

<sup>1</sup>Department of Physics, Lund Institute of Technology,  
P.O. Box 118, S-221 00 Lund, Sweden  
annika.nilsson@fysik.lth.se

<sup>2</sup>Department of Surgery, Lund University Hospital

<sup>3</sup>Department of Pathology, Lund University Hospital

<sup>4</sup>Department of Oncology, Lund University Hospital

## **ABSTRACT**

Five patients with Barrett's metaplastic epithelium were investigated by means of laser-induced fluorescence after low-dose *i.v.* injection (0.35 mg/kg b.w.) of Photofrin<sup>®</sup> in connection with endoscopy procedures. The excitation wavelength was 405 nm. Recorded fluorescence spectra were evaluated by forming ratios with the photosensitiser fluorescence as numerator and the autofluorescence as denominator. Two patients had no evidence of malignancy and their fluorescence ratios were consequently rather small, whereas the other three patients had adenocarcinoma and showed considerably higher ratios. The results indicate that laser-induced fluorescence can be used as an aid in detecting malignant transformations in Barrett's metaplasia.

## **1. INTRODUCTION**

The type of epithelium present in the digestive tract depends on the functions of the specific part that it lines. The oesophagus is lined with a stratified squamous epithelium, which is well suited to withstand the wear and tear caused by chewed food. The stomach is lined by secretory columnar epithelium, where the cells are specialised to secrete mucus and sustain the acidic environment. However, when the conditions of the epithelium change, there is a risk that the type of epithelium changes with it. Barrett's epithelium is such an altered epithelium, a metaplastic columnar epithelium in the lower oesophagus, which is found in approximately 10% of the patients who undergo endoscopy for evaluation of symptoms of gastroesophageal reflux disease<sup>1</sup>. Patients with Barrett's oesophagus are considered to have a 30-125 times higher risk of developing adenocarcinoma in the oesophagus than the general population<sup>2,3</sup> and prospective endoscopic surveillance is thus recommended. It is of utmost importance to find the Barrett's cancers at an early stage<sup>4,5</sup>, as they are otherwise difficult to cure. However, early malignant changes of Barrett's

epithelium are not accompanied by manifest symptomatology and evident changes to be seen at white light endoscopy and therefore difficult to detect. Biopsies are taken randomly from patients with Barrett's epithelium at each endoscopy session to increase the probability of finding the early malignant changes. However, the lesions are often patchy distributed and many biopsies are thus needed. This is impractical and may even be hazardous to the patient.

The 5-year survival rate of patients diagnosed with Barrett's carcinoma is today only approximately 7%<sup>6,7</sup>. It is therefore essential to develop new methods, as for example laser-induced fluorescence (LIF), for detection of early Barrett's adenocarcinoma. Earlier clinical *in vivo* results in tumour fluorescence detection have been reported for various organs, such as the urinary bladder and the lungs<sup>8, 9, 10</sup>. In addition, a promising report on autofluorescence measurements in three cases of Barrett's adenocarcinoma has been published<sup>11</sup>. The complete results of our clinical *in vitro* and *in vivo* LIF-measurements of adenocarcinoma in Barrett's oesophagus using low-dose Photofrin are presented elsewhere<sup>12</sup>.

## 2. MATERIAL AND METHODS

Laser-induced fluorescence measurements were performed in five patients during conventional endoscopy procedures. The biopsy channel in the endoscope was used to introduce the optical fibre, guiding the laser light to the lesion in the oesophagus and the fluorescence from the lesion to the detector. Biopsies were taken according to established practice<sup>13</sup> after completed LIF-measurements, in order to avoid the influence of the resulting bleeding on the recorded fluorescence spectra. Therefore, it was not possible to take the biopsies from the exact measurement sites and correlate the result from each LIF-measurement with the histological status of the epithelium. The total result of the fluorescence measurements was instead correlated with the final diagnosis, based on the biopsies taken. Sixty-five fluorescence spectra were recorded at the five endoscopy sessions.

### 2.1 Patients

The patients were numbered 1 to 5. Patients 1 to 3 had manifested gross carcinoma at endoscopy and was also histologically verified as adenocarcinoma. The other two patients, 4 and 5, had Barrett's oesophagus but not yet any evidence of malignant transformation. All patients were injected *i.v.* with 0.35 mg/kg b.w. of Photofrin<sup>®</sup> (QLT, Vancouver, Canada) 24 hours prior to the endoscopy sessions. Owing to this low dose of Photofrin, there were no cases of dermal photosensitisation, and no precautions concerning exposure to the sun or other light sources were necessary<sup>9, 10</sup>.

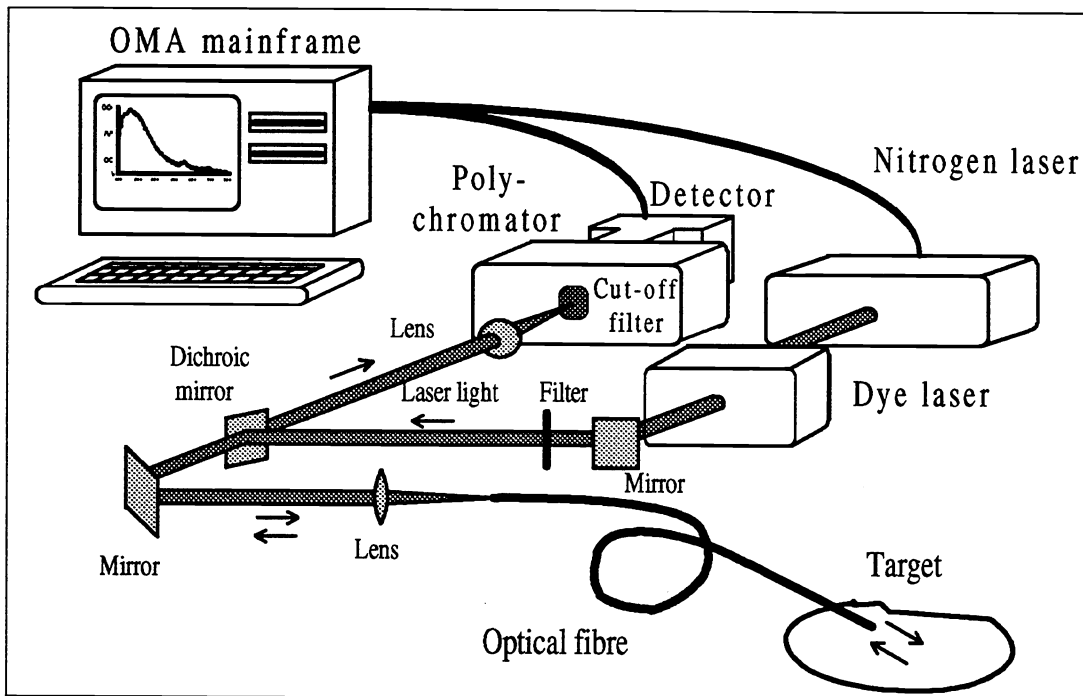


Figure 1. The set-up of the OMA (optical multichannel analyser) system for fluorescence measurements.

## 2.2 Fluorescence measurement equipment

A clinically adapted optical multichannel analyser (OMA) system, arranged on a mobile trolley, was used for the fluorescence measurements. The set-up is shown in Figure 1 and described in detail elsewhere<sup>8</sup>. Briefly, a dye laser pumped by an  $N_2$ -laser was used as an excitation light source. The laser system yielded an excitation wavelength of 405 nm with 10  $\mu$ J/pulse at a repetition rate of 10 Hz. The light was guided by mirrors, through lenses and finally through a 600  $\mu$ m core diameter quartz optical fibre, introduced in the biopsy channel of the endoscope, to the lesion in the oesophagus. The fibre tip was held in close contact with the tissue during the measurements. The resulting fluorescence from the tissue and the retained porphyrin from the Photofrin was collected and guided by the very same optical fibre to the detector, a CCD camera connected to a polychromator. A computer was used to control the equipment and to store and analyse the measured spectra. The fluorescence spectra were recorded from 8-23 locations per patient between 450 and 750 nm with a resolution of approximately 10 nm.

## 2.3 Analysis of the fluorescence spectra

The fluorescence spectra were analysed by taking a ratio of a corrected fluorescence intensity at 630 nm divided by the recorded fluorescence at 500 nm:  $I(630 \text{ nm})/I(500 \text{ nm})$ . The corrected fluorescence intensity at 630 nm,  $I(630 \text{ nm})$ , was obtained as the total fluorescence intensity at 630 nm minus the tissue autofluorescence at 630 nm, evaluated by fitting an exponential curve,  $I=A+Be^{-cx}$ , in the wavelength region 550 to 600 nm and 730-750 nm. This ratioing makes the

result insensitive to probe positioning, light source fluctuations and other measurement inconsistencies. The fluorescence intensities at these two wavelengths are used to calculate the fluorescence ratio as they basically represent two types of information for tumour identification in the two different wavelength regions of a spectrum. The corrected fluorescence at 630 nm originates mainly from the porphyrin, whereas the fluorescence at 500 nm originates mainly from endogenous tissue fluorophores, resulting in the autofluorescence. It has previously been shown that malignant tissue yields higher fluorescence ratios than normal tissue, as the malignant mucosa in general contains more porphyrin and thus has a stronger porphyrin fluorescence<sup>14</sup>. In addition, malignant tissue has a weaker autofluorescence, which also results in higher fluorescence ratios.

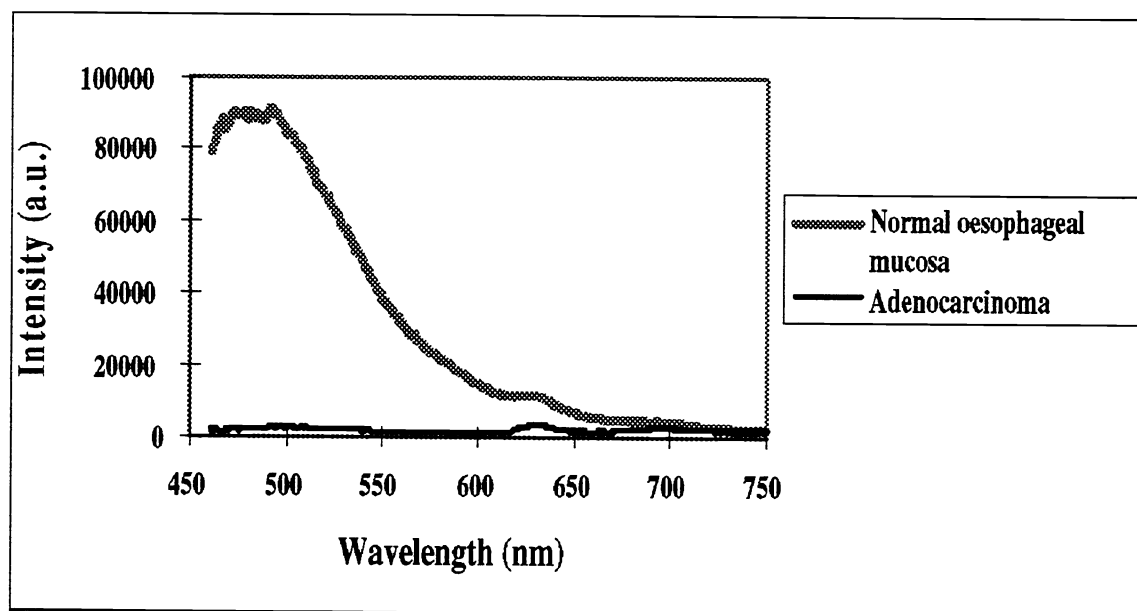


Figure 2. Typical fluorescence spectra recorded from normal oesophageal mucosa and adenocarcinoma.

### 3. RESULTS

Figure 2 shows two examples of recorded spectra from patient 1. A typical spectrum from normal oesophageal mucosa and one from tissue with manifest adenocarcinoma are presented. The tissue was assessed visually by the endoscopist. There was a histological verification of the tissue area, as the biopsies were collected approximately from the measurement site. The spectrum from normal mucosa is characterised by high autofluorescence at approximately 500 nm, which implies low fluorescence ratios, whereas the spectrum from the adenocarcinoma is characterised by low autofluorescence resulting in high fluorescence ratios. The difference in the fluorescence at 630 nm between the two spectra is not as significant and does not contribute that much to the discrimination between the fluorescence ratios of the two tissue types.

The evaluated fluorescence ratios are all shown in Figure 3, separately presented for each patient. Patients 1 to 3, with histologically verified Barrett's adenocarcinoma, show rather high fluorescence ratios compared to the values of patients 4 and 5. Patients 4 and 5 are diagnosed to

have Barrett's oesophagus without any evidence of malignant transformation. The circular symbols represent fluorescence ratios obtained from adenocarcinoma according to visual assessment by the endoscopist, whereas the square symbols represent ratios from normal mucosa and Barrett's epithelium, again according to visual assessment at endoscopy.

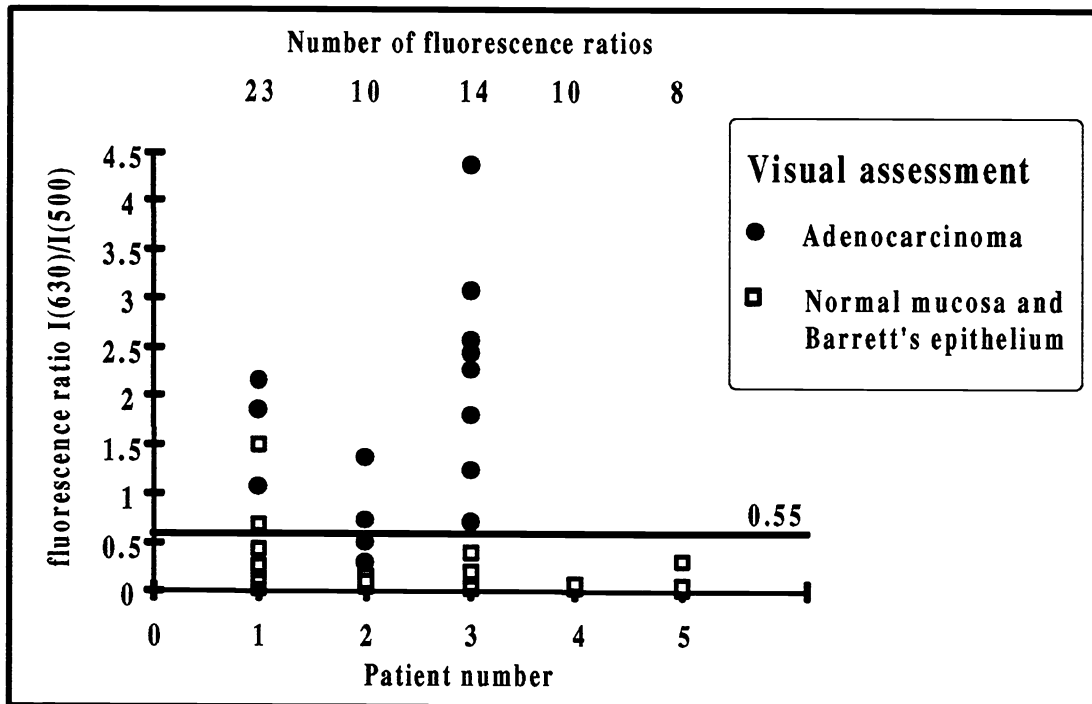


Figure 3. Evaluated fluorescence ratios for each patient related to the cut-off value of 0.55. Patients 1 to 3 have histologically verified Barrett's adenocarcinoma, whereas patients 4 and 5 are diagnosed to have Barrett's oesophagus without any evidence of malignant transformation. Circular symbols represent ratios obtained from adenocarcinoma and square symbols represent ratios from normal mucosa and Barrett's epithelium. The measurement sites are classified according to visual assessment by the endoscopist. Note the number of evaluated fluorescence ratios for each patient (in the upper part of the figure), as several values overlap.

#### 4. DISCUSSION

There is much to be gained with an applicable clinical method to detect early malignant transformation in Barrett's oesophagus, considering today's 5-year survival rate of 7%<sup>6,7</sup>. Our results indicate that laser-induced fluorescence has a potential to increase the diagnostic yield in order to find the Barrett's carcinomas when they are curable, i.e. at an early stage.

All three patients with histologically verified adenocarcinoma manifested high fluorescence ratios, whereas the two patients without evidence of malignant transformation did not. The ratios were compared with a cut-off level of 0.55, which was found in a previous *in vitro* study<sup>12</sup>. The result of that study was that all ratios above 0.55 represented malignancy. As can be seen in Figure 3, ratios above 0.55 were found in all patients with adenocarcinoma but not in the other two patients. Thus,

diagnosis based on fluorescence measurements was in good agreement with that based on biopsies. All fluorescence ratios, apart from two, obtained from adenocarcinomas (visual assessment by the endoscopist) were above the cut-off level of 0.55. The diagnosis based on the fluorescence ratios differed from the visual assessment of the tissue in four cases out of 65 measurements. This should rather be seen as an indication, as visual assessment is not as reliable as histological evaluation. Still, the agreement is remarkably good, probably due to the macroscopically manifest occurrence of the tumours.

The difference in the fluorescence at 630 nm between the two spectra was not as distinct as expected. The difference in the fluorescence ratios between normal tissue and adenocarcinoma is thus mainly due to differences in the autofluorescence and not in the porphyrin fluorescence. This means that the porphyrin was probably not selectively retained in the tumour tissue to the same extent as have been seen in other organs<sup>14</sup> and did not contribute very much to the tumour identification. It implies that fluorescence diagnostics of malignancies in the oesophagus may be possible without any sensitiser, thus simplifying the procedure.

Laser-induced fluorescence cannot replace the collection of biopsies, but it can guide the endoscopist to select multiple biopsy sites in suspicious areas indicated by high fluorescence ratios. Compared to biopsies taken at random, this procedure would minimise the number of biopsies taken and increase the probability in finding the early malignant changes in Barrett's oesophagus. A complete scanning of the oesophagus in order to find suspicious areas would even be possible using a system that images the tissue in terms of fluorescence ratios. This has been performed on a research basis in other organs<sup>15, 16</sup>.

We have demonstrated that laser-induced fluorescence can be used to distinguish Barrett's oesophagus with malignant transformation from those without malignancies. Although some questions still remain to be answered, this diagnostic technique seems to be a powerful and easily performed procedure to increase the diagnostic yield in Barrett's oesophagus.

## 5. ACKNOWLEDGEMENTS

Valuable discussions and support from Sune Svanberg and Dick Killander are appreciated. The study was funded by the Swedish Research Council for Engineering Sciences, the Swedish Cancer Foundation and the Xillix Technologies Corp, which is gratefully acknowledged.

## 6. REFERENCES

1. S. Spechler and R. Goyal, "Barrett's oesophagus." *New Engl J Med*, Vol. 315, pp. 362-371, 1986.
2. A. Cameron, B. Ott and W. Payne, "The incidence of adenocarcinoma in columnar-lined (Barrett's) oesophagus." *New Engl J Med*, Vol. 313, pp. 857-859, 1985.
3. W. Hameeteman, G. Tytgat, H. Houthoff and J. van den Tweel, "Barrett's oesophagus. Development of dysplasia and adenocarcinoma." *Gastroenterology*, Vol. 96, pp. 1249-1256, 1989.
4. C. Robertson, J. Mayberry, D. Nicholson, P. James and M. Atkinson, "Value of endoscopic surveillance in the detection of neoplastic change in Barrett's oesophagus." *Br J Surg*, Vol. 75, pp. 760-763, 1988.
5. J. Johansson, F. Johnsson, B. Walther, C. Staël von Holstein, R. Willén and T. Zilling, "Adenocarcinoma in the distal oesophagus with and without Barrett's epithelium. Differences in symptoms and survival rate." Submitted to *Br J Surg*, 1995.
6. D. Skinner, B. Walther, R. Riddell, H. Schmidt, C. Iascone and T. DeMeester, "Barrett's oesophagus: comparison of benign and malignant cases." *Ann Surg*, Vol. 198, pp. 554-566, 1983.
7. R. Sjögren and L. Johnsson, "Barrett's oesophagus: A review." *Am J Med*, Vol. 74, pp. 313-320, 1983.
8. S. Andersson-Engels, Å. Elner, J. Johansson, S.-E. Karlsson, L. G. Salford, L.-G. Strömblad, K. Svanberg and S. Svanberg, "Clinical recordings of laser-induced fluorescence spectra for evaluation of tumour demarcation feasibility in selected clinical specialities." *Lasers Med Sci*, Vol. 6, pp. 415-424, 1991.
9. L. Baert, R. Berg, B. van Damme, J. Johansson, K. Svanberg and S. Svanberg, "Clinical fluorescence diagnosis of human bladder carcinoma following low-dose Photofrin injection." *Urology*, Vol. 41, pp. 322-330, 1993.
10. S. Lam, B. Palcic, D. McLean, J. Hung, M. Korblik and A. E. Profio, "Detection of early lung cancer using low dose Photofrin II." *Chest*, Vol. 97, pp. 333-337, 1990.
11. K. Wang, K. Gutta, M. Laukka and J. Densmore, "Laser induced fluorescence in the detection of oesophageal carcinoma." *SPIE*, Vol. 2324, pp. 14-18, 1995.
12. C. Staël von Holstein, A. M. K. Nilsson, S. Andersson-Engels, R. Willén, B. Walther and K. Svanberg, "Detection of adenocarcinoma in Barrett's oesophagus by means of laser-induced fluorescence." Submitted to *The Lancet*, 1995.

13. B. Reid, W. Weinstein, K. Lewin, R. Haggitt, G. van Deventer, L. den Besten and C. Rubin, "Endoscopic biopsy can detect high-grade dysplasia or early adenocarcinoma in Barrett's oesophagus without grossly recognisable neoplastic lesions." *Gastroenterology*, Vol. 94, pp. 81-90, 1984.
14. S. Andersson-Engels and B. C. Wilson, "In vivo fluorescence in clinical oncology: fundamental and practical issues." *J Cell Pharmacol*, Vol. 3, pp.48-61, 1992.
15. S. Andersson-Engels, J. Johansson and S. Svanberg, "Medical diagnostic system based on simultaneous multi-spectral fluorescence imaging." *Appl Opt*, Vol. 33, pp. 8022-8029, 1994.
16. S. Andersson-Engels, R. Berg, K. Svanberg and S. Svanberg, "Multi-colour fluorescence imaging in connection to photodynamic therapy of  $\delta$ -amino levulinic acid (ALA) sensitised skin malignancies." Accepted by *Bioimaging*, 1995.