LUND UNIVERSITY

Preterm intraventricular cerebral hemorrhage: role of cell-free hemoglobin

Agyemang, Alex Adusei

2019

Document Version:
Publisher's PDF, also known as Version of record

Link to publication

Citation for published version (APA):
Agyemang, A. A. (2019). *Preterm intraventricular cerebral hemorrhage: role of cell-free hemoglobin*. [Doctoral Thesis (compilation), Department of Clinical Sciences, Lund]. Lund University: Faculty of Medicine.

Total number of authors:
1

General rights
Unless other specific re-use rights are stated the following general rights apply:
Copyright and moral rights for the publications made accessible in the public portal are retained by the authors and/or other copyright owners and it is a condition of accessing publications that users recognise and abide by the legal requirements associated with these rights.
• Users may download and print one copy of any publication from the public portal for the purpose of private study or research.
• You may not further distribute the material or use it for any profit-making activity or commercial gain
• You may freely distribute the URL identifying the publication in the public portal

Read more about Creative commons licenses: https://creativecommons.org/licenses/

Take down policy
If you believe that this document breaches copyright please contact us providing details, and we will remove access to the work immediately and investigate your claim.

LUND UNIVERSITY

PO Box 117
221 00 Lund
+46 46-222 00 00

Preterm intraventricular cerebral hemorrhage: role of cell-free hemoglobin

ALEX ADUSEI AGYEMANG
DEPARTMENT OF CLINICAL SCIENCES | FACULTY OF MEDICINE | LUND UNIVERSITY

Preterm intraventricular cerebral hemorrhage: role of cell-free hemoglobin

Preterm intraventricular cerebral hemorrhage: role of cell-free hemoglobin

Alex Adusei Agyemang

LUND
UNIVERSITY

DOCTORAL DISSERTATION
by due permission of the Faculty of Medicine, Lund University, Sweden.
To be defended at Belfragesalen, BMC Sölvegatan 19, Lund.
Friday, March 15th at 9pm.

Faculty opponent
Professor Praveen Ballabh
Albert Einstein College, New York

Organization LUND UNIVERSITY	Document name DOCTORAL DISSERTATION
	Date of issue
Author: Alex Adusei Agyemang	Sponsoring organization

Title and subtitle. Preterm intraventricular cerebral hemorrhage: role of cell-free hemoglobin

Abstract

Cerebral intraventricular hemorrhage in preterm infants continues to be a major clinical problem associated with neurodevelopmental abnormalities manifested by cognitive, behavioral, attentional, social and motor deficits.

Hypothesis and aims: The central thesis is that the cytotoxicity of extravasated blood and of consequently released cell-free hemoglobin(Hb) is pivotal for the pathophysiological events causally involved in brain injury. The general aim focuses on the development and implementation of novel neuroprotective strategies with the aim of promoting brain development in preterm infants with high risk for neurodevelopmental impairment.

Methods: *Paper I.* The presence and distribution of cell-free Hb in the periventricular white matter was evaluated in preterm rabbit pups with intraventricular hemorrhage(IVH). *Paper II.* The distribution, deposition and effect of cell-free Hb on cerebellar development was investigated following IVH in preterm rabbit pups. The protective effect of the cell-free Hb scavenger haptoglobin (Hp) was evaluated. *Paper III*. The relative cytotoxicity of the different cell-free Hb metabolites was evaluated in mixed glial cell culture. *Paper IV*. The biodistribution and functional protection of intraventricularly administered recombinant (alpha 1 microglobulin (rA1M), a heme and radical scavenger was investigated following IVH in preterm rabbit pups.

Results: *Paper I.* IVH was associated with extensive amounts of cell-free Hb in the periventricular white matter, with a wide distribution throughout the brain. *Paper II.* IVH was followed by a decreased proliferation in the external granular layer (EGL), delayed Purkinje cell maturation and activated microglia in the cerebellum. Cell-free Hb was present in all cerebellar layers, with a gradient towards the molecular and white matter layers. Intraventricular administration of Hp resulted in a partial reversion of the damaging effects following IVH. *Paper III.* Met/oxidized Hb and not oxyHb was found to initiate a proinflammatory and oxidative response with cytoskeletal disintegration in mixed glial cell cultures. *Paper IV.* Administered rA1M following IVH was widely distributed in periventricular white matter tissue and present throughout the fore- and mid brain extending to the cerebellum,with a high coexistence of cell-free Hb. Administration of r A1M resulted in an attenuation of proinflammatory and oxidative damage.

Conclusions: IVH is characterized by the penetration of cell-free Hb into periventricular brain tissue and cerebellum resulting in a proinflammatory and oxidative damage to the brain. Hp and A1M, scavengers of cell-free Hb and Hb

metabolites respectively, attenuate the damage sustained by the periventricular white matter and cerebellum, affirming cell-free Hb to be causally involved in the brain damage resulting from IVH. Hp and A1M hence appear potential candidates for neuroprotective strategies against brain damage following IVH

Key words: IVH, Cell-free hemoglobin, Preterm birth, Hp, A1M, cerebellar hypoplasia, periventricular white matter

Classification system and/or index terms (if any)

Supplementary bibliographical information		Language English
ISSN 1652-8220		ISBN 978-91-7619-751-6
Recipient's notes	Number of pages	Price
	Security classification	

I, the undersigned, being the copyright owner of the abstract of the above-mentioned dissertation, hereby grant to all reference sources permission to publish and disseminate the abstract of the above-mentioned dissertation.

Signature  Date 2019-02-04

Preterm intraventricular cerebral hemorrhage: role of cell-free hemoglobin

Alex Adusei Agyemang

LUND
UNIVERSITY

Coverphoto by Bo Holmqvist

Copyright Alex Adusei Agyemang

Paper 1 © Frontiers in Physiology

Paper 2 © Translational Stroke Research, Springer

Paper 3 © by the Authors (Manuscript submitted)

Paper 4 © by the Authors (Manuscript unpublished)

Faculty of Medicine
Department of Clinical Sciences
Lund University, Sweden

ISBN 978-91-7619-751-6
ISSN 1652-8220

Printed in Sweden by Media-Tryck, Lund University
Lund 2019

MADE IN SWEDEN

Media-Tryck is an environmentally certified and ISO 14001 certified provider of printed material. Read more about our environmental work at www.mediatryck.lu.se

To
The Lord Jesus, my wife and daughter

...Look, children are a gift of the Lord, and the fruit of the womb is a reward.
Psalm 127:3(MEV)

Table of Contents

Original papers 10
Papers not included 10
Abbreviation 11
Preface 13
Abstract 14
Introduction 15
Preterm intraventricular hemorrhage 15
Preterm birth 15
Survival following preterm birth 15
Major morbidites 15
IVH and long-term morbidity 16
Pathophysiology of IVH 16
Clinical presentation 17
Classification 17
Mechanism of brain injury 17
Cell-free hemoglobin (Hb) 17
The damaging role of cell-free hemoglobin 17
Treatment of IVH 20
Preterm IVH rabbit pup model 21
IVH and the brain 23
Periventricular brain damage 23
The cerebellum 24
Glial cells in brain development 27
Hypothesis and aims 31
Paper I 31
Paper II 31
Paper III 32
Paper IV 32

Methods and materials **33**
Preterm IVH pup model 33
Paper I, Paper II and Paper IV 33
Conditions, handling and protocols 33
Survival 34
Ultrasound imaging of the brain 34
Intraventricular injections 35
Brain tissue sampling and processing 35
In vitro cell culture study 37
Cell culture 37
Preparation of oxyHb, oxidized Hb and heme 37
Experimental design 38
Analysis 38
Periventricular brain tissue 38
Cerebellum 40
Mixed glia 41
RNA Isolation and Real-Time PCR 42
Statistics 43
Results and comments **45**
Paper I 45
Paper II 46
Paper III 47
Paper IV 48
Conclusion and future perspectives **49**
Acknowledgement **51**
References **53**

Original papers

I. Ley D, Romantsik O, Vallius S, Sveindóttir K, Sveindóttir S, Agyemang AA, Baumgarten M, Mörgelin M, Lutay N, Bruschettini M, Holmquist B, Gram M. High presence of extracellular hemoglobin in periventricular white matter following preterm intraventricular hemorrhage. Front Physiol 2016; 7:330

II. Agyemang AA, Sveindóttir K, Vallius S, Sveindóttir S, Bruschettini M, Romantsik O, Hellström A, Smith LEH, Ohlsson L, Holmquist B, Gram M, Ley D. Cerebellar exposure to cell-free hemoglobin following preterm intraventricular hemorrhage: Causal in cerebellar damage? Transl Stroke Res 2017; 8:41

III. Agyemang AA, Vallius S, Brinkman N, Gentinetta T, Armengol MI, Ley D, Gram M. Cell-free oxidized hemoglobin drives reactive oxygen species production and pro-inflammation in a mixed glial culture: Implications for damage and intervention following preterm intraventricular hemorrhage? In manuscript.

IV. Romantsik O, Agyemang AA, Sveindóttir S, Rutardóttir S, Holmquist Bo, Cinthio M, Mörgelin M, Gulcin Gumus, Karlsson H, Hansson SR, Åkerström B, Ley D, Gram M. The heme and radical scavenger alpha 1 microglobulin confers protection on the immature brain following preterm intraventricular hemorrhage: A detailed characterization of the biodistribution and early functional protection following intraventricular hemorrhage. Submitted to Journal of Neuroinflammation.

Papers not included

Gumus HG, **Agyemang AA**, Romantsik O, Sandgren R, Karlsson R, Gram M, Vallius S, Ley D, Van den Hove DLA, Bruschettini M. Behavioral testing and litter effects in rabbits. *Behav Brain Res 2018; 353:236-241*.

Abbreviation

IVH	intraventricular hemorrhage
GW	gestational week
NICU	neonatal intensive care unit
CSF	cerebrospinal fluid
Hb	hemoglobin
RBCs	red blood cells
ROS	reactive oxygen species
TNFα	tumor necrosis factor alpha
A1M	alpha-1-microglobulin
GMH	germinal matrix hemorrhage
HIE	hypoxic ischemic encephalopathy
PWMI	periventricular white matter injury
HI	Hypoxia inschemia
MRI	magnetic resonance imaging
EGL	external granular layer
GABA	gamma aminobutyric acid
ML	molecular layer
IGL	internal granular layer
GCP'S	granular cell precursors
IL	interleukin
TLR4	toll-like receptor 4
MCP-1	monocyte chemoattractant protein-1
MMP 9	matrix metalloproteinase 9
INOS	inducible nitric oxide synthase
TEM	transmission electron microscopy
CCL2	chemokine (c-c motif) ligand 2

CCL5	chemokine (c-c motif) ligand 5
NGAL	neutrophil-gelatinase associated lipocalin
PL	Purkinje layer
BLI	biolayer interferometry
HO-1	heme oxygenase-1
SOD2	superoxide dismutase 2
IGF1	insulin like growth factor 1
Shh	sonic hedgehog
BBB	blood brain barrier
OPC'S	oligodendrocyte precursor cells
PreOL's	preoligodendrocytes
SAH	subarachnoid hemorrhage
SEM	scanning electron microscopy
ICC	immunocytochemistry
IHC	immunohistochemistry
IF	immunofluorescence
HE	hemoxylin eosin
PO	peroxidase activity
PSA-NCAM	polysialic acid neural cell adhesion molecule
CNS	central nervous system
COX 2	cyclooxygenase 2

Preface

The survival of smaller and extremely preterm infants has increased over the years due to improvement in clinical practice at the neonatal intensive care unit. The increased survival however is associated with major complications.

These very preterm infants are poorly adapted to the extrauterine environment. This results in nutritional deficits, insufficient levels of growth factors and changes in neurovascular factors. Intraventricular hemorrhage, a complication of very preterm birth is associated with major motor and cognitive deficits. Today, no therapy exists to prevent these preterm infants with IVH from developing serious neurological disability. Hence, an investigation into the pathophysiological events leading to brain damage is needed to support the development of novel neuroprotective interventions.

The cytotoxicity of blood products in the immature brain following the hemorrhage has been suggested to be central to the irreversible brain injury. This thesis focuses on delineating the important role of cell-free hemoglobin *ie* hemoglobin outside the red blood cell compartment, in the pathophysiological events participating in development of brain damage.

Abstract

Cerebral intraventricular hemorrhage in preterm infants continues to be a major clinical problem associated with neurodevelopmental abnormalities manifested by cognitive, behavioral, attentional, social and motor deficits.

Hypothesis and aims: The central thesis is that the cytotoxicity of extravasated blood and of consequently released cell-free hemoglobin (Hb) is pivotal for the pathophysiological events causally involved in brain injury. The general aim focuses on the development and implementation of novel neuroprotective strategies with the aim of promoting brain development in preterm infants with high risk for neurodevelopmental impairment.

Methods: *Paper I.* The presence and distribution of cell-free Hb in the periventricular white matter was evaluated in preterm rabbit pups with intraventricular hemorrhage (IVH). *Paper II.* The distribution, deposition and effect of cell-free Hb on cerebellar development were investigated following IVH in preterm rabbit pups. The protective effect of the cell-free Hb scavenger haptoglobin (Hp) was evaluated. *Paper III*. The relative cytotoxicity of the different cell-free Hb metabolites was evaluated in mixed glial cell culture. *Paper IV*. The biodistribution and functional protection of intraventricularly administered recombinant alpha-1-microglobulin (rA1M), a heme and radical scavenger was investigated following IVH in preterm rabbit pups.

Results: *Paper I.* IVH was associated with extensive amounts of cell-free Hb in the periventricular white matter, with a wide distribution throughout the brain. *Paper II.* IVH was followed by a decreased proliferation in the external granular layer (EGL), delayed Purkinje cell maturation and activated microglia in the cerebellum. Cell-free Hb was present in all cerebellar layers, with a gradient towards the molecular and white matter layers. Intraventricular administration of Hp resulted in a partial reversion of the damaging effects following IVH. *Paper III.* Met/oxidized Hb and not oxyHb was found to initiate a proinflammatory and oxidative response with cytoskeletal disintegration in mixed glial cell cultures. *Paper IV.* Administered rA1M following IVH was widely distributed in periventricular white matter tissue and present throughout the fore- and mid brain extending to the cerebellum, with a high coexistence of cell-free Hb. Administration of rA1M resulted in an attenuation of proinflammatory and oxidative damage.

Conclusions: IVH is characterized by the penetration of cell-free Hb into periventricular brain tissue and cerebellum resulting in a proinflammatory and oxidative damage to the brain. Hp and A1M, scavengers of cell-free Hb and Hb metabolites respectively, attenuate the damage sustained by the periventricular white matter and cerebellum, affirming cell-free Hb to be causally involved in the brain damage resulting from IVH. Hp and A1M hence appear potential candidates for neuroprotective strategies against brain damage following IVH

Introduction

Preterm intraventricular hemorrhage

Preterm birth

Preterm intraventricular hemorrhage (IVH), characterized by bleeding into the ventricular cavities of the brain continues to be a major clinical problem associated with very preterm birth.

Every year, about 15 million babies are born preterm worldwide. Preterm birth is defined as birth before 37 gestational weeks (GW). These preterm infants can be further classified into three groups based on gestational week at birth; moderate to late preterm (32 to 37 weeks), very preterm (28 to 32 weeks) and extremely preterm (<28weeks). For the purpose of this thesis, preterm infants refer to very and extremely preterm birth.

Survival following preterm birth

The survival rate of preterm infants has increased over the past decades due to modernization and improvement in clinical practices at the NICU as well as in care before birth. Although this is very positive, surviving preterm infants are prone to brain damage and, as a consequence, compromised neurodevelopment. This is quite alarming considering relevant statistics.

Every year in the United States alone, 63000 infants are born very preterm with 12 000 infants developing IVH[1]. In Sweden, very preterm birth equals 1600 infants every year with the number for Ghana hovering around 50000 a year.

Major morbidites

The pathophysiological events leading to brain abnormalities in surviving premature infants ensue from both the white and grey matter. Indeed, periventricular leucomalacia, a non-hemorrhagic brain injury associated with cerebral white matter lesions occurs in about 50% of very low birthweight infants [2-6]. Of particular

importance to this thesis, is the major hemorrhagic lesion, the preterm intraventricular hemorrhage with an incidence rate of 20%.

In these very immature infants, other non-cerebral related lesions with great impact on the future health may develop. These major morbidities include necrotizing enterocolitis, bronchopulmonary dysplasia and retinopathy of prematurity [7-9].

IVH and long-term morbidity

IVH is a significant and independent contributor to long-term impairment in preterm infants. IVH in surviving preterm infants is associated with post-hemorrhagic ventricular dilatation and major neuro-developmental impairment including cerebral palsy and severe cognitive disability [10-15].

Pathophysiology of IVH

IVH may occur in adults from a decompression or extension of the hematoma resulting from an intraparenchymal hemorrhage into the ventricles. Thus termed secondary IVH or as a primary IVH ascribed to an intraventricular source or lesion contigious to the ventricles, inclusively; vascular malformations and tumors of the choroid plexus, aneurysm, intraventricular trauma etc [16].

Unlike IVH in adults, preterm IVH that occurs following preterm delivery is mainly a progression of a germinal matrix hemorrhage. The germinal matrix is a germinal region located between the caudate nucleus and the ependymal lining of the lateral ventricles. The germinal matrix is a highly vascularized region made up of actively dividing neuronal and glial progenitor cells which give rise to cells making up the grey matter in the developing baby. The germinal matrix reaches maximal thickness at gestational week 24 and thereafter gradually reduces and disappears by week 35, this being the reason why germinal matrix IVH occurs predominantly in the preterm newborn [12, 13, 17, 18]. Preterm IVH mostly occurs in the first postnatal week, 90% of the hemorrhages usually occurring within the first three postnatal days [19]. The incidence of IVH increases with decreasing gestational age at birth.

The etiology of preterm IVH is multifactorial and complex. Predisposition to IVH can be ascribed to intravascular, vascular and extravascular factors. The factors include fragility of the germinal matrix vasculature inherent to the preterm newborn, fluctuations in cerebral blood flow, increase in cerebral venous pressure, hypoxia, hypercarbia and coagulation abnormalities leading to hemostasis impairment [4, 12, 13, 20].

Clinical presentation

Depending on the severity of IVH, it may be clinically manifested as catastrophical characterized by a bulging fontanel, split sutures and change in level of consciousness or saltatory, marked by gradual deterioration in neurological status or asymptomatic discovered by bedside cranial ultrasound [21, 22].

Classification

Preterm IVH is classified based on the anatomical distribution of the bleeding. Grade 1: The bleeding is limited to the subependymal germinal matrix. Grade 2: The bleeding extends to the brain ventricles, occupying less than 50% of the ventricular volume. Grade 3: Bleeding is marked by an extensive coverage of greater than 50% of the ventricular volume leading to ventricular distension. Grade 4: also known as parenchymal hemorrhagic infarction is an IVH with parenchymal involvement. Grade 1 and 2 are frequently categorized as mild IVH while grades 3 and 4 as severe [23].

Mechanism of brain injury

Despite substantial research over the years, the complex molecular mechanisms involved in development of brain injury following IVH are incompletely understood. Primarily, brain injury can ensue from IVH due to the mechanical or mass effect of the hematoma. This causes an increase in intracranial pressure leading to a decrease in cerebral perfusion. Also blockade of cerebrospinal fluid (CSF) conduits by the hemorrhagic blood is considered to obstruct the reabsorption of CSF leading to post-hemorrhagic ventricular dilatation and hydrocephalus. Depending on the dynamics of the hematoma expansion, the primary damage may occur minutes or hours from the onset of bleeding. The secondary damage however is attributable to pathophysiological events linked to the presence of blood and blood products [24-26].

Cell-free hemoglobin (Hb)

The damaging role of cell-free hemoglobin

Hemoglobin (Hb), a heme conjugated protein confined to red blood cells (RBC'S) plays an important role in maintaining cellular bioenergetic homeostasis. Not only that but has vital functions in fertilization, molecular signaling and modulation of

the innate and adaptive immunity. Structurally, Hb contains the prosthetic group heme, a tetrapyrole ring with Fe^{2+} coordinated to globin proteins. Oxygen has a higher reduction potential than iron (Fe^{2+}), which renders the heme prosthetic group susceptible to spontaneous autoxidation (Fe^{2+} to Fe^{3+}), especially when the oxygen tension is very low. Notwithstanding, this is curtailed intracellularly by the presence in the RBCs of enzymatic reductases, maintaining the iron in an Fe^{2+} oxidation state. Thus at normal physiology, only 1-3% of the hemoglobin mass is found in the Fe^{3+} oxidation state [27-29].

Contrary to the enormous importance of Hb to aerobic organisms, outside the confines of the RBCs, a friend as we know it to be turns a foe. Following intravascular or extravascular hemolysis, cell-free Hb, a redox active protein comes in contact with the extracellular environment. Such Hb outside the confines of the RBC'S has been reported to be cytotoxic and damaging to tissues in several disease contexts including cerebral malaria and sickle cell anemia [28, 30-33].

In fact, the neurotoxicity of cell-free Hb and its metabolites has been reported following subarachnoid and intraparenchymal hemorrhage [34-36]. The damage is attributable to the oxidation of the ferrous Hb to hemoglobin moieties and metabolites of higher oxidation states, which induce the production of electrophilic free radicals and reactive oxygen species (ROS). These metabolites, radicals and ROS are very reactive, causing tissue and cellular injury *via* induction of proinflammatory and apoptotic pathways, intercalation into cell membranes, fragmentation, covalent modification and oxidation of macromolecules [37-44]. It is on the premise of this that this thesis attempts to elucidate the pathophysiological events involved in IVH and thereby address the role of cell-free hemoglobin in the causal pathway of damage leading to functional brain impairment.

Following IVH, there is deposition of extravasated blood into the CSF of the ventricles. This leads to the accumulation of RBCs followed by a hemolytic episode forcing hemoglobin out of the intra-erythrocyte compartment. Outside it's homing in the RBC, cell-free Hb is oxidized to methemoglobin (MetHb, Fe^{3+}), induced spontaneously or via a reaction with nitric oxide. Indeed, Gram *et al* in their studies reported the accumulation of metHb (Fe^{3+}) in intraventricular CSF 72 h following preterm IVH. The concentration of the metHb correlated with that of the proinflammatory cytokine tumor necrosis factor alpha (TNFα) in the CSF [45, 46]. Indeed celecoxib, a cyclooxygenase 2(COX 2) inhibitor and TNFα inhibition reduced inflammation, gliosis and neuronal degeneration following IVH in preterm rabbit pups [47]. Further downstream reactions may lead to the production of ferrylHb (Fe^{4+}), free heme, globin radicals, heme polymer and free iron, species injurious and damaging to tissues.

Further, previous work from our group has shown that cell-free Hb and its metabolites induce cytotoxic, oxidative and proinflammatory pathways in CSF and

the choroid plexus tissue leading to damage and cell death following preterm rabbit pup IVH. Exposure to cell-free Hb and metabolites in choroidal plexus epithelial cell cultures was found to induce structural disintegration, cellular activation, apoptosis and inflammatory response similar to that observed in choroid plexus tissue from preterm rabbit pups with IVH hemorrhage [46].

Though a case can be made for the involvement of cell-free Hb in the development of brain damage, its penetration and accessibility to the periventricular parenchymal regions and important remote areas following preterm IVH had not been investigated prior to this thesis. Of further relevance, is the relative importance of the different Hb metabolites in the resulting brain injury especially when oxyHb (Fe^{2+}) in minute amounts has been reported to be neuroprotective in an other context [48, 49].

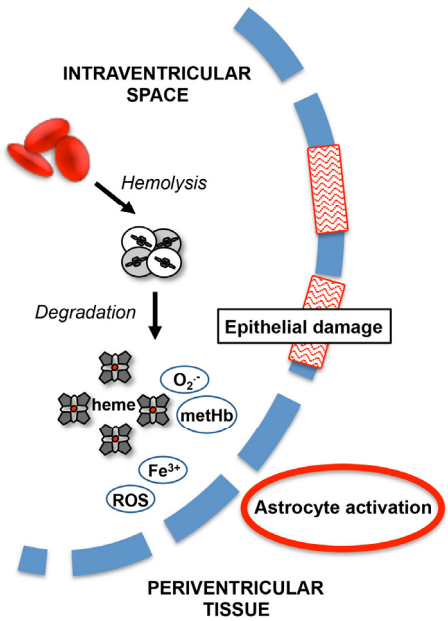

Fig 1. Intraventricular degradation of hemoglobin.
Following IVH, a hemolytic episode leads to the rapid release of hemoglobin, which subsequently undergoes a spontaneous auto-oxidation to form toxic methemoglobin (MetHb). A further degradation leads to the release of heme, free iron (Fe^{3+}) and free radicals, all of which are potentially toxic to the immature brain. Figure used with permission from Gram M

Treatment of IVH

Although the resulting deficits in neurodevelopment associated with preterm IVH are very well described, no therapy yet exists hence the importance for the development of strategies for the prevention or minimization of brain damage.

Detoxification of cell-free Hb and metabolites- the scavenger systems

Endogeneous haptoglobin (Hp) remains the main scavenger of cell-free Hb. Hp binds to cell-free Hb in the extracellular environs to form an inert complex followed by a CD163 receptor mediated endocytosis clearance by macrophages. Of note, Hp also decreases the rate of the spontaneous autoxidation of the Hb dimer. Thus, it decreases the rate of metHb formation [50-52].

The importance of the haptoglobin scavenger system in the human brain has been sparcely studied, especially in the immature brain. The adult intrathecal Hp-Hb clearance system capacity is reported to be 50000 fold lower than that of the systemic circulation. Alarmingly, the haptoglobin level in the systemic circulation of preterm infants is very low. Since the systemic circulation contributes to the intrathecal Hp, the Hp levels in this population is expected to be extremely low. Thus, following preterm IVH, the intrathecal Hp scavenger system will be quickly saturated hence with a residual inability to detoxify the cell-free Hb [50, 53]. Preterm IVH infants will therefore be vulnerable to cell-free Hb. Exogenous Hp would therefore present as a putative neuroprotective strategy in preterm IVH.

Of importance also is the heme and free radical scavenger, alpha-1-microglobulin (A1M). A1M has a multifaceted palette of mechanisms, involved in the protection against tissue damage relating to conditions associated with pathological oxidative stress. This it does as a scavenger of free radicals, ROS, capturing free heme, protecting the mitochondria and inducing tissue repair mechanisms. A1M therefore may constitute a potential therapeutic drug candidate in the protection against the neurological impairment following preterm IVH [54, 55].

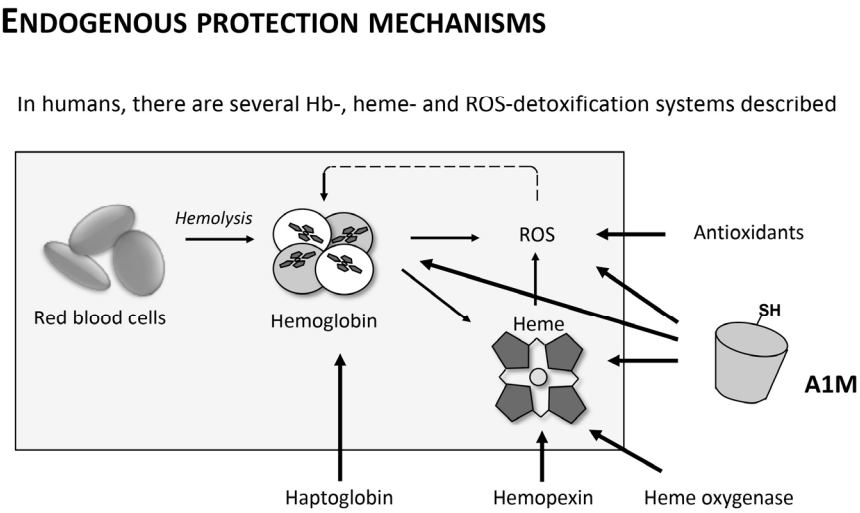

Fig 2. Detoxification systems of cell-free hemoglobin and metabolites.
A figure showing the endogenous systems for the detoxification of cell-free hemoglobin, metabolites and free radicals. Figure used with permission from Gram M.

Preterm IVH rabbit pup model

IVH remains a major complication of preterm birth. No preventive or treatment strategy yet exists for IVH. Hence, the importance of a standardized animal model of IVH to test new therapeutic modalities.

Unlike other animal species, the preterm rabbit pup model has provided for the simulation of the neurologic consequence of IVH in preterm infants. The rabbit pup closely resembles the preterm infant in many aspects, with respect to etiology, pathology and clinical consequence [16]. First, the rabbit pup delivered preterm is at a risk of spontaneous germinal matrix hemorrhage (GMH) as in the case of the preterm infant, the propensity of which increases after intraperitoneal injection of glycerol. Second, the rabbit pup has a gyrencephalic brain, an abundant germinal matrix and perinatal brain growth. Third, hypertonic cerebral palsy, a consequence of severe preterm IVH has been successfully reproduced in preterm rabbit pups unlike in other species. Motor development occurs in rabbits during the perinatal period as in humans. Fourth, periventricular inflammatory changes common to that observed in preterm IVH infants is replicated in the rabbit pup model [56].

Studies on brain development post IVH in other models like mice and rats have been performed in pups delivered at term age with an immature brain. Thus all investigations focus on postnatal development devoid of the systemic physiological alterations related to preterm birth.

The rabbit pup has an early lung development and, in comparison, a late cerebral development. This enables the IVH model to be performed in rabbit pups delivered preterm at gestational day 29 (full term is 32 days). The cerebral brain maturation in the rabbit pup at day 29 corresponds to that of the human infant at GW of 28, a period marked by cortical neurogenesis, transition to myelinating immature oligodendrocytes, ongoing regional dependant synaptogenesis and astrogenesis [57, 58]. Even more immature is the cerebellum, with the rabbit's cerebellar brain development at gestational day 29 corresponding to the cerebellar maturation of the human infant at 22 GW [58, 59].

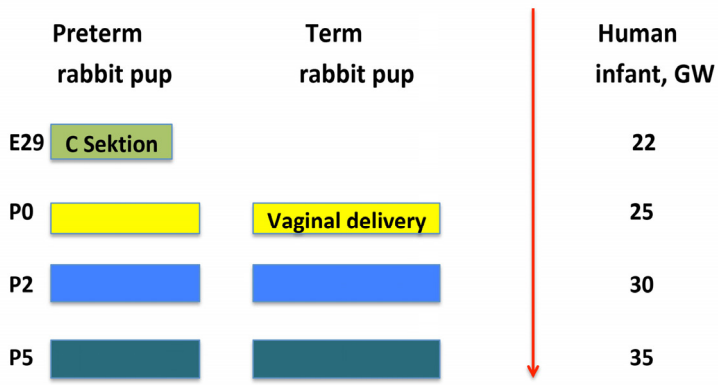

Fig 3.
The timelines for the development of the cerebellum of the preterm rabbit pup as compared to humansThe numbers on the left represent the age of the preterm rabbit pup where E29 is the day of caesarian delivery. Postnatal day 0(P0) corresponding to vaginal delivery of term born pups and to term corrected age for the preterm pups. The numbers on the right denotes corresponding maturational age in the human fetus according to translatingtime.org model

Several aspects of our preterm rabbit pup IVH model have been changed and optimized subsequent to the studies in this thesis. Following preterm delivery, the rabbit pups were cared for in an incubator where they were hand fed by a feeding tube twice daily. We currently implement the wet nurse model where a wet nurse refers to a rabbit doe that has given birth to its own pups the previous day. The term pups, with the exception of two, are taken away and replaced by preterm pups. The preterm pups are then housed, fed and cared for by the wet nurse. This has led to an

improved nutritional status and an increase in survival and improved weight development.

The application of high frequency intracranial ultrasound has permitted the non – invasive monitoring and evaluation of ventricular hemorrhage in the preterm rabbit brain. This includes evaluation with high spatial resolution of the size, grade and development of the induced IVH [16].

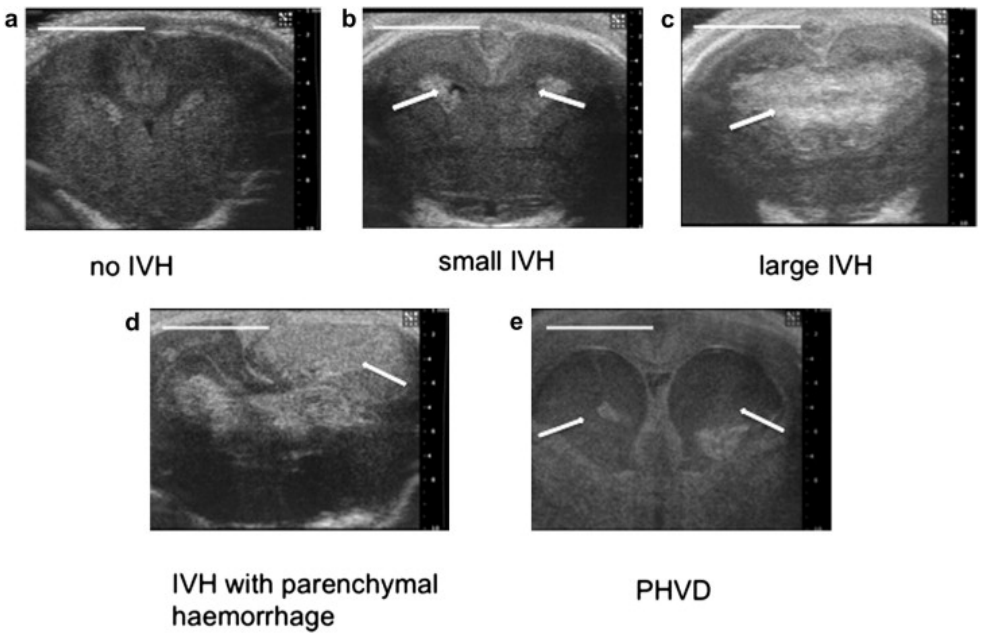

Fig 4. Classification of cerebral intraventricualr hemorrhage in rabbit pups as determined by high frequency ultrasound.
a. No IVH b. Small IVH indicated with arrows c. Large IVH indicated with arrows d. IVH with parenchymal penetration, indicated with arrows e. Post-hemorrhagic ventricular dilatation indicated with arrows. Figure used with permission from Sveindottir S

IVH and the brain

Periventricular brain damage

Fetal brain development is a dynamic process, with the changes in anatomical constitution and physiological maturation as gestation progresses accounting for the differences in brain injury patterns between term and preterm newborns [60].

Hypoxic ischemic encephalopathy in term neonates is predominantly manifested as a diffuse cerebral–deep nuclear disease with involvement of the cerebral neocortex, hippocampus and basal ganglia-thalamus. Lesions suspected to be related to hypoxia-ischemia in preterm neonates have mainly been described in cerebral white matter. Periventricular white matter injury is a leading neurological morbidity consequent to prematurity and may also occur as a consequence of IVH. Immature populations of oligodendrocytes populate the cerebral white matter in the GW of 23-32 weeks, a period corresponding to preterm birth. These oligodendrocyte progenitor cells and preoligodendrocytes are extremely vulnerable to injury induced by oxidative stress and free radicals since they lack antioxidant enzymes [2, 61].

Regarding the etiology of white matter injury due to prematurity, a large body of evidence indicates the involvement of two major pathways namely; the hypoxic ischemic and inflammation pathways. The hypoxic ischemic pathway is related to excitotoxicity and oxidative stress [62, 63]. Severe IVH leads to the deposition of cell-free Hb and its metabolites into the periventricular parenchyma. Cell-free Hb and its metabolites as ROS and free radical producing species are known to induce oxidative stress and proinflammatory pathways and hence are of causal importance in periventricular white matter injury. We therefore sought in paper 1 to investigate the penetration of cell-free Hb and metabolites into the periventricular white matter following preterm IVH in rabbit pups.

The cerebellum

Brain abnormality of prematurity manifested as neurodevelopmental disability was initially thought to involve solely the cerebrum. However, a considerable body of evidence has suggested the involvement also of the cerebellum. The infratentorially located cerebellum plays an important role in the regulation of coordination, and movement and also plays a role in cognitive function [1, 64-66]. It undergoes rapid growth during the latter half of gestation unparalled elsewhere in the brain. Three-dimensional volumetric ultrasound shows that between GW of 24-40, the cerebellar volume increases five-fold. This is coupled by an exponential growth in foliation during the same period leading to a 30-fold increase in cerebellar cortical surface area. This rapidity in growth renders the cerebellum extremely vulnerable to multiple insults following preterm birth [65, 67-72].

Cerebellar abnormality of prematurity may present itself as an overt destructive parenchymal disease. This relates to primary cerebellar hemorrhage and infarction. Cerebellar hypoplasia unrelated to overt destructive parenchymal disease may represent the most common type of cerebellar abnormality in premature infants and can be consequential to altered trophic transynaptic connection between the cerebellum and remote parts of the brain. Cerebellar hypoplasia may also originate

from direct effects including undernutrition, glucorticoid exposure, hypoxia/ischemia and hemosiderin/blood products [1, 10, 65, 73, 74].

Prevalence of cerebellar injury is recorded to be as high as 58% in premature infants with cerebral palsy following IVH. Magnetic resonance imaging (MRI) shows a strong association between cerebellar underdevelopment and the supratentorial lesion, IVH with evidence for the presence of hemosiderin on the cerebellar cortical surface [74]. This finding is suggestive of the causal mechanisms involved in cerebellar underdevelopment following IVH.

Physiologically, CSF produced by the choroid plexus passes *via* the fourth ventricle to the subarachnoid space, which has an interface with the external granular layer (EGL) of the cerebellar cortex during the prenatal period [75, 76]. Hence a case for cerebellar underdevelopment resulting from cerebellar deposition of blood products consequent to supratentorial IVH is not far fetched.

Thus in paper 2, we investigated a possible CSF mediated cerebellar deposition of blood products as a causal route of cerebellar injury following preterm IVH.

Cerebellar development

The development of the cerebellum in humans characterized by the proliferation of granule cell precursors (GCPs), establishment of internal granular layer (IGL) and maturation of Purkinje cells takes place from GW 20 to postnatal age of 2 years. The establishment of two proliferative zones in the first month of gestation, namely the ventricular and subventricular zones, initiates the developmental process of the cerebellum [1]. The ventricular zone gives rise to γ-aminobutyric acid (GABA) - ergic neurons which include; the Purkinje and Golgi cells of the molecular layer (ML), the interneurons of the deep nuclei and the basket and stellate cells of the internal granular layer [77-79]. The rhombic lip of the subventricular zone on the other hand gives rise to glutamatergic neurons, of importance the granule cell precursors, which form the EGL of the cerebellar cortex. Active proliferation and differentiation in the outer half of the EGL leads to the formation of mature granule cells. These granule cells migrate inwardly guided by the Bergman glial fibers to form the IGL [80]. The proliferation of the GCP'S is by far the dominant cellular determinant of cerebellar growth. The importance of this proliferative phase to the ultimate growth of the cerebellum is best appreciated when one considers the fact that granule cells make up 95% of the neuronal population of the adult cerebellum. On their way to form the IGL, the granule cells make important contacts with the Purkinje cells, needed to establish the cerebellar circuitry.

The cerebellum thus is engaged in active cellular proliferation and maturation at the period corresponding to very preterm delivery of the newborn and a hypothesized exposure to blood products following IVH may therefore be detrimental to cerebellar development.

Key factors in cerebellar development

Granule cells

Following maturation, they migrate inwardly, guided by the Bergman glial fibers to form the IGL. Granule cells contribute to the structural and functional integrity of the cerebellum. Of importance is the transfer of excitatory signals to the Purkinje cells by granule cells needed to establish the cerebellar circuitry.

Purkinje cells

The Purkinje cell sources the sonic hedgehog protein (Shh), a growth factor responsible for growth and patterning of the cerebellum. By secreting Shh, essential to the proliferation of GCP'S in the EGL, Purkinje cells regulate cerebellar morphogenesis. The axons of the Purkinje cells represent the sole output of the cerebellar cortex to the thalamus and brainstem. The Purkinje cells also receive all inputs into the cerebellum *via* their contact with climbing fibers from inferior olivary nuclei, indirect, *via* granule cells, from mossy fibers, from the nuclei of the spinal cord, brain stem and deep cerebellar nuclei. Most importantly, Purkinje cells are central to the establishment of the cerebellar circuitry.

Extrenal granular layer

The EGL is a transient structure and represents the outermost part of the cerebellar cortex during development. The EGL houses the active proliferation of the GCP'S and subsequent differentiation into mature granule cells, which is a critical event important for the structural integrity of the cerebellum. The intense proliferation of the GCP's is regulated by Shh produced by Purkinje cells. The EGL reaches its full thickness at GW 25 and disappears at 7 months postnatal age in humans.

Bergman glia fibers

These are astrocytes located around the Purkinje cell layer and are involved in guiding the migration of mature granule cells inwardly to form the IGL. They also ensure the critical contacts between the granule and Purkinje cells needed to establish the cerebellar circuitry. They have a repair mechanism involving switching from a differentiated state to a proliferative phase. The differentiation of Bergman glial fibers is regulated by Shh produced by Purkinje cells.

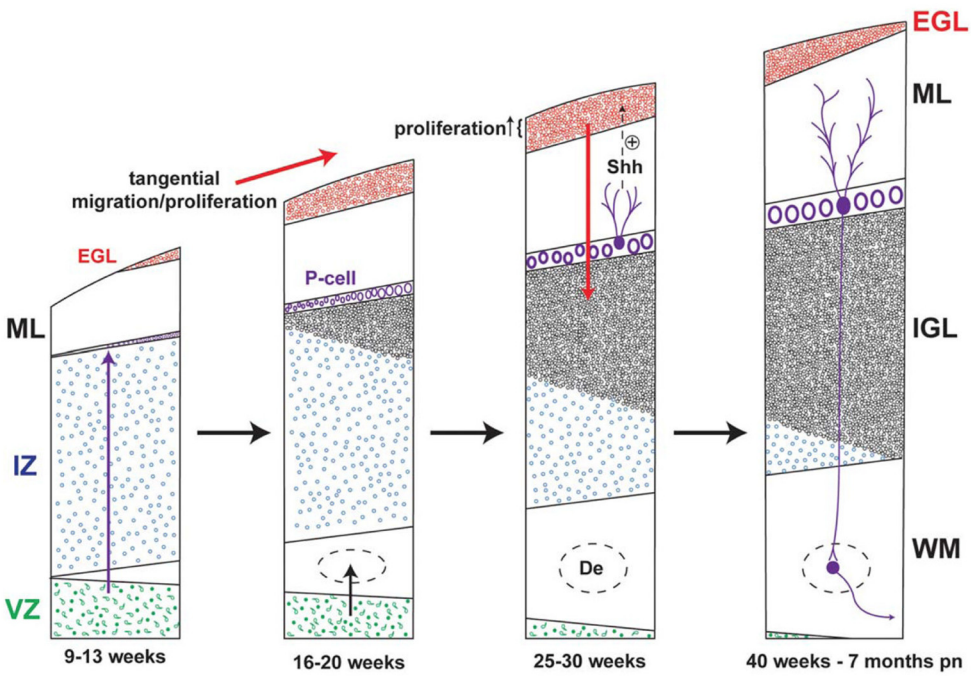

Fig 5. Major events in the perinatal histogenesis of the cerebellum.
The two proliferative zones are the external granular cell layer (EGL) and the ventricular zone. The outer half of the EGL is marked by active cell proliferation of the granular precursor cells under the positive control of sonic hedgehog protein secreted by the Purkinje cells. The mature granule cells migrate downwards to form the internal granular layer. The ventricular zone give rise to Purkinje cells. Note the markedly active proliferation of the granular cell precursors during the premature period. Not shown is equally a marked increase in the size of the molecular layer(ML) around the same period. Adapted from *Volpe, J Child Neurol. 2009 September; 24(9): 1085-1104*

Glial cells in brain development

The study of brain development was previously to a large extent focused on neurogenesis. However, more recent findings have shown that interaction between glia cells and neuronal progenitors is very crucial to neuronal development, especially when neuro- and gliogenesis occurs concurrently and as such any dysfunction in the activity of astrocytes, microglia and oligodendrocytes will be detrimental to neuronal proliferation and maturation process. Contrary to what was traditionally thought, neuroglia plays a far more advanced role in brain physiology and maintenance of cerebral homeostasis with invlovement in synaptic transmission, synaptic pruning, axonal outgrowth, neuro/gliogenesis, immunity, angiogenesis and neural activity [81-85].

Studies experimentally quantifying glial cell numbers in the mammalian brain have shown that, in general, neuroglia makes up at least 50 % of the cellular population in the human brain, with considerable differences in respect to brain regions and to age, supportive of an important role for these cells. For instance, the ratio of glia to neurons in the cerebral cortex is 3.76 and 0.23 in the cerebellum [82, 86, 87].

Accummulated evidence suggests that glia-glia and glia-neuronal crosstalks play an important role in both neurophysiology and neuropathology [48, 88]. Microglial cells were found to be attracted to proliferation zones of Cxcl 12 expressing neural progenitors [89, 90]. Results of an *invitro* study showed a decrease in neuronal proliferation when cortical cultures were depleted of microglia [82]. Additionally, subsets of microglia cells secrete active factors that switch neuro- to astrogenesis [82, 91]. In support of this concept, few astrocytes were found when cortical precursor cells were depleted of microglia. On the other hand, microglia maturation and ramification occurs late in brain development when astrocytes are already present [82]. Thus microglia, astrocytes, and neural progenitors may influence each other's development and behaviour in many ways.

Of note, microglia and astrocytes have been found to potentiate the cytotoxic effects of each other in several neuropathologies. For example, the level of proinflammatory cytokine secretion by astrocytes is increased in the presence of microglia in manganese induced brain toxicity [48].

Taken together, it can be inferred that a possible glia dysfunction caused by the exposure of the immature brain to cytotoxic cell-free Hb and metabolites in an episode of IVH will be harmful to brain development with neurological consequence. In respect to this, paper 3 centered on evaluating the response following an exposure of mixed glia cultures to cell-free Hb metabolites.

Glia cell types

Neuroglia can be classified into different subsets based on function, morphology and location in the central nervous system (CNS). The two main glia subsets in the brain are macroglia and microglia. Macroglia with a neural lineage comprises astrocytes and oligodendrocytes.

Microglia

They are the first glia cells to enter the brain and originate from a yolk sac myeloid progenitor, a macrophagic lineage. They are refered to as the principal immune cells of the brain and respond to pathological triggers. They are also functionally involved in synaptic transmission, angiogenesis, neuro-/gliogenesis, secretion of neuroactive factors and respond to neural activity. Microglia may transition between a spectrum of different functional phenotypes depending on stimuli, with a proinflammatory or

an anti-inflammatory response. Five to 15% of the cellular composition of the human brain is made up of microglia [82, 92].

*Astroc*ytes

Astrocytes are star shaped glia cells with a neural lineage. A wave of astrogenesis starts towards the end of neurogenesis. They make up the major proportion of glial cells in the brain. In the mouse, astrogenesis starts at the embryonic age 18 (E18) and ends at postnatal day 7(P7). Astrocytes are functionally involved in synaptogenesis, synaptic pruning, secretion of gliotransmitters, neuro-/gliogenesis, formation of the brain blood barrier (BBB), neuronal survival and axonal guidance [82, 93-95].

Oligodendrocytes

They are the myelin producing cells of the white matter. They originate from a neural lineage. Oligodendrogeneisis starts in the human foetus by the establishment of oligodendrocyte precursor cells (OPC's) at GW 20. Myelination of neuronal axons forms a protective and insulation layer and helps in the transmission of electrical impulses. The oligodendrocyte lineage transitions from OPC's, preoligodendrocytes (PreOL's), immature oligodendrocyte to mature oligodendrocytes. The premyelinating oligodendrocytes, comprising OPC's and PreOL's, are present at GW 20 to 35, a period corresponding to preterm birth [3, 61, 96, 97]. These premyelinating oligodendrocytes are considered very sensitive to oxidative stress and free radicals [98-101].

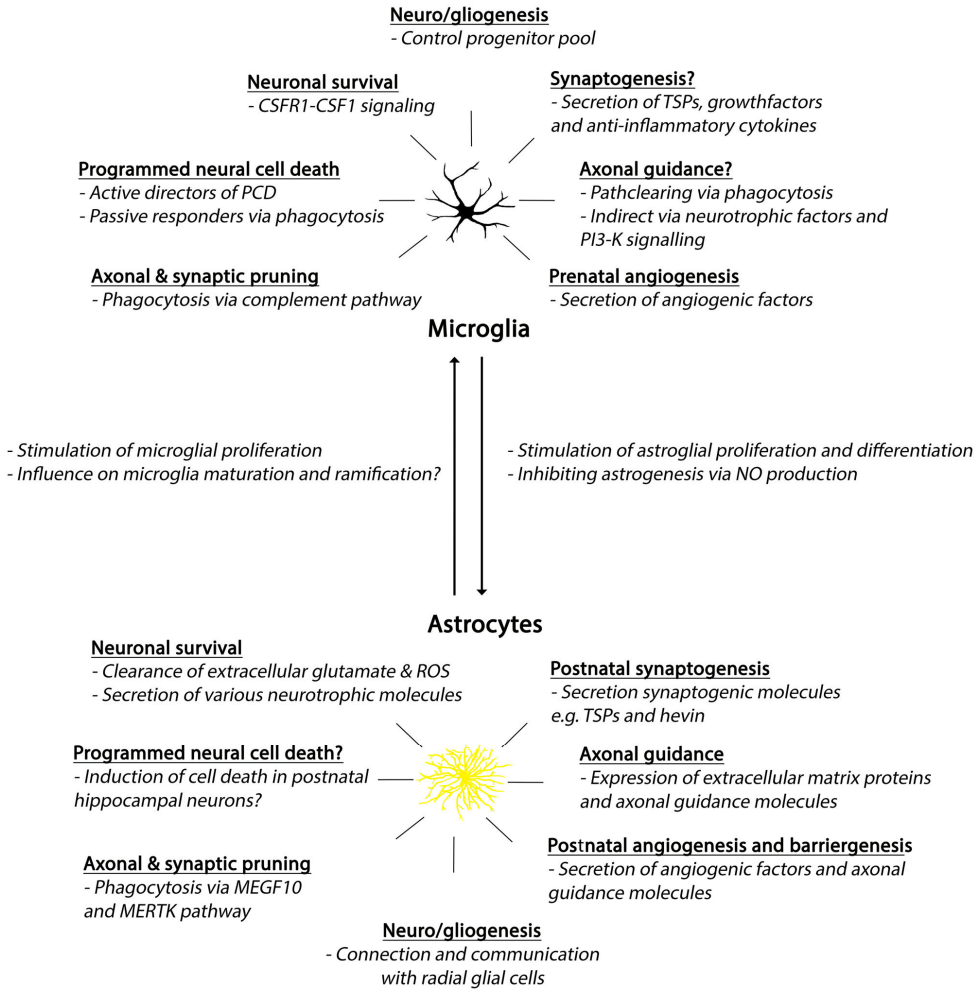

Fig 6. Summary of the roles of microglia and astrocytes in brain development.
Abbreviations: CSFR1, colony stimulating factor 1 receptor; TSPS, thrombospondins; CSF1, colony stimulating factor 1; P13K, Phosphoinositide 3-kinase; MEGF 10, multiple-EGF-like domains; MERTK, MER tyrosine kinase

Hypothesis and aims

The premise for this thesis derives from the fact of the incomplete understanding into the molecular and pathophysiological events leading to the brain injury and neurological consequences following IVH hence making it difficult for the development and implementation of treatment strategies.

The general hypothesis is that the cytotoxicity of blood and importantly hemolysis of extravasated blood and subsequent release of cell-free Hb are central and initially pivotal for the pathophysiological events that eventually leads to irreversible brain damage in IVH.

The overall aim of the thesis involves the development and implementation of novel neuroprotective strategies with the aim of promoting brain development in preterm infants with high risk for neurodevelopmental impairment.

Paper I

Hypothesis

Following hemorrhage, the ventricular ependymal lining is breached and substantial amount of RBC's and released cell-free Hb ie not retained within the RBCs, pass over the barrier and enter into the periventricular parenchymal brain areas.

Aim

To investigate the degree of exposure of the periventricular white matter to cytotoxic cell-free Hb following preterm IVH in a rabbit pup.

Paper II

Hypothesis

Cerebellar deposition of cell-free Hb and metabolites is causal to cerebellar underdevelopment following cerebral IVH and hence scavenging of cell-free Hb may lead to a prevention of the damage

Aim

To evaluate the causality of cerebellar exposure to cell-free Hb in cerebellar damage following IVH, using a preterm rabbit-pup IVH model

To evaluate the therapeutic effect of the intervention with the cell-free Hb scavenger Hp

Paper III

Hypothesis

The production of free radicals (reactive oxygen species) by metHb and its downstream metabolites, but not oxyHb are central to the damaging pathway following preterm IVH.

Aim

To deduce the cell-free Hb metabolite/metabolites responsible for the observed brain damage, in elucidating the pathomechanism of IVH

To deduce the rate limiting/initiation step of the cell-free Hb induced brain damage following cerebral IVH, using invitro cell cultures

Paper IV

Hypothesis

Administration of A1M, a heme and radical scavenger will confer protection of the immature brain following preterm intraventricular hemorrhage

Aim

To evaluate the biodistribution and functional protection of A1M following administration subsequent to cerebral IVH in a preterm rabbit pup.

Methods and materials

Preterm IVH pup model

Paper I, Paper II and Paper IV

The animal protocols were approved by the Swedish Animal Ethics committee in Lund. Throughout the work of this thesis, we have used the well-established preterm rabbit pup model of glycerol-induced IVH in accordance with previous description. The experiments were performed on rabbit pups delivered at gestational day 29 (term 32 days). A half-breed between New Zealand White and Lop was used. The pups were delivered by caesarian section after the does were anesthetized with iv. propofol (5mg/kg) and with local infiltration of the abdominal wall using lidocaine with adrenaline (10mg/ml + 5µl/ml, 20-30ml).

Conditions, handling and protocols

After delivery, the pups were placed and cared for in a closed infant incubator, with humidified air. The conditions, handling and protocols were different for the different studies and were accordingly

Temperature and humidity

Paper I and II: Temperature at 34-35°C with ambient humidity throughout the study.

Paper IV: Temperature at 32°C with ambient humidity throughout the study.

Feeding

Paper I and II: The preterm pups were hand fed with with 2ml (100ml/kg/day) of cat milk formula with first feeding done at approx.1-2h of age using 3.5 French feeding tube, thereafter every 12h, increasing the meal volume by 1ml every 24h.

Paper IV: The feeding was done as in paper I and II with the following changes; The administered amount of milk was increased every 24h by 25ml/kg/day.

IVH induction

Paper I, II and IV: To induce IVH, the preterm rabbit pups at 2-3h of age received an intraperitoneal injection (i.p) of 50% (v/v) sterile glycerol (6.5g/kg; Teknova, Hollister, CA, USA). This causes hyperosmolality and intracerebral hypotension, thus causing rupture of the small veinous vessels in the germinal matrix.

Survival

Paper I: Results from 47 rabbit pups from 13 litters were presented in the study. Overall survival 70%

Paper II: Results from 59 rabbit pups from 9 litters were presented in the study. Overall survival 60 %.

Paper IV: Results from rabbit pups from 18 litters were presented in the study. Overall survival 20%.

Ultrasound imaging of the brain

Paper I

Ultrasound imaging of the brain was initially done at 6h to detect and grade IVH and subsequently at 24, 48 and 72h of age using the Visualsonic Vevo 2100 (Visualsonics Inc, ON, Canada) with a MS-550D 40 MHz transducer. Pups with IVH at 6h of age were included in the IVH group and those without a detectable IVH at all timepoints were assigned to the IVH group

Paper II

Ultrasound imaging of the brain was initially done at 6h to detect and grade IVH band subsequently at 24, 48 and 72h of age using the Visualsonic Vevo 2100 (Visualsonics Inc, ON, Canada) with a MS-550D 40 MHz transducer. Pups with IVH at 6h of age were included in the IVH group and those without a detectable IVH at all timepoints were assigned to the IVH group.

Subarachnoid hemorrhage (SAH) was confirmed in all pups with IVH with the visible presence of hemorrhagic CSF covering the cerebellar cortex following removal of the brain from the skull. None of the control pups exihibited macroscopic signs of SAH. No pup in both the control or IVH group exihibited signs of primary cerebellar hemorrhage.

Paper IV

Ultrasound imaging of the brain was initially done at 6h to detect and grade IVH and subsequently at 18, 24, 48 and 72h of age using the Visualsonic Vevo 2100 (Visualsonics Inc, ON, Canada) with a MS-550D 40 MHz transducer. Pups with

IVH at 6h of age were included in the IVH group and those without a detectable IVH at all timepoints were assigned to the IVH group

Intraventricular injections

Paper II

Pups with IVH were randomized into one of three groups of IVH only, IVH + Hp or IVH + Vehicle. At 8h of age, pups in IVH + Hp and IVH + Vehicle received an ultrasound-guided intraventricular injection of either 20µl of human Hp (50mg/ml, Bio Products Laboratory, London, UK) or 20µl of vehicle solution (9mg/ml NaCl, Fresenius Kabi, Lake Zurich, IL, USA), using 27 G Hamilton syringes (Hamilton Robotics, Reno, NV, USA).

Paper IV

In paper IV intraventricular injections were performed according to one of the following:

Following ultrasound at 18h age, pups were randomized into one of two groups of IVH + recombinant A1M (rA1M) and IVH + Vehicle. At 22h of age, pups in IVH + rA1M and IVH + Vehicle received an ultrasound-guided intracerebroventricular (i.c.v) injection of either 25µl of human recombinant A1M (rA1M, 9.4 mg/ml, A1M Pharma AB, Lund, Sweden) or 25µl of vehicle solution (10mM Tris-HCl pH 8.0, 0.125M NaCl, A1M Pharma AB, Lund, Sweden) using 27 G Hamilton syringes (Hamilton Robotics, Reno, NV, USA).

Pups with IVH were randomized into one of two groups of IVH + human (h)A1M or IVH+Vehicle. At 8h of age, pups in IVH + hA1M and IVH+Vehicle received an ultrasound-guided intraventricular injection of either 25µl of hA1M (9mg/ml) prepared from healthy human donors or 25µl of sterile artificial CSF solution, using 27 G Hamilton syringes (Hamilton Robotics, Reno, NV, USA).

Brain tissue sampling and processing

Paper I

For histochemistry, immunolabeling and scanning electron microscopy (SEM), euthanization of rabbit pups was done at 72h of age by isoflurane anesthesia followed by saline and freshly prepared 4% paraformaldehyde (PFA) perfusion. Subsequently, brains were dissected out from the skulls and were immersed in 4% PFA. Change to fresh PFA was done after 3-6h. Brains were then cryoprotected by sequential immersion in 15% sucrose for 6h and in 25% sucrose for another 6h. Brains were mounted in TissueTec (Sakura Finetek, Torrance, CA, USA) and frozen

(at around -60°C) in cryomolds, on dry ice in isopentane. Sections (12µm) were cut on a cryotome (Microm, HM 500 OM, Microm Laborgeraete GmbH, Walldorf, Germany). Sections were collected on superfrost plus slides, two per slide, starting from the end of the olfactory bulb to the end of the midbrain. Sections were stored at -20°C until used for the labeling.

Paper II

Perfusion-fixation of the brain was performed by cardiac cannulation after thoracotomy and infusion of 0.9% saline. Followed by perfusion with 4% PFA (buffered with phosphate buffer saline (PBS) 0.1M, pH 7.4). Subsequently, the cerebellum and cerebrum were carefully extracted from the skulls and immersed in 4%PFA.Change to fresh PFA was done after 3-6h.

Brains were thereafter fixated in 4% PFA for 48h. Afterwards, they were dehydrated, cleared and infiltrated with paraffin automatically in a Tissue-TEK V.I.P (Miles Scientific Corp., Newark, NJ, USA) and embedded in paraffin blocks. The cerebellum was sectioned, and 4µm sections in the parasagittal plane at the level of the dentate nucleus were made (Leica, RM2255 Microtome) and mounted on microscope slides and dried at 37°C for 12-16h

Paper IV

Euthanization of rabbit pups was done following sedation with i.p. ketamine administration (35mg/kg) and isoflurane anesthesia followed by saline (PBS, pH 7.4, containing 0.01% of heparin) and freshly prepared 4% PFA perfusion. Subsequently, brains were dissected out from the skulls and were immersed in 4% PFA. A change to fresh PFA was done after 6-8h and brains were then immeresed in PFA, at 4°C. Brains were then cryoprotected by sequential immersion in 10% sucrose and in 20% sucrose for a total of 16h. Brains were mounted in TissueTec (OCT, Sakura, Japan) and frozen (at around -60°C) in cryomolds, on dry ice in isopentane. Sections (12µm) were cut on a cryotome (Microm, HM 500 OM, Microm Laborgeraete GmbH, Walldorf, Germany). Sections were collected on superfrost plus slides, two per slide, starting from the end of the olfactory bulb to the end of the midbrain. Sections were stored at -20°C until used for the labeling.

In vitro cell culture study

Cell culture

Paper III

The use of animals was approved by the Swedish Animal Ethics Committee in Lund. Primary mixed glial cell cultures comprising microglia, astrocytes and oligodendrocytes were prepared from postnatal day 1 (P1) Sprague Dawley rats (Janvier, Le Genest-Saint isle, France). Briefly, cerebral hemispheres were dissected in ice-cold Hank's balanced salt solution (HBSS, Thermo fisher, Waltham, MA, USA) in order to carefully remove the cerebellum, eyes and meninges. The cerebrum was then cut in two cortices to remove all seen vessels. The cerebrum was subsequently minced, vessels removed and the cell mass transferred to a 15 mL tube containing HBSS (8 mL) and centrifuged at 300 xg. for 5 min at room temperature (RT). The supernatant was removed and 8 mL of pre-heated complete culture medium (Dulbecco's modified eagle medium, DMEM with glutamine, 4.5g L-glucose + 10% fetal bovine serum (FBS), 1% penicillin and streptomycin, Thermo fisher, Waltham, MA, USA) was added. Using a fire polished glass pipette, a homogenous cell suspension was obtained by pipetting up and down repeatedly. The cell suspension was then directly filtrated through a 40 µM mesh and resuspended in pre-heated complete culture medium. Cells were then seeded in a poly-D-lysine (PDL, Sigma Aldrich, Summit drive Burlington, MA, USA) coated multi-well plates flasks or on cover slips (for immunocytochemistry, ICC).

Preparation of oxyHb, oxidized Hb and heme

Paper III

Human oxyHb was purified as previously described from human blood of healthy subjects. The use of human blood was approved by the ethical committee review board for studies in human subjects at Lund University. Oxidized Hb (containing a mixture of Hb-metabolites with mainly $Fe^{3+}$and some proportion of Fe^{4+}, free heme and iron) was prepared by incubating the purified oxyHb solution at 37°C for 72 h (as described by Gram et al. The proportion of oxyHb to metHb (Fe^{3+}-Hb) was determined as described previously. Heme (Ferriprotoporphyrin IX chloride) was purchased from Porphyrin Products Inc. (Logan, UT, USA), and a 10 mM stock solution was prepared using dimethyl sulfoxide (DMSO; Sigma-Aldrich, St. Louis, MO, USA). All Hb solutions were purified from endotoxin contamination using the endotoxin-removing product EndoTrap (Hyglos GmbH, Bernried am Starnberger See, Germany) as described by the manufacturer.

Experimental design

Paper III

Mixed glial cells were grown in culture medium containing 10% of FBS until day 5-7, at what point all experiments were performed. Complete medium were removed and cells were incubated at 37°C with any of the following component i) CSF from human preterm IVH patients (containing a mixture of Hb-metabolites), ii) oxyHb, iii) oxidized Hb or iv) heme, all substituted in fresh serum-free culture medium immediately before addition, for at most 24h. In addition, co-administration of the previously described compounds with human Hp (a mixture of isotype 2-2/2-1, CSL Behring, Kankakee, IL, USA) was performed.

After incubation, cell culture medium was collected (for ELISA analysis) and cells analyzed (for ROS production) or harvest (for RNA extraction and mRNA expression analysis) as described below.

Analysis

Periventricular brain tissue

Selection of brain anatomical regions

Paper I

To define the brain neuroanatomy, thereby enabling selection of corresponding levels from all animals to be used for histochemical and immunolabeling analysis, every 10-15th section was stained with Hematoxylin-Eosin (HE). The HE staining procedure is described in details in Paper I

Paper IV

Findings of the HE staining performed in Paper I, defining the corresponding neuroanatomical regions and levels preferable for analysis was adapted also in paper IV

Peroxidase Histochemistry

Paper I and Paper IV

To detect peroxidase (PO) activity due to Hb, thereby defining the distribution of cell-free Hb within the brains of all animal groups (control, IVH), we performed an adapted protocol of the enhanced peroxidase reaction of cryosections [102]. About every 10th section was stained for PO, in parallel sections to HE and

immunolabelled sections containing the selected regions of interest at the corresponding levels. Details of procedure is described in paper I.

Immunolabelling of Hb and rA1M

Paper I and IV

To specifically detect Hb for comparison with PO, we performed single immunofluorescence (IF) labeling of Hb, of selected ROIs. Double IF labeling with polysialic acid neural cell adhesion molecule (PSA-NCAM), a marker of developing and migrating neurons and of synaptogenesis was performed to further elucidate the distribution of Hb in differentiation zones and regions of plasticity following IVH. This was performed as described in paper I and IV.

Paper IV

Immunohistochemistry labeling (IHC) of rA1M was performed to investigate whether following i.c.v administration, rA1M could be detected and thereby be used for comparisons between experimental groups with correlation made to the PO activity. Cryosections from IVH+rA1M group adjacent to those used for the

peroxidase staining were labeled for rAIM by means of IHC. IHC of rA1M was performed as described in Paper IV.

To determine the specificity of rA1M labeling, rA1M-IF labeling was performed, in adjacent sections as used for A1M IHC. Thereafter, sections were double IF labeled with PSA-NCAM. The immunofluorescence labeling was performed as described in paper IV.

Electron microscopy (EM)

Paper I

SEM at high magnification was adopted to investigate the presence of intact RBCs within the tissue. This was carried out on cryosections from IVH and sham control brains containing the selected ROIs according to procedure described in paper I.

Transmission EM (TEM) and TEM-IHC were performed to investigate the effect of IVH on the structural integrity of the mitochondria, concurrently elucidating the effect of IVH on tumor necrosis factor alpha (TNFα) protein secretion. Similar investigations were made in IVH + hA1M to evaluate the functional protective role of A1M in IVH. All performed as described in paper I.

Cerebellum

Immunohistochemical staining for cerebellar development

Paper II

Following the removal of paraffin, cerebellar sections were incubated with antibodies towards antigens of calbindin, Ki67, Iba 1, Hb and Hp, details according to the description in paper I and II.

Histological Analysis

Paper II

Following IVH, measurement of the proliferative width of the EGL as determined by Ki67-positive cells, was performed in four predefined regions. These regions were the inner and outer portions of lobule V and the inner and outer portions of lobule IX. These regions were chosen because they are representative of regions with possible maturational differences in EGL proliferation and subsequent width. All measurements of the proliferative EGL were performed with a bright-field microscope (Leica DMRX), using a 40x dry objective lens. The average width of the four respective regions was calculated for each pup.

Using the Leica Q500 image analysis system of the microscope, the areas of Iba 1 (a marker of reactive microgliosis) and calbindin (a marker of Purkinje cell maturation) positive stained cells were respectively determined in relation to the cerebellar white matter area and the area of the molecular layer. Thus both positive Iba 1 and calbindin staining were expressed as a percentage respectively, of standardized area of cerebellar white matter and of molecular layer.

The measurements were done for all the different groups namely; control, IVH only, IVH + Hp, IVH + Vehicle

Immunofluorescent labeling for Hb and Hp

Paper II

Double IF labeling of Hb and Hp was done to simultaneously investigate the presence and distribution of both encapsulated RBCs and cell-free Hb within the cerebellum following supratentorial IVH in preterm rabbit pups and whether subsequent to inventricular injection, Hp could reach the cerebellar brain regions. This was performed as described in paper II

Mixed glia

Immunocytochemistry

Paper III

Immunolabeling of mixed glia cells comprising astrocytes, microglia and oligodendrocytes was performed to evaluate the changes in structural morphology, reactivity and activity of the glia cell types following exposure to hemorrhagic CSF from preterm IVH infants and pure Hb metabolites, with and without Hp. Iba-1 was used as a marker of reactive microglia and phalloidin/F-actin, a marker of the cytoskeletal structure of the glia cells. The ICC protocol was carried out according to material and methods in paper III.

Measurement of intracellular ROS formation

Paper III

ROS production following exposure of mixed glia to the different experimental conditions was investigated.

ROS were detected by measuring the fluorescence of 2,7-dichlorofluorescein (DCF, Abcam, Cambridge, UK). At the end of the exposure period, cells were incubated with 25 μM DCFH2-DA for 45 min at 37°C in the dark. Fluorescence was measured with excitation at 483 nm and emission at 535 nm using a fluorescence microplate reader (Victor multilable plate reader, Pelkin Elmer, Waltham, Massachusetts, USA).

ELISA

Paper III

Proinflammatory cytokine secretion by mixed glia cells following exposure to the experimental conditions was evaluated. Procedure as follows;

The concentration of chemokine ligand 2 (CCL2), chemokine ligand 5 (CCL5), neutrophil gelatinase associated lipocalin (NGAL) and interleukin-12 (IL12), secreted into the cell culture medium of mixed glial cells following exposure to the respective experimental conditions was determined using the Quantikine (CCL2, CCL5) and DuoSet (NGAL) ELISA Development Kits (R&D Systems, Minneapolis, Minnesota, USA) and IL12 ELISA Kit (Invitrogen, Vienna, Austria). The analysis was performed according to the instructions from the manufacturer.

Hp-Hb binding studies

Paper III

To ascertain whether the cell-free Hb metabolites in the cell culture experiment bind to the added Hp, a cell free Hb scavenger, binding affinity studies were carried out.

Human plasma derived Hp was immobilized on the surface of a biosensor as a stationary phase and tested for A. OxyHb (Fe^{2+})-binding and B. MetHb (Fe^{3+})-binding by biolayer interferometry (BLI).

RNA Isolation and Real-Time PCR

Paper II

Total RNA was extracted from the cerebellar tissue of rabbit pups in the different experimental groups using the Nucleospin RNA /protein extraction kit. Reverse transcription was carried out in accordance to the manufacturer's instructions on 1µg total RNA using iScript cDNA synthesis kit (Bio-Rad, Hercules, CA, USA) and the RT^2 qPCR primer assay (primer from QIAGEN, Germantown, MD, USA) was used to quantify mRNA expression of heme oxygenase 1(HO-1) and expression was analysed using iTaq universal SYBR Green Supermix (Bio-Rad). Amplification was performed inaccordance to manufacturer's description for 40 cycles in an iCycler Thermal Cycler (Bio-rad), data analyzed using iCycler iQ Optical System Software (Bio-Rad). Data were normalized to glyceraldehyde-3-phosphate dehydrogenase (GAPDH, primer from QIAGEN), with fold change values calculated by normalizing against control animals.

Paper III

The same procedure was used as in Paper II above but with the following exceptions.

RNA samples were extracted from mixed glia cultures using RNeasy Mini kit supplied by QIAGEN (Alden, Germany). Primers (Primer PCR assay from Biorad) for the following genes were analyzed; inducible nitric oxide synthase (INOS), heme HO-1, TNFα, superoxide dismutase (SOD2), Arginase 1, catalase, insulin growth factor 1(IGF1)

NFK-B (PARN-0252D, Qiagen, Maryland, USA) and apoptotic (PARN-0122D, Qiagen, Maryland, USA) array were performed on all experimental conditions by using 1 µg of pooled RNA as template for reverse transcriptase reactions using the RT^2 First Strand Kit (Qiagen, Maryland, USA). cDNA was mixed with RT^2 SYBR Green qPCR Master mix (Qiagen, Maryland USA). Amplification was performed as described by the manufacturer (Bio-Rad) for 40 cycles in an iCycler Thermal Cycler (Bio-Rad), and data were analyzed using iCycler iQ Optical System Software (Bio-Rad). Normalization and determination of fold change expression for the panel of genes was done on the Qiagen Data analysis center platform.

Paper IV

The same procedure as described in paper II (above), was used with the following exceptions.

RNA samples were extracted from periventricular tissue using the acid guanidinium phenol chloroform method and RNeasy Mini kit supplied by QIAGEN. Reverse transcription was carried out in accordance to the manufacturer's instructions on 0.1-1µg total RNA using iScript cDNA synthesis kit (Bio-Rad, Hercules, CA, USA) and the RT^2 First strand kit (QIAGEN). RT^2PCR Profiler Array real-time PCR (custom made by QIAGEN) were used to quantify the mRNA expression of toll like receptor (TLR) 4,monocyte chemoatractant protein (MCP)-1. Interleukin (IL)-1β, IL6, IL8, IL1 receptor(R) 1, TNFα, matrix metalloprotease (MMP) 9, HO-1

Statistics

Paper II and III

Results were presented as median (ranges) and displayed as box plots. Statistical comparisons made between unrelated groups were performed with the Mann-Whitney U test as appropriate. Comparisons between multiple groups were made using the Kruskal-Wallis test followed by pairwise comparisons. *P*-values <0.05 were considered significant.

Paper IV

Comparisons between multiple groups were analyzed using ANOVA with *post hoc* Bonferroni. *P*-values <0.05 were considered significant.

Results and comments

Paper I

Cell-free Hb is extensively distributed through the periventricular parenchyma following IVH in the preterm rabbit pup.

Hypothetical statement

It was posed that consequent to IVH, the ventricular ependymal epithelium lining is breached causing substantial amounts of RBCs and released cell-free Hb, *ie* not retained within the RBC, to pass over the barrier, thereby entering in to the periventricular parenchymal brain regions.

Findings and discussion

Consistent with the hypothesis, findings of the study in the paper I revealed that following IVH in the preterm rabbit pup, there were disruptions in the ventricular ependymal lining integrity. Staining with HE showed extended hemorrhage typified by intact RBCs in all the evaluated neuroanatomical ROIs; in the rostral forebrain, the caudal forebrain, rostral midbrain, and caudal midbrain. The presence of the intact RBCs were more pronounced in the occipital parts *ie* the rostral midbrain and caudal midbrain. The presence of intact RBCs was prominent in the distended choroid plexus and the subfornical organ. It was also found in the thalamus, hippocampus, ventricles and subventricular zones. Congrously, PO staining and immunolabeling of Hb showed the presence of cell-free Hb in all the evaluated brain regions containing intact RBC'S. Thus cell-free Hb was found extensively in the periventricular white matter in regions of high plasticity.

The extended presence of cell-free Hb in the periventricular white matter supports that cell-free Hb may contribute to pathophysiological events that cause irreversible damage to the immature brain following IVH.

Paper II

Supratentorial IVH in the preterm rabbit pup leads to cerebellar deposition of cell-free Hb

Hypothetical statement

We posed that cerebral IVH leads to a cerebellar deposition of cell-free Hb and that this may be associated with the impaired cerebellar development observed consequent to IVH

Findings and discussion

The findings of this study suggest that contrary to maturational diaschisis, a direct deposition of cell-free Hb into the cerebellum subsequent to IVH may be central in causation of cerebellar underdevelopment.

Immunofluorescent labeling revealed the presence of cell-free Hb in the cerebellar cortex and white matter. The cortical presence of cell-free Hb was associated with both a decrease in the proliferative activity of the EGL and also impaired Purkinje cell maturation. The presence of the cell-free Hb in the cerebellar white matter was associated with reactive microgliosis

Following intraventricular injection of Hp, a cell-free Hb scavenger, Hp was detected widely distributed throughout the cerebellum. Double immunofluorescence showed the coexistence of Hp and Hb in the molecular layer and the white matter. Congruent to this, Hp administration restored the arrested proliferative activity in the outer portion of the EGL and partially reversed the impaired Purkinje cell development.

This confirmed the causal involvement of cell-free Hb in the cerebellar injury consequent to IVH in the preterm rabbit pup

Paper III

Oxidized Hb and not oxyHb (Fe^{2+}) is central to the damaging pathway following preterm IVH

Hypothetical statement

We posed that the production of free radicals (reactive oxygen species) by metHb and its downstream metabolites, but not oxyHb, are central to the damaging pathway following preterm IVH.

Findings and discussion

Although paper II confirmed the causal involvement of cell-free Hb in the brain injury following IVH, there was a limitation in delineating the cell-free Hb metabolite/metabolites responsible for the damage. This constituted the aim of the study in paper III

Immunocytochemistry, RTPCR, ELISA showed that met/oxidized Hb and not oxyHb (Fe^{2+}) induces a similar damaging response (morphological changes, proinflammatory response) on mixed glia cells as the hemorrhagic CSF obtained from preterm IVH infants.

Results from DCFDA assay showed free radicals (ROS) production caused by exposure to oxidized Hb to be central to the induced damage.

Co-administration with Hp had no protective effect on the met/oxidized Hb induced damaging response. This was found not to be due to an inability of the Hp to bind to metHb since Hp-Hb binding studies revealed a strong binding between Hp and metHb similar to that of Hp and oxyHb (Fe^{2+})

Taken together, the observed protective effects of Hp against cell-free Hb induced cerebellar injury in the preterm IVH rabbit pup in paper II together with the findings of paper III, suggest that the spontaneous auto-oxidation of oxyHb (Fe^{2+}) to metHb (Fe^{3+}) is the initiation step of the cell-free Hb-induced brain damage following cerebral IVH

The protective mechanism of Hp against brain damage following IVH may involve preventing the spontaneous auto-oxidation of oxyHb (Fe^{2+}) to metHb (Fe^{3+}). This is consistent with literature since Hp is known to slow the rate of spontaneous auto-oxidation of cell-free Hb dimers.

Paper IV

The heme and radical scavenger rA1M confers protection of the immature brain following preterm IVH

Hypothetical statement

We speculated that the administration of A1M, a heme and radical scavenger will confer protection of the immature brain following preterm intraventricular hemorrhage.

Findings and discussion

Consistent with findings in paper I, PO activity following IVH was found to be present in all evaluated neuroanatomical regions namely; the rostral forebrain, the caudal forebrain, rostral midbrain and the caudal midbrain. In correlation with the results of PO activity, findings from IF labeling of Hb confirmed the presence of cell-free Hb in the periventricular white matter and fiber tracts.

IHC staining for rA1M revealed an extensive distribution of the i.c.v administered A1M within the brain and cerebellum in all IVH animals.

Double IF labeling for A1M and Hb showed a coexistence and even co-localization at the cellular level within periventricular white matter, fiber tracts, thalamic region, corpus callosum, corona radiata and hippocampus. Double labeling of A1M and PSA-NCAM showed a prominent coexistence in areas of high plasticity.

Congrously, i.c.v administered rA1M as revealed by EM and RT-PCR analysis was found to reduce IVH-induced structural damage, mitochondrial hypertrophy, up-regulation of proinflammatory markers, cellular response, oxidative stress and matrix degradation proteins.

These results indicate rA1M as a potential candidate for neuroprotective treatment against brain damage following preterm IVH

Conclusion and future perspectives

The main question of this thesis was if the cytotoxicity of blood and cell-free Hb are causally involved in initiating the pathophysiological events central to the secondary brain damage observed in IVH?

The findings of this thesis indeed confirm that the cytotoxicity of cell-free Hb is central to the pathophysiological events that eventually lead to the irreversible brain damage following preterm IVH.

Thus in addition to a probable mechanical damage which may result from the mass effect of the hematoma on the brain, exposure of the brain parenchyma to cytotoxic cell-free Hb following IVH appears to be a pivotal event in the pathophysiology leading to irreversible brain impairment.

Of note, findings of this thesis show that Hp, a cell-free Hb scavenger and A1M, a heme and free radical scavenger, present as candidates for neuroprotective treatment strategies against IVH-induced brain damage

The timeline between the conversion from oxyHb (Fe^{2+}) to metHb (Fe^{3+}), for the best-case scenario may provide an important therapeutic window for implementation of neuroprotective interventions targeting cell-free Hb.

Hence a kinetic study following IVH on the rate of the spontaneous auto-oxidation of oxyHb (Fe^{2+}) to metHb (Fe^{3+}) for deducing the timelines present *in vivo* presents a good case for future investigations.

Also confirmation of some aspects of the findings of this thesis on brain tissues from postmortem human subjects if available will be important for future investigations.

An important study will be to evaluate the possible causal involvement of cell-free hemoglobin metabolites and free radicals in the denaturation of important neurogenic growth factor proteins in the CSF of the ventricular lumen.

The volume of work done has provided important insight into the pathomechanisms of IVH-induced brain damage. These findings may prove vital in the development of novel neuroprotective treatment strategies against brain damage consequent to preterm IVH.

Acknowledgement

Professor David Ley

First and foremost, thank you for being a great human being. You are very intelligent but also patient and humble. You do what you do with great panache. These qualities make you a great supervisor. Thank you for the high-leveled scientific discussions we always have, especially the one we had on paper 2. Have learnt a lot from you these past years. Importantly, thank you for the role you played in the structural organization for my PhD defence. Very appreciative for the compliments too. They have equally helped in building my confidence as a scientist. Thank you, Prof and thanks to your wife for taking care of my daughter after her birth.

Magnus Gram

First, thank you for the role you played in my recruitment to this wonderful research team. Magnus, like David you are very intelligent and talented. Thank you for the great scientific discussions we have had these past years. Have learnt a lot from you including the silent way of communicating to me that figures have to be in the best possible shape before submitting to a journal. Thank you for the compliments, suggestions and corrections too. You and David have contributed significantly to my growth as a scientist. You have been a great co-supervisor

Research team

Thank you very much **Suvi** for your laboratory expertise and the technical details about laboratory work that I learnt from you not forgetting the different trainings. **Matteo**, thank you for the paper we did together but most especially thank you for being a friend and a great person. I am equally grateful **Olga** for the friendship and for the A1M paper we did together. Likewise to you Krisbjörg**. Claes**, even though by the time you joined the group I had finished with all the laboratory experimentations, you have been helpful in many significant ways. Thank you for the very insightful meetings you put together and also for the article you sent on rabbit's neuroanatomy. But most especially thank you for being such a great friend. Thanks Niklas and Lennart for the friendship. To Åsa Jungner, for the love you shown to me and my familyTo **Bo Holmquist**, for the great collaboration not forgetting the scientific discussions we have had anytime I came to medicon village. You are a wonderful person, Bo.

Erasmus mundus fetal and perinatal medicine PhD

A special thanks to Erasmus mundus fetal and perinatal medicine PhD program for the funding of my PhD studies

Family

A special "thank you" to my lovely wife, **Alberta Agyemang** for the support and selfless sacrifice. To my daughter, **Charis Agyemang**. "I love you to bits" To my mother and brother, not forgetting my cousin **Christiana Agyemang** for the support and prayers. A special mention must be made of my mother and father in- law for the love, your prayers and godly advice. To the rest of the family, I say love you and God bless you

Christ in you and through you ministry

To all the brethren at light embassy, with a special mention to Benedict Oppong Asamoah for all the love, prayers, wonderful fellowship and unflinching support in trying times

Ghanaian community in Lund

To all my brothers at vildanden not forgetting your wives for the love, fellowship and friendshipI want to specially thank **Maa Christy** for being like a mother to me in my stay here in Lund. For the great love you have shown to me and my family.

Finally, I want to most importantly thank God in the name of the Lord Jesus Christ for the wisdom and guidance through my PhD studies. You are everything to me.

References

1. Volpe JJ. Cerebellum of the premature infant: rapidly developing, vulnerable, clinically important. Journal of child neurology. 2009;24(9):1085-104.
2. Lee YA. White Matter Injury of Prematurity: Its Mechanisms and Clinical Features. J Pathol Transl Med. 2017;51(5):449-55.
3. Back SA. Brain Injury in the Preterm Infant: New Horizons for Pathogenesis and Prevention. Pediatr Neurol. 2015;53(3):185-92.
4. Douglas-Escobar M, Weiss MD. Biomarkers of brain injury in the premature infant. Front Neurol. 2012;3:185.
5. Serenius F, Ewald U, Farooqi A, Fellman V, Hafstrom M, Hellgren K, et al. Neurodevelopmental Outcomes Among Extremely Preterm Infants 6.5 Years After Active Perinatal Care in Sweden. JAMA Pediatr. 2016;170(10):954-63.
6. Farooqi A, Hagglof B, Sedin G, Serenius F. Impact at age 11 years of major neonatal morbidities in children born extremely preterm. Pediatrics. 2011;127(5):e1247-57.
7. Chen J, Smith LE. Retinopathy of prematurity. Angiogenesis. 2007;10(2):133-40.
8. Shulhan J, Dicken B, Hartling L, Larsen BM. Current Knowledge of Necrotizing Enterocolitis in Preterm Infants and the Impact of Different Types of Enteral Nutrition Products. Adv Nutr. 2017;8(1):80-91.
9. Davidson LM, Berkelhamer SK. Bronchopulmonary Dysplasia: Chronic Lung Disease of Infancy and Long-Term Pulmonary Outcomes. J Clin Med. 2017;6(1).
10. Georgiadis P, Xu H, Chua C, Hu F, Collins L, Huynh C, et al. Characterization of acute brain injuries and neurobehavioral profiles in a rabbit model of germinal matrix hemorrhage. Stroke; a journal of cerebral circulation. 2008;39(12):3378-88.
11. Chua CO, Chahboune H, Braun A, Dummula K, Chua CE, Yu J, et al. Consequences of intraventricular hemorrhage in a rabbit pup model. Stroke; a journal of cerebral circulation. 2009;40(10):3369-77.
12. Ballabh P. Intraventricular hemorrhage in premature infants: mechanism of disease. Pediatric research. 2010;67(1):1-8.
13. Ballabh P. Pathogenesis and prevention of intraventricular hemorrhage. Clinics in perinatology. 2014;41(1):47-67.
14. Garton TP, He Y, Garton HJL, Keep RF, Xi G, Strahle JM. Hemoglobin-induced neuronal degeneration in the hippocampus after neonatal intraventricular hemorrhage. Brain Research. 2016;1635:86-94.
15. Whitelaw A. Periventricular hemorrhage: a problem still today. Early Hum Dev. 2012;88(12):965-9.

16. Sveinsdottir S, Cinthio M, Ley D. High-frequency ultrasound in the evaluation of cerebral intraventricular haemorrhage in preterm rabbit pups. Ultrasound in medicine & biology. 2012;38(3):423-31.
17. Tortora D, Severino M, Malova M, Parodi A, Morana G, Sedlacik J, et al. Differences in subependymal vein anatomy may predispose preterm infants to GMH-IVH. Arch Dis Child Fetal Neonatal Ed. 2018;103(1):F59-F65.
18. Folkerth RD. Germinal matrix haemorrhage: destroying the brain's building blocks. Brain. 2011;134(Pt 5):1261-3.
19. Szpecht D, Szymankiewicz M, Nowak I, Gadzinowski J. Intraventricular hemorrhage in neonates born before 32 weeks of gestation-retrospective analysis of risk factors. Childs Nerv Syst. 2016;32(8):1399-404.
20. Kadri H, Mawla AA, Kazah J. The incidence, timing, and predisposing factors of germinal matrix and intraventricular hemorrhage (GMH/IVH) in preterm neonates. Childs Nerv Syst. 2006;22(9):1086-90.
21. Ecury-Goossen GM, Dudink J, Lequin M, Feijen-Roon M, Horsch S, Govaert P. The clinical presentation of preterm cerebellar haemorrhage. Eur J Pediatr. 2010;169(10):1249-53.
22. Nahar N, Begum T, Baki A, Ahmed T. Clinical Presentation of Preterm Neonates with Intraventricular Hemorrhage: Experience in a Tertiary Care Hospital in Dhaka. BIRDEM Medical Journal. 2017;7(3):194-7.
23. Volpe JJ. Impaired Neurodevelopmental Outcome After Mild Germinal Matrix-Intraventricular Hemorrhage. Pediatrics. 2015;136(6):1185-7.
24. Robinson S. Neonatal posthemorrhagic hydrocephalus from prematurity: pathophysiology and current treatment concepts. J Neurosurg Pediatr. 2012;9(3):242-58.
25. Bu Y, Chen M, Gao T, Wang X, Li X, Gao F. Mechanisms of hydrocephalus after intraventricular haemorrhage in adults. Stroke Vasc Neurol. 2016;1(1):23-7.
26. Strahle J, Garton HJ, Maher CO, Muraszko KM, Keep RF, Xi G. Mechanisms of hydrocephalus after neonatal and adult intraventricular hemorrhage. Transl Stroke Res. 2012;3(Suppl 1):25-38.
27. Khaket TP, Ahmad R. Biochemical studies on hemoglobin modified with reactive oxygen species (ROS). Applied biochemistry and biotechnology. 2011;164(8):1422-30.
28. Quaye IK. Extracellular hemoglobin: the case of a friend turned foe. Frontiers in physiology. 2015;6:96.
29. Kumar S, Bandyopadhyay U. Free heme toxicity and its detoxification systems in human. Toxicology letters. 2005;157(3):175-88.
30. Bakhubaira S. Hematological Parameters in Severe Complicated Plasmodium falciparum Malaria among Adults in Aden. Turk J Haematol. 2013;30(4):394-9.
31. Akinsheye I, Alsultan A, Solovieff N, Ngo D, Baldwin CT, Sebastiani P, et al. Fetal hemoglobin in sickle cell anemia. Blood. 2011;118(1):19-27.

32. Lee SJ, Stepniewska K, Anstey N, Ashley E, Barnes K, Binh TQ, et al. The relationship between the haemoglobin concentration and the haematocrit in Plasmodium falciparum malaria. Malar J. 2008;7:149.

33. Ferreira A, Balla J, Jeney V, Balla G, Soares MP. A central role for free heme in the pathogenesis of severe malaria: the missing link? J Mol Med (Berl). 2008;86(10):1097-111.

34. Duan X, Wen Z, Shen H, Shen M, Chen G. Intracerebral Hemorrhage, Oxidative Stress, and Antioxidant Therapy. Oxid Med Cell Longev. 2016;2016:1203285.

35. Durnford A, Dunbar J, Galea J, Bulters D, Nicoll JA, Boche D, et al. Haemoglobin scavenging after subarachnoid haemorrhage. Acta Neurochir Suppl. 2015;120:51-4.

36. Lok J, Leung W, Murphy S, Butler W, Noviski N, Lo EH. Intracranial hemorrhage: mechanisms of secondary brain injury. Acta Neurochir Suppl. 2011;111:63-9.

37. Subramanian K, Du R, Tan NS, Ho B, Ding JL. CD163 and IgG codefend against cytotoxic hemoglobin via autocrine and paracrine mechanisms. J Immunol. 2013;190(10):5267-78.

38. Yuan J, Cui G, Li W, Zhang X, Wang X, Zheng H, et al. Propofol Enhances Hemoglobin-Induced Cytotoxicity in Neurons. Anesth Analg. 2016;122(4):1024-30.

39. Chiabrando D, Vinchi F, Fiorito V, Mercurio S, Tolosano E. Heme in pathophysiology: a matter of scavenging, metabolism and trafficking across cell membranes. Front Pharmacol. 2014;5:61.

40. Aronowski J, Zhao X. Molecular pathophysiology of cerebral hemorrhage: secondary brain injury. Stroke; a journal of cerebral circulation. 2011;42(6):1781-6.

41. Deuel JW, Vallelian F, Schaer CA, Puglia M, Buehler PW, Schaer DJ. Different target specificities of haptoglobin and hemopexin define a sequential protection system against vascular hemoglobin toxicity. Free Radic Biol Med. 2015;89:931-43.

42. Tracz MJ, Alam J, Nath KA. Physiology and pathophysiology of heme: implications for kidney disease. J Am Soc Nephrol. 2007;18(2):414-20.

43. Meng F, Alayash AI. Determination of extinction coefficients of human hemoglobin in various redox states. Anal Biochem. 2017;521:11-9.

44. Mollan TL, Jia Y, Banerjee S, Wu G, Kreulen RT, Tsai AL, et al. Redox properties of human hemoglobin in complex with fractionated dimeric and polymeric human haptoglobin. Free Radic Biol Med. 2014;69:265-77.

45. Gram M, Sveinsdottir S, Ruscher K, Hansson SR, Cinthio M, Akerstrom B, et al. Hemoglobin induces inflammation after preterm intraventricular hemorrhage by methemoglobin formation. J Neuroinflammation. 2013;10:100.

46. Gram M, Sveinsdottir S, Cinthio M, Sveinsdottir K, Hansson SR, Morgelin M, et al. Extracellular hemoglobin - mediator of inflammation and cell death in the choroid plexus following preterm intraventricular hemorrhage. J Neuroinflammation. 2014;11:200.

47. Vinukonda G, Csiszar A, Hu F, Dummula K, Pandey NK, Zia MT, et al. Neuroprotection in a rabbit model of intraventricular haemorrhage by cyclooxygenase-2, prostanoid receptor-1 or tumour necrosis factor-alpha inhibition. Brain. 2010;133(Pt 8):2264-80.

48. Kirkley KS, Popichak KA, Afzali MF, Legare ME, Tjalkens RB. Microglia amplify inflammatory activation of astrocytes in manganese neurotoxicity. J Neuroinflammation. 2017;14(1):99.

49. Amri F, Ghouili I, Tonon MC, Amri M, Masmoudi-Kouki O. Hemoglobin-Improved Protection in Cultured Cerebral Cortical Astroglial Cells: Inhibition of Oxidative Stress and Caspase Activation. Front Endocrinol (Lausanne). 2017;8:67.

50. Galea J, Cruickshank G, Teeling JL, Boche D, Garland P, Perry VH, et al. The intrathecal CD163-haptoglobin-hemoglobin scavenging system in subarachnoid hemorrhage. Journal of neurochemistry. 2012;121(5):785-92.

51. Thomsen JH, Etzerodt A, Svendsen P, Moestrup SK. The haptoglobin-CD163-heme oxygenase-1 pathway for hemoglobin scavenging. Oxid Med Cell Longev. 2013;2013:523652.

52. Cooper CE, Schaer DJ, Buehler PW, Wilson MT, Reeder BJ, Silkstone G, et al. Haptoglobin binding stabilizes hemoglobin ferryl iron and the globin radical on tyrosine beta145. Antioxid Redox Signal. 2013;18(17):2264-73.

53. Chavez-Bueno S, Beasley JA, Goldbeck JM, Bright BC, Morton DJ, Whitby PW, et al. 'Haptoglobin concentrations in preterm and term newborns'. Journal of perinatology : official journal of the California Perinatal Association. 2011;31(7):500-3.

54. Zager RA. Alpha 1 Microglobulin: A Potentially Paradoxical Anti-Oxidant Agent. Advanced Techniques in Biology & Medicine. 2017;05(03).

55. Ahlstedt J, Tran TA, Strand SE, Gram M, Akerstrom B. Human Anti-Oxidation Protein A1M--A Potential Kidney Protection Agent in Peptide Receptor Radionuclide Therapy. Int J Mol Sci. 2015;16(12):30309-20.

56. Ballabh P. Preterm Rabbit Model of Glycerol-Induced Intraventricular Hemorrhage. 2015;104:45-54.

57. Tibrewal M, Cheng B, Dohare P, Hu F, Mehdizadeh R, Wang P, et al. Disruption of Interneuron Neurogenesis in Premature Newborns and Reversal with Estrogen Treatment. The Journal of neuroscience : the official journal of the Society for Neuroscience. 2018;38(5):1100-13.

58. Semple BD, Blomgren K, Gimlin K, Ferriero DM, Noble-Haeusslein LJ. Brain development in rodents and humans: Identifying benchmarks of maturation and vulnerability to injury across species. Prog Neurobiol. 2013;106-107:1-16.

59. Clancy B, Finlay BL, Darlington RB, Anand KJ. Extrapolating brain development from experimental species to humans. Neurotoxicology. 2007;28(5):931-7.

60. Saliba E, Marret S. Cerebral white matter damage in the preterm infant: pathophysiology and risk factors. Seminars in neonatology : SN. 2001;6(2):121-33.

61. Khwaja O, Volpe JJ. Pathogenesis of cerebral white matter injury of prematurity. Arch Dis Child Fetal Neonatal Ed. 2008;93(2):F153-61.

62. Deng W, Wang H, Rosenberg PA, Volpe JJ, Jensen FE. Role of metabotropic glutamate receptors in oligodendrocyte excitotoxicity and oxidative stress. Proc Natl Acad Sci U S A. 2004;101(20):7751-6.

63. Panfoli I, Candiano G, Malova M, De Angelis L, Cardiello V, Buonocore G, et al. Oxidative Stress as a Primary Risk Factor for Brain Damage in Preterm Newborns. Front Pediatr. 2018;6:369.

64. Kitai Y, Hirai S, Ohmura K, Ogura K, Arai H. Cerebellar injury in preterm children with cerebral palsy after intraventricular hemorrhage: Prevalence and relationship to functional outcomes. Brain & development. 2015;37(8):758-63.

65. Biran V, Verney C, Ferriero DM. Perinatal cerebellar injury in human and animal models. Neurology research international. 2012;2012:858929.

66. Van Kooij BJ, Benders MJ, Anbeek P, Van Haastert IC, De Vries LS, Groenendaal F. Cerebellar volume and proton magnetic resonance spectroscopy at term, and neurodevelopment at 2 years of age in preterm infants. Developmental medicine and child neurology. 2012;54(3):260-6.

67. Jaeger E, Silveira RC, Procianoy RS. Cerebellar growth in very low birth weight infants. Journal of perinatology : official journal of the California Perinatal Association. 2011;31(12):757-9.

68. Limperopoulos C, Soul JS, Gauvreau K, Huppi PS, Warfield SK, Bassan H, et al. Late gestation cerebellar growth is rapid and impeded by premature birth. Pediatrics. 2005;115(3):688-95.

69. Carletti B, Rossi F. Neurogenesis in the cerebellum. The Neuroscientist : a review journal bringing neurobiology, neurology and psychiatry. 2008;14(1):91-100.

70. Garel C, Fallet-Bianco C, Guibaud L. The fetal cerebellum: development and common malformations. Journal of child neurology. 2011;26(12):1483-92.

71. Koning IV, Dudink J, Groenenberg IAL, Willemsen SP, Reiss IKM, Steegers-Theunissen RPM. Prenatal cerebellar growth trajectories and the impact of periconceptional maternal and fetal factors. Human Reproduction. 2017;32(6):1230-7.

72. Tsai PT. Autism and cerebellar dysfunction: Evidence from animal models. Semin Fetal Neonatal Med. 2016;21(5):349-55.

73. Tam EW. Potential mechanisms of cerebellar hypoplasia in prematurity. Neuroradiology. 2013;55 Suppl 2:41-6.

74. Messerschmidt A, Prayer D, Brugger PC, Boltshauser E, Zoder G, Sterniste W, et al. Preterm birth and disruptive cerebellar development: assessment of perinatal risk factors. European journal of paediatric neurology : EJPN : official journal of the European Paediatric Neurology Society. 2008;12(6):455-60.

75. Simon MJ, Iliff JJ. Regulation of cerebrospinal fluid (CSF) flow in neurodegenerative, neurovascular and neuroinflammatory disease. Biochim Biophys Acta. 2016;1862(3):442-51.

76. Sakka L, Coll G, Chazal J. Anatomy and physiology of cerebrospinal fluid. European annals of otorhinolaryngology, head and neck diseases. 2011;128(6):309-16.

77. White JJ, Arancillo M, Stay TL, George-Jones NA, Levy SL, Heck DH, et al. Cerebellar zonal patterning relies on Purkinje cell neurotransmission. The Journal of neuroscience : the official journal of the Society for Neuroscience. 2014;34(24):8231-45.

78. De Luca A, Cerrato V, Fuca E, Parmigiani E, Buffo A, Leto K. Sonic hedgehog patterning during cerebellar development. Cellular and molecular life sciences : CMLS. 2016;73(2):291-303.

79. Sillitoe RV. Mossy Fibers Terminate Directly Within Purkinje Cell Zones During Mouse Development. Cerebellum. 2016;15(1):14-7.

80. Chung SH, Kim CT, Jung YH, Lee NS, Jeong YG. Early cerebellar granule cell migration in the mouse embryonic development. Anat Cell Biol. 2010;43(1):86-95.

81. Jakel S, Dimou L. Glial Cells and Their Function in the Adult Brain: A Journey through the History of Their Ablation. Front Cell Neurosci. 2017;11:24.

82. Reemst K, Noctor SC, Lucassen PJ, Hol EM. The Indispensable Roles of Microglia and Astrocytes during Brain Development. Front Hum Neurosci. 2016;10:566.

83. Menassa DA, Gomez-Nicola D. Microglial Dynamics During Human Brain Development. Front Immunol. 2018;9:1014.

84. Howard BM, Zhicheng M, Filipovic R, Moore AR, Antic SD, Zecevic N. Radial glia cells in the developing human brain. The Neuroscientist : a review journal bringing neurobiology, neurology and psychiatry. 2008;14(5):459-73.

85. Minocha S, Valloton D, Brunet I, Eichmann A, Hornung JP, Lebrand C. NG2 glia are required for vessel network formation during embryonic development. Elife. 2015;4.

86. Herculano-Houzel S. The glia/neuron ratio: how it varies uniformly across brain structures and species and what that means for brain physiology and evolution. Glia. 2014;62(9):1377-91.

87. Herculano-Houzel S, Dos Santos S. You Do Not Mess with the Glia. Neuroglia. 2018;1(1):193-219.

88. Gabriel Ortiz G, Flores-Alvarado LJ, Pacheco-Moisés FP, A. Mireles-Ramírez M, González-Renovato ED, Sánchez-López AL, et al. Cross-talk between glial cells and neurons: Relationship in Multiple Sclerosis. Clinical Case Reports and Reviews. 2016;2(9).

89. Arno B, Grassivaro F, Rossi C, Bergamaschi A, Castiglioni V, Furlan R, et al. Neural progenitor cells orchestrate microglia migration and positioning into the developing cortex. Nat Commun. 2014;5:5611.

90. Filippo TR, Galindo LT, Barnabe GF, Ariza CB, Mello LE, Juliano MA, et al. CXCL12 N-terminal end is sufficient to induce chemotaxis and proliferation of neural stem/progenitor cells. Stem Cell Res. 2013;11(2):913-25.

91. Frost JL, Schafer DP. Microglia: Architects of the Developing Nervous System. Trends Cell Biol. 2016;26(8):587-97.

92. Sousa C, Biber K, Michelucci A. Cellular and Molecular Characterization of Microglia: A Unique Immune Cell Population. Front Immunol. 2017;8:198.

93. Nedergaard M, Ransom B, Goldman SA. New roles for astrocytes: redefining the functional architecture of the brain. Trends Neurosci. 2003;26(10):523-30.

94. Sidoryk-Wegrzynowicz M, Wegrzynowicz M, Lee E, Bowman AB, Aschner M. Role of astrocytes in brain function and disease. Toxicol Pathol. 2011;39(1):115-23.

95. Burda JE, Bernstein AM, Sofroniew MV. Astrocyte roles in traumatic brain injury. Exp Neurol. 2016;275 Pt 3:305-15.

96. van Tilborg E, de Theije CGM, van Hal M, Wagenaar N, de Vries LS, Benders MJ, et al. Origin and dynamics of oligodendrocytes in the developing brain: Implications for perinatal white matter injury. Glia. 2018;66(2):221-38.

97. Kirby L, Jin J, Gonzalez-Cardona J, Smith M, Martin K, Wang J, et al. 2018.

98. French HM, Reid M, Mamontov P, Simmons RA, Grinspan JB. Oxidative stress disrupts oligodendrocyte maturation. J Neurosci Res. 2009;87(14):3076-87.

99. Haynes RL, Folkerth RD, Keefe RJ, Sung I, Swzeda LI, Rosenberg PA, et al. Nitrosative and Oxidative Injury to Premyelinating Oligodendrocytes in Periventricular Leukomalacia. Journal of Neuropathology & Experimental Neurology. 2003;62(5):441-50.

100. Gerstner B, DeSilva TM, Genz K, Armstrong A, Brehmer F, Neve RL, et al. Hyperoxia causes maturation-dependent cell death in the developing white matter. The Journal of neuroscience : the official journal of the Society for Neuroscience. 2008;28(5):1236-45.

101. Giacci MK, Bartlett CA, Smith NM, Iyer KS, Toomey LM, Jiang H, et al. Oligodendroglia Are Particularly Vulnerable to Oxidative Damage after Neurotrauma In Vivo. The Journal of Neuroscience. 2018;38(29):6491-504.

102. Strum JM. Cytochemical Localization of Endogenous Peroxidase in Thyroid Follicular Cells. The Journal of Cell Biology. 1970;44(3):655-66.

Printed by Media-Tryck, Lund 2019 NORDIC SWAN ECOLABEL 3041 0903

LUND UNIVERSITY

FACULTY OF MEDICINE

Department of Clinical Sciences

Lund University, Faculty of Medicine
Doctoral Dissertation Series 2019:22
ISBN 978-91-7619-751-6
ISSN 1652-8220