



LUND UNIVERSITY

Digital mammography and tomosynthesis for breast cancer diagnosis

Tingberg, Anders; Zackrisson, Sophia

Published in:

Expert Opinion on Medical Diagnostics

DOI:

[10.1517/17530059.2011.616492](https://doi.org/10.1517/17530059.2011.616492)

2011

[Link to publication](#)

Citation for published version (APA):

Tingberg, A., & Zackrisson, S. (2011). Digital mammography and tomosynthesis for breast cancer diagnosis. *Expert Opinion on Medical Diagnostics*, 5(6), 517-526. <https://doi.org/10.1517/17530059.2011.616492>

Total number of authors:

2

General rights

Unless other specific re-use rights are stated the following general rights apply:

Copyright and moral rights for the publications made accessible in the public portal are retained by the authors and/or other copyright owners and it is a condition of accessing publications that users recognise and abide by the legal requirements associated with these rights.

- Users may download and print one copy of any publication from the public portal for the purpose of private study or research.
- You may not further distribute the material or use it for any profit-making activity or commercial gain
- You may freely distribute the URL identifying the publication in the public portal

Read more about Creative commons licenses: <https://creativecommons.org/licenses/>

Take down policy

If you believe that this document breaches copyright please contact us providing details, and we will remove access to the work immediately and investigate your claim.

LUND UNIVERSITY

PO Box 117
221 00 Lund
+46 46-222 00 00

Expert Opinion

1. Introduction
2. Breast tomosynthesis
3. Clinical studies comparing DM and BT
4. Conclusion
5. Expert opinion

Digital mammography and tomosynthesis for breast cancer diagnosis

Anders Tingberg[†] & Sophia Zackrisson

[†]Lund University, Skåne University Hospital, Medical Radiation Physics, Department of Clinical Sciences, Malmö, Sweden

Introduction: Mammography is one of the most common X-ray examinations although it is well-known that the anatomical background of the breast is the main obstacle when it comes to detection of breast lesions with this method. Tomosynthesis is a three-dimensional radiographic technique which, to a large extent, can suppress the confounding effect of the anatomical background. Tomosynthesis is a strong competitor to mammography both for screening and clinical examinations.

Areas covered: This paper gives a description of digital mammography (DM) and breast tomosynthesis (BT). Relevant studies exploring the possibilities of BT from a technical and clinical point of view, in comparison with DM, are presented. The reader will learn about the concept of BT as well as its advantages compared with DM. The review highlights both diagnostic and clinical aspects of BT as well as the challenges that remain before BT can be fully incorporated in clinical breast cancer imaging and potentially in screening.

Expert opinion: BT has the potential to considerably improve breast cancer diagnostics and offers advantages to the existing techniques. It has applications both for clinical breast cancer imaging as well as for screening purposes. The true potential of BT in both fields remains to be further evaluated in clinical trials.

Keywords: breast cancer, breast cancer diagnostics, breast tomosynthesis, digital mammography

Expert Opin. Med. Diagn. [Early Online]

1. Introduction

1.1 Current imaging methods in breast cancer

Breast cancer is the most common type of cancer and also the leading cause of cancer death among women world-wide [1]. Mammography is one of the cornerstones in the current diagnostic imaging strategy in breast cancer. Investigations of suspicious lesions usually also include ultrasound (US). However, none of the techniques alone have enough sensitivity and specificity for breast cancer detection, although the combination of the two of them improves the diagnostic outcome [2,3]. Magnetic resonance imaging (MRI) is used for special indications, such as screening of high-risk groups, certain staging procedures and suspicion of multifocal disease to mention some [4,5].

Studies have shown that mammographic screening can reduce mortality from breast cancer to about 30% [6]. Currently, mammography is the only approved method for breast cancer screening [7]. Many countries offer population-based mammography programs for women, the age range differs, but usually include the age group of 50 – 69 years, and in some countries down to 40 years and up to 75 years [8]. The radiographic appearance of breast cancer ranges from hardly detectable, minimal signs to obvious signs of cancer. Some radiographic patterns of breast cancer are more easily detected at an early stage, such as speculated

informa
healthcare

Article highlights.

- Breast cancer is the most common type of cancer and the leading cause of cancer death among women world-wide.
- Breast cancer detection with mammography is challenging since the normal anatomy of the breast may hide the lesions.
- Tomosynthesis is a relatively new tomographic X-ray technique with the possibility to significantly suppress the confounding effect of overlapping normal anatomy.
- There are few clinical studies comparing BT with DM. In a screening population, the difference between BT and DM is small. Most of the published studies are based on a rather small number of cases, resulting in non-significant differences.
- Larger randomized population-based studies investigating BT in a screening context is underway.

This box summarizes key points contained in the article.

tumors and calcifications, whereas others are difficult to detect such as tumors presenting as non-specific densities and areas with subtle architectural distortion.

The sensitivity of screening mammography with currently used digital mammography (DM) systems is not higher than around 70%, which means that 30% of all cancers are missed [9-12]. Thus, the sensitivity of mammography for the detection of breast cancer is not optimal. Mammography has limitations to detect cancers especially in dense breasts, that is, breasts with a high proportion of glandular tissue in relation to fat [13,14]. Younger age is associated with dense breasts as is the use of hormone replacement therapy (HRT) [15,16]. The dense breast tissue can conceal a tumor on mammography; it may also mimic a tumor even if there is none. Holland *et al.* [17] reported that 76% of all missed cancers were in dense breasts. The tomographic technique, which reduces or eliminates the detrimental effect of superimposed tissue, can reduce this problem [18].

1.2 Digital mammography

Full-field DM with flat panel detectors has been broadly used in clinical routine for about a decade. Before the introduction of DM, it was debated whether the image quality and in particular the spatial resolution of DM was sufficient for detection of small calcifications [19]. It was concluded, however, that even though the spatial resolution of DM generally is inferior to screen-film mammography, the resolution is sufficient for breast cancer diagnostics [20,21]. The digital technique provided a number of desirable properties like increased contrast resolution compared with screen-film mammography, fast transfer and simplified storage of images in PACS (picture archiving and communication systems) and image processing [22].

2. Breast tomosynthesis

The term 'tomosynthesis' was defined by Grant [23] in 1972, but it was not until the late 90s that technical developments made the technique practically possible for investigating patients. These developments included flat panel detectors with high readout speed and dose efficiency (high DQE [24]), and computers with high computational power, allowing reasonable image reconstruction times [25-27]. Originally, breast tomosynthesis (BT) units were developed at research institutions in cooperation with manufacturers of mammography systems [28,29] and somewhat later by manufacturers with the intention to develop commercial systems [30]. Tomosynthesis differs from conventional geometric tomography in that it allows visualization of any plane in the imaged object, whereas with tomography only the focal plane, as decided by the pivot point of the tube movement, is visualized [26]. A new exposure is thus required if another plane in the patient is to be examined. BT seems to be a particularly interesting application of tomosynthesis as BT is a straightforward development of DM (similar equipment, patient examination technique and visual impression of the images), and currently there is no other three-dimensional (3D) X-ray technique available for breast examinations.

In BT [28,31-34], a number of low-dose images (usually 11 – 25) of the compressed breast are acquired from different angles, as the X-ray tube moves along a limited arc, typically between 15 and 50° (Figure 1) [35]. The angular spacing as well as the total dose is often homogeneously distributed over this arc. The detector is generally stationary (exception: slot-scanning detector). The tube movement is either continuous or a step-and-shoot movement where the tube stops moving at the time of each exposure [36]. Continuous movement causes a slight movement unsharpness (focal spot blur) which often can be neglected provided that the X-ray pulses are short or that the tube movement is slow. With step-and-shoot movement, the tube must come to a complete stop to avoid motion blur from tube vibration. This causes a slow image acquisition with possible image blur from patient movement as a consequence [37]. In a simulation study, Shaheen *et al.* [38] showed that the step-and-shoot is beneficial with respect to MTF (modulation transfer function), not taking into account the extended image acquisition time with this method, which may result in patient movement. The so-called projection images that are acquired during the tube movement are reconstructed to a 3D volume with mathematical algorithms, similar to computed tomography (CT). Filtered back-projection (FBP) has frequently been used because of its speed, but several research groups are developing and evaluating this and other types of reconstruction algorithms, for example maximum likelihood expectation maximization (MLEM) and simultaneous algebraic reconstruction technique (SART) [39-43]. No general conclusion on which algorithm is the better one has yet been reached. From the reconstructed 3D volume, individual thin slices can be studied, either as a movie (in a cine-loop) or stepped through manually one-by-one [44]. Each slice image contains much less of the

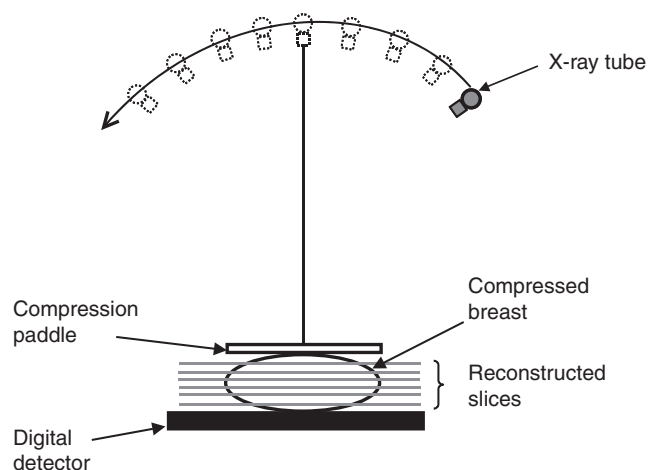


Figure 1. Schematic of a breast tomosynthesis system with stationary detector. The X-ray tube rotates over a limited angle (e.g., $\pm 25^\circ$) while making a number of exposures.

Reproduced with permission from [34].

superimposed normal tissue than the conventional two-dimensional (2D) image. Detection of subtle details, like small tumors with low contrast, is therefore improved (Figure 2).

For diagnostic purposes, a slice separation of 1 mm has commonly been used, but to reduce radiologist's reading time, which is directly connected to the number of slice images, projects are underway to generate thicker image slabs [45] and to study the effect of thicker slices on the detection of breast lesions.

2.1 Technical aspects of BT image volume acquisition

In CT the object is completely sampled as the X-ray tube and detector arc rotates around the object [46]. Contrary to CT where the object is imaged while the X-ray tube and the detector makes a complete revolution around it, the incomplete sampling in tomosynthesis due to the limited angular range, gives rise to loss of information in the depth direction [40]. This is expressed in the tomosynthesis images as out-of-plane artifacts [47]. By increasing the angular range, the magnitude of the out-of-plane artifacts, characterized by the artifact spread function (ASF) [39], will be reduced [48-50]. On the other hand, a larger angular range could result in increased in-plane artifacts [51], as well as a longer image acquisition time. Figure 3 shows a millimetre-sized calcification seen in four different slice images, in the focus plane (a) and outside (b - d). The angular range was 50° , 25 projection images were acquired and FBP was used for the reconstruction. Since the calcification is a high-contrast object it generates an artifact of rather high magnitude, and thus is clearly visible even outside the focus plane. The artifact manifests as a line which is smeared out in the same direction as the scanning direction of the X-ray tube. The figure also shows an in-plane artifact (black area above and below the calcification) that manifests in the scanning direction. This artifact actually improves the

visibility of the calcification. The magnitude of in-plane artifacts was studied by Svahn *et al.* [52], who found that the magnitude of the artifacts was directly proportional to the contrast and the size of the artifact-generating object.

The radiation dose from one tomosynthesis image acquisition is generally the same as the total dose from two projections in mammography (craniocaudal, CC + mediolateral oblique, MLO) [53-55]. Dose levels between 1.6 mGy [53] and 4 mGy [54] have been reported. The total tube loading (mAs value) is often divided equally among the projection images [55], but recently the effect of spending a larger fraction of the total dose on the center projection in order to increase detection of microcalcifications have been investigated [56-58]. Spangler *et al.* [59] did not find any difference in area under the receiver operating characteristic (ROC) curve [60] for BI-RADS (breast imaging reporting and data system) scores of calcifications for DM and BT, although they found a higher sensitivity for calcification detection. Experiments have also been performed in which the angular spacing is varied [61]. As the total dose for tomosynthesis is closely linked to the number of projections and the angular range, the optimum value of these parameters depend on each other. Sechopoulos and Ghetti [50] simulated 63 different combinations of angular range (from 8 to 60°) and number of projections (from 5 to 61), based on 50 unique breast tissue volumes, and found that the depth resolution increased with angular range. Since they had set an upper limit to the average glandular dose they found an optimal number of projections, due to the increase in noise in the projection images which was seen in the reconstructed images. Chawla *et al.* [62] based their study on mastectomy samples which they imaged with tomosynthesis and simulated lesions were added to the tomosynthesis volumes. At a dose level similar to single-view mammography, they found that the optimum number of projection images was 15 - 17 at an angular range of 45° . The optimum angular spacing in both the studies conducted by Sechopoulos and Ghetti [50] and Chawla *et al.* [62] was around 3° . Tingberg *et al.* [63] investigated the dose level required for detection of different types of breast lesions and found that detection of low-contrast lesions with diffuse borders required twice the dose of a single DM image, whereas spiculated high-contrast lesions or lesions with well-defined borders could be detected at lower dose levels. The beam quality is generally the same as the corresponding 2D examination [53], and no studies optimizing this parameter have been published.

3. Clinical studies comparing DM and BT

3.1 Accuracy of breast cancer detection in BT versus DM

Even though there are several studies implying that tomosynthesis has potential to improve breast cancer diagnosis compared with mammography, there are relatively few studies comparing mammography and tomosynthesis in a clinical setting. All studies used enriched populations and in many cases the studies are biased by the fact that the lesions were already

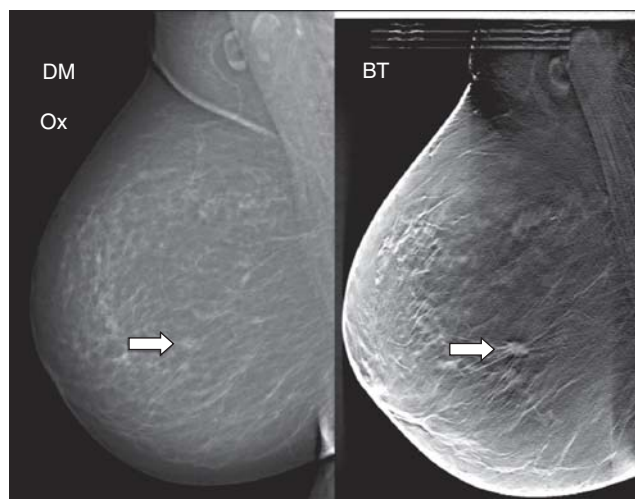

Figure 2. A two-dimensional mammogram (left) of a fatty breast where it is difficult to see a lesion (arrow). In a breast tomosynthesis (BT) image (1 out of approximately 50 images) of the same breast (right), a suspicious malignant finding (approximately 10 mm in diameter) is clearly visible.

selected on the basis of DM. Poplack *et al.* [54] reported that the image quality, including lesion conspicuity and feature analysis, of BT was equivalent or superior to DM in 89% of the 98 cases examined. In a study by Andersson *et al.* [53], 40 cancers which were subtle on DM were in addition imaged with BT, and evaluated with BI-RADS [64] by two experienced breast radiologists in consensus. The study showed that the BI-RADS scores with BT were significantly higher than with DM, indicating that lesions that were classified as benign with DM were more likely to be upgraded to a higher level of malignancy suspicion with BT and with a better correspondence with the true malignancy grade at pathologic-anatomic diagnosis. The study by Andersson *et al.*, in contrast to other studies, only involved cases that proved to be difficult on DM and therefore emphasized those differences, which probably led to the significant difference between BT and DM. In the study by Good *et al.* [65], 30 cases were evaluated by nine observers, both subjectively and under the free-response ROC (FROC) paradigm [66]. Although the observer performance test did not show a significant difference, which the authors attribute to the low number of cases, the subjective rating showed that 67% of the cases deemed BT as 'somewhat better' or 'significantly better' than DM, and 31% deemed as comparable.

If to be used in screening, BT's ability to reduce false positive examinations is of great interest. Gur *et al.* [67] compared DM with BT alone and with a combination of DM and BT. They included 125 selected examinations, 35 with verified cancers and 90 without cancers, and the images were interpreted by eight experienced radiologists. They found that the

combination of DM and BT led to a 30% reduced recall rate for cancer-free examinations that would have led to recall if DM would have been used alone. The authors did not find any substantial improvements for sensitivity for BT alone or in combination with DM, compared with DM. There is no clear statement about the level of recall rate in that study and the results may be more applicable to the US compared with European circumstances, where recall rates with DM are less than 5% [7,9]. In a recently published document by the Food and Drug Administration, two other observer performance experiments comparing DM with a combination of DM and BT were carefully analyzed [68]. In the first study comprising 312 examinations (48 cancers), a two-view BT examination was used in combination with the DM images, whereas in the second study (including 310 examinations, 51 cancers) the DM images were accompanied by a BT examination in the MLO projection. The results of the two studies showed a significant reduction in recall rate and improved clinical performance (expressed as the area under the ROC curve, AUC) for the DM and BT combination compared with DM alone. The combination including two-view BT was better than the BT MLO combination. There was a significant improvement in the AUC for non-calcified tumors for the DM and BT combination (for both studies) compared with DM alone. For calcified tumors the difference was not significant. These results are in agreement with the study by Gur *et al.* [67]. Again, it seems like the recall rates of these studies are substantially higher than what is used in Europe. Teertstra *et al.* [69] imaged 513 cases suspicious from screening, containing 112 cancers, with DM and BT. By using BI-RADS scores 4 and 5 as positive, they found that BT had a higher sensitivity than DM (80 and 73%, respectively) at a similar specificity (97 and 96%, respectively). Gennaro *et al.* [55] recruited 200 patients who had at least one lesion (malignant or benign) discovered by mammography and/or US. The patients underwent BT in the MLO projection, and all images (DM and BT) were evaluated by six experienced breast radiologists in an ROC study. Although lesion conspicuity was better with BT than DM, the ROC analysis did not show a significant difference in diagnostic accuracy between BT and DM. Again, a larger patient population would probably be needed to show such differences. Svahn *et al.* [70] imaged 50 breasts (25 abnormal and 25 normal/benign) with two-view DM and BT in the MLO projection. Three different evaluation schemes were used, based on DM and BT: two-view DM, BT and BT combined with the CC projection of this breast. These image combinations were viewed and rated by five expert breast radiologists in a FROC study. The combined modality, DM in the CC projection and BT in the MLO projection was significantly better than two-view DM. Comparison of the other viewing strategies (combined vs. BT or BT vs. DM) yielded no significant differences. In a computer simulation study, Gong *et al.* [71] generated images with added lesions from a DM system and a BT system based on a model of a breast. The images were evaluated by five observers in an ROC study, and the authors found a

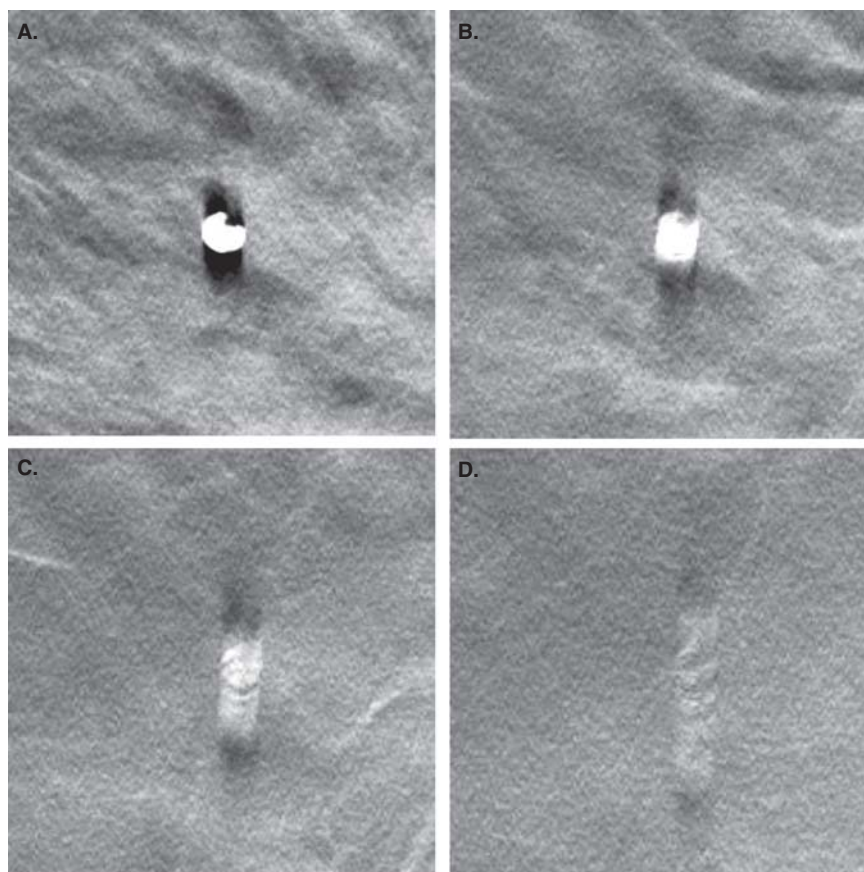


Figure 3. A millimetre-sized calcification seen in different slices: (A) in the focus plane, (B) 6 mm from the focus plane, (C) 10 mm from the focus plane, and (D) 17 mm from the focus plane. The scanning direction of the X-ray tube is from top to bottom.

Reproduced with permission from [34].

significantly higher diagnostic performance (expressed as the area under the ROC curve) for BT than for DM. In a recently published experiment with photon-counting BT, Svane *et al.* presented 144 cases (96 malignant) viewed by two radiologists and assessed both individually and comparing the two techniques. In 56% of the cases the radiologists rated the diagnostic quality of the lesion details significantly higher in the tomosynthesis images than in the conventional images (and in 91% equal or higher). This included the calcifications which were rated as having better quality in 41% of the cases (Figure 4) [72].

To evaluate BT as a screening modality, large population-based screening trials are needed. Currently two such studies are carried out [73]. ‘The Malmö Breast Tomosynthesis Screening Trial (MBTST)’ includes 15,000 women aged 40 – 74 years in Malmö, Sweden, and in Norway the ‘Digital Breast Tomosynthesis in the Oslo Mammography Screening Program’ study includes 25,000 women aged 50 – 69 years in the population-based screening programs.

3.2 Compression force and image quality

There are a number of studies that attempted to optimize different parameters of the tomosynthesis image acquisition procedure or investigated specific image quality parameters, for example, detection of microcalcifications under different conditions, or examined potential advantages with BT compared with DM. More than a decade ago it was foreseen that tomosynthesis could be performed with less compression force than what is used for mammography, and that reduced force would even be beneficial because of the depth resolution of tomosynthesis [22,25]. Saunders *et al.* [74] investigated the effect of compression force on lesion conspicuity for masses and microcalcifications in a Monte Carlo study and found that it was possible to reduce compression by 12.5% at constant average glandular dose without decreasing lesion conspicuity. In a study by Förnvik *et al.* [75], 45 women were investigated with standard compression force at BT (i.e., the force that is used at an ordinary mammography examination) and at half of that force. The quality of the images was evaluated in a visual grading analysis [76,77] study by three experienced

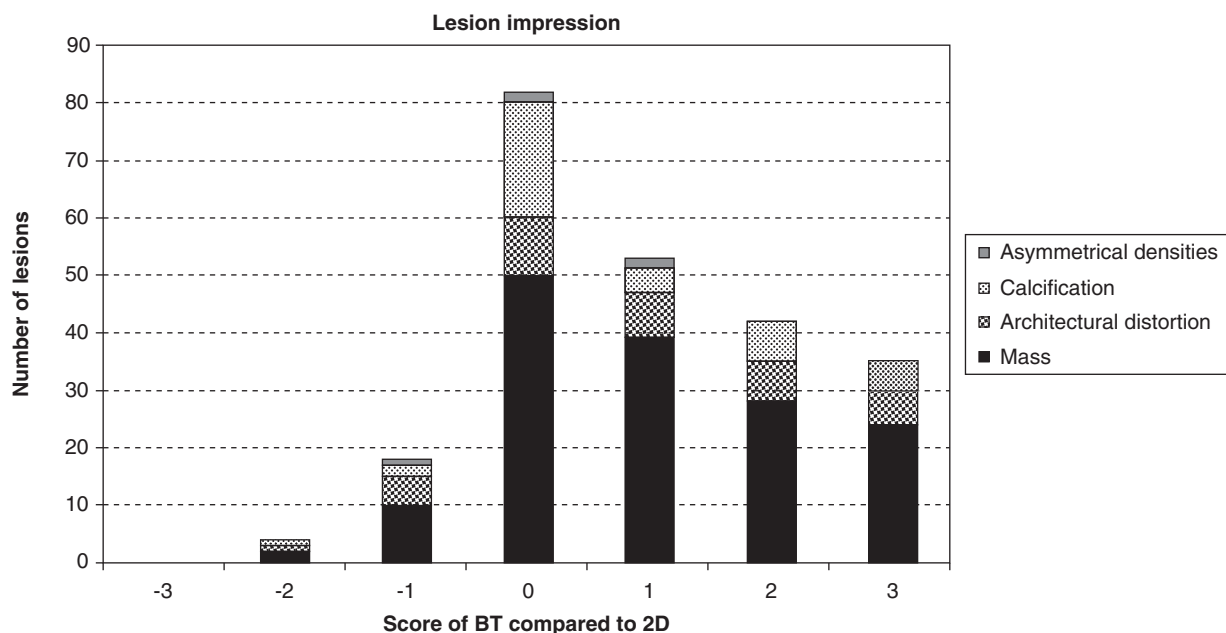


Figure 4. The graph shows the results of the comparison between the impression of the BT image and the two-dimensional (2D) image. It also shows the distribution between different types of lesions in the comparison.

Reproduced with permission from [72], copyright (2011) Royal Society of Medicine Press, UK.

radiologists and the results showed no significant difference in image quality.

Timberg *et al.* [78] studied contrast threshold for detection of simulated structures inserted in normal breast backgrounds with DM and BT and found that detection of 1 mm and larger lesions was significantly better with BT, but for the 0.2 mm lesions, DM outperformed BT.

Breast cancer size is important in preoperative planning and as a prognostic indicator. Förnvik *et al.* [79] investigated if breast cancer size could be more accurately assessed, due to improved visualization of tumor margins with BT than with DM or US. BT, DM and US sizes of 73 breast cancers were measured independently by an experienced radiologist without knowledge of the pathology results, which were used as reference. BT and US size correlated well with pathology, and significantly better than DM size. Tumor staging was, therefore, significantly more accurate with BT than with DM.

3.3 Reading times in BT

The examination time for BT is roughly the same as for the corresponding 2D examination. However, the image reading time (or radiologist time) is one of the major concerns if tomosynthesis should gain a general acceptance for clinical routine use, especially in breast screening where the patient throughput is extremely high (around 1 min reading time per patient). Although there are a few screening studies underway, there are no studies yet that have investigated image reading time

under this condition. It is known that the reading time of BT is longer than for DM, reported to be up to 70% longer [67] or even twice as long or more [80]. It is often the PACS system that limits the reading time, since the retrieving of the tomosynthesis image volume is generally much more time consuming than for 2D as the amount of data in tomosynthesis examination are much larger. The reading time could be decreased by optimized viewing tools or viewing strategies (e.g., Lång *et al.* [81]), quicker PACS systems, etc. Thicker slice images (i.e., fewer slices per breast) could also be a successful strategy for reducing the image reading time. Even though the reading time is longer for tomosynthesis than for the corresponding 2D examination, it may be possible to gain radiologist time by the increased diagnostic information of tomosynthesis which hopefully will decrease the number of false positives (thus reducing recall rate), and shorten the reading time for difficult negative cases.

4. Conclusion

BT in several studies has shown potential to considerably improve the diagnostic accuracy in early detection of breast cancer. It has applications both for clinical breast cancer imaging as well as for screening purposes. The true potential of BT in both fields remains to be further evaluated in clinical trials. We will not have the answer to the question whether BT can replace DM in mammography screening until a couple of years from now, at the earliest.

5. Expert opinion

The commercial introduction of BT has been relatively slow. Outside the USA, BT has been available for approximately 2 years, but only recently the first BT system was approved for sale in the USA. There seems to be a big interest in the radiological community for the technique. The reason for this is obviously that BT has shown potential for increased diagnostic accuracy displayed on several scientific meetings. Furthermore, many radiology departments that have been digital for almost a decade are about to exchange their direct-digital DM units, and since the handling of a BT unit is similar to a DM unit, the implementation of BT is rather straightforward. For a relatively small added cost they can buy the tomosynthesis capability to get access to the new imaging modality.

When evaluating a new diagnostic technique, the most efficient way of getting an indication of its performance is to try it on smaller, enriched populations. If it does not show any advantages compared with a gold standard technique in that setting, given equal conditions, it is unlikely that it would work in a non-selected population. Many of the clinical studies published so far are in this initial stage and have shown promising results. In a next step it would be desirable to see larger, unbiased studies confirming BT's potential.

Based on our experiences with BT and the results from other research groups, it is the authors' belief that BT will be a valuable modality in early detection of breast cancer in a screening situation at least in women with dense breasts. There are several examples published where lesions imaged with BT is considerably better visualized than with DM. It might seem surprising that the studies presented so far do not present stronger evidence for better performance corresponding to what these examples suggest. The lack of significantly different results in some of the studies presented in this paper could probably be explained by the relatively low

number of patients involved in those studies. In many of the studies the study design already favors DM because the cases included were based on what was seen at DM. It is likely that difference in lesion visualization between BT and DM is small and only manifests in a few cases per thousand women. Larger studies involving thousands of women will give valuable information about the potential benefits of BT compared with DM. The results from the ongoing screening trials will form the basis for the potential use of BT in screening. In general, breast cancer screening has been considered cost-effective [82]. The cost-effectiveness of BT compared with DM in screening for breast cancer has not been evaluated and is also yet to be proved.

Besides the fact that larger studies are missing, there is little knowledge in how BT will be used in the clinical routine. Which projections should be used, for example, BT in MLO alone, BT in MLO and CC or BT combined with DM? The latter might be useful in some clinical cases, but in our opinion it has to be carefully investigated before implementing combinations of DM and two-view BT in larger populations such as in screening, considering the radiation dose. What would be the optimum image reading conditions of BT images? Should the images be displayed in a cine-loop or manually scrolled? What slice thickness should be used? There are many research projects that are exploring the more theoretical parts of BT, like acquisition parameters and reconstruction algorithms but few that explore the clinical use of tomosynthesis.

Declaration of interest

The authors would like to thank Region Skåne (regionalt forskningsstöd), Stiftelsen för cancerforskning vid Onkologiska kliniken vid Universitetssjukhuset MAS, Allmänna Sjukhusets i Malmö stiftelse för bekämpande av cancer and Siemens Healthcare for financial support.

Bibliography

Papers of special note have been highlighted as either of interest (●) or of considerable interest (●●) to readers.

1. CANCERmondial. Globocan 2008. International Agency for Research on Cancer. 2008
2. Smith JA, Andreopoulos E. An overview of the status of imaging screening technology for breast cancer. *Ann Oncol* 2004;15(Suppl 1):I18-26
3. Moss HA, Britton PD, Flower CD, et al. How reliable is modern breast imaging in differentiating benign from malignant breast lesions in the symptomatic population? *Clin Radiol* 1999;54(10):676-82
4. Kuhl C. The current status of breast MR imaging. Part I. Choice of technique, image interpretation, diagnostic accuracy, and transfer to clinical practice. *Radiology* 2007;244(2):356-78
5. Kuhl CK. Current status of breast MR imaging. Part 2. Clinical applications. *Radiology* 2007;244(3):672-91
6. Nystrom L, Rutqvist LE, Wall S, et al. Breast cancer screening with mammography: overview of Swedish randomised trials. *Lancet* 1993;341(8851):973-8
7. Perry N, Broeders M, de Wolf C, et al. editors. European guidelines for quality assurance in breast cancer screening and diagnosis. 4th edition. European Commission; Luxembourg: 2006
- **This report describes various aspects of quality assurance in mammography.**
8. Vainio H, Bianchini F. editors. Breast cancer screening. IARC Press; Lyon, France: 2002
9. Ferrini R, Mannino E, Ramsdell E, et al. Screening mammography for breast cancer: American College of Preventive Medicine practice policy statement. *Am J Prev Med* 1996;12(5):340-1
10. Laming D, Warren R. Improving the detection of cancer in the screening of mammograms. *J Med Screen* 2000;7(1):24-30
11. Pisano ED, Gatsonis C, Hendrick E, et al. Diagnostic performance of digital versus film mammography for breast-cancer screening. *N Engl J Med* 2005;353(17):1773-83
12. Skaane P, Balleyguier C, Diekmann F, et al. Breast lesion detection and classification: comparison of screen-film mammography and full-field digital mammography with soft-copy reading—observer performance study. *Radiology* 2005;237(1):37-44
13. Majid AS, de Paredes ES, Doherty RD, et al. Missed breast carcinoma: pitfalls and pearls. *Radiographics* 2003;23(4):881-95
14. Roubidoux MA, Bailey JE, Wray LA, et al. Invasive cancers detected after breast cancer screening yielded a negative result: relationship of mammographic density to tumor prognostic factors. *Radiology* 2004;230(1):42-8
15. Kavanagh AM, Cawson J, Byrnes GB, et al. Hormone replacement therapy, percent mammographic density, and sensitivity of mammography. *Cancer Epidemiol Biomarkers Prev* 2005;14(5):1060-4
16. Banks E. Hormone replacement therapy and the sensitivity and specificity of breast cancer screening: a review. *J Med Screen* 2001;8(1):29-34
17. Holland R, Mravunac M, Hendriks JH, et al. So-called interval cancers of the breast. Pathologic and radiologic analysis of sixty-four cases. *Cancer* 1982;49(12):2527-33
18. Maidment AD. The future of medical imaging. *Radiat Prot Dosimetry* 2010;139(1-3):3-7
19. Diekmann F, Bick U. Tomosynthesis and contrast-enhanced digital mammography: recent advances in digital mammography. *Eur Radiol* 2007;17(12):3086-92
20. Fischer U, Hermann KP, Baum F. Digital mammography: current state and future aspects. *Eur Radiol* 2006;16(1):38-44
21. Pisano ED, Yaffe M. Digital mammography. *Breast Dis* 1998;10(3-4):127-35
22. Yaffe MJ. Digital mammography. In: Beutel J, Kundel HL, Van Metter RL. editors. Handbook of Medical Imaging. Physics and psychophysics. Volume 1 SPIE Press; Bellingham, USA: 2000. p. 329-72
23. Grant DG. Tomosynthesis: a three-dimensional radiographic imaging technique. *IEEE Trans Biomed Eng* 1972;BME-19(1):20-8
24. IEC 62220-1. Medical electrical equipment – Characteristics of digital X-ray imaging devices – Part 1: Determination of the detective quantum efficiency; 2003
25. Niklason LT, Kopans DB, Hamberg LM. Digital breast imaging: tomosynthesis and digital subtraction mammography. *Breast Dis* 1998;10(3-4):151-64
26. Dobbins JT, Godfrey DJ. Digital x-ray tomosynthesis: current state of the art and clinical potential. *Phys Med Biol* 2003;48(19):R65-106
- **This excellent review describes the historical and mathematical background of tomosynthesis, as well as clinical applications.**
27. Niklason LT, Niklason LE, Kopans DB. inventors; The General Hospital Corp. (Boston, MA, USA), assignee. Tomosynthesis system for breast imaging. US5872828; 1999
28. Niklason LT, Christian BT, Niklason LE, et al. Digital tomosynthesis in breast imaging. *Radiology* 1997;205(2):399-406
29. Varjonen M. Three-dimensional (3D) digital breast tomosynthesis (DBT) in the early diagnosis and detection of breast cancer. Thesis. Tampere University of Technology; Tampere, Finland: 2006
30. Lewin JM, Niklason L. Advanced applications of digital mammography: tomosynthesis and contrast-enhanced digital mammography. *Semin Roentgenol* 2007;42(4):243-52
31. Rafferty EA. Digital mammography: novel applications. *Radiol Clin North Am* 2007;45(5):831-43; vii
32. Baldwin P. Digital breast tomosynthesis. *Radiol Technol* 2009;81(1):57M-74M
- **This paper reviews the clinical motivation to tomosynthesis, and potential challenges to the clinical implementation of BT.**
33. Helvie MA. Digital mammography imaging: breast tomosynthesis and advanced applications. *Radiol Clin North Am* 2010;48(5):917-29

Expert Opin. Med. Diagn. Downloaded from informahealthcare.com by Region Skåne on 09/07/11 For personal use only.

34. Tingberg A. X-Ray Tomosynthesis: a review of its use for breast and chest imaging. *Radiat Prot Dosimetry* 2010;139(1-3):100-7
35. Dobbins JTI. Tomosynthesis imaging: at a translational crossroads. *Med Phys* 2009;36(6):1956-67
- **This paper provides translational questions facing tomosynthesis imaging and anticipates some of the likely research and clinical activities in a near future.**
36. Smith A. Full-field breast tomosynthesis. *Radiol Manage* 2005;27(5):25-31
37. Park JM, Franken EA Jr, Garg M, et al. Breast tomosynthesis: present considerations and future applications. *Radiographics* 2007;27(Suppl 1):S231-40
38. Shaheen E, Marshall N, Bosmans H. Investigation of the effect of tube motion in breast tomosynthesis: continuous or step and shoot? *Proc SPIE* 2011;7961:79611E-1-79611E-9
39. Wu T, Moore RH, Rafferty EA, et al. A comparison of reconstruction algorithms for breast tomosynthesis. *Med Phys* 2004;31(9):2636-47
40. Mertelmeier T, Orman J, Haerer W, et al. Optimizing filtered backprojection reconstruction for a breast tomosynthesis prototype device. *Proc SPIE* 2006;6142:61420F-1-F-12
41. Das M, Gifford H, O'Connor J, et al. Penalized maximum likelihood reconstruction for improved microcalcification detection in breast tomosynthesis. *IEEE Trans Med Imaging* 2011;30(4):904-14
42. Jerebko AK, Mertelmeier T. Evaluation and optimization of the maximum-likelihood approach for image reconstruction in digital breast tomosynthesis. *Proc SPIE* 2010;7622:76220E-1-76220E-9
43. Van de Sompel D, Brady SM, Boone J. Task-based performance analysis of FBP, SART and ML for digital breast tomosynthesis using signal CNR and Channelised Hotelling Observers. *Med Image Anal* 2010;15(1):53-70
44. Lang K, Zackrisson S, Holmqvist K, et al. Optimizing viewing procedures of breast tomosynthesis image volumes using eye tracking combined with a free response human observer study. *Proc SPIE* 2011;7966:796602-1-796602-11
45. Diekmann F, Meyer H, Diekmann S, et al. Thick slices from tomosynthesis data sets: phantom study for the evaluation of different algorithms. *J Digit Imaging* 2009;22(5):519-26
46. Kalender WA. X-ray computed tomography. *Phys Med Biol* 2006;51(13):R29-43
47. Hu YH, Zhao B, Zhao W. Image artifacts in digital breast tomosynthesis: investigation of the effects of system geometry and reconstruction parameters using a linear system approach. *Med Phys* 2008;35(12):5242-52
48. Timberg P, Ruschin M, Bath M, et al. Optimization of image quality in breast tomosynthesis using lumpectomy and mastectomy specimens. *Proc SPIE* 2007;6510:651032-1-8
49. Deller T, Jabri KN, Sabol JM, et al. Effect of acquisition parameters on image quality in digital tomosynthesis. *Proc SPIE* 2007;6510:65101L-1-11
50. Sechopoulos I, Ghetti C. Optimization of the acquisition geometry in digital tomosynthesis of the breast. *Med Phys* 2009;36(4):1199-207
51. Lu Y, Chan H-P, Goodsitt M, et al. Effects of projection-view distributions on image quality of calcifications in digital breast Tomosynthesis (DBT) reconstruction. *Proc SPIE* 2010;7622:76220D-1 - 76220D-8
52. Svahn T, Ruschin M, Hemdal B, et al. In-plane artifacts in breast tomosynthesis quantified with a novel contrast-detail phantom. *Proc SPIE* 2007;6510:65104R-1-R-12
53. Andersson I, Ikeda DM, Zackrisson S, et al. Breast tomosynthesis and digital mammography: a comparison of breast cancer visibility and BIRADS classification in a population of cancers with subtle mammographic findings. *Eur Radiol* 2008;18(12):2817-25
54. Poplack SP, Tosteson TD, Kogel CA, et al. Digital breast tomosynthesis: initial experience in 98 women with abnormal digital screening mammography. *AJR Am J Roentgenol* 2007;189(3):616-23
55. Gennaro G, Toledano A, di Maggio C, et al. Digital breast tomosynthesis versus digital mammography: a clinical performance study. *Eur Radiol* 2010;20(7):1545-53
56. Hu YH, Zhao W. Nonuniform angular dose distribution in digital breast tomosynthesis for increased conspicuity of small high contrast objects. *Proc SPIE* 2009;7258:72580Q-1-8
57. Das M, Gifford HC, O'Connor JM, et al. Evaluation of a variable dose acquisition technique for microcalcification and mass detection in digital breast tomosynthesis. *Med Phys* 2009;36(6):1976-84
58. Vecchio S, Albanese A, Vignoli P, et al. A novel approach to digital breast tomosynthesis for simultaneous acquisition of 2D and 3D images. *Eur Radiol* 2011;21(6):1207-13
59. Spangler ML, Zuley ML, Sumkin JH, et al. Detection and classification of calcifications on digital breast tomosynthesis and 2D digital mammography: a comparison. *AJR Am J Roentgenol* 2011;196(2):320-4
60. Metz CE. Fundamental ROC analysis. In: Beutel J, Kundel HL, Van Metter RL, editors. *Handbook of Medical Imaging, Physics and psychophysics*. Volume 1 SPIE Press; Bellingham, USA: 2000. p. 751-69
61. Wu T, Stewart A, Stanton M, et al. Tomographic mammography using a limited number of low-dose cone-beam projection images. *Med Phys* 2003;30(3):365-80
62. Chawla AS, Lo JY, Baker JA, et al. Optimized image acquisition for breast tomosynthesis in projection and reconstruction space. *Med Phys* 2009;36(11):4859-69
63. Timberg P, Bath M, Andersson I, et al. Impact of dose on observer performance in breast tomosynthesis using breast specimens. *Proc SPIE* 2008;6913:69134J-1 - 69134J-10
64. American College of Radiology. *Breast imaging reporting and data system (BI-RADS)*. 2nd edition. Reston, VA: 1995
65. Good WF, Abrams GS, Catullo VJ, et al. Digital breast tomosynthesis: a pilot observer study. *AJR Am J Roentgenol* 2008;190(4):865-9
66. Chakraborty DP, The FROC. AFROC and DROC variants of the ROC analysis. In: Beutel J, Kundel HL, Van Metter RL, editors. *Handbook of Medical Imaging, Physics and*

- psychophysics. Volume 1 SPIE Press; Bellingham, USA: 2000. p. 771-96
67. Gur D, Abrams GS, Chough DM, et al. Digital breast tomosynthesis: observer performance study. *AJR Am J Roentgenol* 2009;193(2):586-91
68. FDA. PMA P080003: FDA summary of safety and effectiveness data. Center for devices and radiological health. Available from: http://www.accessdata.fda.gov/cdrh_docs/pdf8/P080003b.pdf
69. Teertstra HJ, Loo CE, van den Bosch MA, et al. Breast tomosynthesis in clinical practice: initial results. *Eur Radiol* 2010;20(1):16-24
70. Svahn T, Andersson I, Chakraborty D, et al. The diagnostic accuracy of dual-view digital mammography, single-view breast tomosynthesis and a dual-view combination of breast tomosynthesis and digital mammography in a free-response observer performance study. *Radiat Prot Dosimetry* 2010;139(1-3):113-17
71. Gong X, Glick SJ, Liu B, et al. A computer simulation study comparing lesion detection accuracy with digital mammography, breast tomosynthesis, and cone-beam CT breast imaging. *Med Phys* 2006;33(4):1041-52
72. Svane G, Azavedo E, Lindman K, et al. Clinical experience of photon counting breast tomosynthesis: comparison with traditional mammography. *Acta Radiol* 2011;52(2):134-42
73. U.S. National Institutes of Health. Available from: www.ClinicalTrials.gov
74. Saunders RS Jr, Samei E, Lo JY, et al. Can compression be reduced for breast tomosynthesis? Monte Carlo study on mass and microcalcification conspicuity in tomosynthesis. *Radiology* 2009;251(3):673-82
75. Fornvik D, Andersson I, Svahn T, et al. The effect of reduced breast compression in breast tomosynthesis: human observer study using clinical cases. *Radiat Prot Dosimetry* 2010;139(1-3):118-23
76. Tingberg A. Quantifying the quality of medical x-ray images. An evaluation based on normal anatomy for lumbar spine and chest radiography. Thesis. Lund University; Malmö: 2000
77. Tingberg A, Bath M, Hakansson M, et al. Evaluation of image quality of lumbar spine images: a comparison between FFE and VGA. *Radiat Prot Dosimetry* 2005;114(1-3):53-61
78. Timberg P, Bath M, Andersson I, et al. In-plane visibility of lesions using breast tomosynthesis and digital mammography. *Med Phys* 2010;37(11):5618-26
79. Fornvik D, Zackrisson S, Ljungberg O, et al. Breast tomosynthesis: Accuracy of tumor measurement compared with digital mammography and ultrasonography. *Acta Radiol* 2010;51(3):240-7
80. Andersson I. Reading time for breast tomosynthesis. Personal communication; 2010
81. Lang K, Zackrisson S, Holmqvist K, et al. Can horizontally oriented breast tomosynthesis image volumes or the use of a systematic search strategy improve interpretation? An eye tracking and free response human observer study. *Proc SPIE* 2011;7966:796606-1-796606-12
82. Stout NK, Rosenberg MA, Trentham-Dietz A, et al. Retrospective cost-effectiveness analysis of screening mammography. *J Natl Cancer Inst* 2006;98(11):774-82

Affiliation

Anders Tingberg^{†1,2} PhD & Sophia Zackrisson^{3,4} PhD
[†]Author for correspondence
¹Lund University, Skåne University Hospital, Medical Radiation Physics, Department of Clinical Sciences, 205 02 Malmö, Sweden
 Tel: +46 40 331155; Fax: +46 40 963185; E-mail: anders.tingberg@med.lu.se
²Skåne University Hospital, Department of Radiation Physics, 205 02 Malmö, Sweden
³Lund University, Skåne University Hospital, Diagnostic Radiology, Department of Clinical Sciences, 205 02 Malmö, Sweden
⁴Skåne University Hospital, Diagnostic Center for Imaging and Functional Medicine, 205 02 Malmö, Sweden

Expert Opin. Med. Diagn. Downloaded from informahealthcare.com by Region Skåne on 09/07/11
 For personal use only.