LUND UNIVERSITY

Progression in Glaucoma

Öhnell, Hanna Maria

2020

Document Version:
Publisher's PDF, also known as Version of record

Link to publication

Citation for published version (APA):
Öhnell, H. M. (2020). *Progression in Glaucoma*. [Doctoral Thesis (compilation), Department of Clinical Sciences, Malmö]. Lund University, Faculty of Medicine.

Total number of authors:
1

General rights
Unless other specific re-use rights are stated the following general rights apply:
Copyright and moral rights for the publications made accessible in the public portal are retained by the authors and/or other copyright owners and it is a condition of accessing publications that users recognise and abide by the legal requirements associated with these rights.
• Users may download and print one copy of any publication from the public portal for the purpose of private study or research.
• You may not further distribute the material or use it for any profit-making activity or commercial gain
• You may freely distribute the URL identifying the publication in the public portal

Read more about Creative commons licenses: https://creativecommons.org/licenses/

Take down policy
If you believe that this document breaches copyright please contact us providing details, and we will remove access to the work immediately and investigate your claim.

LUND UNIVERSITY

PO Box 117
221 00 Lund
+46 46-222 00 00

Progression in Glaucoma

HANNA MARIA ÖHNELL
FACULTY OF MEDICINE | LUND UNIVERSITY

Printed by Media-Tryck, Lund 2020 NORDIC SWAN ECOLABEL 3041 0903

Hanna Maria Öhnell studied medicine at Lund University, and is currently working as a resident at the Department of Ophthalmology at Skåne University Hospital. This thesis explores the possibility to correctly diagnose glaucoma and evaluates different methods used to monitor glaucoma progression during the lifelong follow-up of this large group of patients in ophthalmic care.

LUND UNIVERSITY

FACULTY OF MEDICINE

Lund University, Faculty of Medicine
Doctoral Dissertation Series 2020:14
ISBN 978-91-7619-874-2
ISSN 1652-8220

Progression in Glaucoma

Progression in Glaucoma

Hanna Maria Öhnell

LUND UNIVERSITY

DOCTORAL DISSERTATION

by due permission of the Faculty of Medicine, Lund University, Sweden.

To be defended in public in the Jubileumsaulan lecture hall,

Jan Waldenströms gata 1,

Skåne University Hospital, Malmö,

Friday the 7th of February, 2020, at 1 pm.

Faculty opponent
Professor Hannu Uusitalo

Faculty of Medicine and Life Sciences

University of Tampere, Finland

Organization
LUND UNIVERSITY
Institute of Clinical Sciences in Malmö
Ophthalmology, Skåne University Hospital, Sweden
Author(s) Hanna Maria Öhnell

Document name
DOCTORAL DISSERTATION

Date of issue
7th of February, 2020

Sponsoring organization:

Title and subtitle
PROGRESSION IN GLAUCOMA

Abstract

The treatment of glaucoma is focused on reducing the intraocular pressure to a level at which progression is impeded. A diagnosis of glaucoma is not considered certain until progression is confirmed, and thus detecting progression is a central aspect in both the diagnosing and the monitoring of glaucoma patients. Progression can be identified either through examination of either functional changes in the visual field or structural changes in the retinal nerve fibre layer in the optic disc or in the retina. Optic disc photography, and optical coherence tomography (OCT) that uses laser light, are two methods that are widely used to detect structural changes.

The objectives of the present research were three-fold: (1) to assess how often a correct diagnosis was made during the few initial clinical visits, when no knowledge of progression was available; (2) to compare visual field examination and optic disc photography as methods to detect progression in glaucoma patients; (3) to evaluate the capacity of OCT to detect the rate of change in the retinal nerve fibre layer. For the first and second objectives, we studied glaucoma patients that had been included in the Early Manifest Glaucoma Trial, in which up to 20 years of regular prospective examinations were performed. To achieve the third objective, two different cohorts of healthy individuals and glaucoma patients were re-examined at a 10-year follow-up visit.

Automated visual field examinations with strict criteria for defining glaucoma resulted in a correct diagnosis in 97% of patients after only two initial visits. Comparing visual fields and optic disc photographs among the glaucoma patients, the visual field examinations detected progression approximately four times as often. However, in eyes without glaucoma, progression was detected equally often by the two methods. The OCT method could not demonstrate a statistically significant difference in rate of change between healthy individuals and glaucoma patients. The automated OCT progression analysis, which is designed to assist the clinician in detecting glaucoma progression, gave excessively high rates of false positives.

Guidelines recommend examinations of both functional and structural measures throughout the lifelong follow-up of glaucoma, a goal that is seldom achieved in reality. Inasmuch as health care resources are limited, the results presented in this thesis can aid in selecting the optimal method to monitor this large group of patients with different stages of glaucoma.

Key words: glaucoma, correct diagnosis, progression, visual field, perimetry, optical coherence omography (OCT),

Classification system and/or index terms (if any)

Supplementary bibliographical information

Language English

ISSN 1652-8220 Progression in Glaucoma

ISBN 978-91-7619-874-2

Recipient's notes

Number of pages 66

Price

Security classification

I, the undersigned, being the copyright owner of the abstract of the above-mentioned dissertation, hereby grant to all reference sources permission to publish and disseminate the abstract of the above-mentioned dissertation.

Signature

Date 2019-12-16

Progression in Glaucoma

Hanna Maria Öhnell

LUND
UNIVERSITY

Copyright pp 1-66 Hanna Maria Öhnell

Paper 1 © Elsevier Inc. open access

Paper 2 © John Wiley & sons, Inc. open access

Paper 3 © Wolters Kluwer Health, Inc. open access

Paper 4 © by the Authors (Manuscript submitted)

Faculty of Medicine
Department of Clinical Sciences in Malmö

ISBN 978-91-7619-874-2
ISSN 1652-8220

Printed in Sweden by Media-Tryck, Lund University,
Lund 2020

Media-Tryck is an environmentally
certified and ISO 14001:2015 certified
provider of printed material.
Read more about our environmental
work at www.mediatryck.lu.se

MADE IN SWEDEN

There is always a third possibility, as long as you have the ability to find it.

Selma Lagerlöf

TABLE OF CONTENTS

TABLE OF CONTENTS **8**
ABSTRACT **11**
LIST OF PAPERS **13**
ABBREVIATIONS **15**
INTRODUCTION **17**
Primary open-angle glaucoma 17
Establishing a diagnosis and detecting progression 19
Functional tests 19
Structural tests 24
AIMS **27**
SUBJECTS AND METHODS **29**
A correct diagnosis of glaucoma (Paper III) 29
Comparing visual fields with optic disc photographs to detect progression (Papers I and II) 31
OCT as a method to detect and measure progression (Paper IV) 32
RESULTS **35**
A correct diagnosis of glaucoma (Paper III) 35
Comparing visual fields with optic disc photographs to detect progression (Papers I and II) 36
OCT as a method to detect and measure progression (Paper IV) 37
DISCUSSION **41**
A correct diagnosis of glaucoma (Paper III) 41
Different methods to detect glaucoma progression (Papers I, II and IV) 43
Future perspectives 46
CONCLUSIONS **49**

POPULÄRVETENSKAPLIG SAMMANFATTNING.....51
Bakgrund.....51
Syfte.....52
Projektbeskrivning och resultat.....52
Slutsatser.....54
ACKNOWLEDGEMENTS.....55
REFERENCES.....59

ABSTRACT

The treatment of glaucoma is focused on reducing the intraocular pressure to a level at which progression is impeded. A diagnosis of glaucoma is not considered certain until progression is confirmed, and thus detecting progression is a central aspect in both the diagnosing and the monitoring of glaucoma patients. Progression can be identified either through examination of either functional changes in the visual field or structural changes in the retinal nerve fibre layer in the optic disc or in the retina. Optic disc photography, and optical coherence tomography (OCT) that uses laser light, are two methods that are widely used to detect structural changes.

The objectives of the present research were three-fold: (1) to assess how often a correct diagnosis was made during the few initial clinical visits, when no knowledge of progression was available; (2) to compare visual field examination and optic disc photography as methods to detect progression in glaucoma patients; (3) to evaluate the capacity of OCT to detect the rate of change in the retinal nerve fibre layer. For the first and second objectives, we studied glaucoma patients that had been included in the Early Manifest Glaucoma Trial, in which up to 20 years of regular prospective examinations were performed. To achieve the third objective, two different cohorts of healthy individuals and glaucoma patients were re-examined at a 10-year follow-up visit.

Automated visual field examinations with strict criteria for defining glaucoma resulted in a correct diagnosis in 97% of patients after only two initial visits. Comparing visual fields and optic disc photographs among the glaucoma patients, the visual field examinations detected progression approximately four times as often. However, in eyes without glaucoma, progression was detected equally often by the two methods. The OCT method could not demonstrate a statistically significant difference in rate of change between healthy individuals and glaucoma patients. The automated OCT progression analysis, which is designed to assist the clinician in detecting glaucoma progression, gave excessively high rates of false positives.

Guidelines recommend examinations of both functional and structural measures throughout the lifelong follow-up of glaucoma, a goal that is seldom achieved in reality. Inasmuch as health care resources are limited, the results presented in this thesis can aid in selecting the optimal method to monitor this large group of patients with different stages of glaucoma.

LIST OF PAPERS

Paper I **Öhnell HM**, Heijl A, Brenner L, Anderson H, Bengtsson B. Structural and Functional Progression in the Early Manifest Glaucoma Trial. *Ophthalmology* 2016;123(6):1173-1180

Paper II **Öhnell HM**, Heijl A, Anderson H, Bengtsson B. Detection of Glaucoma Progression by Perimetry and Optic Disc Photography at Different Stages of the Disease: Results from the Early Manifest Glaucoma Trial. *Acta Ophthalmologica* 2017;95(3):281-287

Paper III **Öhnell HM**, Bengtsson B, Heijl A. Making a Correct Diagnosis of Glaucoma: Data from the EMGT. *Journal of Glaucoma* 2019;28(10)859-864

Paper IV **Öhnell HM**, Heijl A, Bengtsson B. Aging and Glaucoma Progression of the Retinal Nerve Fibre Layer Using Spectral-Domain OCT Analysis. Manuscript submitted to *Acta Ophthalmologica*.

ABBREVIATIONS

AGIS	Advanced Glaucoma Treatment Study
CIGTS	Collaborative Intensive Glaucoma Treatment Study
CNTGS	Collaborative Normal Tension Glaucoma Study
cpRNFL	circumpapillary Retinal Nerve Fibre Layer
EGPS	European Glaucoma Prevention Study
EMGT	Early Manifest Glaucoma Trial
GCIPL	Ganglion Cell-Inner Plexiform Layer
GCP	Glaucoma Change Probability
GDx	Glaucoma Diagnosis analyzer
GHT	Glaucoma Hemifield Test
GPA	Guided Progression Analysis
HD-OCT	High Definition Optical Coherence Tomography
HFA	Humphrey Field Analyzer
IOP	Intraocular Pressure
MD	Mean Deviation
OCT	Optical Coherence Tomography
OHTS	Ocular Hypertension Treatment Study
RNFL	Retinal Nerve Fibre Layer
SITA	Swedish Interactive Threshold Algorithm
STATPAC	Statistical Package
VFI	Visual Field Index

INTRODUCTION

Although descriptions of an eye condition called 'glaukos' were documented by Hippocrates as early as around 400 BC, it was not until the mid 19th century that our current understanding of glaucoma began to emerge when the ophthalmoscope and tonometer were developed (Mackenzie 1830; Helmholtz 1851; Schiötz 1905; Goldmann 1954; Leffler et al. 2015). A raised intraocular pressure (IOP) was originally assumed to be pathognomonic for the disease, but in the 20th century there were reports indicating the existence of glaucoma without an elevated IOP (Sjögren 1946). In the 1960s, studies demonstrated a pressure within normal limits for a large proportion of glaucoma patients, and also showed that the majority of patients with a raised IOP did not exhibit any signs of glaucomatous damage in the visual field or the optic nerve head (Hollows and Graham 1966; Linnér 1969). Thereafter, it successively became clear that an elevated IOP was a risk factor, but not a prerequisite, for glaucoma.

There are different forms of glaucoma, but this thesis deals solely with primary open-angle glaucoma. In this condition, the anterior chamber angle is open at inspection, which allows natural drainage of intra-ocular fluid from the eye on a macroscopic level, even though the IOP is still raised in at least half of the patients (Grødum et al. 2002). Primary open-angle glaucoma is the most common form of the disease, and it leads to indolent loss of retinal nerve fibres, a process that often occurs over the course of many years. The cause of primary open-angle glaucoma is still not fully understood.

Primary open-angle glaucoma

Glaucoma is the leading cause of irreversible blindness worldwide, and approximately one in six patients with open-angle glaucoma become blind during their lifetime (Bourne et al. 2013; Peters et al. 2013; WHO 2014). The prevalence of primary open-angle glaucoma increases with age and was estimated to be around 2% globally for the population over 40 years of age in 2015 (Kapetanakis et al. 2016). In Sweden, glaucoma patients constitute one fourth of the outpatient visits in ophthalmologic care (Linden et al. 2013). This is a progressive disease in which the visual field is

gradually lost as the retinal nerve fibres are damaged. For most individuals, this change remains unnoticed until approximately half of the visual field is lost (Grødum et al. 2002). This progression is possible, because an unaffected fellow eye can compensate for a defect in the affected eye, and the brain also performs a filling-in process by extracting visual information from the surroundings (Walls 1954; Ramachandran and Gregory 1991) (Fig. 1). Inasmuch as the deterioration of the visual field is often not recognized by the individual, detecting and measuring loss of visual field function is central in diagnosing and monitoring these patients.

Figure 1. A visual field of an eye focusing on the road ahead.
Left: A normal visual field in which a child is visible in the periphery. Right: A visual field in which a defect is present in the lower left corner of the field and a filling-in process from the surrounding pavement occurs.

When a diagnosis is made, treatment is initiated to lower the IOP to a level that will halt progression. This can be done pharmacologically, through laser treatment of the trabecular meshwork of the anterior chamber angle, or by different surgical procedures. Although only half of all glaucoma patients exhibit an IOP above the reference values, large randomized studies have demonstrated that even patients with pressures within normal reference limits benefit from pressure-lowering treatment (Collaborative Normal Tension Glaucoma Study Group 1998; Heijl et al. 2002). Considering that there are no safe pressure levels, it is imperative to measure the rate of progression to be able to determine whether the patient needs additional treatment. All forms of pressure-lowering treatment have the potential to cause side effects and entail costs for both the patient and society. Furthermore, the mere establishment of a glaucoma diagnosis has a negative effect on the patient's quality of life (Odberg et al. 2001; Quaranta et al. 2016), and hence it is crucial to avoid false-positive diagnoses of this disease.

Establishing a diagnosis and detecting progression

Many people do not recognize a reduction in their visual field until a large part of the field is already lost, and hence a diagnosis is often suspected through any of the following: detection of a raised IOP at routine optician/optometrist visit; in passing, when a patient is examined by an ophthalmologist for other reasons; if the patient is aware of the risk of glaucoma related to heredity. Attempts have been made to find appropriate screening-tools for glaucoma, but so far none of them have offered sufficient discriminative capacity and cost-effectiveness to be implemented (Wilson 2019).

Once an ophthalmologist has examined a patient, it can be a rather straightforward task to establish a diagnosis of primary open-angle glaucoma, if the patient has clear defects in the visual field with corresponding structural findings in the optic nerve. However, in other instances, such as when examining patients with early stages of glaucoma, establishing a diagnosis can be much more difficult. In some individuals, the earliest signs of the disease can be detected only in the visual field with no findings in the optic disc, whereas in other cases the opposite is true (Kass et al. 2002; Miglior et al. 2005; Medeiros et al. 2009). If the diagnosis is uncertain, it is considered desirable to document structural or functional progression during follow-up before the diagnosis is confirmed (Weinreb and Greve 2004; Stamper et al. 2009). The ability to determine glaucoma progression will always depend on the methods that are used and their differences in sensitivities and specificities, as well as the proficiency and scrutiny of the interpreter of the test.

Functional tests

A variety of different methods are available to detect and measure functional and structural progression. At present, automated perimetry is the predominant technique for assessing the function of the visual field. With that method, the threshold for visual sensitivity is determined for a number of locations in the visual field, usually within the 30 most central degrees from fixation. Several different manufacturers provide such instruments, and the Humphrey Field Analyzer (HFA) is one of the most widely used globally since its introduction in the mid 1980s.

The HFA includes an automated interpretation tool called STATPAC, which consists of a set of software packages that aids the clinician in determining whether a patient's visual field results fall within the normal range for a person of that particular age (Heijl 1989). Total deviation probability plots are displayed in which the threshold sensitivity at each point is compared with age-matched reference values (Fig. 2).

Pattern deviation probability plots are also presented, which analyse the sensitivity losses at each test point outside normal limits after adjustment for any generalized elevation or, more typically, after adjustment for depression of the field that is usually caused by cataracts. The summary index Mean Deviation (MD) describes the average extent to which the whole field differs from a healthy field.

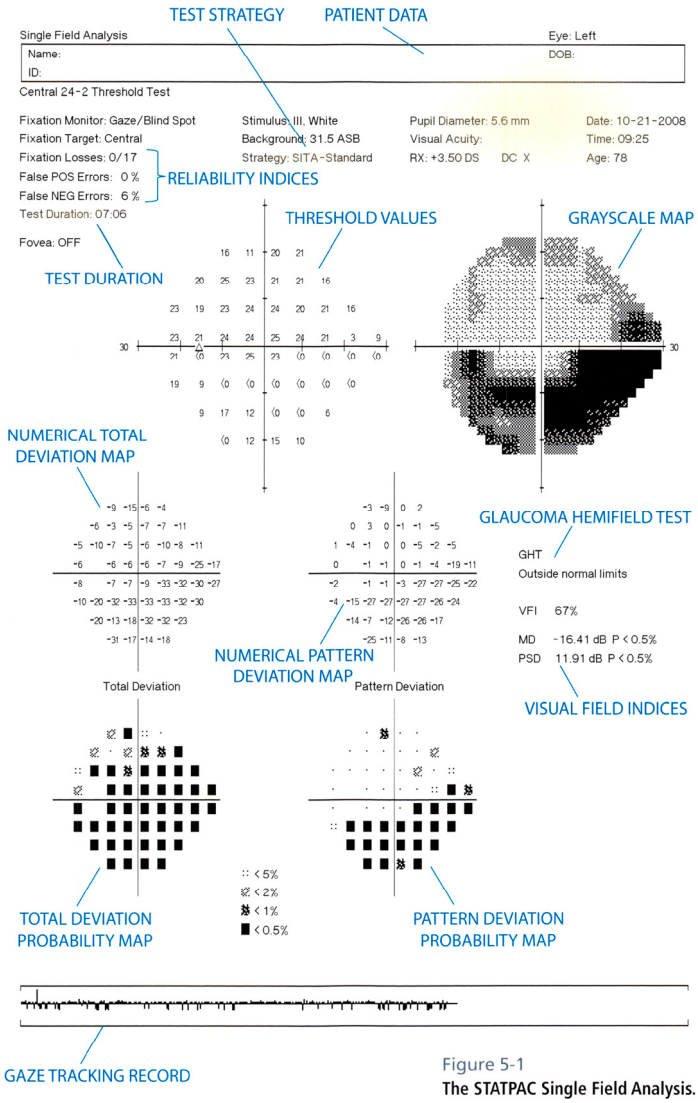

Figure 2. STATPAC single field analysis and its different components.
(Reprinted with permission of the authors, from the book entitled "Effective Perimetry, the Field Analyzer Primer, 4th ed. Heijl A, Patella VM, Bengtsson B. Carl Zeiss Meditec inc. 2012; Dublin, CA, USA.)

The Glaucoma Hemifield Test (GHT) was developed to detect the typical glaucoma field defects that affect nerve fibres in one of the hemispheres of the retina, in contrast to the nerve fibres in the opposite hemisphere that are usually asymmetrically affected (Åsman and Heijl 1992) (Fig 3).

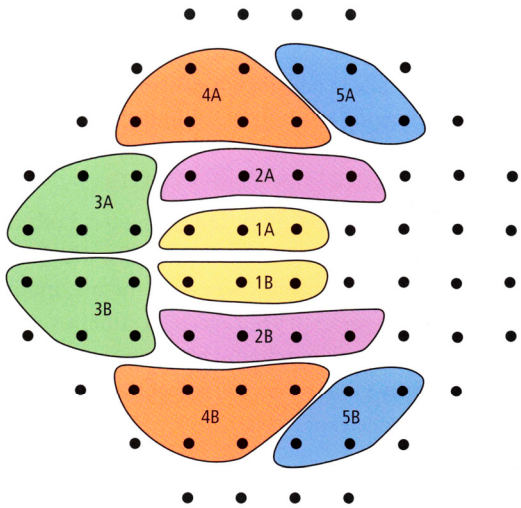

Figure 3. The different zones of the visual field compared over the horizontal meridian in the Glaucoma Hemifield Test.
(Reprinted with permission of the authors, from the book entitled "Effective Perimetry, the Field Analyzer Primer, 4th ed. Heijl A, Patella VM, Bengtsson B. Carl Zeiss Meditec inc. 2012; Dublin, CA, USA.)

The Guided Progression Analysis (GPA) software of the Humphrey perimeter can aid in both detection and quantification of progression by use of event and trend analyses. The event-based Glaucoma Change Probability (GCP) plots highlight changes from two baseline tests at individual test points where the change in measured sensitivities is larger than the test–retest variability in glaucoma patients (Bengtsson et al. 1997a) (Fig. 4). The trend-based Visual Field Index (VFI) is a global index that is designed to be less affected by cataracts compared to MD (Bengtsson and Heijl 2008), and it is also better correlated with ganglion cell density due to the higher weight assigned to paracentral test points (Fig. 5). PROGRESSOR is another software package that applies point-wise linear regression of threshold sensitivities over time to determine progression, (Noureddin et al. 1991), but it is not used as extensively as the GPA. The Swedish Interactive Threshold Algorithm (SITA) was introduced towards the end of the 1990s and now encompasses several testing strategies available in the Humphrey perimeter. These strategies were developed to shorten the time required to perform a visual field test (Bengtsson et al. 1997b; Bengtsson and Heijl 1998; Heijl et al. 2019).

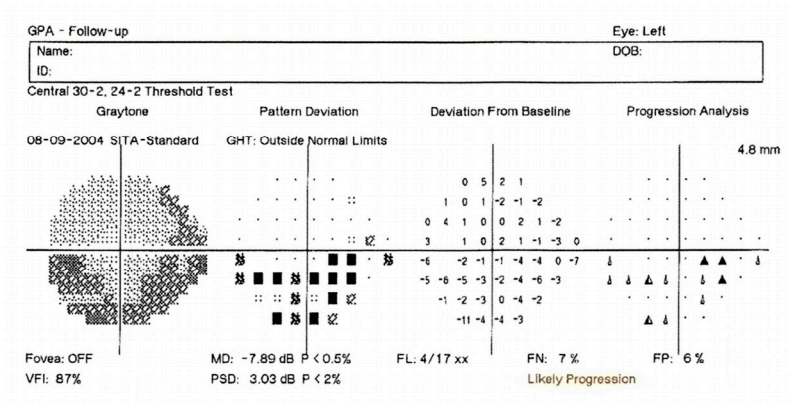

Figure 4. Glaucoma change probability plots.
The three black triangles in the progression analysis map indicate a significant deterioration in the same test points at three consecutive visual field examinations. (Reprinted with permission of the authors, from the book entitled "Effective Perimetry, the Field Analyzer Primer, 4th ed. Heijl A, Patella VM, Bengtsson B. Carl Zeiss Meditec inc. 2012; Dublin, CA, USA.)

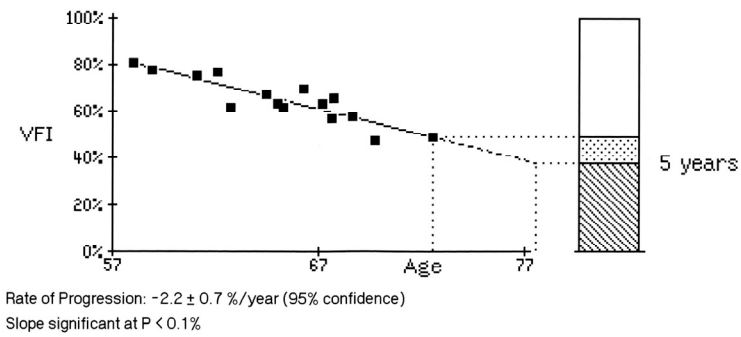

Figure 5. Visual Field Index (VFI) progression rate.
The black squares represent VFI results at each examination. The linear regression is projected to predict VFI results that will occur 5 years in the future if treatment remains unaltered. ((Reprinted with permission of the authors, from the book entitled "Effective Perimetry, the Field Analyzer Primer, 4th ed. Heijl A, Patella VM, Bengtsson B. Carl Zeiss Meditec inc. 2012; Dublin, CA, USA.)

In summary, MD and VFI are global measures used to describe the severity of glaucoma damage in relation to healthy eyes. The GHT is valuable for diagnosing glaucoma patients. The GCP is suitable for detecting a progression event, whereas the rate of change is best described by VFI rate of progression analysed through linear regression over the patient's age.

The large randomized treatment assessments called the Advanced Glaucoma Intervention Study (AGIS), the Collaborative Initial Glaucoma Treatment Study (CIGTS), the Early Manifest Glaucoma Trial (EMGT), and the Collaborative

Normal Tension Glaucoma Study (CNTGS) all used the full-threshold test of the Humphrey perimeter but with different criteria for visual field progression (Ederer et al. 1994; Leske et al. 1999; Musch et al. 1999; Anderson 1998; Collaborative Normal Tension Glaucoma Study Group 1998). In the AGIS and CIGTS, different scoring systems were applied based on the total deviation probability plots. In order to reach the visual field endpoint in both of these studies, a certain reduction in the score that was sustained in three consecutive tests was required. In CNTGS, the visual field endpoint was reached when a certain deterioration of threshold values within or adjacent to an existing scotoma occurred and was confirmed at subsequent visits. The EMGT used GCP plots to determine progression. This criterion also required changes to be confirmed in three consecutive tests, the same as the GPA alert implemented in the HFA. The EMGT criterion for visual field progression was found to have the highest sensitivity and a somewhat lower specificity than the criteria implemented in the AGIS and CIGTS (Vesti et al. 2003; Heijl et al. 2008).

Other modalities of perimetry are also available, such as short-wavelength automated perimetry, which attempts to selectively assess the function of a subpopulation of retinal ganglion cells with large receptive fields assumed to be lost early in the glaucoma process. This technique is more extensively affected by lens opacities, and longitudinal studies have not been able to demonstrate that it offers any additional advantages compared to regular white-on-white perimetry (Bengtsson and Heijl 2006; van der Schoot et al. 2010; Havvas et al. 2013). Frequency-doubling perimetry assesses the function of another type of retinal ganglion cells, and this technique is used mainly for screening purposes (Maddess 1992).

All perimetric testing requires that the patient can cooperate and focus, and these actions are often markedly enhanced by the instructions and support of the perimetrist and treating physician. A well-known learning effect occurs in some patients, and this must also be taken into consideration when assessing visual field results (Wild et al. 1989; Heijl and Bengtsson 1996).

Besides other similar automated perimeters, electroretinography is an entirely different method used to measure the functional capacity of the retina. The electroretinograph detects the electric potential created in the retina by a specific visual stimulus. Electroretinography is time consuming to perform and thus far has been used primarily for research on glaucoma patients (Wilsey and Fortune 2016).

Structural tests

With the introduction of the ophthalmoscope, it became possible to visualize the damage to the optic disc (also called the optic nerve head) that is associated with glaucoma. The initial drawings and descriptions were later replaced by photography, which allowed a more objective documentation of the optic disc damage. Despite this, interpreting the optic disc photographs is still subjective, and several studies have shown only moderate agreement between optic disc assessors (Azuara-Blanco et al. 2003; Jampel et al. 2009; Reus et al. 2010). Notwithstanding, this method is fairly easy to perform and is widely used to document structural changes in the optic disc. Detecting progression of glaucoma in the optic disc can be achieved by assessing changes in the nerve fibre rim of the optic disc, and this strategy predominantly entails searching for changes in the course of the blood vessels that pass over the optic disc rim (Varma 1993) (Fig. 6). It is preferable to obtain stereoscopic optic disc photographs, because this approach adds a sense of depth to the images, although it is difficult to apply this technique in a substantial proportion of the patients. It should also be noted that no convincing difference has been found between stereoscopic and regular optic disc photography with regard to the ability to make a correct judgment of the optic disc (Varma et al. 1992; Chan et al. 2014).

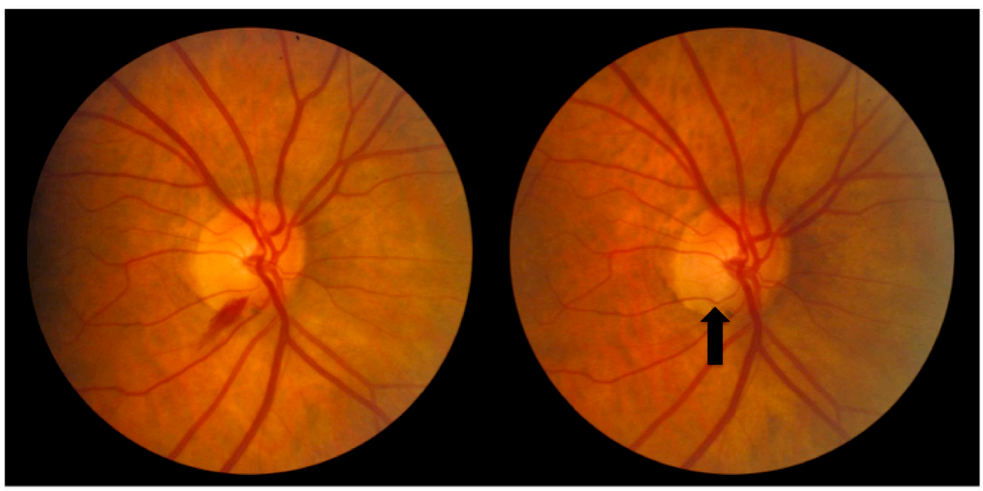

During the last few decades, several other imaging methods have emerged that use laser light to measure the retinal nerve fibre layer in or surrounding the optic disc. The confocal scanning laser tomograph creates a three-dimensional topographic map of the optic disc and the GDx-nerve fiber analyzer detects changes in polarization of the reflected laser beams in a scan circle around the optic disc. Both instruments have certain drawbacks and are not very common in clinical practice. Another widely used imaging method called optical coherence tomography (OCT) detects backscattering of the infrared laser light from retinal layers of different optical density (Fig. 7). This echo of light from the tissue is superimposed with that from a reference beam, and the superimposed waves create an interference pattern that is analysed (Fig. 8). Commercially marketed devices have been available since 1996 and utilize what is referred to as time-domain technology. Spectral-domain versions and swept-source versions are now also available and have increased the resolution and acquisition speed by Fourier transformation of the interference pattern, which allows simultaneous detection of the whole spectra of backscattered light. The swept-source and spectral-domain versions differ with regard to light source, optics, and photodetection. Several of the devices also include event- and trend-based progression analysis tools to facilitate assessment of retinal nerve fibre layer (RNFL) progression over time.

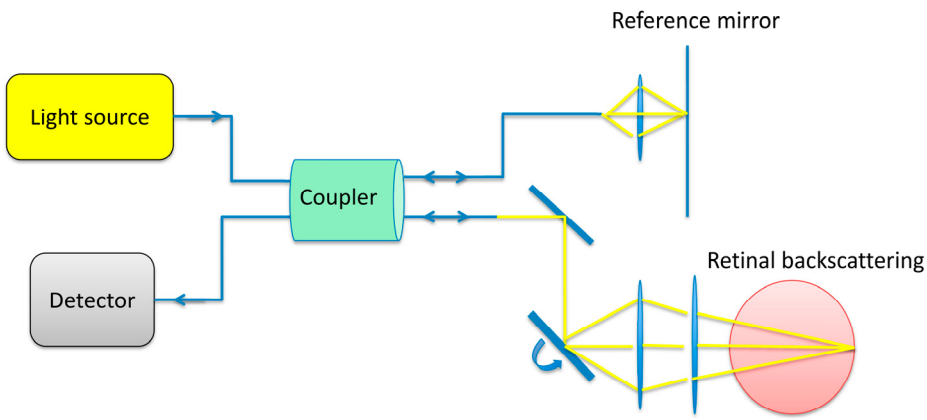

Figure 7. The principle of optical coherence tomography.
Laser light from the light source is split into two beams in the coupler, one of which is reflected by the reference mirror and the other by the retina. The two reflected beams create an interference pattern in the coupler that is registered by the detector and transformed into an axial scan.

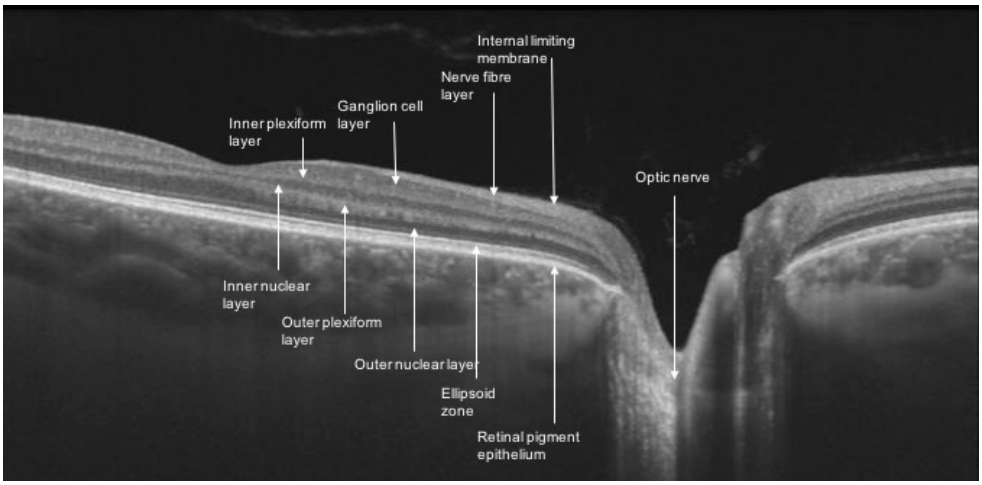

Figure 8. Optical coherence tomography of the retinal layers of a healthy eye.

It is now also possible to use swept-source or spectral-domain OCT to perform optic disc angiography. There are reports describing the correlation between glaucoma damage in the visual field and reduced blood flow measured with OCT angiography (Jia et al. 2014; Liu et al. 2015), although the temporal relationship between OCT angiography findings and visual field damage is yet to be determined.

AIMS

Paper I	To elucidate the temporal relationship between detection of progression by optic disc photography and automated perimetry in eyes with and without previous glaucoma damage of the visual field.
Paper II	To compare the earliest detection of glaucoma progression by automated perimetry and optic disc photography at different stages of the glaucoma disease.
Paper III	To assess how often a correct diagnosis was made during a few initial visits, when no knowledge of progression to confirm the diagnosis was available.
Paper IV	To evaluate the age-related change in retinal nerve fibre layer thickness measured by spectral-domain optical coherence tomography and compare it with the change that occurs in glaucoma patients over time, and also to assess the progression analysis performed with that instrument in the same groups.

SUBJECTS AND METHODS

The four papers included in this thesis were based on studies that were performed in accordance with the Declaration of Helsinki, and the subjects included in all the investigations provided informed consent for participation.

A correct diagnosis of glaucoma (Paper III)

A total of 147 eyes from the 117 patients who had completed 15 years or more of follow-up in the EMGT were evaluated in this study. Subjects had been recruited to the EMGT primarily through a population screening of individuals aged 56–76 years residing in the cities of Malmö and Helsingborg in Sweden. The criteria for a positive screening were suspicion of optic disc changes related to glaucoma including optic disc haemorrhages, an IOP above 25 mmHg, or glaucoma in a sibling.

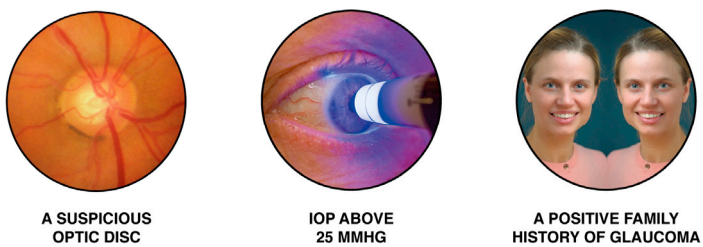

Figure 9. The different criteria for a positive screening for potentially elegible patients to the Early Manifest Glaucoma Trial.
Photographs by Johnny Ring

Due to the screening procedure, patients were diagnosed with earlier stages of glaucoma than would have been the case for self-selected patients in a glaucoma clinic. When a screening was positive, the subject in question was called back for an ophthalmologic examination including perimetry with the Humphrey 24-2 full threshold test. In such patients with no prior experience of perimetry, the diagnosis of glaucoma was based solely on either of the following two criteria:

1. A GHT classification of "outside normal limits" in the same area of the visual field in two consecutive tests.

2. A GHT classification of "borderline" in the same area of the visual field in two consecutive tests, if corresponding findings of the optic disc existed.

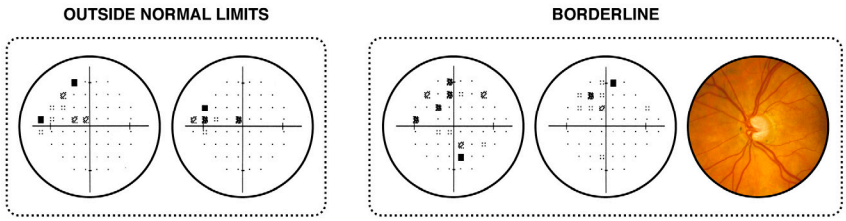

Figure 10. Glaucoma Hemifield Test classification for the diagnosis of glaucoma
Left: Test results showing "outside normal limits" in both tests. Right: A classification of borderline in both tests with glaucomatous optic disc findings.

The patients who entered the trial were subsequently examined regularly, chiefly at 3-month intervals, by optic disc photography and visual field testing. In the current study (Paper III), the diagnosis of glaucoma was confirmed when one or more of the following four criteria were met:

1. Visual field progression in a study eye during the follow-up period.

2. Development of visual field defects in a fellow eye that initially had a seemingly normal visual field.

3. Optic disc progression in either eye.

4. Optic disc haemorrhages in either eye.

To be able to determine whether visual field progression had occurred during follow-up, all of the Humphrey full-threshold tests in the entire series were assessed. The progression was confirmed if the following applied: GCP maps indicated "likely progression" at the third confirmatory visual field test, and the progression was sustained during the remaining follow-up period and was not caused by any other disease. The optic disc photographs were assessed in a masked fashion without knowledge of patient details. The 3-month photograph and the last available photograph were evaluated as a pair for signs of progression. The baseline photograph was disregarded because pressure-lowering treatment after randomization might have changed the appearance of the disc rim. The focus of the assessment was on any change in the course of the small vessels passing over the optic disc rim. This

evaluation was followed by a review of the whole series of photographs to confirm the progression at several visits after it was first observed, in order to minimize the risk of false positives caused by factors such as shifts in parallax. The few cases in which progression was detected during the review of the whole series, but was not perceived in the pair analysis, were also recorded as optic disc progression.

Comparing visual fields with optic disc photographs to detect progression (Papers I and II)

Of the original 255 patients included in the EMGT, six patients had to be excluded from the analyses because their follow-up time was too short to enable evaluation for signs of progression. The remaining 249 patients represented 306 glaucoma eyes and 192 fellow eyes without visual field defects at study inception. Median follow-up time was 8 years, and the maximum follow-up time was 11 years for the analyses reported in Papers I and II. A change in photographic technique in 2005 resulted in this limited follow-up time to enable a completely masked assessment of the optic disc photographs regarding the temporal order in the pair assessment of the first and last photograph in the series; such evaluation was possible only when the same camera technique had been used. Initially, three disc readers made individual assessments and noted the time point when a progression had occurred. The first author also scrutinized the entire series of photographs to ensure that no progression had been missed in the pairwise assessment. When one or more of the three disc readers noted a progression, the series was reviewed again in a joint assessment to reach consensus regarding if and when a progression had occurred.

The visual field criterion of the EMGT was used to determine visual field progression, which was stipulated as three or more points in the GCP maps having deteriorated in three consecutive fields. The above-mentioned method applied in the study reported in Paper III was used to ascertain that the progression criteria had been fulfilled due to glaucoma, and that the progression was sustained during the remaining follow-up time after the progression event.

The time until occurrence of the first type of progression (i.e., disc or visual field) was noted. Inasmuch as progression allowed the treating physician to introduce or alter the treatment and hence possibly delay further progression, only the method that identified progression first could be analysed. Cumulative incidences and competing risks were applied to describe by what method it was possible to detect progression first.

Three categories of fellow-eyes existed: normal appearing eyes, eyes with ocular hypertension (IOP > 21 mmHg), and eyes regarded as having pre-perimetric glaucoma due to glaucomatous findings in the optic disc. Sub-analyses were performed on these three groups. Glaucoma patients were also further analysed by dividing them into three different stages of the disease according to the Hodapp-Parish-Anderson scale (Hodapp 1993): mild, moderate, or advanced glaucoma, based on the MD value of the visual field at study inception.

OCT as a method to detect and measure progression (Paper IV)

In 2008, our research group had examined a cohort of healthy individuals residing in two primary care catchment areas in the province of Scania (Skåne) and a group of glaucoma patients attending the Ophthalmology Department at Skåne University Hospital (Bizios et al. 2011; Bengtsson et al. 2012). Different methods to detect glaucoma damage were evaluated during the ophthalmologic examination. These examinations included use of one of the first Cirrus-HD-OCT instruments available, as well as Humphrey SITA standard tests of the visual field.

Healthy individuals that were still alive in 2018 and not older than 80 years of age were reviewed. Those who had not acquired any known disease of the retina or other condition affecting the visual field function were invited to participate in a follow-up visit in 2018. At this visit, OCT scans of the optic disc and a visual field test on the Humphrey perimeter were repeated, together with a full ophthalmic slit-lamp examination including measurement of the IOP by Goldmann tonometry. Healthy individuals were excluded from the 2018 analysis, if they had developed glaucoma or any other condition since 2008 that prevented us from classifying them as healthy from an ophthalmologic perspective. Of the 95 subjects who were invited to take part in 2018, 69 were examined, and 58 of those subjects were included in the analysis.

The same examination was also performed again on the glaucoma patients in 2018, but those individuals were generally older and were invited to participate if they did not exceed 85 years of age. Of the 65 who were eligible, 49 were examined, and 35 could be included in the analysis. A separate analysis was also performed on a sub-group of glaucoma patients with MD values better than –10 dB, because previous studies had reported a floor effect in OCT measurements when this level of visual field damage had been reached.

The absolute mean change in circumpapillary retinal nerve fibre layer (cpRNFL) thickness was calculated, and the annual rate of change was assessed by linear regression.

An additional analysis of the ability of the software of the OCT instrument called Guided Progression Analysis (GPA) was performed. This assessment required two baseline examinations and two follow-up examinations. A few of the study subjects did not fulfil the required number of examinations, and thus only 56 of the healthy individuals and 27 of the glaucoma patients could be included in this analysis. The GPA identified new or worsening damage of the cpRNFL through three different analyses, and progression was indicated if the findings were confirmed in both of the follow-up scans (Fig. 11). The first analysis evaluated the whole 6 x 6 mm optic disc image, and progression was indicated if ≥ 20 adjacent superpixels had deteriorated more than the expected test–retest variability. The second analysis attempted to identify somewhat wider defects than the first analysis by appraising the cpRNFL profile from the circumpapillary scan circle to detect changes exceeding the variability limit. The third analysis identified more diffuse loss through linear regression of the total, superior, or inferior half of the cpRNFL thickness.

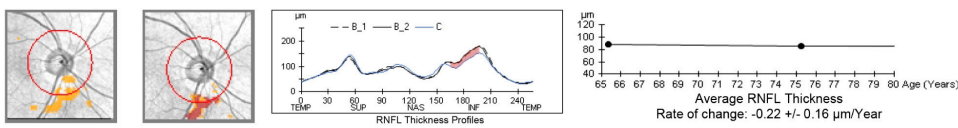

Figure 11. The Guided Progression Analysis of Cirrus HD-OCT.
Left: Two follow-up optic disc scans analysing change in adjacent pixels. Red areas indicate a thinning at both follow-up visits. Middle: An analysis of change in the cpRNFL profile, with change in both follow-up visits indicated in red. Right: Linear regression of the total cpRNFL thickness over time.

The number of progressions indicated by the three different progression analyses were evaluated separately for the healthy individuals, the glaucoma patients with MD better than –10 dB, and the group with MD –10 dB or worse. Specificity was calculated as the proportion of healthy eyes that did not show progression in any of the three progression analyses.

RESULTS

A correct diagnosis of glaucoma (Paper III)

During the median follow-up time of 19.7 years, 134 of the 147 glaucoma eyes exhibited visual field progression, demonstrated by fulfilment of the first criterion for confirmation of the initial glaucoma diagnosis. Among the remaining 13 eyes (9%) in 13 patients, five had confirmed visual field progression or development of manifest glaucoma with field loss. Also, two of the 13 eyes showed optic disc progression, and four exhibited optic disc haemorrhages.

Four of the 147 eyes did not fulfil any of the criteria to confirm the diagnosis of glaucoma. In two of those patients, another likely explanation for the observed field defect was found, and thus they were most probably incorrectly diagnosed. In the other two eyes, no other reasonable explanation for the field defect was found, and the diagnosis was deemed inconclusive (Fig. 12).

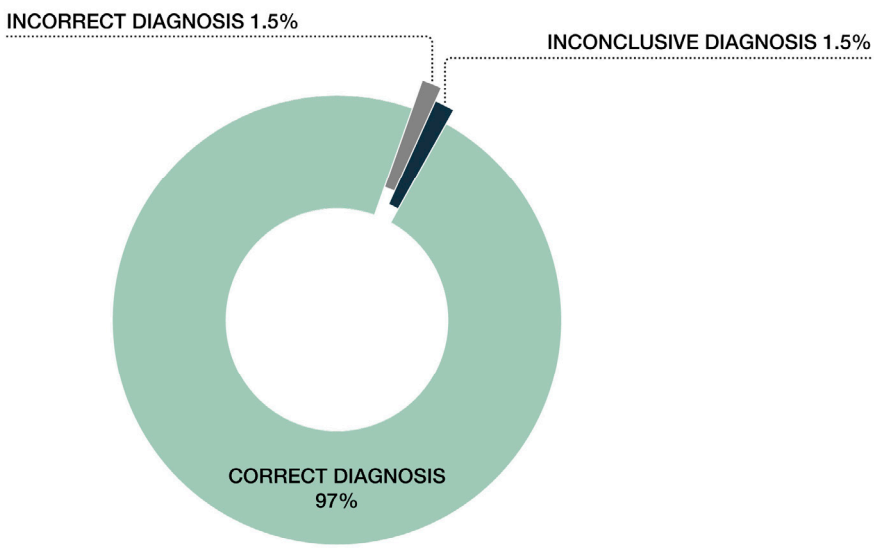

Figure 12. The distribution of correctly and incorrectly diagnosed patients after two initial visits.

In summary, a correct diagnosis was made in at least 97% of cases. This was possible using strict criteria for defining glaucoma at the first two clinical visits. When field findings were indefinite, they were backed up with structural findings.

Comparing visual fields with optic disc photographs to detect progression (Papers I and II)

The 192 fellow eyes without visual field defects at baseline exhibited the following: 60% had normal IOP and also seemed to have normal optic discs; 20% had ocular hypertension with an IOP above 21 mmHg; and 19% were classified as having pre-perimetric glaucoma with a glaucomatous optic disc appearance. Considering all 192 of the fellow eyes, an optic disc progression was noted first in 34 (18%), and a visual field progression was detected first in 28 (15%) (Fig. 13). Given that progression actually did occur, the conditional probability for optic disc progression to occur first was 55%, with no statistically significant difference compared to the conditional probability for visual field progression to occur first. Likewise, evaluating the three different sub-groups of fellow eyes (normal-appearing eyes, ocular hypertensive eyes, and pre-perimetric glaucoma eyes) did not result in any significant difference between the two methods either, as illustrated by Figure 3 in Paper I.

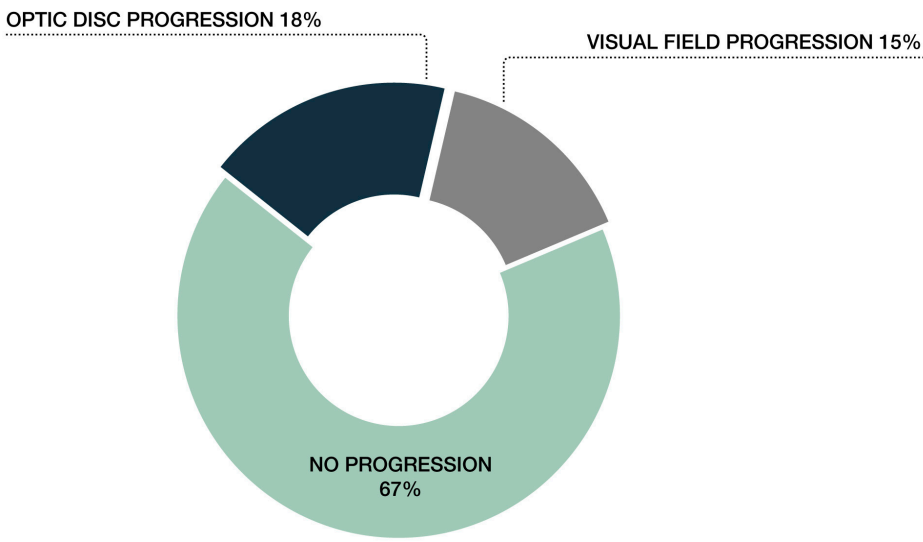

Figure 13. Proportions of progressions detected first by perimetry and optic disc photography in eyes with healthy visual fields at study inception.

Among the 306 study eyes with glaucoma, progression occurred first in the visual field in 163 (52%) and first in the optic disc in 39 (12%) (Fig. 14). The conditional probability for the first type of progression to be noted in the visual field was 81%, versus 19% in the optic disc, which was a statistically significant difference. These results are illustrated by Figure 2 in Paper I.

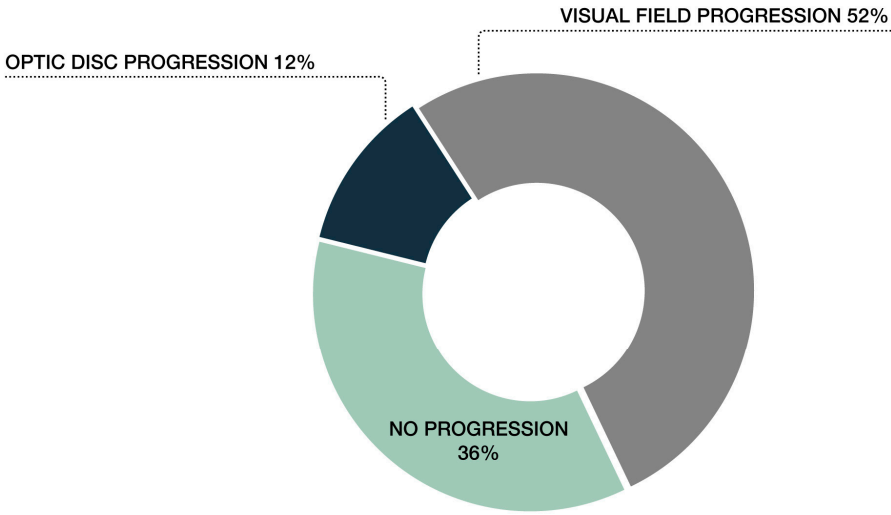

Figure 14. Proportions of progressions detected first by perimetry and optic disc photography among glaucoma eyes.

When glaucoma patients were analysed according to the severity of the disease, visual field examinations showed similar superior ability to detect progression first in all groups, as depicted in Figure 2 in Paper II.

OCT as a method to detect and measure progression (Paper IV)

Among the healthy subjects in this study, the cpRNFL thickness decreased by a mean of 0.10 µm/year (0.01%), although this result was not statistically significant. When all glaucoma patients were evaluated as a group, the cpRNFL thickness instead increased by 0.07 µm/year (0.01%). In contrast, for the patients with less severe glaucoma with an MD value better than –10 dB, there was a thinning of 0.21 µm/year (0.3%). As for the healthy subjects, the rate of change was not

statistically significant for either of the two glaucoma cohorts (Fig. 15). Furthermore, the rate of change in cpRNFL thickness was not correlated with the rate of change in visual field MD. Between the two visits, there was a substantial deterioration of –3.84 dB in the visual field for all glaucoma patients and –5.20 dB for the less affected glaucoma patients. With very few exceptions, the glaucoma eyes with more severe visual field defects almost exclusively showed thickening of the cpRNFL.

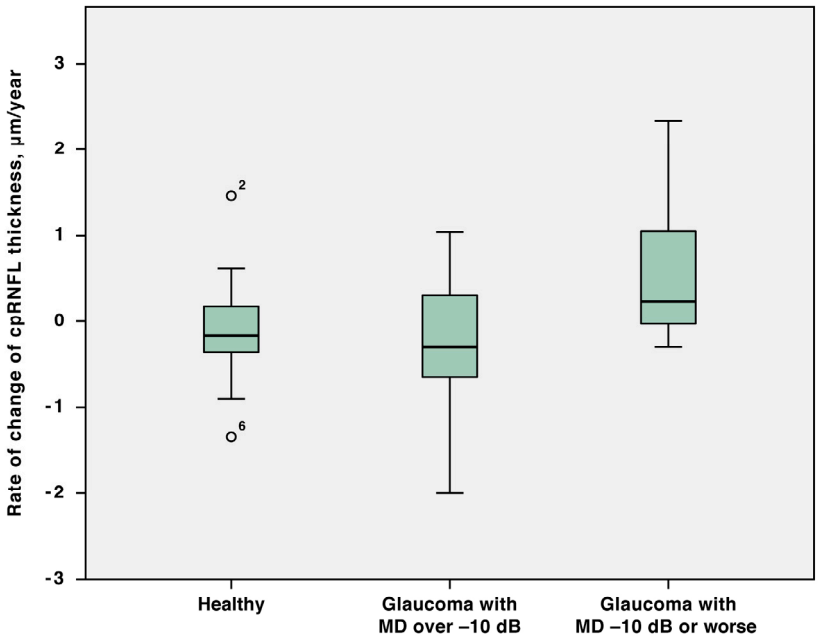

Figure 15. Rate of change of the circumpapillary retinal nerve fibre layer shown separately for apparently healthy eyes, less affected glaucoma eyes, and more severely affected glaucoma eyes.

When instead using a cross-sectional analysis of data from the 2018 visit, the results indicated a statistically significant small age-related deterioration of 0.33 µm/year ($p = 0.01$) that corresponded to a thinning of approximately 0.4%/year (Fig. 16).

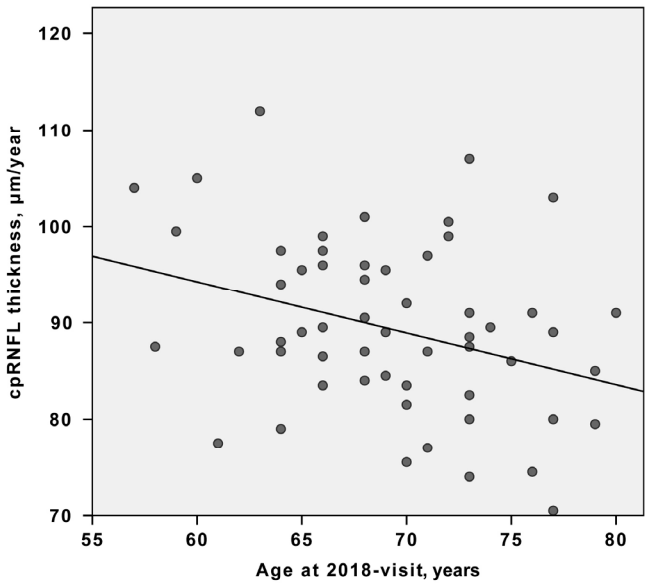

Figure 16. Cross-sectional analysis of the age-related thinning of the circumpapillary retinal nerve fibre layer.

The analyses performed using the GPA of the OCT instrument indicated that progression occurred slightly more often among the glaucoma patients compared with healthy individuals (Table 1). In 30% of the subjects with healthy eyes, at least one of the OCT analyses indicated likely progression.

Table 1. Progressions indicated by the progression analysis tool of the OCT instrument

PROGRESSION ANALYSIS	HEALTHY N= 56	ALL GLAUCOMA N= 27	GLAUCOMA >–10dB MD N = 17
ANALYSIS 1, PIXELS	23%	33%	35%
ANALYSIS 2, cpRNFL PROFILE	13%	22%	29%
ANALYSIS 3, LINEAR REGRESSION	21%	37%	34%

DISCUSSION

One objective of the research underlying this thesis was to evaluate the ability to correctly diagnose primary open-angle glaucoma after two initial visits (Paper III) and the results showed that with strict diagnostic criteria there were very few false-positive diagnoses. Another objective was to compare different methods used to detect and measure progression of this disease (Papers I, II, and IV). Visual field examinations was the preferred method to detect progression compared to optic disc photography in glaucoma patients, whereas both methods were of value for patients without established glaucoma damage of the visual field. The results did not support the use of OCT for monitoring glaucoma patients, as the rate of change of cpRNFL thickness did not differ significantly from the rate of change in healthy individuals. Also, the automated progression analysis tool of the OCT instrument gave high rates of false positives.

A correct diagnosis of glaucoma (Paper III)

Numerous studies have explored the diagnostic capacity of various methods used to detect glaucoma and most of those investigations have been designed to compare results on healthy individuals and patients with established glaucoma (Budenz et al. 2002; Sehi et al. 2009; Bengtsson et al. 2012; Leung et al. 2012; Sung et al. 2012). Attempts have been made to combine data from different modalities, in some cases with the aid of machine learning classifiers, to improve the diagnostic capabilities (Bowd et al. 2008; Bizios et al. 2011; Russell et al. 2012; Christopher et al. 2018). In a recent study (Orlando et al. 2019), automated algorithms were developed to classify optic disc photographs, and the results obtained were promising. An issue with all such cross-sectional methods when considering glaucoma is that there is no "gold standard" available for comparison with the results of a particular test. A comparison of obvious glaucoma cases and healthy individuals will yield very good discriminative results for the technique being tested, unless that method performs extremely poorly. However, it is difficult to assess results for patients with very discrete findings in the earlier stages of glaucoma. For example, a patient with early signs of glaucoma can have abnormal results in one particular test but demonstrate normal results in the test used as a reference standard. Therefore, it is impossible to ascertain whether this

represents a false-positive result or is in fact a correct identification of early glaucoma damage, unless the patient is followed over a period of time to confirm the diagnosis by detecting progressive damage, preferably by a reference method. However, inasmuch as progression of glaucoma can be a very slow process in some individuals, this approach could take many years (Anderson et al. 2001; Heijl et al. 2013; Chauhan et al. 2014). In routine clinical care, treatment is often initiated as soon as there is a strong suspicion of glaucoma in order to preserve as much visual function as possible. Still, for the less severe cases, the diagnosis is generally not considered certain until signs of progression have been documented (Weinreb and Greve 2004; Stamper et al. 2009).

Patients included in the EMGT represented newly diagnosed cases that were identified mainly through a population screening. Therefore, it was possible to evaluate how often an initial diagnosis of open-angle glaucoma that was based on reproducible findings but without any follow-up data was indeed correct, and this could be achieved by confirming or rejecting the diagnosis with the presence or absence of subsequent progression during the long follow-up time. This approach was feasible because of the unique follow-up time of up to 20 years, which included regular examinations throughout the entire period. According to our results, the diagnosis of glaucoma was almost always correct, if it was based on two visual fields with either a GHT classification of "outside normal limits" in the same sector or a GHT classification of "borderline" if reciprocal optic disc findings existed. The GHT was designed to detect visual field changes typical of glaucoma with good sensitivity and specificity, as observed in a cross-sectional analysis (Katz et al. 1991; Åsman and Heijl 1992). Again, when applying any test to a general population or other individuals at increased risk of developing glaucoma, the specificity is often not as satisfactory (Katz et al. 1996; Keltner et al. 2000). Therefore, in such instances, it will not suffice to rely solely on a single GHT result, but will also always require confirmation of the finding by at least one additional visual field examination. Moreover, it is wise to rule out other possible reasons for the abnormal test result (e.g., drooping eyelids and trial lens rim artefacts), and Wang and co-workers demonstrated a number of false positives if this was not taken into consideration (Wang et al. 2018). Our results apply to individuals who were able to produce reliable visual field results. However, in general, there is always a small fraction of individuals who are unable to perform visual field examinations, even if they are given comprehensive instructions and support from the perimetrist.

The mere establishment of a glaucoma diagnosis has been shown to affect the patient's quality of life (Odberg et al. 2001; Quaranta et al. 2016). Overall, incorrect diagnoses also entail unnecessary costs for both the glaucoma patients and society in general (Varma et al. 2011). Accordingly, it is of the utmost importance to be able to achieve early and correct diagnosis of the disease at the initial clinical visits.

Different methods to detect glaucoma progression (Papers I, II and IV)

It is imperative to detect glaucoma progression when establishing a definite diagnosis for patients being followed due to predisposing factors. It is also necessary to measure the rate of progression in order to determine whether escalation of treatment is required.

Several studies have noted that there is poor correlation between different methods used to detect progression in glaucoma patients (Artes and Chauhan 2005; Strouthidis et al. 2006; Hudson et al. 2007; Leung et al. 2011; Na et al. 2012; Lee et al. 2013; Nguyen 2019). This incoherence among test results is a complicated issue when attempting to assess the diagnostic capability of different methods, and also when evaluating different methods to detect and measure glaucoma progression during follow-up. Guidelines recommend that the goal of treatment be to maintain the patient's visual function and quality of life (European Glaucoma Society 2014; Heijl et al. 2010). If progression detected by a structural method does not necessarily correlate with a deterioration of the visual field, it makes it rather difficult to assess the implication of that test result for the individual patient.

On the other hand, if glaucoma changes could be detected with high specificity before the occurrence of visual field defects, that would represent a very attractive alternative. Diagnosing glaucoma and initiating treatment at an early stage before functional damage occurs could even further reduce the risk of the disease affecting the quality of life during the patient's lifetime. Indeed, several previous investigations have reported that it is possible to detect structural changes before any visual field damage is visible in a substantial proportion of patients. (Mohammadi et al. 2004; Miglior et al. 2005; Keltner et al. 2006; Medeiros et al. 2009; Weinreb et al. 2010; Schrems-Hoesl et al. 2014)

Several large randomized trials have used optic disc photography and visual field examinations to detect progression as a means of diagnosing glaucoma in patients with ocular hypertension. The Ocular Hypertension Treatment Study (OHTS) was designed to determine whether use of topical hypotensive eye drops in patients with raised IOP would lower the risk of developing glaucoma (Gordon and Kass 1999). After 6 years of follow-up, progression was noted to occur first in the optic disc in 55% of eyes, first in the visual field in 35% of eyes, and simultaneously in the optic disc and visual field in 10% of eyes (Kass et al. 2002). A later paper on the OHTS considered patients with 8 years of follow-up who had at some point in time developed changes according to both tests, and it was noted that 41% had visual field changes first, and 29% had changes in the optic disc first (Keltner et al. 2006). The European Glaucoma Prevention Study (EGPS) also followed patients with ocular

hypertension and evaluated the risk of developing glaucoma when treated with a specific hypotensive eye drop versus placebo; conversion to glaucoma was seen first in the visual field among 60% of the subjects, and in the optic disc photographs before the visual fields in 40% (Miglior et al. 2005). These results are similar to our findings in fellow eyes without visual field defects at the start of the study. Medeiros and co-workers also performed a prospective observational study on patients suspected of having glaucoma over a period of 8 years; the results showed that 15% developed visual field damage during follow up, and 66% of those patients had had prior visible progression of the optic disc (Medeiros et al. 2009). The variability in the results of these studies reflects how only slight differences in the way such methods are implemented can lead to variations in the percentage of end-points.

Similar to the EMGT, other randomized clinical trials that included manifest glaucoma patients have also used optic disc photography and perimetry to detect progression. One of those investigations was the CNTGS (Collaborative Normal Tension Glaucoma Study Group 1998), the aim of which was to investigate the possibility of preventing progression in glaucoma patients with IOP within normal limits by lowering the pressure even further. In 11% of progressing eyes, the deterioration was noted only in the optic disc, which is in line with our findings among glaucoma patients.

The widely available conventional method of optic disc photography requires a subjective assessment and the interobserver agreement is unsatisfactory (Azuara-Blanco et al. 2003; Jampel et al. 2009; Reus et al. 2010). Moreover, assessing photographs to diagnose glaucoma or to detect progression requires extensive training (Andersson et al. 2011). An advantage of disc photography is that it offers the opportunity to compare changes over long periods of time, regardless of the photographic equipment used or continual development of the technique.

There are expectations that imaging methods such as OCT can be both objective and sensitive for detection of early glaucoma damage. Several studies have observed good correlation between structural progression and subsequent progression of the visual field (Leung et al. 2011; Miki et al. 2014; Kuang et al. 2015; Yu et al. 2016), but, despite some promising results, there are also several issues that need to be addressed. In OCT, artefacts are common, and these should be considered before deciding whether the test results are reliable (Ho et al. 2009; Asrani et al. 2014; Chen and Kardon 2016). Cataracts, corneal opacities, corneal oedema, or other optical obstacles can make it difficult to acquire any useful scans. Newer OCT instruments are not backward compatible, which complicates longitudinal follow-up when a change of the OCT instrument is necessary. Furthermore, it is possible that measurements of the RNFL are affected by several other rather common systemic conditions, such as diabetes mellitus, severe hypertension, and perhaps also Parkinson's disease and

Alzheimer's disease (Ahn et al. 2014; Safi et al. 2018; Nunes et al. 2019). It is assumed that the RNFL becomes thinner with age, but longitudinal OCT measurements of the RNFL are not corrected for age. Histological studies (Dolman et al. 1980; Gao and Hollyfield 1992), cross-sectional studies (Girkin et al. 2011; Knight et al. 2012; Demirkaya et al. 2013; Chaglasian et al. 2018), and longitudinal studies (Leung et al. 2013; Vianna et al. 2015; Hollo and Zhou 2016; Zhang et al. 2016; Hammel et al. 2017) have been performed to investigate the effect of aging on the RNFL. Most of those assessments have suggested a certain impact of age, and several of them were unable to find a statistically significant difference compared to the rate of change among glaucoma patients. The different methods applied in this context have their own limitations. For histological studies, the number of available study subjects is low. On the other hand, cross-sectional studies can include a large number of individuals of different age, but they entail many confounding factors, such as innate RNFL thickness, axial length, and different ethnicities, which cause very large dispersion of values and thus result in wide confidence intervals. Many of these confounding factors are not a problem in longitudinal studies, but subjects included in such investigations can, for instance, develop cataracts, diabetes mellitus, and corneal changes that also affect RNFL measurements. There is still no universal agreement on how to handle the issue of age correction. Considering that it was possible to reach statistically significant results when our data collected in 2018 were instead analysed in a cross-sectional fashion, even if the number of included individuals was limited, it seems that cross-sectional analyses would be the preferable approach for assessment of age-related thinning of the RNFL despite the confounding factors. Our cross-sectional results concur with the findings of other cross-sectional studies that have shown an age-related decay of the cpRNFL of approximately 0.2–0.5%/year (Leung et al. 2012; Hollo and Zhou 2016; Zhang et al. 2016; Hammel et al. 2017). The studies claiming that OCT imaging is more sensitive than optic disc photography in detecting progression may be correct, but it is not an easy task to deduce how many of the progressions detected by OCT are actually false positives.

Another issue related to OCT is that although this method is claimed to measure the thickness of the RNFL, there are a variety of different cells, blood vessels, and extracellular supportive tissue that also contribute to the RNFL measurements. Consequently, the RNFL thickness measurements do not exclusively represent the ganglion cells and associated axons that are proposed to be affected in glaucoma.

A floor effect has also been demonstrated in several earlier reports and was clearly apparent in our results as well (Chan and Miller 2007; Hood and Kardon 2007; Mwanza et al. 2015; Moghimi et al. 2019). When visual field progression occurs, no further tinning of the RNFL can be measured by OCT when the floor is reached, even though, logically, ganglion cell nerve fibres ought to perish during the entire process. This is also another limitation in the use of OCT for longitudinal follow-up

of glaucoma patients, because the floor is already reached when around one third of the visual field is lost. Recent studies have indicated that it might be possible to avoid the floor effect by measuring blood vessel density in the fovea with OCT angiography, but this method is still fairly unproven for glaucoma follow-up (Moghimi et al. 2019). Another possibility might be to measure the ganglion cell-inner plexiform layer (GCIPL) complex in macula scans (Belghith et al. 2016; Bowd et al. 2017; Shin et al. 2017), although assessment of glaucoma in such scans is complicated by age-related macular degeneration, which is another common co-existing condition (Garas et al. 2013).

In relation to the basic economic principle of scarcity and opportunity cost, health care resources are by definition scarce. Therefore, choices must be made between different methods for examining glaucoma patients, so that we provide the best possible care for the individual and at the same time make health care resources available to as many people as possible, especially when considering the large group of glaucoma patients in need of ophthalmologic care. Thus it is imperative to compare the different techniques that are available for detecting and measuring glaucoma progression in order to select the optimal method for each individual patient.

Future perspectives

Exploring the actual causes of glaucoma is fundamental in understanding the disease and thus a key to how we manage these patients. Until this enigma is resolved, research must also focus on how we treat, diagnose, and monitor glaucoma patients.

Future studies on the diagnostic capacity of different methods should preferably include longitudinal data to confirm the diagnosis of glaucoma, with the whole spectra of disease severity represented in included individuals. This is the only way by which the true sensitivity and specificity of each method can be accurately assessed.

In one of our studies we described that the OCT progression analysis tool indicated a high number of false positives. It would be suitable to confirm these findings in a larger longitudinal study of healthy individuals, preferably with several regular visits. Furthermore, it would be of interest to see if our finding could be confirmed that the more severe glaucoma patients rather exhibited a thickening of the cpRNFL over time.

There is still no consensus on how to adjust for age-related thinning of the cpRNFL. Even though cross-sectional studies have many confounding factors with large dispersion, the advantages of including many individuals with a large variation in age seem to be the preferred method.

The OCT technique is continuously evolving and new types of analyses of the different structural components of the retina have emerged. Further explorations are needed before these parameters might be considered for clinical care as tools for assessing glaucoma progression. A deeper knowledge is necessary regarding measurement variability, how they relate to visual field changes, and their ability to measure change during different stages of glaucoma.

Machine learning algorithms provide new possibilities in assisting clinicians to diagnose glaucoma and monitor its progression. While these methods have shown promising results in a number of studies, further research is required to construct automated diagnostic systems that can explain their decisions and to evaluate their performance in new clinical datasets.

CONCLUSIONS

In 97% of cases of glaucoma, a correct diagnosis of the disease should already be possible after the two initial clinical visits. To accomplish this would require that a GHT classification of "outside normal limits" in the same area of the visual field be noted in two consecutive tests. Alternatively, a classification of "borderline" would suffice for diagnosis, if optic disc findings are present. Obviously, other potential causes of the visual field defect must also be excluded, and another prerequisite is that the patient is able to provide reliable visual field results. With this comprehensive approach, there is very little risk of making a false-positive diagnosis, which clearly reduces the risk of over-diagnosing and over-treating glaucoma patients.

When following eyes without documented damage in the visual field, optic disc photographs and visual field tests are equally efficient in finding the first sign of progression. In eyes with visual field damage, regardless of the level of glaucoma damage present, progression can be identified earlier by the visual field tests than by optic disc photographs more than four times as often.

It was not possible to ascertain the effect of aging on OCT measurements. The more advanced glaucoma patients exhibited a thickening of the cpRNFL over time, whereas the less advanced glaucoma patients showed faster deterioration compared with healthy individuals. However, the absolute value for the rate of change was small, and it did not reach statistical significance, despite the long time interval between visits and the substantial deterioration of the visual field in many patients. Also, the automated progression analysis tool of the OCT instrument gave high rates of false positives. Together, the mentioned results illustrate that using OCT for monitoring glaucoma patients is not a straightforward approach.

POPULÄRVETENSKAPLIG SAMMANFATTNING

Bakgrund

Glaukom kallas också för grön starr och orsakerna till ögonsjukdomen är inte helt klarlagda. Den leder till en förlust av nervceller i ögats näthinna som lämnar ögat via synnerven och detta orsakar irreversibla synfältsskador. Diagnosen fastställs genom att hitta förtunningen av nervfiberlagret i synnervshuvudet och i näthinnan, eller genom att mäta den förlorade funktionen i synfältet. När sjukdomen är diagnosticerad leder detta till livslång behandling och uppföljning. Glaukom är globalt sett den vanligaste orsaken till irreversibel blindhet och orsakar betydande synhandikapp där en av sex patienter blir blinda inom sin levnadstid. Gruppen glaukompatienter utgör en fjärdedel av patienterna på Sveriges ögonmottagningar. Förhöjt ögontryck är en riskfaktor för att utveckla sjukdomen, men ingår inte i definitionen av sjukdomen då cirka hälften av individerna med glaukom har ett tryck inom de statistiska normalvärdena. En stor andel av de med förhöjt ögontryck utvecklar heller aldrig glaukom. I tidigare stadium av glaukom kan det vara svårt att ställa rätt diagnos. Det är då inte ovanligt att det saknas den typiska kombinationen av synfältspåverkan och förändringar i synnerven som man oftast hittar hos mer allvarliga glaukomfall. Rekommendationen är att försöka upptäcka förekomst av försämring med någon av de undersökningsmetoder som används under uppföljningen för att bekräfta diagnosen. Dock inleds ofta behandling redan vid stark misstanke om glaukom, då man vill påbörja behandling så snart som möjligt för att försöka undvika en alltför stor skada i patientens synfält under dennes livstid. Det saknas dock säkra diagnoskriterier för patienter med tidiga glaukomskador.

Behandlingen av glaukom går ut på att med olika metoder sänka ögontrycket, då man visat att även patienter med normala trycknivåer har nytta av trycksänkande behandling. Sjukdomsförloppet är dock mycket varierande där vissa patienter försämras långsamt medan andra försämras snabbt. Glaukom kan inte botas, men trycksänkande behandling kan bromsa eller helt stoppa sjukdomsförloppet. Alla typer av behandlingar medför dock risk för biverkningar eller komplikationer och även kostnader för patienten och samhället. Eftersom de drabbade i genomsnitt har förlorat

halva synfältet i ena ögat innan de själva söker vård, och de diagnosticerade patienterna har svårt att upptäcka fortsatt försämring av sin sjukdom, är det avgörande att sjukvården har bra metoder för att upptäcka och mäta försämringshastigheten hos varje individ. På så sätt kan man avgöra vem som har nytta av att påbörja eller öka den trycksänkande behandlingen.

Det finns olika metoder för att upptäcka försämring av glaukom. Datoriserade synfältsundersökningar har länge utgjort en grundstomme i uppföljningen av dessa patienter. Fotografier av synnervshuvudet där man bedömer brämet av nervfibrer inne i synnervshuvudet har också varit en möjlighet för att följa de strukturella förändringarna, men en mer objektiv bedömning genom olika datoriserade metoder för att mäta nervfibrerna i synnervshuvudet eller nervfiberlagret i näthinnan har också tillkommit. Dessa mäter tjockleken på nervfiberlagret med hjälp av laserljus som reflekteras mot näthinnan och synnervshuvudet. Optisk koherens tomografi (OCT) är den vanligast förkommande tekniken som används idag. Den liknar tekniken för ultraljud men använder sig av infrarött laserljus istället för ljud, vilket ger en högre upplösning av näthinnans olika lager, på bekostnad av att ett grundare djup av vävnaden avbildas. Det råder oenighet om vilka metoder som skall användas för att snabbast och säkrast upptäcka en försämring i sjukdomen och huruvida strukturella eller funktionella förändringar kan detekteras först. Idag rekommenderas att man undersöker både synfält och avbildar synnervspapillen under hela den livslånga uppföljningen, vilket i praktiken ofta fallerar. Resurserna för sjukvården är som alltid begränsade och i dagsläget hinner många ögonmottagningar inte med glaukomkontroller i den takt och omfattning som rekommenderas varför en effektivisering av dessa kontroller skulle ge stora möjligheter till att förbättra vården för glaukompatienter.

Syfte

Det övergripande syftet med denna avhandling var att utvärdera hur ofta man kan ställa en korrekt diagnos vid de inledande kliniska besöken samt att jämföra olika metoder att upptäcka försämring under uppföljningen av patienter med olika grader av glaukomskada.

Projektbeskrivning och resultat

De tre första arbetena baserades på material från studien ”The Early Manifest Glaucoma Trial” (EMGT), en studie som har pågått i Malmö och Helsingborg med en uppföljningstid på upp till 20 år. De 255 nydiagnostiserade glaukompatienter som

inkluderades i studien identifierandes huvudsakligen genom en screening av befolkningen. Patienterna undersöktes regelbundet med både datoriserade synfältsundersökningar och fotografier av synnervshuvudet. Studiens primära mål var att undersöka effekten av ögontryckssänkande behandling. Denna fråga besvarades 2002 och visade att behandlingen hade mycket god effekt.

Förmågan att ställa rätt diagnos redan efter de två inledande kliniska besöken undersöktes i arbete III. Vid dessa besök fanns inte någon vetskap om förekomsten av försämring för att bekräfta sjukdomen. Glaukom konstaterades med hjälp av strikta synfältskriterier, och om synfältsfynden var tveksamma krävdes också förändringar i synnervshuvudet som stämde överens med sjukdomen. Diagnosen bekräftades eller förkastades sedan beroende på om det förekom tecken till försämring i sjukdomen eller ej under den långa uppföljningstiden, vilket anses vara det säkraste sättet att bekräfta att patienten verkligen har glaukom. Man kunde då dra slutsatsen att diagnosen blev korrekt redan efter de inledande besöken med dessa diagnoskriterier i hela 97 % av fallen.

I arbete I och II jämförde vi förmågan att först upptäcka en försämring i sjukdomen genom regelbundna synfältsundersökningar respektive fotograferingar av synnervshuvudet. Hos de ögon som ännu ej utvecklat några synliga tecken till glaukom sågs det första tecknet till försämring lika ofta med hjälp av båda dessa metoder. Däremot, när synfältsskador redan hade konstaterats, var det mer än fyra gånger så vanligt att det gick att upptäcka fortsatt försämring i synfältet före någon synlig försämring i synnervshuvudet. Den överlägsna förmågan att detektera försämringar genom synfältsundersökningar sågs oavsett hur stora synfältsskador som redan fanns hos patienten.

I arbete IV undersökte vi år 2018 på nytt samma personer som hade undersökts år 2008, friska individer och glaukompatienter, med bland annat OCT och synfältsundersökningar. Detta med syftet att utvärdera effekten av det naturliga åldrandet respektive försämring i glaukomsjukdomen på näthinnans nervfiberlager.

Resultaten visade inte någon säkerställd förtunning av nervfiberlagret på grund av naturligt åldrande. Det gick heller inte att uppmäta någon säkerställd skillnad jämfört med glaukompatienter, men vi såg en tendens till något högre grad av förtunning hos de tidiga glaukomfallen, och hos glaukompatienterna med mer uttalad synfältsskada sågs istället nästan uteslutande en förtjockning av näthinnan. Det inbyggda beslutsstödet i OCT-instrumentet signalerade felaktigt för försämring av sjukdomen hos 30 % av de friska individerna.

Slutsatser

Det går att ställa en korrekt glaukomdiagnos redan vid de inledande kliniska besöken om strikta diagnoskriterier används. När man följer patienter över tid bör man prioritera synfältsundersökningar, men fotografier av synnervshuvudet kan också vara av värde om synfältet i det aktuella ögat inte redan har blivit påverkat. Våra resultat stödjer inte användandet av OCT för uppföljning av glaukompatienter då man inte kan se någon säker skillnad i förändring av nervfiberlagrets tjocklek mellan patienter och friska individer över tid. OCT-instrumentets beslutsstöd för att upptäcka försämring av sjukdomen gav en oacceptabelt hög andel falskt positiva utfall.

ACKNOWLEDGEMENTS

I am forever thankful to the many people who have in various ways supported me in my quest. I would especially like to express my gratitude to the following:

Boel Bengtsson, my main supervisor. Thank you for guiding me all the way to this doctoral thesis with so much enthusiasm and wit, for being so accessible at all times and bringing all your experience and profound knowledge into every scientific discussion. You are a scientist's role model.

Anders Heijl, my co-supervisor. Thank you for hiring me in the first place, and for never giving up on me during my endless trials in becoming a scientist. Your experience and scientific reasoning have been invaluable. Thank you also for ploughing the road to glaucoma research long before I even knew glaucoma existed, and for providing me with such excellent material to work with.

Johnny Ring, for saving my ass when the computer said no, for your pleasant ways with our study subjects, and for your sense of the figurative that makes everything look better.

Catarina Villalba, for your admirable personality and for being such an excellent perimetrist. Having good-quality data to work with is invaluable.

Kristina Johansson, **Lena Rung, & Anette Lindström,** all Heads of the Department. Thank you for standing firm to make our department a better place, and for doing that with so much sense and sensibility. You make our workplace feel like a second home.

Vesna Ponjavic, our Director of Studies. Your wilful organizing skills are impressive. Thank you for your endless endeavours to achieve optimal education of us residents.

Sigridur Oskarsdottir, my roommate and friend. We started out on this adventure together on the 27th of September 2010. Thank you for being so supportive during both struggles and achievements during all these years, and for being such an awesome companion at medical congresses. You have taught me that the streets of Florence can be trampled barefooted.

The rest of the glaucoma research team, **Dimitrios Bizios, Dorothea Peters, Sabina Geimer Andersson, Johan Aspberg, & Jesper Hougaard.** Thank you for the joy and humour you all bring to the research team, and for the brain capacity and scientific reasoning you all generously contribute with. You make me proud to be a part of our group.

All the **staff and colleagues at the Ophthalmology Department at Skåne University Hospital.** Thank you for making this such an enjoyable workplace, despite all the arduous tasks and obstacles that are thrown in our direction.

Monika, Elin, Mikael, Linna & Nils for your invaluable help with proof-reading.

Patricia, thank you for excellent language editing.

To my dearest **friends**, you are the best possible companions whether time is spent in the sauna, at a restaurant, hiking, starving, night swimming, living the gaucho culture, dancing on empty dance floors, skiing, in prohibition bars, asking the langos salesman about Lara Croft, surviving in thin air, or simply discussing the conditions of the life that we are given.

My loving parents, **Inger & Leif.** Thank you for your care and support. For always believing in me, for making me perform to the best of my ability and at the same time recognize my own value regardless of my achievements. Thank you for showing me places and people, and for teaching me how to enjoy life.

My brother, **Mikael.** Thank you for being a dear friend during our upbringing, despite the disputes at the breakfast table and pillow fights in the back seat. Without you, my childhood would have been a lot paler. Your thoroughness as a dentist and surgeon is inspiring.

My grandparents, **Gulli & Rune, Ranghild & Nils.** I appreciate your love and care, and thank you for bringing perspectives into my young ignorant mind, and for being such inspirational members of our society.

My mother-in-law, **Ingrid,** for helping out with our children when there wasn't enough allotted time.

My beloved children **Iris, Otto, Estrid, & Ingrid.** Thank you for all your unconditional love, despite my sometimes absent-minded ways during this process. I hope that you will be able to grow up to love life and gain the knowledge to learn that you know too little about everything. You are my true pride and joy.

Nils, my love, my companion, my inspiration, my "luce". Thank you for compensating for my weaknesses and for always supporting and believing in me even when research got the best of me. Your reasoning, structure and thoughts have been extremely valuable. Thank you also for being such an admirable father to our children and for providing the best possible ground support during this period.

REFERENCES

AHN SJ, WOO SJ & PARK KH (2014) Retinal and choroidal changes with severe hypertension and their association with visual outcome. *Invest Ophthalmol Vis Sci,* 55, 7775-85.

ANDERSON DR (1998) *Normal Tension Glaucoma Study,* Baltimore, Williams & Wilkins.

ANDERSON DR, DRANCE SM, SCHULZER M & COLLABORATIVE NORMAL-TENSION GLAUCOMA STUDY GROUP (2001) Natural history of normal-tension glaucoma. *Ophthalmology,* 108, 247-53.

ANDERSSON S, HEIJL A, BOEHM AG & BENGTSSON B (2011) The effect of education on the assessment of optic nerve head photographs for the glaucoma diagnosis. *BMC Ophthalmol,* 11, 12.

ARTES PH & CHAUHAN BC (2005) Longitudinal changes in the visual field and optic disc in glaucoma. *Prog Retin Eye Res,* 24, 333-54.

ASRANI S, ESSAID L, ALDER BD & SANTIAGO-TURLA C (2014) Artifacts in spectral-domain optical coherence tomography measurements in glaucoma. *JAMA Ophthalmol,* 132, 396-402.

AZUARA-BLANCO A, KATZ LJ, SPAETH GL, VERNON SA, SPENCER F & LANZL IM (2003) Clinical agreement among glaucoma experts in the detection of glaucomatous changes of the optic disk using simultaneous stereoscopic photographs. *Am J Ophthalmol,* 136, 949-50.

BELGHITH A, MEDEIROS FA, BOWD C, LIEBMANN JM, GIRKIN CA, WEINREB RN & ZANGWILL LM (2016) Structural Change Can Be Detected in Advanced-Glaucoma Eyes. *Invest Ophthalmol Vis Sci,* 57, OCT511-8.

BENGTSSON B, ANDERSSON S & HEIJL A (2012) Performance of time-domain and spectral-domain Optical Coherence Tomography for glaucoma screening. *Acta Ophthalmol,* 90, 310-5.

BENGTSSON B & HEIJL A (1998) SITA Fast, a new rapid perimetric threshold test. Description of methods and evaluation in patients with manifest and suspect glaucoma. *Acta Ophthalmol Scand,* 76, 431-7.

BENGTSSON B & HEIJL A (2006) Diagnostic sensitivity of fast blue-yellow and standard automated perimetry in early glaucoma: a comparison between different test programs. *Ophthalmology,* 113, 1092-7.

BENGTSSON B & HEIJL A (2008) A visual field index for calculation of glaucoma rate of progression. *Am J Ophthalmol,* 145, 343-53.

BENGTSSON B, LINDGREN A, HEIJL A, LINDGREN G, ÅSMAN P & PATELLA M (1997a) Perimetric probability maps to separate change caused by glaucoma from that caused by cataract. *Acta Ophthalmol Scand,* 75, 184-8.

BENGTSSON B, OLSSON J, HEIJL A & ROOTZEN H (1997b) A new generation of algorithms for computerized threshold perimetry, SITA. *Acta Ophthalmol Scand,* 75, 368-75.

BIZIOS D, HEIJL A & BENGTSSON B (2011) Integration and fusion of standard automated perimetry and optical coherence tomography data for improved automated glaucoma diagnostics. *BMC Ophthalmol,* 11, 20.

BOURNE RR, STEVENS GA, WHITE RA, SMITH JL, FLAXMAN SR, PRICE H, JONAS JB, KEEFFE J, LEASHER J, NAIDOO K, PESUDOVS K, RESNIKOFF S, TAYLOR HR & VISION LOSS EXPERT GROUP. (2013) Causes of vision loss worldwide, 1990-2010: a systematic analysis. *Lancet Glob Health,* 1, e339-49.

BOWD C & GOLDBAUM MH. (2008) Machine Learning Classifiers in Glaucoma. *Optom Vis Sci,* 85, 396-405.

BOWD C, ZANGWILL LM, WEINREB RN, MEDEIROS FA & BELGHITH A (2017) Estimating Optical Coherence Tomography Structural Measurement Floors to Improve Detection of Progression in Advanced Glaucoma. *Am J Ophthalmol,* 175, 37-44.

BUDENZ DL, RHEE P, FEUER WJ, MCSOLEY J, JOHNSON CA & ANDERSON DR (2002) Sensitivity and specificity of the Swedish interactive threshold algorithm for glaucomatous visual field defects. *Ophthalmology,* 109, 1052-8.

CHAGLASIAN M, FINGERET M, DAVEY PG, HUANG WC, LEUNG D, NG E & REISMAN CA (2018) The development of a reference database with the Topcon 3D OCT-1 Maestro. *Clin Ophthalmol,* 12, 849-857.

CHAN CK & MILLER NR (2007) Peripapillary nerve fiber layer thickness measured by optical coherence tomography in patients with no light perception from long-standing nonglaucomatous optic neuropathies. *J Neuroophthalmol,* 27, 176-9.

CHAN HH, ONG DN, KONG YX, O'NEILL EC, PANDAV SS, COOTE MA & CROWSTON JG (2014) Glaucomatous optic neuropathy evaluation (GONE) project: the effect of monoscopic versus stereoscopic viewing conditions on optic nerve evaluation. *Am J Ophthalmol,* 157, 936-44.

CHAUHAN BC, MALIK R, SHUBA LM, RAFUSE PE, NICOLELA MT & ARTES PH (2014) Rates of glaucomatous visual field change in a large clinical population. *Invest Ophthalmol Vis Sci,* 55, 4135-43.

CHEN JJ & KARDON RH (2016) Avoiding Clinical Misinterpretation and Artifacts of Optical Coherence Tomography Analysis of the Optic Nerve, Retinal Nerve Fiber Layer, and Ganglion Cell Layer. *J Neuroophthalmol,* 36, 417-438.

CHRISTOPHER M, BELGHITH A, WEINREB RN, BOWD C, GOLDBAUM MH, SAUNDERS LJ, MEDEIROS FA & ZANGWILL LM (2018) Retinal Nerve Fiber Layer Features Identified by Unsupervised Machine Learning on Optical Coherence Tomography Scans Predict Glaucoma Progression. *Invest Ophthalmol Vis Sci,* 59, 2748-2756.

COLLABORATIVE NORMAL TENSION GLAUCOMA STUDY GROUP (1998) Comparison of glaucomatous progression between untreated patients with normal-tension glaucoma and patients with therapeutically reduced intraocular pressures. *Am J Ophthalmol,* 126, 487-97.

DEMIRKAYA N, VAN DIJK HW, VAN SCHUPPEN SM, ABRAMOFF MD, GARVIN MK, SONKA M, SCHLINGEMANN RO & VERBRAAK FD (2013) Effect of age on individual retinal layer thickness in normal eyes as measured with spectral-domain optical coherence tomography. *Invest Ophthalmol Vis Sci,* 54, 4934-40.

DOLMAN CL, MCCORMICK AQ & DRANCE SM (1980) Aging of the optic nerve. *Arch Ophthalmol,* 98, 2053-8.

EDERER F, GAASTERLAND DE, SULLIVAN EK & AGIS INVESTIGATORS (1994) The Advanced Glaucoma Intervention Study (AGIS): 1. Study design and methods and baseline characteristics of study patients. *Control Clin Trials,* 15, 299-325.

EUROPEAN GLAUCOMA SOCIETY (2014) *Terminology and guidelines for glaucoma 4th ed.* Savona, Italy, PubliComm.

GAO H & HOLLYFIELD JG (1992) Aging of the human retina. Differential loss of neurons and retinal pigment epithelial cells. *Invest Ophthalmol Vis Sci,* 33, 1-17.

GARAS A, PAPP A & HOLLO G (2013) Influence of age-related macular degeneration on macular thickness measurement made with fourier-domain optical coherence tomography. *J Glaucoma,* 22, 195-200.

GIRKIN CA, MCGWIN G JR, SINAI MJ, SEKHAR GC, FINGERET M, WOLLSTEIN G, VARMA R, GREENFIELD D, LIEBMANN J, ARAIE M, TOMITA G, MAEDA N & GARWAY-HEATH DF (2011) Variation in optic nerve and macular structure with age and race with spectral-domain optical coherence tomography. *Ophthalmology,* 118, 2403-8.

GOLDMANN H (1954) Un nouveau tonomètre á applanation. *Bull Soc Franc Opthalmol,* 67, 474-477.

GORDON MO & KASS MA (1999) The Ocular Hypertension Treatment Study: design and baseline description of the participants. *Arch Ophthalmol,* 117, 573-83.

GRØDUM K, HEIJL A & BENGTSSON B (2002) A comparison of glaucoma patients identified through mass screening and in routine clinical practice. *Acta Ophthalmol Scand,* 80, 627-31.

HAMMEL N, BELGHITH A, WEINREB RN, MEDEIROS FA, MENDOZA N & ZANGWILL LM (2017) Comparing the Rates of Retinal Nerve Fiber Layer and Ganglion Cell-Inner Plexiform Layer Loss in Healthy Eyes and in Glaucoma Eyes. *Am J Ophthalmol,* 178, 38-50.

HAVVAS I, PAPACONSTANTINOU D, MOSCHOS MM, THEODOSSIADIS PG, ANDREANOS V, EKATOMATIS P, VERGADOS I & ANDREANOS D (2013) Comparison of SWAP and SAP on the point of glaucoma conversion. *Clin Ophthalmol,* 7, 1805-10.

HEIJL A, ALM A, BENGTSSON B, BERGSTRÖM A, CALISSENDORFF B, LINDBLOM B & LINDÉN C (2010) *Riktlinjer för Glaukomsjukvården,* Malmö, Sweden, Sveriges Ögonläkarförening.

HEIJL A & BENGTSSON B (1996) The effect of perimetric experience in patients with glaucoma. *Arch Ophthalmol,* 114, 19-22.

HEIJL A, BENGTSSON B, CHAUHAN BC, LIEBERMAN MF, CUNLIFFE I, HYMAN L & LESKE MC (2008) A comparison of visual field progression criteria of 3 major glaucoma trials in early manifest glaucoma trial patients. *Ophthalmology,* 115, 1557-65.

HEIJL A, BUCHHOLZ P, NORRGREN G & BENGTSSON B (2013) Rates of visual field progression in clinical glaucoma care. *Acta Ophthalmol,* 91, 406-12.

HEIJL A, LESKE MC, BENGTSSON B, HYMAN L, BENGTSSON B, HUSSEIN M & THE EARLY MANIFEST GLAUCOMA TRIAL GROUP (2002) Reduction of intraocular pressure and glaucoma progression: results from the Early Manifest Glaucoma Trial. *Arch Ophthalmol,* 120, 1268-79.

HEIJL A, PATELLA VM, CHONG LX, IWASE A, LEUNG CK, TUULONEN A, LEE GC, CALLAN T & BENGTSSON B (2019) A New SITA Perimetric Threshold Testing Algorithm: Construction and a Multicenter Clinical Study. *Am J Ophthalmol,* 198, 154-165.

HEIJL A, LINDGREN G, OLSSON J (1989) A package for the statistical analysis of visual fields. *In:* GREVE EL & HEIJL A (eds.) *Seventh International Visual Field Symposium.* Dordrecht, Boston, Lancaster: Martinus Nijhoff / Dr W Junk Publishers, Kluwer academic publishers group.

HELMHOLTZ H (1851) *Beschreibung eines augen-spiegels: zur untersuchung der netzhaut im lebenden auge.,* Berlin, Förstner'sche verlagsbuchhandlung (P. Jeanrenaud).

HO J, SULL AC, VUONG LN, CHEN Y, LIU J, FUJIMOTO JG, SCHUMAN JS & DUKER JS (2009) Assessment of artifacts and reproducibility across spectral- and time-domain optical coherence tomography devices. *Ophthalmology,* 116, 1960-70.

HODAPP E, PARRISH RK, ANDERSON DR (1993) *Clinical decisions in glaucoma,* St Louis, Mo, Mosby.

HOLLO G & ZHOU Q (2016) Evaluation of Retinal Nerve Fiber Layer Thickness and Ganglion Cell Complex Progression Rates in Healthy, Ocular Hypertensive, and Glaucoma Eyes With the Avanti RTVue-XR Optical Coherence Tomograph Based on 5-Year Follow-up. *J Glaucoma,* 25, e905-e909.

HOLLOWS FC & GRAHAM PA (1966) Intra-ocular pressure, glaucoma, and glaucoma suspects in a defined population. *Br J Ophthalmol,* 50, 570-86.

HOOD DC & KARDON RH (2007) A framework for comparing structural and functional measures of glaucomatous damage. *Prog Retin Eye Res,* 26, 688-710.

HUDSON CJ, KIM LS, HANCOCK SA, CUNLIFFE IA & WILD JM (2007) Some dissociating factors in the analysis of structural and functional progressive damage in open-angle glaucoma. *Br J Ophthalmol,* 91, 624-8.

JAMPEL HD, FRIEDMAN D, QUIGLEY H, VITALE S, MILLER R, KNEZEVICH F & DING Y (2009) Agreement among glaucoma specialists in assessing progressive disc changes from photographs in open-angle glaucoma patients. *Am J Ophthalmol,* 147, 39-44 e1.

JIA Y, WEI E, WANG X, ZHANG X, MORRISON JC, PARIKH M, LOMBARDI LH, GATTEY DM, ARMOUR RL, EDMUNDS B, KRAUS MF, FUJIMOTO JG & HUANG D (2014) Optical coherence tomography angiography of optic disc perfusion in glaucoma. *Ophthalmology,* 121, 1322-32.

KAPETANAKIS VV, CHAN MP, FOSTER PJ, COOK DG, OWEN CG & RUDNICKA AR (2016) Global variations and time trends in the prevalence of primary open angle glaucoma (POAG): a systematic review and meta-analysis. *Br J Ophthalmol,* 100, 86-93.

KASS MA, HEUER DK, HIGGINBOTHAM EJ, JOHNSON CA, KELTNER J L, MILLER JP, PARRISH RK 2ND, WILSON MR & GORDON MO (2002) The Ocular Hypertension Treatment Study: a randomized trial determines that topical ocular hypotensive medication delays or prevents the onset of primary open-angle glaucoma. *Arch Ophthalmol,* 120, 701-13; discussion 829-30.

KATZ J, QUIGLEY HA & SOMMER A (1996) Detection of incident field loss using the glaucoma hemifield test. *Ophthalmology,* 103, 657-63.

KATZ J, SOMMER A, GAASTERLAND DE & ANDERSON DR (1991) Comparison of analytic algorithms for detecting glaucomatous visual field loss. *Arch Ophthalmol,* 109, 1684-9.

KELTNER JL, JOHNSON CA, ANDERSON DR, LEVINE RA, FAN J, CELLO KE, QUIGLEY HA, BUDENZ DL, PARRISH RK, KASS MA, GORDON MO & THE OCULAR HYPERTENSION TREATMENT STUDY GROUP (2006) The association between glaucomatous visual fields and optic nerve head features in the Ocular Hypertension Treatment Study. *Ophthalmology,* 113, 1603-12.

KELTNER JL, JOHNSON CA, QUIGG JM, CELLO KE, KASS MA & GORDON MO (2000) Confirmation of visual field abnormalities in the Ocular Hypertension Treatment Study. Ocular Hypertension Treatment Study Group. *Arch Ophthalmol,* 118, 1187-94.

KNIGHT OJ, GIRKIN CA, BUDENZ DL, DURBIN MK, FEUER WJ & CIRRUS OCT NORMATIVE DATABASE STUDY GROUP (2012) Effect of race, age, and axial length on optic nerve head parameters and retinal nerve fiber layer thickness measured by Cirrus HD-OCT. *Arch Ophthalmol,* 130, 312-8.

KUANG TM, ZHANG C, ZANGWILL LM, WEINREB RN & MEDEIROS FA (2015) Estimating Lead Time Gained by Optical Coherence Tomography in Detecting Glaucoma before Development of Visual Field Defects. *Ophthalmology,* 122, 2002-9.

LEE JR, SUNG KR, NA JH, SHON K & LEE KS (2013) Discrepancy between optic disc and nerve fiber layer assessment and optical coherence tomography in detecting glaucomatous progression. *Jpn J Ophthalmol,* 57, 546-52.

LEFFLER CT, SCHWARTZ SG, HADI TM, SALMAN A & VASUKI V (2015) The early history of glaucoma: the glaucous eye (800 BC to 1050 AD). *Clin Ophthalmol,* 9, 207-15.

LESKE MC, HEIJL A, HYMAN L & BENGTSSON B (1999) Early Manifest Glaucoma Trial: design and baseline data. *Ophthalmology,* 106, 2144-53.

LEUNG CK, LIU S, WEINREB RN, LAI G, YE C, CHEUNG CY, PANG CP, TSE KK & LAM DS (2011) Evaluation of retinal nerve fiber layer progression in glaucoma a prospective analysis with neuroretinal rim and visual field progression. *Ophthalmology,* 118, 1551-7.

LEUNG CK, YU M, WEINREB RN, LAI G, XU G & LAM DS (2012) Retinal nerve fiber layer imaging with spectral-domain optical coherence tomography: patterns of retinal nerve fiber layer progression. *Ophthalmology,* 119, 1858-66.

LEUNG CKS, YE C, WEINREB RN, YU M, LAI G & LAM DS (2013) Impact of age-related change of retinal nerve fiber layer and macular thicknesses on evaluation of glaucoma progression. *Ophthalmology,* 120, 2485-2492.

LINDÉN C, BENGTSSON B, ALM A, CALISSENDORFF B, ECKERLUND I & HEIJL A (2013) Glaucoma management in Sweden - results from a nationwide survey. *Acta Ophthalmol,* 91, 20-4.

LINNÉR E (1969) A longitudinal study of ocular hypertension. *Doc Ophthalmol,* 27, 259-66.

LIU L, JIA Y, TAKUSAGAWA HL, PECHAUER AD, EDMUNDS B, LOMBARDI L, DAVIS E, MORRISON JC & HUANG D (2015) Optical Coherence Tomography Angiography of the Peripapillary Retina in Glaucoma. *JAMA Ophthalmol,* 133, 1045-52.

MACKENZIE W (1830) On Glaucoma. *Glasgow Med J,* 3, 254-267.

MADDESS T, HENRY GH (1992) Performance of nonlinear visual units in ocular hypertension and glaucoma. *Clinical Vision Science,* 7, 371-383.

MEDEIROS FA, ALENCAR LM, ZANGWILL LM, BOWD C, SAMPLE PA & WEINREB RN (2009) Prediction of functional loss in glaucoma from progressive optic disc damage. *Arch Ophthalmol,* 127, 1250-6.

MIGLIOR S, ZEYEN T, PFEIFFER N, CUNHA-VAZ J, TORRI V, ADAMSONS I & EUROPEAN GLAUCOMA PREVENTION STUDY GROUP (2005) Results of the European Glaucoma Prevention Study. *Ophthalmology,* 112, 366-75.

MIKI A, MEDEIROS FA, WEINREB RN, JAIN S, HE F, SHARPSTEN L, KHACHATRYAN N, HAMMEL N, LIEBMANN JM, GIRKIN CA, SAMPLE PA & ZANGWILL LM (2014) Rates of retinal nerve fiber layer thinning in glaucoma suspect eyes. *Ophthalmology,* 121, 1350-8.

MOGHIMI S, BOWD C, ZANGWILL LM, PENTEADO RC, HASENSTAB K, HOU H, GHAHARI E, MANALASTAS PIC, PROUDFOOT J & WEINREB RN (2019) Measurement Floors and Dynamic Ranges of OCT and OCT Angiography in Glaucoma. *Ophthalmology,* 126, 980-988.

MOHAMMADI K, BOWD C, WEINREB RN, MEDEIROS FA, SAMPLE PA & ZANGWILL LM (2004) Retinal nerve fiber layer thickness measurements with scanning laser polarimetry predict glaucomatous visual field loss. *Am J Ophthalmol,* 138, 592-601.

MUSCH DC, LICHTER PR, GUIRE KE & STANDARDI CL (1999) The Collaborative Initial Glaucoma Treatment Study: study design, methods, and baseline characteristics of enrolled patients. *Ophthalmology,* 106, 653-62.

MWANZA JC, BUDENZ DL, WARREN JL, WEBEL AD, REYNOLDS CE, BARBOSA DT & LIN S (2015) Retinal nerve fibre layer thickness floor and corresponding functional loss in glaucoma. *Br J Ophthalmol,* 99, 732-7.

NA JH, SUNG KR, BAEK S, KIM YJ, DURBIN MK, LEE HJ, KIM HK & SOHN YH (2012) Detection of glaucoma progression by assessment of segmented macular thickness data obtained using spectral domain optical coherence tomography. *Invest Ophthalmol Vis Sci,* 53, 3817-26.

NGUYEN AT, GREENFIELD DS, BHAKTA AS, LEE J, FEUER WJ (2019) Detecting glaucoma progression using guided progression analysis with OCT and visual field assessment in eyes classified by international classification of disease severity codes. *Opthalmology Glaucoma,* 2, 36-46.

NOUREDDIN BN, POINOOSAWMY D, FIETZKE FW & HITCHINGS RA (1991) Regression analysis of visual field progression in low tension glaucoma. *Br J Ophthalmol,* 75, 493-5.

NUNES A, SILVA G, DUQUE C, JANUARIO C, SANTANA I, AMBROSIO AF, CASTELO-BRANCO M & BERNARDES R (2019) Retinal texture biomarkers may help to discriminate between Alzheimer's, Parkinson's, and healthy controls. *PLoS One,* 14, e0218826.

ODBERG T, JAKOBSEN JE, HULTGREN SJ & HALSEIDE R (2001) The impact of glaucoma on the quality of life of patients in Norway. I. Results from a self-administered questionnaire. *Acta Ophthalmol Scand,* 79, 116-20.

ORLANDO JI, FU H, BARBOSSA BREDA J, VAN KEER K, BATHULA DR, DIAZ-PINTO A, FANG R, HENG PA, KIM J, LEE J, LEE J, LI X, LIU P, LU S, MURUGESAN B, NARANJO V, PHAYE SSR, SHANKARANARAYANA SM, SIKKA A, SON J, VAN DEN HENGEL A, WANG S, WU J, WU Z, XU G, XU Y, YIN P, LI F, ZHANG X, XU Y & BOGUNOVIC H (2019) REFUGE Challenge: A unified framework for evaluating automated methods for glaucoma assessment from fundus photographs. *Med Image Anal,* 59, 101570.

PETERS D, BENGTSSON B & HEIJL A (2013) Lifetime risk of blindness in open-angle glaucoma. *Am J Ophthalmol,* 156, 724-30.

QUARANTA L, RIVA I, GERARDI C, ODDONE F, FLORIANI I & KONSTAS AG (2016) Quality of Life in Glaucoma: A Review of the Literature. *Adv Ther,* 33, 959-81.

RAMACHANDRAN VS & GREGORY RL (1991) Perceptual filling in of artificially induced scotomas in human vision. *Nature,* 350, 699-702.

REUS NJ, LEMIJ HG, GARWAY-HEATH DF, AIRAKSINEN PJ, ANTON A, BRON AM, FASCHINGER C, HOLLO G, IESTER M, JONAS JB, MISTLBERGER A, TOPOUZIS F & ZEYEN TG (2010) Clinical assessment of stereoscopic optic disc photographs for glaucoma: the European Optic Disc Assessment Trial. *Ophthalmology,* 117, 717-23.

RUSSELL RA, MALIK R, CHAUHAN BC, CRABB DP & GARWAY-HEATH DF (2012) Improved estimates of visual field progression using bayesian linear regression to integrate structural information in patients with ocular hypertension. *Invest Ophthalmol Vis Sci,* 53, 2760-9.

SAFI H, SAFI S, HAFEZI-MOGHADAM A & AHMADIEH H (2018) Early detection of diabetic retinopathy. *Surv Ophthalmol,* 63, 601-608.

SCHIÖTZ H (1905) Et nyt tonometer, tonometri. *Norsk Mag Lägevidensk,* 66, 597-622.

SCHREMS-HOESL LM, SCHREMS WA, LAEMMER R, HORN FK, JUENEMANN AG, KRUSE FE & MARDIN CY (2014) Confocal Laser Scanning Tomography to Predict Visual Field Conversion in Patients With Ocular Hypertension and Early Glaucoma. *J Glaucoma*.

SEHI M, GREWAL DS, SHEETS CW & GREENFIELD DS (2009) Diagnostic ability of Fourier-domain vs time-domain optical coherence tomography for glaucoma detection. *Am J Ophthalmol,* 148, 597-605.

SHIN JW, SUNG KR, LEE GC, DURBIN MK & CHENG D (2017) Ganglion Cell-Inner Plexiform Layer Change Detected by Optical Coherence Tomography Indicates Progression in Advanced Glaucoma. *Ophthalmology,* 124, 1466-1474.

SJÖGREN H (1946) A Study in Pseudoglaucoma. *Acta Ophthalmol,* 24, 239-294.

STAMPER RL, LIEBERMAN MF & DRAKE MV (2009) Introduction to patient management. *Becker-Shaffer's Diagnosis and therapy of the glaucomas.* 8th ed ed. Edinburgh: Mosby/Elsevier.

STROUTHIDIS NG, SCOTT A, PETER NM & GARWAY-HEATH DF (2006) Optic disc and visual field progression in ocular hypertensive subjects: detection rates, specificity, and agreement. *Invest Ophthalmol Vis Sci,* 47, 2904-10.

SUNG KR, NA JH & LEE Y (2012) Glaucoma diagnostic capabilities of optic nerve head parameters as determined by Cirrus HD optical coherence tomography. *J Glaucoma,* 21, 498-504.

VAN DER SCHOOT J, REUS NJ, COLEN TP & LEMIJ HG (2010) The ability of short-wavelength automated perimetry to predict conversion to glaucoma. *Ophthalmology,* 117, 30-4.

VARMA R, LEE PP, GOLDBERG I & KOTAK S (2011) An assessment of the health and economic burdens of glaucoma. *Am J Ophthalmol,* 152, 515-22.

VARMA R, STEINMANN WC & SCOTT IU (1992) Expert agreement in evaluating the optic disc for glaucoma. *Ophthalmology,* 99, 215-21.

VARMA R & SPAETH GL (1993) *The Optic Nerve in Glaucoma,* Philadelphia, Pennsylvania, USA, J.B. Lippincott company.

VESTI E, JOHNSON CA & CHAUHAN BC (2003) Comparison of different methods for detecting glaucomatous visual field progression. *Invest Ophthalmol Vis Sci,* 44, 3873-9.

VIANNA JR, DANTHUREBANDARA VM, SHARPE GP, HUTCHISON DM, BELLIVEAU AC, SHUBA LM, NICOLELA MT & CHAUHAN BC (2015) Importance of Normal Aging in Estimating the Rate of Glaucomatous Neuroretinal Rim and Retinal Nerve Fiber Layer Loss. *Ophthalmology,* 122, 2392-8.

WALLS GL (1954) The filling-in process. *Am J Optom Arch Am Acad Optom,* 31, 329-41.

WANG M, PASQUALE LR, SHEN LQ, BOLAND MV, WELLIK SR, DE MORAES CG, MYERS JS, WANG H, BANIASADI N, LI D, SILVA RNE, BEX PJ & ELZE T (2018) Reversal of Glaucoma Hemifield Test Results and Visual Field Features in Glaucoma. *Ophthalmology,* 125, 352-360.

WEINREB RN & GREVE EL (2004) Concluding remarks. *In:* WEINREB RN & GREVE EL (eds.) *Glaucoma Diagnosis. Structure and function. Consensus series 1. Association of international glaucoma societies.* The Hague, The Neatherlands: Kugler publications.

WEINREB RN, ZANGWILL LM, JAIN S, BECERRA LM, DIRKES K, PILTZ-SEYMOUR JR, CIOFFI GA, TRICK GL, COLEMAN AL, BRANDT JD, LIEBMANN JM, GORDON MO, KASS MA & OHTS CSLO ANCILLARY STUDY GROUP (2010) Predicting the onset of glaucoma: the confocal scanning laser ophthalmoscopy ancillary study to the Ocular Hypertension Treatment Study. *Ophthalmology,* 117, 1674-83.

WHO (2014) *Visual impairment and blindness: Fact Sheet No 282.* [Online]. http://www.who.int/mediacentre/factsheets/fs282/en/ [Accessed October 2019].

WILD JM, DENGLER-HARLES M, SEARLE AE, O'NEILL EC & CREWS SJ (1989) The influence of the learning effect on automated perimetry in patients with suspected glaucoma. *Acta Ophthalmol (Copenh),* 67, 537-45.

WILSEY LJ & FORTUNE B (2016) Electroretinography in glaucoma diagnosis. *Curr Opin Ophthalmol,* 27, 118-24.

WILSON R, LESKE C, LEE P, YAMAMOTO T, GRIGERA D, HEALEY P, ZANGWILL L, HEIJL A (2019) *Screening for open-angle glaucoma, report from the WGA comittee* [Online]. https://wga.one/wga/screening-for-open-angle-glaucoma/ [Accessed October 2019].

YU M, LIN C, WEINREB RN, LAI G, CHIU V & LEUNG CK (2016) Risk of Visual Field Progression in Glaucoma Patients with Progressive Retinal Nerve Fiber Layer Thinning: A 5-Year Prospective Study. *Ophthalmology,* 123, 1201-10.

ZHANG X, FRANCIS BA, DASTIRIDOU A, CHOPRA V, TAN O, VARMA R, GREENFIELD DS, SCHUMAN JS, HUANG D & ADVANCED IMAGING FOR GLAUCOMA STUDY GROUP (2016) Longitudinal and Cross-Sectional Analyses of Age Effects on Retinal Nerve Fiber Layer and Ganglion Cell Complex Thickness by Fourier-Domain OCT. *Transl Vis Sci Technol,* 5, 1.

ÅSMAN P & HEIJL A (1992) Glaucoma Hemifield Test. Automated visual field evaluation. *Arch Ophthalmol,* 110, 812-9.