



LUND UNIVERSITY

Neonatal Instability of the Hip. Results of screening and early treatment with the von Rosen splint

WENGER, DANIEL

2016

Document Version:

Publisher's PDF, also known as Version of record

[Link to publication](#)

Citation for published version (APA):

WENGER, DANIEL. (2016). *Neonatal Instability of the Hip. Results of screening and early treatment with the von Rosen splint*. Lund University: Faculty of Medicine.

Total number of authors:

1

General rights

Unless other specific re-use rights are stated the following general rights apply:

Copyright and moral rights for the publications made accessible in the public portal are retained by the authors and/or other copyright owners and it is a condition of accessing publications that users recognise and abide by the legal requirements associated with these rights.

- Users may download and print one copy of any publication from the public portal for the purpose of private study or research.
- You may not further distribute the material or use it for any profit-making activity or commercial gain
- You may freely distribute the URL identifying the publication in the public portal

Read more about Creative commons licenses: <https://creativecommons.org/licenses/>

Take down policy

If you believe that this document breaches copyright please contact us providing details, and we will remove access to the work immediately and investigate your claim.

LUND UNIVERSITY

PO Box 117
221 00 Lund
+46 46-222 00 00

Neonatal Instability of the Hip

Neonatal Instability of the Hip

Results of screening and early treatment with the von
Rosen splint

Daniel Wenger



LUND
UNIVERSITY

DOCTORAL DISSERTATION

by due permission of the Faculty of Medicine, Lund University, Sweden.

To be defended at the Clinical Research Center Aula, SUS Malmö,

May 21st 2016, 11 a.m.

Faculty opponent

Associate Professor Bertil Romanus, Sahlgrenska University Hospital, Gothenburg

Organization LUND UNIVERSITY Department of Orthopedics Clinical Sciences, Malmö Author: Daniel Wenger	Document name DOCTORAL DISSERTATION	
	Date of issue 2016-05-21	
	Sponsoring organization	
Title and subtitle Neonatal Instability of the Hip – Results of screening and early treatment with the von Rosen splint		
Abstract <p>Developmental Dysplasia of the Hip (DDH) is a disease spectrum, ranging from Neonatal Instability of the Hip (NIH) to acetabular dysplasia and hip dislocation. In Sweden, screening for NIH by clinical examination of all newborn children was instituted in the 1950:s. With screening and early treatment using abduction splints, the incidence of late diagnosed hip dislocations decreased. The aims of this work were to study the results of early treatment (commencing in the first week of life) with the von Rosen splint, and to study the efficacy of the Swedish screening program as we have moved into the 21:st century.</p> <p>In Paper I, we retrospectively studied the radiographs of 243 children that had been referred on suspicion of NIH during 2004-2007. Acetabular dysplasia at 1-year age was more common in hips with neonatal instability compared to hips that were clinically stable, despite early treatment.</p> <p>In Paper II, we found avascular necrosis of the femoral head (AVN) to occur in 2 (0.9%) of 229 children treated early for NIH during 2003-2010. Both cases of AVN were Kalamchi-MacEwen group I which carries a good prognosis. They were asymptomatic and normalized spontaneously. We also found a slower ossification of the femoral head in hips with NIH.</p> <p>In Paper III, 21 study subjects with residual dysplasia after treatment for NIH (born and treated in 1987-1993) were followed-up to skeletal maturity. At 21 years age, acetabular dysplasia had remodeled to normal in all but 1 subject. No subject had signs of hip osteoarthritis (OA) at radiography or cartilage degeneration as assessed by delayed Gadolinium-Enhanced Magnetic Resonance Imaging of Cartilage (dGEMRIC). Their subjective outcome, assessed by the 12-item WOMAC (a patient related outcome measure) was good. We found a positive correlation between radiographic measures of DDH and dGEMRIC measurements of cartilage quality, possibly indicating that cartilage can adapt to a moderately increased mechanical load.</p> <p>In Paper IV, we report the results from 10 years of Swedish screening (2000-2009) in 1 million children born and examined. The incidence of late diagnosed hip dislocation was 0.12 per 1,000 live births, which can be compared to a minimum incidence of 0.9 per 1,000 found in the pre-screening era. The risk of a high dislocation (Tönnis grade 3 or 4) was 0.02 per 1,000 live births. The median age at diagnosis was 7 months. Girls had a 9 times higher risk of having a hip dislocation compared to boys.</p> <p>In conclusion, early diagnosis of NIH and treatment with the von Rosen splint yields good results and is safe. The Swedish screening program has led to a marked decrease in the incidence of late diagnosed hip dislocation and earlier detection of late presenting cases. The correlation between radiographic measures of DDH and cartilage quality (dGEMRIC) in young adults is intriguing. As OA represents a major burden of disease globally, further research is warranted to increase our understanding of the impact of joint anatomy and mechanical loading on cartilage health.</p>		
Key words: DDH, developmental dysplasia of the hip, NIH, neonatal instability of the hip, von Rosen splint, AVN, avascular necrosis, dGEMRIC, cartilage, osteoarthritis, screening, hip dislocation		
Classification system and/or index terms (if any)		
Supplementary bibliographical information Lund University, Faculty of Medicine Doctoral Dissertation Series 2016:59		Language English
ISSN and key title 1652-8220		ISBN 978-91-7619-285-6
Recipient's notes	Number of pages	Price
	Security classification	

I, the undersigned, being the copyright owner of the abstract of the above-mentioned dissertation, hereby grant to all reference sources permission to publish and disseminate the abstract of the above-mentioned dissertation.

Signature



Date

15/4 2016

Neonatal Instability of the Hip

Results of screening and early treatment with the von
Rosen splint

Daniel Wenger



LUND
UNIVERSITY

Cover photo: One of the study subjects in Paper III a few days after birth. A von Rosen splint is fitted. At 24 years follow-up, her mother brought the photo. Image printed with kind permission from the subject.

Copyright Daniel Wenger

Lund University, Clinical Sciences Malmö

Faculty of Medicine Doctoral Dissertation Series 2016:59

ISBN 978-91-7619-285-6

ISSN 1652-8220

Printed in Sweden by Media-Tryck, Lund University

Lund 2016



Contents

Populärvetenskaplig sammanfattning	9
Abbreviations	11
List of papers	12
Introduction	13
Developmental dysplasia of the hip (DDH)	13
Historical background from a Swedish perspective	15
Osteoarthritis (OA)	17
Articular cartilage	18
Radiography in OA	19
delayed Gadolinium Enhanced Magnetic Resonance Imaging of Cartilage (dGEMRIC)	20
DDH and OA	22
The natural history of hip dislocation	22
A case study	23
Thesis' aims	24
Methods	25
Study subjects	25
Papers I and II	25
Paper III	25
Paper IV	26
Outcome measures	26
Paper I – the acetabular index (AI)	26
Paper II – the Kalamchi-MacEwen classification	27
Paper II – the diagnosis registry of ICD-10 codes and hospital files ..	28
Paper II – the size of the ossific nucleus	28
Paper III – radiographic measures of DDH in adults	29
Paper III – the Kellgren-Lawrence classification of OA	31
Paper III – the minimum joint space width (minJSW)	32
Paper III – dGEMRIC	33
Paper III – the 12-item WOMAC score	34

Paper IV – late diagnosed hip dislocation	35
Paper IV –Tönnis grading of hip dislocation.....	35
Software and Statistics	35
Ethics.....	36
Results and Discussion.....	37
How common is NIH?	37
Results of early treatment.....	39
Acetabular dysplasia at 1 year (Paper I).....	39
Low risk of AVN (Paper II)	42
Slower ossification of the femoral head epiphysis (Paper II).....	44
Remodeling of residual acetabular dysplasia (Paper III).....	46
No radiographic OA at 21 years (Paper III)	47
Normal cartilage quality at 21 years (Paper III)	48
Normal hip function at 21 years (Paper III)	49
Relationship between DDH measures and dGEMRIC.....	50
Results of screening for NIH.....	51
Reduced incidence of late diagnosed hip dislocation (Paper IV)	51
Earlier diagnosis of hip dislocation (Paper IV)	54
How should screening for DDH ideally be performed?.....	57
Conclusions	59
Future prospects.....	61
Screening for DDH	61
Biomechanics and cartilage health.....	61
Acknowledgements	63
References	65

Populärvetenskaplig sammanfattning

Knappt en procent av alla barn som föds har instabil höftled på ena eller båda sidorna. Flickor drabbas mycket oftare än pojkar och den vänstra höften är oftare instabil än den högra. Sedan 1950-talet undersöks alla nyfödda barn i Sverige av barnläkare med avseende på höftinstabilitet. Barn med instabil höftled behandlas av barnortoped i en skena som håller benen utåt, oftast von Rosen-skenan (se fotot på omslaget). Efter 6-12 veckor i skenan brukar höftlederna vara stabila varvid behandlingen avslutas.

Ett par ytterligare kontroller av höftlederna görs på barnavårdscentraler för alla barn i Sverige. Vid misstanke om att höften är ur led eller instabil görs röntgenundersökning och barnet remitteras till barnortoped. Ju tidigare behandlingen inleds, desto bättre resultat kan man vänta sig.

Anledningen till dessa undersökningar och behandlingar är att barn med höften ur led (höftluxation) får hälta och senare även värk från höften. Ledskålen i höften utvecklas inte normalt om inte lårbenshuvudet ligger stabilt på plats. På längre sikt uppstår skador på ledbrosket i höftleden och den smärtsamma ledsjukdomen artros utvecklas. Artros kan i dessa fall utvecklas så hastigt att patienten behöver opereras med en höftprotes redan vid 30–40 års ålder.

Innan man började undersöka nyfödda och behandla tidigt i skena drabbades ca 1 av 1000 barn av höftluxation. På de svenska vanförestalerna (institutioner för handikappade) var en tredjedel av alla intagna patienter där på grund av sjukdomen.

I denna avhandling ingår fyra studier. De tre första studierna är uppföljningsstudier av barn som har behandlats från nyföddhetstiden på grund av höftinstabilitet. Den fjärde studien är en rapport från det svenska nationella registret för sent upptäckta höftluxationer där alla fall av sjukdomen har rapporterats in sedan år 2000.

Studie I visar att instabila höfter har en mindre utvecklad ledskål än stabila höfter vid 1 års uppföljning trots tidig behandling. En högre grad av instabilitet var förknippad med mindre välutvecklad ledskål. Alla barn som behandlades i Malmö från april 2002 till december 2007 ingick i studien. 82% var flickor.

Studie II visar att tidig behandling med von Rosen-skenan är säker avseende störningar i blodcirkulationen till lårbenshuvudet. Sådan cirkulationsstörning kallas avaskulär nekros (AVN) och uppstår i ca 10% av de fall som behandlas senare (3 – 4 månaders ålder) med den internationellt ofta använda Pavlik-selen. I studien ingick alla barn som har behandlats tidigt (med start under första levnadsveckan) i Malmö under åren 2003–2010. Hos 229 sådana barn sågs röntgenförändringar i lårbenshuvudet endast hos 2 individer (0,9%). Förändringarna var av den lindrigaste graden och höfterna utvecklades normalt. Barnen observerades i 6,5 år.

Studie II visar också att lårbenshuvudet förbenas långsammare i höfter som varit instabila i nyföddhetsperioden.

I Studie III undersöktes 21 barn som hade behandlats för höftinstabilitet 1987-1993 och inte hade normaliserats helt vid 1 års ålder. De var i genomsnitt 21 år gamla vid uppföljningen. Röntgenundersökningar visade att en av personerna hade kvarvarande grunda ledskålar. Som grupp skiljde sig deras höftleder dock inte från ett stort norskt normalmaterial. Ingen hade tecken till artros på röntgen. Ett frågeformulär visade att de inte hade mer höftbesvär än ett tidigare beskrivet normalmaterial. Den mycket känsliga magnetkamera-tekniken dGEMRIC (delayed Gadolinium Enhanced Magnetic Resonance Imaging of Cartilage) visade att deras ledbrosk var av normal kvalitet.

Vi fann att grundare ledskål (alltså sämre utvecklad led med högre belastning på ledbrosket) var kopplad till högre dGEMRIC-index (som indikerar bättre broskkvalitet). Detta fynd kan tala för att ledbrosk anpassar sig till en måttligt ökad belastning hos unga vuxna.

Studie IV visar att sent upptäckt höftluxation är förhållandevis ovanligt i Sverige: på drygt 1 miljon födda barn under åren 2000-2009 upptäcktes bara 126 fall (0,12 per 1000). Hälften av dessa barn upptäcktes vid 7 månaders ålder eller tidigare vilket visar hur viktiga undersökningarna på barnavårdscentralerna är. Flickor löpte 9 gånger högre risk att drabbas av sent upptäckt höftluxation än pojkar.

Studie IV visar också att senare upptäckt är förknippat med högre (allvarligare) luxation.

Sammanfattningsvis är sent upptäckt höftluxation mycket ovanligt i Sverige idag och att de allra flesta sådana fall upptäcks förhållandevis tidigt. Behandlingen som ges vid höftinstabilitet hos nyfödda har utmärkta resultat och är säker.

Abbreviations

AI	acetabular index
AVN	avascular necrosis of the femoral head
BMI	body mass index
CE angle	center-edge angle of Wiberg
DDH	developmental dysplasia of the hip
dGEMRIC	delayed gadolinium enhanced MRI of cartilage
FHEI	femoral head extrusion index
GAG	glycosaminoglycan
Gd(DTPA) ²⁻	gadolinium diethylene triamine pentaacetic acid
minJSW	minimum joint space width
MRI	magnetic resonance imaging
NIH	neonatal instability of the hip
OA	osteoarthritis
THA	total hip arthroplasty
T ₁	relaxation time (ms)
T _{1Gd}	T ₁ in the presence of Gd(DTPA) ²⁻
ROI	region of interest
dGEMRIC index	mean T _{1Gd} in a ROI

List of papers

- I. Acetabular dysplasia at the age of 1 year in children with neonatal instability of the hip – A cohort study of 243 infants.
Wenger D, Düppe H, Tiderius CJ
Acta Orthopaedica 2013 Oct;84(5):483-8.
- II. Early treatment with the von Rosen splint for neonatal instability of the hip is safe regarding avascular necrosis of the femoral head.
Wenger D, Samuelsson H, Düppe H, Tiderius CJ
Acta Orthopaedica 2016 Apr;87(2):169-75.
- III. Residual hip dysplasia at 1 year after treatment for neonatal hip instability is not related to degenerative joint disease in young adulthood: a 21-year follow-up study including dGEMRIC.
Wenger D, Siversson C, Dahlberg LE, Tiderius CJ
Osteoarthritis and Cartilage 2016 Mar;24(3):436-42.
- IV. Clinical screening decreases the incidence of late diagnosed hip dislocation – Results from 1 million children born in Sweden from 2000 through 2009.
Düppe H, Wenger D, Tiderius CJ
Manuscript

In the following text, I have referred to the papers by their Roman numerals.

Introduction

“A good hip should last a man through his lifetime.”

- Ian Sharp 1961

Developmental dysplasia of the hip (DDH)

Developmental dysplasia of the hip (DDH) refers to a disease of the hip joint where the acetabulum is steep and shallow (acetabular dysplasia) and the femoral head is poorly contained, subluxated or even dislocated (Figure 1). An unstable hip joint, that can be manually dislocated during clinical examination, is also included in the DDH disease spectrum. Such unstable or dislocated hips are present in ~ 1% of newborn children and, in most cases, normalize spontaneously (Barlow 1962). The condition is called neonatal instability of the hip (NIH) in the newborn. In NIH, the instability of the hip can be felt with a dislocation provocation test (Barlow 1962). If the hip is dislocated in a newborn child, it can often be diagnosed clinically with a reduction maneuver (Ortolani 1976). The term DDH was introduced by Predrag Klisic (1989) and has replaced the previously used “congenital dislocation of the hip” (CDH) (Catterall 1994).

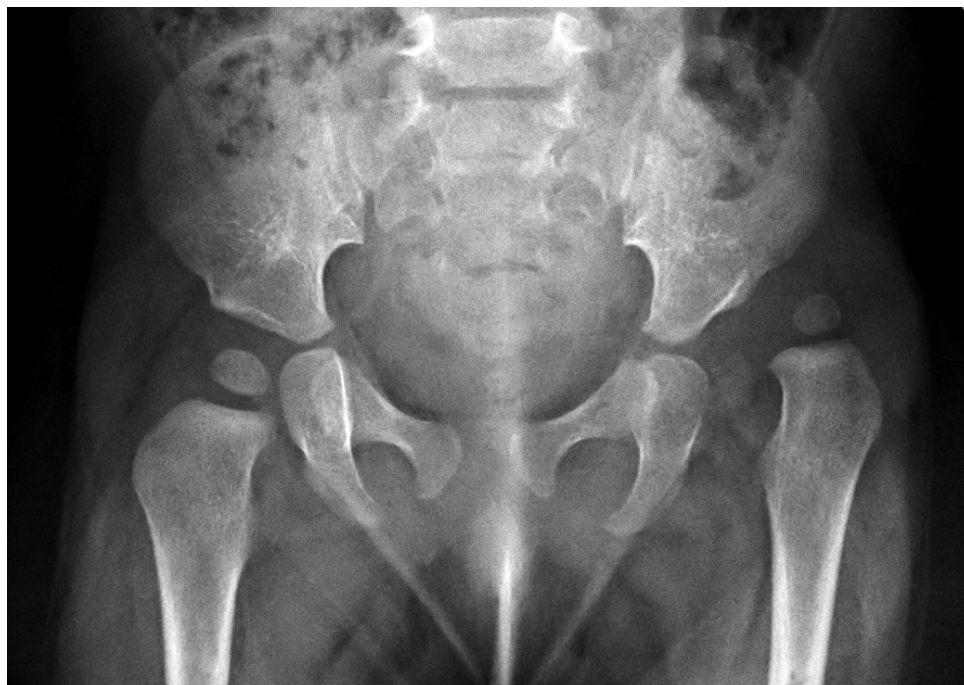

Figure 1.

Radiograph of a late diagnosed hip dislocation. The left hip is dislocated out of the acetabulum, with the proximal epiphysis of the femur at the level of the acetabular rim (Tönnis grade 3 dislocation). The acetabulum on the left side is dysplastic and a pseudo-acetabulum is developing cranial to the true acetabulum.

In newborns, acetabular morphology is quite variable with a high percentage of steep acetabula, most of whom normalize spontaneously by 2 months (Marks et al. 1994). During the normal growth and development of a child, the acetabulum becomes less and less steep (Tönnis 1976). The fully grown hip joint can be compared to a ball and socket, with great inherent mechanical stability (Ponseti 1978a). In DDH, this development is deficient (Ponseti 1978b).

In two Scandinavian population based studies, the prevalence of radiographic DDH was 2.4-4.3% in men and 3.6-4.3% in women (Gosvig et al. 2010, Engesaeter et al. 2013).

Known major risk factors for DDH are listed in Table 1.

Table 1.

Risk factors for NIH and late presenting hip dislocation in previous studies (Fredensborg 1975, Dunn et al. 1985, Hadlow 1988, Jones et al. 1990, Chan et al. 1997).

Risk factor	Odds Ratio	Relative Risk
Pes equinovarus adductus (PEVA)	12-18	9
Breech presentation at birth ¹	5-17	5-13
Heredity for DDH	4-14	5
Oligohydramnios	4	
Female sex	1.4-4	
Sectio ¹	2	
Primiparity	1.2-2	

¹ In breech presentation, vaginal delivery is associated with a higher risk of DDH compared to caesarean section, with odds ratios 17 and 10 respectively compared to baseline (Chan et al. 1997).

Historical background from a Swedish perspective

Although hip dislocation has been known since Hippocratic times (Palmén 1984), it was probably first clearly described pathoanatomically by Guillaume Dupuytren in 1826 (Dupuytren 1964, Dunn 1989). In Vienna, Adolf Lorenz attempted open reduction of dislocated hips, but poor results (this was in the pre-antibiotic era) led to the abandonment of surgical treatment around the turn of the century. In 1895, Lorenz instead described a method of closed reduction and cast treatment. Patrik Haglund, the first professor of orthopedics in Sweden, was of the same opinion as Lorenz: that closed reduction of dislocated hips was best performed at 2-3 years age. Patients diagnosed earlier had to wait (Severin 1941).

In 1941 one of Haglund's students, Erik Severin, published his landmark thesis on the subject (Severin 1941). Severin had performed a follow-up study of children treated with closed reduction in Stockholm during 1913–1932. Of 757 treated children, 330 (44%) had had a successful reduction. These successful cases were reviewed. With great tenacity, Severin reached a 93% rate of follow-up (306 patients with 417 affected hips) at 5-27 years after treatment. The results were poor with a 79% redislocation rate and severe malformations of the femoral head (Table 2). With every year of delay in treatment, the results became worse.

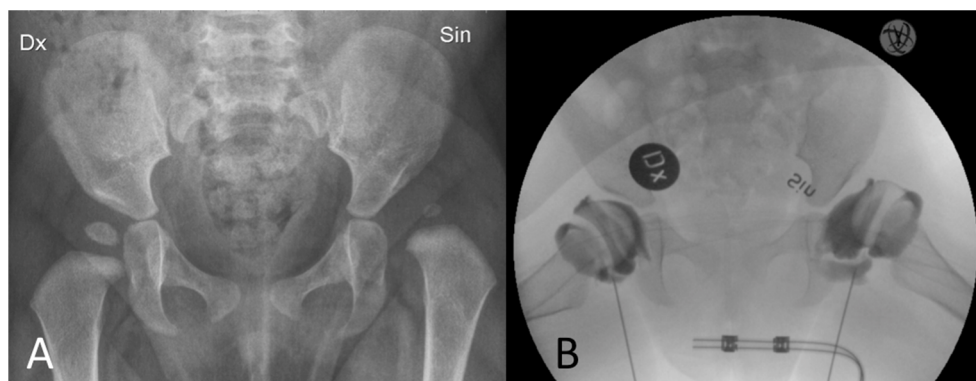
Table 2.

The Severin classification describes radiographic appearance in DDH (Severin 1941).

Severin class ¹	Description	Criteria
I (4%)	Normal development of the femoral head	a) CE angle $\geq 26^\circ$ ($\geq 20^\circ$ if 6 – 13 years) b) CE angle $20^\circ - 25^\circ$ ($15^\circ - 19^\circ$ if 6 – 13 years)
II (7%)	Some malformation of the femoral head	a) as in I b) as in I
III (8%)	Acetabular dysplasia	CE angle $< 20^\circ$ ($< 15^\circ$ if 6-13 years)
IV (44%)	Subluxation	a) CE angle $\geq 0^\circ$ b) CE angle $< 0^\circ$
V (13%)	Dislocation with secondary acetabulum at the lateral margin of the original acetabulum	
VI (17%)	High dislocation (with or without secondary acetabulum)	

¹ The numbers in parenthesis give the overall distribution of Severin's material (417) hips, i.e. the results at 5-27 years follow-up after closed reduction of late diagnosed hip dislocations. 7% are unaccounted for as 20 patients had died, 2 had moved abroad and 2 refused follow-up.

In his thesis, Severin also developed a radiographic classification that is still in use (Table 2) and described how hip arthrography can give additional information on joint congruency and soft tissue interposition (Severin 1939) (Figure 2).

**Figure 2.**

A. The left hip is dislocated and there is acetabular dysplasia. The femoral head is less ossified compared to the healthy right side. B. At arthrography, the complete femoral, including the non-ossified cartilage, is visualized, making it easier to assess dynamic stability, joint congruency and the presence of interposing soft-tissue in the joint.

Severin later described the incidence of late diagnosed hip dislocation in Sweden in the birth cohort of 1936 – 1945 using hospital files from all orthopedic clinics at the Swedish “Institutes for the disabled”. The 641 patients identified gave an incidence of 0.9 per 1,000 live births (Severin 1956).

In 1950, the Swedish pediatrician Kurt Palmén began systematically examining newborn children using the Ortolani test, in the town Falköping. He constructed a simple device to treat dislocated hips in abduction. In 1952 he wrote to fellow pediatricians at 21 Swedish hospitals, urging them to screen for hip dislocation in newborns, and in 1953 he extended the recommendation to all maternity units in the country (Palmén 1984). Palmén included a subluxation provocation test in his clinical examination of newborns in 1956, which he described in his 1961 PhD Thesis (Palmen 1961). The same test was presented by Thomas Geoffrey Barlow at the British Orthopaedic Association meeting of 1961 and now bears his name (Barlow 1962).

In my institution the head of the pediatric department, Per Selander, heeded Palmén's recommendation and started examining newborns systematically in 1952. The first child with a positive Ortolani test was referred to the Department of Orthopedics in 1953. An abduction splint was constructed from a sheet of aluminum covered with celluloid (Von Rosen 1956). From 1956 through 1963, practically all children born in Malmö were examined by Selander and treated by the head of the Orthopedic Department, Sophus von Rosen (Fredensborg et al. 1976). The incidence of late diagnosed hip dislocation in Malmö dropped to 0.07 per 1,000 live births (Fredensborg 1976b).

Palmén and von Rosen later showed that Swedish maternity units with a pediatric consultant had lower rates of late diagnosed hip dislocation compared to units with a less experienced physician performing the screening (Palmen et al. 1975). The National Board of Health and Welfare in Sweden issued recommendations on screening in 1957, and again in 1980.

Osteoarthritis (OA)

Osteoarthritis (OA) is a common joint disease that increases in prevalence with age (Dagenais et al. 2009) (Figure 3). In end-stage hip OA, there is severe joint pain and stiffness and limited walking ability. When oral analgesics and physiotherapy become insufficient in severe OA, hip arthroplasty surgery is indicated. There are more than 16,000 primary total hip arthroplasties (THAs) performed annually in Sweden, most often due to OA (Garellick et al. 2015). OA is considered to be mainly a disease of joint cartilage, although changes also occur in the bone.

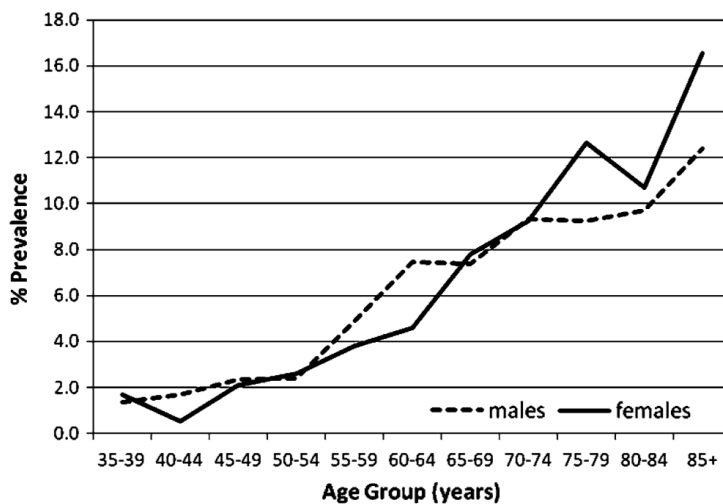


Figure 3. In a meta-analysis from 2009, the prevalence of primary hip OA was clearly seen to increase with age (Dagenais et al. 2009). Reprinted with permission from Springer Publishing.

Articular cartilage

One of the main constituents of joint cartilage is the anionic molecule glycosaminoglycan (GAG) that is bound in proteoglycan aggregates (Figure 4). The large proteoglycan molecules are contained within a collagen network. The strong negative electrochemical charge of GAGs gives the cartilage a negative fixed charge density attracting positive ions, of which sodium is the most abundant (Maroudas et al. 1977). The increased sodium content results in an osmotic gradient that causes water diffusion into the cartilage and creates a “swelling pressure” of the tissue that is important for the load bearing properties of the cartilage (Maroudas 1976, Little et al. 2011). GAG content is decreased in OA, and so is the fixed charge density (Venn et al. 1977).

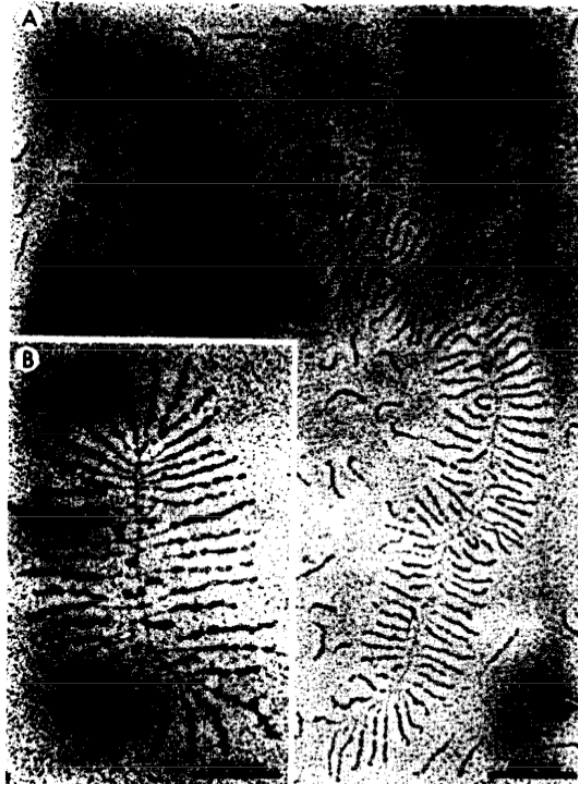

Figure 4. Electron micrographs of bovine cartilage proteoglycan aggregates. Reprinted from Buckwalter and Rosenberg (Buckwalter et al. 1988) with permission from Elsevier.

Radiography in OA

The American College of Rheumatology have proposed combined clinical, biochemical and radiographic criteria for the diagnosis of OA (Table 3) (Altman et al. 1991). The radiographic finding of osteophytes has a high sensitivity and specificity for OA and the addition of laboratory parameters only improves diagnostic performance marginally (Altman et al. 1991). Therefore, radiographic criteria are often used alone in studies on OA, most commonly the Kellgren-Lawrence classification (Kellgren et al. 1957, Dagenais et al. 2009) (Table 5).

Table 3.

Criteria for the diagnosis of hip OA according to the American College of Rheumatology (Altman et al. 1991).

ACR criteria of hip OA	
1.	Hip pain for most days of the previous month and at least 2 of the 3 following
2.	erythrocyte sedimentation rate < 20 mm
3.	Radiographic osteophytes
4.	Joint space narrowing

Even though radiography plays a central role both in clinical OA diagnosis and in reporting OA in scientific studies, there are some flaws in the method:

Already in the original presentation of the Kellgren-Lawrence classification, the authors reported a substantial inter-observer variability (Kellgren et al. 1957). They recommended that all radiographs in a scientific study should be read by the same observer, or that mean values from multiple observers should be used.

Another issue is that the association between radiographic changes and hip symptoms is not very strong (Kinds et al. 2011). This means that some patients with radiographic OA have little bother, whereas others may have joint pain with practically normal radiographs. The onset of pain in DDH is typically earlier than radiographic OA changes (Wiberg 1939b).

Despite these issues, Kellgren-Lawrence grading of OA is clearly associated with hip pain (Jacobsen et al. 2004b).

More recently, measurement of the minimum joint space width (minJSW) has been proposed for the study of OA (Jacobsen et al. 2004b, Jacobsen et al. 2004c, Terjesen et al. 2012a).

delayed Gadolinium Enhanced Magnetic Resonance Imaging of Cartilage (dGEMRIC)

delayed Gadolinium Enhanced Magnetic Resonance Imaging of Cartilage (dGEMRIC) is a contrast-enhanced magnetic resonance imaging (MRI) technique for depicting the chemical composition of cartilage. The negatively charged MRI contrast agent gadolinium diethylene triamine pentaacetic acid ($\text{Gd}(\text{DTPA})^{2-}$) is water soluble. As water is freely exchangeable in cartilage (Maroudas et al. 1977), the $\text{Gd}(\text{DTPA})^{2-}$ will distribute in the cartilage in inverse relation to the likewise negatively charged GAGs (Bashir et al. 1997, Bashir et al. 1999) (Figure 5).

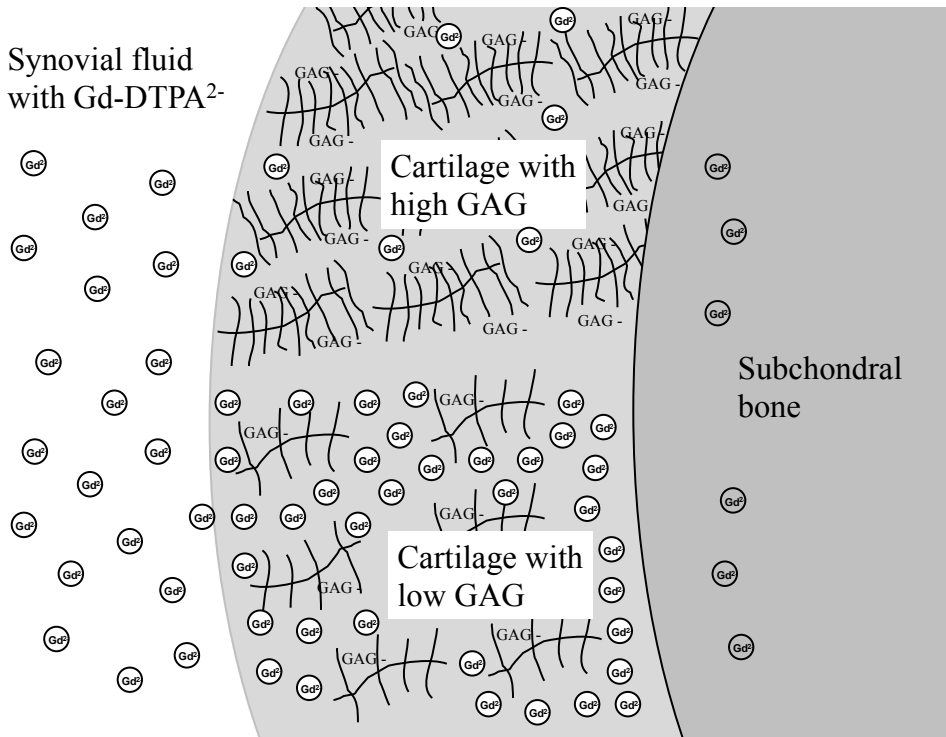


Figure 5.

In cartilage with early OA there is a decreased GAG concentration. Intravenously injected $\text{Gd}(\text{DTPA})^{2-}$ diffuses from the synovial fluid into the cartilage. At steady-state, the contrast agent $\text{Gd}(\text{DTPA})^{2-}$ is distributed in the cartilage in inverse relation to the concentration of negatively charged GAGs. Areas with different $\text{Gd}(\text{DTPA})^{2-}$ concentration will give different $T_{1\text{Gd}}$ values, which can be calculated, voxel by voxel, from MRI images with different inversion times. Image slightly modified and reprinted with permission from Carl Johan Tiderius (Tiderius 2004).

As $\text{Gd}(\text{DTPA})^{2-}$ shortens the MRI relaxation time (T_1), quantitative T_1 analysis can be used to estimate the GAG concentration in the cartilage. A low GAG concentration results in a high concentration of $\text{Gd}(\text{DTPA})^{2-}$, and hence, a low T_1 . T_1 in the presence of $\text{Gd}(\text{DTPA})^{2-}$, is referred to as $T_{1\text{Gd}}$, and the average $T_{1\text{Gd}}$ in a cartilage region is called the dGEMRIC index (Burstein et al. 2001).

The calculated $T_{1\text{Gd}}$ correlates closely to quantitative calculations of GAG concentration in tissue samples and histological staining of GAG distribution (Bashir et al. 1999). In vivo dGEMRIC of osteoarthritic cartilage has also been validated against histological staining of samples excised during knee arthroplasty (Bashir et al. 1999). In vitro dGEMRIC correlates to the mechanical stiffness of the tissue (Samosky et al. 2005). dGEMRIC is sensitive enough to show differences between cartilage regions with different local contact stress (Hingsammer et al. 2015) and at different depths of the cartilage (Hawezi et al. 2011) due to time dependent diffusion and the depth-wise distribution of GAG.

DDH and OA

Hips with acetabular dysplasia have elevated contact pressures on the joint surfaces (Michaeli et al. 1997, Russell et al. 2006). DDH is an established risk factor for OA, both in cross-sectional studies (Jacobsen et al. 2005a, Jacobsen et al. 2005b, Klit et al. 2011), a case-control study (McWilliams et al. 2010), and in prospective studies with incident OA or THA as outcome (Reijman et al. 2005, Agricola et al. 2013, Thomas et al. 2014).

In 1995–2009, 1.8% of all THAs in Sweden were performed due to DDH (according to surgeons' reports). Corresponding numbers from Denmark and Norway were 2.1% and 7.5% respectively (Engesaeter et al. 2012). The accuracy of surgeon's reports has been validated both in Denmark (Pedersen et al. 2004) and Norway (Engesaeter et al. 2011). THA surgery, i.e. end-stage OA, typically occurs earlier in DDH patients compared to patients with primary OA (Engesaeter et al. 2012), with 12% being < 40 years old at the time of surgery (Garellick et al. 2015). In Norway, 26% of all THAs in patients ≤ 40 years old and 18% of all THAs in patients < 60 years old are performed due to DDH (Furnes et al. 2001, Engesaeter et al. 2011).

In Norway, children with NIH have a 2.6 (1.4-4.8) times risk of having a THR before the age of 38 (Engesaeter et al. 2008).

The natural history of hip dislocation

If left untreated, a dislocated hip develops an abduction contracture and leg shortening can be noticed. As the child begins to walk, sometimes later, he or she will limp. A false acetabulum may develop where the dislocated hip is in contact with the ilium. Such false joints often develop early OA (Wedge et al. 1979, Weinstein 1987). If the femoral head is only subluxated in the native but dysplastic acetabulum, OA can develop very early (Cooperman et al. 1983) and is almost certain to occur (Wiberg 1939a). The degree of uncovering of the femoral head is related to the age at onset of pain (Wiberg 1939b, Murphy et al. 1995). In unilateral hip dislocation, secondary valgus knee deformity and OA is common, and secondary scoliosis of the spine can also develop (Wedge et al. 1979).

A case study

The case study in Figure 6 illustrates several important points.

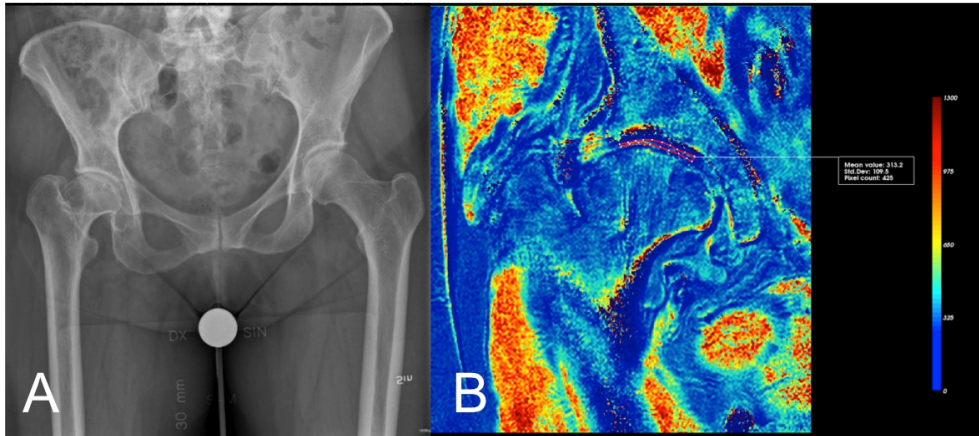


Figure 6.

A. Radiograph of a patient who was diagnosed with a right-sided hip dislocation at 3-months age, before screening for NIH was instituted in Sweden. After closed reduction and lengthy cast treatment, avascular necrosis of the femoral head developed. She had 3 cm leg shortening. After a life of poor hip function but moderate pain, she suffered a rapid deterioration at age 67. Despite narcotic analgesics, her walking distance was reduced to less than 50 m and she could sleep for only 3-4 hours per night due to hip pain. She then had a THA. The femoral head is deformed and the femoral neck is short due to growth disturbance from avascular necrosis. Despite the severe symptoms, radiographic signs of OA are sparse. B. dGEMRIC study of the right hip. The dGEMRIC index of 313 ms indicates GAG loss, i.e. the disease process of OA has begun. Images printed with kind permission from the patient.

- Avascular necrosis of the femoral head (AVN) can be a serious complication to treatment of late diagnosed hip dislocation.
- A hip with poor biomechanics is at high risk of developing OA.
- OA is not always visible on radiographs, despite severe symptoms.
- dGEMRIC is a sensitive tool for assessing cartilage quality.

Thesis' aims

The aims of the four studies in this work were to describe the outcomes of early treatment for NIH with the von Rosen splint and to study the efficacy of screening for DDH in Sweden. More specifically, we have studied:

- Acetabular morphology at 1 year after early treatment.
- The risk of AVN after early treatment.
- The ossification of the femoral head epiphysis at 1 year in hips with NIH.
- Outcomes after the completion of growth in hips with NIH that were treated early but still had residual acetabular dysplasia at 1-year age. Clinical outcome, radiographic measurements of DDH and OA, and dGEMRIC measurements of hip cartilage quality were studied.
- The relationship between radiographic measures of DDH and the dGEMRIC index in a group of young adults with a history of NIH.
- The epidemiology of late diagnosed hip dislocation in Sweden during the ten-year period 2000-2009.

Methods

”The surgeon who does not keep in touch with his patients until they reach adult life is ignorant of their fate, and understandably happy with his results.”

– Ian MacKenzie 1972

Study subjects

Papers I and II

In Papers I and II, children who had been referred to the Orthopaedic Department in Malmö on suspicion of NIH were included. In Paper I, children born from April 2002 through December 2007 were included. In Paper II, we included children born from 2003 through 2010. The study periods are largely overlapping and no change was made in the screening program during this time.

Only children examined and treated within 7 days from birth were included.

Roughly half of all neonates referred to the Orthopaedic Department had their suspected NIH confirmed by the pediatric orthopaedic surgeon, often by aid of dynamic sonography. Children with a positive Barlow- or Ortolani sign were treated for 12 weeks in the von Rosen splint. Children where the femoral head could be subluxated > 25% of its diameter, but not dislocated, were treated for 6 weeks. The other half of the referrals, children who were cleared from suspicion of NIH, were followed-up identically as the children treated for NIH. In Papers I and II, they constituted a reference group for comparison of radiographic measurements.

Paper III

The study subjects in Paper III were also children who had been treated early for NIH. All had a positive Barlow- or Ortolani test and were treated for 12 weeks in the von Rosen splint. The aim of the study was to describe longer-term outcomes,

after completion of growth, in a subset of patients who had not normalized fully by 1 year. 1-year radiographs from all children treated from 1987 through 1993 were reviewed, and those who had an AI of $\geq 28^\circ$ were eligible for the study. Of 30 such cases, 21 could be contacted and agreed to participate. We selected the subjects with the worst radiographic outcome at the end of our regular follow-up of children with NIH in order to increase the likelihood of finding subjects with a poor outcome.

Paper IV

In Paper IV, all children born in Sweden from 2000 through 2009 were included, as screening examination for hip instability is mandatory in Swedish maternity units. There were 1,013,589 children born during the study period.

The Swedish screening program is based on clinical hip examination using the Barlow and Ortolani tests (Barlow 1962, Ortolani 1976). A few maternity wards add a sonographic assessment of dysplasia (Graf 1984). In some institutions, such as mine, dynamic sonography is used to aid the clinical examination in cases where hip stability cannot be clearly determined (Dahlstrom et al. 1986).

Repeated hip examinations at child health care centers are commonly performed by general practitioners at 6-8 weeks, 6 months, and 10-12 months age. Further assessments of physical and mental development are performed at 1½, 2½-3, 4 and 5-6 year's age.

Outcome measures

Paper I – the acetabular index (AI)

The acetabular index (AI) is a commonly used radiographic measure of acetabular dysplasia in children from ~ 3-months age to the closure of the tri-radiate cartilage (Figure 7). It was first described in 1925 by Heinrich Hilgenreiner (Thieme et al. 1986). Measurements of AI on film will be within 5-6° of the true value in 95% of readings (Broughton et al. 1989, Boniforti et al. 1997). We calculated the variability of measurements of the AI by measuring the AI in 22 randomly chosen subjects (44 hips) on two occasions, with a minimum 3 months interval. My systematic error of measurement was 0.2% and my coefficient of variation was 3.3%. More details on the calculations of variability are given in Paper I. The reason for the high reproducibility of measurements in Paper I may be that I used

digital radiographs with a software tool for measuring angles. I performed all the measurements for the study results in order to eliminate any inter-observer variability.

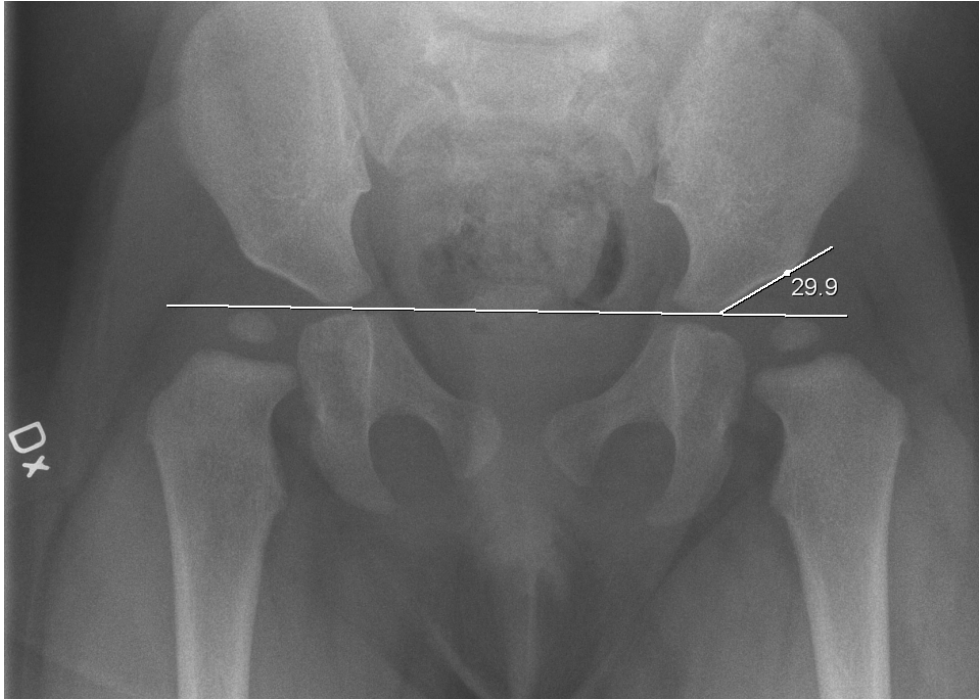


Figure 7.
The AI is the angle between a horizontal line (The Hilgenreiner line), drawn between the tri-radiate cartilages of the hips, and the "slope" of the acetabulum on a frontal pelvic radiograph. A higher value corresponds to a more dysplastic acetabulum.

As the AI normally decreases during growth (Tonnis 1976), we included only radiographs taken within 1 month from the subject's 1-year birthday. Measurements of the AI are also sensitive to rotation of the pelvis. Therefore, we excluded radiographs with rotation in the axial plane (defined as a foramen obturator index < 0.56 or > 1.8) or in the sagittal plane (Tonnis 1976).

Paper II – the Kalamchi-MacEwen classification

The Kalamchi-MacEwen classification of AVN was described in 1980 (Kalamchi et al. 1980). It describes the location of changes in the growing hip as seen on an anteroposterior (AP) radiograph (Table 4). The authors based the classification on 119 patients (153 hips) with AVN following treatment for hip dislocation and

found it to be predictive of outcome. A higher Kalamchi-MacEwen group of AVN is associated with a worse outcome. The 1-year radiographs of all children referred on suspicion of NIH (both treated children and those cleared of suspicion), as well as all pelvic and hip radiographs taken for any reason at a later date, were reviewed for AVN changes. The observation time was to age 6.5 (2.8-11) years.

Table 4.
The Kalamchi-MacEwen classification of AVN.

Kalamchi-MacEwen group	Description
I	Changes affecting the ossific nucleus.
II	Lateral physeal damage.
III	Central physeal damage.
IV	Total damage to the head and the physis.

Paper II – the diagnosis registry of ICD-10 codes and hospital files

The International Statistical Classification of Diseases and Related Health Problems – Tenth Revision (ICD-10) is a classification of diagnoses issued by the World Health Organization. The ICD-10 is translated to Swedish by the National Board of Health and Welfare (Socialstyrelsen 2010). In Sweden, it is used in practically all health care and statistics based on ICD-10 codes are commonly used to allocate resources for health care. We searched a registry of ICD-10 diagnoses covering the catchment areas of our hospital and the two neighboring hospitals (Lund University Hospital and Trelleborg Hospital). The ICD-10 codes M870, M911, and M918 were used in the search.

We also reviewed the hospital files of all treated patients. The subjects were 6.5 (range: 2.8-11) years old at the time of the search.

Paper II – the size of the ossific nucleus

The maximum diameter was measured on AP pelvic radiographs according to Figure 8. As the ossific nucleus grows we only included radiographs taken within 1 month from the subject's 1-year birthday. We also excluded children with treatment start later than 7 days from birth. The intra-observer variability was determined by measuring 40 hips twice with 2 months interval. The coefficient of variation was 1.9%. The systematic error was 0.004 mm. My co-author, Hanna Samuelsson, performed all the measurements in order to eliminate any inter-observer variability.

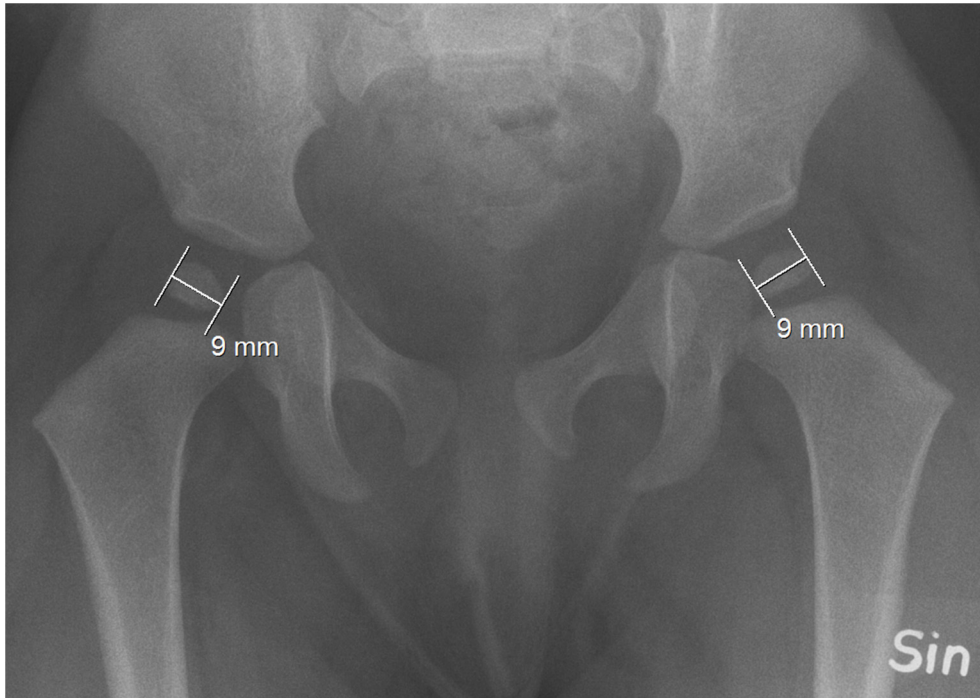


Figure 8.
The maximum diameter of the ossific nucleus was measured on AP pelvic radiographs taken at 1-year age.

Paper III – radiographic measures of DDH in adults

The 21 subjects included in Paper III underwent AP pelvic radiographs. Three commonly used radiographic measures of DDH were analyzed: the center-edge angle of Wiberg (CE angle), the femoral head extrusion index (FHEI) and the Sharp angle.

The CE angle was described by Gunnar Wiberg in Malmö (1939b) and is a widely used measure of DDH (Figure 9). The CE angle decreases both if there is acetabular dysplasia and if there is subluxation or dislocation of the hip. As measurements of the CE angle are sensitive to pelvic rotation in the axial plane, the Tönnis index (Tönnis 1976) should be between 0.7 and 1.8 in order to keep measurement variations within 2° (Jacobsen et al. 2004a). The CE angle is also sensitive to pelvic rotation in the sagittal plane (Henebry et al. 2013).

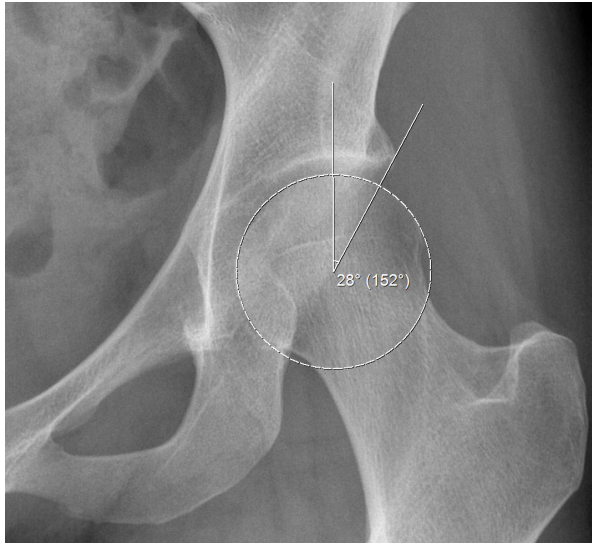


Figure 9.

The CE angle of Wiberg is the angle formed between a vertical line (the normal to a line between the two centers of the femoral heads) and a line drawn from the center of the femoral head to the lateral point of the acetabulum.

The FHEI was originally intended as an outcome measure after Legg-Calvé-Perthes disease (Heyman et al. 1950) (Figure 10). It is frequently used in studies on DDH. Measurements of FHEI are not very sensitive to pelvic rotation (Jacobsen et al. 2004a).

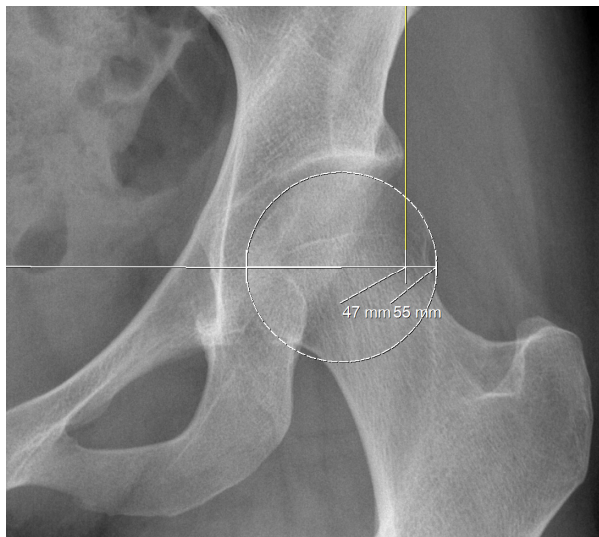

Figure 10.

The FHEI describes the proportion of the femoral head that is covered under the roof of the acetabulum.

The Sharp angle was first described by Ullman in 1938 (German), but was initially thought to vary too much in the normal population to be useful (Severin 1941). It was described again in 1961 by Ian Sharp as a measure of DDH (Sharp 1961) (Figure 11). The Sharp angle measures acetabular dysplasia without taking the position of the femoral head into account. It is sensitive to pelvic rotation in the sagittal plane (Henebry et al. 2013).

Both the CE angle and the FHEI can be measured with high reproducibility (Jacobsen et al. 2005a, Jacobsen et al. 2005b, Terjesen et al. 2012b).

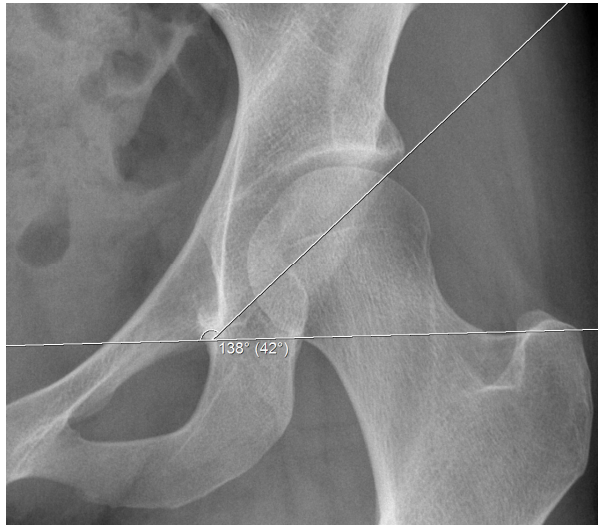


Figure 11. The Sharp angle is a measure of acetabular dysplasia in isolation. It is defined as the angle between a horizontal line and a line from the inferior border of the pelvic teardrop and the lateral edge of the acetabulum.

Paper III – the Kellgren-Lawrence classification of OA

The radiographic classification of Kellgren and Lawrence may be the most commonly used in scientific studies of hip OA (Dagenais et al. 2009). It is based on the presence of osteophytes, periarticular ossicles, joint space narrowing associated with subchondral sclerosis, pseudocysts and altered bone shape. The classification was presented with a small atlas of radiographs for different joints: the finger joints, the base of the thumb, the wrist, the cervical spine, the hip and the knee (Kellgren et al. 1957). A supplementary atlas of radiographs was published by the Osteoarthritis Research Society International in 2007 with the intention to facilitate uniform reporting in scientific studies (Altman et al. 2007). Grading of OA is performed according to Table 5. I used both AP pelvic radiographs and AP and lateral hip radiographs in the assessment of OA.

Table 5.

The Kellgren-Lawrence classification. In scientific studies, the cut-off between OA and non-OA is commonly at Kellgren-Lawrence grade 2.

Radiographic OA appearance	Kellgren-Lawrence grade
None	0
Doubtful	1
Minimal	2
Moderate	3
Severe	4

Paper III – the minimum joint space width (minJSW)

The minJSW was measured using AP pelvic radiographs according to Figure 12. A minJSW < 2 mm is associated with self-reported hip pain (Jacobsen et al. 2004c, Jacobsen et al. 2004b). Joint space width measurements are not significantly affected by rotation of the pelvis in the axial plane and can be measured with high reproducibility (Jacobsen et al. 2004c, Jacobsen et al. 2005a, Terjesen et al. 2012b).




Figure 12.

The minJSW is the smallest of 3 distances, measured from the subchondral bone of the femoral head to the acetabulum in the medial, central and lateral part of the weight-bearing dome of the hip joint. In this case the minJSW is 4.1 mm, measured in the medial aspect of the joint.

Paper III – dGEMRIC

We used the dGEMRIC index of the entire weight-bearing joint surface in the mid-coronal plane as outcome measure (Figure 13).

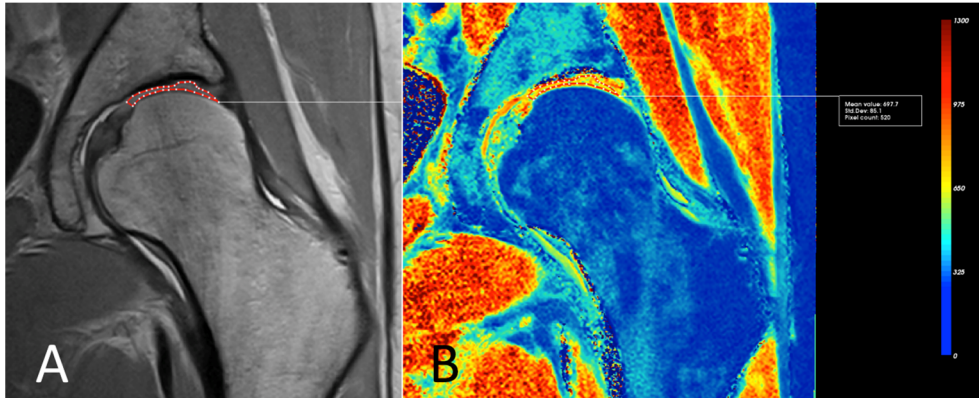


Figure 13.

A. The region of interest (ROI) is drawn manually on the midcoronal section of the hip MRI, using the anatomical image that gives the best visual contrast between cartilage and subchondral bone. B. The software calculates the T_{1Gd} of each voxel. The dGEMRIC index is the mean T_{1Gd} of the ROI.

As dGEMRIC is sensitive to changes in cartilage GAG content, it is also sensitive to disturbances. The method is reproducible to within 10-15% when measurements are made at two separate time points, but it is crucial that a strict protocol be followed (Burstein et al. 2001).

The $Gd(DTPA)^{2-}$ diffuses into the cartilage from the synovial fluid in a time-dependent manner (Tiderius et al. 2001, Hawezi et al. 2011). Standardized exercise and a 30-90 minute time window between contrast administration and imaging are necessary for complete $Gd(DTPA)^{2-}$ uptake in the cartilage (Burstein et al. 2001). Contrast agent was dosed by patient body-weight (Burstein et al. 2001) and the dGEMRIC index was corrected for body mass index (BMI), as it affects the distribution volume of the water soluble $Gd(DTPA)^{2-}$ (Tiderius et al. 2006). The dGEMRIC protocol used in Paper III is given in detail in Table 6.

Table 6.

The dGEMRIC protocol for imaging hip cartilage in Paper III.

Parameter	Protocol
Time from contrast injection to imaging start	60 minutes
Exercise after contrast injection	10 minute timed walk
Intravenous dose of Gd(DTPA) ²⁻	0.2 mmol/kg
Magnetic field strength	1.5 T
Receiver coils	One flexible Body Matrix coil directly over each hip
Repetition time (TR)	1840 ms
Exho time (TE)	15 ms
Inversion times (TI)	1650, 650, 350, 250 and 50 ms ¹
Field of view (FoV)	140x140 mm ²
Imaging matrix	256x256
Slice thickness	3 mm
dGEMRIC calculation	Exclusion of voxels with $T_{1Gd} > 1300$ ms Mathematical correction for BMI

¹ The 5 different inversion times are used to create 5 images using a turbo inversion recovery pulse sequence. The T_{1Gd} is calculated for each voxel from its MRI signal in the 5 images.

Paper III – the 12-item WOMAC score

The 12-item WOMAC score is a subset of questions from the commonly used WOMAC (The Western Ontario and McMaster Universities Arthritis Index) questionnaire. The WOMAC score was introduced and validated in the late 1980:s (Bellamy et al. 1988) and is a commonly used outcome measure in studies on hip and knee OA. It has been validated in Swedish translation for patients receiving a THA (Soderman et al. 2000). As there are floor effects with the WOMAC questionnaire, we chose the 12-item WOMAC, which is sensitive also to less severe hip disease (Rothenfluh et al. 2008).

The 12-item WOMAC contains 12 questions on hip pain and function. The subject marks each question on a Likert scale from 0 (indicating no symptoms/problems) to 4 (indicating severe symptoms/problems). The total score is calculated by adding the score for each item. In the original description of the 12-item WOMAC the score ranged from 0 to 47, as item 4 was reduced to 4 options: 0 to 3 (Rothenfluh et al. 2008). To make it practically manageable we used the same Likert scale: 0 to 4, also for item 4. This change shouldn't significantly affect the results (personal communication with the author). Thus, the 12-item WOMAC score could range from 0 to 48.

Paper IV – late diagnosed hip dislocation

Children with hip dislocation were registered prospectively from January 2000. Registration is ongoing and today the registry has earned the status of a National Quality Registry, forming a part of the SPOQ (the Swedish Pediatric Orthopaedic Quality Registry).

A late diagnosed hip dislocation was defined as one diagnosed later than 14 days from birth. Children with neuromuscular or teratogenic hip dislocation were excluded. Only children born in Sweden were included, as the aim of the study was to assess the effectiveness of the Swedish screening program.

Paper IV –Tönnis grading of hip dislocation

I graded the initial radiographs of all children with late diagnosed hip dislocation, except 8 where radiographs could not be retrieved, according to Tönnis (1987). In 4 of the “missing” radiographs, only sonography had been used to diagnose the dislocation. In the other 4 cases, radiographs had been taken but had since been destroyed. The Tönnis grading system is based on an AP pelvic radiograph and describes the position of the ossific nucleus of the femoral head relative to the Perkin’s line and a horizontal line drawn between the lateral points of the left and right acetabulum (Table 7).

Table 7.

The Tönnis grading system describes the displacement of the femoral head in relation to the acetabulum.

Tönnis grade	Position of the ossific nucleus of AP pelvic radiograph
1	Medial to Perkin's line
2	Lateral to Perkin's line
3	Level with the lateral edge of the acetabulum
4	Above the lateral edge of the acetabulum

Software and Statistics

Radiographs and MRI images were viewed with the Sectra PACS software (Sectra, Linköping, Sweden). Measurements on radiographs were performed using the Sectra PACS software (Sectra, Linköping, Sweden). Drawing of ROIs and calculating the dGEMRIC index was done with MedMap (Dept. of Medical Radiation Physics, Lund University, Malmö, Sweden).

Statistical calculations were performed with Microsoft Excel for Mac 2011, version 14.2.3 (Redmond, WA: Microsoft Corp.), SigmaPlot 11.0 (Systat Software Inc., Richmond, CA, USA), and SPSS versions 21.0 for Mac and 22.0 for Mac (IBM Corp., Armonk, NY, USA).

For comparisons of continuous variables between groups, the Student's t-test was used for normally distributed data and the Mann-Whitney Rank Sum test was used for data that failed normality testing (Shapiro-Wilk Statistic < 0.95). Pearson's chi-squared test was used to compare frequency distributions of categorical data. In Paper III, the mixed-effects model was used to estimate regression coefficients. Confidence intervals for proportions were calculated using binomial distribution. In Paper IV, we used Poisson regression to analyze time trends in incidence. P-values < 0.05 were considered statistically significant.

Ethics

The Lund University Institutional Review Board approved the studies:

Papers I and II (LU 2013/605)

Paper III (LU 2008/348)

Paper IV (LU 1999/578 and LU 2014/736).

Results and Discussion

“However the early diagnosis of congenital dislocation of the hip is unfortunately a rare occurrence in our country. Consequently we have only been able to treat a few cases before the age of one year.”

- Erik Severin 1941

How common is NIH?

The incidence of NIH in Malmö was 7 per 1,000 live births from 2003 through 2010 (Paper II). The same incidence was found in our institution in the 1990:s (Danielsson 2000, Duppe et al. 2002) and in the mid-1960:s (Palmen et al. 1975). A large study from Gothenburg found 7.2 NIH cases per 1,000 live births in 1961 – 1970. However, the incidence of NIH depends not only on biological factors in the newborn population but to a large extent on the design of the screening program. Therefore, the incidence of NIH has varied over time in Malmö (Table 8) and it has also varied greatly between different institutions in Sweden (Palmen et al. 1975).

Table 8.

The incidence of NIH in Malmö in different time periods.

Study	Time period	Incidence of NIH (per 1,000 live births)	Comment
(Fredensborg 1976b)	1956-1964	4.0	One experienced pediatrician.
(Fredensborg et al. 1976)	1965-1972	15	Many pediatricians.
(Duppe et al. 2002)	1980-1989	17	14 – 22 pediatricians each year
(Duppe et al. 2002)	1990-1999	6.6	9 – 16 pediatricians each year
Paper II	2003-2010	7.0	Examination supplemented by dynamic sonography.

It is not surprising to find wide variations in reported NIH incidence from different parts of the world (Table 9).

Table 9.

The incidence of NIH and the success of screening programs have varied greatly in publications from different parts of the world.

Study	Country, time period	Incidence of NIH (per 1,000 live births)	Late dislocation rate (per 1,000 live births)
(Barlow 1962)	England, 1957-1962	15	0 (5,496 births)
(Dunn et al. 1985)	England, 1970-1979	19	0.88
(Fiddian et al. 1994)	England, 1982-1992	5.3	0.31
(Gardiner et al. 1990)	England, 1988-1989	9.3	0.12
(Mitchell 1972)	Scotland, 1962-1968	3.1	0.13
(Bertol et al. 1982)	Scotland, 1969-1978	6	0.62
(Burger et al. 1990)	The Netherlands, 1971-1979	9.8	0.21
(Lehmann et al. 1981)	Canada, 1967-1971	5-6	0.3-0.8 ¹
(Myers et al. 2009)	New Zealand, 1964-2004	16 ²	0.14
(Engesaeter et al. 2008)	Norway ³ , 1967–2004	8.8	
(Palmen et al. 1975)	Sweden ³ , 1963	5.6	

¹ Data from 2 hospitals where the clinical examinations were performed by physicians with different levels of experience.

² Neonatal incidence of 39 per 1,000 live births dropped to 16 per 1,000 after a 3-4 days wait-and-see period.

³ Nationwide study.

Since many hips with NIH stabilize spontaneously, the incidence of NIH will depend on the age at which the examination is performed. Thomas G. Barlow, who performed clinical examinations of newborn once weekly, noted that the incidence of NIH was 60% lower in children examined at the end of their first week compared to those examined within the first days from birth (Barlow 1962, Barlow 1963). At 2 months, 88% of the children with NIH had normalized spontaneously (Barlow 1962). Other authors have reported normalization rates of ~ 50% within the first 5 days to 3 weeks (MacKenzie 1972, Hadlow 1988). Barlow's finding that many neonatally unstable hips normalize spontaneously is the rationale for the so-called "wait-and-see" policy (delaying treatment during a period of repeated examinations, thus lowering treatment rates). However, it could also be interpreted as evidence that the clinical examination is most sensitive if performed very early. Barlow himself reflected that "muscular activity appears to be a very potent factor in spontaneous recovery" and that at 2 months age "these children proved just as difficult to treat as children whose dislocated hips are discovered after a year" (Barlow 1962). In a study from New Zealand, adopting a wait-and-see policy for 3-4 days reduced the treatment rate from 3.9% to 1.6%, but this was at the cost of a nearly doubled rate of late presenting hip dislocation (Myers et al. 2009).

The reported incidence of NIH, as well as the rate of late diagnosed hip dislocation, also depends on the skill of the person performing the screening. In

Edinburgh, the rate of splintage fell from 6 to less than 3 per 1,000 live births when more experienced examiners performed the neonatal screening (Macnicol 1990). In our institution, both referral rates from pediatricians and treatment rates decreased when fewer people were involved in the screening (Duppe et al. 2002) (Table 10). In contrast, Lehmann and Street reported no big difference in NIH incidence comparing one dedicated orthopedic surgeon to a group of orthopedic residents (though infants examined by the former ran a much lower risk of having a late diagnosed hip dislocation) (Lehmann et al. 1981).

Table 10.

When fewer pediatricians were involved in the neonatal screening for NIH in the 1990:s, referral rates and treatment rates dropped and results were markedly improved compared to the previous decade (Duppe et al. 2002).

	Incidence 1980:s (per 1,000 live births)	Incidence 1990:s (per 1,000 live births)
Referred from the maternity unit	31.7	12.9
Treated (suspicion of NIH confirmed)	16.9	6.6
Late diagnosed cases	0.51	0.07

The positive predictive value of the pediatricians' examinations has been 40-50% in Malmö through the last decades (Duppe et al. 2002). A Norwegian study, comparing 6 pediatricians with different levels of experience found sensitivity to detect NIH ranging from 20-100% and positive predictive values ranging from 27-92% (Finne et al. 2008).

Results of early treatment

Papers I, II and III are follow-up studies of patients who were treated early for NIH in Malmö. The results are discussed below.

Acetabular dysplasia at 1 year (Paper I)

Hips with NIH had a higher AI compared to hips that were clinically normal in the neonatal period (Figure 14). Both hips that were dislocated or dislocatable and hips that could be subluxated $\geq 25\%$ of the femoral head diameter had a higher AI compared to the reference group. There was no difference comparing the AI of Barlow-positive to Ortolani-positive hips.

Hips that were clinically normal in children with unilateral NIH had a higher AI compared to hips in untreated children (i.e. with bilaterally normal hips).

Left hips had a higher AI compared to right hips. However, in sub-analysis of the reference group, there was no side difference.

Girls had a higher mean AI compared to boys. The same finding has been made both in children treated for NIH (Hinderaker et al. 1992) and in a population based reference cohort (Tönnis 1976).

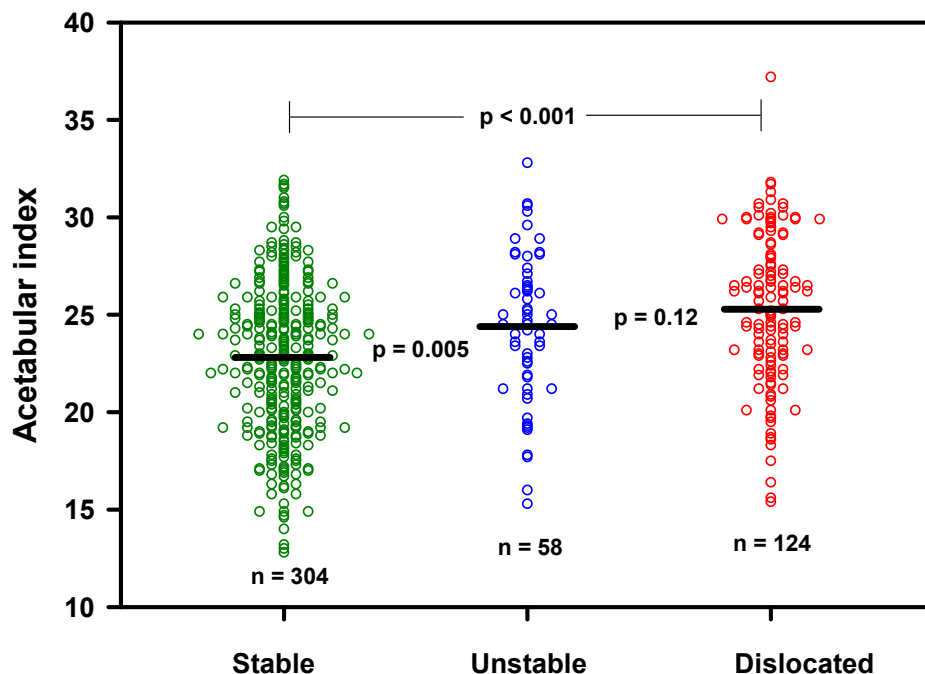


Figure 14. Both Barlow- and Ortolani-positive hips (to the right in the figure) and unstable hips (in the center of the figure) had higher AI at 1 year compared to the reference group. Each circle corresponds to an individual hip. P-values are given in the figure.

Paper I thus showed that hips with NIH are not fully normalized at 1 year despite early treatment. The cut-off between a dysplastic hip and a normal one has to be somewhat arbitrary, as the AI changes with age and there is no clear link between a certain AI and the risk of future hip disease. Tönnis reported reference values at different ages and suggested a cut-off at +2 SD from the mean (Tönnis 1976). Using +2 SD to define disease will lead to the unreasonable situation where 2.5% of the population is considered affected, regardless of the prevalence of hip

symptoms in the population. Furthermore, a hip with AI 27 would be classified as severely dysplastic if right-sided in a 1-year-old boy, but completely normal if left-sided in a girl of the same age (Tonnis 1976). In Paper III, we studied the outcomes of children with high AI following early treatment, aiming to establish the prognostic value of the findings in Paper I.

The finding that there was no difference in AI between right and left hips if they were stable neonatally challenges the idea that left hips would inherently be more dysplastic in the normal situation. A clear difference between left and right hips has been shown in population samples (Tonnis 1976), but the difference may be due to a higher incidence of instability on the left side; a concentric, stable hip being the main determinant of normal acetabular development.

We used clinical hip stability to group the study subjects. Dynamic sonography was used to refine the assessment. The dynamic sonography seems to lower treatment rates as half of the referred cases were cleared of suspicion at the sonographic examination. The sonographic examination depends on the skill of the examiners (Dunn et al. 1985, Macnicol 1990, Krikler et al. 1992, Fiddian et al. 1994, Wood et al. 2000, Lee et al. 2001).

We use sonography as an adjunct to the Barlow maneuver and not as a means of assessing acetabular morphology (Dahlstrom et al. 1986). In studies using sonography to assess acetabular dysplasia according to Graf (1984), the prevalence of dysplasia in neonates is high. One Israeli study found a 6.8% prevalence of dysplasia at 1-2 days age, of which 90% normalized spontaneously (Bialik et al. 1999). Another study found a 19% prevalence of sonographic acetabular dysplasia in clinically normal neonates (who developed normally without treatment) (Gardiner et al. 1990). In Bergen, Norway, 5.1% of all children born in 1989 were treated for DDH as newborns (Laborie et al. 2013) as a study on universal sonographic screening was performed that year (Rosendahl et al. 1994). Another study from England, found a 6% prevalence of acetabular dysplasia using the technique of Harcke et al. (1986). Using a wait-and-see approach, 90% of those hips normalized spontaneously. However, the hips that failed to normalize spontaneously had a 9% rate of treatment failure after the waiting period (Marks et al. 1994).

As the AI decreases with age, we only included children with follow-up radiographs taken within 1 month from their 1-year birthday. We excluded radiographs taken with rotation of the pelvis in the sagittal or axial plane, as this affects measurements of AI (Tonnis 1976), and children with treatment start later than 7 days. Together with a loss of follow-up of 7%, these strict inclusion criteria led to only 73% of all treated children during the study period being included in the study. Although loss to follow-up was more common in untreated children, it

seems improbable that the results of the radiographic measurements were affected by a selection bias.

Low risk of AVN (Paper II)

Of the 240 children who were treated for NIH in 2003-2010, 234 had 1-year radiographs taken. 229 had treatment started within 1 week from birth. We found 2 cases (0.9%) of group I AVN at 1 year. No further case appeared during a 6.5-year (range 2.8-11) observation period.

Group I AVN is reported to have a good prognosis (Kalamchi et al. 1980). However, as more severe AVN may sometimes appear as only group I changes initially, a long follow-up is recommended (Kalamchi et al. 1980, Koizumi et al. 1996, Cashman et al. 2002, Nakamura et al. 2007, Firth et al. 2010). This recommendation is based on studies on children undergoing reduction of a hip dislocation at a much older age. The Kalamchi-MacEwen material, for example, had a mean age of 11 months at reduction, compared to 3 days (range: 0-7) in Paper II. Other authors have reported that group I AVN can be diagnosed within a year from the reduction of the dislocated hip (Iwasaki 1983, Agus et al. 2010). We followed our 2 cases of AVN with repeat radiographs to the ages of 5 years 7 months and 8 years respectively. They were free of symptoms and developed normal hips. We also performed later radiographs in 2 children with late appearing femoral head epiphyses to ensure normal development.

The low risk of AVN found in Paper II is consistent with the finding from a previous case-control study, that children undergoing early treatment for NIH with the von Rosen splint have normal femoral head shape at 10 (8-16) years age (Fredensborg 1976b). The same finding was made at 5-15 years follow-up of 223 children treated early with the von Rosen splint (Lauge-Pedersen et al. 2006). A low risk of AVN (< 1%) in early treatment of NIH has been reported both for the von Rosen splint, the Aberdeen splint, the Frejka pillow and the Pavlik harness (Fredensborg et al. 1976, Dunn et al. 1985, Fiddian et al. 1994, Williams et al. 1999, Tegnander et al. 2001, Duppe et al. 2002, Finne et al. 2008, Myers et al. 2009). However, such studies have often been inadequate in reporting on methodology or focusing on other issues, giving only brief mention of AVN. A recent guideline document from the American Academy of Orthopaedic Surgeons commented that “AVN rates are inadequately reported” for different splints (National Guideline 2014). Paper II was specifically designed to assess the risk of AVN after early treatment with a methodology that allows reproduction.

In studies on the Pavlik harness in fairly young children (< 3 months old), the rate of AVN has been 1.6%-1.8% (Bradley et al. 1987, Cashman et al. 2002). If

treatment is initiated later however, the risk of AVN is higher (Iwasaki 1983, Pap et al. 2006, Nakamura et al. 2007, Ohmori et al. 2009).

The results from previous studies on AVN following abduction splinting are summarized in Table 11.

Table 11.

The incidence of AVN after treatment with various abduction splints.

Study	AVN risk, percent (95% CI)	no treated	splint	Age at reduction
Paper II	0.9 (0.1-3.1)	234	von Rosen	3 days (0-7)
(Fiddian et al. 1994)	0 ¹	255	Pavlik	≤ 2 days
(Duppe et al. 2002)	0.5 (0.0-2.8)	198	von Rosen	≤ 5 days
(Fredensborg et al. 1976)	0.2 (0.0-1.0) ¹	548	von Rosen	≤ 1 week ²
(Myers et al. 2009)	0.2 (0.0-0.8) ¹	663	von Rosen	≤ 1 week ²
(Hadlow 1988)	0.3 (0.0-1.7)	331	von Rosen	≤ 1 week
(Krikler et al. 1992)	0 ¹	468	von Rosen	≤ 1 week ²
(Williams et al. 1999)	0 ³	86	Aberdeen	≤ 1 week ²
(Dunn et al. 1985)	0 ¹	445	Aberdeen / von Rosen	≤ 1 week ²
(Tegnander et al. 2001)	0.9 (0.0-5.1)	108	Frejka	≤ 1 week
(Finne et al. 2008)	0 ¹	298	Frejka	≤ 10 days ²
(Bradley et al. 1987)	1.8 (0.4-5.0)	171	von Rosen / Pavlik	≤ 6 weeks
(Cashman et al. 2002)	1.6 (0.5-3.7) ⁴	316	Pavlik	≤ 3 months
(Kruczynski 1996)	8.1 (3.6-15)	99	Frejka	< 3 months
(Pap et al. 2006)	12 (9.9-14) ⁵	1064	Pavlik	3.2 months (0-7)
(Iwasaki 1983)	7.3 (4.0-12) ⁵	193	Pavlik	4 months (1-7)
(Nakamura et al. 2007)	20 (13-29) ⁴	115	Pavlik	4.8 months (1-12)

¹ Methodology not clearly reported.

² Outliers (older children) possibly included.

³ Treatment mainly based on acetabular dysplasia (Graf method).

⁴ Not including patients where treatment failed to reduce the dislocation: 16 patients (5%) (Cashman et al. 2002) and 38 patients (18%) (Nakamura et al. 2007) respectively.

⁵ Incidence per hip.

It is difficult to say from the existing literature if AVN risk is mainly dependent on the type of abduction splint or the age at treatment start. The Pavlik harness is typically used in older children, where the von Rosen splint is not sufficient to keep the hips concentrically reduced. The Pavlik harness has been associated with complications such as inferior hip dislocation (Lerman et al. 2001), medial knee instability (Schwentker et al. 1983) and nerve palsies of the femoral nerve and brachial plexus (Mooney et al. 1994, Murnaghan et al. 2011), indicating that the device can exert substantial pressure. The risk of AVN in the Pavlik harness

increases with later treatment start (Bradley et al. 1987, Grill et al. 1988). Kruczynski (1996) made the same finding using the Frejka pillow. One study reported 0 cases in 255 children with early treatment start in the Pavlik harness (though the methodology to assess AVN was not mentioned in that paper) (Fiddian et al. 1994).

In my view, the diagnosis of NIH should be made as early as possible and treatment should not be delayed.

The Frejka pillow is abandoned in most parts of Sweden due to a higher risk of treatment failure compared to the von Rosen splint (Hansson 1980, Heikkila 1988, Hinderaker et al. 1992). The von Rosen splint also outperforms the Pavlik harness and the Craig splint in early treatment (Wilkinson et al. 2002). However, the von Rosen splint should not be used in children older than 3 months in order to avoid treatment failures.

Slower ossification of the femoral head epiphysis (Paper II)

The size of the ossific nucleus was smaller in hips with NIH (Figure 15). There was a dose-response relationship with a higher degree of instability neonatally leading to a smaller ossific nucleus at 1 year. The finding that NIH leads to slower ossification of the femoral head epiphysis has been reported previously (Fredensborg 1976b, Bertol et al. 1982, Williams et al. 1999). Fredensborg also noted that in cases of bilateral NIH with differing degree of instability, the less stable hips ossified slower (Fredensborg 1976b).

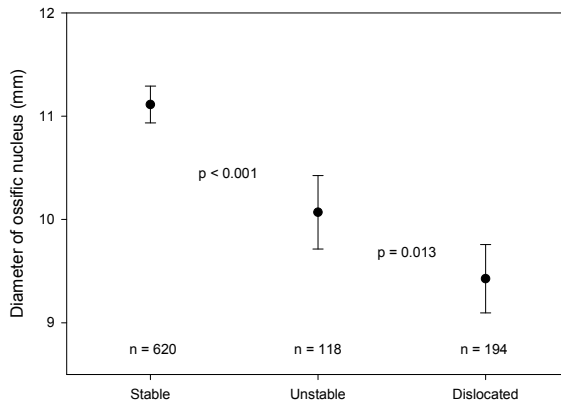


Figure 15.

Hips with a higher degree of neonatal instability had smaller femoral head epiphyses at 1-year follow-up. Note that the y axis is cut: the difference in size amounts to ~ 10% of the size of the ossific nucleus between each group of hips.

It is difficult to know if the delayed ossification in NIH hips is a result of a minor vascular disturbance due to the treatment, or related to the disease per se. The finding that Ortolani positive hips had smaller epiphyses compared to Barlow positive hips (Figure 16) support the latter hypothesis, but a combination of factors could be present.

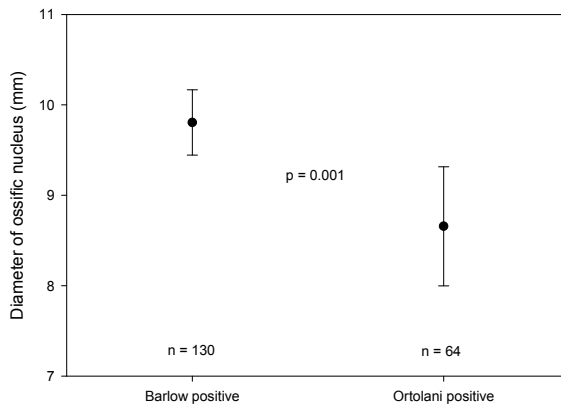


Figure 16.

Ortolani positive hips had smaller femoral head epiphyses at 1-year follow-up compared to Barlow-positive hips. All the hips in this comparison were treated for 3 months in the von Rosen splint. Note that the y axis is cut.

We also found a difference between genders, with girls' femoral head epiphyses being more ossified (mature) at 1 year (Figure 17). This confirms previous findings (MacKenzie 1972).

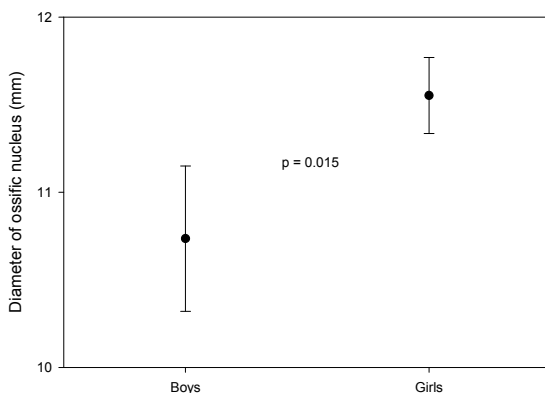


Figure 17.
The femoral head epiphysis is more mature at 1-year follow-up in girls compared to boys. Note that the y axis is cut.

Remodeling of residual acetabular dysplasia (Paper III)

At 21-year follow-up, the group of subjects in Paper III had normal radiographic outcomes (Table 12). It has previously been shown that early treatment with the von Rosen splint leads to normal hip morphology in childhood (Fredensborg 1976b, Lauge-Pedersen et al. 2006). A higher AI at 1 year was not predictive of acetabular dysplasia at completion of growth.

Table 12.
Mean values with 95% CI from the radiographic study of 21 subjects (18 females) in Paper III.

Radiographic measure of DDH	mean (95% CI)	Normal value, female ¹ , mean (SD)	Normal value, male ¹ , mean (SD)
CE angle of Wiberg	30° (28-32)	30.1° (6.1)	32.1° (6.1)
FHEI	86% (83-88)	85.6% (6.6)	85.6% (6.3)
Sharp angle	41° (40-42)	40.7° (3.5)	38.8° (3.5)

¹ Normal values from a population based material of 2,038 Norwegian 19-year-olds, right hips (Laborie et al. 2013).

One male subject had slightly dysplastic hips, with CE angles of 20° (right) and 15° (left), and FHEI 75% (right) and 73% (left). His Sharp angle was 42° bilaterally. A CE angle of less than 20° is considered pathologic in adults (Wiberg 1939b, Fredensborg 1976b, Fredensborg 1976a, Laborie et al. 2013) and is associated with hip OA in older subjects (Jacobsen et al. 2005a). An FHEI < 70%

is considered pathologic (Heyman et al. 1950), but based on a large Norwegian reference material 74% has been suggested as cut-off in males (Laborie et al. 2013). He was free of symptoms, had no radiographic signs of OA, and had a normal dGEMRIC index in both hips.

No radiographic OA at 21 years (Paper III)

There was no case of radiographic OA, either according to the Kellgren-Lawrence classification or using a minJSW < 2 mm as definition. 5 hips in 3 subjects had a possible small osteophyte on the lateral aspect of the femoral head (Figure 18). There was no difference in any outcome parameter between those 5 hips and the rest.

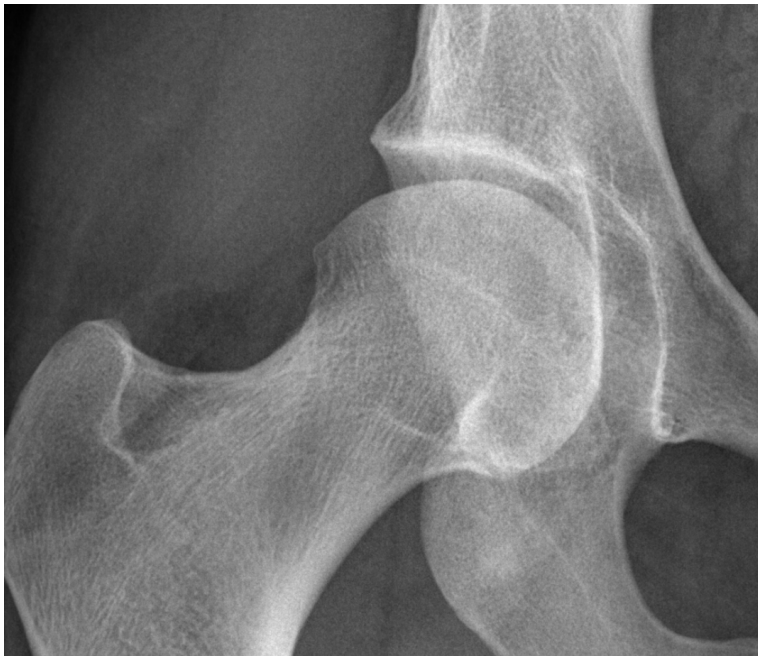

Figure 18. A small irregularity (possibly an osteophyte) on the lateral part of the femoral head was found in 5 hips (3 patients). Such hips did not differ from the rest with regards to radiographic measurements of DDH, minJSW or dGEMRIC index.

The Kellgren-Lawrence classification shows substantial inter-observer variability (Kellgren et al. 1957). When dichotomizing into no OA (Kellgren-Lawrence grade 0-1) and OA (grade 2-4) the reproducibility improves (Jacobsen et al. 2005b). I graded all radiographs myself in order to avoid inter-observer variability.

A minJSW of < 2 mm has been proposed as a more sensitive radiographic measure of OA as has a stronger association to hip pain than classical radiographic signs such as cysts, subchondral sclerosis and osteophytes (Jacobsen et al. 2004b).

Normal cartilage quality at 21 years (Paper III)

The mean dGEMRIC index in the 40 hips that could be analyzed (2 were excluded due to motion artifacts) was 630 ms (95% CI: 600-666). No hip had a dGEMRIC index < 500 ms. A previous study, using the same protocol, found a mean dGEMRIC index of 570 ms in a group of healthy volunteers. In that study, patients with hip dysplasia but no or minimal joint space narrowing had a mean dGEMRIC index of ~ 400 ms (Tiderius et al. 2007). Another study found a mean dGEMRIC index of 570 ms in radiographically normal hips in subjects with unilateral DDH. The dGEMRIC index correlated to both pain and radiographic severity of DDH (the CE angle) (Kim et al. 2003). In another cohort of subjects with DDH and hip symptoms, 9 of 20 had a dGEMRIC index < 500 ms (Domayer et al. 2010). A low dGEMRIC index predicts early failure of periacetabular osteotomy, meaning that the cartilage changes imaged are relevant for hip function and prognosis (Cunningham et al. 2006).

The finding that dGEMRIC is prognostic of incident OA has also been shown in the knee (Owman et al. 2008) (Figure 19).

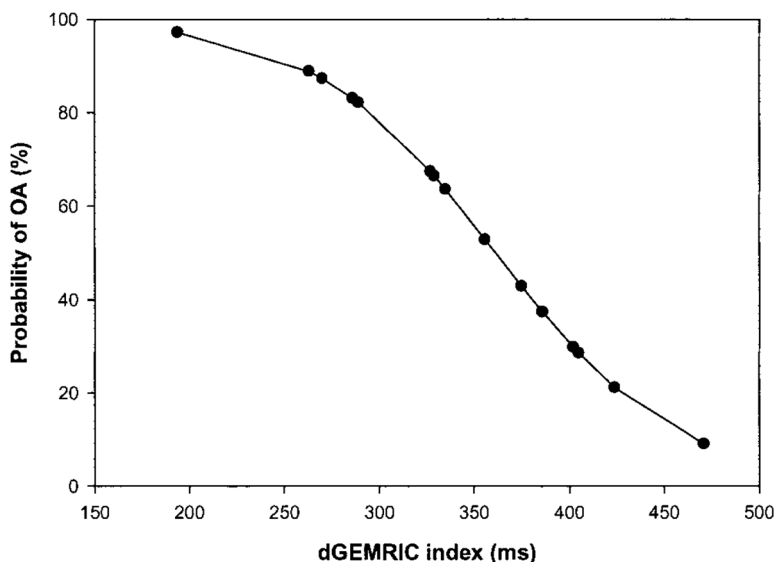


Figure 19.

In a study on 15 subjects with knee pain and arthroscopic signs of early OA but normal radiography, a lower dGEMRIC index was associated with a higher risk of incident OA at 6-year follow-up. Reprinted from Owman et al. (Owman et al. 2008) with permission from John Wiley and sons.

Normal hip function at 21 years (Paper III)

The subjects had normal, symmetrical range of motion of the hips, with 1 exception who had signs of increased hip anteversion on the right side. No subject had a limp or a positive Trendelenburg sign. They reported a mean 12-item WOMAC score of 1.2 (95% CI: 0.02-2.5). One outlier scored 11 on the 12-item WOMAC. She had marked a “1” on 11 of the 12 items, indicating slight but global hip symptoms. The 12-item WOMAC score did not differ from a previously published reference group of healthy volunteers (Figure 20).

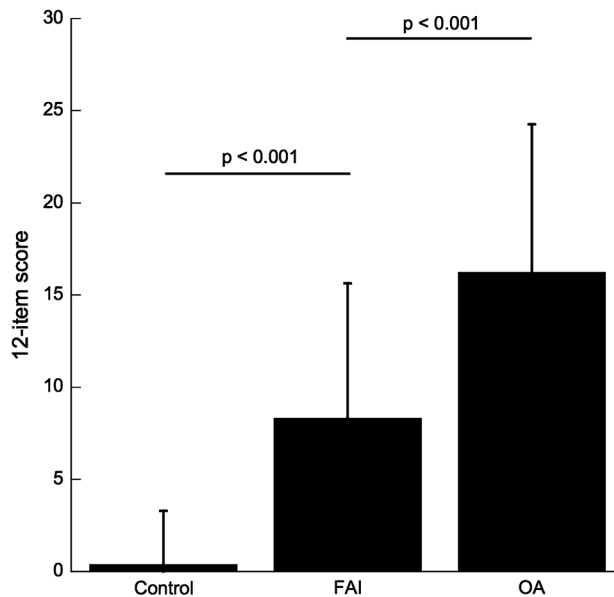


Figure 20.

In a validation study, the 12-item WOMAC had the sensitivity to discriminate between healthy volunteers, patients with less pronounced hip symptoms (due to femoro-acetabular impingement) and patients with established OA (Rothenfluh et al. 2008). Reprinted with permission from Elsevier.

The WOMAC score is one of the most widely used patient reported outcome measures to assess hip OA symptoms (Bellamy et al. 1988). The 12-item WOMAC is a newer subset of 12 items (questions) from the WOMAC that shows internal construct validity and has enough sensitivity to discriminate subjects with lesser symptoms from both healthy volunteers and patients with OA (Rothenfluh et al. 2008) (Figure 20). We chose the less used 12-item WOMAC score, as we did not expect to find a high grade of hip symptoms in the studied cohort. We predicted it to be more sensitive in this setting compared to the more commonly used WOMAC score, which has issues with floor effects.

Relationship between DDH measures and dGEMRIC

In Paper III, the study subjects had normal hips with regard to measures of DDH at follow-up. There was, of course, some variation in these measures within the group. As a previous longitudinal study in middle-aged women showed that already a CE angle $< 28^\circ$ is a risk factor for incident OA or THA (Thomas et al. 2014), we hypothesized that radiographic measurements of DDH could correlate to lower dGEMRIC indices in our study cohort. We found the opposite (Figure 21).

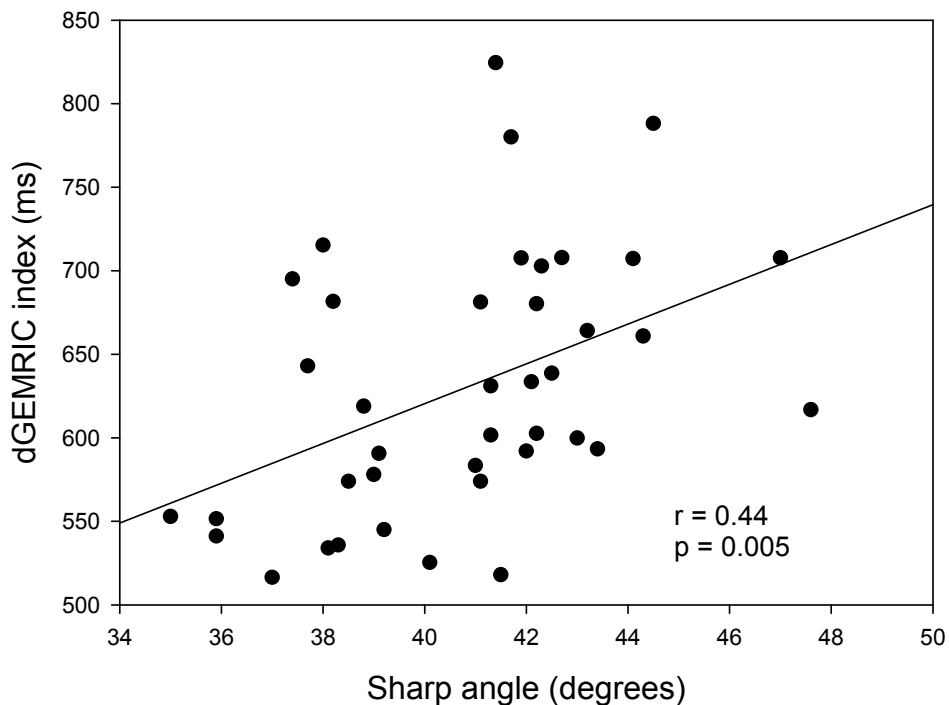


Figure 21.

A higher Sharp angle correlated to a higher dGEMRIC index (Paper III). Similar findings were also made for the CE angle and the FHEI; with increased tendency towards radiographic dysplasia, cartilage quality seemed to improve.

What is the explanation to our finding that hips with a tendency towards acetabular dysplasia had a higher dGEMRIC index? Perhaps cartilage can adapt to moderately increased mechanical stress. Some previous dGEMRIC studies support this hypothesis. In one study on 37 healthy volunteers, a higher physical activity level correlated to a higher dGEMRIC index in the knee cartilage (Tiderius et al.

2004). In a randomized controlled trial on middle-aged patients undergoing partial meniscus resection, exercise intervention led to an increased dGEMRIC index in the knee cartilage, whereas the control group with no intervention had a decrease in dGEMRIC index at follow-up (Roos et al. 2005). In a prospective cohort study on 37 patients with DDH and no or minimal OA, the cartilage regions where calculated contact stresses were highest had higher local $T_{1\rho}$. After rotational osteotomy, the same regions had a decrease in $T_{1\rho}$, which can be interpreted as an adaptation to increased mechanical loading which normalized when hip anatomy improved following surgery (Hingsammer et al. 2015).

It is uncontroversial that bone and muscle adapt to mechanical loading (Turner 1998, Ireland et al. 2015, Parry et al. 2015). In cartilage, dynamic mechanical loading is an important factor for chondrocyte cell differentiation and the regulation of extra-cellular matrix (Panadero et al. 2016). A 2014 Cochrane review of exercise in hip OA concluded that exercise intervention reduces pain and improves physical function in OA patients (Fransen et al. 2014). The Swedish National Board of Health and Welfare recommends exercise as primary treatment in their national guideline document on hip and knee OA (Socialstyrelsen 2012).

Even though exercise is known to be clinically beneficial in OA, and there is evidence of mechanotransduction signaling in cartilage differentiation and formation, there is “an important gap in the knowledge in this field”, as stated in a recent review (Panadero et al. 2016). Previous studies have shown the dGEMRIC index to be decreased in DDH (Kim et al. 2003, Jessel et al. 2009, Domayer et al. 2010). The study subjects in those publications had established grave DDH, as opposed to the subjects in Paper III whose hip anatomy varied within the normal range.

It is too early to determine the prognosis of the hips that show signs of adaptation to mechanical loading today. In a longer time perspective the continued stress may exceed the adaptive capacity of the articular cartilage.

Results of screening for NIH

Reduced incidence of late diagnosed hip dislocation (Paper IV)

There were 126 children diagnosed with hip dislocation later than 2 weeks from birth in Sweden during the years 2000 – 2009. The incidence was 0.12 (95% CI: 0.10-0.15) per 1,000 live births. The yearly incidence did not change statistically during the study period.

Girls ran a 9 times higher risk of having a late diagnosed hip dislocation, compared to boys. 64% of all hip dislocations were left-sided, 24% were right-sided, and 12% were bilateral.

The incidence of 0.12 late diagnosed hip dislocations per 1,000 live births can be compared to the situation in Sweden before screening started. Erik Severin made an inventory of the Swedish Institutes for the Disabled, where children and adolescents with physical handicaps were offered orthopedic care and education. From the birth cohort 1936–1945, Severin found 641 patients with hip dislocation. The incidence was 0.9 per 1,000 live births which must be considered a minimum estimation of the true incidence (Severin 1956). As screening for NIH was instituted in Sweden, the national incidence fell from 0.8 per 1,000 live births in 1950-1952 (266 cases), by $\sim 2/3$ during the 1950:s (Palmén 1984).

There is, to my knowledge, no randomized trial comparing screening to not screening for NIH. Some studies have been published on the use of sonography. A randomized controlled trial in Bergen, Norway, failed to show an additional effect of adding selective or universal sonography to clinical screening, even though the prevalence of late subluxation or dislocation was very high in the clinical screening group (1.3 per 1,000) (Rosendahl et al. 1994). Another randomized controlled trial failed to demonstrate an effect of performing universal sonographic screening compared to selective sonographic screening (Holen et al. 2002). Dynamic sonography as an aid to evaluate hip stability can lower treatment rates, seemingly without an increase in adverse effects (Elbourne et al. 2002).

However, there is good evidence from comparative studies that if clinical screening is performed by properly trained examiners (not necessarily physicians), the rate of late diagnosed hip dislocation decreases (Table 13).

Table 13.

Studies comparing screening by specially trained or more experienced practitioners to a reference group of other examiners.

Study	Group 1	Group 2	Incidence of late diagnosed hip dislocation (per 1,000 live births), Group 1 / Group 2	p-value ¹
(MacKenzie 1972)	Family doctors	“Ample staff” at hospital	0.50 / 1.06	0.015
(Palmen et al. 1975)	Pediatric consultants	Less experienced physicians	0.18 / 0.52	0.005
(Jones 1977)	Born in hospital	Born in nursing home or home	0.45 / 0.73	0.3
(Lehmann et al. 1981)	One dedicated orthopaedic surgeon	A succession of orthopaedic residents	0.3 / 0.8 ²	n.a.
(Dunn et al. 1985)	Born in University hospital	Born in general practice unit	0.44 / 1.41	0.001
(Macnicol 1990) ³	Two dedicated orthopaedic surgeons	Pediatric junior staff	~ 0.1 / 0.5	n.a.
(Krikler et al. 1992)	2 physiotherapists, supervised by an orthopaedic surgeon	Pediatric medical team	0.08 / 0.32	0.023
(Lennox et al. 1993)	2 dedicated physicians	A succession of junior hospital physicians	1.1 / 2.1	n.a.
(Fiddian et al. 1994) ³	Trained physiotherapists	Pediatricians	0.31 / 1.96	< 0.001
(Duppe et al. 2002) ³	Most by one of two experienced physicians	22 less experienced physicians	0.07 / 0.51	0.002

¹ p-values calculated using Pearson chi-square test.

² A number of maternity units with no regular screening, in the same region, had a late dislocation rate of 1.4 per 1,000 live births.

³ Longitudinal design.

A higher incidence of both NIH and late hip dislocation in girls has been found uniformly in the literature. In the Swedish children with late diagnosed hip dislocation born in 1950 – 1952 for example, 86% were girls (Palmén 1984).

Earlier diagnosis of hip dislocation (Paper IV)

The median age at diagnosis was 7 months (Figure 22). 64% were diagnosed before the age of 1 year.

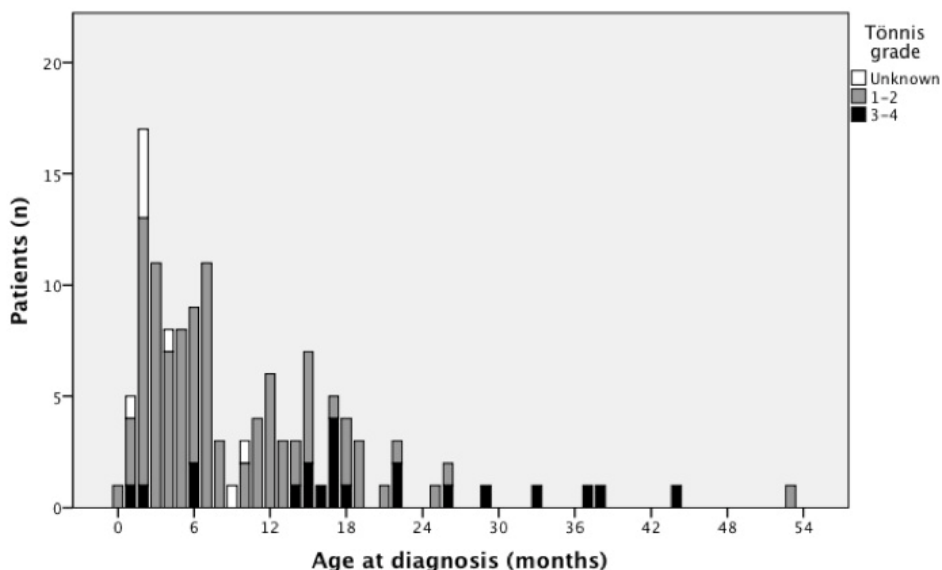


Figure 22.

In the 126 cases of late diagnosed hip dislocation in Sweden during the years 2000 through 2009, the median age at diagnosis was 7 months (mean: 10 months). A pre-reduction radiograph was lacking in 8 subjects (see Methods section for details). The Tönnis grade is given in the figure. In bilateral cases with a side difference, the hip with a higher Tönnis grade is given.

Of the 118 children with pre-reduction radiographs, 21 (18%) had a high dislocation, defined as Tönnis grade 3 or 4. The risk of having a high dislocation was 0.02 (95% CI: 0.01-0.03) per 1,000 live births. A higher Tönnis grade was associated with a higher age at diagnosis (Table 14).

Table 14.

Patients with more severe dislocations were older at the time of diagnosis.

Tönnis grade	Patients, no (bilateral)	Mean age, weeks (95% CI)
1	7 (0)	18 (10-27)
2	92 (9)	41 (34-48)
3	14 (1)	76 (53-99)
4	7 (6)	111 (53-169)
All	126 ¹	46 (39-53)

¹ Includes 8 patients where radiographs could not be retrieved.

As screening for DDH was introduced in Sweden, not only did the incidence of late diagnosed hip dislocations decrease but also, the diagnosis was typically made earlier. In 1950-1952, only 10% of all dislocations were found before the age of 1 year. By contrast, during 1973-1979, 78% of the cases found (including “subluxations”) were younger than 1 year at diagnosis (Palmén 1984). In my institution, the mean age at diagnosis fell from 13 months during the first decades of screening, to 4 months in the 1980:s and 1990:s (Duppe et al. 2002). When primary care centers became more involved in screening for hip dislocation in Edinburgh, the average age at diagnosis of late diagnosed hip dislocations fell from 17 to 8 months (Macnicol 1990).

A problem with the Tönnis grading system is that it describes the position of the femoral head epiphysis, which is sometimes not ossified, i.e. not visible on radiographs. A new system for grading hip dislocation, which doesn’t take the epiphysis into account, has recently been developed and shows a higher intraclass correlation coefficient compared to Tönnis grading (Narayanan et al. 2015). However, we chose the Tönnis grading system as it is very well established and is predictive of treatment outcome (Rosen et al. 1999).

Papers I, II and III in this work describe outcomes of early treatment for NIH, starting in the first week of life. Children treated in the first 10 days from birth have a lower risk of pathological hip development at 6-18 years age compared to children treated later (Hansson 1980).

In late diagnosed cases, an earlier age at reduction and a lower Tönnis grade of displacement predicts better radiographic outcome and lower risk of treatment failure (Bradley et al. 1987, Brougham et al. 1988, Malvitz et al. 1994, Rosen et al. 1999, Albinana et al. 2004) (Figure 23). The finding that earlier reduction leads to better results was made already by Erik Severin, but in a patient population where diagnosis before age 1 year was rare (Severin 1941). Earlier treatment start also lowers the risk of AVN (Bradley et al. 1987, Malvitz et al. 1994, Kruczynski 1996, Wang et al. 2013).

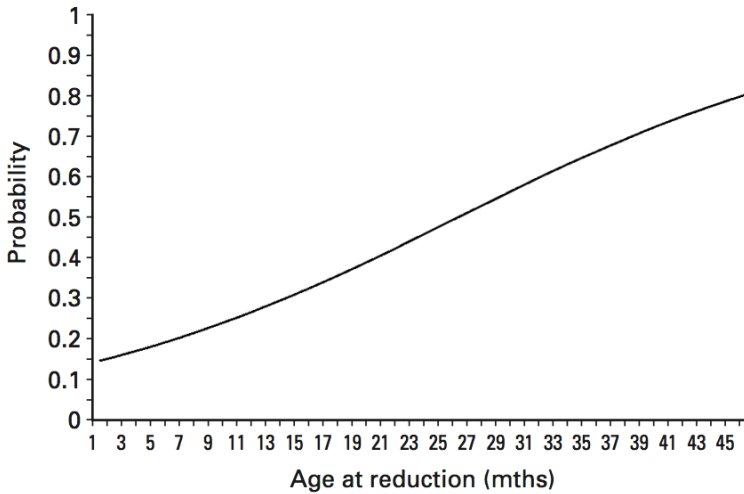


Figure 23.

In 72 hips (58 patients) treated for DDH by closed or open reduction, the age at reduction was predictive of the risk of poor radiographic outcome (defined as Severin III/IV) at skeletal maturity. The Severin grade predicted later THA. Reproduced with permission and copyright © of the British Editorial Society of Bone and Joint Surgery (Albinana et al. 2004).

Before the advent of screening for NIH in Sweden, 87% of the patients had high dislocations at the time of diagnosis (Palmén 1984). Based on the minimum incidence of late diagnosed hip dislocation without screening (Severin 1956) and the high proportion of high dislocations from that time, there would have been an expected 790 children with high dislocations in the birth cohort we studied. Instead we found 21 such cases.

How should screening for DDH ideally be performed?

The following suggestions represent my own personal view. They are open for debate. A flowchart detailing the screening program at my institution is given in Figure 24.

- All children should be examined clinically for NIH within days from birth.
- Treatment of NIH should not be delayed.
- As few persons as possible should perform the screening examination. Education and experience are key factors for success.
- The von Rosen splint should be chosen in early-diagnosed cases.
- Further hip examinations should be performed during the child's first year. A continuous education program outreaching to primary care providers is probably key to finding late diagnosed hip dislocations as early as possible.
- Recommendations should be made against swaddling infants, by pediatricians, orthopedic surgeons and general practitioners in concert.
- Neonatal screening should not rely on sonographic assessments of acetabular morphology.
- Sonography as an aid in determining hip stability can lower treatment rates, probably without any adverse effect.
- The screening program should be monitored, preferably through a prospective nationwide registry.

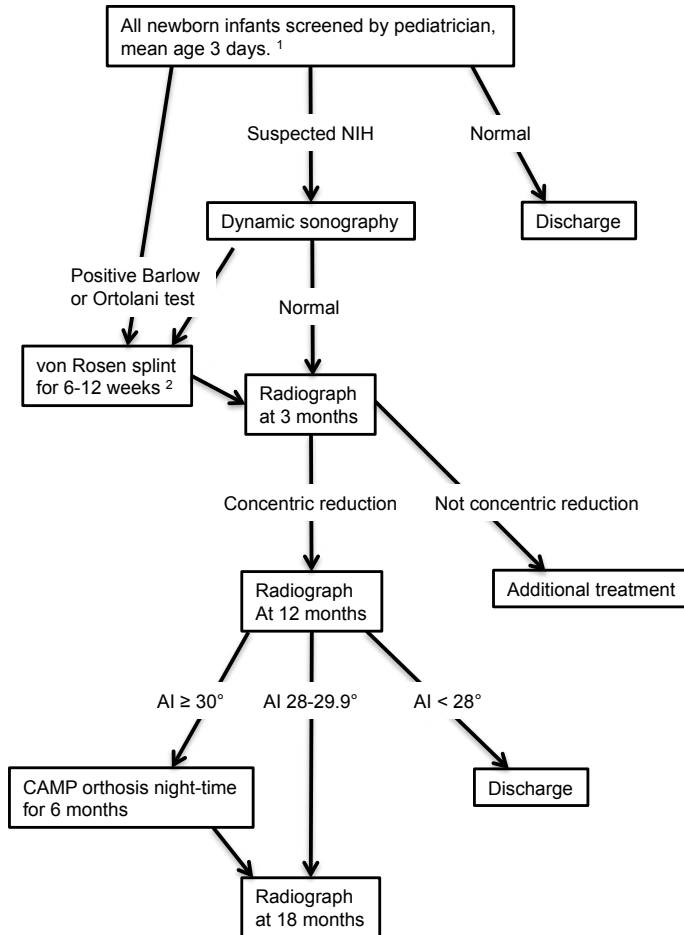


Figure 24.

Screening and early treatment of NIH at Skåne University Hospital, Sweden.

¹ Children in need of neonatal intensive care are often examined later. It is important not to miss the mandatory examination in such cases.

² During the study period of Papers I-III, children with Barlow- or Ortolani-positive hips were treated for 12 weeks. Currently, the treatment length has been shortened to 6 weeks for all cases of NIH, which is being evaluated.

Conclusions

In Papers I, II and III, we studied the outcome of early treatment with the von Rosen splint. Treatment was considered early if started in the first week of life, which is common practice today.

- At 1 year, acetabular dysplasia was more common in neonatally unstable hips compared to a reference group.
- Spontaneously resolving Kalamchi-MacEwen group I AVN occurred in 0.9% of treated cases. There was no case of clinically significant AVN in 229 treated children.
- A higher degree of instability neonatally was associated with a smaller ossific nucleus at 1 year.
- At 21 years, subjects who had residual acetabular dysplasia at 1 year reported normal clinical outcome, had normal hips radiographically on a group level (though 1 of 21 subjects had radiographic dysplasia), and had normal cartilage quality as assessed with dGEMRIC.
- We found an inverse relationship between the radiographic measures of DDH and the dGEMRIC index. This finding may indicate adaptive properties in cartilage to moderately increased mechanical stress.

Paper IV constitutes a report from the Swedish national registry of late diagnosed hip dislocation. We studied the epidemiology of the disease in the first decade of the 21st century.

- The incidence of late diagnosed hip dislocation in Sweden was 0.12 (95% CI: 0.10-0.15) per 1,000 live births. The incidence did not change during the study period. 0.02 (0.01-0.03) per 1,000 live births had a high dislocation.
- The median age at diagnosis was 7 months. A later diagnosis was associated with a more severe degree of dislocation.
- Girls had a 9 times higher risk of having a late diagnosed hip dislocation compared to boys.

Future prospects

“The positive and surely correct alternative should be to compare the methodology of successful and unsuccessful programmes and make appropriate modifications to the latter.”

- Peter M. Dunn 1985

Screening for DDH

More prospective nation-wide registry based studies on late diagnosed hip dislocation are warranted, both for monitoring the efficacy of screening programs and in order to find possible aspects to improve.

Interventions to improve less successful screening programs should be scientifically evaluated, preferably in randomized controlled trials.

Biomechanics and cartilage health

Experimental studies should be designed to further clarify the impact of joint anatomy and mechanical loading on cartilage quality. As acetabular reorienting osteotomies are increasingly being performed in order to change hip joint biomechanics in DDH patients, we need to improve our understanding of these matters.

Clinical studies with longer follow-up are warranted in subjects with differing hip anatomy and calculated joint contact stresses.

Acknowledgements

I want to thank the following:

Carl Johan Tiderius, my main supervisor, colleague and friend, for all the fun we've had during this work, at home and abroad!

Henrik Düppe, for the levity effect you constantly bring and for your comments, which are based on encyclopedic knowledge and are always à point.

Leif Dahlberg, for building a great research group and inviting me into it.

Hanna Samuelsson, for your contagious enthusiasm and great work on Paper II.

Carl Siversson, for the insights you shared during discussions on Paper III.

Per-Olof Josefsson, my mentor, for all your support, guidance and friendship.

Anders Lindstrand, for being one of my principal role models as an orthopedic surgeon, and my main influence to becoming one myself.

Jeanette Nilsson, for your tireless work, especially with Paper III.

Sonia Szabo, for venturing into the antique archives of radiographs of Malmö Allmänna Sjukhus, in search of a treasure.

Anetta Bolejko and Carmen Bengtsson, for all your work during our long evenings of dGEMRIC examinations.

The study subjects of Paper III, who willingly spent an evening with us, and in some cases travelled far to do so.

Jan Åke Nilsson, for trying to teach an orthopedic surgeon some statistics.

My colleagues at the Swedish Pediatric Orthopaedic Society (SBOF) who have built the registry of late diagnosed hip dislocations in a great joint effort, most particularly Lars Gösta Danielsson and Henrik.

My colleagues at the Orthopaedic Dept. of Skåne University Hospital, for all the good times we share.

Last but Foremost I am thankful to my family: Helena, Mikaël, Eva-Pia and Marie, for teaching me how to be me, and Isabel, for being you!

References

- Agricola, R., M. P. Heijboer, R. H. Roze, M. Reijman, S. M. Bierma-Zeinstra, J. A. Verhaar, H. Weinans and J. H. Waarsing (2013). "Pincer deformity does not lead to osteoarthritis of the hip whereas acetabular dysplasia does: acetabular coverage and development of osteoarthritis in a nationwide prospective cohort study (CHECK)." *Osteoarthritis Cartilage* 21(10): 1514-1521.
- Agus, H., H. Omeroglu, A. Bicimoglu and Y. Tumer (2010). "Is Kalamchi and MacEwen Group I avascular necrosis of the femoral head harmless in developmental dysplasia of the hip?" *Hip Int* 20(2): 156-162.
- Albinana, J., L. A. Dolan, K. F. Spratt, J. Morcuende, M. D. Meyer and S. L. Weinstein (2004). "Acetabular dysplasia after treatment for developmental dysplasia of the hip. Implications for secondary procedures." *J Bone Joint Surg Br* 86(6): 876-886.
- Altman, R., G. Alarcon, D. Appelrouth, D. Bloch, D. Borenstein, K. Brandt, C. Brown, T. D. Cooke, W. Daniel, D. Feldman and et al. (1991). "The American College of Rheumatology criteria for the classification and reporting of osteoarthritis of the hip." *Arthritis Rheum* 34(5): 505-514.
- Altman, R. D. and G. E. Gold (2007). "Atlas of individual radiographic features in osteoarthritis, revised." *Osteoarthritis Cartilage* 15 Suppl A: A1-56.
- Barlow, T. G. (1962). "Early diagnosis and treatment of congenital dislocation of the hip." *J Bone Joint Surg Br* 44B(2): 292-301.
- Barlow, T. G. (1963). "Early Diagnosis and Treatment of Congenital Dislocation of the Hip." *Proc R Soc Med* 56: 804-806.
- Bashir, A., M. L. Gray, R. D. Boutin and D. Burstein (1997). "Glycosaminoglycan in articular cartilage: in vivo assessment with delayed Gd(DTPA)(2-)-enhanced MR imaging." *Radiology* 205(2): 551-558.
- Bashir, A., M. L. Gray, J. Hartke and D. Burstein (1999). "Nondestructive imaging of human cartilage glycosaminoglycan concentration by MRI." *Magn Reson Med* 41(5): 857-865.
- Bellamy, N., W. W. Buchanan, C. H. Goldsmith, J. Campbell and L. W. Stitt (1988). "Validation study of WOMAC: a health status instrument for measuring clinically important patient relevant outcomes to antirheumatic drug therapy in patients with osteoarthritis of the hip or knee." *J Rheumatol* 15(12): 1833-1840.
- Bertol, P., M. F. Macnicol and G. P. Mitchell (1982). "Radiographic features of neonatal congenital dislocation of the hip." *J Bone Joint Surg Br* 64(2): 176-179.
- Bialik, V., G. M. Bialik, S. Blazer, P. Sujov, F. Wiener and M. Berant (1999). "Developmental dysplasia of the hip: a new approach to incidence." *Pediatrics* 103(1): 93-99.

- Boniforti, F. G., G. Fujii, R. D. Angliss and M. K. Benson (1997). "The reliability of measurements of pelvic radiographs in infants." *J Bone Joint Surg Br* 79(4): 570-575.
- Bradley, J., M. Wetherill and M. K. Benson (1987). "Splintage for congenital dislocation of the hip. Is it safe and reliable?" *J Bone Joint Surg Br* 69(2): 257-263.
- Brougham, D. I., N. S. Broughton, W. G. Cole and M. B. Menelaus (1988). "The predictability of acetabular development after closed reduction for congenital dislocation of the hip." *J Bone Joint Surg Br* 70(5): 733-736.
- Broughton, N. S., D. I. Brougham, W. G. Cole and M. B. Menelaus (1989). "Reliability of radiological measurements in the assessment of the child's hip." *J Bone Joint Surg Br* 71(1): 6-8.
- Buckwalter, J. A. and L. C. Rosenberg (1988). "Electron microscopic studies of cartilage proteoglycans." *Electron Microsc Rev* 1(1): 87-112.
- Burger, B. J., J. D. Burger, C. F. Bos, W. R. Obermann, P. M. Rozing and J. P. Vandenbroucke (1990). "Neonatal screening and staggered early treatment for congenital dislocation or dysplasia of the hip." *Lancet* 336(8730): 1549-1553.
- Burstein, D., J. Velyvis, K. T. Scott, K. W. Stock, Y. J. Kim, D. Jaramillo, R. D. Boutin and M. L. Gray (2001). "Protocol issues for delayed Gd(DTPA)(2)-enhanced MRI (dGEMRIC) for clinical evaluation of articular cartilage." *Magn Reson Med* 45(1): 36-41.
- Cashman, J. P., J. Round, G. Taylor and N. M. Clarke (2002). "The natural history of developmental dysplasia of the hip after early supervised treatment in the Pavlik harness. A prospective, longitudinal follow-up." *J Bone Joint Surg Br* 84(3): 418-425.
- Catterall, A. (1994). "The early diagnosis of congenital dislocation of the hip." *J Bone Joint Surg Br* 76(4): 515-516.
- Chan, A., K. A. McCaul, P. J. Cundy, E. A. Haan and R. Byron-Scott (1997). "Perinatal risk factors for developmental dysplasia of the hip." *Arch Dis Child Fetal Neonatal Ed* 76(2): F94-100.
- Cooperman, D. R., R. Wallenstein and S. D. Stulberg (1983). "Acetabular dysplasia in the adult." *Clin Orthop Relat Res*(175): 79-85.
- Cunningham, T., R. Jessel, D. Zurakowski, M. B. Millis and Y. J. Kim (2006). "Delayed gadolinium-enhanced magnetic resonance imaging of cartilage to predict early failure of Bernese periacetabular osteotomy for hip dysplasia." *J Bone Joint Surg Am* 88(7): 1540-1548.
- Dagenais, S., S. Garbedian and E. K. Wai (2009). "Systematic review of the prevalence of radiographic primary hip osteoarthritis." *Clin Orthop Relat Res* 467(3): 623-637.
- Dahlstrom, H., L. Oberg and S. Friberg (1986). "Sonography in congenital dislocation of the hip." *Acta Orthop Scand* 57(5): 402-406.
- Danielsson, L. G. (2000). "Instability of the hip in neonates. An ethnic and geographical study in 24,101 newborn infants in Malmo." *J Bone Joint Surg Br* 82(4): 545-547.
- Domayer, S. E., T. C. Mamisch, I. Kress, J. Chan and Y. J. Kim (2010). "Radial dGEMRIC in developmental dysplasia of the hip and in femoroacetabular impingement: preliminary results." *Osteoarthritis Cartilage* 18(11): 1421-1428.

- Dunn, P. M. (1989). "Baron Dupuytren (1777-1835) and congenital dislocation of the hip." *Arch Dis Child* 64(7 Spec No): 969-970.
- Dunn, P. M., R. E. Evans, M. J. Thearle, H. E. Griffiths and P. J. Witherow (1985). "Congenital dislocation of the hip: early and late diagnosis and management compared." *Arch Dis Child* 60(5): 407-414.
- Duppe, H. and L. G. Danielsson (2002). "Screening of neonatal instability and of developmental dislocation of the hip. A survey of 132,601 living newborn infants between 1956 and 1999." *J Bone Joint Surg Br* 84(6): 878-885.
- Dupuytren, G. (1964). "Original or congenital displacement of the heads of thigh-bones." (Translation) *Clin Orthop Relat Res* 33: 3-8.
- Elbourne, D., C. Dezateux, R. Arthur, N. M. Clarke, A. Gray, A. King, A. Quinn, F. Gardner, G. Russell and U. K. C. H. T. Group (2002). "Ultrasonography in the diagnosis and management of developmental hip dysplasia (UK Hip Trial): clinical and economic results of a multicentre randomised controlled trial." *Lancet* 360(9350): 2009-2017.
- Engesaeter, I. O., L. B. Laborie, T. G. Lehmann, J. M. Fevang, S. A. Lie, L. B. Engesaeter and K. Rosendahl (2013). "Prevalence of radiographic findings associated with hip dysplasia in a population-based cohort of 2081 19-year-old Norwegians." *Bone Joint J* 95-B(2): 279-285.
- Engesaeter, I. O., T. Lehmann, L. B. Laborie, S. A. Lie, K. Rosendahl and L. B. Engesaeter (2011). "Total hip replacement in young adults with hip dysplasia: age at diagnosis, previous treatment, quality of life, and validation of diagnoses reported to the Norwegian Arthroplasty Register between 1987 and 2007." *Acta Orthop* 82(2): 149-154.
- Engesaeter, I. O., S. A. Lie, T. G. Lehmann, O. Furnes, S. E. Vollset and L. B. Engesaeter (2008). "Neonatal hip instability and risk of total hip replacement in young adulthood: follow-up of 2,218,596 newborns from the Medical Birth Registry of Norway in the Norwegian Arthroplasty Register." *Acta Orthop* 79(3): 321-326.
- Engesaeter, L. B., I. O. Engesaeter, A. M. Fenstad, L. I. Havelin, J. Karrholm, G. Garellick, A. B. Pedersen and S. Overgaard (2012). "Low revision rate after total hip arthroplasty in patients with pediatric hip diseases." *Acta Orthop* 83(5): 436-441.
- Fiddian, N. J. and J. C. Gardiner (1994). "Screening for congenital dislocation of the hip by physiotherapists. Results of a ten-year study." *J Bone Joint Surg Br* 76(3): 458-459.
- Finne, P. H., I. Dalen, N. Ikonomou, G. Ulmoen and T. W. Hansen (2008). "Diagnosis of congenital hip dysplasia in the newborn." *Acta Orthop* 79(3): 313-320.
- Firth, G. B., A. J. Robertson, A. Schepers and L. Fatti (2010). "Developmental dysplasia of the hip: open reduction as a risk factor for substantial osteonecrosis." *Clin Orthop Relat Res* 468(9): 2485-2494.
- Fransen, M., S. McConnell, G. Hernandez-Molina and S. Reichenbach (2014). "Exercise for osteoarthritis of the hip." *Cochrane Database Syst Rev* 4: CD007912.
- Fredensborg, N. (1975). "Congenital dislocation of the hip." Doctoral dissertation, Lund University, Lund.

- Fredensborg, N. (1976a). "The CE angle of normal hips." *Acta Orthop Scand* 47(4): 403-405.
- Fredensborg, N. (1976b). "The results of early treatment of typical congenital dislocation of the hip in Malmo." *J Bone Joint Surg Br* 58(3): 272-278.
- Fredensborg, N. and B. E. Nilsson (1976). "Overdiagnosis of congenital dislocation of the hip." *Clin Orthop Relat Res*(119): 89-92.
- Furnes, O., S. A. Lie, B. Espehaug, S. E. Vollset, L. B. Engesaeter and L. I. Havelin (2001). "Hip disease and the prognosis of total hip replacements. A review of 53,698 primary total hip replacements reported to the Norwegian Arthroplasty Register 1987-99." *J Bone Joint Surg Br* 83(4): 579-586.
- Gardiner, H. M. and P. M. Dunn (1990). "Controlled trial of immediate splinting versus ultrasonographic surveillance in congenitally dislocatable hips." *Lancet* 336(8730): 1553-1556.
- Garellick, G., J. Kärrholm, H. Lindahl, H. Malchau, C. Rogmark and O. Rolfson (2015). Svenska Höftprotesregistret, Årsrapport 2014. Mölndal.
- Gosvig, K. K., S. Jacobsen, S. Sonne-Holm, H. Palm and A. Troelsen (2010). "Prevalence of malformations of the hip joint and their relationship to sex, groin pain, and risk of osteoarthritis: a population-based survey." *J Bone Joint Surg Am* 92(5): 1162-1169.
- Graf, R. (1984). "Classification of hip joint dysplasia by means of sonography." *Arch Orthop Trauma Surg* 102(4): 248-255.
- Grill, F., H. Bensahel, J. Canadell, P. Dungal, T. Matasovic and T. Vizkelety (1988). "The Pavlik harness in the treatment of congenital dislocating hip: report on a multicenter study of the European Paediatric Orthopaedic Society." *J Pediatr Orthop* 8(1): 1-8.
- Hadlow, V. (1988). "Neonatal screening for congenital dislocation of the hip. A prospective 21-year survey." *J Bone Joint Surg Br* 70(5): 740-743.
- Hansson, G. (1980). Neonatal hip instability in Göteborg, Sweden, between 1961 and 1970. Doctoral dissertation, Göteborg University, Göteborg.
- Harcke, H. T., M. S. Lee, L. Sinning, N. M. Clarke, P. F. Borns and G. D. MacEwen (1986). "Ossification center of the infant hip: sonographic and radiographic correlation." *AJR Am J Roentgenol* 147(2): 317-321.
- Hawezi, Z. K., E. Lammentausta, J. Svensson, L. E. Dahlberg and C. J. Tiderius (2011). "In vivo transport of Gd-DTPA(2-) in human knee cartilage assessed by depth-wise dGEMRIC analysis." *J Magn Reson Imaging* 34(6): 1352-1358.
- Heikkila, E. (1988). "Comparison of the Frejka pillow and the von Rosen splint in treatment of congenital dislocation of the hip." *J Pediatr Orthop* 8(1): 20-21.
- Henebry, A. and T. Gaskill (2013). "The effect of pelvic tilt on radiographic markers of acetabular coverage." *Am J Sports Med* 41(11): 2599-2603.
- Heyman, C. H. and C. H. Herndon (1950). "Legg-Perthes disease; a method for the measurement of the roentgenographic result." *J Bone Joint Surg Am* 32(A:4): 767-778.
- Hinderaker, T., M. Rygh and A. Uden (1992). "The von Rosen splint compared with the Frejka pillow. A study of 408 neonatally unstable hips." *Acta Orthop Scand* 63(4): 389-392.

- Hingsammer, A. M., L. A. Kalish, D. Stelzeneder, S. Bixby, T. C. Mamisch, P. Connell, M. B. Millis and Y. J. Kim (2015). "Does periacetabular osteotomy for hip dysplasia modulate cartilage biochemistry?" *J Bone Joint Surg Am* 97(7): 544-550.
- Holen, K. J., A. Tegnander, T. Bredland, O. J. Johansen, O. D. Saether, S. H. Eik-Nes and T. Terjesen (2002). "Universal or selective screening of the neonatal hip using ultrasound? A prospective, randomised trial of 15,529 newborn infants." *J Bone Joint Surg Br* 84(6): 886-890.
- Ireland, A., H. Degens, N. Maffulli and J. Rittweger (2015). "Tennis service stroke benefits humerus bone: is torsion the cause?" *Calcif Tissue Int* 97(2): 193-198.
- Iwasaki, K. (1983). "Treatment of congenital dislocation of the hip by the Pavlik harness. Mechanism of reduction and usage." *J Bone Joint Surg Am* 65(6): 760-767.
- Jacobsen, S. and S. Sonne-Holm (2005a). "Hip dysplasia: a significant risk factor for the development of hip osteoarthritis. A cross-sectional survey." *Rheumatology (Oxford)* 44(2): 211-218.
- Jacobsen, S., S. Sonne-Holm, B. Lund, K. Soballe, T. Kiaer, H. Rovsing and H. Monrad (2004a). "Pelvic orientation and assessment of hip dysplasia in adults." *Acta Orthop Scand* 75(6): 721-729.
- Jacobsen, S., S. Sonne-Holm, K. Soballe, P. Gebuhr and B. Lund (2004b). "Radiographic case definitions and prevalence of osteoarthritis of the hip: a survey of 4 151 subjects in the Osteoarthritis Substudy of the Copenhagen City Heart Study." *Acta Orthop Scand* 75(6): 713-720.
- Jacobsen, S., S. Sonne-Holm, K. Soballe, P. Gebuhr and B. Lund (2004c). "The relationship of hip joint space to self reported hip pain. A survey of 4.151 subjects of the Copenhagen City Heart Study: the Osteoarthritis Substudy." *Osteoarthritis Cartilage* 12(9): 692-697.
- Jacobsen, S., S. Sonne-Holm, K. Soballe, P. Gebuhr and B. Lund (2005b). "Hip dysplasia and osteoarthritis: a survey of 4151 subjects from the Osteoarthritis Substudy of the Copenhagen City Heart Study." *Acta Orthop* 76(2): 149-158.
- Jessel, R. H., D. Zurakowski, C. Zilkens, D. Burstein, M. L. Gray and Y. J. Kim (2009). "Radiographic and patient factors associated with pre-radiographic osteoarthritis in hip dysplasia." *J Bone Joint Surg Am* 91(5): 1120-1129.
- Jones, D. (1977). "An assessment of the value of examination of the hip in the newborn." *J Bone Joint Surg Br* 59(3): 318-322.
- Jones, D. A. and N. Powell (1990). "Ultrasound and neonatal hip screening. A prospective study of 'high risk' babies." *J Bone Joint Surg Br* 72(3): 457-459.
- Kalamchi, A. and G. D. MacEwen (1980). "Avascular necrosis following treatment of congenital dislocation of the hip." *J Bone Joint Surg Am* 62(6): 876-888.
- Kellgren, J. H. and J. S. Lawrence (1957). "Radiological assessment of osteo-arthritis." *Ann Rheum Dis* 16(4): 494-502.
- Kim, Y. J., D. Jaramillo, M. B. Millis, M. L. Gray and D. Burstein (2003). "Assessment of early osteoarthritis in hip dysplasia with delayed gadolinium-enhanced magnetic resonance imaging of cartilage." *J Bone Joint Surg Am* 85-A(10): 1987-1992.

- Kinds, M. B., P. M. Welsing, E. P. Vignon, J. W. Bijlsma, M. A. Viergever, A. C. Marijnissen and F. P. Lafeber (2011). "A systematic review of the association between radiographic and clinical osteoarthritis of hip and knee." *Osteoarthritis Cartilage* 19(7): 768-778.
- Kliscic, P. J. (1989). "Congenital dislocation of the hip--a misleading term: brief report." *J Bone Joint Surg Br* 71(1): 136.
- Klit, J., K. Gosvig, S. Jacobsen, S. Sonne-Holm and A. Troelsen (2011). "The prevalence of predisposing deformity in osteoarthritic hip joints." *Hip Int* 21(5): 537-541.
- Koizumi, W., H. Moriya, K. Tsuchiya, T. Takeuchi, M. Kamegaya and T. Akita (1996). "Ludloff's medial approach for open reduction of congenital dislocation of the hip. A 20-year follow-up." *J Bone Joint Surg Br* 78(6): 924-929.
- Krikler, S. J. and N. S. Dwyer (1992). "Comparison of results of two approaches to hip screening in infants." *J Bone Joint Surg Br* 74(5): 701-703.
- Kruczynski, J. (1996). "Avascular necrosis of the proximal femur in developmental dislocation of the hip. Incidence, risk factors, sequelae and MR imaging for diagnosis and prognosis." *Acta Orthop Scand Suppl* 268: 1-48. Doctoral dissertation, Karol Marcinkowski University of Medical Sciences, Poznan.
- Laborie, L. B., I. O. Engesaeter, T. G. Lehmann, F. Sera, C. Dezateux, L. B. Engesaeter and K. Rosendahl (2013). "Radiographic measurements of hip dysplasia at skeletal maturity--new reference intervals based on 2,038 19-year-old Norwegians." *Skeletal Radiol* 42(7): 925-935.
- Lauge-Pedersen, H., J. Gustafsson and G. Hagglund (2006). "6 Weeks with the von Rosen splint is sufficient for treatment of neonatal hip instability." *Acta Orthop* 77(2): 257-261.
- Lee, T. W., R. E. Skelton and C. Skene (2001). "Routine neonatal examination: effectiveness of trainee paediatrician compared with advanced neonatal nurse practitioner." *Arch Dis Child Fetal Neonatal Ed* 85(2): F100-104.
- Lehmann, E. C. and D. G. Street (1981). "Neonatal screening in Vancouver for congenital dislocation of the hip." *Can Med Assoc J* 124(8): 1003-1008.
- Lennox, I. A., J. McLauchlan and R. Murali (1993). "Failures of screening and management of congenital dislocation of the hip." *J Bone Joint Surg Br* 75(1): 72-75.
- Lerman, J. A., J. B. Emans, M. B. Millis, J. Share, D. Zurakowski and J. R. Kasser (2001). "Early failure of Pavlik harness treatment for developmental hip dysplasia: clinical and ultrasound predictors." *J Pediatr Orthop* 21(3): 348-353.
- Little, C. J., N. K. Bawolin and X. Chen (2011). "Mechanical properties of natural cartilage and tissue-engineered constructs." *Tissue Eng Part B Rev* 17(4): 213-227.
- MacKenzie, I. G. (1972). "Congenital dislocation of the hip. The development of a regional service." *J Bone Joint Surg Br* 54(1): 18-39.
- Macnicol, M. F. (1990). "Results of a 25-year screening programme for neonatal hip instability." *J Bone Joint Surg Br* 72(6): 1057-1060.
- Malvitz, T. A. and S. L. Weinstein (1994). "Closed reduction for congenital dysplasia of the hip. Functional and radiographic results after an average of thirty years." *J Bone Joint Surg Am* 76(12): 1777-1792.

- Marks, D. S., J. Clegg and A. N. al-Chalabi (1994). "Routine ultrasound screening for neonatal hip instability. Can it abolish late-presenting congenital dislocation of the hip?" *J Bone Joint Surg Br* 76(4): 534-538.
- Maroudas, A. and M. Venn (1977). "Chemical composition and swelling of normal and osteoarthrotic femoral head cartilage. II. Swelling." *Ann Rheum Dis* 36(5): 399-406.
- Maroudas, A. I. (1976). "Balance between swelling pressure and collagen tension in normal and degenerate cartilage." *Nature* 260(5554): 808-809.
- McWilliams, D. F., S. A. Doherty, W. D. Jenkins, R. A. Maciewicz, K. R. Muir, W. Zhang and M. Doherty (2010). "Mild acetabular dysplasia and risk of osteoarthritis of the hip: a case-control study." *Ann Rheum Dis* 69(10): 1774-1778.
- Michaeli, D. A., S. B. Murphy and J. A. Hipp (1997). "Comparison of predicted and measured contact pressures in normal and dysplastic hips." *Med Eng Phys* 19(2): 180-186.
- Mitchell, G. P. (1972). "Problems in the early diagnosis and management of congenital dislocation of the hip." *J Bone Joint Surg Br* 54(1): 4-12.
- Mooney, J. F., 3rd and J. R. Kasser (1994). "Brachial plexus palsy as a complication of Pavlik harness use." *J Pediatr Orthop* 14(5): 677-679.
- Murnaghan, M. L., R. H. Browne, D. J. Sucato and J. Birch (2011). "Femoral nerve palsy in Pavlik harness treatment for developmental dysplasia of the hip." *J Bone Joint Surg Am* 93(5): 493-499.
- Murphy, S. B., R. Ganz and M. E. Muller (1995). "The prognosis in untreated dysplasia of the hip. A study of radiographic factors that predict the outcome." *J Bone Joint Surg Am* 77(7): 985-989.
- Myers, J., S. Hadlow and T. Lynskey (2009). "The effectiveness of a programme for neonatal hip screening over a period of 40 years: a follow-up of the New Plymouth experience." *J Bone Joint Surg Br* 91(2): 245-248.
- Nakamura, J., M. Kamegaya, T. Saisu, M. Someya, W. Koizumi and H. Moriya (2007). "Treatment for developmental dysplasia of the hip using the Pavlik harness: long-term results." *J Bone Joint Surg Br* 89(2): 230-235.
- Narayanan, U., K. Mulpuri, W. N. Sankar, N. M. Clarke, H. Hosalkar, C. T. Price and I. International Hip Dysplasia (2015). "Reliability of a New Radiographic Classification for Developmental Dysplasia of the Hip." *J Pediatr Orthop* 35(5): 478-484.
- National Guideline, C. (2014). "American Academy of Orthopaedic Surgeons clinical practice guideline on detection and nonoperative management of pediatric developmental dysplasia of the hip in infants up to six months of age." Retrieved 4/14/2016, from <http://www.guideline.gov/content.aspx?id=48516>.
- Ohmori, T., H. Endo, S. Mitani, H. Minagawa, T. Tetsunaga and T. Ozaki (2009). "Radiographic prediction of the results of long-term treatment with the Pavlik harness for developmental dislocation of the hip." *Acta Med Okayama* 63(3): 123-128.
- Ortolani, M. (1976). "Congenital hip dysplasia in the light of early and very early diagnosis." *Clin Orthop Relat Res*(119): 6-10.

- Owman, H., C. J. Tiderius, P. Neuman, F. Nyquist and L. E. Dahlberg (2008). "Association between findings on delayed gadolinium-enhanced magnetic resonance imaging of cartilage and future knee osteoarthritis." *Arthritis Rheum* 58(6): 1727-1730.
- Palmen, K. (1961). "Preluxation of the hip joint. Diagnosis and treatment in the newborn and the diagnosis of congenital dislocation of the hip joint in Sweden during the years 1948-1960." *Acta Paediatr Suppl* 50(Suppl 129): 1-71.
- Palmén, K. (1984). "Prevention of congenital dislocation of the hip." *Acta Orthopaedica* 55(s208): 5-107.
- Palmen, K. and S. von Rosen (1975). "Late diagnosis dislocation of the hip joint in children." *Acta Orthop Scand* 46(1): 90-101.
- Panadero, J. A., S. Lanceros-Mendez and J. L. Ribelles (2016). "Differentiation of mesenchymal stem cells for cartilage tissue engineering: Individual and synergetic effects of three-dimensional environment and mechanical loading." *Acta Biomater* 33: 1-12.
- Pap, K., S. Kiss, T. Shisha, G. Marton-Szucs and G. Szoke (2006). "The incidence of avascular necrosis of the healthy, contralateral femoral head at the end of the use of Pavlik harness in unilateral hip dysplasia." *Int Orthop* 30(5): 348-351.
- Parry, S. M. and Z. A. Puthuchery (2015). "The impact of extended bed rest on the musculoskeletal system in the critical care environment." *Extrem Physiol Med* 4: 16.
- Pedersen, A., S. Johnsen, S. Overgaard, K. Soballe, H. T. Sorensen and U. Lucht (2004). "Registration in the danish hip arthroplasty registry: completeness of total hip arthroplasties and positive predictive value of registered diagnosis and postoperative complications." *Acta Orthop Scand* 75(4): 434-441.
- Ponseti, I. V. (1978a). "Growth and development of the acetabulum in the normal child. Anatomical, histological, and roentgenographic studies." *J Bone Joint Surg Am* 60(5): 575-585.
- Ponseti, I. V. (1978b). "Morphology of the acetabulum in congenital dislocation of the hip. Gross, histological and roentgenographic studies." *J Bone Joint Surg Am* 60(5): 586-599.
- Reijman, M., J. M. Hazes, H. A. Pols, B. W. Koes and S. M. Bierma-Zeinstra (2005). "Acetabular dysplasia predicts incident osteoarthritis of the hip: the Rotterdam study." *Arthritis Rheum* 52(3): 787-793.
- Roos, E. M. and L. Dahlberg (2005). "Positive effects of moderate exercise on glycosaminoglycan content in knee cartilage: a four-month, randomized, controlled trial in patients at risk of osteoarthritis." *Arthritis Rheum* 52(11): 3507-3514.
- Rosen, A., J. G. Gamble, H. Vallier, D. Bloch, L. Smith and L. A. Rinsky (1999). "Analysis of radiographic measurements as prognostic indicators of treatment success in patients with developmental dysplasia of the hip." *J Pediatr Orthop B* 8(2): 118-121.
- Rosendahl, K., T. Markestad and R. T. Lie (1994). "Ultrasound screening for developmental dysplasia of the hip in the neonate: the effect on treatment rate and prevalence of late cases." *Pediatrics* 94(1): 47-52.

- Rothenfluh, D. A., D. Reedwisch, U. Muller, R. Ganz, A. Tennant and M. Leunig (2008). "Construct validity of a 12-item WOMAC for assessment of femoro-acetabular impingement and osteoarthritis of the hip." *Osteoarthritis Cartilage* 16(9): 1032-1038.
- Russell, M. E., K. H. Shivanna, N. M. Grosland and D. R. Pedersen (2006). "Cartilage contact pressure elevations in dysplastic hips: a chronic overload model." *J Orthop Surg Res* 1: 6.
- Samosky, J. T., D. Burstein, W. Eric Grimson, R. Howe, S. Martin and M. L. Gray (2005). "Spatially-localized correlation of dGEMRIC-measured GAG distribution and mechanical stiffness in the human tibial plateau." *J Orthop Res* 23(1): 93-101.
- Schwentker, E. P., R. J. Zaleski and S. R. Skinner (1983). "Medial knee instability complicating the Pavlik-harness treatment of congenital hip subluxation. Case report." *J Bone Joint Surg Am* 65(5): 678-680.
- Severin, E. (1939). "Arthrography in Congenital Dislocation of the Hip." *Acta Orthopaedica Scandinavica* 10(1-4): 372-375.
- Severin, E. (1941). "Contribution to the knowledge of congenital dislocation of the hip joint : Late results of closed reduction and arthrographic studies of recent cases." *Acta chirurgica Scandinavica. Supplementum*; 63: 1-142. Doctoral dissertation, Karolinska Institute, Stockholm.
- Severin, E. (1956). "[The frequency of congenital hip dislocation and congenital equinovarus in Sweden]." *Nord Med* 55(7): 221-223.
- Sharp, I. K. (1961). "ACETABULAR DYSPLASIA: The Acetabular Angle." *Journal of Bone & Joint Surgery, British Volume* 43-B(2): 268-272.
- Socialstyrelsen (2010). *Internationell statistisk klassifikation av sjukdomar och relaterade hälsoproblem : (ICD-10-SE). Systematisk förteckning.* Stockholm, Socialstyrelsen.
- Socialstyrelsen (2012). *Nationella riktlinjer för rörelseorganens sjukdomar 2012 : osteoporos, artros, inflammatorisk ryggsjukdom och ankyloserande spondylit, psoriasisartrit och reumatoid artrit : stöd för styrning och ledning.* Stockholm, Socialstyrelsen.
- Soderman, P. and H. Malchau (2000). "Validity and reliability of Swedish WOMAC osteoarthritis index: a self-administered disease-specific questionnaire (WOMAC) versus generic instruments (SF-36 and NHP)." *Acta Orthop Scand* 71(1): 39-46.
- Tegnander, A., K. J. Holen, S. Anda and T. Terjesen (2001). "Good results after treatment with the Frejka pillow for hip dysplasia in newborns: a 3-year to 6-year follow-up study." *J Pediatr Orthop B* 10(3): 173-179.
- Terjesen, T. and R. B. Gunderson (2012a). "Radiographic evaluation of osteoarthritis of the hip: an inter-observer study of 61 hips treated for late-detected developmental hip dislocation." *Acta Orthop* 83(2): 185-189.
- Terjesen, T. and R. B. Gunderson (2012b). "Reliability of radiographic parameters in adults with hip dysplasia." *Skeletal Radiol* 41(7): 811-816.
- Thieme, W. T. and J. B. Thiersch (1986). "Translation: Hilgenreiner on Congenital Hip Dislocation." *Journal of Pediatric Orthopaedics* 6(2): 202-214.

- Thomas, G. E., A. J. Palmer, R. N. Batra, A. Kiran, D. Hart, T. Spector, M. K. Javaid, A. Judge, D. W. Murray, A. J. Carr, N. K. Arden and S. Glyn-Jones (2014). "Subclinical deformities of the hip are significant predictors of radiographic osteoarthritis and joint replacement in women. A 20 year longitudinal cohort study." *Osteoarthritis Cartilage* 22(10): 1504-1510.
- Tiderius, C., M. Hori, A. Williams, L. Sharma, P. V. Prasad, M. Finnell, C. McKenzie and D. Burstein (2006). "dGEMRIC as a function of BMI." *Osteoarthritis Cartilage* 14(11): 1091-1097.
- Tiderius, C. J. (2004). "Contrast-enhanced MRI of human knee cartilage : clinical applications of the novel dGEMRIC technique to study glycosaminoglycan content in articular cartilage." Doctoral dissertation, Lund University, Lund.
- Tiderius, C. J., R. Jessel, Y. J. Kim and D. Burstein (2007). "Hip dGEMRIC in asymptomatic volunteers and patients with early osteoarthritis: the influence of timing after contrast injection." *Magn Reson Med* 57(4): 803-805.
- Tiderius, C. J., L. E. Olsson, H. de Verdier, P. Leander, O. Ekberg and L. Dahlberg (2001). "Gd-DTPA2)-enhanced MRI of femoral knee cartilage: a dose-response study in healthy volunteers." *Magn Reson Med* 46(6): 1067-1071.
- Tiderius, C. J., J. Svensson, P. Leander, T. Ola and L. Dahlberg (2004). "dGEMRIC (delayed gadolinium-enhanced MRI of cartilage) indicates adaptive capacity of human knee cartilage." *Magn Reson Med* 51(2): 286-290.
- Tonnis, D. (1976). "Normal values of the hip joint for the evaluation of X-rays in children and adults." *Clin Orthop Relat Res*(119): 39-47.
- Turner, C. H. (1998). "Three rules for bone adaptation to mechanical stimuli." *Bone* 23(5): 399-407.
- Tönnis, D. (1987). *Congenital Dysplasia and Dislocation of the Hip in Children and Adults*, Springer-Verlag Berlin Heidelberg.
- Venn, M. and A. Maroudas (1977). "Chemical composition and swelling of normal and osteoarthrotic femoral head cartilage. I. Chemical composition." *Ann Rheum Dis* 36(2): 121-129.
- Von Rosen, S. (1956). "Early diagnosis and treatment of congenital dislocation of the hip joint." *Acta Orthop Scand* 26(2): 136-155.
- Wang, T. M., K. W. Wu, S. F. Shih, S. C. Huang and K. N. Kuo (2013). "Outcomes of open reduction for developmental dysplasia of the hip: does bilateral dysplasia have a poorer outcome?" *J Bone Joint Surg Am* 95(12): 1081-1086.
- Wedge, J. H. and M. J. Wasylenko (1979). "The natural history of congenital disease of the hip." *J Bone Joint Surg Br* 61-B(3): 334-338.
- Weinstein, S. L. (1987). "Natural history of congenital hip dislocation (CDH) and hip dysplasia." *Clin Orthop Relat Res*(225): 62-76.
- Wiberg, G. (1939a). "Relation between Congenital Subluxation of the Hip and Arthritis Deformans." *Acta Orthopaedica Scandinavica* 10(1-4): 351-371.
- Wiberg, G. (1939b). "Studies on dysplastic acetabula and congenital subluxation of the hip joint with special reference to the complication of osteoarthritis." *Acta chirurgica*

Scandinavica. Supplementum; 58: 1-135. Doctoral dissertation, Karolinska Institute, Stockholm.

Wilkinson, A. G., D. A. Sherlock and G. D. Murray (2002). "The efficacy of the Pavlik harness, the Craig splint and the von Rosen splint in the management of neonatal dysplasia of the hip. A comparative study." *J Bone Joint Surg Br* 84(5): 716-719.

Williams, P. R., D. A. Jones and M. Bishay (1999). "Avascular necrosis and the Aberdeen splint in developmental dysplasia of the hip." *J Bone Joint Surg Br* 81(6): 1023-1028.

Wood, M. K., V. Conboy and M. K. Benson (2000). "Does early treatment by abduction splintage improve the development of dysplastic but stable neonatal hips?" *J Pediatr Orthop* 20(3): 302-305.

