



# LUND UNIVERSITY

## Cell-free hemoglobin, hyperoxemia and the immature brain during cardiopulmonary bypass circulation

Jungner, Åsa

2020

*Document Version:*  
Publisher's PDF, also known as Version of record

[Link to publication](#)

*Citation for published version (APA):*  
Jungner, Å. (2020). *Cell-free hemoglobin, hyperoxemia and the immature brain during cardiopulmonary bypass circulation*. [Doctoral Thesis (compilation), Department of Clinical Sciences, Lund]. Lund University, Faculty of Medicine.

*Total number of authors:*  
1

### General rights

Unless other specific re-use rights are stated the following general rights apply:  
Copyright and moral rights for the publications made accessible in the public portal are retained by the authors and/or other copyright owners and it is a condition of accessing publications that users recognise and abide by the legal requirements associated with these rights.

- Users may download and print one copy of any publication from the public portal for the purpose of private study or research.
- You may not further distribute the material or use it for any profit-making activity or commercial gain
- You may freely distribute the URL identifying the publication in the public portal

Read more about Creative commons licenses: <https://creativecommons.org/licenses/>

### Take down policy

If you believe that this document breaches copyright please contact us providing details, and we will remove access to the work immediately and investigate your claim.

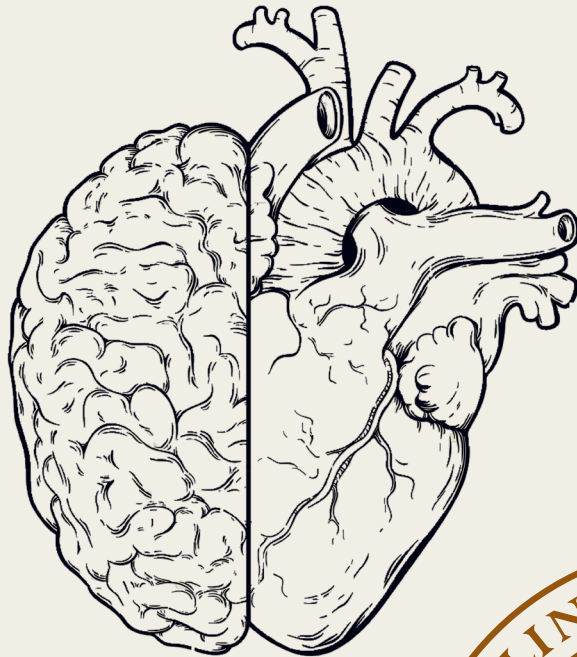
LUND UNIVERSITY

PO Box 117  
221 00 Lund  
+46 46-222 00 00

# Cell-free hemoglobin, hyperoxemia and the immature brain during cardiopulmonary bypass circulation

ÅSA JUNGNER

DEPARTMENT OF CLINICAL SCIENCES, LUND | LUND UNIVERSITY





Cell-free hemoglobin, hyperoxemia and the immature brain during  
cardiopulmonary bypass circulation



# Cell-free hemoglobin, hyperoxemia and the immature brain during cardiopulmonary bypass circulation

by Åsa Jungner




**LUND**  
UNIVERSITY

Thesis for the degree of Doctor of Philosophy  
Thesis advisors: Professor David Ley, Ph.D. Magnus Gram  
Faculty opponent: Professor Hanne Berg Ravn, Copenhagen University

To be presented, with the permission of the Faculty of Medicine of Lund University, for public criticism in  
Segerfalkssalen at the 11th of December 2020 at 13:00.

Organization <b>LUND UNIVERSITY</b>		Document name <b>DOCTORAL DISSERTATION</b>
Department of Clinical Sciences, Lund Section of Pediatrics 221 45 Lund Sweden		Date of disputation <b>2020-12-11</b>
Author(s) <b>Åsa Jungner</b>		Sponsoring organization
Title and subtitle Cell-free hemoglobin, hyperoxemia and the immature brain during cardiopulmonary bypass circulation		
Abstract <b>Background:</b> Neonates born with a critical congenital heart defect are at risk for impaired neurodevelopment. We hypothesized that exposure to circulating cell-free hemoglobin and supranormal oxygen tensions would translate into alterations in the developing white matter by activation of inflammatory and oxidative pathways of injury. <b>Experimental study:</b> Postnatal day 6 rat pups were exposed to circulating cell-free hemoglobin and/or hyperoxia. Following model characterization, brain white matter were examined using immunohistochemistry, gene- and protein analyses and in vivo MRI. <b>Clinical study:</b> Forty neonates with an isolated critical congenital heart defect were included in a clinical study. The included infants were subjected to pre- and postoperative brain MRI imaging and perioperative sampling of blood and urine until postoperative day 3. <b>Results:</b> High oxygen tensions mediated apoptosis in the developing oligodendrocytes. No effects of exposure to circulating hemoglobin or supranormal oxygen tensions on oligodendrocyte maturation or subsequent myelination were observed in the rat pup model. The main determinant of exposure to circulating cell-free hemoglobin during neonatal bypass circulation was the concentration of cell-free hemoglobin in blood prime solution. Scavenger protein concentrations were low during bypass circulation and, for haptoglobin, remained low until postoperative day 1. Postoperative white matter injury was diagnosed in 50% of the included neonates. Lower concentrations of postoperative brain white matter glutathione (GSH) and glutaminergic metabolites (Glx) were associated with prolonged time on bypass circulation. The expected maturational trajectory with an increase in Glx and in the composite measure of N-acetylaspartate and N-acetylaspartylglutamate was not observed. <b>Conclusion:</b> No long-lasting alterations in the developing white matter were observed after exposure to circulating cell-free hemoglobin and high oxygen tensions in a rat pup model. When addressing cell-free hemoglobin exposure, blood prime solution must be considered. Postoperative brain white matter metabolite profile is correlated to the duration of cardiopulmonary bypass circulation.		
Key words neonate, white matter injury, cardiopulmonary bypass, cell-free hemoglobin, hyperoxemia		
Classification system and/or index terms (if any)		
Supplementary bibliographical information		Language English
ISSN and key title		ISBN 978-91-7619-994-7 (print) (pdf)
Recipient's notes	Number of pages 151	Price
	Security classification	

I, the undersigned, being the copyright owner of the abstract of the above-mentioned dissertation, hereby grant to all reference sources the permission to publish and disseminate the abstract of the above-mentioned dissertation.

Signature 

Date 2020-11-05

# Cell-free hemoglobin, hyperoxemia and the immature brain during cardiopulmonary bypass circulation

by Åsa Jungner



**LUND**  
UNIVERSITY



A doctoral thesis at a university in Sweden takes either the form of a single, cohesive research study (monograph) or a summary of research papers (compilation thesis), which the doctoral student has written alone or together with one or several other author(s).

In the latter case the thesis consists of two parts. An introductory text puts the research work into context and summarizes the main points of the papers. The research papers may either have been already published or are manuscripts at various stages (in press, submitted, or in draft).

**Funding information:** The thesis work was financially supported by Swedish Research Council (2017-02112), The Swedish Heart-Lung Foundation, ALF Government grants to Lund University, Skåne Council Foundation for research and Lilla barnets fond.

© Åsa Jungner 2020

Faculty of Medicine, Department of Clinical Sciences, Lund

ISBN: 978-91-7619-994-7 (print)

ISSN: 1652-8220

Printed in Sweden by Media-Tryck, Lund University, Lund 2020



*Dedicated to all families participating in our study*

*By knowing the process, better the art*  
— John W Severinghaus



# Contents

List of publications . . . . .	ii
Acknowledgements . . . . .	iii
Popular summary in English . . . . .	v
Populärvetenskaplig sammanfattning på svenska . . . . .	vii
Abbreviations . . . . .	viii
<b>Cell-free hemoglobin, hyperoxemia and the immature brain during cardiopulmonary bypass circulation</b>	<b>I</b>
1 Hypothesis . . . . .	I
2 Background . . . . .	I
3 Research strategy . . . . .	6
4 Material and methods . . . . .	6
5 Main results of the research papers . . . . .	16
6 Discussion . . . . .	22
7 Conclusions and future research directions . . . . .	25
8 Closing remarks . . . . .	27
9 References . . . . .	28
<b>Scientific publications</b>	<b>4I</b>
Paper I: Cardiopulmonary Bypass in the Newborn: Effects of Circulatory Cell-free Hemoglobin and Hyperoxia evaluated in a Novel Rat Pup Model . . .	43
Paper II: White matter brain development after exposure to circulating cell-free haemoglobin and hyperoxia in a rat pup model . . . . .	59
Paper III: The impact of prime solution on cell-free hemoglobin exposure and scavenger protein concentrations during cardiopulmonary bypass circulation in the newborn . . . . .	75
Paper IV: White matter brain metabolite shifts associated with surgery on cardiopulmonary bypass in the newborn . . . . .	101

## List of publications

This thesis is based on the following publications, referred to by their Roman numerals:

- I **Cardiopulmonary Bypass in the Newborn: Effects of Circulatory Cell-free Hemoglobin and Hyperoxia evaluated in a Novel Rat Pup Model**  
Å Jungner, S Vallius Kvist, M Gram, D Ley  
*Intensive Care Medicine Experimental* 2017 5:45 DOI 10.1186/s40635-017-0153-2
- II **White matter brain development after exposure to circulating cell-free haemoglobin and hyperoxia in a rat pup model**  
Å Jungner, S Vallius Kvist, O Romantsik, M Bruschetti, C Ekström, I Bendix, J Herz, U Felderhoff-Mueser, A Bibic, R In'T Zandt, M Gram, D Ley  
*Developmental Neuroscience* 2020 Feb;41(3- 4):234- 246 DOI: 10.1159/000505206
- III **The impact of prime solution on cell-free hemoglobin exposure and scavenger protein concentrations during cardiopulmonary bypass circulation in the newborn**  
Å Jungner, S Vallius Kvist, M Gram, D Ley  
*Submitted to Journal of Cardiothoracic and Vascular Anesthesia*
- IV **White matter brain metabolite shifts associated with surgery on cardiopulmonary bypass in the newborn**  
Å Jungner, I M Björkman-Burtscher, J Lätt, F Lennartsson, D Ley  
*In manuscript*

All papers are reproduced with permission of their respective publishers.

## Acknowledgements

**David Ley** for having the courage to let me pursue a new field of research. For believing in my ability to carry out the thesis and providing me with the confidence to do so. For the gentle guiding hand – never too much and never too little.

**Magnus Gram** for being the voice of realism always soaked in good spirits. I am so thankful for your solid knowledge on whatever redox-related question posed and your smiling face emojis at the end of every email. Sometimes I really needed those.

**Isabella Björkman-Burtscher** for providing a sustainable platform for the MRI-part of our clinical study, for explaining MRI-mysteries and for being a friend.

**Ingela Andersson**, research nurse and sister in arms. Appointing you as research nurse was a super decision. Thank you for every minute spent in OR, at the MRI facility or searching for genetically modified pigs at C15 at odd hours.

**My research group at BMC C14.** The finest translational research team a girl could get! I thoroughly enjoy my little cubicle and my cubicle-neighbors. Kiitos paljon, **Suvi**, for all ELISAs and qPCRs.

**Sal 6 and the perfusionists Ann-Katrin, Thomas and Paulina** for answering all my questions and for the 468 intraoperative samples.

**The MRI facility** with an especially huge thank you to **Åsa, Håkan and Makda**. I am forever grateful for your extremely considerate ways of handling our not-so-sleepy-but-very-easily-woken babies and toddlers, and for always being greeted with a smile.

**Johanna Månsson and Emma Englund** for transforming Bailey III into a fun playdate.

**Elisabeth Olhager, Per Westrin and Jan Gelberg.** Present head of department of Pediatric Surgery and Neonatal Care, past and present heads of Pediatric Anesthesia. Thank you for providing me with the resources needed for writing my thesis and for never being impatient with my seemingly endless PhD studies (FYI: my pass card for BMC expires year 3000. There is no end).

**Past and present colleagues** for making my life in the clinic inspiring, challenging and never, ever boring. Thank you a million times for all support and for the work you have done while I have been away. An extra hug to the super schedulers **Anders and Hanna** – experts in solving unsolvable puzzles.

**Lars Lindberg and Valéria Perez de Sá** for teaching me everything I know on neonatal cardiac intensive care during daylight and night-time hours in PICU.

**Jónas Ingimarson** for being the premier role model an aspiring anesthesiologist could ask for.

**Personnel at PICU and at the pediatric operating theater** for always making my day a bit better. A special thanks to **everyone at PICU** for all the pre- and postoperative sampling.

**Avdelning 67** for helping out with the postoperative MRI scans.

**My friends**; fun, skilled, strong-willed and absolutely fabulous.

**Lars Gillberg** for being a great bonus grandpa.

**Johan, Aracelly, Hannah and Noah; Ossian, Ulrika, Simon and Sophie; Björn, Lisa, Frida and Gabriel** for providing yet another aspect of life.

**Olle and Gunilla** for all support during the years, and for summers spent in the most beautiful archipelago in the world.

**Dad.** I still miss you.

**Mum** for your unconditional love and for always having my back. On a grander scale, for paving the way for women in science.

**David, Jakob and Johanna.** The greatest of joys and the most amazing of adventures. I love you forever.

**Mårten.** Simply the best. Looking forward to the next 25!

## Popular summary in English

Infants born with critical congenital heart defects (cCHD) are at high risk for neurodevelopmental impairment. About 30% will have a delayed motor function as a toddler, and 20 - 30% will have learning difficulties and behavioral difficulties at school age. We know from previous research that neonates with a cCHD have more immature, and thus more vulnerable, brains than expected even when born at term age.

The most prominent feature when analyzing magnetic resonance images (MRI) of the brains in children born with a cCHD are alterations in the brain white matter. Brain white matter is comprised of cells called oligodendrocytes that are responsible for the transmission and coordination of brain activity between different parts of the brain. Alterations in brain white matter may cause problems with motor skills (movement of small and large muscle groups) and language development, but also alterations in the ability to concentrate, to plan ahead and to solve problems.

Our research investigates the origins of the brain white matter alterations in children born with cCHD. We know from previous research that the developing brain white matter is sensitive to inflammation and high oxygen tensions, both present during surgery on cardiopulmonary bypass circulation (CPB). We believe that the hemoglobin in the red blood cells that leaks out from within the cell during CPB (i.e. circulating cell-free hemoglobin) will start an inflammatory process that will add to the inflammation already present due to the surgery per se. We also believe that the high oxygen tensions during CPB will aggravate the stress posed on the immature brain, and ultimately contribute to the development of brain white matter injuries.

We have done a clinical study and experiments in an animal model to evaluate the impact of circulating cell-free hemoglobin and high oxygen tensions on the developing white matter. The clinical study included neonates born with a cCHD that required surgery within 30 days of life. The included neonates have done pre- and postoperative brain MRI scans, and we have taken blood samples during surgery to determine the exposure to circulating cell-free hemoglobin and high oxygen tensions. In the experimental study, we utilized six days old rat pups as a model animal. We injected cell-free hemoglobin in the abdomen of the rat pup and placed the animal in an incubator with 80% oxygen. After a predetermined number of days we analyzed the rat pup brain white matter using different means of tissue analysis (e.g. protein analysis, immunohistochemistry and MRI).

We have observed that developing oligodendrocytes die when they are exposed to high oxygen tensions in our experimental study, but the presence or absence of circulating cell-free hemoglobin does not alter the outcome. In our clinical study we have confirmed that 50% of the included neonates have lesions in the brain white matter when discharged from hospital, but we have not seen any connection between the development of structural



white matter lesions and the exposure to circulating cell-free hemoglobin and high oxygen tensions. Given the amazing ability of the developing brain to rewire itself, we are now performing a follow-up at 2 <sup>1</sup>/<sub>2</sub> years of age to determine if the white matter lesions detected in infancy affect the child's development as a toddler.

# Populärvetenskaplig sammanfattning på svenska

Varför får barn med hjärtfel förändringar i hjärnan?

Gemensamt för barn som föds med svåra hjärtfel är att även hjärnan är drabbad. Barn med svåra hjärtfel har en omogen och därmed mer sårbar hjärna när de föds. Efter hjärtoperationen har nästan fem av tio barn förändringar i hjärnans vita substans, den del av hjärnan som sköter samarbetet mellan nervcellerna. Förändringar i den vita substansen kan ge problem med motorik och språk, men också bristande förmåga till koncentration, flexibilitet och planering.

Vår forskning undersöker vad det är som gör att barn med hjärtfel också drabbas av hjärnskador. Det finns många anledningar till att ett barns hjärna inte utvecklas normalt, men vi har valt att titta på det som händer när barnet opereras på hjärtlungmaskin. Vi tror att två faktorer spelar speciellt stor roll för just de späda barnen – att syrgasnivåerna är betydligt högre än normalt, och att de röda blodkropparna slås sönder så att fritt hemoglobin läcker ut i cirkulationen och startar en inflammatorisk process. Vi vet från tidigare forskning att nyfödda barns hjärnor störs i sin utveckling när de utsätts för höga syrgasnivåer, och vi vet också att en omogen hjärna kan skadas av inflammatoriska processer.

Vi har gjort en klinisk och en djurexperimentell studie där vi har tittat på hur fritt hemoglobin och höga syrgasnivåer påverkar hjärnans vita substans. I den kliniska studien har vi undersökt barn med svåra hjärtfel som opereras på hjärtlungmaskin före trettio dagars ålder. Barnen har fått göra en MR-undersökning av hjärnan före och efter operationen, och vi har tagit blodprov under och efter operationen för att mäta halterna av fritt hemoglobin och syrgas i blodet. I den djurexperimentella studien har vi sprutat fritt hemoglobin på sex dagar gamla råttor och låtit rättungarna vistas i en syrerik miljö. Efter ett bestämt antal dagar har vi undersökt rått hjärnorna med proteinanalyser, genanalyser och MR-undersökningar.

I vår djurexperimentella studie har vi sett att cellerna i hjärnans vita substans dör när de utsätts för onormalt höga syrehalter, men vi har inte sett någon effekt på den vita substansen av det fria hemoglobinet. Vår kliniska studie har bekräftat att hälften av de nyfödda barn som opereras för hjärtfel har förändringar i hjärnans vita substans när de skrivs ut från sjukhuset, men vi har inte kunnat se att förändringarna är kopplade till de höga syrgasnivåerna eller det hemoglobin som läckt ut. Hjärnans självläkande förmåga är fantastisk hos barn, så just nu håller vi på med en uppföljning vid 2 1/2 års ålder av barnen för att se om de förändringar i den vita substansen vi såg i nyföddhetsperioden har betydelse för hur barnet utvecklas.

# Abbreviations

aa	aortic arch
ANOVA	analysis of variance
AUC	area under curve
CCr	adenomatous polyposis coli clone
cCHD	critical congenital heart defect
CPB	cardiopulmonary bypass
CVST	cerebral venous sinus thrombosis
DHCA	deep hypothermic circulatory arrest
DTI	diffusion tensor imaging
ECG	electrocardiogram
ECMO	extracorporeal membrane oxygenation
ELISA	enzyme-linked immunosorbent assay
FA	fractional anisotropy
$f_iO_2$	fraction inhaled oxygen
HLHS	hypoplastic left heart syndrome
IAA	interrupted aortic arch
IVS	intact ventricular septum
IQR	interquartile range
Hb	hemoglobin
Hp	haptoglobin
Hpx	hemopexin
LVOTO	left ventricular outflow tract obstruction
MBP	myelin basic protein
MRI	magnetic resonance imaging
MRS	magnetic resonance spectroscopy
NAA	N-acetylaspartate
OPC	oligodendrocyte progenitor cell
$P_n$	postnatal day $n$
PA	pulmonary atresia
PICU	pediatric intensive care unit
pre-OL	pre-myelinating oligodendrocyte
qPCR	quantitative polymerase chain reaction
PS	pulmonary stenosis
RBC	red blood cell
ROI	region of interest
ROS	reactive oxygen species
RV	right ventricle
$S_pO_2$	peripheral oxygen saturation
T	tesla
TAPVD	totally anomalous pulmonary venous drainage
TUNEL	terminal deoxynucleotidyl transferase dUTP nick end labelling
TGA	transposition of the great arteries
VOI	voxel of interest
VSD	ventricular septal defect
WMI	white matter injury

# Cell-free hemoglobin, hyperoxemia and the immature brain during cardiopulmonary bypass circulation

## 1 Hypothesis

Exposure to circulating cell-free hemoglobin and supranormal oxygen tensions during surgery on cardiopulmonary bypass circulation mediates white matter alterations in the immature brain by activation of inflammatory and oxidative stress pathways.

## 2 Background

### 2.1 Neurodevelopmental outcome and white matter alterations in the neonate with a critical congenital heart defect

Children born with a critical congenital heart defect (cCHD) are at high risk for neurodevelopmental morbidity [1, 2, 3]. The neurocognitive impairment may be described as "high-prevalence, low-severity" [2], affecting multiple developmental domains – motor and language function, behavioral functions and executive functions.

The estimated prevalence of neurodevelopmental impairment differs depending on chosen cohort and outcome measure. Published aggregated data from children undergoing cardiac surgery in infancy indicates a prevalence of motor function below  $-2$  SD of normative mean in 37% and a prevalence of cognitive function below  $-2$  SD in 15% of children assessed at 14 months of age [4]. Importantly, delayed motor function is considered an early indicator of impaired neurodevelopmental outcome, whereas diagnoses of impaired executive and behavioral functions occur at a later age [2].

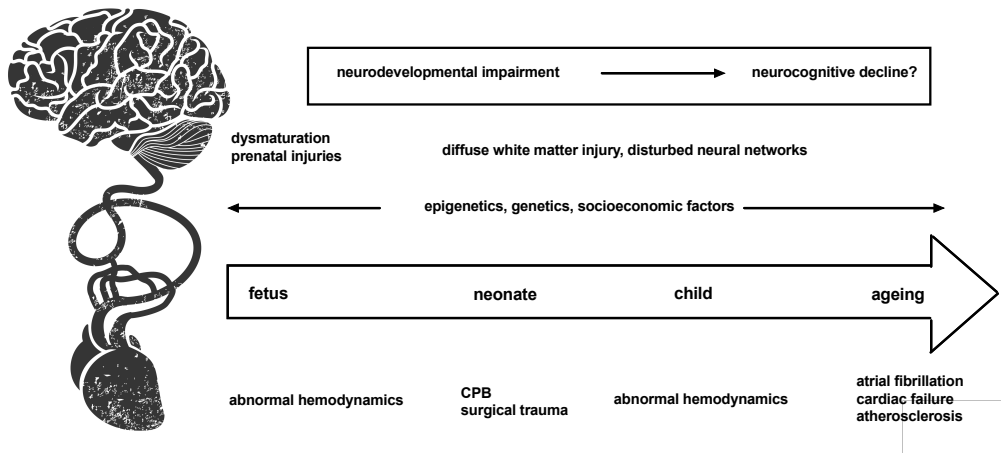


Figure 1: The accumulated neurocognitive burden over time in a patient with a cCDH

The origin of the neurodevelopmental impairment in children born with a cCHD is considered multifactorial and cumulative [5], with prenatal, postnatal, genetic and socioeconomic factors governing final neurodevelopmental outcome, Figure 1. Innate factors, such as cardiac diagnosis, gender, socioeconomic status and maternal education, are important predictors for adverse neurodevelopmental outcome [6, 7, 8], but do not explain more than 20% - 30% of the variation when incorporated in an explanatory model [4].

The predominant neuroradiological finding in the infant with a cCDH is structural white matter injury (WMI) with a postoperative prevalence of 30% – 70%, as determined by magnetic resonance imaging [9, 10, 11, 12, 13]. Importantly, preoperative brain abnormality, most often white matter lesions, is present in 20% of infants [9, 10, 13].

A thorough appraisal of white matter alterations requires assessment of not only morphological MRI-sequences but also of white matter diffusion characteristics, connectivity analyses and volumetrics [14, 15]. A number of studies in adolescents born with a cCHD using advanced MRI-diagnostics and neurocognitive outcome quantifications have shown correlations between white matter aberrations and impaired cognition [16, 17, 18], neurobehavioral dysfunction [19, 20] and lesser academic achievements [21, 20]. Advanced MRI-technologies not only enable an understanding of the white matter structural and functional alterations associated with clinical aspects of neurodevelopmental impairment, but also provide insight into the white matter histoarchitecture that might bring cues for future preclinical trials [22].

## 2.2 The dysmature brain

Term neonates with a cCHD do not have a term brain. Results from fetal and postnatal studies in neonates with cCHD using morphologic, volumetric and metabolic outcome measures have shown that the brain in a term infant with a cCHD is smaller and less elaborately folded than in the healthy term neonate, and that the brain metabolic profile is similar to that of an infant born at 34 – 36 gestational weeks [23, 24].

Starting from third trimester, a progressive decline from the expected brain growth spurt has been shown using fetal brain MRI volumetrics [25, 26, 27]. The prenatal aberration from the expected growth trajectory translates into smaller postnatal brain volumes as determined by MRI [28, 29, 30] and a smaller head circumference in infants with critical congenital heart defects. [31, 32]. Not only volumetric measures but also brain anatomical indices indicate a less developed brain at term birth as determined by a less intricate cortical folding [33, 34, 35, 36].

The brain metabolic profile in the neonate with a cCDH has been evaluated using fetal and postnatal preoperative magnetic resonance spectroscopy (MRS). Compared to the healthy fetus and neonate, the infant with a cCHD has a lower ratio of the neuronal marker N-acetylaspartate (NAA) to choline and a higher ratio of lactate to choline than expected given their gestational age [23, 25]. Using diffusion tensor imaging (DTI), an increase in the average diffusivity and a decrease in fractional anisotropy in white matter consistent with a delayed maturation have been shown in neonates with critical congenital heart defects compared to healthy controls [23]. Within the critical congenital heart defect cohort, infants with transposition of the great arteries present with the most mature brain white matter microstructure [37]. Overall, brain dysmaturation in the neonate with a cCDH is well-recognized, and fundamental for the understanding of the pathophysiology of subsequent acquired brain injuries.

## 2.3 Heart-and-brain interaction

For the majority of outcome measures – prenatal dysmaturation, prevalence of WMI, severity of neurodevelopmental impairment – neonates with hypoplastic left heart syndrome (HLHS) fare the worst.

The developing heart and the developing brain share a number of genetic pathways which might suggest a genetic contribution to the altered brain development in isolated cCHD [38]. The impact of altered prenatal hemodynamics on cerebral dysmaturation in the fetus with a cCHD has been evaluated. Fetal cerebral hemodynamics have been assessed predominantly by measurements of middle cerebral artery pulsatility index. Results are conflicting [39, 40, 41], but most studies report a lower cerebrovascular resistance in fetuses

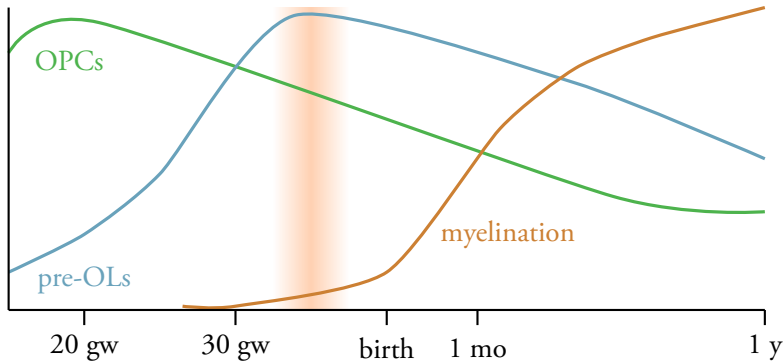
with left-sided obstructive lesions [42]. One study including a fetal cohort with mixed cardiac diagnoses did not find indications of an altered intrauterine cerebral blood flow as determined by MRI, but found an association between decreased cerebral oxygenation and reduced brain volumes [43]. As regards to metabolic maturational data and volumetric data, the absence of antegrad aortic arch flow has been correlated to smaller brain volumes and a lower NAA:choline ratio [25].

The influence of prenatal diagnosis, perioperative care and timing of surgery on the prevalence of subsequent WMI has been investigated in neonates. One study suggests that prenatal diagnosis is associated with less preoperative brain injuries, but found no impact on the prevalence of newly acquired injuries at the postoperative scan [44]. Other studies suggest that a prolonged time to surgery and lower oxygen saturation is associated with a higher risk of pre- and postoperative WMI [12, 45].

The proposed estimate of newly acquired WMI at the postoperative scan ranges from 30% – 70% [9, 13, 10, 11, 12]. The presence of newly acquired WMI has been associated with time on CPB and diagnostic group [10], preoperative brain immaturity [9, 13, 10], the presence of preoperative WMI [10, 9] and time to surgery [12]. Notably, no consistent correlation between intra- and postoperative factors and subsequent white matter alterations has been shown, but a number of studies have shown associations with isolated hemodynamic measurements or estimates of oxygenation whereas other have not [46, 47, 48]. The inconsistency in literature has established an understanding that innate factors predominately guide the prevalence of acquired WMI and neurodevelopmental impairment [4, 7, 8]. Contrary to this notion, there is a significant impact of surgical site on the prevalence of neurodevelopmental impairment and WMI that cannot be accounted for by intrinsic factors only [8, 4, 49, 50].

## 2.4 The developing oligodendrocyte and white matter vulnerability

Oligodendrocyte maturation follows a tightly regulated temporal and spatial scheme with an initial migration of oligodendrocyte progenitor cells (OPCs) along the developing vasculature. When reaching the destined site, OPCs mature into pre-myelinating oligodendrocytes (pre-OLs) and finally, into myelinating oligodendrocytes. Developing oligodendrocytes display a maturation-dependent vulnerability, i.e. stimuli that exert an injurious effect on the immature oligodendrocytes do not have the same effect on the more mature, and therefore more resilient, cells. The cellular response to noxious stimuli encompasses apoptosis, and perhaps even more important in the context of chronic white matter alterations, maturational arrest and subsequent myelination failure [51, 52]. The pre-OLs are exquisitely sensitive to oxidative stress [51, 52], hyperoxia [53, 54], inflammation [55, 56] and perfusion disturbances [51, 56].



**Figure 2:** Schematic representation of pre- and postnatal oligodendrocyte maturation and myelination. Shaded area denotes corresponding brain maturation at birth in a term neonate with a critical congenital heart defect. OPCs = oligodendrocyte progenitor cells, pre-OL = pre-oligodendrocytes, gw = gestational weeks, mo = month, y = year. Graph adapted from [58].

The white matter maturation in an infant with a cCHD follows a delayed, but expected, maturational pattern – from central to peripheral parts of the brain, and from posterior to anterior [37, 57]. The maturational trajectory corresponds to the localization of WMI - a predilection for injuries in the more peripheral parts of the brain and a spared central region [57]. In the infant with a cCHD key oligodendrocyte maturational time points, and thus white matter vulnerability, coincide with a multitude of postnatal stressors, Figure 2.

## 2.5 Cardiopulmonary bypass, circulating cell-free hemoglobin and hyperoxemia in the newborn

Open-heart surgery on cardiopulmonary bypass (CPB) circulation evokes a profound inflammatory and oxidative stress response [59, 60, 61]. We postulated that circulating cell-free hemoglobin (Hb) and hyperoxemia during CPB would translate into white matter brain alterations via activation of inflammatory and pro-oxidative signaling pathways.

Cell-free hemoglobin and its metabolite heme are molecules with pro-inflammatory and oxidative properties. After release from its location within the red blood cell (RBC), cell-free hemoglobin exists in an equilibrium of  $\alpha\beta$ -heterodimers and tetramers. The suggested toxicity of cell-free hemoglobin relies on four main properties; endothelial barrier disruption [62, 63, 64], alterations of vasomotor tone by nitric oxide scavenging [65, 66], production of reactive oxygen species (ROS) in the conversion of ferrous iron ( $\text{Fe}^{2+}$ ) to ferric iron ( $\text{Fe}^{3+}$ ) and ferryl iron ( $\text{Fe}^{4+}$ ) [67, 68, 69], and release of heme [70]. Cell-free hemoglobin toxicity in the context of pediatric bypass circulation has been investigated as a proposed cause of postoperative acute kidney injury [71, 72], but not in relation to developing brain white matter. Importantly, the neonate presents with scarce circulating concentrations of



haptoglobin and hemopexin, the principal scavenger proteins of cell-free hemoglobin and heme, respectively [73].

The detrimental effects of hyperoxemia on the developing brain white matter is well characterized in the preclinical context [53, 54, 74] but less so in the clinical setting of neonatal CPB. An important, but often neglected factor when evaluating the influence of hyperoxia on the immature white matter is the hemodynamic response to acute hyperoxemia with a diminished cardiac output and increased systemic vascular resistance [75], and a decreased cerebral blood flow [76, 77].

### **3 Research strategy**

We explored our hypothesis in a combined experimental and clinical study. The experimental study utilized a novel postnatal day 6 rat pup model. The clinical study included 40 neonates born with a critical congenital heart defect requiring open heart surgery on cardiopulmonary bypass circulation within 30 days of life.

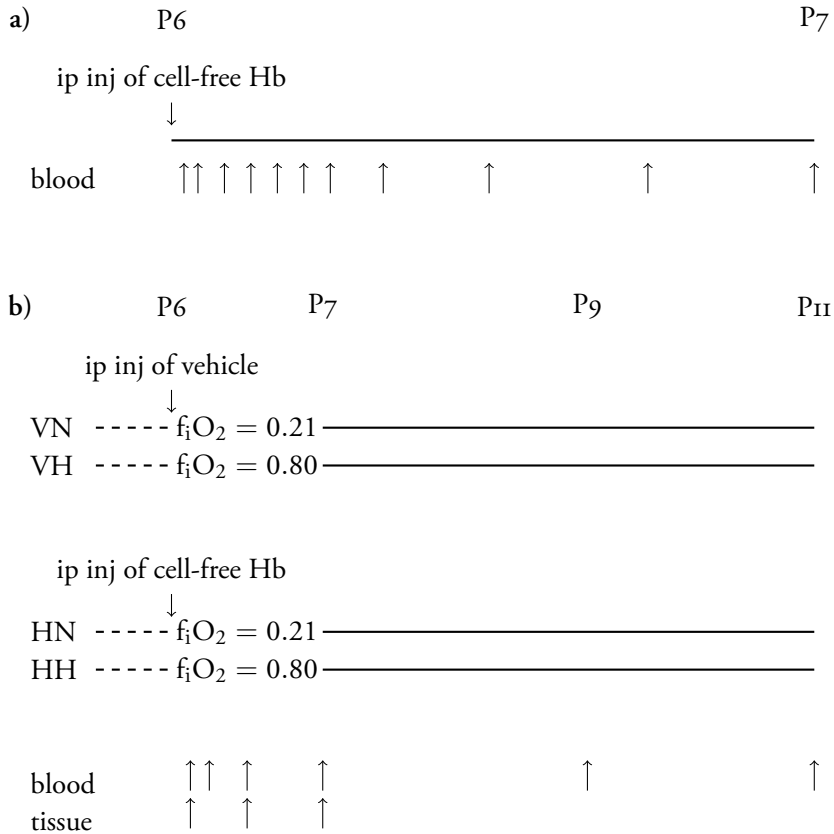
## **4 Material and methods**

### **4.1 Experimental study**

The impact of circulating cell-free hemoglobin and supranormal oxygen tensions on the developing white matter was evaluated as singular and combined insults in a novel rat pup model. Paper I characterizes the animal model and paper II assesses the intraparenchymal cerebral effects.

#### **Animal model**

P6 rat pups were chosen as model animal to account for the relative immaturity of the brain in an infant with a critical congenital heart defect. Human hemoglobin or vehicle were administered intraperitoneally, and the animals were subjected to 24 hours of hyperoxia or normoxia. Model characterization included the definition of plasma pharmacokinetics of circulating cell-free hemoglobin after intraperitoneal administration, measurement of circulating scavenger proteins after exposure to cell-free hemoglobin and/or hyperoxia, relative quantification of scavenger protein gene expression in liver and systemic DNA oxidation. Endogenous scavenger protein plasma concentrations from P0 – P12 were defined in a non-exposed cohort. The study design applied for model characterization is given in Figure 3.

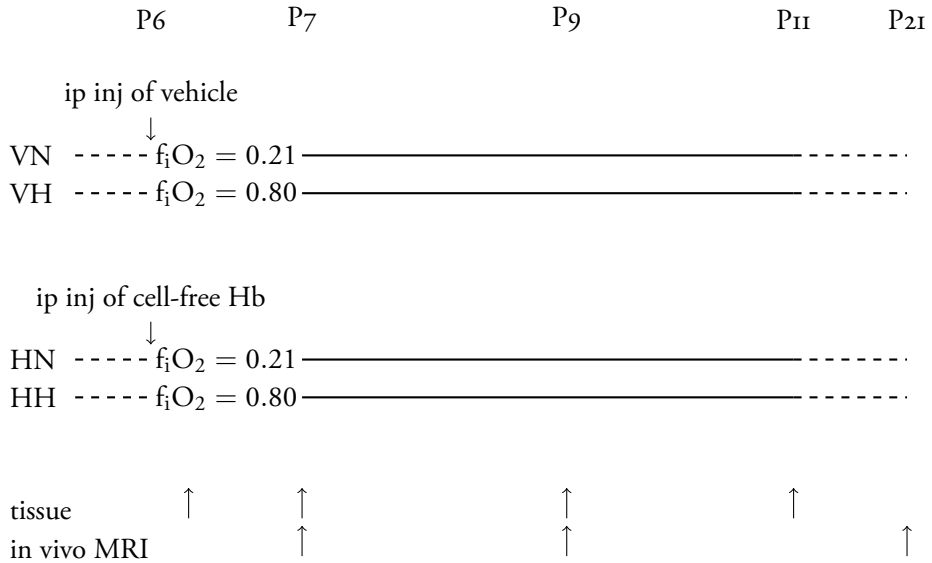


**Figure 3:** Study outline of (a) evaluation of plasma pharmacokinetics after intraperitoneal administration of cell-free hemoglobin, and (b) model characterization of postnatal day 6 rat pup model. Downward pointing arrows indicate intraperitoneal injection, and upward pointing arrows indicate blood and tissue sampling respectively. P6 - 11 = postnatal day 6 - 11, ip = intraperitoneal, Hb = hemoglobin,  $f_iO_2$  = fraction of inspired oxygen. VN = experimental group subjected to vehicle and normoxia (control), VH = vehicle + hyperoxia, HN = hemoglobin + normoxia, HH = hemoglobin + hyperoxia.

Following model characterization, the P6 rat pup model was utilized for evaluating brain white matter alterations after exposure to cell-free hemoglobin and/or hyperoxia. Evaluation of white matter was done using immunohistochemistry, gene array expression analysis (qPCR), protein analysis (Western Blot) and in vivo MRI. Experimental outline of the study on white matter development is given in Figure 4.

### Immunohistochemical evaluation of brain white matter

Immunohistochemistry was performed at postnatal day 7 and postnatal day 11. At postnatal day 7 a marker for apoptosis (TUNEL-stains) was used, at postnatal day 11 a maturational marker (CCr) and a marker for myelination (MBP) was used. Olig2 was considered a



**Figure 4:** Outline of the experimental study evaluating brain white matter alterations after exposure to cell-free hemoglobin and/or hyperoxia in a rat pup model. Downward pointing arrows indicate intraperitoneal injection of vehicle or cell-free hemoglobin, upward pointing arrows indicate tissue sampling and in vivo MRI, respectively. ip = intraperitoneal, inj = injection, Hb = hemoglobin,  $f_iO_2$  = fraction of inspired oxygen, P6 - 21 = postnatal day 6 - 21. VN = experimental group subjected to vehicle and normoxia (control), VH = vehicle + hyperoxia, HN = hemoglobin + normoxia, HH = hemoglobin + hyperoxia.

marker for oligodendrocytes irrespective of maturational stage. Cerebral regions of interest (ROI) were selected according to Figure 5.

### Intraparenchymal gene expression analyses and protein quantification

Gene expression in brain homogenate was evaluated at 6 hours post-exposure, postnatal day 7 and postnatal day 11. Gene expression array analyses were performed on pooled samples evaluating four different pathophysiological pathways: Oxidative stress, Apoptosis,  $NF\kappa B$  signaling pathway and Tight junctions. Protein quantification of myelin basic protein (MBP) as a marker for myelination was performed at postnatal day 11 using Western Blot.

### Preclinical MRI

In vivo brain MRI in rat pups sedated with isoflurane was done at postnatal day 7, 9 and 21 on a 9.4 tesla (T) horizontal bore animal scanner. Details of the preclinical scanning protocol and animal handling is given in Paper 11. Performed sequences included a T2-sequence and a DTI-sequence. Calculation of fractional anisotropy (FA) was selected as



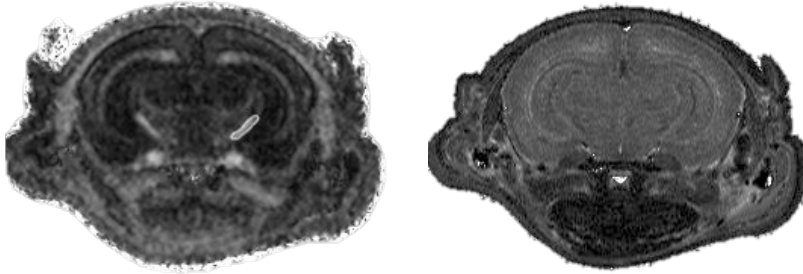
Figure 5: Areas evaluated with immunohistochemistry. a) cortex, b) white matter tracts, c) hippocampus, d) thalamus

the principal means of evaluating white matter microstructural integrity, and T2 relaxation times were chosen as the primary means of evaluating water content in tissue as a proxy parameter for myelination. Three regions of interest were chosen according to their differing maturational timelines: capsula interna, corpus callosum and the trigeminal nerve. Representative image of MRI scans is given in Figure 6.

## 4.2 Clinical study

### Study participants

Forty term neonates with isolated critical congenital heart defects requiring surgery on cardiopulmonary bypass circulation within 30 days of life were included after parental consent. Neonates with hypoxic-ischemic encephalopathy grade 2-3 or a suspected or confirmed syndrome diagnosis were excluded, as were neonates with severe hemodynamic instability requiring cardiopulmonary resuscitation or treatment on extracorporeal membrane oxygenation (ECMO) prior to surgery. Clinical characteristics of the included neonates are described in Table 1. Neonates included in the study were subjected to a preoperative brain MRI, pre-, per- and postoperative sampling of blood and urine until postoperative day 3 and a postoperative MRI after removal of myocardial electrodes. A neurocognitive and neuroradiological follow-up of included children was performed at 2<sup>1</sup>/<sub>2</sub> years of age. Study outline of clinical study is given in Figure 7. Details on the neonates' clinical course are described in Table 2.



**Figure 6:** Preclinical brain MRI scans in a P7 rat pup. Left panel: the diffusion tensor sequence with capsula interna marked as a region of interest. Right panel: the corresponding T2-sequence.

## MRI protocol

Details of MRI protocol are described in Paper iv. MR scans were performed on a 3T MR scanner (PRISMA, Siemens Healthineers, Erlangen, Germany) using a 20 channel receive head coil (Siemens Healthineers, Erlangen, Germany). MR spectroscopy was performed using a point resolved spectroscopy (PRESS) sequence with TR 2000 ms, TE 30 ms, 128 excitations, automated shim and eddy current correction with a non-water suppressed scan. A voxel size of  $2 \times 2 \times 2 \text{ cm}^3$  was used for grey and white matter volumes, positioned in midline grey matter structures of the parietooccipital lobes posteriorly to the corpus callosum and, for white matter, in the left parietooccipital lobe, superoposterior to the lateral ventricle. The basal ganglia volume of  $2 \times 4 \times 2 \text{ cm}^3$  covered both basal ganglia including the third ventricle. Voxel of interest (VOI) positioning is illustrated in Figure 8.

## Preoperative image acquisition

Preoperative imaging was obtained in 24 neonates at a median postnatal age of four days. The preoperative MRI scans were performed at a median time point of one day before surgery, Table 1.

Electrocardiogram (ECG), invasive blood pressure, end-tidal carbon dioxide,  $S_pO_2$  and ventilatory parameters were continuously monitored throughout the image acquisition in intubated infants (9/24). The previous sedation regimen was continued during the MRI examination in 7/9 neonates, for 2/9 neonates sedation depth was increased. Non-intubated infants (15/24) were fed and placed in a vacuum mattress. 13/15 neonates received adjunct

**Table 1:** Clinical characteristics and obtained MRI examinations of the 40 neonates included in the clinical study. For abbreviations of cardiac diagnosis, please see "Abbreviations". RACHS1 = Risk Adjustment in Congenital Heart Surgery - 1, MRI = magnetic resonance imaging

sex (male/female) ( <i>n</i> )	25/15
birthweight, grams (mean±SD)	3357 ± 336
gestational age, weeks (mean (range))	39+5 (38+0 – 42+1)
diagnosis ( <i>n</i> )	
biventricular repair ( <i>n</i> =32)	TGA/ IVS (11) TGA/VSD (9) aa hypoplasia/VSD (5) truncus arteriosus (2) TGA/VSD/aa hypoplasia (1) aa hypoplasia (1) TAPVD (1) IAA, LVOTO (1) aortic stenosis (1)
palliative procedure ( <i>n</i> =8)	HLHS (3) PA/IVS/RV-hypoplasia (3) PA/VSD/RV-hypoplasia (1) TGA/PS (1)
preop MRI ( <i>n</i> )	24
postnatal age at preoperative MRI, days (median (IQR))	4 (2 - 5)
days between preoperative MRI and surgery (median (IQR))	1 (1- 3)
postnatal age at surgery, days (median (IQR))	5 (4 - 7)
RACHS -1 (median (range))	4 (3 - 6)
postop MRI ( <i>n</i> )	33
postnatal age at postoperative MRI, days (median (IQR))	13 (11 - 17)
days between surgery and MRI (median (IQR))	7 (6 - 10)

sedation with dexmedetomidine, 2/15 did not receive any pharmacological sedation. All infants were monitored by continuous ECG, invasive blood pressure measurement,  $S_pO_2$  and respiratory rate. No adverse circulatory or respiratory events were documented during the preoperative image acquisition.

### Postoperative image acquisition

Postoperative imaging was obtained in 33 neonates at a median postnatal age of 13 days. The postoperative scans were performed at a median of seven days post surgery, Table 1.

The neonates were fed and placed in a vacuum mattress. 19/33 infants received dexmedetomidine as an adjunct sedative, whereas 7/33 neonates received chloralhydrate due to previous administration of long-acting anti-arrhythmic drugs in the postoperative period. 5/33 neonates received oral clonidine due to lack of intravenous access. 2/33 infants did

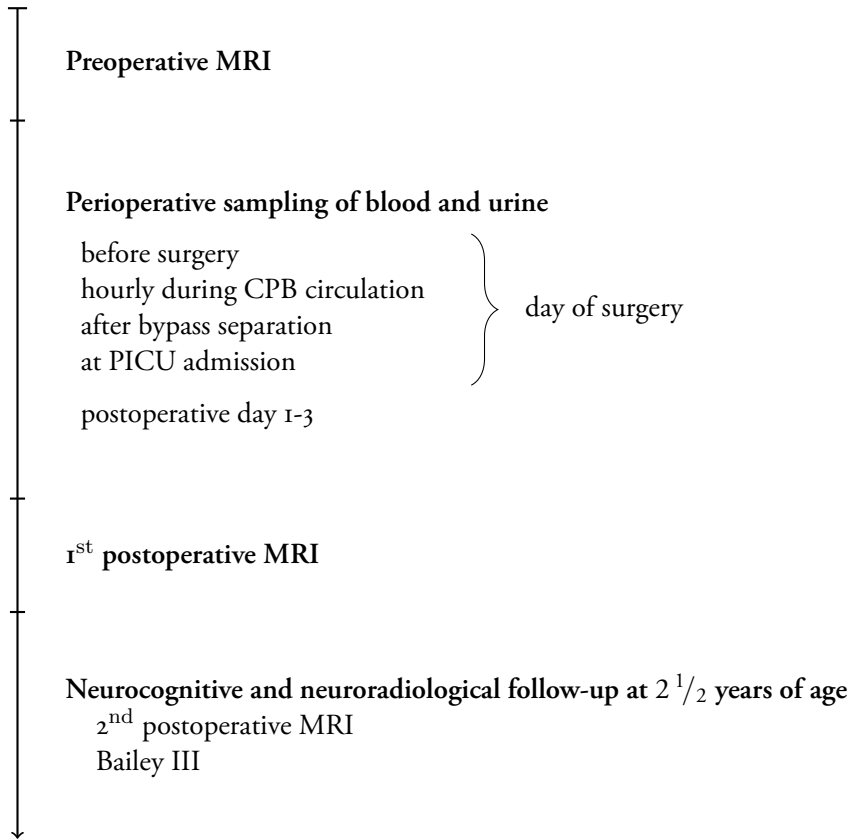


Figure 7: Study outline of clinical study

not receive any pharmacological sedation due to a structurally difficult airway as deemed by the intubating anesthesiologist at the time of surgery. All infants were monitored by continuous ECG,  $S_pO_2$  and respiratory rate during image acquisition. No circulatory or respiratory adverse events were documented during postoperative image acquisition. All neonates were awake and alert when returning to the ward.

### Calculations of exposure to cell-free hemoglobin and supranormal oxygen tension

Exposure to cell-free hemoglobin and supranormal oxygen tensions were quantified by AUC-calculations. For cell-free hemoglobin, calculations started at start of bypass and ended at postoperative day 1. Baseline was set to 0. For oxygen exposure, calculations were started at start of bypass and ended at separation from bypass. Baseline was set to the preoperative oxygen tension. Representative image of AUC-calculations for one patient is given in Figure 9.

**Table 2:** Pre-, per- and postoperative clinical characteristics of 40 neonates included in the clinical study. None of the neonates were diagnosed with postoperative low cardiac output syndrome (LCOS) defined as two consecutive measurements of lactate > 4.0 mmol/L and pH < 7.3 [48]. None of the neonates required postoperative cardiopulmonary resuscitation or postoperative ECMO. BAS = balloon atrial septostomy, PICU = pediatric intensive care unit, CPB = cardiopulmonary bypass, DHCA = deep hypothermic cardiac arrest, NPWT = negative pressure wound therapy, LOS = length of stay

prenatal diagnosis ( <i>n</i> )	18
BAS ( <i>n</i> )	13
preoperative care in PICU ( <i>n</i> )	38
preoperative prostaglandins ( <i>n</i> )	35
preoperative invasive ventilation ( <i>n</i> )	9
highest preoperative lactate, mmol/L (median (IQR))	2.8 (2.2 - 4.0)
time on CPB, min (mean±SD)	182 ± 61
selective cerebral perfusion ( <i>n</i> )	11
DHCA ( <i>n</i> )	1
lowest temperature on CPB (median (IQR))	32.8 (29.9 - 33.4)
ultrafiltration ( <i>n</i> )	23
highest postoperative lactate, mmol/L (median (IQR))	3.1 (2.3 - 3.9)
delayed sternal closure ( <i>n</i> )	17
postoperative peritoneal dialysis ( <i>n</i> )	1
postoperative seizures ( <i>n</i> )	2
postoperative infection	3
superficial surgical site infection ( <i>n</i> )	2
pulmonary infection ( <i>n</i> )	1
unplanned reoperation ( <i>n</i> )	5
pericardial drainage ( <i>n</i> )	3
NPWT ( <i>n</i> )	3
LOS in PICU, hours (median (IQR))	72 (46 - 137)

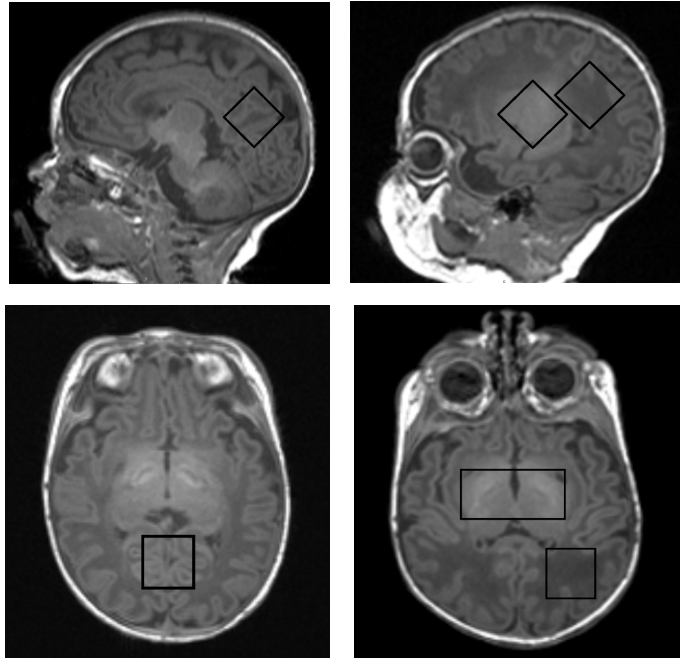
### Analysis of circulating cell-free hemoglobin, haptoglobin and hemopexin

Analysis of circulation cell-free hemoglobin and its scavenger proteins haptoglobin and hemopexin were made using commercially available enzyme-linked immunosorbent assays (ELISA) according to the manufacturer's instructions.

### 4.3 Statistics

Data were tested for distribution characteristics using the Shapiro-Wilk test. Student's t-test was used for group-wise comparisons between groups with normally distributed data. Wilcoxon rank-sum test was used for group-wise comparisons of non-paired data with non-normal distributions. Wilcoxon signed-rank test was used for group-wise comparisons of paired data with non-normal distributions. Partially overlapping samples t-test [78] was used when comparing groups with both non-paired and paired data. One-way ANOVA with post hoc Tukey's test was used for testing between multiple groups.





**Figure 8:** Illustration of MRS voxel positioning on sagittal (upper row) and axial (lower row) T1-weighted images. Grey matter voxels were positioned in the parietooccipital midline grey matter (left panels). White matter voxels were positioned in the parietal white matter in the left hemisphere and basal ganglia voxels as a large voxel covering both basal ganglia (right panels). Voxels were angulated to optimize positioning (upper row).

Sample size for the clinical study was determined by assuming a prevalence of acquired postoperative white matter injury of 40%, a difference of means in cell-free hemoglobin exposure between the groups with and without postoperative white matter lesions of 150%, and a standard deviation of 40% in the group without postoperative white matter lesions. With alpha set to 0.05 and power to 0.8, the sample size was estimated to be 11 neonates per group.

Univariate and multivariate linear regression modeling was applied to the clinical data. In cohorts including paired and unpaired data mixed linear regression models was used.

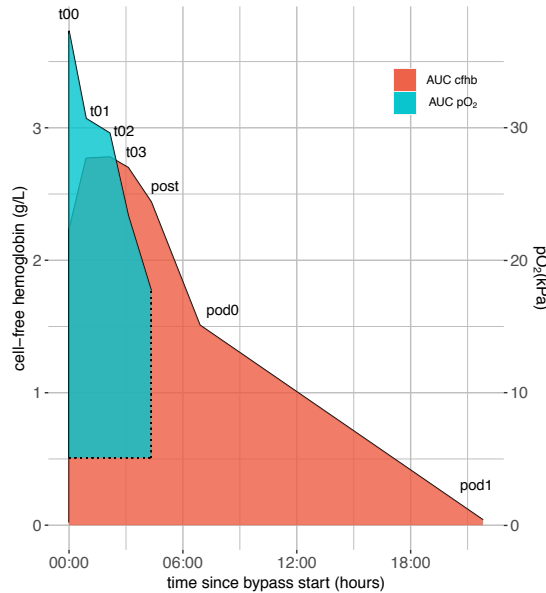
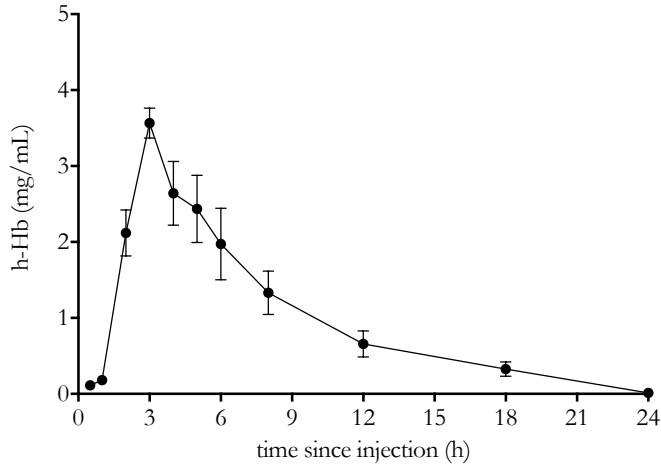


Figure 9: Area under curve (AUC) calculations for cell-free hemoglobin exposure and exposure to supranormal oxygen tensions in one patient. Cell-free hemoglobin concentrations is given on the left y-axis whereas oxygen tensions is given on the right y-axis. 00:00 denotes bypass start. Baseline for calculations of cell-free hemoglobin exposure was set to 0, whereas baseline for calculations of oxygen exposure was set to preoperative  $pO_2$  (in the illustrated patient 5.05 kPa). t00 = start of bypass, t01 - t04 = hourly sampling during bypass circulation, post = separation from bypass, pod0 = PICU admission, pod1 = postoperative day 1

For all statistical testing,  $p < 0.05$  was considered significant.

#### 4.4 Ethics

Ethical permit was granted from Lund Ethics Committee on Animal Testing, permit number M48-14, for the experimental study, and from the Swedish Ethical Review Authority, permit number 2014/479, for the clinical study. Written informed parental consent was obtained from both guardians for all participants in the clinical study prior to inclusion.



**Figure 10:** Plasma concentrations of cell-free hemoglobin after intraperitoneal administration. h-Hb = human cell-free hemoglobin. Black circle denotes mean value, error bars denotes standard error of the mean.  $n = 5 - 7$  at each time point.

## 5 Main results of the research papers

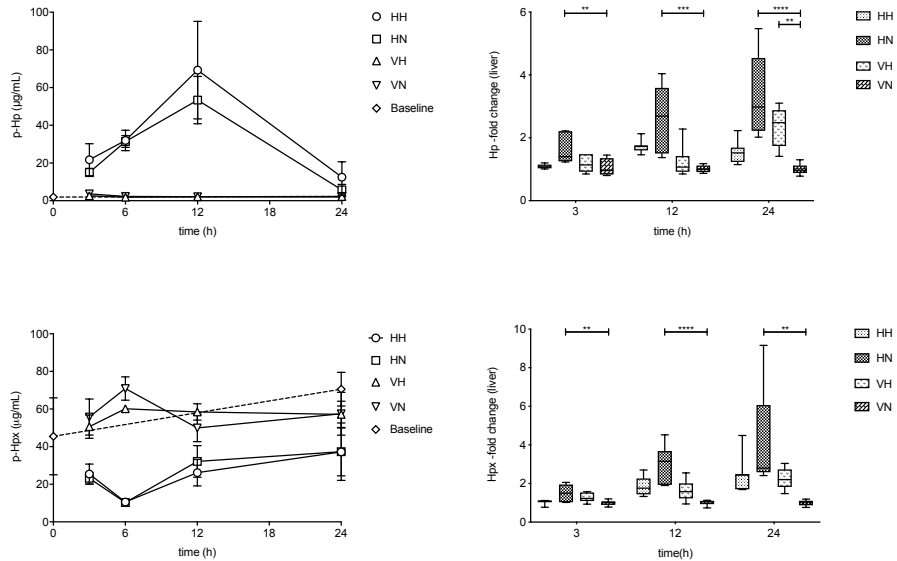
### 5.1 Paper I and II

#### **Intraperitoneally administered cell-free hemoglobin has a predictable systemic uptake and clearance**

We observed a temporally uniform systemic uptake and clearance of cell-free hemoglobin after intraperitoneal administration. Approximately 1/10th - 1/15th of the administered amount reached the systemic circulation. Maximal circulating concentrations of cell-free hemoglobin was obtained at 3 hours after injection. Plasma cell-free hemoglobin was completely cleared from circulation 24 hours post-injection. A graphic illustration of cell-free hemoglobin uptake and clearance is given in Figure 10.

#### **Intraperitoneally administered cell-free hemoglobin renders an endogenous scavenger response**

We found a distinct increase in circulating concentrations of haptoglobin at 6 and 12 hours post injection of cell-free hemoglobin, and a concomitant decrease in hemopexin plasma concentrations. At 24 hours post injection haptoglobin concentration were approximately equal to the concentration in control (i.e. not exposed to either insult) animals, Figure 11.



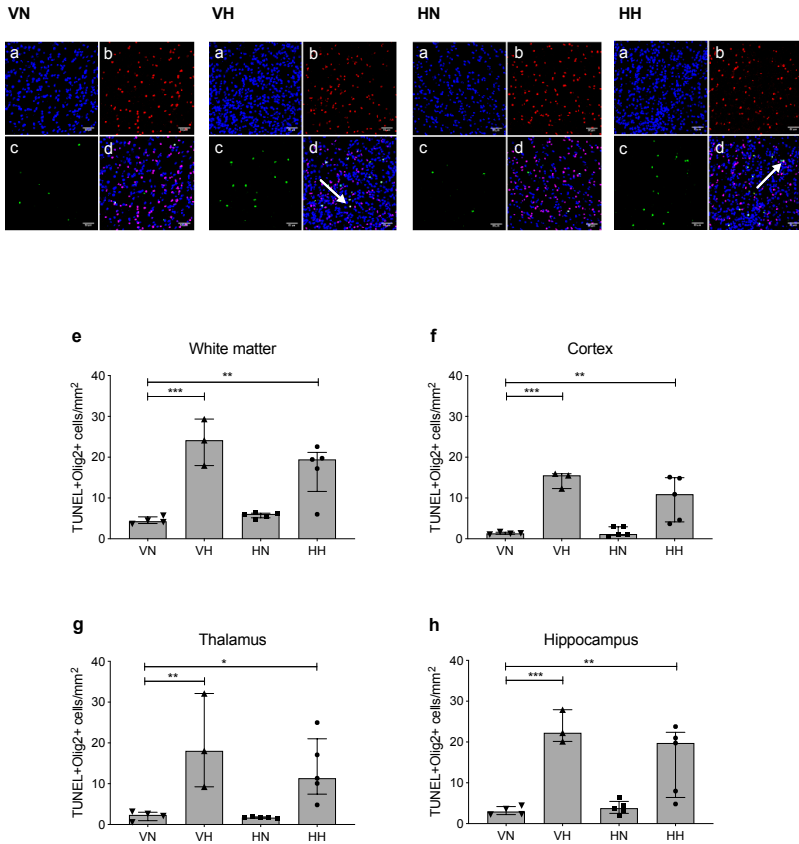
**Figure 11:** **Left panels:** Plasma concentrations of haptoglobin and hemopexin after intraperitoneal administration of cell-free hemoglobin or vehicle  $\pm$  hyperoxia. Symbols denote mean value, error bars denote standard deviation **Right panels:** Hepatic gene expression after intraperitoneal administration of cell-free hemoglobin or vehicle  $\pm$  hyperoxia. Hp = haptoglobin. Hpx = hemopexin, VN = experimental group subjected to vehicle and normoxia (control), VH = vehicle + hyperoxia, HN = hemoglobin + normoxia, HH = hemoglobin + hyperoxia. Baseline = non-exposed rat pups.  $n = 5 - 18$  in all experimental groups

### Hyperoxic exposure accelerates cell-free hemoglobin metabolism and alters scavenger protein gene expression

The circulating concentrations of free heme were increased at 3 hours post injection in the group subjected to hemoglobin exposure and hyperoxia (HH) compared to the group exposed to hemoglobin injection and normoxia (HN), data not shown. The hepatic gene expression of haptoglobin and hemopexin was mitigated in the group subjected to hemoglobin injection and hyperoxia (HH) compared to the increased in gene expression in the group subjected to hemoglobin exposure and normoxia (HN), Figure 11.

### Hyperoxic exposure with or without the addition of cell-free hemoglobin is associated with increased apoptosis in the developing oligodendrocyte

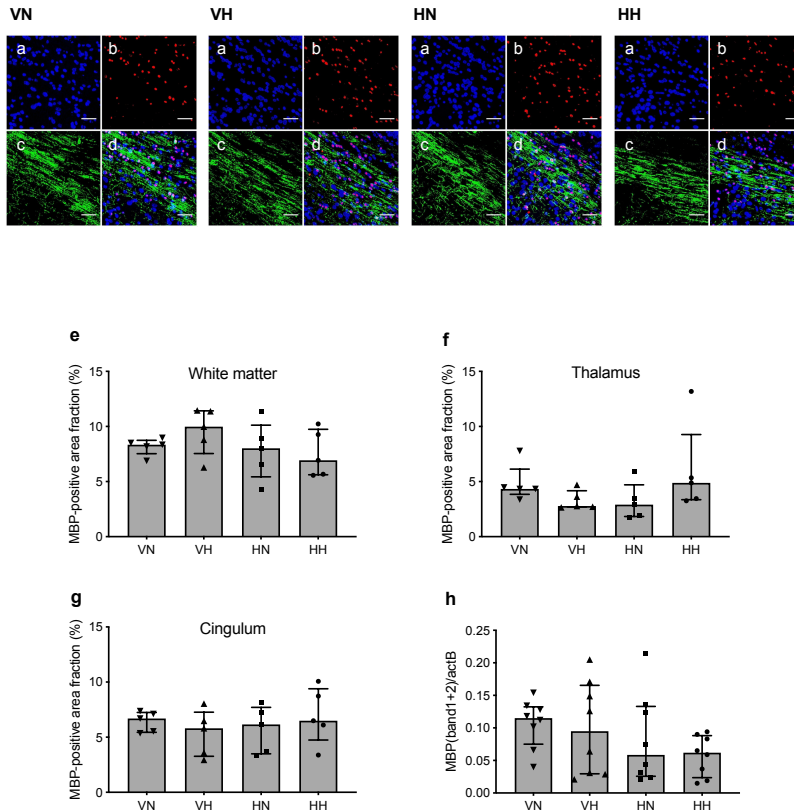
We found an increased apoptosis as determined by immunohistochemistry in the developing oligodendrocytes at P7 in rat pups exposed to a hyperoxic environment. The presence or absence of cell-free hemoglobin exposure did not aggravate or mitigate the influence of hyperoxia, Figure 12.



**Figure 12:** TUNEL/Olig2 staining of rat pup brain sections after exposure to hyperoxia (VH), circulating cell-free Hb (HN), both insults (HH), or neither insult (VN). Representative images were acquired at P7 (24 h post injection) in all experimental groups. Scale bar = 50  $\mu$ m. (a) blue = DAPI staining of cell nuclei; (b) red = Olig2+ cells; (c) green = TUNEL+ cells; and (d) merged image. White arrows indicate co-labelled cells. TUNEL+Olig2+ cells were quantified in (e) white matter, (f) cortex, (g) thalamus, and (h) hippocampus at P7. Results are presented as the median and IQR; n = 3- 5. \*p < 0.05, \*\*p < 0.01, \*\*\*p < 0.001. DAPI, 4',6 diamidino 2 phenylindole; TUNEL, terminal deoxynucleotidyl transferase dUTP nick end labelling; P7, postnatal day 7; Olig2, oligodendrocyte transcription factor 2, IQR, interquartile range.

**No indications of decreased myelination or delayed oligodendrocyte maturation were observed at P11 and P21**

We did not find any evidence of decreased myelination after exposure to cell-free hemoglobin and/or hyperoxia when evaluated with immunohistochemistry and Western Blot at postnatal day 11, Figure 13. Nor did we find any evidence of a decreased number of mature oligodendrocytes using CC1 as a maturational marker at P11, or a delayed white matter maturation defined as a decreased FA-value and an increased T2-relaxation time at the in vivo MRI at postnatal day 21, data not shown.

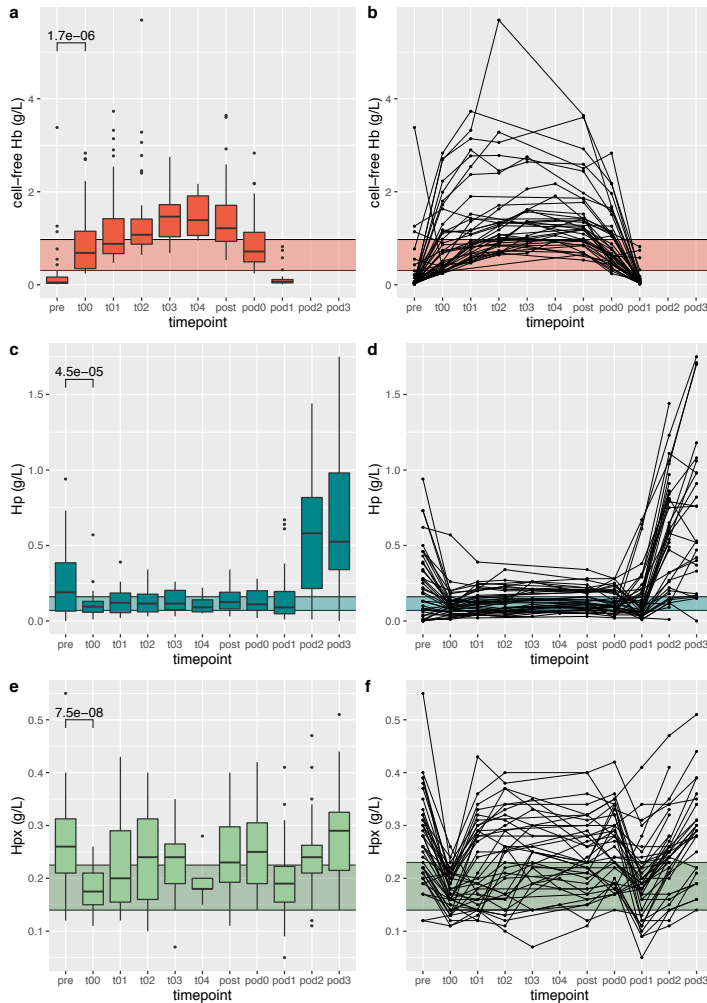


**Figure 13:** IHC analysis of myelin formation in rat pup brain after exposure to hyperoxia (VH), circulating cell-free Hb (HN), both insults (HH), or neither insult (VN). (a-d) Representative images show MBP in brain sections at P11 (120 h post injection) in all experimental groups. Scale bar = 50 μm. (a) Blue = DAPI-staining of cell nuclei, (b) red = Olig2+ cells, (c) green = MBP, and (d) merged image. (e-g) Quantification of MBP protein content, displayed as the fraction of the region of interest area (%) in (e) white matter, (f) thalamus, and (g) cingulum; (h) Western blot analysis of MBP content (MBP band 1+2) compared to endogenous β-actin (actB) in brain homogenates at P11. Results are presented as the median and IQR; n = 5 (a-c), n = 8 (d). IHC = immunohistochemistry; MBP = myelin basic protein; P11 = postnatal day 11; DAPI = 4',6 diamidino 2 phenylindole; Olig2 = oligodendrocyte transcription factor 2; IQR = interquartile range.

## 5.2 Paper III

### Concentration of cell-free hemoglobin in blood prime solution is the main determinant of the neonate's exposure to cell-free hemoglobin during bypass circulation

The main predictor for cell-free hemoglobin exposure during neonatal cardiopulmonary bypass was the concentration of cell-free hemoglobin in the prime solution. Time on bypass, intraoperative red blood cell transfusion, age of blood product in prime solution or vacuum-assisted venous drainage and ultrafiltration as dichotomous variables were not associated with exposure to cell-free hemoglobin in our cohort.



**Figure 14:** Circulating concentrations of cell-free hemoglobin (Hb) (a,b), haptoglobin (Hp) (c,d) and hemopexin (Hpx) (e,f) illustrated as aggregated (a,c,e) and individual (b, d, f) data. Shaded area denotes IQR of concentrations of respective protein in prime solution. pre = preoperative, t00 = start of bypass, t01-t04 = hourly sampling during bypass circulation, post = separation from bypass, pod0 = PICU admission, pod1-3 = postoperative day 1-3

## Blood prime solution depletes hemoglobin scavenger resources during and after bypass circulation

The circulating concentrations of hemoglobin- and heme-scavenger proteins haptoglobin and hemopexin were significantly decreased at bypass start compared to preoperative plasma concentrations. For haptoglobin, plasma concentrations remained low until postoperative day 1. Figure 14 depicts the circulating concentrations of scavenger proteins and cell-free hemoglobin during the perioperative course.

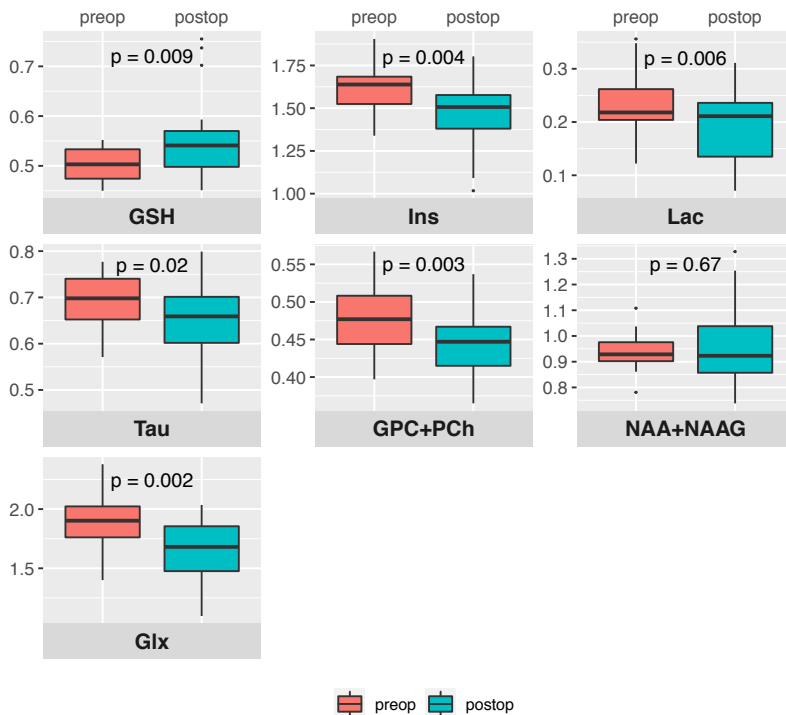


Figure 15: Pre- and postoperative white matter magnetic spectroscopy data from entire cohort. GSH = glutathione, Ins = inositol, Lac = lactate, Tau = taurine, GPC + PCh = composite measurement of glycerophosphorylcholine and phosphocholine, NAA + NAAG = composite measurement of N-acetylaspartate and N-acetylaspartylglutamate, Glx = composite measurement of glutamine and glutamate

### 5.3 Paper iv

#### White matter brain metabolite concentrations shift during the perioperative course

The concentrations of white matter brain metabolites were significantly different at the postoperative MRI scan compared to the preoperative MRI scan, Figure 15. For glutathione (GSH), glutaminergic metabolites (Glx) and choline-containing metabolites (GPC + PCh), the metabolite shift was attributed to surgery per se, and not to increasing postnatal age. For lactate, taurine and inositol no distinction between increasing postnatal age and the influence of surgery could be made. The expected developmental trajectory with an increase in both Glx and the composite measure of N-acetylaspartate and N-acetylaspartylglutamate (NAA + NAAG) with increasing postnatal age was not observed.



## **Postoperative glutathione and Glx metabolite concentrations are inversely related to time on cardiopulmonary bypass**

When analyzing the postoperative cohort, concentrations of GSH, an intracellular antioxidant, and Glx, a marker of cerebral energy metabolism, was inversely related to time on cardiopulmonary bypass, i. e., the longer duration of bypass, the lower concentrations of GSH and Glx.

## **6 Discussion**

As of now, we have not been able to show that any of our postulated insults – exposure to cell-free hemoglobin and supranormal oxygen tensions – translates into long-lasting white matter alterations.

A postoperative prevalence of 50% WMI in our clinical study confirms the vulnerability of brain white matter when exposed to neonatal cardiac surgery. We have not been able to correlate our proposed insults to adverse outcomes as determined by MRI-diagnosed white matter alterations, but we believe that previous research on neonatal white matter vulnerability and the concept of white matter injury as the consequence of an accumulated burden makes it reasonable to minimize the exposure to potentially harmful stimuli if possible. As no means are available to increase endogenous brain resilience as of now, the balance between stress resilience and vulnerability must be shifted by minimizing exogenous stressors.

Hyperoxemia is an easily avoidable stressor that needs to be recognized. The initial oxygen tensions on bypass circulation in our clinical cohort ranged between 13.3 – 50.4 kPa with a median-value of 29.8 kPa. Supranormal oxygen tensions are harmful to the immature brain, and perhaps even more so in a neonatal cCDH cohort as the majority of neonates in such a cohort will have a cyanotic heart defect [79]. Moreover, the observation of the profound influence of cell-free hemoglobin concentration in blood prime solution on the neonate's exposure to cell-free hemoglobin provides a way of minimizing the exposure by considering the concentrations of cell-free hemoglobin in prime solution. This might not be relevant from a purely neuroprotective perspective, but in terms of the impact of cell-free hemoglobin on the risk of postoperative acute kidney injury [71].

### **6.1 Predicting the future from a snapshot in time**

Our clinical study cohort is a fairly representative sample of the neonatal open heart surgery cohort at our pediatric heart center. The perioperative course followed the expected

trajectory and no major postoperative complications were documented. WMI was diagnosed in 50% of the patients with a postoperative MRI scan, the second most common postoperative cerebral lesion was cerebellar microhemorrhages detected in seven patients. Postoperative brain injuries beyond white matter lesions and cerebellar microhemorrhages were rare, but of note, three patients were diagnosed with clinically silent central venous sinus thrombosis (CVST). The finding of postoperative CVST in neonates with a cCHD is recently described [80], but the origins and clinical relevance of a clinically silent CVST are not well-characterized.

What does a postoperative prevalence of structural WMI in 50% of neonates imply? The association between MRI-determined WMI at term age and adverse neurodevelopmental outcome is well established in the premature cohort [81]. A number of studies indicate a correlation between moderate-severe WMI in the neonatal period and subsequent neurodevelopmental impairment in neonates with cCDH [82, 83]. One study [10] reports a negative finding but notably, 7 of 19 infants with moderate-severe WMI in the latter study died before neurodevelopmental follow-up.

Sequential MRI-studies in infants with cCDH have shown resolution of white matter brain injuries over time in a substantial proportion of patients [9, 10, 84]. Importantly, in those studies white matter evaluation consisted only of a structural assessment. It must be stressed that resolution of a structural lesion not necessarily equates to a restoration of function, nor does a structural lesion imply a mandatorily impaired neurodevelopment. More studies are needed to evaluate the long-term impact of white matter alterations in neonates with a cCHD including not only white matter structural lesions but also more elaborate assessments of white matter function.

## 6.2 Modeling a multifactorial pathway of injury

The development of white matter injuries in neonates is multifactorial, making animal modeling of its origins challenging. In our experimental study we deemed that a corresponding brain maturation to that of a neonate with a cCDH was of great importance given the maturation-dependent vulnerability in developing oligodendrocytes. Neurodevelopment in the rodent brain and in the human brain share key neurodevelopmental time points [85], but the immaturity of the brain in a neonate with cCDH might not only represent a delayed maturation but rather a dysmaturation. Moreover, modeling brain injury in a rodent model assumes that there is an approximately similar resilience in the newborn brain compared to that in the rodent pup brain, and that there exist common cross-species pathophysiological pathways.

To single out two potentially harmful factors – hyperoxia and systemic inflammation – is a reductionist approach to understand very specific parts of the diverse impact of cardiopul-

monary bypass on the immature brain. A model with a greater mechanistic validity would incorporate surgical trauma and bypass circulation, making interpretation and differentiation of the specific factors difficult and prone to confounding. There are published data from piglet bypass models [86, 87], with a more or less corresponding brain maturation to that of a neonate with a cCHD. Irrespective of a small or large animal model, the very specific intrauterine and postnatal conditions that apply to an infant with a cCHD will be challenging to model [88].

A major disadvantage of using rat pups when modeling cell-free hemoglobin toxicity is the rat's capability of endogenous ascorbic acid production. Endogenous ascorbic acid acts as an important detoxifier of cell-free hemoglobin as showed in a comparative study on rats and guinea pigs [89], guinea pigs being the only rodent species with a similar incapability of endogenous ascorbic acid production as humans. Unfortunately, guinea pigs are precocial animals with a far more accelerated brain maturity at birth than the human neonate, rendering them unsuitable for studies on neonatal brain injuries.

In our animal model we observed an interaction between the exposure to hyperoxia and the exposure to cell-free hemoglobin with a mitigated response in scavenger protein gene expression in liver, Figure 11. As of now, we do not have a plausible explanation for this observation, but we acknowledge the potential interaction between inflammation and hyperoxia [90, 91].

### **6.3 Inherent limitations and advantages of a small single-center cohort**

Our clinical study is an investigation of a small single center cohort and the results must be interpreted as such. Established paradigms of determinants for the development of WMI in neonatal cardiac surgery – boys fare worse than girls and single-ventricle physiology is a risk factor – were not evident in our cohort, presumably due to the low number of included infants and the exceedingly low number of neonates undergoing initial surgical palliation. As in all single-center studies, the external validity of our study is limited and our results cannot uncritically be adapted into another clinical context.

The included neonates were operated and anesthetized by a limited number of surgeons and anesthetists. They were scanned on the same MRI scanner and the images were evaluated by the same pediatric neuroradiologist. The samples were handled by the same person throughout the study. The advantages of the homogeneity in the execution of a single center study must be balanced by the time it will take to include the number of participants that equates to an adequately powered study. In our clinical study, forty neonates were included over a time period of 34 months.

Finally, the knowledge of an ongoing study and its objectives might alter the clinical treat-

ment during the study. We did not observe any change in perfusion regimen as determined by initial pO<sub>2</sub>, initial concentration of cell-free hemoglobin or the absence or presence of ultrafiltration. No changes over time were noted in the clinical characteristics of included neonates, nor in the timing of surgery and MRI-scans.

## 7 Conclusions and future research directions

### **Paper I**

Intraperitoneal administration of cell-free hemoglobin results in significant plasma concentrations of cell-free hemoglobin and an endogenous scavenger protein response

### **Paper II**

No long-lasting alterations in the developing brain white matter can be observed after exposure to circulating cell-free hemoglobin and/or supranormal oxygen tensions in our rat pup model

### **Paper III**

Concentration of cell-free hemoglobin in blood prime solution is the main determinant of the neonate's exposure to cell-free hemoglobin during open-heart surgery on cardiopulmonary bypass

### **Paper IV**

Postoperative white matter concentrations of Glx and GSH are correlated to the duration of cardiopulmonary bypass circulation. Exposure to cell-free hemoglobin or hyperoxemia did not influence the postoperative white matter metabolite profile

### **Long-term follow-up**

Our finding of a 50% prevalence of postoperative structural white matter lesions is consistent with previous reports on white matter injury in neonatal cardiac cohorts. Whether the high prevalence of white matter injury in our cohort translates into clinically relevant adverse neurodevelopmental outcomes is currently being evaluated in a structured follow-up study at 2 1/2 years of age.

## **Analysis of postoperative inflammatory proteome and oxidative stress burden**

The potential impact of exposure to cell-free hemoglobin and hyperoxemia on pathophysiological processes includes delineating alterations in the inflammatory proteome and quantification of the oxidative stress burden attributable to our postulated insults. We have observed a rapid and temporally uniform postoperative inflammatory response in our cohort, where the inflammatory profile at postoperative day 1 can be used to predict white matter lesions at the postoperative MRI scan. The proteins with the highest predictive value in our cohort are mainly involved in regulating the postoperative immune cell response. Several alterations in protein expression are associated with exposure to cell-free hemoglobin and supranormal oxygen tensions, but those results have not yet been controlled for confounding factors.

A likewise important analysis is the quantification of oxidative stress burden posed on the developing brain. We will quantify oxidative stress by analyzing oxidized nucleic acids in urine [92].

## **Diffusion tensor analysis and analysis of network connectivity**

Our clinical MRI-data will be analyzed for alterations in diffusion and network connectivity to allow evaluation of white matter microstructural integrity and network topology. We believe that a thorough understanding of the etiology of the white matter vulnerability in neonates with congenital heart defects requires a more elaborate pre- and postoperative white matter assessment than a structural assessment only.

## **Circulating brain injury markers**

Circulating neural and glial cell injury markers are currently being evaluated in relation to postulated insults and clinical determinants.

## **Analysis of the correlation between macro-circulation and brain hemodynamics**

A crucial part of understanding the origins of the postoperative white matter injuries is an evaluation of the relation between patient and pump hemodynamic parameters and cerebral blood flow. We have access to new technologies that provide continuous non-invasive measures of microvascular perfusion and oxygenation in the frontal cerebral cortex using a combination of near infrared spectroscopy and diffuse correlation spectroscopy. We will be able to estimate not only pre- and postoperative cerebral blood flow, but also the non-pulsatile flow during bypass circulation.

## 8 Closing remarks

The newborn with a cCHD has a dysmature and vulnerable brain. The optimal neuroprotective strategies for open-heart surgery in the neonatal period must incorporate hemodynamic considerations as well as the particular pathophysiology associated with the developing white matter. The finding of 50% structural WMI in the postoperative cohort warrants the implementation of a systematic neurocognitive follow-up that extends into adolescence.

## 9 References

- [1] Bradley S Marino, Paul H Lipkin, Jane W Newburger, Georgina Peacock, Marsha Gerdes, J William Gaynor, Kathleen A Mussatto, Karen Uzark, Caren S Goldberg, Walter H Johnson, Jennifer Li, Sabrina E Smith, David C Bellinger, William T Mahle, and American Heart Association Congenital Heart Defects Committee, Council on Cardiovascular Disease in the Young, Council on Cardiovascular Nursing, and Stroke Council. Neurodevelopmental outcomes in children with congenital heart disease: evaluation and management: a scientific statement from the American Heart Association. *Circulation*, 126(9):1143–1172, August 2012.
- [2] Rabia Liamlahi and Beatrice Latal. *Neurodevelopmental outcome of children with congenital heart disease*, volume 162. Elsevier, 2019.
- [3] Patrick S McQuillen and Steven P Miller. Congenital heart disease and brain development. *Annals of the New York Academy of Sciences*, 1184(1):68–86, January 2010.
- [4] J William Gaynor, Christian Stopp, David Wypij, Dean B Andropoulos, Joseph Atallah, Andrew M Atz, John Beca, Mary T Donofrio, Kim Duncan, Nancy S Ghanayem, Caren S Goldberg, Hedwig Hövels-Gürich, Fukiko Ichida, Jeffrey P Jacobs, Robert Justo, Beatrice Latal, Jennifer S Li, William T Mahle, Patrick S McQuillen, Shaji C Menon, Victoria L Pemberton, Nancy A Pike, Christian Pizarro, Lara S Shekerdemian, Anne Synnes, Ismee Williams, David C Bellinger, Jane W Newburger, and International Cardiac Collaborative on Neurodevelopment (ICCON) Investigators. Neurodevelopmental outcomes after cardiac surgery in infancy. *Pediatrics*, 135(5):816–825, May 2015.
- [5] Ariane Marelli, Steven P Miller, Bradley Scott Marino, Angela L Jefferson, and Jane W Newburger. Brain in Congenital Heart Disease Across the Lifespan: The Cumulative Burden of Injury. *Circulation*, 133(20):1951–1962, May 2016.
- [6] Shabnam Peyvandi, Beatrice Latal, Steven P Miller, and Patrick S McQuillen. The neonatal brain in critical congenital heart disease: Insights and future directions. *NeuroImage*, 185:776–782, January 2019.
- [7] Hedwig Hubertine Hövels-Gürich. Factors Influencing Neurodevelopment after Cardiac Surgery during Infancy. *Frontiers in Pediatrics*, 4(12):1111, December 2016.
- [8] International Cardiac Collaborative on Neurodevelopment (ICCON) Investigators. Impact of Operative and Postoperative Factors on Neurodevelopmental Outcomes After Cardiac Operations. *The Annals of Thoracic Surgery*, 102(3):843–849, September 2016.

- [9] Dean B Andropoulos, Jill V Hunter, David P Nelson, Stephen A Stayer, Ann R Stark, E Dean McKenzie, Jeffrey S Heinle, Daniel E Graves, and Charles D Fraser. Brain immaturity is associated with brain injury before and after neonatal cardiac surgery with high-flow bypass and cerebral oxygenation monitoring. *The Journal of Thoracic and Cardiovascular Surgery*, 139(3):543–556, March 2010.
- [10] John Beca, Julia K Gunn, Lee Coleman, Ayton Hope, Peter W Reed, Rodney W Hunt, Kirsten Finucane, Christian Brizard, Briana Dance, and Lara S Shekerdeman. New White matter brain injury after infant heart surgery is associated with diagnostic group and the use of circulatory arrest. *Circulation*, 127(9):971–979, March 2013.
- [11] Selma O Algra, Nicolaas J G Jansen, Ingeborg van der Tweel, Antonius N J Schouten, Floris Groenendaal, Mona Toet, Wim van Oeveren, Ingrid C van Haastert, Paul H Schoof, Linda S de Vries, and Felix Haas. Neurological injury after neonatal cardiac surgery: a randomized, controlled trial of 2 perfusion techniques. *Circulation*, 129(2):224–233, January 2014.
- [12] Jennifer M Lynch, Erin M Buckley, Peter J Schwab, Ann L McCarthy, Madeline E Winters, David R Busch, Rui Xiao, Donna A Goff, Susan C Nicolson, Lisa M Montenegro, Stephanie Fuller, J William Gaynor, Thomas L Spray, Arjun G Yodh, Maryam Y Naim, and Daniel J Licht. Time to surgery and preoperative cerebral hemodynamics predict postoperative white matter injury in neonates with hypoplastic left heart syndrome. *The Journal of Thoracic and Cardiovascular Surgery*, 148(5):2181–2188, November 2014.
- [13] Anastasia Dimitropoulos, Patrick S McQuillen, Viyeka Sethi, Alisha Moosa, Vann Chau, Duan Xu, Rollin Brant, Anthony Azakie, Andrew Campbell, A James Barkovich, Kenneth J Poskitt, and Steven P Miller. Brain injury and development in newborns with critical congenital heart disease. *Neurology*, 81(3):241–248, July 2013.
- [14] Elisa Cainelli, Filippo Arrigoni, and Luca Vedovelli. White matter injury and neurodevelopmental disabilities: A cross-disease (dis)connection. *Progress in Neurobiology*, 193:101845, October 2020.
- [15] Michael von Rhein, Andreas Buchmann, Cornelia Hagmann, Reto Huber, Peter Klaver, Walter Knirsch, and Beatrice Latal. Brain volumes predict neurodevelopment in adolescents after surgery for congenital heart disease. *Brain*, 137:268–276, January 2014.
- [16] Ashok Panigrahy, Vincent J Schmithorst, Jessica L Wisnowski, Christopher G Watson, David C Bellinger, Jane W Newburger, and Michael J Rivkin. Relationship of white matter network topology and cognitive outcome in adolescents with d-transposition of the great arteries. *YNICL*, 7:438–448, 2015.



- [17] Caitlin K Rollins, Christopher G Watson, Lisa A Asaro, David Wypij, Sridhar Vajapeyam, David C Bellinger, David R DeMaso, Richard L Robertson, Jane W Newburger, and Michael J Rivkin. White matter microstructure and cognition in adolescents with congenital heart disease. *The Journal of Pediatrics*, 165(5):936–44.e1–2, November 2014.
- [18] Christopher G Watson, Christian Stopp, David Wypij, David C Bellinger, Jane W Newburger, and Michael J Rivkin. Altered White Matter Microstructure Correlates with IQ and Processing Speed in Children and Adolescents Post-Fontan. *The Journal of Pediatrics*, 200:140–149.e4, September 2018.
- [19] Vincent J Schmithorst, Ashok Panigrahy, J William Gaynor, Christopher G Watson, Vince Lee, David C Bellinger, Michael J Rivkin, and Jane W Newburger. Organizational topology of brain and its relationship to ADHD in adolescents with d-transposition of the great arteries. *Brain and Behavior*, 6(8):e00504–12, June 2016.
- [20] D C Bellinger, D Wypij, M J Rivkin, D R DeMaso, R L Robertson, C Dunbar-Masterson, L A Rappaport, G Wernovsky, R A Jonas, and J W Newburger. Adolescents With d-Transposition of the Great Arteries Corrected With the Arterial Switch Procedure: Neuropsychological Assessment and Structural Brain Imaging. *Circulation*, 124(12):1361–1369, September 2011.
- [21] Nathalie H P Claessens, Selma O Algra, Tom L Ouwehand, Nicolaas J G Jansen, Renske Schappin, Felix Haas, Maria J C Eijssers, Linda S de Vries, Manon J N L Benders, and CHD Lifespan Study Group Utrecht. Perioperative neonatal brain injury is associated with worse school-age neurodevelopment in children with critical congenital heart disease. *Developmental Medicine & Child Neurology*, 60(10):1052–1058, October 2018.
- [22] Kaitlyn Easson, Charles V Rohlicek, Jean-Christophe Houde, Guillaume Gilbert, Christine Saint-Martin, Kimberly Fontes, Annette Majnemer, Ariane Marelli, Pia Wintermark, Maxime Descoteaux, and Marie Brossard-Racine. Quantification of apparent axon density and orientation dispersion in the white matter of youth born with congenital heart disease. *NeuroImage*, 205:116255, January 2020.
- [23] Steven P Miller, Patrick S McQuillen, Shannon Hamrick, Duan Xu, David V Glidden, Natalie Charlton, Tom Karl, Anthony Azakie, Donna M Ferriero, A James Barkovich, and Daniel B Vigneron. Abnormal brain development in newborns with congenital heart disease. *New England Journal of Medicine*, 357(19):1928–1938, November 2007.
- [24] Daniel J Licht, David M Shera, Robert R Clancy, Gil Wernovsky, Lisa M Montenegro, Susan C Nicolson, Robert A Zimmerman, Thomas L Spray, J William Gaynor, and

- Arastoo Vossough. Brain maturation is delayed in infants with complex congenital heart defects. *The Journal of Thoracic and Cardiovascular Surgery*, 137(3):529 – 36, March 2009.
- [25] C Limperopoulos, W Tworetzky, D B McElhinney, J W Newburger, D W Brown, R L Robertson, N Guizard, E McGrath, J Geva, D Annese, C Dunbar-Masterson, B Trainor, P C Laussen, and A J du Plessis. Brain Volume and Metabolism in Fetuses With Congenital Heart Disease: Evaluation With Quantitative Magnetic Resonance Imaging and Spectroscopy. *Circulation*, 121(1):26–33, January 2010.
- [26] Cynthia Ortinau, John Beca, Jennifer Lambeth, Barbara Ferdman, Dimitrios Alexopoulos, Joshua S Shimony, Michael Wallendorf, Jeffrey Neil, and Terrie Inder. Regional alterations in cerebral growth exist preoperatively in infants with congenital heart disease. *The Journal of Thoracic and Cardiovascular Surgery*, 143(6):1264–1270, June 2012.
- [27] H Olshaker, R Ber, D Hoffman, E Derazne, R Achiron, and E Katorza. Volumetric Brain MRI Study in Fetuses with Congenital Heart Disease. *American Journal of Neuroradiology*, 39(6):1164–1169, June 2018.
- [28] Cynthia M Ortinau, Kathryn Mangin-Heimos, Joseph Moen, Dimitrios Alexopoulos, Terrie E Inder, Ali Gholipour, Joshua S Shimony, Pirooz Eghtesady, Bradley L Schlaggar, and Christopher D Smyser. Prenatal to postnatal trajectory of brain growth in complex congenital heart disease. *YNICL*, 20:913–922, 2018.
- [29] Michael von Rhein, Andreas Buchmann, Cornelia Hagmann, Hitendu Dave, Vera Bernet, Ianina Scheer, Walter Knirsch, and Beatrice Latal. Severe Congenital Heart Defects Are Associated with Global Reduction of Neonatal Brain Volumes. *The Journal of Pediatrics*, 167(6):1259–1263.e1, December 2015.
- [30] N H P Claessens, N Khalili, I Isgum, H ter Heide, T J Steenhuis, E Turk, N J G Jansen, L S de Vries, J M P J Breur, R de Heus, and M J N L Benders. Brain and CSF volumes in fetuses and neonates with antenatal diagnosis of critical congenital heart disease: A longitudinal MRI study. *American Journal of Neuroradiology*, 40(5):885–891, January 2019.
- [31] Martin Poryo, Laura Antonia Paes, Thomas Pickardt, Ulrike M M Bauer, Sascha Meyer, Stefan Wagenpfeil, Hashim Abdul-Khaliq, and German Competence Network for Congenital Heart Defects Investigators. Somatic Development in Children with Congenital Heart Defects. *The Journal of Pediatrics*, 192:136–143.e4, January 2018.
- [32] Niels B Matthiesen, Tine B Henriksen, Peter Agergaard, J William Gaynor, Cathrine C Bach, Vibeke E Hjortdal, and John R Østergaard. Congenital Heart Defects

- and Indices of Placental and Fetal Growth in a Nationwide Study of 924 422 Liveborn Infants. *Circulation*, 134(20):1546–1556, November 2016.
- [33] Cynthia Ortinau, Dimitrios Alexopoulos, Donna Dierker, David Van Essen, John Beca, and Terrie Inder. Cortical folding is altered before surgery in infants with congenital heart disease. *The Journal of Pediatrics*, 163(5):1507–1510, November 2013.
- [34] Christopher J Kelly, Antonios Makropoulos, Lucilio Cordero-Grande, Jana Hutter, Anthony Price, Emer Hughes, Maria Murgasova, Rui Pedro A G Teixeira, Johannes K Steinweg, Sagar Kulkarni, Loay Rahman, Hui Zhang, Daniel C Alexander, Kuberan Pushparajah, Daniel Rueckert, Joseph V Hajnal, John Simpson, A David Edwards, Mary A Rutherford, and Serena J Counsell. Impaired development of the cerebral cortex in infants with congenital heart disease is correlated to reduced cerebral oxygen delivery. *Scientific Reports*, 7(1):15088–10, November 2017.
- [35] C Clouchoux, A J du Plessis, M Bouyssi-Kobar, W Tworetzky, D B McElhinney, D W Brown, A Gholipour, D Kudelski, S K Warfield, R J McCarter, R L Robertson, A C Evans, J W Newburger, and C Limperopoulos. Delayed cortical development in fetuses with complex congenital heart disease. *Cerebral Cortex*, 23(12):2932–2943, December 2013.
- [36] Christopher J Kelly, Daan Christiaens, Dafnis Batalle, Antonios Makropoulos, Lucilio Cordero-Grande, Johannes K Steinweg, Jonathan O’Muircheartaigh, Hammad Khan, Geraint Lee, Suresh Victor, Daniel C Alexander, Hui Zhang, John Simpson, Joseph V Hajnal, A David Edwards, Mary A Rutherford, and Serena J Counsell. Abnormal Microstructural Development of the Cerebral Cortex in Neonates With Congenital Heart Disease Is Associated With Impaired Cerebral Oxygen Delivery. *Journal of the American Heart Association*, 8(5):e009893, March 2019.
- [37] Nathalie H P Claessens, Johannes M P J Breur, Floris Groenendaal, Roelie M Wösten-van Asperen, Raymond Stegeman, Felix Haas, Jeroen Dudink, Linda S de Vries, Nicolaas J G Jansen, and Manon J N L Benders. Brain microstructural development in neonates with critical congenital heart disease: An atlas-based diffusion tensor imaging study. *YNICL*, 21:101672, 2019.
- [38] Patrick S McQuillen, Donna A Goff, and Daniel J Licht. Effects of congenital heart disease on brain development. *Progress in Pediatric Cardiology*, 29(2):79–85, August 2010.
- [39] J R Kaltman, H Di, Z Tian, and J Rychik. Impact of congenital heart disease on cerebrovascular blood flow dynamics in the fetus. *Ultrasound in Obstetrics & Gynecology*, 25(1):32–36, January 2005.

- [40] M J Mebius, S A B Clur, A S Vink, E Pajkrt, W S Kalteren, E M W Kooi, A F Bos, G J du Marchie Sarvaas, and C M Bilardo. Growth patterns and cerebroplacental hemodynamics in fetuses with congenital heart disease. *Ultrasound in Obstetrics & Gynecology*, 53(6):769–778, June 2019.
- [41] Tingting Man, Yihua He, Ying Zhao, Lin Sun, Xiaowei Liu, and Shuping Ge. Cerebrovascular hemodynamics in fetuses with congenital heart disease. *Echocardiography*, 34(12):1867–1871, December 2017.
- [42] Fenna A R Jansen, Sheila M P Everwijn, Robert Scheepjens, Theo Stijnen, Cacha M P C D Peeters-Scholte, Jan M M van Lith, and Monique C Haak. Fetal brain imaging in isolated congenital heart defects – a systematic review and meta-analysis. *Prenatal Diagnosis*, 36(7):601–613, July 2016.
- [43] Liqun Sun, Christopher K Macgowan, John G Sled, Shi-Joon Yoo, Cedric Manlhiot, Prashob Porayette, Lars Grosse-Wortmann, Edgar Jaeggi, Brian W McCrindle, John Kingdom, Edward Hickey, Steven Miller, and Mike Seed. Reduced fetal cerebral oxygen consumption is associated with smaller brain size in fetuses with congenital heart disease. *Circulation*, 131(15):1313–1323, January 2015.
- [44] Shabnam Peyvandi, Veronica De Santiago, Elavazhagan Chakkarapani, Vann Chau, Andrew Campbell, Kenneth J Poskitt, Duan Xu, A James Barkovich, Steven Miller, and Patrick McQuillen. Association of Prenatal Diagnosis of Critical Congenital Heart Disease With Postnatal Brain Development and the Risk of Brain Injury. *JAMA Pediatrics*, 170(4):e154450, April 2016.
- [45] Christopher J Petit, Jonathan J Rome, Gil Wernovsky, Stefanie E Mason, David M Shera, Susan C Nicolson, Lisa M Montenegro, Sarah Tabbutt, Robert A Zimmerman, and Daniel J Licht. Preoperative brain injury in transposition of the great arteries is associated with oxygenation and time to surgery, not balloon atrial septostomy. *Circulation*, 119(5):709–716, February 2009.
- [46] Patrick S McQuillen, A James Barkovich, Shannon E G Hamrick, Marta Perez, Phil Ward, David V Glidden, Anthony Azakie, Tom Karl, and Steven P Miller. Temporal and anatomic risk profile of brain injury with neonatal repair of congenital heart defects. *Stroke*, 38(2 Suppl):736–741, February 2007.
- [47] Jane W Newburger, Lynn A Sleeper, David C Bellinger, Caren S Goldberg, Sarah Tabbutt, Minmin Lu, Kathleen A Mussatto, Ismee A Williams, Kathryn E Gustafson, Seema Mital, Nancy Pike, Erica Sood, William T Mahle, David S Cooper, Carolyn Dunbar-Masterson, Catherine Dent Krawczeski, Alan Lewis, Shaji C Menon, Victoria L Pemberton, Chitra Ravishankar, Teresa W Atz, Richard G Ohye, J William Gaynor, and Pediatric Heart Network Investigators. Early developmental outcome

- in children with hypoplastic left heart syndrome and related anomalies: the single ventricle reconstruction trial. *Circulation*, 125(17):2081–2091, May 2012.
- [48] Nathalie H P Claessens, Nicolaas J G Jansen, Johannes M P J Breur, Selma O Algra, Raymond Stegeman, Thomas Alderliesten, Kim van Loon, Linda S de Vries, Felix Haas, Manon J N L Benders, and Petra M A Lemmers. Postoperative cerebral oxygenation was not associated with new brain injury in infants with congenital heart disease. *The Journal of Thoracic and Cardiovascular Surgery*, 158(3):867–877.e1, September 2019.
- [49] Selma O Algra, Felix Haas, Kenneth J Poskitt, Floris Groenendaal, Antonius N J Schouten, Nicolaas J G Jansen, Anthony Azakie, Sanjiv Gandhi, Andrew Campbell, Steven P Miller, Patrick S McQuillen, and Linda S de Vries. Minimizing the risk of preoperative brain injury in neonates with aortic arch obstruction. *The Journal of Pediatrics*, 165(6):1116–1122.e3, December 2014.
- [50] Nathalie H P Claessens, Vann Chau, Linda S de Vries, Nicolaas J G Jansen, Stephanie H Au-Young, Raymond Stegeman, Susan Blaser, Manohar Shroff, Felix Haas, Davide Marini, Johannes M P J Breur, Mike Seed, Manon J N L Benders, and Steven P Miller. Brain Injury in Infants with Critical Congenital Heart Disease: Insights from Two Clinical Cohorts with Different Practice Approaches. *The Journal of Pediatrics*, 215:75–82.e2, December 2019.
- [51] Stephen A Back and Paul A Rosenberg. Pathophysiology of glia in perinatal white matter injury. *Glia*, 62(11):1790–1815, January 2014.
- [52] Joseph J Volpe, Hannah C Kinney, Frances E Jensen, and Paul A Rosenberg. The developing oligodendrocyte: key cellular target in brain injury in the premature infant. *International Journal of Developmental Neuroscience*, 29(4):423–440, June 2011.
- [53] Bettina Reich, Daniela Hoerber, Ivo Bendix, and Ursula Felderhoff-Mueser. Hyperoxia and the Immature Brain. *Developmental Neuroscience*, 38(5):311–330, March 2017.
- [54] Bettina Gerstner, Tara M DeSilva, Kerstin Genz, Amy Armstrong, Felix Brehmer, Rachael L Neve, Ursula Felderhoff-Mueser, Joseph J Volpe, and Paul A Rosenberg. Hyperoxia causes maturation-dependent cell death in the developing white matter. *The Journal of Neuroscience*, 28(5):1236–1245, January 2008.
- [55] Géraldine Favrais, Yohan van de Looij, Bobbi Fleiss, Nelina Ramanantsoa, Philippe Bonnin, Gisela Stoltenburg-Didingier, Adrien Lacaud, Elie Saliba, Olaf Dammann, Jorge Gallego, Stéphane Sizonenko, Henrik Hagberg, Vincent Lelièvre, and Pierre Gressens. Systemic inflammation disrupts the developmental program of white matter. *Annals of Neurology*, 70(4):550–565, October 2011.

- [56] Juliane Schneider and Steven P Miller. *Preterm brain Injury: White matter injury*. Elsevier, January 2019.
- [57] Ting Guo, Vann Chau, Shabnam Peyvandi, Beatrice Latal, Patrick S McQuillen, Walter Knirsch, Anne Synnes, Maria Feldmann, Nadja Naef, M Mallar Chakravarty, Alessandra De Petrillo, Emma G Duerden, A James Barkovich, and Steven P Miller. White matter injury in term neonates with congenital heart diseases: Topology & comparison with preterm newborns. *NeuroImage*, 185:742–749, January 2019.
- [58] Erik van Tilborg, Caroline G M de Theije, Maurik van Hal, Nienke Wagenaar, Linda S de Vries, Manon J Benders, David H Rowitch, and Cora H Nijboer. Origin and dynamics of oligodendrocytes in the developing brain: Implications for perinatal white matter injury. *Glia*, 66(2):221–238, February 2018.
- [59] Deborah J Kozik and James S Tweddell. Characterizing the inflammatory response to cardiopulmonary bypass in children. *The Annals of Thoracic Surgery*, 81(6):S2347–54, June 2006.
- [60] Oliver J Warren, Andrew J Smith, Christos Alexiou, Paula L B Rogers, Noorulhuda Jawad, Charles Vincent, Ara W Darzi, and Thanos Athanasiou. The inflammatory response to cardiopulmonary bypass: part 1—mechanisms of pathogenesis. *Journal of Cardiothoracic and Vascular Anesthesia*, 23(2):223–231, April 2009.
- [61] Daniel Fudulu and Gianni Angelini. Oxidative Stress after Surgery on the Immature Heart. *Oxidative Medicine and Cellular Longevity*, 2016(4):1971452–10, 2016.
- [62] Ciara M Shaver, Nancy Wickersham, J Brennan McNeil, Hiromasa Nagata, Adam Miller, Stuart R Landstreet, Jamie L Kuck, Joshua M Diamond, David J Lederer, Steven M Kawut, Scott M Palmer, Keith M Wille, Ann Weinacker, Vibha N Lama, Maria M Crespo, Jonathan B Orens, Pali D Shah, Chadi A Hage, Edward Cantu, Mary K Porteous, Gundeep Dhillon, John McDyer, Julie A Bastarache, Jason D Christie, Lorraine B Ware, and Lung Transplant Outcomes Group (LTOG). Cell-free hemoglobin promotes primary graft dysfunction through oxidative lung endothelial injury. *JCI Insight*, 3(2):H650, January 2018.
- [63] Jamie E Meegan, Ciara M Shaver, Nathan D Putz, Jordan J Jesse, Stuart R Landstreet, Han Noo Ri Lee, Tatiana N Sidorova, J Brennan McNeil, James L Wynn, Joyce Cheung-Flynn, Padmini Komalavilas, Colleen M Brophy, Lorraine B Ware, and Julie A Bastarache. Cell-free hemoglobin increases inflammation, lung apoptosis, and microvascular permeability in murine polymicrobial sepsis. *PLoS ONE*, 15(2):e0228727, 2020.
- [64] Omer I Butt, Paul W Buehler, and Felice D’Agnillo. Blood-brain barrier disruption and oxidative stress in guinea pig after systemic exposure to modified cell-free hemoglobin. *The American Journal of Pathology*, 178(3):1316–1328, March 2011.

- [65] Iris C Vermeulen Windsant, Norbert C J de Wit, Jonas T C Sertorio, Annemarie A van Bijnen, Yuri M Ganushchak, John H Heijmans, Jose E Tanus-Santos, Michael J Jacobs, Jos G Maessen, and Wim A Buurman. Hemolysis during cardiac surgery is associated with increased intravascular nitric oxide consumption and perioperative kidney and intestinal tissue damage. *Frontiers in Physiology*, 5:340, 2014.
- [66] Christine C Helms, Mark T Gladwin, and Daniel B Kim-Shapiro. Erythrocytes and vascular function: Oxygen and nitric oxide. *Frontiers in Physiology*, 9(FEB):125, February 2018.
- [67] Magnus G Olsson, Maria Allhorn, Leif Bülow, Stefan R Hansson, David Ley, Martin L Olsson, Artur Schmidtchen, and Bo Åkerström. Pathological conditions involving extracellular hemoglobin: molecular mechanisms, clinical significance, and novel therapeutic opportunities for  $\alpha(1)$ -microglobulin. *Antioxidants & Redox Signaling*, 17(5):813–846, September 2012.
- [68] Dominik J Schaer, Paul W Buehler, Abdu I Alayash, John D Belcher, and Gregory M Vercellotti. Hemolysis and free hemoglobin revisited: exploring hemoglobin and heme scavengers as a novel class of therapeutic proteins. *Blood*, 121(8):1276–1284, February 2013.
- [69] Joseph M Rifkind, Joy G Mohanty, and Erika Nagababu. The pathophysiology of extracellular hemoglobin associated with enhanced oxidative reactions. *Frontiers in Physiology*, 5:500, 2014.
- [70] Fabianno F Dutra and Marcelo T Bozza. Heme on innate immunity and inflammation. *Frontiers in Pharmacology*, 5(e14298):115, 2014.
- [71] Lara S Mamikonian, Lisa B Mamo, P Brian Smith, Jeannie Koo, Andrew J Lodge, and Jennifer L Turi. Cardiopulmonary bypass is associated with hemolysis and acute kidney injury in neonates, infants, and children. *Pediatric Critical Care Medicine*, 15(3):e111–9, March 2014.
- [72] Nahmah Kim-Campbell, Catherine Gretchen, Clifton Callaway, Kathryn Felmet, Patrick M Kochanek, Timothy Maul, Peter Wearden, Mahesh Sharma, Melita Viegas, Ricardo Munoz, Mark T Gladwin, and Hülya Bayir. Cell-Free Plasma Hemoglobin and Male Gender Are Risk Factors for Acute Kidney Injury in Low Risk Children Undergoing Cardiopulmonary Bypass. *Critical Care Medicine*, 45(11):e1123–e1130, November 2017.
- [73] F Kanakoudi, V Drossou, V Tzimouli, E Diamanti, T Konstantinidis, A Germanis, and G Kremenopoulos. Serum concentrations of 10 acute-phase proteins in healthy term and preterm infants from birth to age 6 months. *Clinical Chemistry*, 41(4):605–608, April 1995.

- [74] Yun-Wen Peng, Terry Major, Azmath Mohammed, Kristopher B Deatrck, and John R Charpie. Normoxic re-oxygenation ameliorates end-organ injury after cardiopulmonary bypass. *Journal of Cardiothoracic Surgery*, 15(1):134, June 2020.
- [75] Bob Smit, Yvo M Smulders, Johannes C van der Wouden, Heleen M Oudemans-van Straaten, and Angelique M E Spoelstra-de Man. Hemodynamic effects of acute hyperoxia: systematic review and meta-analysis. *Critical Care*, 22(1):45, February 2018.
- [76] Thomas F Floyd, James M Clark, Robert Gelfand, John A Detre, Sarah Ratcliffe, Dimitri Guvakov, Christian J Lambertsen, and Roderic G Eckenhoff. Independent cerebral vasoconstrictive effects of hyperoxia and accompanying arterial hypocapnia at 1 ATA. *Journal of Applied Physiology*, 95(6):2453–2461, December 2003.
- [77] João D Mattos, Monique O Campos, Marcos P Rocha, Daniel E Mansur, Helena N M Rocha, Vinicius P Garcia, Gabriel Batista, Thiago S Alvares, Gustavo V Oliveira, Mônica V Souza, Rogério L R Videira, Natalia G Rocha, Niels H Secher, Antonio C L Nóbrega, and Igor A Fernandes. Human brain blood flow and metabolism during isocapnic hyperoxia: the role of reactive oxygen species. *The Journal of Physiology*, 597(3):741–755, February 2019.
- [78] Ben Derrick, Deirdre Toher, and Paul White. How to compare the means of two samples that include paired observations and independent observations: A companion to Derrick, Russ, Toher and White (2017). *The Quantitative Methods for Psychology*, 13(2):120–126, May 2017.
- [79] Meredith L Sheil, Catherine Luxford, Michael J Davies, Jennifer K Peat, Graham Nunn, and David S Celermajer. Protein oxidation injury occurs during pediatric cardiopulmonary bypass. *The Journal of Thoracic and Cardiovascular Surgery*, 130(4):1054–1061, October 2005.
- [80] Nathalie H P Claessens, Selma O Algra, Nicolaas J G Jansen, Floris Groenendaal, Esther de Wit, Alexander A Wilbrink, Felix Haas, Antonius N J Schouten, Rutger A J Nievelstein, Manon J N L Benders, and Linda S de Vries. Clinical and neuroimaging characteristics of cerebral sinovenous thrombosis in neonates undergoing cardiac surgery. *The Journal of Thoracic and Cardiovascular Surgery*, 155(3):1150–1158, March 2018.
- [81] Elizabeth K Sewell and Nickie N Andescavage. Neuroimaging for Neurodevelopmental Prognostication in High-Risk Neonates. *Clinics in Perinatology*, 45(3):421–437, September 2018.
- [82] Shabnam Peyvandi, Vann Chau, Ting Guo, Duan Xu, Hannah C Glass, Anne Synnes, Kenneth Poskitt, A James Barkovich, Steven P Miller, and Patrick S McQuillen. Neonatal Brain Injury and Timing of Neurodevelopmental Assessment in



- Patients With Congenital Heart Disease. *Journal of the American College of Cardiology*, 71(18):1986–1996, May 2018.
- [83] Nathalie H P Claessens, Selma O Algra, Tom L Ouweland, Nicolaas J G Jansen, Renske Schappin, Felix Haas, Maria J C Eijssers, Linda S de Vries, Manon J N L Benders, and CHD Lifespan Study Group Utrecht. Perioperative neonatal brain injury is associated with worse school-age neurodevelopment in children with critical congenital heart disease. *Developmental Medicine & Child Neurology*, 60(10):1052–1058, October 2018.
- [84] William T Mahle, Federica Tavani, Robert A Zimmerman, Susan C Nicolson, Kristin K Galli, J William Gaynor, Robert R Clancy, Lisa M Montenegro, Thomas L Spray, Rosetta M Chiavacci, Gil Wernovsky, and C Dean Kurth. An MRI study of neurological injury before and after congenital heart surgery. *Circulation*, 106(12 Suppl 1):I109–14, September 2002.
- [85] Bridgette D Semple, Klas Blomgren, Kayleen Gimlin, Donna M Ferriero, and Linda J Noble-Haesslein. Brain development in rodents and humans: Identifying benchmarks of maturation and vulnerability to injury across species. *Progress in Neurobiology*, 106-107:1–16, July 2013.
- [86] Gary R Stinnett, Stephen Lin, Alexandru V Korotcov, Ludmila Korotcova, Paul D Morton, Shruti D Ramachandra, Angeline Pham, Sonali Kumar, Kota Agematsu, David Zurakowski, Paul C Wang, Richard A Jonas, and Nobuyuki Ishibashi. Microstructural Alterations and Oligodendrocyte Dysmaturation in White Matter After Cardiopulmonary Bypass in a Juvenile Porcine Model. *Journal of the American Heart Association*, 6(8), August 2017.
- [87] Andreas W Loepke, Jeffrey A Golden, John C McCann, and C Dean Kurth. Injury pattern of the neonatal brain after hypothermic low-flow cardiopulmonary bypass in a piglet model. *Anesthesia & Analgesia*, 101(2):340–8– table of contents, August 2005.
- [88] Paul D Morton, Nobuyuki Ishibashi, Richard A Jonas, and Vittorio Gallo. Congenital cardiac anomalies and white matter injury. *Trends in Neurosciences*, 38(6):353–363, June 2015.
- [89] Paul W Buehler, Felice D’Agnillo, Victoria Hoffman, and Abdu I Alayash. Effects of endogenous ascorbate on oxidation, oxygenation, and toxicokinetics of cell-free modified hemoglobin after exchange transfusion in rat and guinea pig. *Journal of Pharmacology and Experimental Therapeutics*, 323(1):49–60, October 2007.
- [90] Felix Brehmer, Ivo Bendix, Sebastian Prager, Yohan van de Looij, Barbara S Reinboth, Julia Zimmermanns, Gerald W Schlager, Daniela Brait, Marco Sifringer, Stefanie Endesfelder, Stéphane Sizonenko, Carina Mallard, Christoph Bühner, Ursula Felderhoff-

- Mueser, and Bettina Gerstner. Interaction of inflammation and hyperoxia in a rat model of neonatal white matter damage. *PLoS ONE*, 7(11):e49023, 2012.
- [91] Yutaka Fujii, Mikiyasu Shirai, Hirotugu Tsuchimochi, James T Pearson, Yoshiaki Takewa, Eisuke Tatsumi, and Yoshiyuki Taenaka. Hyperoxic condition promotes an inflammatory response during cardiopulmonary bypass in a rat model. *Artificial Organs*, 37(12):1034–1040, December 2013.
- [92] Henrik E Poulsen, Allan Weimann, Trine Henriksen, Laura Kofoed Kjær, Emil List Larsen, Elin Rebecka Carlsson, Cramer K Christensen, Ivan Brandslund, and Mogens Fenger. Oxidatively generated modifications to nucleic acids in vivo: Measurement in urine and plasma. *Free Radical Biology and Medicine*, 145:336–341, December 2019.







**FACULTY OF  
MEDICINE**

Department of Clinical Sciences, Lund

Lund University, Faculty of Medicine  
Doctoral Dissertation Series 2020:131  
ISBN 978-91-7619-994-7  
ISSN 1652-8220

