



LUND UNIVERSITY

A new non-invasive ultrasonic method for simultaneous measurements of longitudinal and radial arterial wall movements: first in vivo trial.

Persson, Magnus; Rydén Ahlgren, Åsa; Jansson, Tomas; Eriksson, Anders; Persson, Hans W; Lindström, Kjell

Published in:
Clinical Physiology and Functional Imaging

DOI:
[10.1046/j.1475-097X.2003.00504.x](https://doi.org/10.1046/j.1475-097X.2003.00504.x)

2003

[Link to publication](#)

Citation for published version (APA):

Persson, M., Rydén Ahlgren, Å., Jansson, T., Eriksson, A., Persson, H. W., & Lindström, K. (2003). A new non-invasive ultrasonic method for simultaneous measurements of longitudinal and radial arterial wall movements: first in vivo trial. *Clinical Physiology and Functional Imaging*, 23(5), 247-251. <https://doi.org/10.1046/j.1475-097X.2003.00504.x>

Total number of authors:
6

General rights

Unless other specific re-use rights are stated the following general rights apply:
Copyright and moral rights for the publications made accessible in the public portal are retained by the authors and/or other copyright owners and it is a condition of accessing publications that users recognise and abide by the legal requirements associated with these rights.

- Users may download and print one copy of any publication from the public portal for the purpose of private study or research.
- You may not further distribute the material or use it for any profit-making activity or commercial gain
- You may freely distribute the URL identifying the publication in the public portal

Read more about Creative commons licenses: <https://creativecommons.org/licenses/>

Take down policy

If you believe that this document breaches copyright please contact us providing details, and we will remove access to the work immediately and investigate your claim.

LUND UNIVERSITY

PO Box 117
221 00 Lund
+46 46-222 00 00

A new non-invasive ultrasonic method for simultaneous measurements of longitudinal and radial arterial wall movements: first *in vivo* trial

Magnus Persson¹, Åsa Rydén Ahlgren², Tomas Jansson¹, Anders Eriksson¹, Hans W. Persson¹ and Kjell Lindström¹

¹Department of Electrical Measurements, Lund University, Lund, Sweden, and ²Department of Clinical Physiology, Lund University, Malmö University Hospital, Malmö, Sweden

Summary

Correspondence

Magnus Persson, Department of Electrical Measurements, Box 118, Lund University, SE-221 00 Lund, Sweden
E-mail: magnus.persson@elmat.lth.se

Accepted for publication

Received 25 April 2003;
accepted 24 June 2003

Key words

arterial longitudinal movement; arteries; mechanical properties; shear stress; ultrasound; vessel wall

During recent years, the radial movement of the arterial wall has been extensively studied, and measurements of the radial movement are now an important tool in cardiovascular research for characterizing the mechanical properties of the arterial wall. In contrast, the longitudinal movement of vessels has gained little or no attention as it has been presumed that this movement is negligible. With modern high-resolution ultrasound, it can, however, be seen that the intima-media complex of the arterial wall moves not only in the radial direction, but also in the longitudinal direction during pulse-wave propagation. This paper describes a new non-invasive ultrasonic method that is able to measure simultaneously two dimensionally arterial vessel wall movements. The method is demonstrated in a limited *in vivo* trial. Results from the *in vivo* trial show that, apart from the well-known radial movement, there is a distinct longitudinal movement in the human common carotid artery with, in this case, the intima-media complex moving substantially as compared with the region of the tunica adventitia. Two-dimensional evaluation of the vessel-wall movements, taking not only the radial movement, but also the longitudinal movement into account, may provide novel information of importance in the evaluation of vessel-wall function.

Introduction

Cardiovascular diseases constitute the major cause of morbidity and mortality in the Western World. To increase our knowledge of cardiovascular diseases, it is important to find methods, preferably non-invasive ones, to study very early manifestations of vascular disease. Changes in the mechanical properties of the arteries can be an early manifestation of vascular disease (Nichols & O'Rourke, 1998a). Moreover, changes in the mechanical properties of arteries can have important haemodynamic consequences, and these changes are being increasingly recognized as important factors in cardiovascular morbidity and mortality (Nichols & O'Rourke, 1998b). During recent years, the radial movement of arteries (the diameter change) has been extensively studied, and this is now widely used in characterization of vessel-wall mechanics by measuring pulse-wave velocity (Lehmann, 1996; Eriksson *et al.*, 2002) and distension (Hoeks *et al.*, 1985; Lindström *et al.*, 1987). Thus, measurements of the radial movement of arteries are now an established tool in cardiovascular research, forming the basis for estimation of vessel-wall elasticity.

The longitudinal movement of vessels, *i.e.* the movement along the vessel, has gained little or no attention, because

previously it was assumed that the longitudinal movement of the arterial vessels during passage of the pulse wave was negligible (Nichols & O'Rourke, 1998c). Lawton & Greene (1956) made measurements of the longitudinal movement of the abdominal aorta by using cinematographic observations of beads sutured to the surface of the vessel. The measured longitudinal movement was very small. The results were later confirmed by Patel *et al.* (1961) on the thoracic aorta. The small movements present were considered to be mainly the result of respiratory movements of the diaphragm. All of these studies were performed on the outer part of the arterial wall. However, recently our group (Persson *et al.* 2002) reported that with modern ultrasound scanners it can be observed that the inner layers of the arterial vessels, the intima-media complex, move not only in the radial direction, but also in the longitudinal direction during pulse-wave propagation (Fig. 1). This observation had recently been observed visually in both the common carotid and the brachial arteries. Two-dimensional evaluation of the vessel-wall movements – taking not only the radial movement, but also the longitudinal movement into account – might improve the chances of detecting early abnormalities in vessel-wall function. Further, increased knowledge of the

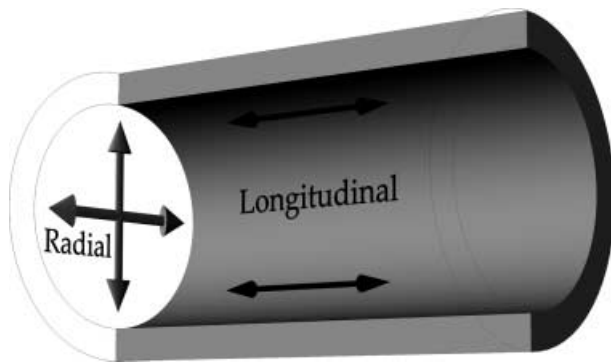


Figure 1 A schematic figure of a vessel showing the definition of the longitudinal and the radial movements. The vessel was scanned in the longitudinal direction and oriented horizontally in the image. During a scan, the movements longitudinally and one dimension in the radial direction were measured.

longitudinal movement itself might provide valuable new and important information in the study and evaluation of vessel-wall function.

This paper describes a new ultrasonic method that makes possible simultaneous measurement of longitudinal and radial movements in different positions of the arterial wall non-invasively *in vivo*. Results from the first *in vivo* trial on the right common artery are reported.

Methods

Measurements

The longitudinal and radial movements were measured over a limited segment of the arterial wall using B-mode ultrasound. The movement between consecutive frames was estimated from the grey-scale information by a two-dimensional block-matching technique (Hein & O'Brien, 1993). The longitudinal

movement is measured in the lateral direction, and the radial movement is measured in the axial direction of the ultrasound image.

The ultrasound information was provided by a HDI[®]-5000 ultrasonic system (Philips Medical Systems, ATL Ultrasound, Bothell, WA, USA). The system was equipped with a 50-mm 5–12 MHz linear array transducer, L12-5, and run in the *Peripheral Vascular/Arterial* application. To achieve the best possible spatial and temporal quantification, the area of interest was zoomed and the persistence function was off. These settings allowed a frame rate of 55 Hz and a spatial quantification of 75 μm in each direction. The data was stored in a cine-loop as consecutive frames. The acquisition memory of the ultrasound scanner allowed up to 5.5 s of data to be collected and transferred to a PC for postprocessing. The cine-loops containing prescan-converted data were visualized on the PC in HDILab (Philips Medical Systems), a software designed for off-line cine-loop analysis. The images were then exported to Matlab[®] (The MathWorks Inc., Natick, MA, USA), where all the image processing was performed.

Image processing

A region-of-interest (ROI), $f(x,y)$, containing a well-defined point of the vessel wall was chosen in frame n (Fig. 2). The size of the ROI was approximately 0.7 × 0.7 mm. The spatial quantification in the ROI was set by the pixel size. To obtain a better movement estimate, the ROI was interpolated by a factor of 10, resulting in a spatial quantification of 7.5 μm in each direction. A kernel, $g(x,y)$, of the ROI was selected automatically in the middle of the ROI. The size of the kernel was seven times smaller than the ROI, which resulted in a kernel size of approximately 0.1 × 0.1 mm. The kernel was two-dimensionally cross-correlated with the larger ROI in frame n ,

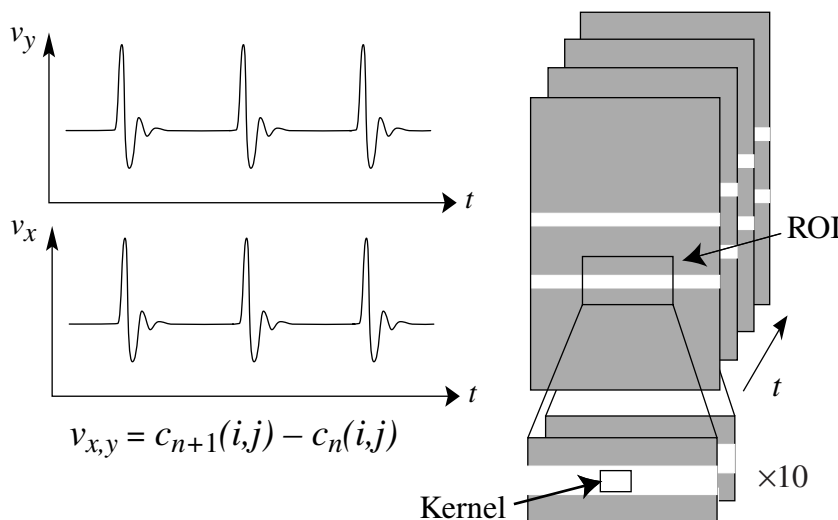


Figure 2 The movement between two successive frames, $v_{x,y}$, in the axial and the lateral direction, respectively, was estimated through the difference between the two-dimensional cross-correlations of the kernel in the first frame and the ROIs in the first and the second frame. Next, the ROI was translated the same distance as the estimated movement, and then repeated in the next frame with the ROI in the new position. To obtain a better movement estimate, the ROI was interpolated by a factor of 10 before the cross-correlation.

$$c(i, j) = \sum_{i=1}^{N_x} \sum_{j=1}^{N_y} f(x, y)g((x - i), (y - j)),$$

to obtain a reference value and thereafter with the corresponding interpolated region in the succeeding frame $n + 1$. The difference between the two two-dimensional correlations, $c_n(i, j)$ and $c_{n+1}(i, j)$, measured the movement per frame, $v_{x,y}$ (pixel/frame), between the two successive frames in the lateral and the axial direction, respectively. The ROI was then translated the same distance as the estimated movement, after which the algorithm was repeated using frames $n + 1$ and $n + 2$ with the ROI in the new position.

The movements trace in the lateral, t_l , and axial, t_c , directions was obtained by cumulative summation of the estimated motion $v_{x,y}(t)$.

In vivo trial

The first in vivo trials were performed on the common carotid artery. The investigated subject was a 45-year-old healthy, normotensive, non-smoking female with no history of cardiovascular disease. The recordings were carried out with the subject in the supine position. The right common carotid artery was scanned in the longitudinal direction, and the vessel was oriented horizontally in the image. Measurements were performed approximately 3 cm proximal to the bifurcation. Care was taken to minimize the pressure of the transducer. Regions of interest were placed at the intima-media complex of both the anterior and the posterior arterial wall, and at the adventitia of the posterior wall (Fig. 3). The ROI at the adventitia was

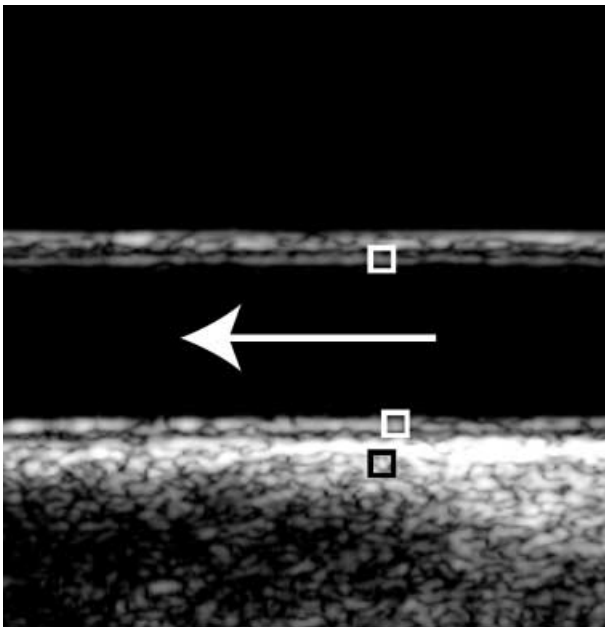


Figure 3 A scan of the common carotid artery. The boxes schematically indicate the positions of the region-of-interest (ROI) at the intima-media complex at the anterior and the posterior wall (white) and in the adventitial region at the posterior wall (black) during the measurements. The direction of the blood flow is indicated by the arrow.

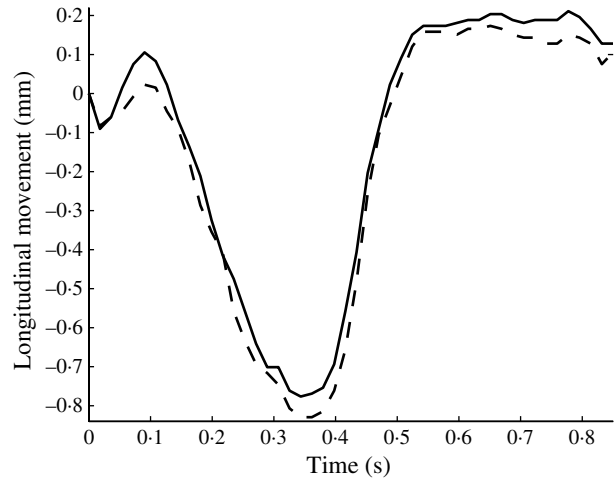


Figure 4 The longitudinal movement of the intima-media complex in the posterior wall (—) and the anterior wall (- - -) of the common carotid artery 3 cm proximal to the bifurcation during a cardiac cycle in a healthy 45-year-old female. A positive longitudinal movement corresponds to movement in the same direction as the blood flow.

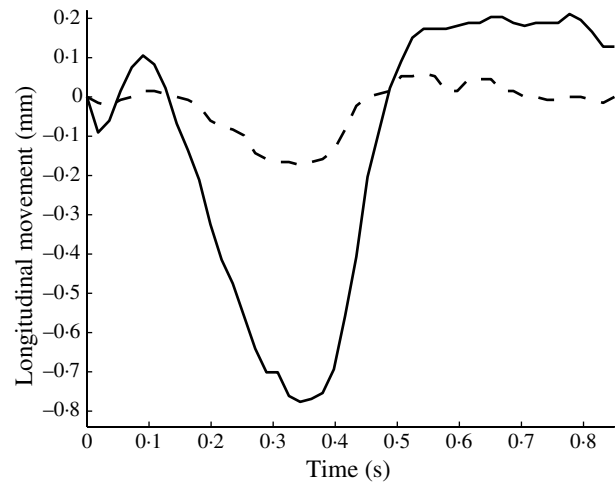


Figure 5 The longitudinal movement in the intima-media complex (—) and in the region of the adventitia (- - -) of the posterior wall of the common carotid artery 3 cm proximal to the bifurcation during a cardiac cycle in a healthy 45-year-old female. A positive longitudinal movement corresponds to movement in the same direction as the blood flow.

positioned 1.3 mm deeper into the vessel wall than the ROI at the intima-media complex of the posterior wall.

Results

The limited in vivo trial shows wall movements, both longitudinally and radially in the common carotid artery. The longitudinal movement of the intima-media complex was approximately 0.9 mm in both the anterior and the posterior wall (Fig. 4). The longitudinal movement of the region of the tunica adventitia of the posterior wall was approximately 0.1 mm (Fig. 5). In Fig. 6 the movement loops of the

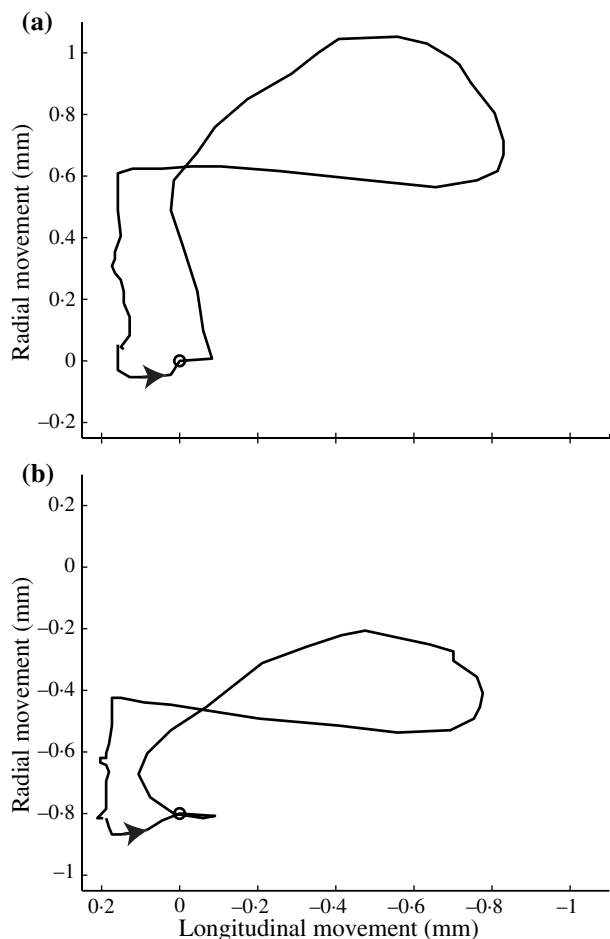


Figure 6 The movement loop for the intima-media complex in (a) the anterior wall and (b) the posterior wall in the common carotid artery 3 cm proximal to the bifurcation. The rings mark the position of end-diastole. The arrows indicate the direction of the movement. A positive longitudinal movement corresponds to movements in the same direction as the blood flow. A positive radial movement corresponds to expected movements of the distension of the artery.

intima-media complex of common carotid artery for the respective wall are shown, and the radial movements are approximately 1 and 0.55 mm in the anterior and the posterior wall, respectively. The well-known distension, the diameter change during the cardiac cycle, is approximately 0.45 mm (Fig. 7). All measurements were performed approximately 3 cm proximal to the bifurcation.

Discussion

Traditionally, the longitudinal movement of the arteries during the passage of the pulse wave it is considered to be negligible in comparison with the well-known radial movement (the diameter change). Our group (Persson *et al.*, 2002) recently reported that, apart from the well-known radial movement, a definite longitudinal movement of the arterial wall can be observed visually in the common carotid artery, as well as in the

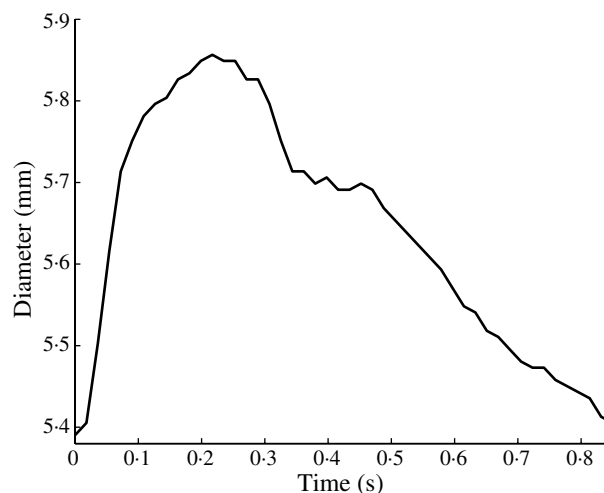


Figure 7 The change in diameter of the common carotid artery 3 cm proximal to the bifurcation during a cardiac cycle.

brachial artery, with especially the intima-media complex moving. The present paper describes a new non-invasive ultrasonic method for simultaneous measurement of longitudinal and radial vessel-wall movements, and reports the first *in vivo* trial using the method. We found that the investigated human common carotid artery has a distinct longitudinal movement of the intima-media complex of the same magnitude as the radial movement, i.e. there was a considerably larger longitudinal movement than had been presumed earlier. The longitudinal movement was of the same magnitude in both the anterior and the posterior vessel wall (Fig. 4). The method also permits the measurement of longitudinal movement in different regions, i.e. at different depths, of the vessel wall, and we found that the intima-media complex moves much more than the adventitia (Fig. 5), i.e. a shear stress within the arterial wall is present. Our finding that the intima-media complex is moving longitudinally, as well as radially, seems reasonable, because the pulse wave and the blood flow exert force on the vessel wall during the pulse-wave propagation not only in the radial direction, but also as a shear force in the longitudinal direction of the blood flow and the pulse wave.

The arterial wall consists of three concentric zones or regions: the tunica intima (the innermost layer), tunica media and tunica adventitia (the outer wall). The tunica intima consists of the vascular endothelium, which is a single layer of cells resting on a thin layer of connective tissue. The tunica media forms the largest part of the arterial wall, and is the principal determinant of the mechanical properties of the vessel (Nichols & O'Rourke, 1998c). The tunica adventitia is a region of collagen and some elastin tissue that merges with the surrounding connective tissue.

Wall-shear stress is the drag exerted by the pulse wave and flowing blood on the vessel wall. It has been shown in a variety of studies that shear stress is an important determinant of endothelial cell function, among others, influencing the production of vasoactive substances such as nitric oxide (NO)

(Rubanyi et al., 1990), prostacycline (Frangos et al., 1985), and endothelium (Malek & Izumo, 1992). Increased knowledge of the longitudinal movement in the arterial wall may provide new information not only on the mechanical properties of arteries, but might also provide new information on the mechanical forces, their type and pattern, acting on the vessel wall – information that can be of great relevance in the study and the evaluation of endothelial function.

To be able to estimate the movements *in vivo*, it is important that the scan is very carefully conducted, as the movements of the vessel wall seem to be <1 mm. The prerequisites for a scan are high frame rate, with no persistence between consecutive images, to achieve acceptable temporal resolution. Further, the vessel walls should be at a right angle to the scan head so that the longitudinal and the radial movements can be easily separated. It is essential that the intima-media complex is clearly visible to be able to perform the measurements, and, if possible, to use a well-defined point visible throughout the cine-loop.

To avoid introducing false movements, it is very important to hold the scan head completely still. We found this difficult, and scan head movements were often present in the recordings. Consequently, it was hard to obtain consecutive cardiac cycles to analyse. Only one cardiac cycle is therefore presented to demonstrate the method *in vivo*. However, there were several individual cardiac cycles that had essentially the same movement pattern and the same magnitude of the movement. Future *in vivo* measurements will be improved by using a mechanical transducer holder to minimize the movements of the transducer relative to the patient.

In the investigated healthy middle-age female, the longitudinal movement of the intima-media complex of the common carotid artery was of approximately the same magnitude as the radial movement, i.e. considerably larger than what had earlier been presumed. For the posterior wall, the longitudinal movement was even larger than the radial wall movement. In the examined common carotid artery, the whole vessel was moving parallel during a cardiac cycle causing the radial movement, for the two walls, to move in the same direction (Fig. 6). An interesting finding is that in this case the longitudinal movement moved more opposite to the direction of propagation of the pulse wave than with it, and the opposite movement started before the radial movement was at its maximum.

Further studies are needed to improve our knowledge of the longitudinal vessel-wall movements and their relevance for vessel-wall characterization and vascular haemodynamics.

Conclusion

This paper focuses on the longitudinal movement of arteries, and a new unique non-invasive ultrasonic method for simul-

taneous estimation of the longitudinal and radial movements of arteries *in vivo* is presented. The longitudinal movement of the arterial wall has until now gained little or no attention, but it might be an important additional factor in the study and evaluation of vessel-wall function.

Acknowledgments

This study was supported by a grant from the Swedish Foundation for Strategic Research via Cortech (Swedish Universities in Cooperation for New Cardiovascular Technology), and from The Swedish Research Council for Applied Research.

References

- Eriksson A, Greiff E, Loupas T, Persson M, Pesque P. Arterial pulse wave velocity with tissue Doppler imaging. *Ultrasound Med Biol* (2002); **28**: 571–580.
- Frangos JA, Eskin SG, Mctire LV. Flow effects on prostacyclin production by cultured human endothelial cells. *Science* (1985); **227**: 1477–1479.
- Hein IA, O'Brien WDJ. Current time-domain methods for assessing tissue motion by analysis from reflected ultrasound echoes—a review. *IEEE Trans Ultrason Ferroelect Freq Contr* (1993); **40**: 84–102.
- Hoeks APG, Ruijsen CJ, Hick P, Reneman RS. Transcutaneous detection of relative changes in artery diameter. *Ultrasound Med Biol* (1985); **11**: 51–59.
- Lawton RW, Greene LC. A method for the *in situ* study of aortic elasticity in the dog. Report No. NADC-MA-5603, AMAL, US Naval and Air Development Center (1956).
- Lehmann ED. Pulse wave velocity as a marker of vascular disease. *Lancet* (1996); **348**: 744.
- Lindström K, Gennser G, Sindberg-Eriksen P, Benthin M, Dahl P. An improved echo tracker for studies on pulse waves in fetal aorta. *Fetal Physiol Measurements* (1987): 217–226.
- Malek A, Izumo, S. Physiological shear stress causes downregulation of endothelin-1 mRNA in bovine aortic endothelium. *Am J Physiol* (1992); **32**: C392–C396.
- Nichols WW, O'Rourke MF. Specific disease. In: *McDonald's Blood Flow in Arteries* (1998a), pp. 402–417. Edward Arnold, London.
- Nichols WW, O'Rourke MF. Wave reflections. In: *McDonald's Blood Flow in Arteries* (1998b), pp. 203–222. Edward Arnold, London.
- Nichols WW, O'Rourke MF. Properties of the arterial wall: practice. In: *McDonald's Blood Flow in Arteries* (1998c), pp. 73–97. Edward Arnold, London.
- Patel DJ, Mallos AJ, Fry DL. Aortic mechanics in the living dog. *J Appl Physiol* (1961); **16**: 293–299.
- Persson M, Rydén Ahlgren Å, Eriksson A, Jansson T, Persson HW, Lindström K. Non-invasive measurement of arterial longitudinal movement. *IEEE Ultrasonics Symposium Proceedings* (2002), 1739–1742. IEEE, New York, NY.
- Rubanyi GM, Freay AD, Kauser K, Johns A, Harder DR. Mechanoreception by the endothelium: mediators and mechanisms of pressure- and flow-induced vascular responses. *Blood Vessels* (1990); **27**: 246–257.