



LUND UNIVERSITY

Depletion of enteric gonadotropin-releasing hormone is found in a few patients suffering from severe gastrointestinal dysmotility.

Hammar, Oskar; Ohlsson, Bodil; Veress, Bela; Alm, Ragnar; Nordin Fredrikson, Gunilla; Montgomery, Agneta

Published in:
Scandinavian Journal of Gastroenterology

DOI:
[10.3109/00365521.2012.706826](https://doi.org/10.3109/00365521.2012.706826)

2012

[Link to publication](#)

Citation for published version (APA):

Hammar, O., Ohlsson, B., Veress, B., Alm, R., Nordin Fredrikson, G., & Montgomery, A. (2012). Depletion of enteric gonadotropin-releasing hormone is found in a few patients suffering from severe gastrointestinal dysmotility. *Scandinavian Journal of Gastroenterology*, 47(10), 1165-1173.
<https://doi.org/10.3109/00365521.2012.706826>

Total number of authors:
6

General rights

Unless other specific re-use rights are stated the following general rights apply:
Copyright and moral rights for the publications made accessible in the public portal are retained by the authors and/or other copyright owners and it is a condition of accessing publications that users recognise and abide by the legal requirements associated with these rights.

- Users may download and print one copy of any publication from the public portal for the purpose of private study or research.
- You may not further distribute the material or use it for any profit-making activity or commercial gain
- You may freely distribute the URL identifying the publication in the public portal

Read more about Creative commons licenses: <https://creativecommons.org/licenses/>

Take down policy

If you believe that this document breaches copyright please contact us providing details, and we will remove access to the work immediately and investigate your claim.

LUND UNIVERSITY

PO Box 117
221 00 Lund
+46 46-222 00 00

Depletion of enteric gonadotropin-releasing hormone (GnRH) is found in a few patients suffering from severe gastrointestinal dysmotility

Short title: GnRH and dysmotility

Authors: Oskar Hammar^{1*}, Bodil Ohlsson^{1*}, Béla Veress², Ragnar Alm³, Gunilla Nordin Fredrikson³ and Agneta Montgomery⁴

Department of Clinical Sciences, Section of Gastroenterology and Hepatology¹, Section of Pathology², Experimental Cardiovascular Research Unit³ and Section of Surgery⁴, Skåne University Hospital, Malmö, Lund University, 205 02 Malmö, Sweden.

*= Both are first authors

Correspondence to: Oskar Hammar
Department of Clinical Sciences
Skåne University Hospital, Malmö
Entrance 35,
S-205 02 Malmö, Sweden
Phone: +4640331000 (operator)
Fax: +4640336208
E-mail: oskar.hammar@med.lu.se

Conflicts of Interests: The authors have no competing financial or other interests.

Acknowledgements: This study was sponsored by grants from the Crafoord Foundation, Bengt Ihre Foundation and the Development Foundation of Region Skane. Maria Nilsson and Annika Jönsson are acknowledged for excellent technical support in performing the immunostaining. Klas Sjöberg is acknowledged for providing control sera

Abstract

Objective: Many patients, especially women, suffer from severe gastrointestinal pain and dysmotility for several years without being diagnosed. Depletion of gonadotropin-releasing hormone (GnRH) in the enteric nervous system (ENS) has been described in some patients. The aim of this study was to examine the expression of GnRH in ENS and antibodies against GnRH in serum, in a dysmotility patient cohort of southern Sweden.

Materials and Methods: All consecutive patients (n=35) referred for laparoscopic full-thickness biopsy because of symptoms or signs of severe dysmotility between 1998 and 2009, or patients with a severe dysmotility disorder having had a bowel resection within the time-frame, were considered for inclusion. In 22 cases, representative biopsy material containing ganglia was available, and these patients were included. Medical records were scrutinized. The expression of GnRH was determined by immunohistochemistry in bowel biopsies from these patients and in patients with carcinoma or diverticulosis without ENS histopathology. Antibodies against GnRH in serum were determined by ELISA in patients and controls.

Results: Fourteen patients were diagnosed with enteric dysmotility and 8 with chronic intestinal pseudo-obstruction due to varying etiology. Immunostained biopsies showed expression of GnRH in the ENS. A reduced expression of GnRH-containing neurons was found in 5 patients, as well as antibodies against GnRH in serum. Three of these patients had a history of in vitro fertilization (IVF) using GnRH analogs.

Conclusions: A subgroup of patients with severe dysmotility had a reduced expression of GnRH-containing neurons in the ENS and expressed antibodies against GnRH in serum.

Key words: Chronic intestinal pseudo-obstruction (CIPO); dysmotility; enteric dysmotility (ED); full-thickness biopsy; gonadotropin-releasing hormone (GnRH); in vitro fertilization (IVF)

Introduction

Chronic intestinal pseudo-obstruction (CIPO) is a disorder affecting gastrointestinal motor activity, producing symptoms and signs resembling those of mechanical obstruction (1-3). Enteric dysmotility (ED) encompasses patients with abnormal intestinal motor activity but no signs of obstruction (4). The etiologies of these two disorders are largely unknown, but the disorders are more common in women than in men (5). Clinically, we have had the impression that women suffering from severe dysmotility have a history of gynecological diseases, such as endometriosis, genital infections and that some have had treatment with gonadotropin-releasing hormone (GnRH) analogs.

Gonadotropin-releasing hormone is expressed in neurons of the human enteric nervous system (ENS), and continuous stimulation by the GnRH analog buserelin enhances survival of rat enteric neurons in culture (6, 7). In rats, GnRH receptors have been described on gastrointestinal smooth muscle cells, and a short stimulation in cell culture inhibits cell proliferation (8, 9). Buserelin is used as pretreatment for in vitro fertilization (IVF) and also in treatment of endometriosis and uterine leiomyoma. We have recently reported how a woman acquired antibodies against GnRH after IVF, with ensuing abolition of GnRH in myenteric neurons and clinical development of CIPO (6). Antibodies against GnRH and reduced expression of GnRH and its receptor in the intestinal wall have also been found in a patient suffering from ED, although he had never been treated with GnRH (7). A subgroup of patients with irritable bowel syndrome (IBS) and dysmotility expressed antibodies against GnRH in serum (10). We therefore hypothesized that GnRH may play a role in gastrointestinal motility, and that depletion of this peptide might explain some cases of gastrointestinal dysfunction.

The aim of the present study was to scrutinize consecutive patients with severe dysmotility who underwent full-thickness biopsy for information on co-existing diseases, possible etiologic factors, and to describe the expression of GnRH in the ENS and the

expression of antibodies against GnRH in serum, aiming to investigate whether GnRH depletion is a wide-spread problem in this patient group.

Material and Methods

This study was performed according to the Helsinki declaration and approved by the Ethics Committee of Lund University. All patients gave their informed consent before entering the study.

Subjects

Consecutive patients subjected to laparoscopic full-thickness biopsy at the Departments of Surgery or Gastroenterology, Skåne University Hospital, Malmö, between 1998 and 2009 because of severe gastrointestinal pain and dysmotility were identified retrospectively. Thorough investigation comprising radiological and/or endoscopic investigation to rule out organic disease or mechanical obstruction had been performed. Gastrointestinal investigations were completed with oesophageal manometry, gastric emptying scintigraphy, antroduodenojejunal manometry and/or colonic transit time after exclusion of organic disease (2, 11-13). Appropriate laboratory samples were analyzed. In addition, patients with symptoms of severe dysmotility who underwent intestinal resection within the same time-frame were also identified. These patients were not considered for laparoscopic biopsy since full-thickness intestinal wall tissue was already available for analysis and thereby histopathological classification (14-16). Identified patients represent the majority of cases of suspected CIPO/ED in the most southern parts of Sweden.

Clinical classification

In order to receive a CIPO diagnosis, patients had to fulfill 3 criteria: a medical history compatible with pseudo-obstruction, documented events or chronic signs mimicking mechanical obstruction (bowel dilatation and/or air/fluid levels) and absence of mechanical

obstruction or other organic cause for these symptoms and findings (1-3). The criteria for ED were documented abnormal contractile activity, but no past history of episodes, or current signs, mimicking mechanical obstruction and absence of any medication that could lead to the observed motor abnormalities (2, 4).

Study design

Patients having remaining, representative material, containing sufficient amount of ganglia for GnRH staining, were included in a retrospective manner. Twenty-two patients fulfilled the inclusion criteria. Fourteen biopsies originated from laparoscopic full-thickness specimen and 8 from bowel resection specimen. In total, 19 small bowel specimen and 8 large bowel specimen were available, reflecting material from resections with both small and large bowel specimens present in 5 patients.

Medical records were scrutinized and age, sex, gastrointestinal symptoms, examinations, treatments and concomitant diseases were recorded. Former abdominal and gynecologic surgery was identified. Based upon the information available the patients were classified as CIPO or ED according to clinical criteria (1-5).

Quantitative immunohistochemical analyses for GnRH positive neurons were performed in the paraffin-embedded material. Furthermore, antibodies against GnRH in serum were analyzed by an enzyme-linked immunosorbent assay (ELISA) in all but 5 patients that had moved from the region and no serum was available. The immunohistochemistry and ELISA were performed by independent co-authors not informed on clinical data (BV, GNF, RA).

Full-thickness biopsy of the bowel

Laparoscopy was performed for diagnostic purposes to exclude mechanical obstruction and to obtain a full-thickness biopsy. A previously described laparoscopy-assisted

technique for ileal full-thickness biopsies and preparing the biopsies was used (6, 17). In short, full-thickness slices perpendicular to each other were cut from the specimen and embedded in paraffin for conventional transversal sections. The remaining, larger part of the biopsy was embedded *in toto* for tangential sectioning. Serial sections from all the blocks were stained according to a protocol for CIPO analysis with both classical stainings (haematoxylin & eosin, PAS, PS-diastase, Giemsa, kresylviolet, trichrome) and with immunostaining (6, 17). The specific immunohistochemical stainings were applied for the analysis of neurons (protein gene product 9.5 (PGP 9.5), neurofilaments, synaptophysin, bcl-2, substance P, and α -internexin), glial cells and Schwann cells (S100), T-lymphocytes (CD3), intermediate/microfilaments of the smooth muscle cells (α -actin, γ -actin, desmin, vimentin), and the interstitial cells of Cajal (ICCs; CD117) as well as Cajal cells-related fibrocytes (CD34). The histopathological findings were classified as defined earlier (15). The criteria for the neuro- and myopathies were based upon criteria suggested by the Gastro 2009 International Working Group for Gastrointestinal Neuromuscular Pathology (14).

Apart from the histochemical staining for CIPO analysis, sections were also stained for GnRH. Polyclonal rabbit anti-GnRH antibodies (anti-LH-RH; PROGEN Biotechnik GmbH, Heidelberg, Germany) were applied to sections at 1:75 dilution. The specificity of the binding of the GnRH-antibody was evaluated by addition of the GnRH peptide (Suprefact[®] (buserelin), Sanofi-Aventis, Bromma, Sweden) before applying the antibody to the sections (6, 7).

As controls for GnRH +/- neurons in small bowel, sections from 6 cases of bowel resection due to non-obliterating adenocarcinoma of the jejunum and ileum, and 2 cases of colonic carcinoma were used, median age 69 (range: 53-85) years. Three were women. Regarding large bowel, the control group was 8 cases (5 women) with colon resection due to diverticulosis, median age 74 (range: 60-87) years. All samples were taken

from areas with normal macro- and microscopic appearance 10 cm above the tumor in the small bowel and from diverticulum-free normal parts of the colonic specimen. The sections were stained for GnRH in the same manner as in dysmotility patients.

The number of GnRH +/- neurons per mm length of myenteric ganglia in transversal sections was counted, and the amount of GnRH + neurons was expressed as percentage of the total number of neurons both in dysmotility patients and in patients with non-obliterating carcinoma and diverticulosis who were used as controls. The method of counting was then verified calculating percentage of GnRH + neurons in relation to PGP 9.5-labeled neurons, and the two methods showed high concordance (data not shown).

Measurement of human antibodies against gonadotropin-releasing hormone (GnRH)

Blood samples were collected from patients and serum was separated and kept frozen in -20° C until analyzed. GnRH antibody analysis was carried out by an ELISA method slightly modified from results described in previous studies (6, 7). The wells of micro titer plates were coated with human GnRH (L7134, Sigma, St Louis, MO, USA) in an overnight incubation at 4° C and thereafter the plastic wells were blocked with 0.5% fish gel solution (G7765, Sigma) in PBS containing 0.05% Tween-20 (PBS-T). Serial dilutions of patient serum (1/100, 1/500 and 1/2500 in PBS-T) was added to the plates and incubated for 2 h at room temperature (RT) and overnight at 4° C. After rinsing with PBS-T, deposition of autoantibodies directed to GnRH was detected using biotinylated rabbit anti-human IgM (673211, MP Biomedicals, Solon, OH, USA) or IgG antibodies (ab7159, Abcam, Cambridge, MA, USA) appropriately diluted in PBS-T. After another incubation for 2 h at RT the plates were washed and the bound biotinylated antibodies detected by alkaline phosphatase conjugated streptavidin (405211, Biolegend, San Diego, CA, USA), incubated for 1 h at RT. The color reaction was developed by using phosphatase substrate kit (37620, Pierce, Rockford, Ill, USA) and the absorbance at 405 nm was measured after 2 h of incubation at

RT. Antibody levels are presented as relative units (RU) (absorbance values after subtracted background levels and multiplied with 100). Relative units above 0 were considered positive.

A cohort of 456 healthy blood donors have been analyzed for the expression of GnRH antibodies in serum (10). From this cohort, 2 age- and gender-matched controls were randomly extracted for each patient sample and served as controls.

Statistical methods

All variables were analyzed for normal distribution by Kolmogorov-Smirnov test. As normality was rejected, the Mann Whitney *U*-test was used. Values are expressed as median, interquartile range (IQR). $P < 0.05$ was considered statistical significant.

Results

Patient characteristics

Out of the 22 patients suffering from severe dysmotility, 19 were women. The median age was 44 (range: 18 – 96) years at the time of investigation.

Fourteen patients were diagnosed with ED and 8 patients with CIPO. Of the 22 patients, 10 had concomitant diseases suspected to cause secondary dysmotility, whereas in 12 no such diseases were found, hence idiopathic dysmotility had to be suspected (Table 1). No complications were reported in relation to the laparoscopy-assisted procedures.

A majority of the patients had undergone abdominal and/or gynecological surgery several times. It was difficult to evaluate whether these were performed prior to or as a consequence of dysmotility-related symptoms. Five out of the 19 female patients (26 %) suffered from endometriosis (Table 1). Three of these patients had a history of Chlamydia trachomatis infection and one of Herpes simplex infection. The 3 patients who had received GnRH analogs in combination with IVF, had also received GnRH analogs for endometriosis.

Histopathological findings

Histopathological analysis revealed inflammatory neuropathy as an independent disease or in combinations with myopathy in 11 dysmotility patients and degenerative neuropathy or combined myoneuropathy in the remaining 11 dysmotility patients (Table 1). All diverticulosis- and non-obliterating carcinoma patients were found to have normal histology in the samples.

The median lengths of counted biopsies are presented together with the total number of neurons per mm myenteric plexus (Table 2). The length of the large bowel specimen counted and the number of neurons was different in the large bowel of the dysmotility patients compared to the diverticulosis patients (Table 2).

Expression of enteric gonadotropin-releasing hormone (GnRH) and serum antibodies

GnRH was found in the cytoplasm of approximately 50% of the myenteric neurons, whereas all other cell types of the bowel wall were negative (Table 2, Figure 1). No immunoreactivity was observed in the specificity tests. A group of submucosal neurons were labelled for GnRH, but they were not counted as these neurons are not affected in this cohort of dysmotility patients.

When the dysmotility patients as a group was compared to diverticulosis- or non-obliterating carcinoma patients, there was no significant differences regarding percentage of neurons labeled with GnRH in small or large bowel ($p=0.31$ and $p=0.96$, respectively). However, 5 dysmotility patients demonstrated a markedly lower percentage of labeled neurons as compared to diverticulosis- and non-obliterating carcinoma patients. These 5 could be characterized as outliers, as shown in the dot-plot in Figure 2. Further characteristics regarding these outliers are presented in Table 3. Three out of these 5 patients had a history of treatment with GnRH analogs as part of IVF treatment prior to the onset of gastrointestinal

symptoms, while the other 2 (one male) had no known history of such treatment. The male had a down-regulated expression of the peptides, whereas the females also had a reduced number of myenteric neurons.

When the dysmotility patients as a group was compared to controls, there was no significant differences ($p=0.071$), regarding antibody levels in serum. All patients with a normal expression of GnRH in the bowel wall, either had GnRH IgM antibody levels within the same range as controls (0.0-0.3 RU) ($n=3$), or had no measurable antibody level ($n=10$). In the patients with reduced expression of enteric GnRH ($n=5$), serum was not available from one of the patients. The remaining 4 patients had levels of antibodies above the range of age- and gender-matched controls, where 2 cases were analyzed previously and have been published in ref No 6 and 7. In these patients, antibody levels were 400 μg compared to 0 μg (6), and 1.030 compared to reference value < 0.800 for controls (7). In the presently analyzed patients the antibody titer was 4.4 RU and 0.6 RU, respectively, as opposed to age- and gender-matched controls where all titers were found within the range 0.0-0.3 RU as stated above. None of the patients expressed any GnRH IgG antibodies in serum.

Discussion

The main finding in the present study was that GnRH is present in about 50% of human myenteric neurons, and in 5 out of 22 examined patients with dysmotility (23 %), GnRH expression was reduced in bowel biopsies as compared to patients with carcinoma or diverticulosis. The reduced bowel peptide content was accompanied by expression of antibodies against GnRH in serum. Previous treatment with a GnRH analog was identified in 3 of the study patients, constituting 16% of the female study population, underlining our previous finding in one patient regarding a possible relation between GnRH treatment and dysmotility (6). All of the examined patients had a pathological full-thickness biopsy.

Gonadotropin-releasing hormone is released from hypothalamus and stimulates the GnRH receptors on the hypophysis in a pulsative manner, with ensuing secretion of gonadotropines (18). Continuous stimulation leads to down-regulation of the receptor with ensuing chemical castration, whereas intermittent stimulation leads to upregulation of the receptor (19). Chemical castration is used in the treatment of sex-dependent tumors, endometriosis, polycystic ovarian syndrome and precocious puberty. No GnRH is secreted from the hypothalamus to the peripheral circulation, why the endogenous effect of GnRH on non-pituitary tissue depends on autocrine/paracrine effects. The effect evoked by GnRH on the cell depends on which mitogen-activated protein kinases (MAPKs) that are activated in the individual cell (19). In rats, GnRH and GnRH receptor mRNA and/or peptide has been found in ganglion cells of the myenteric plexus (8), on gastric smooth muscle cells (9) and on parietal cells in the epithelium (20). The role of GnRH in the gut is not completely elucidated, but GnRH analogs have been shown to inhibit gastric secretion and gastrin release in rat and dog (21, 22), to inhibit cell proliferation in gastric epithelium (23), to protect enteric rat neurons in culture when continuously stimulated (7), whereas shorter stimulation inhibits cell proliferation in gastric smooth muscle cells (9), and to induce apoptosis and inhibited cell proliferation in several cancer cells (24).

The analog leuprolide has been reported to restore motor function in the gastrointestinal tract in female ovariectomized rats and in a woman suffering from CIPO (25, 26), and has been shown to improve symptoms in women suffering from functional bowel diseases (27, 28). The hypothesis is that the continuous stimulation by leuprolide on the hypothalamic-pituitary-gonadal axis down-modulates gonadotropines and gonadal products (18, 29), which are known neural antagonists of gastrointestinal motility (30, 31). Thus, the improvement of gastrointestinal symptoms by leuprolide could be more dependent on absence of gonadotropines and sex-hormones than by a direct effect on the gastrointestinal tissue *per*

se, which is utilized in tumor prevention (24). Use of different GnRH agonists may have different effects, depending on differences between analogs regarding for instance half-life elimination in plasma and length of intervals between administrations (32, 33). Intermittent treatment in the setting of repeated IVF could theoretically have a direct effect on the myenteric neuron population with induction of apoptosis and cell death, in analogy with the effect on cancer cells (24). The neuron death may then influence gastrointestinal physiology. It remains to be determined to what extent there is a real neuron death, or if the lowered levels of GnRH-containing neurons represent a down-regulation of protein expression.

The importance of antibodies against GnRH in the development of dysmotility is not known (6, 7, 10). Previous studies have shown development of antibodies against GnRH after intermittent buserelin treatment, but not after continuous treatment (33, 34). Antibodies may be involved in neurodegeneration, but did not affect neuron survival in vitro (7). On the contrary, the antibodies may be secondary to exposure of GnRH during a degenerative process started by other factors. Earlier studies have described presence of autoantibodies against the ENS in CIPO, especially when secondary to malignancy (35-38). In some cases, antibodies have been proposed to evoke the enteric neurodegeneration (39). Routine immunostaining with GnRH could be valuable in future CIPO analyses.

We observed an increased prevalence of endometriosis amongst our patients, 26% as compared to 15% in the population (40). An association between endometriosis and neuromuscular disease of the gastrointestinal tract has been described previously (31). This association may depend on secondary damage to the ENS and ICCs (41). In our cohort, the 5 affected by endometriosis displayed different patterns regarding ICCs. Two showed hyperplasia and 2 showed hypoplasia of ICCs, one showed normal number of ICCs. Thus, conclusions regarding endometriosis and possible relations to GnRH depletion in the current material are difficult to make. The high prevalence of endometriosis could be an effect of a

more thorough search for endometriosis in a cohort suffering from severe abdominal pain. Three patients with GnRH depletion also suffered from endometriosis (Table 3), but as one of the patients with reduced GnRH expression was a man, GnRH related dysmotility is not necessarily only secondary to endometriosis *per se*. It should not be forgotten that GnRH analogs are a widely used treatment for endometriosis and the risk of a possible relation between GnRH treatment and dysmotility should also be taken into account.

The strength of this study was the thorough investigation of the material at hand and the in some aspects pioneering results, whereas the major weakness is the retrospective nature of the study which is responsible for some missing data. The relatively small number of patients included, is another weakness reflecting a rare disease.

Conclusions

GnRH is present in the human ENS, possibly in the role of a neuropeptide since it is not found in other cells. In addition, there seems to be a subgroup of patients with severe dysmotility who express antibodies against GnRH and have a reduced expression of GnRH-containing neurons in the ENS. This, however, has to be further evaluated in larger prospective studies; and further efforts will also be needed to try to clarify the role of GnRH in intestinal physiology.

Author Contributions-List: The study was designed by OH, BO, BV and AM. Analysis and interpretation of clinical data was performed by OH, BO and AM. Drafting of the manuscript was performed by OH, BO and AM. Immunohistochemistry was analyzed by BV and ELISA by RA and GNF. BO obtained funding for the study. All authors contributed to the intellectual content of the manuscript and accepted the final version of it.

Grant Support: This study was sponsored by grants from the Crafoord Foundation, Bengt Ihre Foundation and the Development Foundation of Region Skane

Abbreviations: Body mass index (BMI), Chronic intestinal pseudo-obstruction (CIPO), Enteric dysmotility (ED), Enzyme-linked immunosorbent assay (ELISA), Enteric nervous system (ENS), Gonadotropin-releasing hormone (GnRH), Inflammatory bowel disease (IBD), Irritable bowel syndrome (IBS), Interstitial Cells of Cajal (ICCs), In vitro fertilization (IVF), Interquartile range (IQR), Room temperature (RT), Relative units (RU), Standard deviations (SD)

1. De Giorgio R, Sarnelli G, Corinaldesi R, Stanghellini V. Advances in our understanding of the pathology of chronic intestinal pseudo-obstruction. *Gut*. 2004 Nov;53(11):1549-52.
2. Stanghellini V, Camilleri M, Malagelada JR. Chronic idiopathic intestinal pseudo-obstruction: clinical and intestinal manometric findings. *Gut*. 1987 Jan;28(1):5-12.
3. Mann SD, Debinski HS, Kamm MA. Clinical characteristics of chronic idiopathic intestinal pseudo-obstruction in adults. *Gut*. 1997 Nov;41(5):675-81.
4. Wingate D, Hongo M, Kellow J, Lindberg G, Smout A. Disorders of gastrointestinal motility: towards a new classification. *J Gastroenterol Hepatol*. 2002 Feb;17 Suppl:S1-14.
5. Stanghellini V, Cogliandro RF, de Giorgio R, Barbara G, Salvioli B, Corinaldesi R. Chronic intestinal pseudo-obstruction: manifestations, natural history and management. *Neurogastroenterol Motil*. 2007 Jun;19(6):440-52.
6. Ohlsson B, Veress B, Janciauskiene S, Montgomery A, Haglund M, Wallmark A. Chronic intestinal pseudo-obstruction due to busserelin-induced formation of anti-GnRH antibodies. *Gastroenterology*. 2007 Jan;132(1):45-51.
7. Ohlsson B, Ekblad E, Veress B, Montgomery A, Janciauskiene S. Antibodies against gonadotropin-releasing hormone (GnRH) and destruction of enteric neurons in 3 patients suffering from gastrointestinal dysfunction. *BMC Gastroenterol*. 2010;10:48.
8. Huang W, Yao B, Sun L, Pu R, Wang L, Zhang R. Immunohistochemical and in situ hybridization studies of gonadotropin releasing hormone (GnRH) and its receptor in rat digestive tract. *Life Sci*. 2001 Mar 2;68(15):1727-34.
9. Chen L, He HX, Sun XD, Zhao J, Liu LH, Huang WQ, et al. Expression of gonadotropin-releasing hormone receptor and effect of gonadotropin-releasing hormone analogue on proliferation of cultured gastric smooth muscle cells of rats. *World J Gastroenterol*. 2004 Jun 15;10(12):1780-4.
10. Ohlsson B, Sjoberg K, Alm R, Fredrikson GN. Patients with irritable bowel syndrome and dysmotility express antibodies against gonadotropin-releasing hormone in serum. *Neurogastroenterol Motil*. 2011 Jun 30;23(11):1000-1006.
11. Spechler SJ, Castell DO. Classification of oesophageal motility abnormalities. *Gut*. 2001 Jul;49(1):145-51.
12. Hanson M, Lilja B. Gastric emptying in smokers. *Scand J Gastroenterol*. 1987 Nov;22(9):1102-4.
13. Abrahamsson H, Antov S, Bosaeus I. Gastrointestinal and colonic segmental transit time evaluated by a single abdominal x-ray in healthy subjects and constipated patients. *Scand J Gastroenterol Suppl*. 1988;152:72-80.
14. Knowles CH, De Giorgio R, Kapur RP, Bruder E, Farrugia G, Geboes K, et al. The London Classification of gastrointestinal neuromuscular pathology: report on behalf of the Gastro 2009 International Working Group. *Gut*. 2010 Jul;59(7):882-7.
15. Lindberg G, Tornblom H, Iwarzon M, Nyberg B, Martin JE, Veress B. Full-thickness biopsy findings in chronic intestinal pseudo-obstruction and enteric dysmotility. *Gut*. 2009 Aug;58(8):1084-90.
16. Knowles CH, Veress B, Kapur RP, Wedel T, Farrugia G, Vanderwinden JM, et al. Quantitation of cellular components of the enteric nervous system in the normal human gastrointestinal tract--report on behalf of the Gastro 2009 International Working Group. *Neurogastroenterol Motil*. 2011 Feb;23(2):115-24.
17. Tornblom H, Lindberg G, Nyberg B, Veress B. Full-thickness biopsy of the jejunum reveals inflammation and enteric neuropathy in irritable bowel syndrome. *Gastroenterology*. 2002 Dec;123(6):1972-9.

18. Hazum E, Conn PM. Molecular mechanism of gonadotropin releasing hormone (GnRH) action. I. The GnRH receptor. *Endocr Rev.* 1988 Nov;9(4):379-86.
19. Naor Z. Signaling by G-protein-coupled receptor (GPCR): studies on the GnRH receptor. *Front Neuroendocrinol.* 2009 Jan;30(1):10-29.
20. Gama P, Alvares EP. Localization of luteinizing-hormone releasing hormone binding sites in the gastric mucosa of suckling rats. *Anat Rec.* 2001 Sep 1;264(1):43-50.
21. Soldani G, Del Tacca M, Bambini G, Polloni A, Bernardini C, Martinotti E, et al. Effects of gonadotropin-releasing hormone (GnRH) on gastric secretion and gastrin release in the dog. *J Endocrinol Invest.* 1982 Nov-Dec;5(6):393-6.
22. Chen L, Sun XD, Zhao J, Yang AG, Huang WQ. Distribution, cloning and sequencing of GnRH, its receptor, and effects of gastric acid secretion of GnRH analogue in gastric parietal cells of rats. *Life Sci.* 2005 Feb 4;76(12):1351-65.
23. Gama P, Alvares EP. LHRH and somatostatin effects on the cell proliferation of the gastric epithelium of suckling and weaning rats. *Regul Pept.* 1996 Jul 5;63(2-3):73-8.
24. Aguilar-Rojas A, Huerta-Reyes M. Human gonadotropin-releasing hormone receptor-activated cellular functions and signaling pathways in extra-pituitary tissues and cancer cells (Review). *Oncol Rep.* 2009 Nov;22(5):981-90.
25. Khanna R, Browne RM, Heiner AD, Clench MH, Mathias JR. Leuprolide acetate affects intestinal motility in female rats before and after ovariectomy. *Am J Physiol.* 1992 Jan;262(1 Pt 1):G185-90.
26. Mathias JR, Baskin GS, Reeves-Darby VG, Clench MH, Smith LL, Calhoon JH. Chronic intestinal pseudoobstruction in a patient with heart-lung transplant. Therapeutic effect of leuprolide acetate. *Dig Dis Sci.* 1992 Nov;37(11):1761-8.
27. Mathias JR, Clench MH, Reeves-Darby VG, Fox LM, Hsu PH, Roberts PH, et al. Effect of leuprolide acetate in patients with moderate to severe functional bowel disease. Double-blind, placebo-controlled study. *Dig Dis Sci.* 1994 Jun;39(6):1155-62.
28. Palomba S, Orio F, Jr., Manguso F, Russo T, Falbo A, Lombardi G, et al. Leuprolide acetate treatment with and without coadministration of tibolone in premenopausal women with menstrual cycle-related irritable bowel syndrome. *Fertil Steril.* 2005 Apr;83(4):1012-20.
29. Rabin D, McNeil LW. Pituitary and gonadal desensitization after continuous luteinizing hormone-releasing hormone infusion in normal females. *J Clin Endocrinol Metab.* 1980 Oct;51(4):873-6.
30. Wang F, Zheng TZ, Li W, Qu SY, He DY. Action of progesterone on contractile activity of isolated gastric strips in rats. *World J Gastroenterol.* 2003 Apr;9(4):775-8.
31. Mathias JR, Clench MH. Relationship of reproductive hormones and neuromuscular disease of the gastrointestinal tract. *Dig Dis.* 1998 Jan-Feb;16(1):3-13.
32. Sennello LT, Finley RA, Chu SY, Jagst C, Max D, Rollins DE, et al. Single-dose pharmacokinetics of leuprolide in humans following intravenous and subcutaneous administration. *J Pharm Sci.* 1986 Feb;75(2):158-60.
33. Holland FJ, Fishman L, Costigan DC, Luna L, Leeder S. Pharmacokinetic characteristics of the gonadotropin-releasing hormone analog D-Ser(TBU)-6EA-10luteinizing hormone-releasing hormone (buserelin) after subcutaneous and intranasal administration in children with central precocious puberty. *J Clin Endocrinol Metab.* 1986 Nov;63(5):1065-70.
34. Lindner J, McNeil LW, Marney S, Conway M, Rivier J, Vale W, et al. Characterization of human anti-luteinizing hormone-releasing hormone (LRH) antibodies in the serum of a patient with isolated gonadotropin deficiency treated with synthetic LRH. *J Clin Endocrinol Metab.* 1981 Feb;52(2):267-70.
35. Ahmed MN, Carpenter S. Autonomic neuropathy and carcinoma of the lung. *Can Med Assoc J.* 1975 Sep 6;113(5):410-2.

36. Bell CE, Jr., Seetharam S. Expression of endodermally derived and neural crest-derived differentiation antigens by human lung and colon tumors. *Cancer*. 1979 Jul;44(1):13-8.
37. Schuffler MD, Baird HW, Fleming CR, Bell CE, Bouldin TW, Malagelada JR, et al. Intestinal pseudo-obstruction as the presenting manifestation of small-cell carcinoma of the lung. A paraneoplastic neuropathy of the gastrointestinal tract. *Ann Intern Med*. 1983 Feb;98(2):129-34.
38. Graus F, Elkouf KB, Cordon-Cardo C, Posner JB. Sensory neuronopathy and small cell lung cancer. Antineuronal antibody that also reacts with the tumor. *Am J Med*. 1986 Jan;80(1):45-52.
39. De Giorgio R, Bovara M, Barbara G, Canossa M, Sarnelli G, De Ponti F, et al. Anti-HuD-induced neuronal apoptosis underlying paraneoplastic gut dysmotility. *Gastroenterology*. 2003 Jul;125(1):70-9.
40. Stephansson O, Kieler H, Granath F, Falconer H. Endometriosis, assisted reproduction technology, and risk of adverse pregnancy outcome. *Hum Reprod*. 2009 Sep;24(9):2341-7.
41. Remorgida V, Ragni N, Ferrero S, Anserini P, Torelli P, Fulcheri E. The involvement of the interstitial Cajal cells and the enteric nervous system in bowel endometriosis. *Hum Reprod*. 2005 Jan;20(1):264-71.

TABLE 1. Patient characteristics and biopsy location derived from medical records

Patient id	Age	Sex	Diagnosis	Onset	Surgery	Diseases	Etiology	Biopsy	Histopathology
1	96	F	CIPO	Acute	None	DM, AF, IHD	Idiopathic	Ileum	infl neuropathy, deg myopathy
1								Colon	infl neuropathy, deg myopathy
2	84	F	CIPO	Ascending	A & G	HT	Idiopathic	Ileum	infl neuropathy, actin deficiency
3	72	M	CIPO	Acute	A	IHD, UC	UC	Ileum	infl neuropathy
3								Colon	infl neuropathy
4	66	F	ED	Acute	G	0	Idiopathic	Ileum	deg neuropathy
5	65	F	ED	Missing	A & G	0	Idiopathic	Colon	deg neuropathy
6	59	F	CIPO	Ascending	A & G	Ehler-Danlos, X	Idiopathic	Ileum	infl neuropathy
7	58	F	ED	Ascending	A & G	X	Idiopathic	Ileum	deg neuropathy
7								Colon	deg neuropathy
8	54	F	CIPO	Ascending	A & G	EM	GnRH?	Ileum	infl neuropathy
8								Colom	infl neuropathy
9	49	F	ED	Ascending	A & G	EM, CD	GnRH?/CD?	Sigmoid	deg neuropathy
10	45	F	CIPO	Ascending	A & G	EM	GnRH?	Ileum	infl neuropathy
11	44	F	ED	Acute	A & G	0	Idiopathic	Ileum	deg neuropathy
12	44	F	ED	Ascending	A & G	DM	DM	Ileum	deg neuropathy
13	42	F	ED	Ascending	A & G	0	Idiopathic	Ileum	infl neuropathy
13								Colon	infl neuropathy
14	38	F	CIPO	Ascending	A & G	EM, X	GnRH?	Ileum	deg neuropathy, deg myopathy
15	34	F	ED	Ascending	A	0	Idiopathic	Ileum	deg neuropathy
16	32	F	ED	Ascending	None	DM	DM	Ileum	infl neuropathy
17	31	F	ED	Acute	A	Anorexia	Idiopathic	Ileum	deg neuropathy
18	27	F	CIPO	Acute	A	Epilepsia	Idiopathic	Sigmoid	infl neuropathy
19	27	F	ED	Acute	A	Backpain, CD	CD	Ileum	deg neuropathy, actin deficiency
20	26	F	ED	Acute	A & G	EM, CD	CD	Ileum	deg neuropathy, deg myopathy
21	25	M	ED	Acute	None	0	GnRH?	Ileum	infl neuropathy
22	18	M	ED	Acute	A	0	Idiopathic	Ileum	infl neuropathy

Values are presented as absolute number of patients. Age is given as years. A= Prior abdominal surgery, AF= Atrial fibrillation, A & G= Prior abdominal and gynecological surgery, CD= Crohn's disease, CIPO= Chronic intestinal pseudo-obstruction, DM= Diabetes mellitus, ED= Enteric dysmotility, EM= Endometriosis, GnRH= Gonadotropin-releasing hormone deficiency, HT= Hypertension, IHD= Ischemic heart disease, UC= Ulcerative colitis, X= Extrauterine pregnancy. Histopathological classification according to Lindberg et al 2009 (15)

TABLE 2. Histologic description of the bowel biopsies related to GnRH staining

Biopsy	Patients		p-value	Patients		p-value
	Carcinoma	Dysmotility		Diverticulosis	Dysmotility	
Sample	Small bowel (n 8)	Small bowel (n 19)		Large bowel (n 8)	Large bowel (n 8)	
Length	13.50 (10.25– 16.75) (range: 10.00-35.00)	15.00 (11.00– 21.70) (range: 4.80-65.00)	0.633	17.5 (11.00– 19.00) (range: 10.00-23.00)	30.50 (24.13– 40.23) (range: 9.00-60.40)	0.013
Neurons/mm	8.21 (5.72–9.19) (range: 5.34- 15.23)	6.70 (6.00– 10.10) (range: 2.40-21.00)	0.832	8.76 (5.77–9.08) (range: 5.00- 10.71)	5.55 (4.83–7.25) (range: 4.30- 8.50)	0.046
Percentage GnRH+ neurons	61.65 (56.75- 67.14) (range: 53.54-71.66)	60.00 (51.00- 63.00) (range: 3.00-82.00)	0.313	60.56 (56.94- 65.52) (range: 55.15-68.68)	60.50 (33.00- 69.50) (range: 23.00-72.00)	0.958

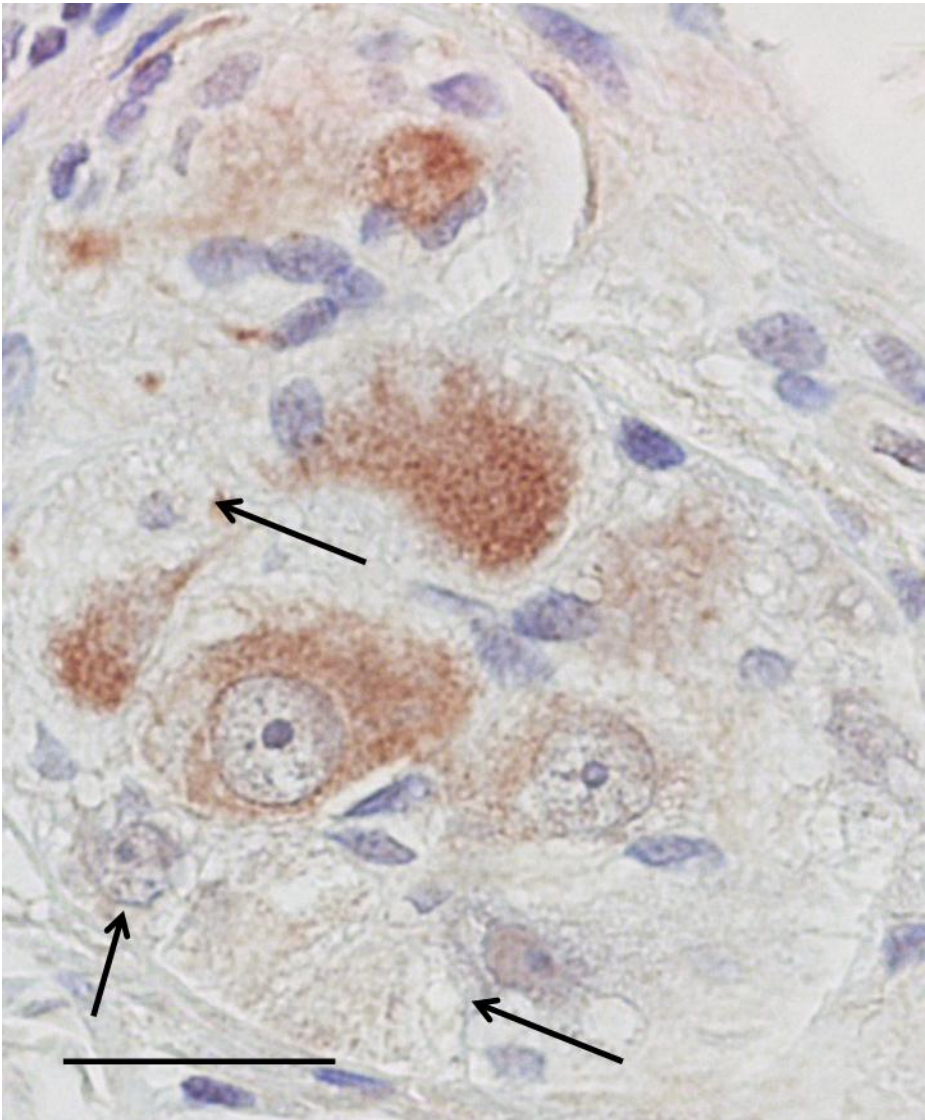
Values are given as median (interquartile range) and range. GnRH=Gonadotropin-releasing hormone. Mann Whitney U test was used. P<0.05 was considered statistical significant.

TABLE 3. Characteristics in dysmotility patients with GnRH depletion

Gender	Pat id	Age	Classification	Antibodies	GnRH Ileum (54%- 72%)	GnRH Colon (55%- 69%)	Endo- metriosis	Prior IVF	Prior GnRH Treatment	Prior surgery	Histopathologic diagnosis
Woman	8	54	CIPO	Missing	28%	23%	no	no	no	yes	infl neuropathy
Woman	9	49	ED	+	Missing	25%	yes	yes	yes	yes	deg neuropathy
Woman	10	45	CIPO	+	36%	Missing	yes	yes	yes	yes	infl neuropathy
Woman	14	38	CIPO	+	3%	Missing	yes	yes	yes	yes	deg neuropathy, deg myopathy
Man	21	25	ED	+	28%	Missing	man	no	no	no	infl neuropathy

CIPO=Chronic intestinal pseudo-obstruction, ED=Enteric dysmotility, GnRH=Gonadotropin-releasing hormone, IVF=In vitro fertilization. (n%)=range of the values from the control patients. Missing values mean that appropriate tissue was unavailable.

FIGURE 1



Control myenteric ganglion containing several GnRH immunoreactive neurons (brown colour). Arrows show GnRH-negative neurons. Note that all other cells are negative (GnRH immunohistochemistry; bar: 20 μ m).

FIGURE 2A

Percentage of GnRH labeled neurons in 27 small bowel samples (8 non-obliterating carcinoma patients, 19 dysmotility patients). Patient id, corresponding to Table 1, is within the circle to identify patients. Squares represent carcinoma patients.

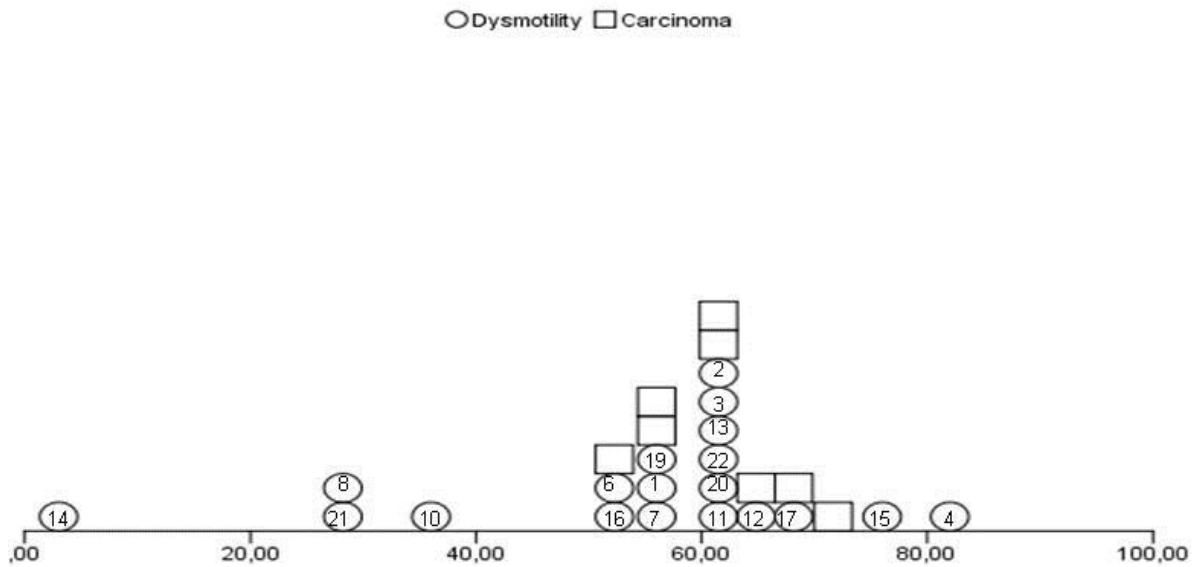


FIGURE 2B

Percentage of GnRH labeled neurons in 16 large bowel samples (8 diverticulosis patients, 8 dysmotility patients). Patient id, corresponding to Table 1, is within the circle to identify patients. Squares represent diverticulosis patients.

