



LUND UNIVERSITY

Interstitial laser thermotherapy (ILT) of breast cancer - Methodology and immunological response

Huld-Haraldsdottir, Kristin

2013

[Link to publication](#)

Citation for published version (APA):

Huld-Haraldsdottir, K. (2013). *Interstitial laser thermotherapy (ILT) of breast cancer - Methodology and immunological response*. [Doctoral Thesis (compilation), Surgery (Lund)]. Surgery, Lund University.

Total number of authors:

1

General rights

Unless other specific re-use rights are stated the following general rights apply:

Copyright and moral rights for the publications made accessible in the public portal are retained by the authors and/or other copyright owners and it is a condition of accessing publications that users recognise and abide by the legal requirements associated with these rights.

- Users may download and print one copy of any publication from the public portal for the purpose of private study or research.
- You may not further distribute the material or use it for any profit-making activity or commercial gain
- You may freely distribute the URL identifying the publication in the public portal

Read more about Creative commons licenses: <https://creativecommons.org/licenses/>

Take down policy

If you believe that this document breaches copyright please contact us providing details, and we will remove access to the work immediately and investigate your claim.

LUND UNIVERSITY

PO Box 117
221 00 Lund
+46 46-222 00 00

Interstitial laser thermotherapy (ILT) of breast cancer

- Methodology and immunological response

Akademisk avhandling

i ämnet klinisk medicin med inriktning kirurgi
som med vederbörligt tillstånd av
Medicinska fakulteten vid Lunds Universitet
offentligen försvaras i Föreläsningssal 1,
Centralblocket, Universitetssjukhuset i Lund,
lördagen den 14 september, kl. 09.00

av

Kristín Huld Haraldsdóttir, MD

Handledare
Professor Karl-Göran Tranberg
Bihandledare:
Professor Christian Ingvar

Fakultetsopponent:
Docent Stig Holmberg
Göteborg




LUND
UNIVERSITY

Organization LUND UNIVERSITY Department of Surgery Clinical Sciences Lund Skåne University Hospital SE-22185 Lund, Sweden	Document name DOCTORAL DISSERTATION Date of issue August 8, 2013
Author(s) Kristin Huld Haraldsdóttir, M.D.	Sponsoring organization
Title and subtitle Interstitial laser thermotherapy (ILT) of breast cancer - Methodology and immunological response	
Abstract <p>Interstitial laser thermotherapy (ILT) is an attractive form of local therapy against cancer because of its anti-tumor immune activity. The aim of this work was to evaluate ILT in breast cancer with respect to technique, changes in tissue immunocompetent cells and effect on prognosis. The method is dependent on accurate assessment of the tumor, and another aim was therefore to evaluate if MRI is better than ultrasound (US) for imaging.</p> <p>Twenty-four patients were treated with ILT, followed by surgical resection about two weeks later. Pre-treatment US estimated the average tumor diameter to be 14 (range 5-35) mm. ILT was performed at 48C° for 30 minutes under local anesthesia. Three patients were radically treated with ILT and the average tumor necrosis was 33% (0-100). Microscopic examination of the resected specimen showed that the average tumor diameter was 23 (range 7-55) mm. US underestimation of tumor size contributed to the rather poor local efficacy. ILT-induced changes in tissue immunocompetent cells were assessed by comparing findings in pre-treatment core biopsies and post-treatment pathologic specimens (paired comparisons). Changes in regional lymph nodes were assessed by comparison with a control group undergoing surgery only. ILT induced a significant increase of mature dendritic cells, B lymphocytes and macrophages at the tumor border and of cytotoxic T lymphocytes and macrophages within the tumor. In the lymph nodes there was a significant decrease in T regulatory cells. Most of these changes are considered to have a favorable prognostic value.</p> <p>Follow up after ILT was 116 (91-136) months. No patient had local recurrence of disease. Five patients developed distant metastases, and three of them have died. The number of cytotoxic T cells within the tumor was higher in patients with recurrence than in patients without recurrence. Patients with recurrent disease had a lower number of NK cells in tumor-free lymph nodes than patients without recurrence. Possible clinical benefit of ILT should be examined in a larger and less heterogenous patient population. MRI has been used preoperatively in most patients (68%) with breast cancer in Iceland during 2007-2009, in addition to mammography and US. Invasive tumor was measurable on all imaging methods in 267 patients. The study revealed that MRI and US both under- and overestimated size. Routine MRI was not shown to be a better radiological method than US for estimating tumor size in local ablative therapy.</p>	
Key words Breast cancer; Laser thermotherapy; Minimally invasive treatment; Tumour immunology; Thermal treatment; Tumour size; Magnetic resonance imaging	
Classification system and/or index terms (if any)	
Supplementary bibliographical information	Language English
ISSN and key title 1652-8220	ISBN 978-91-87449-65-9
Recipient's notes	Number of pages 164 Security classification

Distribution by (name and address)

I, the undersigned, being the copyright owner of the abstract of the above-mentioned dissertation, hereby grant to all reference sources permission to publish and disseminate the abstract of the above-mentioned dissertation.

Signature 

Date August 8, 2013

“More one thinks, the more you realize that there is no simple answer”
–Winnie the Pooh

To Hrafnkell Oddi, Líney Erla and Hákon Helgi

Cover page: Infrared light of a laser fiber.

© Kristín Huld Haraldsdóttir, MD, 2013

e-mail: Kristin.Huld-Haraldsdottir@med.lu.se

Supervisor: Professor Karl-Göran Tranberg

Co-supervisor: Professor Christian Ingvar

Department of Surgery, Clinical Sciences Lund

Lund University Hospital, Sweden

Bulletin No. 144 from the Department of Surgery

Clinical Sciences, Lund, Lund University, Sweden

ISSN 1652-8220

ISBN 978-91-87449-65-9

Lund University, Faculty of Medicine Doctoral Dissertation Series 2013:93

Printed by Media-Tryck, Lund, Sweden

TABLE OF CONTENTS

LIST OF ORIGINAL PAPERS	7
ABBREVIATIONS	9
INTRODUCTION	11
GENERAL BACKGROUND	13
BREAST CANCER	13
DIAGNOSTIC METHODS IN BREAST CANCER	16
LOCAL DESTRUCTION OF TUMOURS	18
LOCAL HYPERTHERMIA	25
TUMOUR IMMUNOLOGY.....	26
AIMS OF THE STUDY	31
MATERIAL AND METHODS WITH COMMENTS	33
RESULTS AND DISCUSSION	47
CONCLUSIONS.....	69
FUTURE PERSPECTIVES.....	71
POPULÄRVETENSKAPLIG SAMMANFATTNING	73
ALMENN SAMANTEKT	77
ACKNOWLEDGEMENTS.....	81
REFERENCES	83
ORIGINAL ARTICLES	97

LIST OF ORIGINAL PAPERS

The thesis is based on the following papers, which will be referred to by their Roman numerals I-IV. The papers are appended at the end of the thesis.

- I. Haraldsdóttir KH, Ivarsson K, Götberg S, Ingvar C, Stenram U, Tranberg K-G. Interstitial laser thermotherapy (ILT) of breast cancer. *Eur J Surg Oncol* 2008; 34:739-745.
- II. **Haraldsdóttir KH**, Ivarsson K, Jansner K, Stenram U, Tranberg K-G. Changes in immunocompetent cells after interstitial laser thermotherapy of breast cancer. *Cancer Immunol Immunother* 2011; 60: 847-856.
- III. Haraldsdóttir KH, Ingvar C, Stenram U, Tranberg K-G. Long-term follow up after interstitial laser thermotherapy (ILT) of breast cancer. *Manuscript*
- IV. **Haraldsdóttir KH**, Jónsson Þ, Halldórsdóttir AB, Tranberg K-G, Ásgeirsson KS. Tumour size of invasive breast cancer on MRI and conventional imaging (MGM/US): Comparison to pathological size and clinical implications. *Submitted*

Published papers are reprinted with permission from the respective publishers.

ABBREVIATIONS

APC	Antigen-presenting cell
CD	Cluster of differentiation
CIS	Cancer in situ
CK	Cytokeratin
CT	Computed tomography
CTL	Cytotoxic lymphocyte
DC	Dendritic cells
DCIS	Ductal cancer in situ
EGFR	Epidermal growth factor receptor
ER	Estrogen receptor
FNA	Fine needle aspiration
Her-2	Herceptin-2
HIFU	High intensity focused ultrasound
IDC	Invasive ductal cancer
IL	Interleukin
ILT	Interstitial laser thermotherapy
ILC	Invasive lobular cancer
LCIS	Lobular cancer in situ
MGM	Mammogram
MHCI/II	Major histocompatibility complex I/II
MRI	Magnetic resonance imaging
MWA	Microwave ablation
MDSC	Myeloid derived suppressor cell
Nd:YAG	Neodymium:yttrium aluminium garnet
NK cell	Natural killer cell
PET	Positron emission tomography
PgR	Progesterone receptor
RFA	Radiofrequency ablation
TAM	Tumour associated macrophage
TNBC	Triple negative breast cancer
T _{reg}	T regulatory cell
US	Ultrasound

INTRODUCTION

Breast cancer is the most frequent cancer form in women followed by lung and colorectal cancer. Over 8000 (2012) are diagnosed with breast cancer every year in Sweden (cancerfonden.se) and over 1.3 million women worldwide (Grayson. 2012). With screening small tumours are diagnosed (Tabar *et al.* 1992; Earnst *et al.* 2002) and a lower stage of disease at the time of diagnosis improves the prognosis and survival. The standard treatment is surgery, either by mastectomy or breast conserving surgery, followed by radiotherapy of the remaining breast tissue.

Less invasive therapy for cancer, ablative therapies, such as interstitial laser thermotherapy (ILT), have been used in breast cancer. Most of these methods induce hyperthermia, which causes cell death. Local therapy of this kind can be used in breast cancer and other cancer forms both as curative and palliative treatment.

This thesis is focused on local therapy of breast cancer with ILT.

GENERAL BACKGROUND

BREAST CANCER

Breast cancer is classified according to histology into different types. Pre-invasive forms are lobular cancer in situ (LCIS), ductal cancer in situ (DCIS) and Paget's disease of the nipple. Paget's disease is often combined with other forms of cancer such as invasive ductal cancer (Dalberg *et al.* 2008). Invasive cancers are ductal (IDC), which is the most common form, and lobular cancer (ILC), which account for about 85-90%. Other more rare forms are mixed ductal and lobular cancer, mucinous, tubular, papillary, medullary and phyllodes cancers. In men IDC is the most common form.

The histological classification of tumours is important as well as molecular profiling of tumours, which has a great influence on therapy and prognosis of patients. These factors divide the tumours into four main groups that are Luminal A (ER⁺ and/or PgR⁺, Her-2⁻), Luminal B (ER⁺ and/or PgR⁺, Her-2⁺), Her-2 positive subtype (ER⁻ and PgR⁻, Her-2⁺) and triple-negative cancers (TNBC) (ER⁻, PgR⁻ and Her-2⁻) (Li X *et al.* 2011). TNBC are often referred to as basal like tumours although this is not entirely true (Greenberg & Rugo. 2010). About 80% of TNBC are "basal like" and can be distinguished from non-basal like with factors like CK5/6 and EGFR (Dawood. 2010). TNBC have been shown to have a poor prognosis but many studies indicate that this might be the basaloid differentiation and not only the triple negative phenotype (Dawood. 2010; Pala *et al.* 2012).

Therapy is influenced by molecular profiling and histological grading (I, II and III, Nottingham school) but tumour size and lymph node status of the patient is of great importance. TNM classification is used for staging of breast cancer (Tables 1 and 2) and used for recommendation of further treatment for the patient.

Table 1. *TNM classification of breast cancer.*

Tumour size
Tis Cancer in situ
T1 $\leq 20\text{mm}$
T2 21-50mm
T3 $>50\text{mm}$
T4 Involvement of chest wall, skin or inflammatory cancer
Lymph node status
N0 no lymph node metastases
N1 1-3 lymph nodes positive
N2 4-9 lymph nodes positive
N3 ≥ 10 lymph nodes positive
Metastases
M0 no distal metastases
M1 distal metastases

Table 2. *Stages of breast cancer.*

Stage 0	TisN0M0
Stage I	T1N0M0
Stage II	T2-3N0M0
	T1-2N1M0
Stage III	T3N1M0
	T1-3N2M0
	T4N0-2M0
	T1-4N3M0
Stage IV	T1-4N0M1

The standard treatment of breast cancer is surgery, either breast conservation or mastectomy for larger tumours, multifocal disease or because of patient choice. For disseminated disease palliative chemo- and/or radiotherapy is given.

For lymph nodes, sentinel node biopsy is done if radiology, palpation or biopsy from lymph node does not indicate or confirm lymph node metastases. Otherwise axillary dissection is done (Level I and II, Figure 1). Axillary dissection is also done if sentinel lymph node is positive.

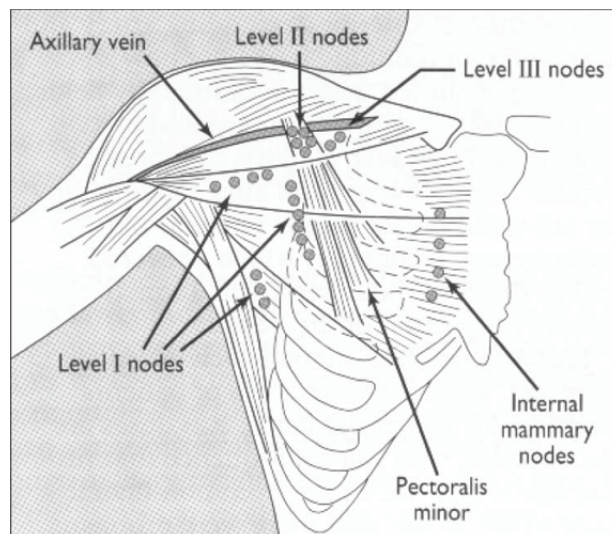


Figure 1. Schematic drawing of the anatomical landmarks used in axillary dissection of lymph nodes (*ABC of breast diseases, CD Rom Slide set, edited by J Michael Dixon*).

According to the tumour evaluation, at the time of diagnosis, the therapy is determined. In advanced cases palliative therapy is warranted but in some cases chemo- and/or radiation therapy is used for down staging of tumours. In most cases surgery is applied and adjuvant therapy is decided at the time of multidisciplinary meeting where TNM status, histology and molecular profile of the tumour is known.

Breast cancer is in general a disease with a relatively good prognosis. This is of course different between stages and the prognosis diminishes with a higher stage of disease at the time of diagnosis. With more attention to molecular profiling of tumours it has been demonstrated that patients with Luminal A tumours have a better prognosis than other subtypes of tumours (Li Z. 2011). Prognosis by stage has been published and is shown in Table 3.

Table 3. 5 year survival according to the American cancer society (www.cancer.org)

Stage	5 years survival (%)
0	93
I	88
IIA	81
IIB	74
IIIa	67
IIIB	41
IIIC	49
IV	15

DIAGNOSTIC METHODS IN BREAST CANCER

Mammography (MGM) is used in screening for breast cancer and as the first radiological method of a palpable nodule in the breast. If the MGM is not normal, gives rise to a suspicion of cancer or is normal with a palpable nodule an ultrasound (US) is done for further characterization. Combination of palpation, MGM and US, with a possibility of fine needle aspiration (FNA) or core biopsy, most often gives the diagnosis or rules out cancer. If not a resection biopsy is done.

Fat appears dark on MGM but epithelium and stroma look light and is referred to mammographic density (Boyd *et al.* 2007). Indirect signs, like

dens areas and micro calcifications can be a sign of cancer in situ or invasive cancer and are considered to day to be an indicator that other radiological method needs to be used for ruling out cancer. Sensitivity and specificity of mammography are affected by breast density, menstrual cycle phase, parity, body mass index and genetic or familial tendency (Carney *et al.* 2003). Women with dense breast tissue have an increased risk of cancer. Interval cancers, that are cancers diagnosed in the period between screening MGM's, are relatively common in women with dense breasts (Boyd *et al.* 2007). Lobular carcinoma and tumours without micro calcifications limit the effectiveness of mammography since they could be missed, especially in the extremely dense breast (Albyrak *et al.* 2011).

US is an important tool in the diagnosis of breast cancer in further characterizing the lesions as well as a tool for biopsies. It is frequently used to image palpable masses in the breast, to distinguish between benign and malignant lesions as well as a follow up test for abnormal results on a MGM. It is the method of choice to examine women not able to undergo mammography such as women at young age and the pregnant ones. Ultrasound with contrast is increasingly used to distinguish between a benign and malignant lesion. Rapid contrast uptake and rapid washout distinguishes benign from malignant lesions and contrast US is considered more precise than non-contrast US when estimating size. Including the halo often found around the tumours makes the estimation of size more accurate (Hieken *et al.* 2001).

MRI has been more frequently used in the diagnosis of breast cancer in the last years. It has been thought to increase the diagnosis of multifocal and multicentric cancers. But a specificity around 55-65% leads to more lesions found with uncertain diagnosis and an increased number of biopsies. Overestimation of size has been reported and that may lead to larger resection and increase in mastectomy rate (Houssami *et al.* 2013). However a decrease in the frequency of reoperation because of a small margin to invasive cancer has not been shown (Weber *et al.* 2012).

MRI has been suggested as a complimentary modality in breast cancer. It has been suggested to be used in patients with high risk of developing breast cancer, in patients with axillary metastasis of unknown primary and negative MGM and US and in dense breast tissue (Hlawatsch *et al.* 2002; Gümüş *et al.* 2012). Its use has also been suggested in ILC and in patients that have received neoadjuvant therapy and are considered for a conservative resection.

Before surgery or other treatment, diagnosis of the lesion is made by FNA or, when that does not give the diagnosis, a core biopsy. FNA can give malignant cells for diagnosis of invasive tumour. Core biopsy more characteristics can be gained as this gives more tissue that can be stained both for regular microscopy and immunohistochemical staining. When all information has been gathered the patient is discussed at a multidisciplinary conference that recommends the therapy to be discussed with the patient.

Other diagnostic methods are used when disseminated disease is suspected, like isotope scanning for bone metastasis, CT scan of thorax and abdomen and a PET scan. These methods are not discussed in any detail in this thesis.

LOCAL DESTRUCTION OF TUMOURS

Pros and cons of local destruction

Local destruction of cancer has been used in treatment for many years, both as palliative and curative treatment. These methods are minimally invasive and can often be done, as in this thesis, percutaneously with local sedation in outpatient settings. Radiology is a limiting factor in local destruction as the methods rely on it for optimal placement of equipment and detection and demarcation of tumours. Also real time monitoring is important so that inadequately treated areas can be dealt with appropriately with re-localization of equipment for radical treatment. The risk of local recurrence

of disease or locally non-radical treatment is a major drawback of local therapy. Real time monitoring is important and different radiological modalities have been used for this purpose, mostly ultrasound. In studies where surgery has been done after local destruction foci of untreated tumour is a fact in some patients (Harries *et al.* 1994; Dowlatshahi *et al.* 2000; Burak *et al.* 2003). Methods like cryotherapy, high intensity focused ultrasound (HIFU) and microwave ablation (MWA) have been used more and more because of the possibility of gaining large necrosis volumes and because the equipment is easily managed. By larger necrosis volumes discrepancies in pretreatment managing is of less importance.

Morbidity and mortality is low after local destructions of tumours in general but after cryotherapy (p. 24) severe adverse effect have been reported as well as death. In our study small skin necrosis was seen as well as tenderness after treatment. This has been seen after other types of treatment as well such as cryotherapy (Sabel *et al.* 2004). If a tumour is situated near the skin, saline can be infiltrated between the tumour and the skin in the purpose of increasing the distance to the skin. This can also be done in breast cancer if the tumour is close to the fascia to increase the distance between tumour and fascia to reduce the risk of pain in this situation. Mortality after local destruction is very low with exception of cryoshock after cryotherapy of large liver tumours. Patients can develop multi organ failure, coagulopathy, disseminated intravascular coagulation and this is combined with high mortality (Chen *et al.* 2011). Device insertion may cause bleeding, pain and tumour seeding with implantation metastasis. (Bonatti *et al.* 2003; Jaskolka *et al.* 2005; Yamauchi *et al.* 2011, Koda *et al.* 2012). In order to prevent seeding, and sometimes bleeding, the puncture channel is treated on the way out that is the device is not turned off until it has been drawn out through the skin.

In breast cancer multifocal disease is relatively common and preoperative assessment is of importance for correct inclusion of patients for this kind of treatment. CIS is difficult to diagnose on radiology although multiple micro calcifications, present in DCIS, can be an indicator. Core biopsies are

important for diagnosis, receptor profile of the patients and for diagnosis of CIS within or around the invasive cancer.

An important factor after local destruction is that an immunological effect, with an increase in immunocompetent cells, has been described after many of these methods. This is addressed in paper II. Because of this immunological effect well described for example in ILT, this method could change the microenvironment of tumours, with repolarization of cells as for example macrophages. Because of this ILT might have advantages beyond other local ablative methods and have a role in neoadjuvant treatment for tumours even if surgery is planned (Tranberg *et al.* 2002; Ivarsson *et al.* 2005).

Many methods are used for local destruction of tumours and are still evolving. If therapy of cancer is possible with local ablation this is much less stressful and less trauma for the patient as well as cosmetic aspects as in for example breast cancer. It is often possible to treat tumours without general anesthesia and as mentioned before morbidity and mortality is low. On the other hand if operation is not done a pathological evaluation is not possible. That means like in breast cancer that core biopsies are warranted before treatment (as in paper I) for receptor status of the tumour and evaluation of resection margins and multifocality, not seen on preoperative radiology, is not possible. It is therefore necessary for the local ablation methods to do evaluations of local recurrence within studies and evaluate methods for such diagnostic.

In this chapter the most frequently used methods in breast cancer are addressed. The placement of the treatment probe within or near the tumour is often done with ultrasound.

Laser-mediated therapies

Laser-mediated therapy is a technique where light generates heat in the tissue treated, which causes cell death and destruction (local hyperthermia p. 25). Laser therapy is usually performed with infrared or near infrared light with wavelengths from about 700 - 2000 nm. That is because infrared

light has relatively good penetration of the tissue and homogeneous spread (Nikfarjam & Christophi. 2003). It scatters less than blue, green and yellow radiation but the property of the tissue is also important. Skin, blood and vessel wall scatters light more than solid tumours (Găzdaru *et al.* 2008) The laser light penetrates a few millimeters into the tissue before all is absorbed. The absorption causes heat that is transported through the tissue with conduction (Tranberg. 2004). Laser light is transported through flexible fibers (Figure 2), where the laser light is mediated to the tip which is either bare (Figure 3) or of diffuser type. Bare tip provides a near spherical lesion and diffuser tip causes larger ablative areas (Gough-Palmer & Gedroyc. 2008). The generator is usually a Neodymium:yttrium aluminium garnet laser (Nd:YAG) or a diode laser, as used in this thesis, with a suitable wavelength.

One bare tip fiber can cause approximately 1 cubic centimeter of cell destruction, so for large tumours several fibers or multiple insertions/placements of fibers are needed (Möller *et al.* 1996). In ILT, laser power and temperature are regulated by a computer feedback system (Figure 7). Temperatures between 46-48°C at the tumour border are used to achieve tumour destruction (Ivarsson *et al.* 1998). If high power is used, time to total destruction will be shorter. High temperatures can cause carbonization of the tissue, which causes "isolation" of the fiber causing vaporization and less conduction to the surrounding tissue (Ivarsson *et al.* 1998).

ILT was first used in palliative settings to reduce tumour load and treatment of local symptoms but is now also used in curative treatments. For example in liver metastases where it is used as a complementary treatment to surgery for tumours in difficult locations within the liver (Tranberg. 2004).

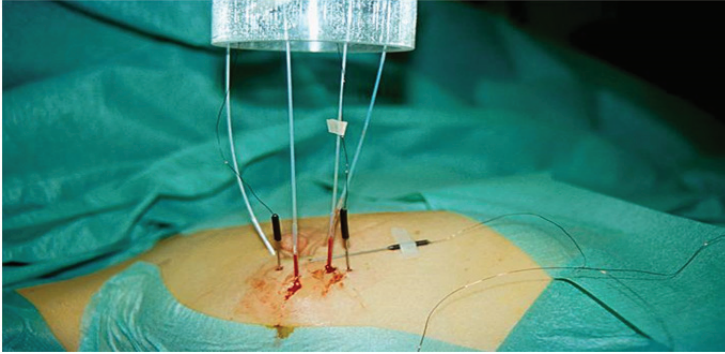


Figure 2. *ILT of breast cancer in the operation theatre. Four laser fibers and two temperature probes used for treatment monitoring.*




Figure 3. *Bare laser fiber used in paper I in outpatient settings. Laser light emitted through the tip of the laser fiber.*

Radiofrequency ablation (RFA)

RFA uses needle electrodes to deliver high frequency, alternating current, which causes friction of molecules that generates heat. RFA uses electromagnetic energy sources with frequencies less than 900 kHz to generate heat and the target temperature is around 95°C (Nikfarjam et al. 2005). Most devices function in the range of 375-500 kHz. Star-like needles (Figure 4) of different sizes can be used, and cause coagulative necrosis of

larger areas, 2-5cm (Huston & Simmons. 2005). The method has mostly been used in liver tumours but other cancer types have also been treated such as breast cancer.

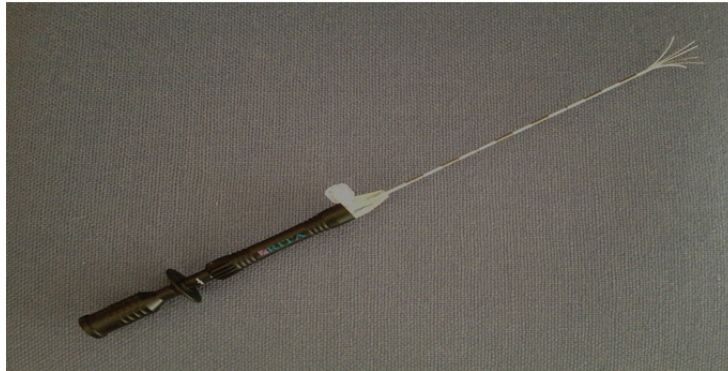


Figure 4. Star like needle used for RFA.

High intensity focused ultrasound (HIFU)

Ultrasound penetrates tissue and causes heat production by movement of waves and friction within the tissue. With high intensity focused ultrasound (HIFU) high temperatures ($>90^{\circ}\text{C}$) are created causing irreversible damage of the tissue (Hall-Craggs & Vaidya. 2002). HIFU is an extracorporeal method using a probe that is applied, usually apart from the skin, above the tumour in water (Wu *et al.* 2003). Boundaries between the treated area and normal tissue are very sharp and no damage is seen in the tissue surrounding the treated area (Huston & Simmons. 2005).

Microwave ablation

Microwave ablation (MWA) is an electromagnetic method that uses frequencies of 900-2450 MHz for ablation of tumours (Vargas *et al.* 2004; Simon *et al.* 2005). This type of radiation lies between infrared radiation and radio waves.

A microwave generator emits an electromagnetic wave that agitates water molecules, producing friction and heat causing cellular death via coagulation necrosis (Simon *et al.* 2005). The ablation temperatures in the tissue are high, ablation time is fast and charring is not produced as in for example RFA (Hompes *et al.* 2010).

On the other hand variability in ablative zone after MWA has been reported, which is a risk factor of local recurrence. Also MWA causes temperature rise outside the tumour called “comet effect” which can cause adverse effect of benign tissue around the tumour (Hompes *et al.* 2010).

Cryotherapy

Cryotherapy has been used in numerous cancer types such as liver, breast, kidney and skin cancer. With this method hypothermia is created for destruction of tumour, performed with freezing and thawing cycles. Hypothermia is produced by liquid nitrogen or argon gas, which destroys cells with ice formation within the cell, which causes osmotic injury, swelling and destruction (Urgas & Simmons. 2010). Argon-based systems, reach operating temperatures as low as -180°C more rapidly (Urgas & Simmons. 2010) whereas liquid-based nitrogen systems, which are more frequently used, create a larger ice ball in a warm environment (Hewitt *et al.* 1997). Active thawing is done in cycles where helium gas is used for warming the tissue (Sabel *et al.* 2004). Factors that influence the efficacy of cryodestruction include the cooling rate, tissue temperature, the freeze-thaw cycle, and the number of repetitions (Finger. 2005). Therapy is monitored in real time. For tumours larger than 1.5 cm multiple cryoprobes should be used (Pfleiderer *et al.* 2005)

LOCAL HYPERTHERMIA

The definition of hyperthermia is a temperature range between 41-42.5°C and over 42.5°C is called thermotherapy. Temperature of 42-60°C, for 30-60 minutes, cause irreversible cell damage, mostly because of inactivation of vital enzymes (Nikfarjam *et al.* 2005). Disruption of cells by thermotherapy is caused by denaturation of proteins, which is both dependent on time and temperature level (Lepock. 2003). About 60% of DNA damage is needed for the killing a mammalian cell, and cells are most vulnerable during mitosis and S-phase (Lepock. 2003). Changes in cell membrane and liquefying of lipids also causes cell death, because of leakage in the cell membrane.

Temperature of 60-100°C causes coagulation within seconds and 100-300°C causes vaporization (Nikfarjam *et al.* 2005).

Consequences of hyperthermia are often classified as direct and indirect. Direct is what happens directly in the cell and microenvironment and indirect changes follow within the next days because of necrosis and changes in the immune microenvironment (Nikfarjam *et al.* 2005). The level of hyperthermia defines the level of damage and lower temperature within the thermotherapy range for a long time causes indirect damage.

Blood flow is important in some local ablation methods, like laser mediated therapies and RFA. Hemoglobin absorbs heat and transfers it from the tumour. This causes "heat sink" effect, which is different in different organs depending on it's vascularization. This explains why it is relatively difficult to treat tumours in the liver, which is highly vascularized. Hyperthermia also causes changes in endothelial cells and increased blood viscosity and thrombosis, which leads to tissue damage due to ischemic necrosis. High doses of energy around the device used to cause hyperthermia require heat conduction through the tissue to cause coagulation of tissue surrounding the device (Goldberg *et al.* 2000). Temperatures greater than 105°C result in tissue boiling, vaporization and carbonization. Vaporization serves as an

isolator and prevents heat spread, as does carbonization, which causes decrease in energy transmission (Goldberg *et al.* 2000).

The goal of local thermotherapy is to destroy tissue by heat. Low temperatures are used to cause proteins to denature, but mostly preserve their structures so that they may become immunogenic.

TUMOUR IMMUNOLOGY

Dendritic cells

Dendritic cells (DCs) are thought to arrive from one common precursor. Newly formed DCs migrate with circulating blood from the bone marrow to non-lymphoid organs where they develop into immature resident cells (Khochenkov. 2008). Under influence of chemokines, DCs penetrate into lymphoid organs and produce cytokines that attract effector lymphocytes (Khochenkov. 2008). CD1a expression is high when cells are capturing antigen and is down regulated when antigen presentation is occurring and cells develop into mature DCs (Moulon *et al.* 1991).

Normal breast tissue is usually not infiltrated with DCs. In breast cancer immature DCs are seen within the tumour and mature DCs, usually only present in lymphoid organs, are seen at the tumour border or peritumoural areas (Bell *et al.* 1999).

The presence of mature DCs has been correlated with prolonged relapse-free and overall survival in breast cancer (Iwamoto *et al.* 2003; Miyagawa *et al.* 2004). Node negative patients have been shown to have more immature DCs within the cancer of the primary lesion compared to node-positive patients (Tsuge *et al.* 2000). The number of DCs has also been studied in other cancer forms as for example colon cancer, where an increased number of DCs correlates with survival (Gulubova *et al.* 2012).

Macrophages

Macrophages are cells that derive from the monocyte. Monocytes develop in the bone marrow and mature into macrophages, when they enter tissue via the blood stream (Abbas & Lichtman. 2003). A macrophage is an immune cell that can phagocytize and present antigens on its cell surface. It is in the front line of pathogen defense, wound healing and maintaining homeostasis within the body.

Macrophages have varied and sometimes incomprehensible properties. In order to ease interpretation of their function, the term “macrophage” has been proposed to cover two main subtypes said to have different "polarization": M1 and M2 polarized macrophages.

The M1 type is a macrophage of acute inflammation and reacts to foreign antigens. It expresses MHC class II and is able to destroy microorganisms and tumour cells, stimulate T-cell proliferation (cytotoxic T-cells and NK-cells) and serve as an antigen-presenting cell (APC; Mantovani *et al.* 2002).

The M2 polarized macrophage suppresses T-cell proliferation and promotes angiogenesis (Lewis & Pollard. 2006; Allavena & Mantovani. 2012). It is important in wound healing and maintaining homeostasis (Allavena & Mantovani. 2012). Tumour cells secrete IL-4, IL-6, IL-10 and other factors that inhibit cytotoxic activity of macrophages by causing polarization towards M2.

These factors also suppress the expression of MHC class II molecules on macrophages, which reduces the ability of macrophages to serve as antigen presenting cells (Lewis & Pollard. 2006). M2 macrophages promote tumour cell invasion by breaking down the basal membrane of tumours, a membrane-like structure surrounding cancer cells, and separating cancer cells from the tumour stroma and normal tissue (Menon *et al.* 2003), thereby helping cancer cells to invade healthy tissue (Condeelis & Pollard. 2006). M2 macrophages are also able to help cancer cells to enter vessels, which can cause metastatic disease (Wyckoff *et al.* 2007).

Tumour associated macrophages (TAMs) are macrophages present in tumours, usually in the tumoural stroma. These macrophages tend to be M2 polarized macrophages and have been associated with poor prognosis (Qualls & Murray. 2011). This has been shown in most tumour types but in some macrophages at the tumour border has been associated with improved disease-free survival (Ohtani *et al.* 1997; Sugita *et al.* 2002). This has been suggested to be a tumour-host interaction. In non-small cell lung cancer, M1 macrophages have been associated with better prognosis (Ma *et al.* 2010).

Increase in macrophages after local therapy may be a response to the acute change in the tissue and therefore have a different polarization, that is M1, since it is known that macrophages can be influenced to change (Biswas & Mantovani. 2010; Allavena & Mantovani. 2012). Markers expressed by M2 macrophages are CD163 and CD206 so these can be stained with immunohistochemical reactions. This has not been done in this thesis.

T-Lymphocytes

T lymphocytes represent an important part of the cellular immunity. There are several subtypes of T-lymphocytes. Those looked at in this thesis are T-helper cells (CD4⁺), T-cytotoxic cells (CD8⁺), T-regulatory cells (T_{reg}, CD4⁺CD25⁺Foxp3⁺) and NK cells (CD57⁺, CD94⁺). Although a few immunocompetent cells are usually present in normal breast tissue this is not true for breast cancer where multiple immunological cells are found in the stroma and the benign tissue around the cancer. Local therapy, such as ILT, causes changes in the microenvironment.

T-cells are important in the microenvironment. High levels of CD8⁺ cells (Figure 5) have been associated with significant better prognosis in several malignancies, both longer disease-free survival and overall survival (Sato *et al.* 2005; Pagés *et al.* 2005) and T_{reg} has on the opposite been associated with poor prognosis (Piersma *et al.* 2007).

Natural T_{reg} cells develop in the thymus and are found in the peripheral lymphoid tissue. They represent 5-10% of peripheral CD4⁺ T cells and encompass a major T_{reg}-cell activity. These cells act to suppress the activation of other immune cells and maintain immune system homeostasis (Bohling & Allison. 2008). T_{regs}, which are found in increasing numbers in late stage of disease, promote progression with immune suppression. It has been shown that more aggressive breast cancers (Nottinham grade III, tumours >2cm, receptor negativity) have significantly larger number of T_{regs} than other breast cancers (Bohling & Allison. 2008; Mahmoud *et al.* 2011).

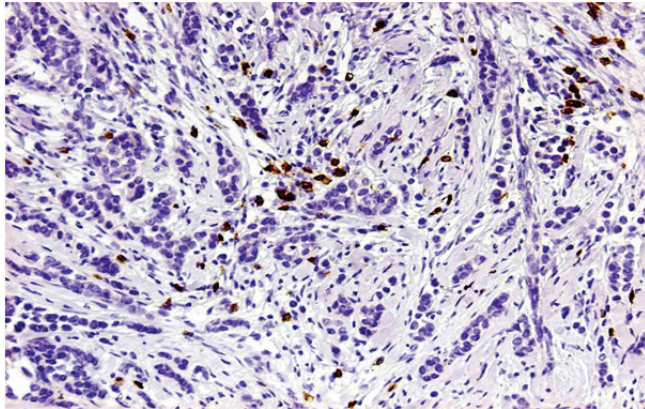


Figure 5. Cytotoxic T-cells (CD8⁺, brown) within breast cancer.

NK cells constitute a fraction of total lymphocytes, about 2-18% in human peripheral blood (Vivier *et al.* 2008). They interact with other immunological cells like dendritic cells, other T-cells and macrophages as well as with cytokines such as IL-12, IL-18 and IL-15, which are activators of NK cell function. Granzymes are serine proteases that are released by cytoplasmic granules within cytotoxic T cells and NK cells (Kajitani *et al.* 2012). Their purpose is to induce apoptosis within virus-infected cells, thus destroying them. Perforin, is also contained in granules, and it was

postulated that it makes pores on the plasma membrane of the target cells so that granzyme A and B can enter (Kontani *et al.* 2001). Now it is known that granzyme B and perforin enters the target cells via a receptor (CI-MPR). Granzyme B can then activate endonucleases and induce DNA fragmentation, which causes apoptosis (Lord *et al.* 2003).

B - lymphocytes

B-lymphocytes are effector cells of humoral immunity, producing antibodies and differentiating into plasma cells. They serve as well in cellular immunity as APCs and stimulating T-lymphocytes. In tumour immunology they have often been seen as bystanders but it is known that B-lymphocytes can induce tumour-specific cytotoxic T cell activation (Coughlin *et al.* 2004).

Large number of B-cells has been associated with better prognosis in breast cancer (Mahmoud *et al.* 2012). On the other hand T_{regs} may stimulate B-lymphocytes in producing antibodies against extracellular matrix components recruiting other cells like macrophages (Andreu *et al.* 2010).

AIMS OF THE STUDY

The following aims were addressed in the original papers:

1. To evaluate technical aspects of ILT as a method for local treatment of breast cancer.
2. To find out if ILT of breast carcinoma induces changes in relevant immunocompetent cells (B cells, several T cells, dendritic cells, macrophages) in the tumour and in regional lymph nodes.
3. To review the outcome of 24 breast cancer patients treated with ILT.
4. To evaluate if MRI is more accurate in preoperative assessment of invasive cancer than US or MGM.

MATERIAL AND METHODS WITH COMMENTS

Patient selection, papers I-III

In paper I, which is a pilot study, twenty-four women were selected from a multidisciplinary weekly conference and treated with ILT for breast cancer. There was a large variety of patients when considering size, histological diagnosis and molecular profiling. Twelve patients did not have lymph node metastasis but the other had N1-N3. All twenty-four patients were included in paper III where the focus was on follow up.

Six more patients were considered for ILT but on pre-treatment ultrasound the tumour border was difficult to define, often because of bleeding after core biopsy, for proper targeting. These patients served as controls in paper II. These patients were in retrospect not perfect as they had hematoma in the tumour after core biopsy, which could potentially influence the number of immunocompetent cells within the tumour because of the inflammation, caused by the hematoma.

Criteria for inclusion were palpable and/or visual tumour on ultrasound and verified invasive cancer on core biopsy. The size should not exceed 30 mm in the beginning of the study but was later changed to 15 mm because necrosis volumes were small and the tumours were larger than preoperative assessment indicated. The patient should be planned for curative operation and be able to lie still for 30 minutes during treatment. Because of the large variation in size of tumours treatments were planned very differently for the patients as seen in Table 8 where both the number of laser fibers and location of those and temperature probes was different. That gives a great variation in a small group of treated patients, which is a drawback in the study.

Pre-treatment diagnostic work up included pulmonary x-ray and liver function tests.

In paper II patients with necrosis $<1\%$ ($n=4$) were excluded. This was done in order to evaluate the tumours may have been affected by the ILT. Patients radically treated with ILT ($n=3$) were excluded because no tumour was left for immunohistochemical staining. Also lymph nodes for these patients were not examined as these patients were only three and no difference was thought to be measurable.

Patient selection, paper IV

From January 2007 to December 2009 641 women were diagnosed with invasive breast cancer in Iceland. All 641 had routinely both MGM and US at the breast diagnostic clinic (the Icelandic Cancer Society) and 438 were referred for MRI and these entered the study retrospectively. 12 patients were excluded, having received neoadjuvant chemotherapy. 65 patients with multifocal or contra-lateral disease were assessed separately. As the study is retrospective and the pathological report was often not precise regarding the size of every tumour and that it was difficult to be sure about size on pathological report and the size on MRI was on the exact same tumour, these tumours were not included in the comparison of size. The primary patient group for analysis therefore included 361 patients with unifocal invasive breast cancer (Table 4).

It was possible to visualize the tumour by all three imaging modalities (MGM, US, and MRI) in 267 patients. A separate analysis was done for visible tumours by the individual imaging modalities (MGM, $n=286$, US, $n=340$, MRI, $n=348$). Thus, these evaluations of the capability of the imaging modalities to predict tumour size included only tumours visible on imaging.

Table 4. *Patient characteristics (n=361) in paper IV.*

Mean age at op (years)	55 (26-85)
Histological type n (%)	
IDC	310 (86)
ILC	38 (10)
Other	13 (4)
T-stage of tumour n (%)	
<20 mm (T1)	239 (66)
20-50 mm (T2)	107 (30)
>50 mm (T3)	15 (4)
Lymph node status n (%)	
N0	220 (61)
N1	91 (25)
N2 and N3	38 (11)
NX	12 (3)
Histological grade n (%)	
I	73 (20)
II	181 (50)
III	107 (30)
Receptor status n (%)	
ER+	294 (81)
PgR+	261 (72)
Her-2+	43 (12)
Triple negative (%)	43 (12)

The number of false negative result from radiology is not addressed in paper IV. It is well known that interval cancer, that is cancer diagnosed in the period of two screening occasions, are missed during MGM more often in dense breast tissue. In this retrospective study on diagnosed invasive cancers these numbers are not available for MGM, US and MRI and could only be answered in a study where all MGMs, USs and MRIs of breast in the study period would be evaluated. In this study an assumption of this can be made, as it is known how many patients had measurable tumour on each radiological method and how many were measurable on every radiological method. For MGM 75 patients did not have measurable tumour (21%,

75/361) although some of these patients did have a distortion in the parenchyma or micro calcifications giving suspicion of cancer. Corresponding numbers for US and MRI are 6% vs 4% (21/361 and 13/361).

Treatment protocol, paper I

ILT was performed in the outpatient clinics. Patients were monitored and an intravenous line was set up for conscious sedation, if necessary. A local anesthetic was infiltrated in the treatment area and laser fibers were placed at a depth corresponding to the middle of the tumour.

As this was a pilot study placement of fibers differed, taking into account tumour size and location within the breast. One (n=10) or 4 (n=14) laser fibers were used (Table 7). When one laser fiber was used, which was in the smaller tumours, the fiber was placed in the center of the tumour. When four fibers were used the laser fibers were placed at the tumour border or little outside the border.

Placement of laser fibers was performed under sterile conditions after inserting plastic venous cannulas (1.6 mm) and removing the metal stylet. The laser fibers and the thermistor probe (Figure 6) were placed with help of palpation in 5 patients and under US guidance in 19 patients. Placement of thermistor probe is seen in Table 7. US was also used for measuring tumour size and distances from the tumour to the skin and to the pectoralis fascia.

Color Doppler ultrasound was performed after ILT, before surgery, in 18 patients and operation was preformed 4-23 days after ILT (mean 12). Type of operation performed is found in Table 5.

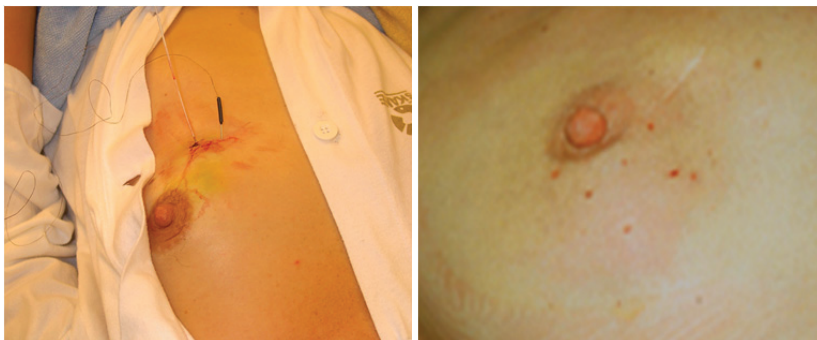

Figure 6. ILT treatment of breast cancer (left) and immediately after ILT (right). On the left side one laser fiber is seen entering the breast and one thermistor probe.

TABLE 5. Operation type (n=24)

	Primary operation	Re-operation
T1N0 (n=12)	Sector resection and SNB 11 Mastectomy 1	Sector re-resection 1 Mastectomy 1
T1N1 (n=4)	Sector resection and SNB+Axillary dissection 4	Sector re-resection 1 Mastectomy 2
T2N0 (n=3)	Sector resection and SNB 2 Mastectomy 1	
T2N1 (n=2)	Sector resection and SNB+Axillary dissection 2	Mastectomy 1
T2N2/T3N0/T3N 3 (n=1/1/1)	Mastectomy and axillary dissection 2 Sector resection and SNB+Axillary dissection 1	Mastectomy 1

SNB= sentinel node biopsy.

ILT – feedback temperature system, paper I

Treatment was carried out with a system consisting of a diode laser and a temperature feedback control unit interfaced with the laser. The temperature feedback control unit consisted of a personal computer, an automatic thermometry system (ATS-100), Lund Science, Lund, Sweden) and a temperature probe. Treatment was performed at a steady-state target temperature of 48°C for 30 minutes and the output laser power was stepwise regulated to keep the treatment temperature stable (Figure 7).

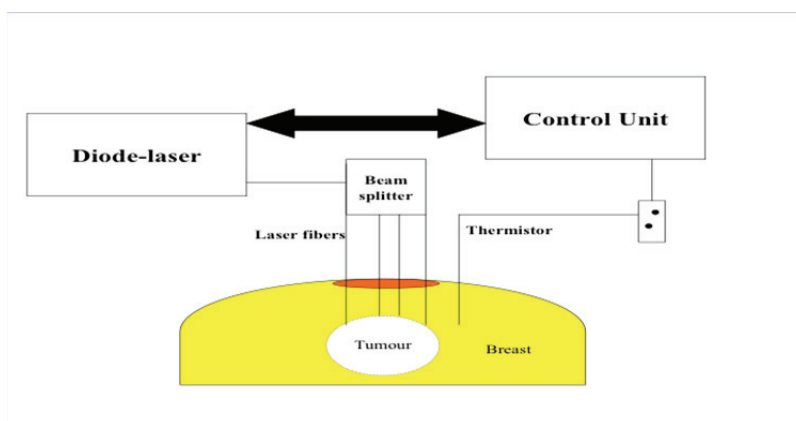


Figure 7. *ILT feedback temperature system used in paper I*

Immunohistological methods, paper II and III

All immunohistological reactions were performed on paraffin sections. From the large blocks of resected cancer, vital tumour areas with a few mm of surrounding tissue, totally slightly more than 1x1 cm, were chosen. The whole needle biopsies and sections from the lymph nodes were also used.

For single immunohistochemistry, the reactions were performed in an automatic immunostainer TechMate 500 (Ventana BioTech Systems, Tucson, AZ, USA) and the double staining was made in DakoCytomation

Autostainer (Dako, Glostrup, Denmark). This ensures standardization in the staining, which is of great importance in a study like paper II where many antibodies are used.

The antibodies, dilutions and companies are listed in paper II. Markers and corresponding cell types are listed in Table 6.

The antibody against the estrogen receptor alpha and the progesterone receptor are listed in paper II and antibodies against Her-2, CK5/6, EGFR and Ki-67 in paper III.

Table 6. *Antigens, often situated in the cell membrane, and targeted cell type.*

Antigen	Targeted cell type:
CD1a	Immature dendritic cell
CD4	T helper cell
CD8	T cytotoxic cell
CD20	B cell
CD25	Interleukin-2 receptor, placed on T helper cell
CD57	NK cell
CD68	Macrophage
CD83	Mature dendritic cell
CD94	NK cell
Granzyme-B	Perforin and granzyme B present in some cytotoxic T- and NK cells
Foxp3	Forkhead/winged helix family of transcription factors, placed inside T _{regs}

Tissue analysis, paper II

Photos of the immunohistological reactions were taken of vital tumour at the tumour border and in the interior of the cancers using a standard light microscope and a 10x objective (Bx-60, Olympus, Tokyo, Japan). The tumour border photos were taken with the tumour edge at the middle of the photo, meaning that half of the photo showed tumour and the other half benign tissue outside the tumour. Results labeled as “within the tumour” did not include parts that were photo’d as tumour border. We tried to get 20 photos at the border and 20 in the interior of the cancers, but that was often not possible, especially not in the core biopsies. The median number of photos taken in the core biopsies was 4 (range 1-10) at the border of the tumour and 9 (1-36) within the tumour. The number of photos taken of the vital tumour after ILT was 19 (3-42) at the border and 17 (2-46) within. Immunohistological reactions were considered positive only if the cell nucleus was seen. The average number of cells per visual field was reported for core biopsies and for resected tumours.

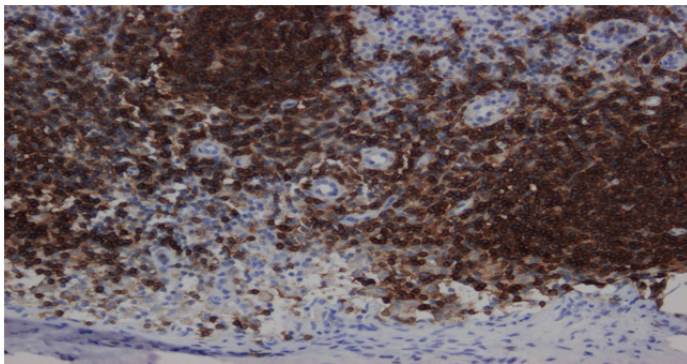


Figure 8. *CD20⁺ cells in a lymph node (brown colour).*

In the lymph nodes visual fields with the highest number of positive cells were used for counting (“hot spot”) and representative photos were with and without cancer. Lymph nodes were not examined for CD4⁺, CD20⁺,

CD8⁺ and CD68⁺ cells because of the extreme amount of positive cells and another approach was necessary for counting than the one we used with the Image Pro Plus program or manually (Figure 8).

The reason for using the “hot spot” method for counting cells in lymph nodes was the fact that many visual fields contained zero or very few positive cells. This was even true for core biopsies and resected specimen and an analysis was done on “hot spots” there as well. There we used the three pictures with the most cell amount for analysis. This was done to see if we could visualize further differences, as it is known that areas for example around cells can have more cells clustered (Figure 9). The results did not differ from the original one.

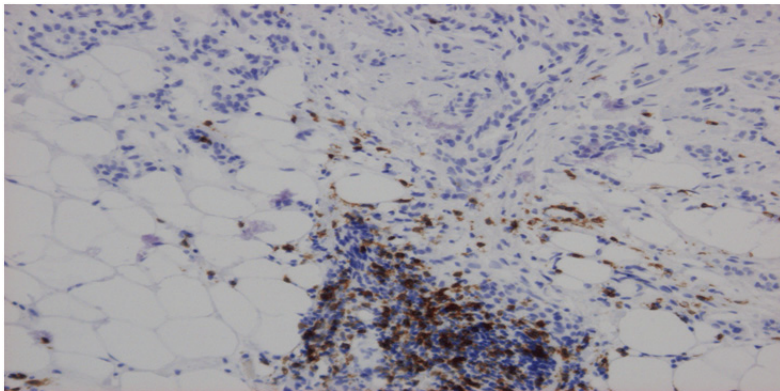


Figure 9. CD8⁺ cells (brown) around small vessels at the tumor border

Computerized digital analysis paper II

For computerized digital analysis pictures were scanned and captured with a three-color charge in order to facilitate interpretation and quantification of findings (Ivarsson *et al.* 2003). The images were saved in TIFF (Tagged Image File Format) format for analysis with Image-Pro Plus 4.5 software (Media Cybernetics; Silver Spring, MD). This software was used for

counting the cells for all antibodies (Figure 10) except CD68⁺ and CD25⁺Foxp3⁺ cells which were counted manually. The color was set for one picture in each patient for each antibody and that setting used in all the pictures for the antibody in that patient. The advantage was that it was standardized and more true positive cells were captured. The disadvantage was that in for example CD68⁺ cells this could not be used because of other cell type was also colored ((myo)fibroblasts) and had therefore to be counted manually. CD25⁺Foxp3⁺ cells were counted manually in order to be able to discriminate between double stained CD25⁺Foxp3⁺ cells and single stained CD25⁺ or Foxp3⁺ lymphocytes. The number of cells in the whole picture was counted even though areas within the picture did not have many cells (Figure 10). This gives an average for the tumour in a whole but does not concentrate only on the “hot” areas within the tumour or tumour border.

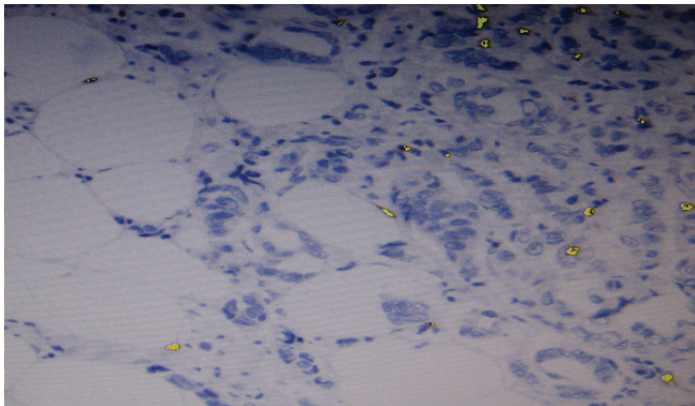


Figure 10. *Positive cells were manually marked. After that the Image-Pro Plus program was used to count all positive cells in that and other pictures of the same patient.*

Pathological examination, paper I, II and IV

A core biopsy was performed for histological diagnosis and receptor status. On resected specimen in paper I, sector or mastectomy, a section was cut through the middle of the tumour (Figure 11). Sections of 0.5-1 cm were cut from the fascia through the whole preparation perpendicular to and down to the skin. Tumour size and resection margins were noted and measured. The slices, still adherent to the skin, were fixed in 6% formaldehyde for 24-72 h. The large slices were embedded in paraffin and cut, due to thickness, on one or two levels and stained with haematoxylin-eosin. Tumour size, lesion size and resection margins were measured also under the microscope.

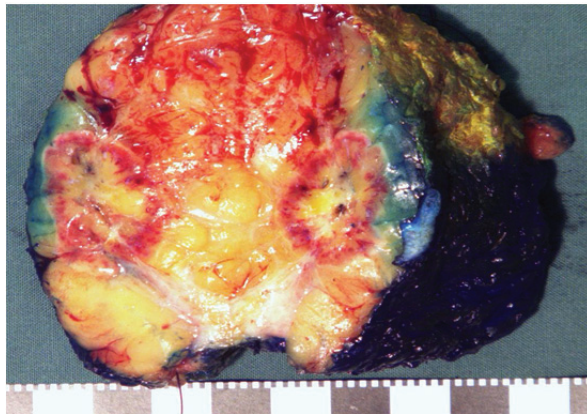


Figure 11. *Resected specimen with incised lesion 6 days after laser thermotherapy. The hemorrhagic border is clearly visible around the treated area.*

In paper IV sections of 5-10 mm were cut from the skin to the fascia and fixed in 10% formaldehyde for 16-48 h. Thereafter the tumour size and resections margins were noted and measured. Representative areas of the tumour were cut, embedded in paraffin and thereafter stained with haematoxylin-eosin. Largest diameter of invasive tumour, taken from the pathological report, was used in the study. Because of this and that there are

no whole transverse slices found it was not possible to reevaluate the resected specimens. Because of this it is possible that there is an under- or overestimation of size on pathology, which does that the difference between radiology and pathology is larger or smaller than reported.

In paper I volumes (V) of tumour and lesion size was estimated according to the formula $V = a \times b^2/2$, where a is the largest width and b is the maximum diameter perpendicular to the width of the tumour or necrosis (Carlsson *et al.* 1983). Estimations of tumour size did not include possible areas of carcinoma in situ (CIS) because CIS was quantitatively small. Malignancy was graded according to the Nottingham school.

Follow-up, paper III

Follow-up adhered to the regional standard protocol for southern Sweden and included postoperative clinical control 2 weeks after surgery and then clinical examination and mammography, and in some cases ultrasound, every year for 3 years. After that, patients younger than 75 years of age entered the standard screening protocol.

Information after scheduled routine follow-up was obtained from hospital records and the civil register.

Radiology paper IV

Information on US, MGM and MRI was gathered from patient's charts. Images were not re-read which should have been better when evaluating a method like MRI. Re-evaluation would probably give a different size on several occasions but it is likely that the difference would have been small. On the other hand, it would have been good to re-evaluate the ones where size differed with 10 mm or more to see if the inaccuracy could be explained by a suspicion only or distortion of parenchyma. On the other hand, the estimations in the patients's charts are important since they were the ones that further management was based on.

MGM and US were done according to local protocols. Three MGM views were taken on the index breast. Tumour size was measured in all cases and the largest diameter given as the maximal tumour size.

On ultrasonography perpendicular views were taken of the tumour and measurements done in three planes. The largest diameter was given as the maximal size of the tumour. A hyper echogenic rim around the tumours was not routinely included in the size measurement.

Following the diagnosis of breast cancer, an MRI was performed within 5 days and surgery within 3 weeks. The MRI was performed on a 1.5 T magnet (Magnetom Avanto V17, Siemens Medical Solutions, Erlangen, Germany) with a dedicated bilateral breast surface coil. The imaging was performed in a prone position and took about 15 minutes. The imaging protocol includes T2 weighted turbo spin-echo imaging sequence in the transverse plane and a 3D FLASH axial T1 weighted sequence in the transverse plane before contrast injection. An intravenous contrast, gadopentetate dimeglumine (Magnevist®, Bayer Schering Pharma AG, Berlin, Germany) was used and a dynamic T1 weighted imaging was performed with five sequential series. A fat-selective inversion is used for fat suppression and the pre-contrast image is subtracted from the corresponding post-contrast image with standard software subtraction function available on the console. The size of tumour was measured in three imaging planes (coronal, axial and sagittal planes) and the largest diameter used in this study.

Statistical analysis paper II-IV

In paper II each patient was its own control. We used the difference in number of cells for the various antibodies between the core biopsy and the resected tissue. Statistical significance of these differences was determined by the paired t-test, and students' t-test was used for comparing ILT patients with the control group. A *p*-value of <0.05 was considered significant.

In paper III we used student's t-test for comparing patients with and without recurrence of disease. Again a p-value of <0.05 was considered significant.

In paper IV relationships between microscopic and imaging measurements of tumour size were estimated with linear regression. Possible differences in the frequencies of over- and underestimation between MRI and US were tested with Fisher's exact test. Calculations were made with GraphPad Prism, version 6.01.

RESULTS AND DISCUSSION

Patient characteristics papers I-III

The patients were selected for radical treatment and should have no distant metastases (Table 7). Apart from that, the most important factor in patient selection was size, which is addressed on page 50

The type of breast cancer, that is for example IDC or ILC, or lymph node metastases, was not considered as an exclusion criterion for ILT. It is known that ILC growth pattern is different from IDC. They infiltrate the stroma of the breast and do not destroy anatomic structures (Arpino et al. 2004) and because of this they often fail to form distinct masses that are easily diagnosed with palpation or MGM. ILC is more often multifocal or multicentric than IDC (Arpino *et al.* 2004) and the incidence of contralateral disease is more frequent. Radiological methods like MGM and US used in screening frequently miss that and only give size of the main tumour. It has been suggested that ILC should not be included in a study evaluating local therapy like ILT (Snelling *et al.* 2004) as was done in paper I. Eight patients had ILC and one had a mixed lobuloductal cancer. Four were not measurable on MGM but distortion of parenchyma gave suspicion of tumour as well as a palpable mass in 3. These patients did not have multifocal disease. The mean necrosis percentage for these nine patients was 46 % and one of them was radically treated. This is higher than the average necrosis percentage (33%) so the results of our study do not support the suggestion that local treatment will be less radical in ILC than in IDC.

Table 7. Tumour characteristics and treatment efficacy of ILT patients

Patient number	Diagnosis	Tumour size (mm) on palpation/ultrasound/ mammography before treatment	Microscopic examination after treatment (mm)/CIS outside invasive cancer	Number of laser probes	Location of laser probes within the tumour	Location of temperature probe	Placement of laser probes and temperature probe with ultrasound	Tumour necrosis (% of tumour volume)
1	D	25/30/30	25/-	4	O	OL	Y	0
2	D	15/18/a	22/-	4	O	OL	N	0.1
3	D	20/16/25	18/-	4	O	OL	Y	1.5
4	D	20/25/25	11/-	4	O	OL	N	33
5	D	20/11/b	15/-	4	B	OL (=OB)	Y	0.5
6	LD	20/16/b	12/-	4	B	OL (=OB)	N	15
7	L	20/14/a	15/-	4	B	OL (=OB)	N	60
8	D	30/35/30	55/+	4	B	OL (=OB)	Y	1
9	D	20/18/18	33/+	4	B	OL (=OB)	N	1
10	D	20/15/a	21/-	4	B	OL (=OB)	Y	0
11	L	15/15/15	19/-	4	B	OL (=OB)	Y	100
12	L	10/12/b	16/-	4	B	OL (=OB)	Y	5
13	D	10/13/10	c/-	4	B	C	Y	100
14	L	15/15/15	18/+	4	B	C	Y	33
15	L	10/7/10	15/-	1	C	B	Y	98
16	D	10/7/a	8/-	1	C	B	Y	40
17	D	10/12/12	16/+	1	C	B	Y	60
18	L	10/6/10	c/+	1	C	OB	Y	83
19	L	10/12/12	15/+	1	C	OB	Y	2
20	D	10/7/a	11/-	1	C	OB	Y	25
21	D	10/8/a	14/+	1	C	OB	Y	5
22	D	10/8/a	c/-	1	C	OB	Y	100
23	L	0/11/b	40/-	1	C	OB	Y	15
24	D	0/5/b	7/+	1	C	OB	Y	19

D Ductal cancer, L Lobular cancer, LD Lobular ductal cancer, a Not visible on mammography, b Distortion of parenchyma but no isolated tumour, c Radically treated with ILT, O 3 mm outside the tumour boarder, B Tumour border, C Centre, OL 5 mm outside laser probe, OB 5 mm outside tumour border, Y Yes, N No.

Lymph node status of patients with malignancies is an important factor of prognosis. It has been shown that cancer in lymph nodes influences the number of immunocompetent cells (Tsuge *et al.* 2000). When evaluating the lymph nodes of ILT treated patients we compared the nodes without tumour with tumour free lymph nodes of the control patients.

The control patients (Table 8) were patients that were considered for ILT treatment but were not treated with ILT because US could not define the tumour border. They were thus selected in the same way as the patients that were ILT treated which is an advantage. It is possible that the reason for the diffuse tumour border was bleeding in the tumour after the core biopsy, which can cause inflammatory changes. In paper II number of immunocompetent cells in controls versus ILT treated patients were considered but statistical comparison between the two was not done except in the lymph nodes. The only statistical difference within the lymph nodes was a decrease in the number of T_{regs} after ILT compared to control patients. In acute inflammation T_{regs} increase to remain homeostasis in the tissue. Other cell types had a tendency towards significance such as immature dendritic cells (P=0.15), which increased after ILT. If bleeding caused these changes the acute inflammation after ILT and in control patients after bleeding should cause increase in both groups for both cell types.

Table 8. *Clinical characteristics of control patients included in paper II*

	Control patients (n=6)
Tumour size, mm	
Ultrasound	11 (8-14)
Microscopic	13 (9-19)
Pathological diagnosis D/L/LD	5/1/0
Tumour necrosis, %	-
Lymph node metastases, Y/N	1/5

^aD= ductal carcinoma, L= Lobular carcinoma, LD= lobular ductal carcinoma.

Size of ILT treated tumours

Tumour characteristics and operation type are listed in tables 5 and 7. As a rule, the tumours were larger at pathological examination than on ultrasound or mammography. The size ranged from 7-60 mm (mean 22 mm) at microscopic examination and from 3-35 mm (mean 14 mm) on ultrasound (Figure 12). Three tumours were impossible to measure after surgery due to a complete response to ILT.

The underestimation of tumour size at ultrasound is a problem for treatment with local ablation with radical intent. The halo seen around invasive tumours should probably be included in the measurement of tumours (Hieken *et al.* 2001; Golshan *et al.* 2004). Also US is more inaccurate in ILC than in IDC (Snelling *et al.* 2004; Heusinger *et al.* 2005). If contrast enhanced US is used studies have shown a more accurate size assessment (van Esser *et al.* 2007). Another problem is the inability of MGM and US to visualize CIS at the tumour border and in local ablation this is may be important. Calcifications on MGM indicate CIS but this is often not seen in lobular cancer in situ (LCIS). Because of this core biopsy should be critically judged with regard to CIS before deciding on local ablative therapy. MRI has been shown to be more sensitive in pure DCIS than MGM (Kuhl *et al.* 2007) and should probably be done if local ablation is considered for radical treatment. Local ablation could be considered in breast cancer with low grade CIS if radiation therapy will be given in adjuvant settings to treat in situ tumour left untreated.

Another consideration is ILT in neoadjuvant settings. Then treatment can be done which might not be radical to get the immunological effect of the treatment. Radicality is then of less importance as operation would be planned. On the other hand ILT should probably be done on a large proportion of the tumour to get enough change in the microenvironment of the tumour. How large a proportion that needs to be treated is not known and further studies are needed.

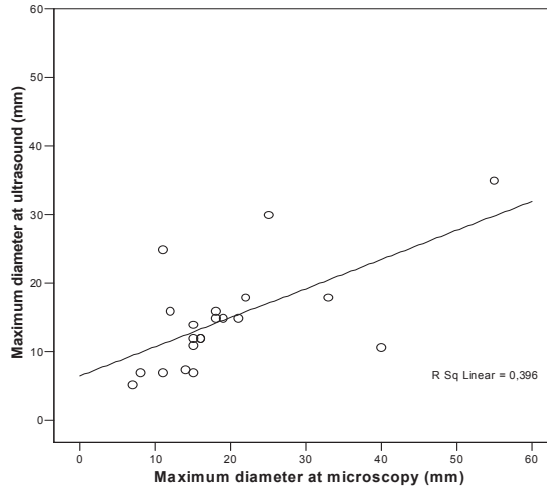


Figure 12. Scatterplot of tumour size on ultrasound examination, versus microscopic tumour size.

Treatment effect and laser fiber placement

The tumours treated were irregular in form, and placement of laser fibers outside the tumour or at the tumour border was difficult. The border was often somewhat indistinct at US. Tumours >2 cm are more difficult to treat with ILT, as more fibers are needed. In four patients fibers were placed outside the tumour border and the mean necrosis was 9% (0-33). Larger necrosis was achieved in patients with laser fibers at the tumour border but ultrasound has difficulties at the tumour boarder because of a halo often found around the tumours and the irregularity of tumour structure as mentioned before. In 10 patients the tumours were smaller than 13 mm (palpation, ultrasound, mammography) and were treated with one laser fiber in the center of the tumour and the feedback thermistor at or outside the tumour border (Table 7), which resulted in necrosis volumes of 5-100% (mean 50%). A low percentage of tumour necrosis was associated with necrotic areas in the fatty tissue outside the cancers.

Post-ILT ultrasound was performed in 18 patients shortly before surgery (mean 8 days after ILT). The extent of laser damage could not be judged

with ultrasound but an indication of necrosis was seen when using Doppler as blood flow was absent in areas of the tumours.

Paper I is a pilot study where we tried to refine the method for radically treat the patients. Placing the laser fibers outside the tumour border where the thermistor probe was further away from the tumour border by a few mm did not give a good result (Table 7). The average necrosis percent was 9% and three patients had a necrosis percentage less than 2%.

For radical treatment small tumours should be selected so that one laser fiber can be used which eliminates the problem with placement of several fibers. Eventually a contrast enhanced US or a 3D US would be more accurate methods in the placement of fibers than conventional US.

Another issue is the aim of the treatment. In paper I the aim was to treat tumours radically. Treatment was not radical in 21 of 24 patients but in those not radically treated there was a change in the number of immunocompetent cells. Many of the changes seen are known positive prognostic factors. The question then arises if ILT should be used in neoadjuvant settings before surgery to get the change in the microenvironment of tumours known to be positive. This is a larger question and cannot be answered by this thesis. Further research is needed.

ILT – adverse effects

Treatment with ILT was well tolerated by the patients and the patients were positive to ILT. Pain during treatment was easily relieved with medication and some patients did not experience any pain. If the tumour was lying near the pectoralis fascia pain was more common. It is possible to infiltrate a local anesthetic or saline between the tumour and fascia if the distance between is small, but that was not done in this study. Tenderness after ILT was similar to tenderness after core biopsy according to the patients.

Two patients had a small skin necrosis. In one patient the distance between the skin and tumour was only 3.5 mm but in the other it was 15 mm. Explanation to the latter is probably that the laser fiber was inserted from

the side so that the diffuse spreading of laser light from the tip of the fiber caused coagulation in subcutaneous vessels.

None of the ILT treated patients had local recurrence of disease or late adverse effects of ILT. Cyst formation has been described after ILT (Dowlatshahi *et al.* 2004) and infection and bleeding is also a risk. None of the patients had that because the treated area was resected. Dissemination of disease has been described to occur after ablation, although infrequently. This has mostly been suspected to occur in the liver in hepatocellular cancer (Nikfarjam *et al.* 2005; Masuda *et al.* 2008; Koda *et al.* 2012). The reason for this is thought to be the stimulation of proliferation of liver parenchyma after ablation combined with explosion of tumour cells. Also dissemination within the portal veins can give metastasis in other locations within the liver (Masuda *et al.* 2008). This has not been described for local ablation in breast cancer. Seeding in the tract of the device is important to consider as described on page 19.

Changes in immunocompetent cells within tumour and at tumour border after ILT

There was a great variation in the density of immunocompetent cells between patients and within the tumour specimens from the same patient, both in ILT and control patients. Cells were usually in the stroma between the cancer nests but in some cases within the cancer nests (Figure 13).

Comparison was done between core biopsies and resected tumour for each patient both at the tumour border and within the tumour. Counts for NK cells were low as for granzyme B and no variation was noted both within tumour and at the tumour border.

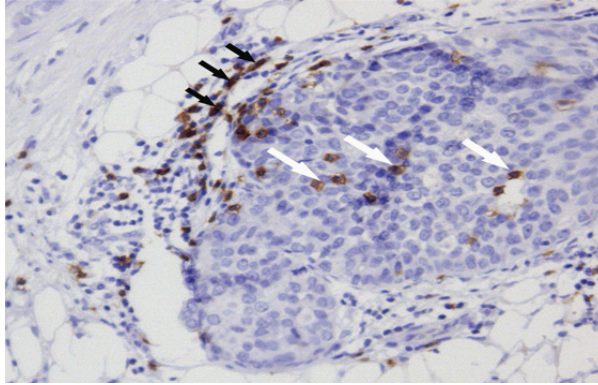


Figure 13. Cytotoxic T cells (CD8, brown color) at the tumour border. Positive cells in the stroma and within the cancer nests (white arrows). A few (myo)fibroblasts are also positive (black arrows).

Changes seen at the tumour border are illustrated in Figure 14. At the tumour border the predominant cell types were CD8⁺, CD20⁺ and CD68⁺ cells. Significant increases were observed for CD20⁺ ($P<0.05$), CD68⁺ ($P<0.001$) and CD83⁺ ($P<0.01$) cells. There was a tendency for CD8⁺ cells to be increased after laser treatment ($P=0.12$).

Within the tumours the main cell types were CD8⁺ and CD68⁺ cells. The densities of CD8⁺ and CD68⁺ cells were significantly larger after ILT than in the pre-treatment biopsies (Figure 15; $P<0.05$ and $P<0.01$, respectively). There was no significant increase in the CD8⁺/CD4⁺ ratio after ILT. The number of CD25⁺Foxp3⁺ cells tended to be smaller after ILT but did not reach significant levels ($P=0.20$).

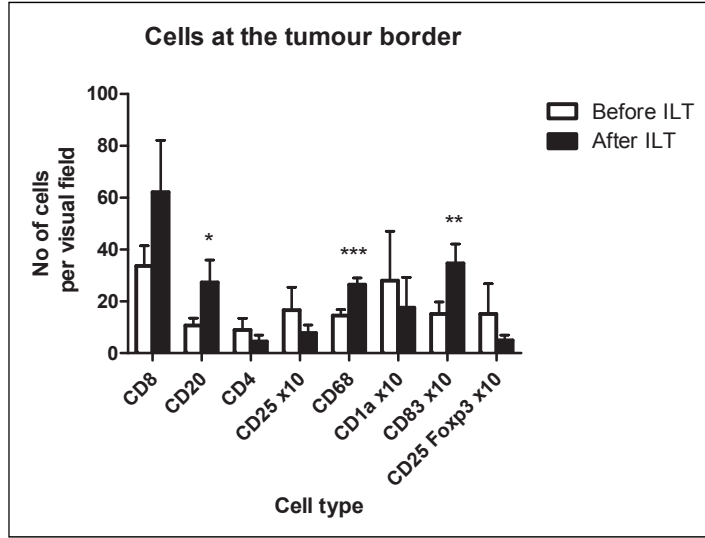


Figure 14. Findings at the tumour border, before and after ILT. Paired *t* test: * $P < 0.05$, ** $P < 0.01$, *** $P < 0.001$

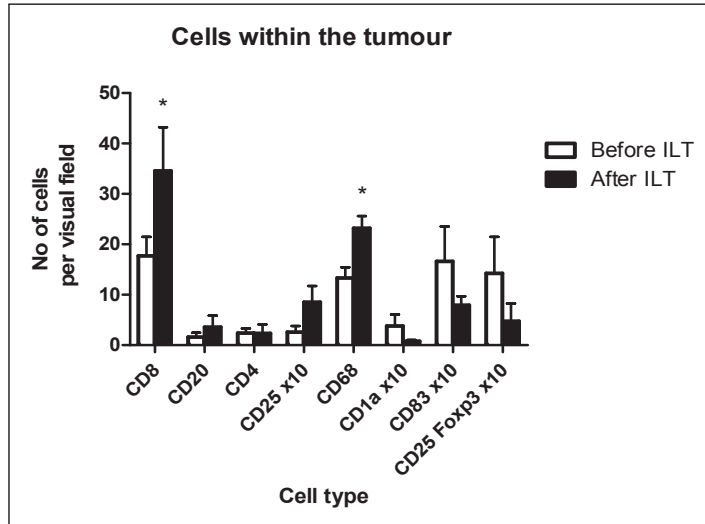


Figure 15. Findings within the tumour after ILT. Paired *t* test: * $P < 0.05$

Increase in mature DC has been shown to be a positive prognostic factor in breast cancer (Iwamoto *et al.* 2003). In the present study significant difference was seen in mature DC at the tumour border (Figure 14). There was a decrease in immature dendritic cells at the tumour border that correlates to that but the difference was not significant.

Macrophages can be polarized as M1, cells of acute inflammation and antigen presenting macrophages, or M2 who promote progression of tumours (p. 27). M2 polarized macrophages, also called TAMs most likely represent macrophages found in the core biopsy. After ILT, the macrophages are significantly increased both within the tumour and at the tumour border. This increase might be a response to the acute change in the tissue caused by ILT and may have a different polarization, that is M1, since it is known that macrophages can be influenced to change (Biswas & Mantovani. 2010; Allavena & Mantovani. 2012). Markers expressed by M2 macrophages are CD163 and CD206 so these can be stained with immunohistochemical reactions. In paper II no immunohistochemical staining has been done to differentiate between M1 and M2 macrophages. This should be done in future studies.

In paper II there was a tendency to statistical difference at the tumour border of cytotoxic T cells ($CD8^+$) and a significant difference within the tumour after ILT. This has been shown in other studies to be a positive prognostic factor in several malignancies (Sato *et al.* 2005; Pagés *et al.* 2005). In paper III an increased number of $CD8^+$ cells were seen in patients with recurrence of disease both in the core biopsy and also in the resected tumour. These results were not expected but similar results have been reported (p. 60).

T_{regs} have been combined with poor prognosis because of suppression of inflammatory response. It has been shown that larger number of T_{regs} is seen in later stages of disease in breast cancers (Bohling & Allison. 2008; Mahmoud S *et al.* 2011). In cancers at a late stage more TAMs are also seen and both factors lead to tumour progression. Since the study was done (paper II) a new cell type with immunosuppressive features have been

described, myeloid derived suppressor cells (MDSCs). Immature myeloid cells differentiate into granulocytes, macrophages or dendritic cells under normal conditions but in pathological situations like infections and cancer they differentiate into MDSCs (Gabrilovich & Nagaraj. 2009). MDSCs are suppressor cells known to promote angiogenesis and tumour progression and to be able to influence the activity of cytotoxic T cells and the activity of T_{regs} (Lindau *et al.* 2012). It is therefore important in understanding the mechanism in the microenvironment of cancers to understand the function of these suppressor cell types to be able to alter it with targeted therapy.

Not much has been published on B-lymphocytes in cancer. In paper II we used antigen against CD20, a B-cell specific antigen and a significant difference in the number of B-lymphocytes was seen at the tumour border ($p < 0.05$; Figure 14) but not within the tumour. Large number of B-cells has been associated with better prognosis in breast cancer (Mahmoud *et al.* 2012). The lowered presence of T_{regs} may play a role since it has been shown that T_{regs} can lyse antigen-presenting B cells (Janssens *et al.* 2003). Further research is necessary to evaluate the role of B-lymphocytes after ILT.

In paper II we examined changes in the number of cells both within tumour and at the tumour border. Many studies imply that cells accumulate at the tumour border and are found there in larger amount than within the cancer (Sell *et al.* 2012). Tumour progression takes place at the tumour border and levels of cells there are thought to have a larger value than immunological cells within tumour (Kondratiev *et al.* 2013).

At the tumour border there was no significant difference between pre- and postoperative cell counts in control patients receiving surgery only and the same was true for the comparisons of cell counts in resected specimens in control and ILT patients. This is most likely because of the small group of patients and the great variety of immunological cells within each tumour and between patients. Within the tumour the patients not submitted to ILT had a higher number of CD8⁺ cells in the resected breast tissue than in the

core biopsy before surgery ($P<0.05$). CD68⁺ counts were higher after ILT than after surgery alone ($P<0.05$). There is no available explanation to the increased number of cytotoxic T lymphocytes after surgery but it may be speculated that the core biopsy was relatively traumatic with associated tissue changes and difficulties at the following US examination. Another explanation is the fact that a large number of tests, in a small patient group, increase the risk that a test can become significant. On the contrary the small patient group also increases the risk that differences found in different cell counts don't become significant. Awareness of the great variation in immunohistochemical findings between patients led to the method that used the difference between core biopsy and resected specimen for each patient.

Changes in immunocompetent cells in lymph nodes after ILT

In the lymph nodes CD1a⁺, CD25⁺, CD57⁺, CD83⁺, CD25⁺Foxp3⁺ and granzyme B were examined. As in the resected tumour counts for CD57⁺ and granzyme B were low and no variation seen. In order to try to find possible effects of ILT, we restricted the comparison between ILT and control patients to patients without lymph node metastases, in laser-treated and control patients (Figure 16).

The number of immunocompetent cells correlated with the presence or absence of lymph node metastases. Cancer-free lymph nodes in patients with lymph node metastases contained similar numbers of CD1a⁺, CD83⁺, CD25⁺ and granzyme B⁺ cells as lymph nodes in metastases-free patients.

Cancer-containing lymph nodes had lower numbers of CD1a⁺ and CD83⁺ dendritic cells than lymph nodes in patients without lymph node metastases ($P<0.01$ in both cases).

In patients with lymph node metastases there were no significant differences between lymph nodes containing cancer and cancer-free lymph nodes. However, there were strong trends towards decreased counts of

CD1a⁺ (P=0.06), CD83⁺ (P=0.06), CD25⁺ (P=0.09) and granzyme B⁺ cells (P=0.09) in lymph nodes containing cancer.

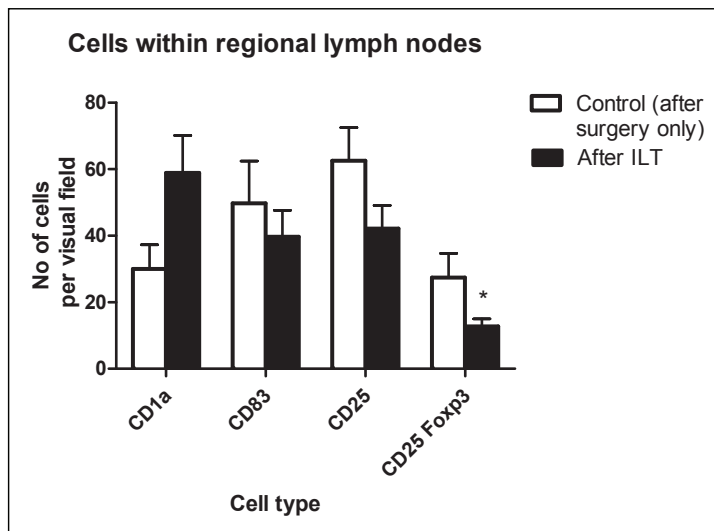


Figure 16. Comparison of cell densities in regional lymph nodes after ILT and in patients submitted to surgical resection only. Comparison was done on metastasis free lymph nodes only. Students' *t* test * P<0.05

As compared to surgical resection only (control patients), ILT and resection was followed by a lower number of CD25⁺Foxp3⁺ lymphocytes (P<0.05). Also, in patients without lymph node metastases, ILT was followed by a non-significant increase in CD1a⁺ (P=0.15) and a non-significant decrease in CD25⁺ (P=0.20). Number of T_{regs} in lymph nodes in node negative patients is a positive prognostic factor in breast cancer (Nakamura et al. 2009). The evaluation done in paper II (Figure 16) was done on negative lymph nodes.

Prognosis and immunocompetent cells

Sixteen patients had pN0 status and none developed metastatic breast cancer. 8 patients had pN 1-3 and 5 patients developed metastasis. Six patients have died, three because of metastatic disease and three of causes not related to breast cancer. The disease-free survivals for stages I, II and III were 100% (n=12), 90 % (n=10) and 0% (n=2), respectively.

In order to assess possible effects of ILT on prognosis, we compared the differences in number of immunocompetent cells between patients with and without recurrence of disease, at the tumour border and within the tumour, before and after ILT. There was not a significant difference in number of immature dendritic cells (CD1a⁺), mature dendritic cells (CD83⁺), T-helper cells (CD4⁺), cytotoxic T-cells (CD8⁺), Granzyme B, natural killer cells (CD57⁺, CD94⁺), macrophages (CD68⁺), B-lymphocytes (CD20⁺) and T-regulatory cells (CD25⁺Foxp3⁺) when all, or stage 2-3 patients only, were included (data not shown). It is possible that differences would have been acknowledged if the study group had been larger or if the necrosis volumes would have been larger with more effect on the tumour.

There was a significant difference in number of CD8⁺ cells within tumour in the core biopsy (12±3.2) in patients without recurrence compared to patients with recurrence (34±7.9, $p<0.01$). In the resected specimens there was also a significant difference ($p<0.05$) of the number of CD8⁺ cells (24±6.3) in patients without recurrence compared to patients with recurrence (64±27.1).

The presence of cytotoxic T-lymphocytes in the tumour has been shown to be a positive prognostic factor in various cancer forms (Gooden *et al.* 2011). This finding was therefore unexpected. However, similar findings have been reported before. Matkowski et al (2009) reported that a high expression of CD4⁺ and CD8⁺ cells correlated with cancer positive lymph nodes and bad prognosis in breast cancer patients. It has also been reported that high infiltration of CD8⁺ cells correlates with shorter survival in patients with renal cell carcinoma (Nakano *et al.* 2001). In that study they

also showed a positive correlation between tumour grade and infiltration of CD8⁺ cells, suggesting that tumour grade or the proliferative activity of tumour cells was a stronger prognostic factor than lymphocytes.

Patients with recurrence of disease had a lower number of CD57⁺ cells in tumour-free lymph nodes than patients without recurrence ($p < 0.05$). The infiltration of regional lymph nodes of NK cells has not been correlated to prognosis (Ishigami *et al.* 2003) as it has been in for example primary tumour in gastric cancer (Ishigami *et al.* 2000). The reason for these differing results is unclear. Numbers of CD1a⁺, CD83⁺, CD94⁺, granzyme B⁺ and CD25⁺Foxp3⁺ positive cells in the lymph nodes were similar in patients with and without recurrence.

Prognosis and stage of disease

Tumour characteristics and receptor status is found in Tables 7 and 9. Only one patient had triple negative breast cancer (TNBC). Patients operated with sector resection received radiotherapy after surgery. Operation type is found in Table 5.

None of the patients with pT1N0 (n=12) developed recurrent disease. In this patient group 6 women had invasive ductal cancer (DC), five had invasive lobular cancer (LC) and one had mixed invasive ductal and lobular carcinoma. Median tumour necrosis after ILT was 47% (0.1-100%). All patients received anti-estrogen treatment alone as adjuvant therapy.

One patient died at the age of 88, four years after treatment, of causes not related to breast cancer. One patient was diagnosed with maxillary cancer 5 years after breast cancer therapy, she is alive and has not had recurrence of breast cancer.

Table 9. *Receptor status of the 24 patients treated with ILT.*

Receptors	T1N0/T1N1/T2N0/T2N1/Other
ER ⁺	12/4/2/1/1
PgR ⁺	8/4/0/1/2
Her-2 ⁺	2/0/1/1/1
Ki67 ⁺	0/3/2/0/2
CK5/6 ⁺	All patients negative
EGFR ⁺	All patients negative

Three patients with pT1N1 (n=4) had DC and 1 had LC and the median tumour necrosis after ILT was 29 % (5-60).

One patient refused all adjuvant treatment and developed bone metastasis. She is alive 9 years after treatment. One patient developed metastases in the liver and lungs and died one year after surgery. The remaining two patients are alive and disease-free.

Three patients had pT2N0. Two had DC and one had LC. Tumour necrosis after ILT was 31 (0-60) %.

Two patients have died, one at the age of 88 because of pneumonia and one died of metastatic pancreatic cancer six years after breast cancer surgery. The third patient is alive without recurrence.

Patients with pT2N1 (n=2) were 68 and 70 years old and had tumour necrosis after ILT of 0 and 15%. One patient died 16 months after surgery with liver metastases. She did not receive adjuvant treatment and had a tumour negative for ER and PgR. The other patient is alive without metastatic disease 7 years after surgery.

Three patients had pT2N2, pT3N0 and pT3N3, respectively. These patients had tumours that were 26 (20-35) mm larger than on preoperative ultrasound, which contributed to little or no tumour necrosis after ILT (0-1%).

The patient with pT2N2 is alive but has relapsed with positive lymph nodes, supra- and infra-clavicular, and has received chemotherapy at

intervals. The patient with pT3N3 died within a year after surgery, with liver metastases. The patient with pT3N0 is alive without metastasis.

The most important prognostic factor in our patients was the presence of histologically positive axillary lymph nodes. ILT has been shown to have favorable effects on cancer. Ten of the 24 ILT treated patients had 0-5% of the tumour successfully treated. Three patients were radically treated with ILT and were therefore not included in paper II. This is an important factor in paper III where no correlation was found between ILT and progression in our group of patients.

MRI - evaluation of invasive tumour size in comparison to MGM and US

In paper IV, 267 tumours had a measurable size measurable on all modalities, MGM, US and MRI. The average diameter was 18 mm (4-65 mm) on US, 21 mm (5-80 mm) on MGM and 21 mm (6-80 mm) on MRI compared to 21 mm (4-75 mm) on pathology (Figure 17) The correlations between microscopic and radiologic tumour sizes are quite weak and all imaging methods underestimate tumour size for large tumours ($p < 0.001$ in all cases).

US over- and underestimated tumour size by 10 mm or more in 31 (12%). MRI over- and underestimated tumour size by 10 mm or more in 28 patients (10%) (Table 10). Overestimation of tumour size by 10 mm or more was more frequent with MRI than with US (Fisher's exact test, $p = 0.01$). Underestimation of tumour size by 10 mm or more occurred more often with US than with MRI (Fisher's exact test, $p = 0.02$). Similar results were observed when the analysis included all tumours seen on each modality (data are summarized in Table 11).

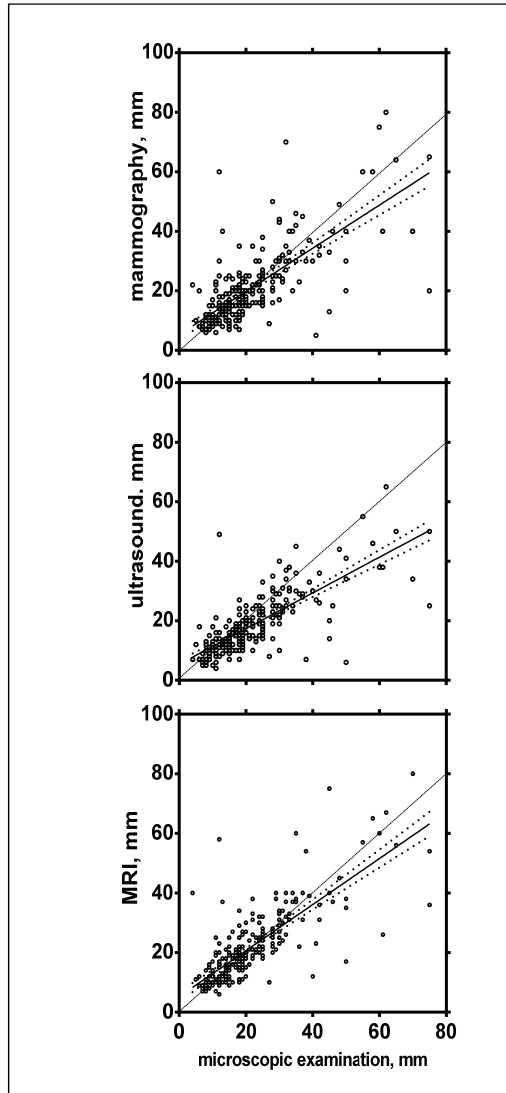


Figure 17. Linear regression plots between tumour size determined on microscopic examination and the imaging methods. The dashed line shows the theoretically ideal relationship between microscopic examination and imaging. The slopes of the calculated regression lines are significantly different from 1 for each imaging method (t-test in a regression model with log-transformed data, $p < 0.001$ in all cases). The dotted lines represent the 95% confidence intervals of the slope.

Table 10. Tumour size when measurable by all imaging modalities within the same patient (MGM, US and MRI) (n=267). Comparison with microscopic examination.

	Underestimation by ≥ 10 mm	Within 1-9 mm	Overestimation by ≥ 10 mm
MGM	18 (6.7 %)	227(85 %)	22 (8.2 %)
US	26 (9.8 %)	236 (88 %)	5 (1.9 %)
MRI	11 (4.1 %)†	239 (90 %)	17 (6.4 %)‡

US= ultrasound, MGM= mammography, MRI= magnetic resonance imaging.

† MRI underestimates tumour size less often than US ($p=0.02$, Fisher's exact test).

‡ MRI overestimates tumour size more often than US ($p=0.01$, Fisher's exact test).

Table 11. Tumour size when measurable by MGM (n=286), US (n=340) or MRI (n=348). Comparison with microscopic examination.

	Underestimation by ≥ 10 mm	Within 1-9 mm	Overestimation by ≥ 10 mm
MGM	20 (7.0 %)	243 (85 %)	23 (8.0 %)
US	35 (10 %)	297 (87 %)	8 (2.4 %)
MRI	16 (4.6 %)†	306 (88 %)	26 (7.5 %)‡

US= ultrasound, MGM= mammography, MRI= magnetic resonance imaging.

† MRI underestimates tumour size less often than US ($p<0.01$, Fisher's exact test).

‡ MRI overestimates tumour size more often than US ($p<0.01$, Fisher's exact test).

MRI was falsely negative in 13 patients (3.6%): no lesion was seen in 9 cases and a benign or unspecific lesion in 4. The average diameter of these missed tumours was 7.4 mm (3-19 mm). MGM was falsely negative in 58/344 (17%) patients (data were unavailable in 17 patients): no lesion was seen in 20 patients, distortion or calcification only in 38. US was falsely

negative in 30/355 (8.5%) patients (data were unavailable in 6 patients): no lesion was seen in 6 patients, tumour was not measurable in 21, a benign or unspecific lesion in 6.

When looking at ILC only (n=38), tumour was measurable on MRI in 92% of cases vs 61% on US. Under- or overestimation did not differ between MRI and US ($p>0.05$).

The result of paper IV show, that routine use of MRI breast cancer may be a double-edged sword. It identifies a relatively high number of patients with multifocal disease and patients with contralateral disease even though they are few. But on the other hand it over- or underestimates pathological tumour size in one tenth of patients with 10 mm or more. The main criticism of routine use of MRI in breast cancer has been overestimation of size and diagnosis of irrelevant multifocality in addition to cost.

Multifocal and contralateral disease

In paper IV, 51/438 patients (12%) had multifocal and 14/438 patients (3.2%) had contra-lateral disease on pathology. MRI demonstrated contralateral tumours in 13/14 (93%) patients, and exclusively in 7/14 (50%) patients. MGM and/or US showed multifocal disease in 19 patients (37%). MRI showed multifocality in 37/51 (73%) patients, giving 24 additional patients (47%). For patients in whom multifocal disease was correctly described by MRI (n=37) mastectomy was performed in 22 (59%) and breast conservation in 15 (41%). 4 of the latter patients (27%) had mastectomies due to inadequate margins. The end mastectomy rate was therefore 70% (26/37) in these patients.

MRI suggested multifocal disease in 28/361 patients having unifocal disease on pathology, i.e., a falsely positive rate of 7.8%. The mastectomy rate in these cases was 57%. Ultrasound erroneously showed multifocal disease in 15/340 patients (4.4%).

Diagnosis of multifocal disease is important and almost half of the cases in our study were diagnosed with MRI alone (43%). Early diagnosis can diminish reoperation rate as two thirds of the patients diagnosed in our study were operated with mastectomy.

For diagnosis of contralateral disease we feel that MRI is an important tool. In screening only MGM is most often used and in dense breast tissue we know that the sensitivity of diagnosis is lower and in general 10-15% of cancers are not seen on MGM (Hlawatsch *et al.* 2002). MRI on patients with diagnosed unilateral breast cancer could aid in the diagnosis of contralateral disease.

MRI - a routine radiological method in breast cancer?

The result of paper IV shows both benefits and disadvantages of routine MRI in the diagnostic process of breast cancer. What we have not been able to reveal is the sensitivity and specificity in our material as it is a retrospective study. MRI, like US, both under- and overestimated size of invasive cancer. It is well known that MRI diagnoses additional foci of cancer and benign nodules that are occult on conventional imaging (Houssami & Hayes. 2009). This may lead to biopsies, which in benign nodules do not effect the operation planned for the patient but adds to discomfort and worries of the patient (Berg *et al.* 2004). It has not been demonstrated that the diagnosis of occult cancer changes the prognosis of the patient. There is no significant difference in recurrent disease between patients operated with mastectomy and patients operated with sector resection followed by radiotherapy. It is known that sector resection leaves tumour foci in some patients, which are treated with radiotherapy. MRI diagnoses at least some of these foci, which can lead to a larger operation, with uncertain effect on the prognosis. This has to be considered in studies with long follow up time. One would expect a decrease in reoperation frequency for patients undergoing preoperative MRI but this has not been shown (Turnbull *et al.* 2010).

MRI should be used in certain patients groups, such as women with dense breast tissue, where MGM is known to fail in the diagnosis of cancer (Berg *et al.* 2004). MRI should also be used in pregnant women and in women with an increased risk of breast cancer (Pediconi *et al.* 2012). The use of MRI in the diagnosis of contralateral disease is also of importance. Routine use of MRI in lobular cancer (ILC) has been suggested (Gümüş *et al.* 2012) and a part of that is that ILC more often has a contralateral cancer at the time of diagnosis. In our study MRI diagnosed contralateral disease exclusively in 50% of patients. Ten patients had bilateral IDC (71%), one had bilateral ILC (7%), and three, 22% two types of cancer. It is important that the contralateral breast is screened with another radiological method than MGM, if normal, at the time of diagnosis. It is unclear if this should be done with US or MRI taking into account additional biopsy rate and cost. Paper IV suggests that MRI is better than US in diagnosing contralateral disease. This is the only finding in our study that favors routine use of preoperative MRI.

CONCLUSIONS

1. Small breast cancers could be eradicated with ILT, but the method needs further refinement if it is going to be used for radical treatment in the everyday clinical setting.
2. Ultrasound underestimated tumour size before ILT. Improved radiological methods are needed to accurately place laser fibers and monitor treatment.
3. ILT induced changes in immunocompetent cells in patients with breast cancer. Changes known to have favorable prognostic value were seen but further work will help to clarify the role of ILT in breast cancer therapy.
4. ILT was a safe method both in the short- and long-term perspectives. The immune stimulation is a promising feature of ILT but demonstration of its possible clinical significance awaits improvements in technique and, especially, evaluation in a large patient population.
5. MRI and US both under- and overestimated tumour size.
6. MRI may become a valuable method in the diagnosis of contralateral and multifocal disease.

FUTURE PERSPECTIVES

Radiology is evolving fast. Radiological methods with contrast media, three dimensional images and reconstruction are evolving and can be used in patients diagnosed with cancer when planning an operation or other therapy. Radiology has been a limiting factor in local ablation therapy as the major concern is non-radical treatment. This will change with better resolution and the diagnosis of smaller tumour foci and when tumour left untreated is seen with real time monitoring and treated in the same session. Radiology will also aid in follow up after local ablation in the absence of pathological evaluation when operation is not done.

In breast cancer as well as other cancer forms a local therapy like ILT may become an important factor in neoadjuvant treatment because of the immunological effect known to occur. In higher stages of tumour, prognosis is poorer and additional immunomodulation may be an important factor in influencing that. Here more studies are needed.

In tumours immunosuppressive factors are found in the microenvironment of tumours, including T_{regs} and MDSCs as well as M2 polarized macrophages previously described. It is known that the cytokines found in the microenvironment (not discussed in this thesis) can change the polarization of cells and can cause changes towards acute inflammation and effective immune response known to have positive effects on prognosis. Another factor to change are the escape mechanisms of tumours, which down regulate factors that trigger an immunological response. It would also be helpful to find means to express tumour-specific antigens to overcome the fact that most tumour antigens are self-antigens and not tumour specific, meaning that they do not trigger a specific immunological response. Much is known about the microenvironment of tumours and results of studies have resulted in the use of specific drugs that affect immune pathways, like drugs that block immune checkpoints. More such drugs will

be used in the future in tailored treatment decided in multidisciplinary meetings held for each patient diagnosed with cancer.

Cancer therapy is evolving more towards minimally invasive techniques. Laparoscopic and robotic surgery are increasingly used as well as minimally invasive methods. A technique like ILT that has both the potential of radical treatment and immunostimulation may become an important factor in cancer therapy both for radical treatment and in neoadjuvant treatment. Studies need to be performed, but the future is usually closer than we think.

POPULÄRVETENSKAPLIG SAMMANFATTNING

Bröstcancer är den vanligaste cancerformen hos kvinnor. I Sverige diagnostiseras över 8000 nya fall årligen. Standardbehandling är kirurgi för lokaliserad sjukdom men andra lokala behandlingar, som oftast är behandlingar som ger lokal värme, har använts i botande eller lindrande syfte. En av dessa behandlingar är lasermedierad värmebehandling, kallad Interstitial Laser Thermotherapy (ILT). Liksom andra icke-kirurgiska behandlingar är ILT mindre påfrestande för patienten än kirurgi och har en förhållandevis liten risk för komplikationer. Vår grupp har visat att ILT skiljer sig från andra metoder genom att hos experimentdjur kunna framkalla ett immunologiskt försvar mot tumör med förlängd överlevnad som följd. Denna avhandling handlar om ILT-behandling av bröstcancer och om immunologiskt svar vid behandlingen.

I *delarbete I* behandlades 24 kvinnor med ILT. Före behandling genomgick patienterna mammografi, ultraljudsundersökning samt mellannålsbiopsi för beskrivning av tumörens egenskaper. Tumörerna skulle vara relativt små och synas på ultraljud. Patienterna behandlades på mottagningen i lokalbedövning. Laserfibrerna placerades oftast ultraljudslett. Temperaturen vid tumörkanten hölls konstant vid 48°C under 30 minuter. Patienterna opererades cirka 2 veckor efter ILT.

Patienterna hade inga stora besvär under eller efter ILT-behandlingen: 3 patienter hade ont under behandlingen och 5 patienter hade ömhet i bröstet efter ILT. Tre patienter blev radikalt behandlade. I medeltal lyckades behandlingen direkt döda endast 1/3 av tumören. En viktig orsak till detta var att ultraljudsundersökningen ofta avsevärt underskattade tumörstorleken.

Konklusionen av detta arbete var att små bröstcancrar kan behandlas radikalt med ILT och att metoden behöver utvecklas. Man kan t ex uppnå bättre resultat genom att förbättra det fiberavslut som släpper ut laserljuset

och, särskilt, genom att förbättra röntgenundersökningens förmåga att beskriva tumörens storlek och utbredning.

I *delarbete II* inkluderades de 17 patienter i föregående studie som inte blev radikalt behandlade och som hade tumörcellsdöd 1-98%. Dessutom undersöktes 6 patienter som enbart genomgick kirurgi för bröstcancer.

Vi fann att ILT ökade antalet tumörcellsdödande T lymfocyter i tumören och antalet antigen-presenterande dendritiska celler i tumörkanten.

Förekomst av tumörceller i regional lymfkörtel påverkade förekomsten av alla immunokompetenta celler utom s.k. regulatoriska T lymfocyter, som har en hämmande inverkan på kroppens immunförsvar mot cancer. Jämförelser mellan ILT- och kontrollpatienter gjordes därför enbart hos patienter utan lymfkörtelmetastaser. Hos dessa patienter var antalet regulatoriska T lymfocyter lägre hos patienter som behandlats med ILT.

Konklusionen av detta arbete var att ILT påverkar antalet immunokompetenta celler hos patienter med bröstcancer. Ökat antal celldödande T lymfocyter, ökat antal antigen-presenterande dendritiska celler samt minskat antal T-regulatoriska celler anses vara positiva prognostiska faktorer vid cancer. ILT kan således bli en del i behandlingen av bröstcancer även när ILT inte är lokalt radikal.

Delarbete III inriktades på uppföljning av de 24 laserbehandlade patienterna 6-10 år efter behandlingen. Ingen av patienterna fick återfall på behandlingsplatsen. Tre patienter har avlidit av sin bröstcancersjukdom genom att den gett dottersvulster (metastaser).

Hos patienter med återfall i bröstcancersjukdomen var antalet tumörcellsdödande T lymfocyter högre både före och efter ILT än hos patienter utan återfall. Antalet av NK celler, en annan immunokompetent lymfocyt, i lymfkörtlar var lägre hos patienter med återfall än hos patienter utan återfall.

Konklusionen av detta arbete var att antalet patienter var för litet för att kunna ge svar på hypotesen att de immunologiska effekterna av ILT förbättrar prognosen.

I *delarbete IV* var syftet att undersöka om magnetröntgen (magnetic resonance imaging, MRI) är bättre än ultraljud och mammografi för att bedöma tumörstorlek.

Undersökningen gjordes i Island där man har använt MRI rutinmässigt under senare år. År 2007-2009 genomgick 438 kvinnor med bröstcancer MRI jämte mammografi och ultraljud.

Vi fann att MRI både under- och överskattade tumörstorleken. Uppskattningen av tumörstorlek var osäker för samtliga röntgenundersökningar; detta var speciellt uttalat för stora tumörer där undersökningarna ofta underskattade tumörstorleken. MRI kunde påvisa mer än en tumör hos 51 patienter. Å andra sidan angav MRI felaktigt förekomsten av mer än en tumör hos 28 patienter.

Konklusionen av detta arbete var att MRI både under- och överskattar tumörstorlek och att rutinmässig användning av denna metod för att uppskatta tumörstorlek är av begränsat värde. Användningen av MRI för att diagnosticera fler tumörer än de som är synliga på mammografi eller ultraljud är också av begränsat värde.

ALMENN SAMANTEKT

Brjóstakrabbamein er algengasta tegund krabbameins hjá konum og í Svíþjóð greinast rúmlega 8000 (2012) ný tilfelli árlega. Fyrir sjúkdóm sem greinist, án fjarmeinvarpa, er hefðbundin meðferð skurðaðgerð. Eftir aðgerð eru þættir eins og hormónaviðtakar metnir og í samræmi við þá ásamt eitlameinvörpum er viðbótar meðferð (*adjuvant*) ákveðin.

Önnur meðferð eins og staðbundin hitameðferð á æxli hafa verið notaðar í líknandi og lækandi tilgangi. Þessi doktorsritgerð fjallar um lasermeðferð (ILT) á brjóstakrabbameini og þá staðbundnu ónæmissvörun sem verður við hana.

Í *rannsókn I* voru 24 konur með brjóstakrabbamein meðhöndlaðar með ILT fyrir skurðaðgerð. Konurnar voru ræddar á samráðsfundi og valdar til þátttöku. Fyrir ILT var gerð brjóstamyndataka (MGM), ómskoðun (US) og tekið grófnálarsýni, til greiningar og litana m.t.t. hormónaviðtaka. Æxlin þurftu að vera smá, þreifanleg og sjáanleg við US. Einum eða 4 laserþráðum var komið fyrir. US var notað til staðsetningar hjá 19 konum. Meðferðin fór fram á göngudeild í staðdeyfingu og var hitanum haldið í 48°C í 30 mínútur. Konurnar fóru í aðgerð að meðaltali 12 dögum (6-23) eftir ILT.

Meðferðin, sem gerð var á tímabilinu maí 2001 til febrúar 2005, þoldist vel og konurnar líktu eymslum eftir ILT við eymsli eftir grófnálarsýnatöku. Hjá tveimur konum varð lítilsháttar drep í húðinni yfir meðhöndlunarstað, en það svæði var síðar skorið burt í aðgerð. Þrjár konur voru með staðbundna verki og 5 konur voru með eymsli í brjóstinu eftir ILT. Hjá þremur konum fannst enginn lífvænlegur æxlisvefur við smásjárskoðun á skurðsýni. Meðal rúmmál dreps (metið skv formúlunni $V=ab^2/2$) var 33% (0-100). Mikilvægur orsakavaldur að þessu var að æxlin voru stærri við meinafræðirannsókn en á myndrannsóknnum fyrir aðgerð. Við smásjárskoðun reyndust æxlin vera 7-55 mm (meðaltal 23) að stærð en samsvarandi tölur fyrir US voru 3-35 (14) mm.

Við ályktum að hægt er að meðhöndla lítil brjóstakrabbamein að fullu með ILT en að bæta þurfi þætti er snúa að framkvæmd hennar. Fyrst og fremst þarf að bæta mat myndrannsókna á stærð æxla fyrir meðferð og þar með tryggja betri staðsetningu á laserþráðum.

Í *rannsókn II* voru skoðaðar þær konur sem ekki voru meðhöndlaðar að fullu í rannsókn I, en höfðu rúmmál dreps á bilinu 1-98%. Að auki voru skoðaðar 6 konur sem einungis fóru í skurðaðgerð vegna brjóstakrabbameins en ekki ILT.

Borinn var saman fjöldi ónæmisfruma sem litaðar voru í grófnálarsýni og í aðgerðarsýni, bæði í æxli og æxlisjaðri. Niðurstöður sýndu aukningu á frumudrepandi T frumum (CD8⁺) og stórátfrumum (CD68⁺) í æxli eftir ILT miðað við grófnálarsýni ($p < 0.01$ fyrir báða frumuhópa). Í æxlisjaðri var fjöldi B fruma (CD20⁺), stórátfruma (CD68⁺) og þroskaðra griplufruma (CD83⁺) marktækt hærri eftir ILT en í grófnálarsýni ($p < 0.05$, $p < 0.001$, $p < 0.01$). Fjöldi fruma var bæði mismunandi milli einstakra sjúklinga og innan sama æxlis.

Í viðmiðunarhóp kom í ljós að CD8⁺ frumum fjölgaði í æxlinu eftir aðgerð ($p < 0.05$). Stórátfrumur voru fleiri í æxlinu eftir ILT en eftir eingöngu skurðaðgerð ($p < 0.05$). Bornar voru saman frumur úr eitlum án æxlisvaxtar hjá konum sem fengið höfðu ILT meðferð og hjá viðmiðunarhóp. Fjöldi T hjálparfruma með ónæmisbælandi verkun (CD25⁺Foxp3⁺) var lægri hjá ILT hóp miðað við viðmiðunarhóp ($p < 0.05$).

Við ályktum að ILT breyti samsetningu fruma ónæmiskerfisins í æxli og æxlisjaðri hjá konum með brjóstakrabbamein. Aukinn fjöldi þroskaðra griplufruma og fækkun í fjölda T hjálparfruma (T_{reg}) eru þættir sem eru þekktir af því að hafa jákvæð áhrif á horfur sjúklinga með krabbamein, þar með talið brjóstakrabbamein. ILT gæti verið hluti af meðferð fyrir skurðaðgerð (*neoadjuvant*) hjá sjúklingum með brjóstakrabbamein.

Í *rannsókn III* voru þær 24 konur sem meðhöndlaðir voru með ILT, í rannsókn I, skoðaðir m.t.t. staðbundinnar endurkomu krabbameinsins og fjarmeinvarpa. Engin kona fékk staðbundna endurkomu. Sex konur hafa

látist, þrjár af völdum fjarmeinvarpa en tvær af orsökum óháðum brjóstakrabbameininu.

Hjá þeim konum sem fengið höfðu endurkomu á sjúkdómi voru frumudrepandi T frumur ($CD8^+$) marktækt fleiri í æxli, fyrir og eftir ILT samanborið við þá sem ekki höfðu fengið endurkomu. NK frumur ($CD57^+$) voru marktækt fleiri í eitlum hjá konum sem ekki höfðu fengið endurkomu miðað við þá sem fengið höfðu endurkomu ($p < 0.05$). Einn af mikilvægustu áhættuþáttunum fyrir endurkomu æxlis voru jákvæðir eitlar við skurðaðgerð.

Við ályktum að stærð þýðis í rannsókninni er of lítið til að svara tilgátunni um að ónæmisfræðileg áhrif eftir ILT bæti horfur sjúklinga með brjóstakrabbamein.

Í *rannsókn IV* var markmiðið að athuga hvort segulómskoðun (MRI) af brjósti væri nákvæmari rannsókn á ífarandi brjóstakrabbameini en US og MGM.

Frá árinu 2007 fóru flestar konur sem greindust með brjóstakrabbamein á Íslandi í MRI af brjóstum. Á árunum 2007-2009 greindust 641 kona með brjóstakrabbamein á Íslandi og af þeim fóru 438 (68%) í MRI fyrir aðgerð, auk MGM og US. Tólf konur voru útilokaðar frá rannsókninni vegna krabbameinslyfjameðferðar fyrir aðgerð sem hefur áhrif á stærð æxlis. Þær 65 konur sem greindust með krabbamein í hinu brjóstinu eða fjöluppsprettukrabbamein (*multifocal cancer*) voru skoðaðar sérstaklega.

Rannsóknin sýndi að MRI van- og ofmat stærð krabbameinsins samanborið við niðurstöðu vefjagreiningar. Allar myndannsóknirnar voru ónákvæmar, sérstaklega hvað varðar stærri krabbamein og vanmátu stærð þessarra æsla. MRI van- og ofmat stærð æxlis um meira en 10 mm í 4.6% og 7.5% tilfella. Í þeim tilfellum sem MRI ofmat stærð krabbameins gengust 65% kvenna undir brottnám á brjósti samanborið við 43% af heildarhópnum.

Fjöluppsprettukrabbamein greindust hjá 51 konu og 14 konur voru með krabbamein í hinu brjóstinu. MRI sýndi fram á þetta í 93% og 73% tilfella.

Við ályktum að MRI bæði van- og ofmeti stærð krabbameina. MRI er gagnlegt í greiningu á fjöluppsprettukrabbameini og krabbameini í hinu brjóstinu.

ACKNOWLEDGEMENTS

I would like to express my sincere gratitude and appreciation to:

Professor Karl-Göran Tranberg my mentor and friend, who introduced me to his research group and the field of hyperthermia. Thank you for your invaluable guidance, encouraging words and for keeping me on track.

Professor Christian Ingvar my co-supervisor for discussions and guidance.

My co-authors in Lund, Unne Stenram, Karin Jansner and Kjell Ivarsson for collaboration and helping me in the world of laboratory. My co-authors in Reykjavík, Kristján Skúli Ásgeirsson and Þorvaldur Jónsson for good discussions and collaboration.

Monica Keidser for help and instructions over the Atlantic Ocean.

My friend and head of general surgery in Landspítali, Páll Helgi Möller for support and helping me with practical things in combining clinical work and research.

My ex-roomies and friends, Ellen Andersson and Pauline Djerf and my friends Christian Sturesson, Per Leveau and Bobby Tingstedt. Thank you all for great laughs, discussions and for being in my support team!

Margrét Agnarsdóttir, Elísabet Reykdal Jóhannesdóttir, Sólveig Hafsteinsdóttir my dear friends and supporters. Thank you for all the pep talk and always being willing to listen!

All friends and colleagues, at the Department of Surgery in Lund and Reykjavík, for support and making work a nice place to be. Special thanks to my team members at the HPB team in Lund and Upper GI surgery in Reykjavík.

Professor Jónas Magnússon and the late Margrét Oddsdóttir for introducing me to surgery.

My Icelandic family/colleagues in Sweden; Páll Hallgrímsson, Ester Sigursteinsdóttir, Helena Sveinsdóttir, Ólafur Guðmundsson, Anna Björk Jónsdóttir, Anna Gunnarsdóttir for good laughs and support.

My parents, for always supporting me and helping me getting my goals.

Last but not least my dear husband Hallgrímur, who has supported me the whole way and helped me a lot when I and the computer were no longer friends, and my children Hrafnkell Oddi, Líney Erla and Hákon Helgi. This was for you!

This work was supported by grants from the Swedish Cancer Society (project no. 3163-B01-09XBB), the Crafoord Foundation; Lund University Hospital; Lundgren Foundation, GAE Nilsson Foundation for Cancer Treatment, John and Augusta Persson Foundation for Scientific Medical Research, and the Royal Physiographic Society in Lund.

REFERENCES

- Abbas AK, Lichtman AH. Cellular and Molecular Immunology, fifth edition, 2003. Saunders. p 25-26.
- Albayrak ZK, Önay HK, Karatag GY, Karatag O. Invasive lobular carcinoma of the breast: mammographic and sonographic evaluation. *Diagn Interv Radiol* 2011; **17**: 232-238.
- Allavena P, Mantovani A. Immunology in the clinic review series; focus on cancer: tumour-associated macrophages: undisputed stars of the inflammatory tumour microenvironment. *Clinical and Experimental Immunology* 2012; **167**: 195-205.
- Andreu P, Johansson M, Affra NI, Pucci F, Tan T, Junankar S, Korets L, Lam J, Tawfik D, DeNardo DG, Naldini L, de Visser KE, De Palma M, Coussens LM. FcR γ activation regulates inflammation-associated squamous carcinogenesis. *Cancer Cell* 2010; **17**: 121-134.
- Arpino G, Bardou VJ, Clark GM, Elledge RM. Infiltrating lobular carcinoma of the breast: tumor characteristics and clinical outcome. *Breast cancer Res* 2004; **6**: R149-R156.
- Bell D, Chomarat P, Broyles D, Netto G, Harb GM, Lebecque S, Valladeau J, Davoust J, Palucka KA, Banchereau J. In breast carcinoma tissue, immature dendritic cells reside within the tumor, whereas mature dendritic cells are located in peritumoral areas. *J Exp Med* 1999; **190**: 1417-1426.
- Berg WA, Gutierrez L, NessAiver MS, Bradford Carter W, Bhargavan M, Lewis RS, Ioffe OB. Diagnostic accuracy of mammography, clinical examination, us, and MR imaging in preoperative assessment of breast cancer. *Radiology* 2004; **233**: 830-849.

Biswas SK, Mantovani A. Macrophage plasticity and interaction with lymphocyte subsets: cancer as a paradigm. *Nature Immunology* 2010; **11**: 889-896.

Bohling SD, Allison KH. Immunosuppressive regulatory T cells are associated with aggressive breast cancer phenotypes: a potential therapeutic target. *Modern Pathology* 2008; **21**: 1527-1532.

Bonatti H, Bodner G, Obrist P, Bechter O, Wetscher G, Oefner D. Skin implant metastasis after percutaneous radio-frequency therapy of liver metastasis of a colorectal carcinoma. *Am J Surg* 2003; **69**: 763-765.

Boyd NF, Guo H, Martin LJ, Sun L, Stone J, Fishell E, Jong RA, Hislop G, Chiarelli A, Minkin S, Yaffe MJ. Mammographic density and the risk and detection of breast cancer. *NEJM* 2007; **356**: 227-236.

Burak Jr WE, Agnese DM, Povoski SP, Yanssens TL, Bloom KJ, Wakely PE, Spigos DG. Radiofrequency ablation of invasive breast carcinoma followed by delayed surgical excision. *Cancer* 2003; **98**: 1369-1376.

Carlsson G, Gullberg B, Hafström L. Estimation of liver tumor volume using different formulas – an experimental study in rats. *J Cancer Res Clin Oncol* 1983; **105**: 20-23.

Carney PA, Miglioretti DL, Yankaskas BC, Kerlikowske K, Rosenberg R, Rutter CM, Geller BM, Abraham LA, Taplin SH, Dignan M, Cutter G, Ballard-Barbash R. Individual and combined effects of age, breast density, and hormone replacement therapy use on the accuracy of screening mammography. *Ann Intern Med* 2003; **138**: 168-175.

Chen HW, Lai ECH, Zhen ZJ, Cui WZ, Liao S, Lau WY. Ultrasound-guided percutaneous cryotherapy of hepatocellular carcinoma. *Int J Surg* 2011; **9**: 188-191.

Condeelis J, Pollard JW. Macrophages: obligate partners for tumor cell migration, invasion, and metastasis. *Cell* 2006; **124**: 263-266.

Coughlin CM, Vance BA, Grupp SA, Vonderheide RH. RNA-transfected CD40-activated B cells induce functional T-cell responses against viral and tumor antigen targets: implications for pediatric immunotherapy. *Blood* 2004; **103**: 2046-2054.

Dalberg K, Hellborg H, Wärnberg F. Paget's disease of the nipple in a population based cohort. *Breast Cancer Res treat* 2008; **111**: 313-319.

Dawood S. Triple-negative breast cancer - epidemiology and management options. *Drugs* 2010; **70**: 2247-2258.

Dowlatsahi K, Fan M, Gould VE, Bloom KJ, Ali A. Stereotactically guided laser therapy of occult breast tumors: work-in-progress report. *Arch Surg* 2000; **135**: 1345-1352.

Dowlatsahi K, Dieschbourg JJ, Bloom KJ. Laser therapy of breast cancer with 3-year follow-up. *Breast J* 2004; **10**: 240-243.

Ernst MF, Roukema JA, Coebergh JWW, Repelaer van Driel OJ, van Beek M, van der Sangen MJC, Voogd AC. Breast cancers found by screening: earlier detection, lower malignant potential or both? *Breast Cancer Res and Treat* 2002; **76**:19-25.

Finger PT. "Finger-tip" cryotherapy probes: treatment of squamous and melanocytic conjunctival neoplasia. *Br J Ophthalmol* 2005; **89**: 942-945.

Gabrilovich DI, Nagaraj S. Myeloid-derived suppressor cells as regulators of the immune system. *Nature rev immunol* 2009; **9**: 162-174.

Găzdaru D, Chilom C, Călin MA, Geantă C, Popescu A. Laser radiation propagation and heat transfer into cells and tissues. *Romanian J Biophys* 2008; **18**: 73-85.

Goldberg SN, Gazelle GS, Mueller PR. Thermal ablation therapy for focal malignancy: a unified approach to underlying principles, techniques, and diagnostic imaging guidance. *Am J Roentgenol* 2000; **174**: 323-331.

Golshan M, Fung BB, Wiley E, Wolfman J, Rademaker A, Morrow M. Prediction of breast cancer size by ultrasound, mammography and core biopsy. *Breast* 2004; **13**: 265-271.

Gooden MJM, de Bock GH, Leffers N, Daemen T, Nijman HW. The prognostic influence of tumour-infiltrating lymphocytes in cancer: a systematic review with meta-analysis. *Br J Cancer* 2011; **105**: 93-103.

Gough-Palmer AL, Gedroyc WMW. Laser ablation of hepatocellular carcinoma- a review. *World J Gastroenterol* 2008; **14**: 7170-7174.

Grayson M (2012) Editorial. *Nature Outlook* **485**: S49.

Greenberg S, Rugo H. Challenging clinical scenarios: treatment of patients with triple-negative or basal-like metastatic breast cancer. *Clin Breast Cancer* 2010; **10**: S20-S29.

Gulubova MV, Ananiev JR, Vlaykova TI, Yovchev Y, Tsoneva V, Manolova IM. Role of dendritic cells in progression and clinical outcome of colon cancer. *Int J Colorectal Dis* 2012; **27**: 159-169.

Gümüş H, Mills P, Jones S, Jones P, Fish D, Gümüş M, Devalia H, Sever A. Invasive lobular carcinoma: the concordance of pathologic tumor size with magnetic resonance imaging. *The Journal of Breast Health* 2012; **8**: 81-85.

Hall-Craggs MA, Vaidya JS. Minimally invasive therapy for the treatment of breast tumours. *Eur J Radiol* 2002; **42**: 52-57.

Harries SA, Amin Z, Smith MEF, Lees WR, Cooke J, Cook MG, Scurr JH, Kissin MW, Bown SG. Interstitial laser photocoagulation as a treatment for breast cancer. *Br J Surg* 1994; **81**: 1617-1619.

Heusinger K, Löhberg C, Lux MP, Papadopoulos T, Imhoff K, Schulz-Wendtland R, Beckmann MW, Fasching PA. Assessment of breast cancer tumor size depends on method, histopathology and tumor itself. *Breast Cancer Res and Treat* 2005; **94**: 17-23.

Hewitt PM, Zhao J, Akhter J, Morris DL. A comparative laboratory study of liquid nitrogen and argon gas cryosurgery systems. *Cryobiology* 1997; **35**: 303-308.

Hieken TJ, Harrison J, Herrero J, Velasco JM. Correlating sonography, mammography, and pathology in the assessment of breast cancer size. *Am J Surg* 2001; **182**: 351-354.

Hlawatsch A, Teifke A, Schmidt M, Thelen M. Preoperative assessment of breast cancer: sonography versus MR imaging *AJR* 2002; **179**: 1493-1501.

Hompes R, Fieuws S, Aerts R, Thijs M, Penninckx F, Topal B. Results of single-probe microwave ablation of metastatic liver cancer. *EJSO* 2010; **36**: 725-730.

Houssami N & Hayes DF. Review of preoperative magnetic resonance imaging (MRI) in breast cancer – should MRI be performed on all women with newly diagnosed, early stage breast cancer? *CA Cancer J Clin* 2009; **59**: 290-302.

Houssami N, Turner R, Morrow M. Preoperative magnetic resonance imaging in breast cancer- Meta-Analysis of surgical outcomes. *Ann Surg* 2013; **257**: 249-255.

Huston T, Simmons R. Ablative therapies for the treatment of malignant diseases of the breast. *Am J Surg* 2005; **189**: 694-701.

Ishigami S, Natsugoe S, Tokuda K, Nakajo A, Che X, Iwashige H, Aridome K, Hokita S, Aikou T. Prognostic value of intratumoral natural killer cells in gastric carcinoma. *Cancer* 2000; **88**: 577-583.

Ishigami S, Natsugoe S, Uenosono Y, Hata Y, Nakajo A, Miyazono F, Matsumoto M, Hokita S, Aikou T. Infiltration of antitumor immunocytes into the sentinel node in gastric cancer. *J Gastrointest Surg* 2003; **7**: 735-739.

Ivarsson K, Olsrud J, Stureson C, Möller P, Persson B, Tranberg K-G. Feedback interstitial diode laser (805 nm) thermotherapy system: ex vivo evaluation and mathematical modeling with one and four-fibers. *Laser Surg Med* 1998; **22**: 86-96.

Ivarsson K, Myllymaki L, Jansner K, Bruun A, Stenram U, Tranberg KG. Heat shock protein 70 (HSP=) after laser thermotherapy of an adenocarcinoma transplanted into rat liver. *Anticancer Res* 2003; **23**: 3703-3712.

Ivarsson K, Myllymaki L, Jansner K, Stenram U, Tranberg KG. Resistance to tumour challenge after tumour laser thermotherapy is associated with a cellular immune response. *Br J Cancer* 2005; **93**: 435-440.

Iwamoto M, Shinohara H, Miyamoto A, Okazawa M, Mabuchi H, Nohara T, Gon G, Toyoda M Tanigawa N. Prognostic value of tumor-infiltrating dendritic cells expressing CD83 in human breast carcinomas. *Int J Cancer* 2003; **104**: 92-97.

Janssens W, Carlier V, Wu B, VanderElst L, Jacquemin MG, Saint-Remy JMR. CD4+CD25+ T cells lyse antigen-presenting B cells by Fas-Fas ligand interaction in an epitope-specific manner. *J Immunol* 2003; **171**: 4604-4612.

Jaskolka JD, Asch MR, Kachura JR, Ho Cs, Ossip M, Wong F, Sherman M, Grant DR, Greig PD, Gallinger S. Needle tract seeding after radiofrequency ablation of hepatic tumors. *J Vasc Interv Radiol* 2005; **16**: 485- 491.

Kajitani K, Tanaka Y, Arihiro K, Kataoka T, Ohdan H. Mechanistic analysis of the antitumor efficacy of human natural killer cells against breast cancer cells. *Breast Cancer Res Treat* 2012; **134**: 139-155.

Khochenkov DA. Biology of dendritic cells. *Biochemistry (Moscow) supplement series A: membrane and cell biology* 2008; **2**: 296-311.

Koda M, Murawaki Y, Hirooka Y, Kitamoto M, Ono M, Sakaeda H, Joko K, Sato S, Tamaki K, Yamasaki T, Shibata H, Shimoe T, Matsuda T, Toshikuni K, Aikata H, Kobayashi Y, Tsutsui A. Complications of radiofrequency ablation for hepatocellular carcinoma in a multicentre study: an analysis of 16346 treated nodules in 13283 patients. *Hepatol Res* 2012; **42**: 1058-1064.

Kondratiev S, Sabo E, Yakirevich E, Lavie O, Resnick MB. Intratumoral CD8⁺ T lymphocytes as a prognostic factor of survival in endometrial carcinoma. *Clin Cancer Res* 2004; **10**: 4450-4456.

Kontani K, Sawai S, Hanaoka J, Tezuka N, Inoue S, Fujino S. Involvement of granzyme B and perforin in suppressing nodal metastasis of cancer cells in breast and lung cancers. *EJSO* 2001; **27**: 180-186.

Kuhl CK, Schrading S, Bieling HB, Wardelmann E, Leutner CC, Koenig RK, Kuhn W, Schild HH. MRI for diagnosis of pure ductal carcinoma in situ: a prospective observational study. *Lancet* 2007; **370**: 485-492.

Lepock JR. Cellular effects of hyperthermia: relevance to the minimum dose for thermal damage. *Int J Hyperthermia* 2003; **19**: 252-66.

Lewis CE, Pollard JW. Distinct role of macrophages in different tumor microenvironments. *Cancer Res* 2006; **66**: 605-612.

Li Z-s, Yao L, Liu Y-q, Ouyang T, Li J-f, Wang T-f, Fan Z-q, Fan T, Lin B-y, Xie Y-t. Breast cancer subtypes and survival in Chinese women with operable primary breast cancer. *Chin J Cancer Res* 2011; **23**(2): 134-139.

Li X-ru, Liu M, Zhang Y-j, Wang J-d, Zheng Y-q, Li J, Ma B, Song X. CK5/6, EGFR, Ki-67, cyclin D1, and nm23-H1 protein expressions as predictors of pathological complete response to neoadjuvant chemotherapy in triple-negative breast cancer patients. *Med Oncol* 2011; **28**: S129-S134.

Lindau D, Gielen P, Kroesen M, Wesseling P, Adema GJ. The immunosuppressive tumour network: myeloid-derived suppressor cells, regulatory T cells and natural killer T cells. *Immunology* 2012; **138**: 105-115.

Lord SJ, Rajotte RV, Korbitt GS, Bleackley RC. Granzyme B: a natural born killer. *Immunol Rev* 2003; **193**: 31-38.

Ma J, Liu L, Che G, Yu N, Dai F, You Z. The M1 form of tumor-associated macrophages in non-small cell lung cancer is positively associated with survival time. *BMC Cancer* 2010; **10**: 112.

Mahmoud SMA, Lee AHS, Paish EC, Macmillan RD, Ellis IO, Green AR. The prognostic significance of B lymphocytes in invasive carcinoma of the breast. *Breast Cancer Res Treat* 2012; **132**: 545-553.

Mahmoud SMA, Paish EC, Powe DG, Macmillan RD, Lee AHS, Ellis IO, Green AR. An evaluation of the clinical significance of FOXP3⁺ infiltrating cells in human breast cancer. *Breast Cancer Res Treat* 2011; **127**: 99-108.

Mantovani A, Sozzani S, Locati M, Allavena P, Sica A. Macrophage polarization: tumor-associated macrophages as a paradigm for polarized M2 mononuclear phagocytes. *TRENDS in Immunology* 2002; **23**: 549-555.

Masuda T, Beppu T, Ishiko T, Horino K, Baba Y, Mizumoto T, Hayashi H, Okabe H, Horlad H, Dor K, Okabe K, Takamori H, Hirota M, Iyama K-I, Baba H. Intrahepatic dissemination of hepatocellular carcinoma after local ablation therapy. *J Hepatobiliary Pancreat Surg* 2008; **15**: 589-595.

Matkowski R, Gisterek I, Halon A, Lacko A, Szewczyk U, Pudelko M, Szynglarewicz B, Szelachowska J, Zolnierek A, Kornafel J. The prognostic role of tumor-infiltrating CD4 and CD8 T lymphocytes in breast cancer. *Anticancer Res* 2009; **29**: 2445-2452.

Menon AG, Fleuren GJ, Alphenaar EA, Jonges LE, Janssen van Rhijn CM, Ensink NG, Putter H, Tollenaar R, van de Velde C, Kuppen P. A basal membrane-like structure surrounding tumour nodules may prevent intraepithelial leucocyte infiltration in colorectal cancer. *Cancer Immunol Immunother* 2003; **52**: 121-126.

Miyagawa S, Soeda J, Takagi S, Miwa S, Ishikawa E, Noike T. Prognostic significance of mature dendritic cells and factors associated with their accumulation in metastatic liver tumors from colorectal cancer. *Hum Pathol* 2004; **35**: 1392-1396.

Moulon C, Péguet-Navarro J, Schmitt D. A potential role for CD1a molecules on human epidermal Langerhans cells in allogeneic T-cell activation. *J Investig dermatol* 1991; **97**: 524-528.

Möller PH, Lindberg L, Henriksson PH, Persson BR, Tranberg KG. Temperature control and light penetration in a feedback interstitial laser thermotherapy system. *Int J Hyperthermia* 1996; **12**: 49-63.

Nakamura R, Sakakibara M, Nagashima T, Sangai T, Arai M, Fujimori T, Takano S, Shida T, Nakatani Y, Miyazaki M. Accumulation of regulatory T cells in sentinel lymph nodes is a prognostic predictor in patients with node-negative breast cancer. *Eur J Cancer* 2009; **45**: 2123-2131.

Nakano O, Sato M, Naito Y, Suzuki K, Orikasa S, Aizawa M, Suzuki Y, Shintaku I, Nagura H, Ohtani H. Proliferative activity of intratumoral CD8+ T-lymphocytes as a prognostic factor in human renal cell carcinoma: clinicopathologic demonstration of antitumor immunity. *Cancer Res* 2001; **61**: 5132-5136.

Nikfarjam M, Christophi C. Interstitial laser thermotherapy for liver tumours. *Br J Surg* 2003; **90**: 1033-47.

Nikfarjam M, Muralidharan V, Christophi C (2005) Mechanisms of focal heat destruction of liver tumors. *JSR* 127: 208-23.

Nikfarjam M, Muralidharan V, Malcontenti-Wilson C, Christophi C. Progressive microvascular injury in liver and colorectal liver metastases following laser induced focal hyperthermia therapy. *Lasers Surg Med* 2005; **37**: 64-73.

Ohtani H, Naito Y, Saito K, Nagura H. Expression of costimulatory molecules B7-1 and B7-2 by macrophages along invasive margin of colon cancer: a possible antitumor immunity? *Lab Invest* 1997; **77**: 231-241.

Pagés F, Berger A, Camus M, Sanchez-Cabo F, Costes A, Molitor R, Mlecnik B, Kirilovsky A, Nilsson M, Damotte D, Meatchi T, Bruneval P, Cugnenc P-H, Trajanoski Z, Fridman W-H, Galon J. Effector memory T cells, early metastasis, and survival in colorectal cancer. *N Engl J Med* 2005; **325**: 2654-2666.

Pala EE, Bayol Ü, Cumurcu S, Keskin E. Immunohistochemical characteristics of triple negative/basal-like breast cancer. *Türk Patoloji Derg* 2012; **28**: 238-244.

Pediconi F, Miglio E, Telesca M, Luciani ML, Kirchin MA, Passeriello R, Catalano C. Effect of preoperative breast magnetic resonance imaging on surgical decision making and cancer recurrence rates. *Investig Radiol* 2012; **47**: 128-135.

Pfleiderer S, Marx C, Camara O, Gajda M, Kaiser WA. Ultrasound-guided, percutaneous cryotherapy of small (<15mm) breast cancers. *Investigative Radiology* 2005; **40**: 472-477.

Piersma SJ, Jordanova ES, van Poelgeest MI, Kwappenberg KM, van der Hulst JM, Drijfhout JW, Melief CJ, Kenter GG, Fleuren GJ, Offringa R, van der Burg SH. High number of intraepithelial CD8+ tumor-infiltrating lymphocytes is associated with the absence of lymph node metastases in patients with large early-stage cervical cancer. *Cancer Res* 2007; **67**: 354-361.

Qualls JE, Murray PJ. Tumor macrophages: protective and pathogenic roles in cancer development. *Current Topics in Developmental Biology* 2011; **94**: 309-328.

Sabel M, Kaufman C, Whitworth P, Chang H, Stocks L, Simmons R, Schultz M. Cryoablation of early-stage breast cancer: work-in-progress report of a multi-institutional trial. *Ann Surg Oncol* 2004; **11**: 542-9.

Sato E, Olson SH, Ahn J, Bundy B, Nishikawa H, Qian F, Jungbluth AA, Frosina D, Gnjjatic S, Ambrosone C, Kepner J, Odunsi T, Ritter G, Lele S, Chen Y-T, Ohtani H, Old LJ, Odunsi K. Intraepithelial CD8+ tumor-infiltrating lymphocytes and a high CD8+/regulatory T cell ratio are associated with favorable prognosis in ovarian cancer. *PNAS* 2005; **102**: 18538-18543.

Sell K, Barth PJ, Moll R, Thomas MA, Zimmer N, Oplesch E, Gudo M, Schrader M, Hofmann R, Schrader AJ. Localization of Foxp3-positive cells in renal cell carcinoma. *Tumor Biol* 2012; **33**: 507-513.

Simon CJ, Dupuy DE, Mayo-Smith WW. Microwave ablation: principles and applications. *RadioGraphics* 2005; **25**: S69-S83.

Snelling JD, Abdullah N, Brown G, King DM, Moskovic E, Gui GPH. Measurement of tumor size in case selection for breast cancer therapy by clinical assessment and ultrasound. *EJSO* 2004; **30**: 5-9.

Sugita J, Ohtani H, Mizoi T, Saito K, Shiiba K, Sasaki I, Matsuno S, Yagita H, Miyazawa M, Nagura H. Close association between Fas ligand (FasL; CD95L)-positive tumor-associated macrophages and apoptotic cancer cells along invasive margin of colorectal carcinoma: a proposal on tumor-host interactions. *Jpn J Cancer Res* 2002; **93**: 320-328.

Tabar L, Fagerberg G, Day NE, Duffy SW, Kitchin RM. Breast cancer treatment and natural history: new insights from results of screening. *Lancet* 1992; **339**:412-14.

Tranberg K-G. Percutaneous ablation of liver tumours. *Best Practice & Research Clinical Gastroenterology* 2004; **18**: 125-45.

Tranberg K-G, Ivarsson K, Willner J, Håkansson L, Stenram U. Induction of a distant anti-tumour effect by interstitial laser thermotherapy (ILT) in a patient with malignant melanoma. *2nd international conference on tumor microenvironment: progression, therapy and prevention*. Baden, Austria: 2002, p. 49.

Tsuge T, Yamakawa M, Tsukamoto. Infiltrating dendritic/Langerhans cells in primary breast cancer. *Breast Cancer Research and Treatment* 2000; **59**: 141-152.

Turnbull L, Brown S, Harvey I, Olivier C, Drew P, Napp V, Hanby A, Brown J. Comparative effectiveness of MRI in breast cancer (COMICE) trial: a randomised controlled trial. *Lancet* 2010; **375**: 563-571.

Urgas S, Simmons R. Cryotherapy ablation of primary breast cancer. *Breast Diseases: A Year Book Quarterly* 2010; **21**: 20-2.

van Esser S, Veldhuis WB, van Hillegersberg R, van Diest PJ, Stapper G, Elouamari M, Borel Rinkes IH, Mali WP, van den Bosch MA. Accuracy of contrast-enhanced breast ultrasound for pre-operative tumor size assessment in patients diagnosed with invasive ductal carcinoma of the breast. *Cancer Imaging* 2007; **7**: 63-68.

Vargas HI, Dooley WC, Gardner RA, Gonzales KD, Venegas R, Heywang-Kobrunner SH, Fenn AJ. Focused microwave phased array thermotherapy for ablation of early-stage breast cancer: results of thermal dose escalation. *Ann Surg Onc* **2004**; **11**: 139-146.

Vivier E, Tomasello E, Baratin M, Walzer T, Ugolini S. Functions of natural killer cells. *Nature Immunol* 2008; **9**: 503-510.

Weber JJ, Bellin LS, Milbourn DE, Verbanac KM, Wong JH. Selective preoperative magnetic resonance imaging in women with breast cancer. *Arch Surg* 2012; **147**: 834-839.

Wu F, Wang Z, Cao Y, Chen W, Bai J, Zou J, Zhu H. A randomised clinical trial of high-intensity focused ultrasound ablation for the treatment of patients with localised breast cancer. *Br J Cancer* 2003; **89**: 2227-33.

Wyckoff J, Wang Y, Lin E, Li J-F, Goswami S, Stanley E, Segall J, Pollard J, Condeelis J. Direct visualization of macrophage-assisted tumor cell intravasation in mammary tumors. *Cancer Res* 2007; **67**: 2649-56.

Yakamauchi Y, Izumi Y, Hashimoto K, Inoue M, Nakatsuka S, Kawamura M, Nomori H. Needle-tract seeding after percutaneous cryoablation for lung metastasis of colorectal cancer. *Ann Thorac Surg* 2011; **92**: e69-71.

ORIGINAL ARTICLES
