



LUND UNIVERSITY

Scaphoid Fractures - epidemiology, diagnosis and treatment.

Jörgsholm, Peter

2015

[Link to publication](#)

Citation for published version (APA):

Jörgsholm, P. (2015). *Scaphoid Fractures - epidemiology, diagnosis and treatment*. [Doctoral Thesis (compilation), Hand Surgery, Malmö]. Hand Surgery Research Group.

Total number of authors:

1

General rights

Unless other specific re-use rights are stated the following general rights apply:

Copyright and moral rights for the publications made accessible in the public portal are retained by the authors and/or other copyright owners and it is a condition of accessing publications that users recognise and abide by the legal requirements associated with these rights.

- Users may download and print one copy of any publication from the public portal for the purpose of private study or research.
- You may not further distribute the material or use it for any profit-making activity or commercial gain
- You may freely distribute the URL identifying the publication in the public portal

Read more about Creative commons licenses: <https://creativecommons.org/licenses/>

Take down policy

If you believe that this document breaches copyright please contact us providing details, and we will remove access to the work immediately and investigate your claim.

LUND UNIVERSITY

PO Box 117
221 00 Lund
+46 46-222 00 00

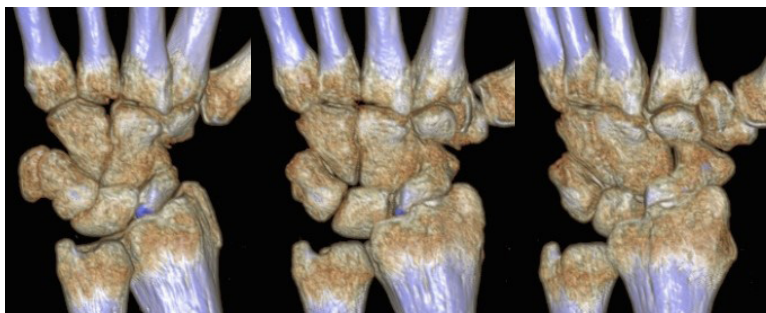


Scaphoid Fractures

Epidemiology, diagnosis and treatment

PETER JØRGSHOLM

DEPARTMENT OF HAND SURGERY | SKÅNE UNIVERSITY HOSPITAL | MALMÖ
CLINICAL SCIENCE | FACULTY OF MEDICINE | LUND UNIVERSITY 2015



Scaphoid Fractures

The scaphoid is the most commonly fractured carpal bone. The diagnosis is difficult and untreated the long-term results are poor. Approximately 10% do not unite even if they are treated properly.

All scaphoid fractures attending the Emergency Department in Malmö were investigated during a four-year period, and we aimed to find the best way to diagnose and treat these patients. We found that MRI is superior in diagnosing scaphoid fractures and often shows other simultaneous carpal fractures. Scaphoid fractures frequently had serious ligament injuries, and by using arthroscopy, we could see that these injuries often were unstable. Even radiographic comminuted fractures were unstable as seen by arthroscopy. Fracture stability may be of importance for scaphoid fracture union. We used CT to compare surgical treatment with conservative treatment and no difference in time-to-union was found.

In conclusion scaphoid fractures are more complex than they appear on plain radiographs. When using MRI, CT and arthroscopy a wide variety of fracture patterns will appear that warrant a dedicated treatment program – ranging from simple plaster treatment to advanced arthroscopy-assisted fracture surgery. The majority of undisplaced waist fractures will unite with six weeks in a cast. Generally surgical treatment will have a faster recovery with the inherent risk of complications.



Scaphoid Fractures

Epidemiology, diagnosis and treatment

Peter Jørgsholm



LUND
UNIVERSITY

DOCTORAL DISSERTATION

By permission of the Faculty Medicine, Lund University, Sweden.

To be defended at Lilla Aulan, Medicinsk Forskningscentrum,

Skåne University Hospital, Malmö

Friday Jan 23, 2015 at 1.00 pm

Faculty opponent

Professor Leiv M. Hove

University of Bergen, Norway

Organization: LUND UNIVERSITY Department of Hand Surgery Clinical sciences, Malmö Skåne University Hospital, SE-205 02 Malmö Author(s) Peter Jørgsholm	Document name DOCTORAL DISSERTATION Date of issue 2015-01-23 Sponsoring organization	
Title and subtitle: Scaphoid Fractures - epidemiology, diagnosis and treatment		
<p>Abstract The scaphoid is the most commonly fractured carpal bone. The diagnosis is difficult and untreated the long-term results are poor. Approximately 10% do not unite even if they are treated properly. The aim of this thesis was to study scaphoid fracture epidemiology, diagnosis and treatment. During a four-year period (2004-03-01 to 2008-02-28) all patients attending the Emergency Department at Skåne University Hospital in Malmö, due to posttraumatic radial sided wrist pain, were invited to participate in a scaphoid fracture study. The basis for this thesis consists of the 526 patients (531 wrists) who accepted to participate. First we assessed the diagnostic performance of radiographs and CT with MRI as the reference standard. In paediatric patients (<18 years) fracture patterns were studied in relation to skeletal maturity. Using arthroscopy we aimed at identifying factors, which could contribute to prolonged union or non-union of scaphoid fractures. Finally, we evaluated time-to-union of scaphoid waist fractures treated conservatively or by arthroscopy-assisted surgery. In the two diagnostic studies on adults and paediatric patients (paper I-II) 390 wrists were enrolled for MRI investigation. We were able to show that radiographs and CT scans are less sensitive in diagnosing carpal fractures compared to MRI. In particular radiographs in paediatric patients had a poor sensitivity when diagnosing carpal fractures; however, CT had a good sensitivity in finding scaphoid fractures regardless of patient age. We found more concomitant fractures than previously described, and the most common carpal fracture combination was that of the scaphoid and the capitate. Skeletal immature patients had a higher proportion of distal scaphoid fractures compared to the skeletal mature. In the descriptive study using arthroscopy (paper III) 41 scaphoid waist fractures were included. We found, that scapholunate ligament injuries were common with a complete rupture in 24% of the patients. Paper IV is a joint venture with Harvard Medical School, Boston, USA. In 58 scaphoid fractures we were able to show, that radiographic fracture comminution was strongly correlated to displacement and instability as judged by arthroscopy. Scapholunate ligament injuries and fracture comminution may be of importance when deciding on treatment of scaphoid fractures. Time-to-union based on CT was assessed in 65 scaphoid waist fractures in paper V. Of the non- or minimally-displaced fractures 90% united after six weeks of conservative treatment. In a randomized subgroup of non-displaced fractures we were not able to show any difference in time-to-union between conservatively and surgically treated patients. The present thesis shows, that MRI is superior in diagnosing carpal fractures in adults and children. Furthermore we found, that concomitant carpal fractures and ligament injuries are common in patients with scaphoid fractures. Radial fracture comminution is strongly correlated to fracture instability. Finally we recognized, that non- or minimally-displaced scaphoid waist fractures are best treated in a cast.</p>		
Key words: Scaphoid fracture, carpal fracture, paediatric, radiography, CT, MRI, arthroscopy, scapholunate ligament injury, radial comminution, surgical treatment, conservative treatment, fracture union		
Classification system and/or index terms (if any)		
Supplementary bibliographical information		Language English
ISSN and key title 1652-8220		ISBN 978-91-7619-086-9
Recipient's notes	Number of pages	Price
	Security classification	

I, the undersigned, being the copyright owner of the abstract of the above-mentioned dissertation, hereby grant to all reference sources permission to publish and disseminate the abstract of the above-mentioned dissertation.

Signature



Date

2014-12-12

Scaphoid Fractures

Epidemiology, diagnosis and treatment

Peter Jørgsholm



LUND
UNIVERSITY

Cover lay-out Trine Struve/Geir Haukursson/Jonas Palm/Peter Jørgsholm

Front cover: Three-dimensional CT reconstruction of left hand in a 18-years-old male patient (blue-collar worker) who during a mountain bike accident sustained a transunate arc injury: comminuted unstable transverse scaphoid waist fracture, volar chip fracture in the lunate and a stable transverse fracture in triquetrum (volar view). None of the fractures were seen on initial radiographs.

Back cover: Three views of same scaphoid fracture treated by arthroscopy-assisted screw fixation from dorsal. The tip of the screw is seen in the proximal pole of the scaphoid in the two left images (dorsal view). All fractures were united at 9 weeks.

All reprints of illustrations were granted from the publishers.

Copyright©Peter Jørgsholm

Department of Hand Surgery
Clinical Sciences, Malmö
Skåne University hospital
S-20055 02 Malmö
E-mail: peter.jorgsholm@med.lu.se

Lund University, Faculty of Medicine
Doctoral Dissertation Series 2015:6
ISSN 1652-8220
ISBN 978-91-7619-086-9 (print)
ISBN 978-91-7619-999-2 (PDF)

Printed in Sweden by Media-Tryck, Lund University
Lund 2014



FÖRPACKNINGSS
& TIDNINGSS
INSÄMLINGEN

KLIMATKOMPENSERAT
PAPPER



Contents

List of papers	7
Abbreviations	9
Thesis at a glance	11
Introduction	15
Background	17
Anatomy	17
Osseous anatomy	17
Developmental anatomy	18
Surface anatomy	18
Vascular anatomy	19
Ligamentous anatomy	20
Biomechanics	22
Clinically anatomy	23
Pathomechanism	24
Epidemiology	25
Diagnosis	28
Clinical diagnosis	28
Plain radiography	30
Tomosynthesis	31
Computed tomography	32
Bone scan	33
SPECT/CT	34
Ultrasound	35
Magnetic resonance imaging	35
Arthrography	36
Treatment	37
Conservative treatment	37
Operative treatment	40
Combined scaphoid injuries	44
Complications	46
Aim of Thesis	49

Patients	51
Paper I-II	52
Paper III	53
Paper IV	53
Paper V	53
Methods	55
Clinical examination	55
Radiologic examination	55
Arthroscopic surgery	57
Conservative treatment	59
Statistical analysis	59
Paper I-II	59
Paper III	59
Paper IV	60
Paper V	60
Results	61
Discussion	67
Radiology	67
Arthroscopy	71
Radiology and arthroscopy	72
Conservative and operative treatment	73
Strength and limitations	75
Clinical implications and future perspective	76
Conclusion	77
Summary in Swedish	79
Populärvetenskaplig sammanfattning	79
Summary in Danish	79
Populærvidenskabeligt resume	81
Acknowledgement	83
Appendix 1	85
Appendix 2	89
Appendix 3 and 4	91
References	93

List of papers

This thesis is based on the following papers, which will be referred to by their Roman numerals:

- I **The Benefit of Magnetic Resonance Imaging for Patients With Posttraumatic Radial Wrist Tenderness.** Jørgsholm P, Thomsen NO, Besjakov J, Abrahamsson SO, Björkman A. J Hand Surg Am. 2013 Jan;38A(1):29-33.
- II **MRI findings in children and adolescents with clinical symptoms of a scaphoid fracture.** Jørgsholm P, Thomsen NO, Besjakov J, Abrahamsson SO, Björkman A. (Manuscript)
- III **The incidence of intrinsic and extrinsic ligament injuries in scaphoid waist fractures.** Jørgsholm P, Thomsen NO, Björkman A, Besjakov J, Abrahamsson SO. J Hand Surg Am. 2010 Mar;35(3):368-74.
- IV **Factors associated with arthroscopically determined scaphoid fracture displacement and instability.** Buijze GA, Jørgsholm P, Thomsen NO, Björkman A, Besjakov J, Ring D. J Hand Surg. Am. 2012;37(7):1405-10.
- V **Union of scaphoid waist fractures assessed by CT scan.** Clementson M, Jørgsholm P, Besjakov J, Björkman A, Thomsen N.O.B. (Accepted for publication in Journal of Wrist Surgery 2014-11-10)

Permission to reprint the articles has been granted from Elsevier.

Abbreviations

3D Three-Dimensional

ACR American College of Radiology

ASB Anatomical SnuffBox

BS Bone Scan

CI Confidence Interval

CSS Clinical Scaphoid Score

CT Computed Tomography

DIC Dorsal Inter Carpal

LCT Longitudinal Compression Thumb

LRL Long RadioLunate

MRI Magnetic Resonance Imaging

RSC RadioScaphoCapitate

RLT RadioLunoTriquetral

SPECT/CT Single Photon Emission Computed Tomography

SL ScaphoLunate

SLAC ScaphoLunate Advanced Collapse

SNAC Scaphoid Non-union Advanced Collapse

SC ScaphoCapitate

ST Scaphoid Tubercle

STT ScaphoTrapezioTrapezoid

Thesis at a glance

Paper I. The Benefit of Magnetic Resonance Imaging for Patients With Posttraumatic Radial Wrist Tenderness.

MRI in adults with clinically suspected scaphoid fracture reveals more fractures than radiographs and CT.

Aim: To describe fractures revealed by MRI in skeletally mature patients with posttraumatic radial wrist tenderness and to access the diagnostic value of radiographs and computed tomography (CT) with MRI as reference.

Patients: 296 consecutive adult patients with acute wrist trauma.

Methods: During a three-year period all patients older than 17 years presenting at the emergency department, Skåne University Hospital, Malmö with posttraumatic radial wrist tenderness less than 2 weeks after trauma were prospectively included. All patients had radiographs and MRI of the injured wrist. Patients diagnosed with a scaphoid fractures had a supplementary CT scan.

Conclusion: MRI showed a high incidence of scaphoid fractures in skeletal mature patients with posttraumatic radial wrist tenderness and demonstrated more fractures than radiographs and CT. A scaphoid fracture was the most common carpal fracture followed by a triquetral and capitate fracture. Many patients with a scaphoid fracture had other concomitant fractures.

Paper II. MRI findings in children and adolescents with clinical symptoms of a scaphoid fracture.

MRI in children and adolescents with clinically suspected scaphoid fracture reveals more fractures than radiographs and CT and skeletal immature patients have a different fracture pattern.

Aim: To describe fractures revealed by MRI in paediatric patients with posttraumatic radial wrist tenderness and to access the diagnostic value of radiographs and CT with MRI as reference.

Patients: 89 consecutive paediatric patients with acute wrist trauma.

Methods: During a three-year period all patients younger than 18 years presenting at the emergency department, Skåne University Hospital, Malmö with posttraumatic radial wrist tenderness less than 2 weeks after trauma were prospectively included. All

had radiographs and MRI of the injured wrist. Patients diagnosed with a scaphoid fractures had a supplementary CT scan.

Conclusion: MRI showed a high incidence of fractures in paediatric patients with posttraumatic radial wrist tenderness and demonstrated more fractures than radiographs and CT. A scaphoid fracture was the most common carpal fracture followed by capitate and triquetral fracture. Many patients with a scaphoid fracture had other concomitant fractures. The skeletal immature patients had a higher proportion of distal scaphoid fractures.

Paper III. The incidence of intrinsic and extrinsic ligament injuries in scaphoid waist fractures.

Arthroscopy reveals many scapholunate ligament injuries in scaphoid waist fractures.

Aim: To determine the incidence of associated intrinsic and extrinsic ligament injuries in patients with scaphoid waist fractures.

Patients: 40 consecutive patients with scaphoid waist fracture.

Methods: During a three-year period all patients diagnosed with a scaphoid waist fracture were prospectively asked to participate in a study focusing on associated ligament injuries. Radiographs, MRI, and CT confirmed diagnosis. All displaced fractures were offered arthroscopy-assisted screw fixation and non- and minimally-displaced fractures were randomized to cast treatment or arthroscopy-assisted screw fixation.

Conclusion: Arthroscopy demonstrated a high incidence of ligament injuries in scaphoid waist fractures. Complete scapholunate ligament injuries were found in 24% of waist fractures. At the same time many other ligament injuries were found. This emphasizes the need for careful assessment of intrinsic and extrinsic ligaments, particularly the scapholunate ligament, before deciding on treatment.

Paper IV. Factors associated with arthroscopically determined scaphoid fracture displacement and instability.

Comminuted scaphoid fractures are often displaced and unstable as seen by arthroscope.

Aim: To identify factors associated with arthroscopically diagnosed fracture displacement and instability.

Patients: 58 consecutive patients with scaphoid fracture.

Methods: During a three-year period 43 patients in Malmö and 15 patients in Boston, USA, with a diagnosed scaphoid fracture, were prospectively enrolled for arthroscopy-assisted screw fixation because of fracture displacement or patient/doctor preference or

as part of a randomized study. All patients had preoperative CT with reconstructions in planes defined by the long axis of the scaphoid.

Conclusion: Radiographic scaphoid comminution is associated with both displacement and instability as determined by arthroscopy.

Paper V. Union of scaphoid waist fractures assessed by CT scan.

Most non- and minimally-displaced waist scaphoid fractures are united after 6 weeks in a cast.

Aim: To assess union of scaphoid waist fractures based on CT scan at 6 weeks, and to compare time to union between conservative treatment and arthroscopy-assisted screw fixation.

Patients: 65 consecutive patients with scaphoid waist fracture.

Methods: During a four-year period all patients between 16 and 65 year of age presenting at the emergency department, Skåne University Hospital, Malmö with a diagnosed acute scaphoid waist fracture were prospectively asked to participate in studies focusing on scaphoid waist fractures. All displaced fractures were offered arthroscopic screw fixation and non- and minimally-displaced fractures were randomized to cast treatment or arthroscopy-assisted screw fixation. All patients had CT of the scaphoid initially and at 6 weeks and a subgroup of randomized patients at 10 weeks, 14 weeks, and 6 months and 12 months.

Conclusion: The majority of non- and minimally-displaced scaphoid waist fractures is sufficiently treated with 6 weeks in cast. Screw fixation does not reduce time to union, compared to conservative treatment. Radial comminution was not uncommon and related to prolonged time to union.

Introduction

The anatomic description ‘scaphoid’ is derived from the Greek *skaphe* which means ‘a dugout’ or ‘a small boat’. Indeed this important carpal bone is boat shaped and lies, acting like a rocker arm, between the proximal and distal row of the carpus. The evolutionary development of the wrist has been meticulously investigated during the last centuries [1-6]. The ability of our closest relatives - the gorilla and the chimpanzee - to ‘knuckle-walk’ has probably caused a fusion of the scaphoid and the os centrale, a carpal bone that was found in other hominids (orangutan)(Fig 1). A larger scaphoid supports the second metacarpal during knuckle-walking.

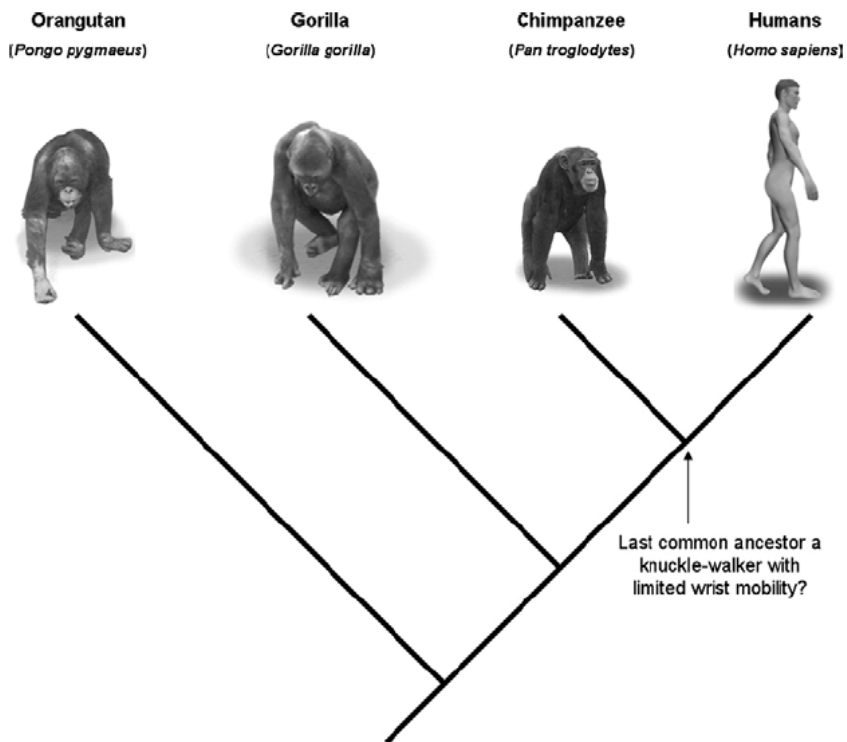


Figure 1.

A cladogram (diagram of biological classification) illustrating the evolutionary relationship between the great apes and human beings as supported by molecular genetics (Illustration from Wolfe et al. [7] permission granted from publisher).

This larger scaphoid created a solid base for the thumb, which, in the humans through evolution, became longer and provided a forceful power grip that is important in tool manufacturing [8]. The scaphoid plays an important role in dart thrower's motion, a combined flexion and ulnar deviation of the wrist for accelerating tools and weapons like in hammering and spear throwing [7]. The human wrist became both forceful and mobile, and the scaphoid bone is the keystone for understanding the evolution of manipulative abilities in the human hand and wrist (Fig 2).

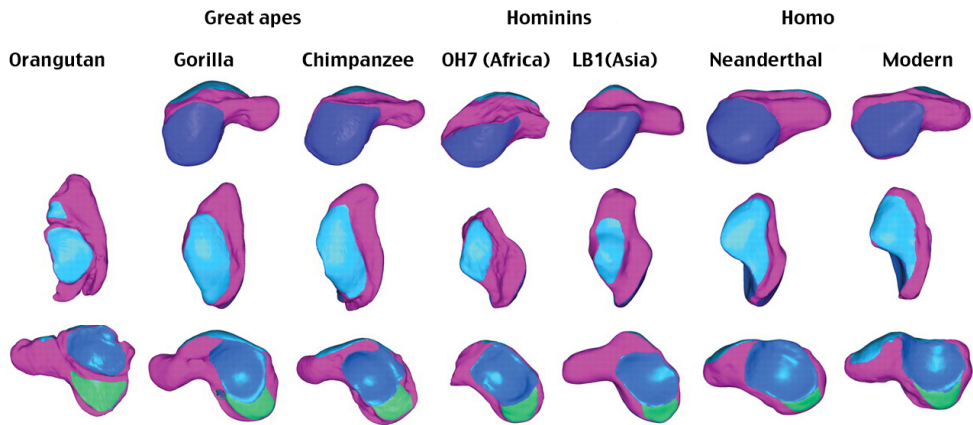


Figure 2: The evolution of the scaphoid bone.

The slightly different scaphoid in hominids - gorilla, chimpanzee, 2 extinct prehistoric hominins (OH7 African *Homo habilis*, LB1 Asian *Homo floresiensis*), a Neanderthal, and a modern man compared with the orangutan scaphoid (far left) with its unfused os centrale. The time span from OH7 to modern man is 1.7 million years (Illustration from Tocheri et al. [5] permission granted from publisher).

The human upright position endangered the scaphoid as most injuries occur through a fall on outstretched hand, which is common in daily life, in many work situations and sport activities. A fractured scaphoid, one of the smallest bones accounting for 2% of all fractures [9], often in young active persons, is infamous for the diagnostic challenge it presents and its tricky treatment.

Background

Anatomy

Osseous anatomy

The scaphoid lies radially in the wrist 45° to the long axis of the radius in both the anterior posterior and lateral planes. It has an average length of 29.3 mm in men and 24.8 mm in women, and is the third largest of the eight carpal bones [10]. The scaphoid has a complex anatomy (Fig. 3). It is bean or boat shaped but it is also twisted and not symmetrical in stem and stern. Furthermore, most of its surface is cartilage and it is articulating with five other bones: a proximal large convex articulation to the radius, two distal smaller slightly convex joint surfaces to the trapezium and the trapezoid, an ulnar large concave articulation towards the capitate, and an ulnar plane joint surface to the lunate.

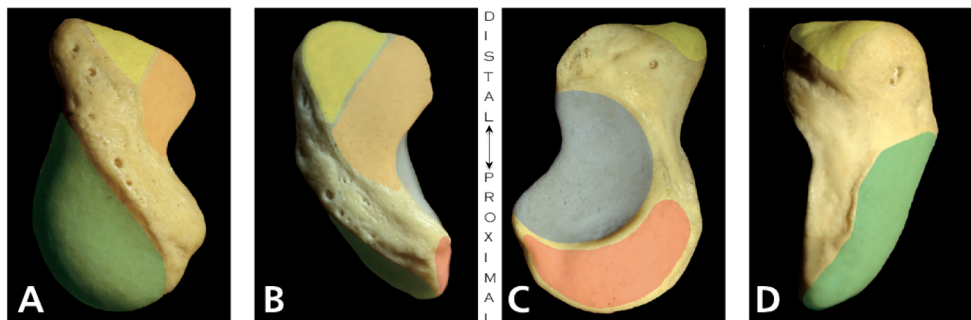


Figure 3: Morphology of the scaphoid bone.

Radial (A), dorsal (B), ulnar (C) and volar (D) views of the right scaphoid and its articular surfaces colour coded for contact with the distal radius (green), trapezium (yellow), trapezoid (orange), capitate (blue), and lunate (red). The bottom of each image represents proximal and the top represents distal. Note the vascular foramina in the regions of the radiodorsal ridge and the tubercle (Illustration from Buijze et al. [11] permission granted from publisher).

By using micro-computed tomography (micro-CT) Lee et al have shown that the scaphoid bone has a higher bone density in the proximal pole as the trabeculae are thicker and more tightly packed proximally in the scaphoid. The trabeculae are thinner and more sparsely distributed at the scaphoid waist, and this is where most fractures occur [12]. The trabeculae are arranged like spokes in a wheel centred towards the volar

supportive radioscaphocapitate ligament (RSC), around which the scaphoid has a rocking motion (Fig. 4).

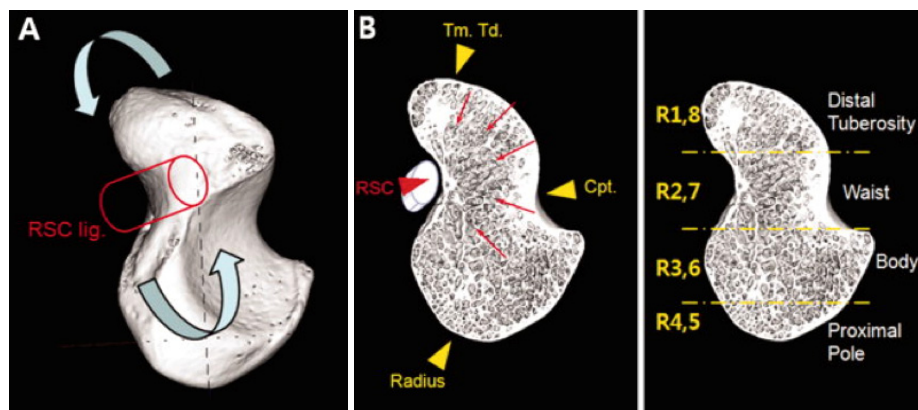


Figure 4: Architecture of the scaphoid bone.

(A) Schematic diagrams of the scaphoid's rocking motion and the correlated bone structure. Scaphoid has a 'rocking' motion that looks like a 'seesaw' motion. (B) The RSC ligament works like a fulcrum of the levers. The anisotropic trabecular bone structure spreads out like the spokes of a wheel (red arrows) and the point of contact with the RSC ligament as the hub (red index). Articulating regions indicated by yellow index have high values of bone mineral density and tissue mineral density (Tm. Trapezium; Td. Trapezoid; Cpt. capitate)(Illustration from Lee et al. [12] permission granted from publisher).

Developmental anatomy

The ossification of the scaphoid starts during the first decade of life, and a visible ossific nucleus is seen around 4-5 years in girls and 1 year later in boys. The ossification is completed around 13-14 years in girls and almost 2 years later in boys. Fractures in children under 6 years are very rare, probably because of the large amount of cartilage present in the immature scaphoid. This is thought to give a cushioning effect protecting the bone [13].

Surface anatomy

The distal pole is palpable volarly at the thenar eminence in extension, the waist radially in the snuffbox in ulnar deviation (Fig. 5), and the proximal pole dorsally between the third and fourth extensor compartment in flexion.

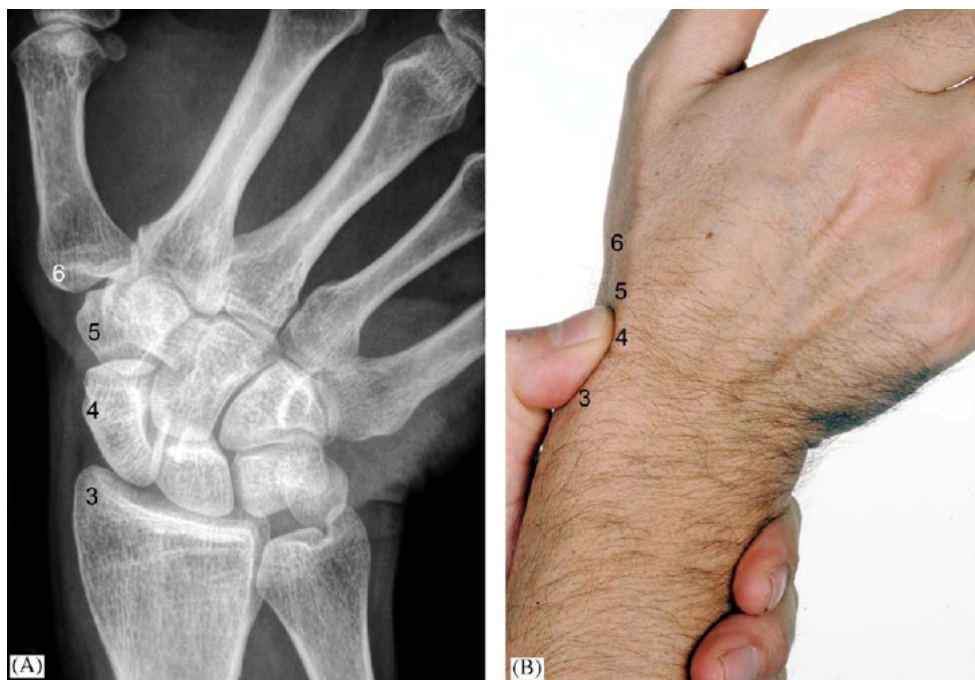


Figure 5: Anatomical landmarks around the scaphoid

(A) Radiograph of the wrist in ulnar deviation. (B) Photograph of the wrist in ulnar deviation. The landmarks are (3) the radial styloid, (4) waist of the scaphoid, (5) trapezium, and (6) base of the first metacarpal (Illustration from Reddy et al. [14] permission granted from publisher).

Vascular anatomy

The vascular supply to the scaphoid is delicate. The main vascular contribution comes from the radial artery. Extraosseous vessels enter the dorsal ridge of the scaphoid and supply two-thirds of the bone and the entire proximal pole through small intraosseous branches. Vessels entering through the tuberosity area supply the remaining distal one-third of the scaphoid. Some collateral circulation exists arising from branches of the anterior intraosseous artery [15]. The small vascular foraminae is well seen in Figure 3.

The vessels supplying the proximal pole enter through the dorsal ridge and have an intraosseous retrograde flow to the proximal pole. Owing to the anatomical organization of these vessels the proximal pole has an inferior and vulnerable blood supply (Fig. 6).

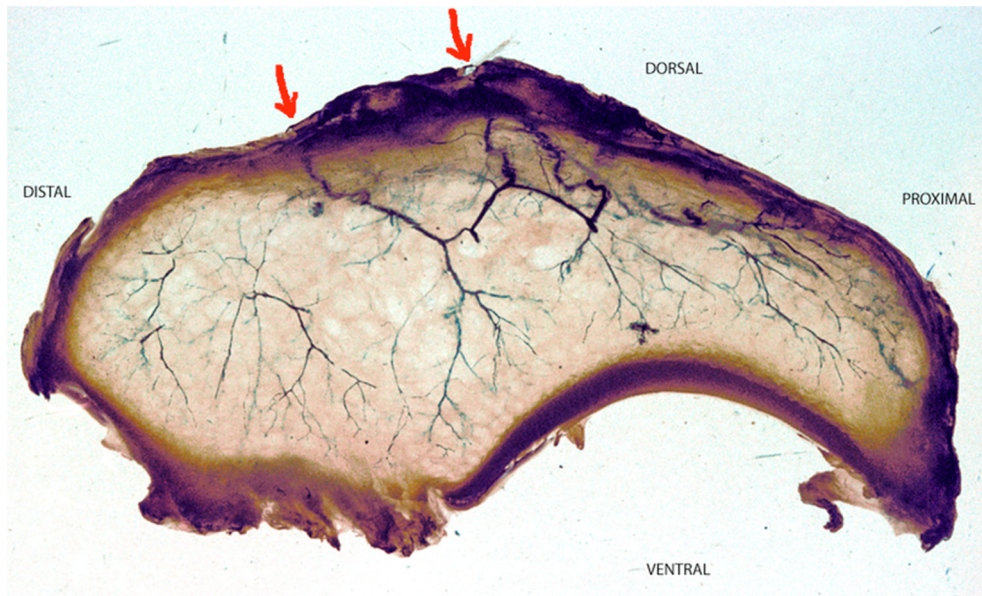


Figure 6: Retrograde bloodflow into the proximal pole of the scaphoid.

Extraosseous vessels enter the dorsal ridge of the scaphoid at points marked by red arrows. (From Wikimedia Commons, the free media repository).

Ligamentous anatomy

The scaphoid is supported volarly by two long and strong ligaments the radioscaphocapitate (RSC) and the long radiolunate ligament (LRL) and three short ligaments the scaphocapitate (SC) and scaphotrapezotrapezoid ligaments (STT) [16, 17] (Fig. 7A). The transverse carpal ligament adds to this volar support [18]. Dorsally, the long intercarpal ligament (DIC) supports the scaphoid, together, and to some extent, with the radiolunotriquetral ligament (RLT) [19](Fig. 7B). Finally the scaphoid is suspended proximal to the lunate by the scapholunate ligament complex (SL). This C-shaped complex is made of three parts: a volar and dorsal ligament and a membranous portion in between the two ligaments [20]. The dorsal ligament is mechanically the strongest part of the complex (Fig. 7B) although the volar part has recently been claimed equally important [21]. Controversy exists concerning the ligaments in the wrist; however, the above mentioned ligaments have been confirmed in advanced fusions of CT images and cryomicrotome images [22] that quantify the course, size, attachment, and insertion areas (Fig. 8AB). During arthroscopy, the only visible ligaments concerning the scaphoid are the SL, RSC, and LRL ligaments.

The dorsal ligaments (SL and DIC) keep the scaphoid linked to the proximal row while allowing flexion of the scaphoid in radial deviation (Fig. 9).

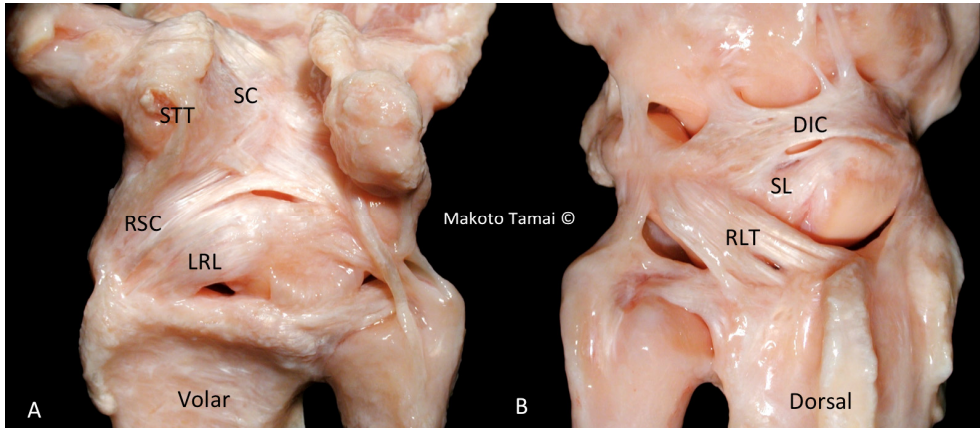


Figure 7: Anatomical specimen dissected for visualization of wrist ligaments.

(A) Volar ligaments: long radiolunate (LRL), radioscaphocapitate (RSC), scaphotrapezotrapezoidal (STT), scaphocapitate (SC). (B) Dorsal ligaments: dorsal intercarpal (DIC), scapholunate (SL), radiolunotriquetral (RLT). (With permission from Makoto Tamai)

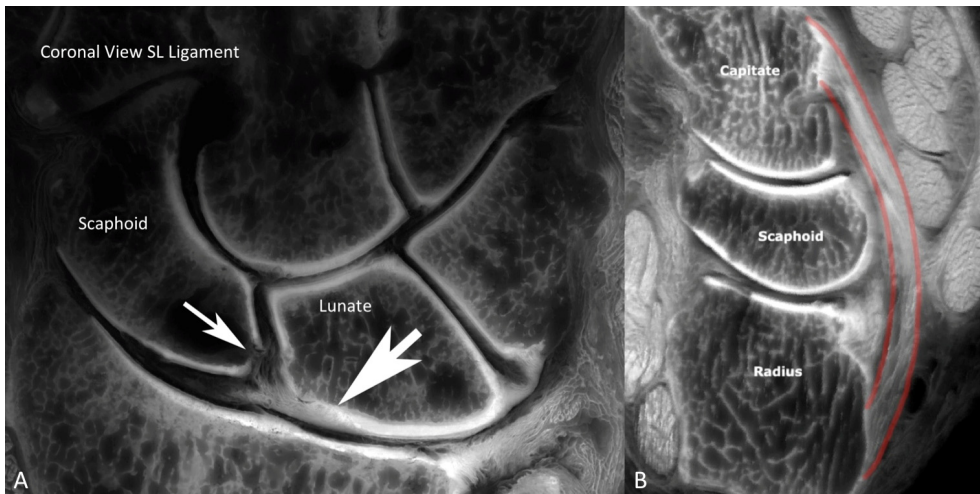


Figure 8: Computed tomography/cryomicrotome images of the right wrist.

(A) Cross-section in the coronal plane showing the short dorsal portion of the scapholunate ligament. The ligament arise from the ulnar edge of the scaphoid (thin arrow), and inserts into the radial edge of the lunate (thick arrow). (B) Oblique sagittal plane showing the long volar radioscaphocapitate ligament (Illustration by Buijze et al. [22] permission granted from publisher).

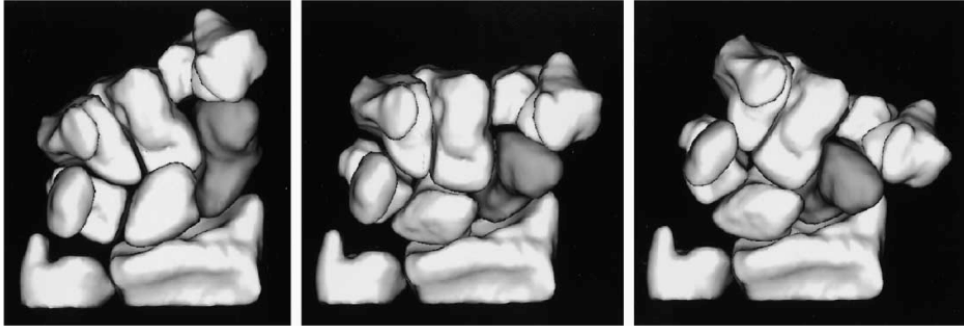


Figure 9: Three-dimensional CT reconstruction of the wrist.

The palmar aspects of the carpal bones are shown. The scaphoid is dark and flexes during ulnar-radial deviation (Illustration from Moojen et al. [23] permission granted from publisher).

Biomechanics

The carpus has 21 unique articulations internally kept together by their shape and a ligamentous apparatus like an arch bridge. In the forearm 19 muscles act to position the hand and only the flexor carpi ulnaris inserts on the carpus (pisiform and hook of hamate). Accordingly, the carpal motion is determined by the intricate articulations and the ligamentous insertions and attachments.

The three-dimensional (3D) anatomy of the scaphoid is complex and the comprehension of the dynamic anatomy is even more intricate. The scaphoid interacts with its five articular surfaces, several supportive and suspending ligaments, and, finally, the entire flexor and extensor mechanism. In particular, the flexor carpi radialis and the extensor carpi radialis brevis and longus have a buttress function volar and dorsal to the scaphoid, respectively. Wrist flexion and extension are equally distributed between the radiocarpal joint and the midcarpal joint. Radial deviation is mainly in the midcarpal joint, and ulnar deviation is equally divided between the radio- and midcarpal joints [24]. Most importantly, the scaphoid provides a mechanical link between the proximal and distal carpal rows (Fig. 10A). An indirect proof of this linkage is found in displaced scaphoid fractures. The proximal fragment is still connected to the lunate by the SL ligament and thus acts as part of the proximal row. The distal fragment, on the other hand, is connected through the STT and SC ligaments to the distal carpal row. An axial loading of the scaphoid produces a flexion force leading to a humpback deformity of the fractured scaphoid (Fig. 10B). If the fracture does not unite and turn to a non-union, the link between the proximal and the distal carpal row is disconnected. This carpal instability will, in the long term, make the distal part of the scaphoid rotate and collapse and develop a localized osteoarthritis towards the scaphoid facet on radius. This sequential process is also known as scaphoid non-union advanced collapse (SNAC). Equivalently to the cruciate ligament in the knee, the SL ligament acts as a primary stabilizer of the scapholunate joint and even the entire carpus [25, 26]. A

completely ruptured SL ligament will break the link between the proximal and distal rows, and, in long term, develop a similar collapse and finally osteoarthritis of the wrist termed a scapholunate advanced collapse (SLAC).

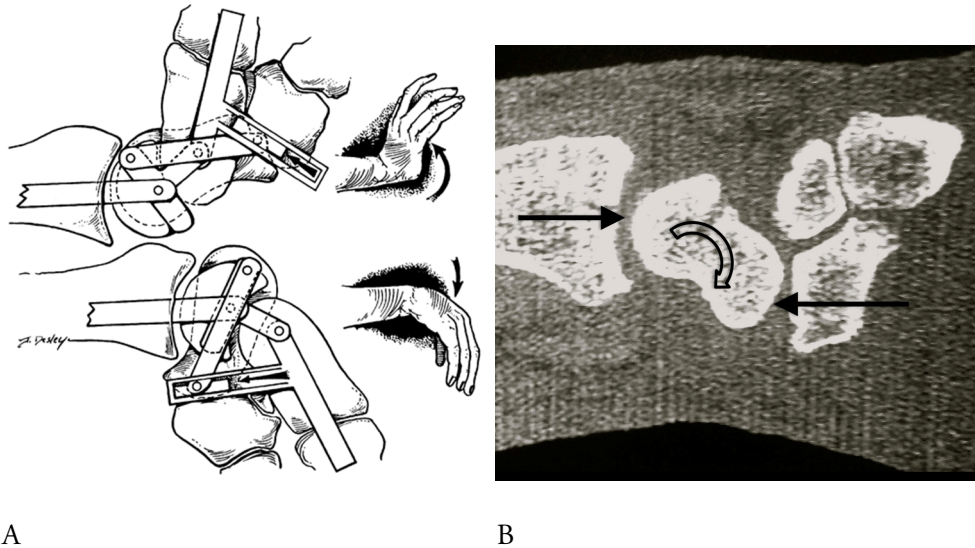


Figure 10: Biomechanics of the scaphoid.

(A) The scaphoid links the proximal and distal row through a slider crank mechanism (Illustration from Cooney [27] permission granted from publisher). (B) Sagittal CT scan of a scaphoid fracture showing the biomechanical rationale for the development of a humpback deformity in a waist fracture.

Clinically anatomy

The scaphoid is traditionally divided into three parts: the proximal pole (proximal third), the waist (middle third) and the distal pole (distal third). This equal third classification is used to describe the radiographic appearance of a fracture and is preferably applied to a radiograph taken in a Stecher's projection [55] of the scaphoid (fist closed and the wrist in maximal ulnar deviation) to produce a picture of the scaphoid in its entire length (Fig. 11A). A more clinical way to describe the fractures is by their appearance in the arthroscope. A waist fracture is only visible in the midcarpal joint (Fig. 11B). A proximal fracture, on the other hand, is seen both in the radiocarpal joint and the midcarpal joint. When a distal fracture is transverse or oblique, it is visible in the midcarpal joint. A distal fracture involving the STT joint is seen from a radial STT portal and a tubercle fracture is purely extra-articular and not seen arthroscopically.

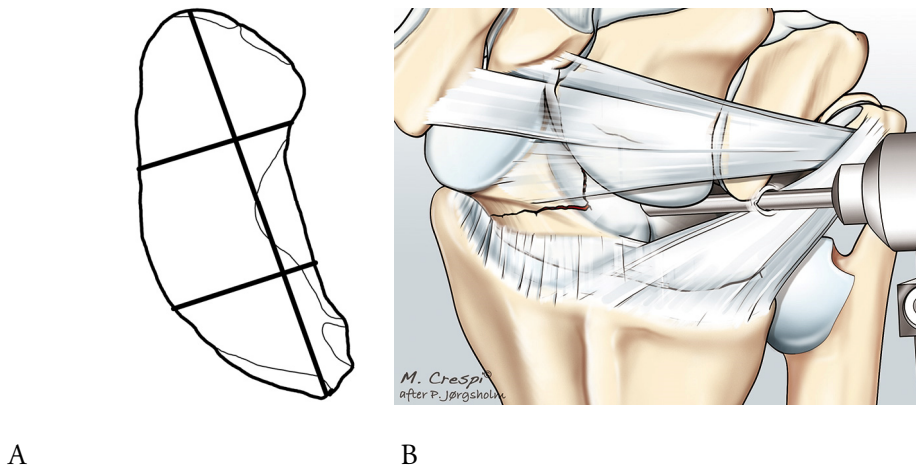


Figure 11: Clinically anatomy.

(A) Equal third classification. (B) Waist fractures only visible during midcarpal arthroscopy.

Pathomechanism

Hyperextension with axial load during a fall on an outstretched hand is the most common cause of scaphoid waist fracture [28](Fig. 12A). A direct blow to the scaphoid tubercle often during a fall could cause a distal fracture [29], and this is the most common fracture in children [30-33](Fig. 12B). Fracture can also occur with an unloaded wrist in maximum extension in combination with a sudden hit. This is typical for a goalkeeper getting struck by a high-velocity ball, and it often results in a proximal pole fracture [34, 35](Fig. 12C). Yet, another way to fracture the scaphoid is through a punch mechanism whereby an axial load to the index metacarpal through the trapezium and trapezoid is transferred to the distal scaphoid, causing a shear force type of scaphoid waist fracture [36](Fig 12D). When a high-energy trauma is involved, a scaphoid fracture could result, often in combination with other concomitant carpal fractures and, sometimes, perilunate dislocation [37].

Studies on anatomical specimens have shown that the most likely fracture site is the waist when reproducing the hyperextension with load and radial deviation [28]; however, these studies failed to establish a consistent injury mechanism. Various scenarios with axial load and hyperextension in radial and ulnar deviation have shown a tendency to cause waist and proximal pole or SL ligament injuries, respectively [38]; however, the exact trauma mechanism is still not fully understood.

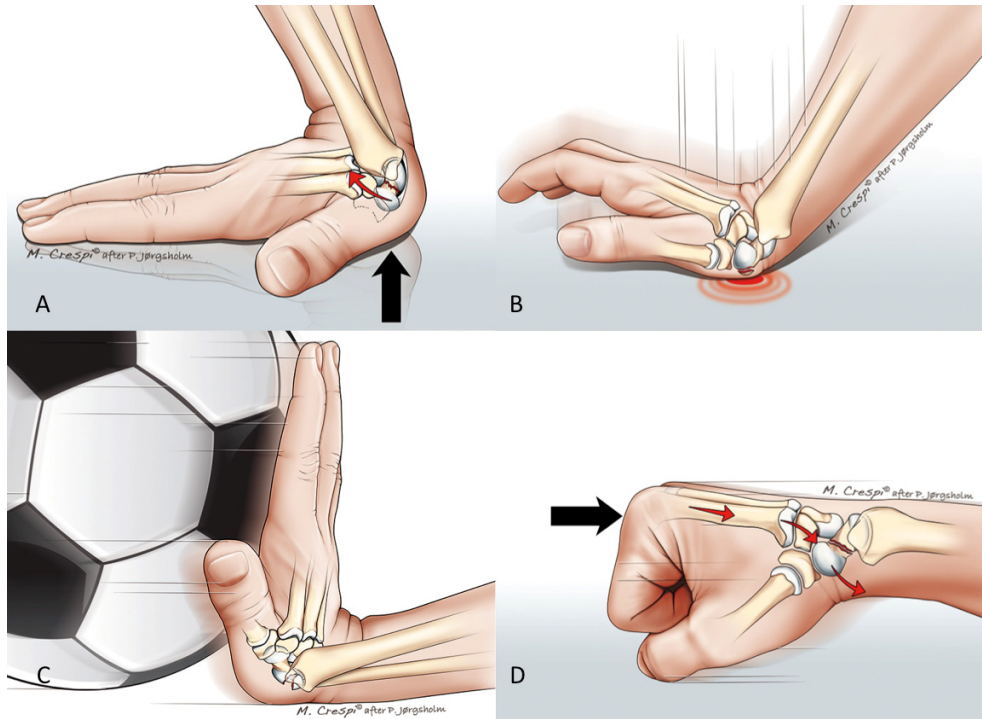


Figure 12: Four most common mechanisms of injury in scaphoid fractures.

(A) Extreme hyperextension impinge the scaphoid on the dorsal rim of the radius and can cause a scaphoid waist fracture. (B) Direct impact on the scaphoid tubercle often causes a distal extra-articular scaphoid tubercle fracture. (C) Sudden dorsal extension due to a hit from a ball often produces a proximal pole scaphoid fracture. (D) In the 'punch' mechanism, the index metacarpal delivers a volar-directed shear force across the distal scaphoid through the trapezoid and trapezium and often causes a scaphoid waist fracture (modified after Horii et al. [36]).

Epidemiology

Fracture of the scaphoid is the most common carpal fracture and account for 60 % of all carpal fractures, 10% of all hand fractures and 2% of all fractures [9]. Five per cent of patients with scaphoid fractures have an additional ipsilateral hand or wrist fracture [9]. There is a male dominance (82%) with a peak of age-specific incidence between 10 and 30 years [9](Fig. 13A). According to a Danish investigation, the peak is more concentrated in the late adolescence [39](Fig. 13B). In urban populations in Bergen, Norway, the incidence is higher (43 in 100,000 per year) [9] compared with the rest of the Scandinavia and United Kingdom (17-29 in 100,000 per year)[39, 40], as shown in Table 1. Bergen also has a high incidence of distal radius fractures probably owing to many days with temperatures below freezing point and precipitation [41].

In a US joint forces study consisting of mainly young male personnel the incidence was found to be 121 in 100,000 per year [42], and in a stratified mixed urban/rural US population as low as 1,7 in 100,000 per year [43]. This discrepancy can likely be explained with the differences in study population. Military personnel are physically active young men, whereas the study of van Tassel et al. included a mixed population in terms of sex, age, and level of activity. In the mixed urban/rural population one-third of scaphoid fractures occurred during sports activities (Fig. 14), one-fourth at home and one-fourth at the work place.

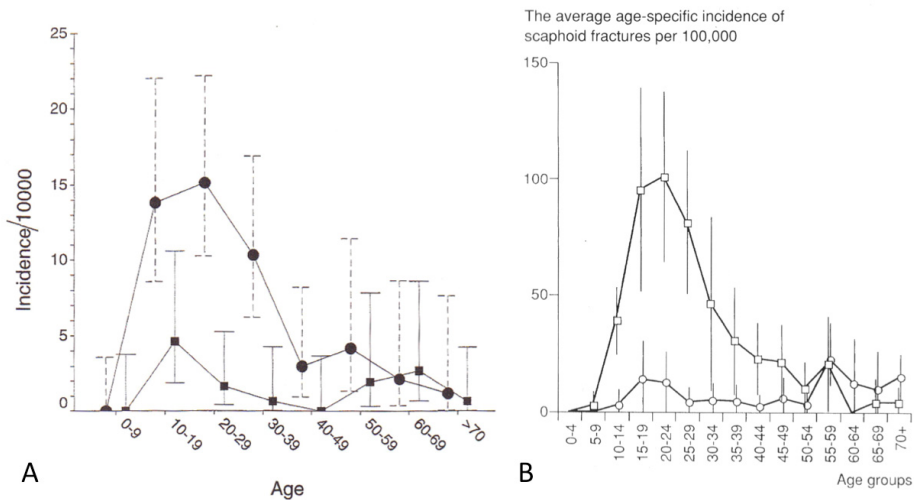


Figure 13: Age and sex-specific scaphoid fractures incidences in Scandinavia.

(A) The average age- and sex-specific incidence per 10,000 in Bergen, Norway (solid dots, men; solid squares, women) (Illustration from Hove [9] permission granted from publisher). (B) Incidence per 100,000 in Odense, Denmark (hollow squares, men; hollow dots, women) (Illustration from Brøndum et al. [44] permission granted from publisher)

Table 1:
Scaphoid fracture incidence. * Unpublished data

Country	Year	Numbers	Author	Incidents/pop per 100,000 per year
Malmö, Sweden	1953-1957	150	B Jonsson*	17 urban
Odense, Denmark	1982-1989	273	CF Larsen	23 urban
Malmö, Sweden	1992-1993	134	B Jonsson*	24 urban
Bergen, Norway	1988-1990	273	L Hove	43 urban
Malmö, Sweden	2004-2005	141	P Jørgsholm*	26 urban
Denver, US	1998-2006	14,704	JM Wolf	121 military
Denver, US	2002-2006	507	D Van Tassel	1.47 urban/rural
Edingburg, UK	2007-2008	151	A Duckworth	29 urban

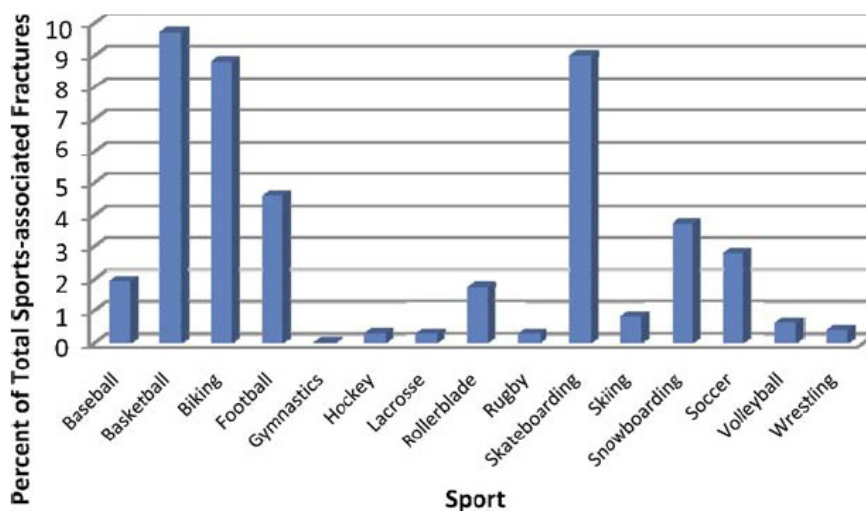


Figure 14:
Scaphoid fractures (N=112) according to sport in a US mixed urban/rural population (Illustration from Van Tassel et al. [43] permission granted from publisher.)

The most common fracture location is the middle third (59-66%), then distal third (25-34%), and the least common is the proximal third (6-10%) [45] [44, 46]. In children (<15 years old), fractures are mainly located in the distal third (65-87%), then

the middle third (12-35%), and rarely in the proximal third (0-2%) [30, 46, 47]. The incidence of scaphoid fractures in the paediatric patients (<18 years old) is generally lower than in adults; however, a change in incidence has been noted lately. This could be caused by a change in the level of activity, body mass index, skeletal maturity [48, 49], or diagnostic sensitivity [50]. In our unpublished material, we noted a significant increase in age-specific incidence in young men from the 1950s to the 1990s, and a significant slide towards younger age from the 1990's to 2000's.

Diagnosis

Clinical diagnosis

Diagnosing fractures of the scaphoid or injuries to the ligaments around the scaphoid poses a real challenge to the treating doctor. In many patients the symptoms are subtle and often mistaken for a wrist sprain. However, a missed scaphoid fracture carries a high risk of non-union or malunion resulting in severe problems for the patient.

A medical history with a relevant and recent trauma is necessary to suspect an acute fracture. The clinical examinations consist traditionally of three diagnostic tests: A. anatomical snuffbox tenderness (ASB); B. scaphoid tubercle tenderness (ST); C. pain on longitudinal compression of the thumb (LCT) (Fig. 15).

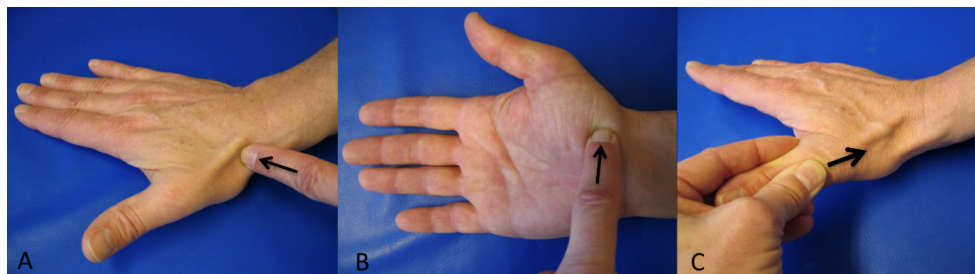


Figure 15: The three classic clinical tests for scaphoid fracture.

(A) Anatomical snuffbox tenderness (ASB); (B) scaphoid tubercle tenderness (ST); (C) pain on longitudinal compression of the thumb (LCT).

Each test has 100% sensitivity but a low specificity [51]. Parvizi et al. showed that these tests used in combination within the first 24 h after injury still produced 100% sensitivity and improved the specificity to 74%. Among 215 patients examined in their study with a history suggestive of scaphoid fracture, confirmation through repeated radiographs, clinical examinations, and, if necessary, bonescans (BS) were attained in only 56 (26%). Of their patients, 159 had a false-positive clinical investigation and were treated with scaphoid plaster for 2 weeks while waiting for repeat radiographs. By

using the combination of these three tests in the acute setting (<24hours) instead of a single test (ASB) the false-positive diagnosis was reduced by 65% and only 41(19%) patients would have had an ‘unnecessary’ scaphoid plaster.

Yet, a similar clinically testing was proposed by Bergh and co-workers by using the three classic tests with a different grading [52] and magnetic resonance imaging (MRI) as the final reference. The LCT test has the value of 1 point, the ST test a double value of 2 points, and the ASB test a triple value of 3 points. With this graded combination, named the clinical scaphoid score (CSS), they were able to show that of 154 patients with wrist sprain and negative radiographs and a CSS ≥ 4 , 10 of 13 occult fractures were found corresponding to a sensitivity of 71% and CSS ≥ 4 was their ‘cut-off’ for referring to an MRI investigation. These tests were performed at a median of 1 day after trauma (range, 0-31 days).

Duckworth et al. [53] evaluated a combination of medical history and clinical tests recently. In 62 of 223 (28%) patients, a scaphoid fracture was ultimately confirmed with repeat radiographs, clinical examinations, and, if necessary, CT or MRI. A logistic regression model identified male, sports injury, anatomical snuffbox pain on active ulnar deviation/pronation (<72h), and scaphoid tubercle tenderness at 2 weeks as independent predictors of fracture. By using predictive factors in a flow chart (Fig. 16) within 72 h and at 2 weeks, the false positives were reduced to 9% and only 20 patients would have an ‘unnecessary’ scaphoid plaster.

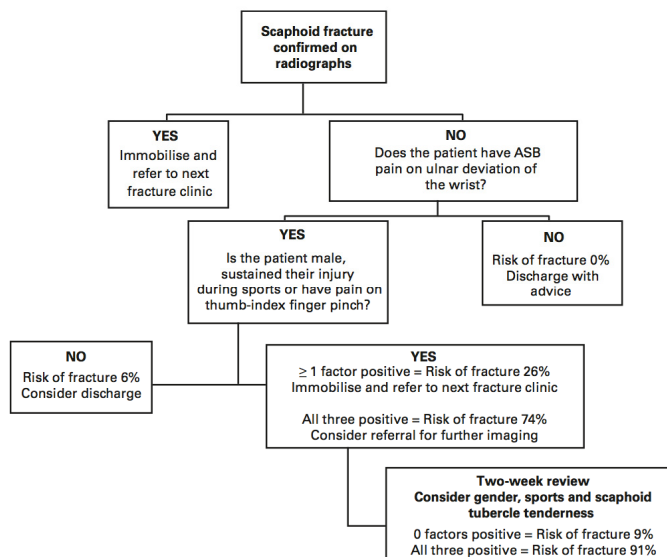


Figure 16:

A potential management algorithm based on anatomical snuffbox pain on ulnar deviation of the wrist within 72 h of injury (Illustration from Duckworth et al. [53] permission granted from publisher).

Plain radiography

Conventional radiographs of the wrist are still the gold standard and the initial line of investigation for clinically suspected scaphoid fractures. The American College of Radiology (ACR) has recommend four views of the wrist; posterioranterior (PA), lateral, a PA with ulnar deviation (15°/15°) and a semi pronated oblique (writing position)[54]. Many radiologists add one or two more specific scaphoid projections, often with some extension of the wrist by volar ulnar support (30°) (Fig. 17) or as a Stecher's projection (fist closed and maximum ulnar deviation)[55]. Regardless of which of the many proposed projections are used, it is important to ensure that the x-ray beam is parallel to the narrow fracture line that most often is situated transversely in the waist (Fig. 18).

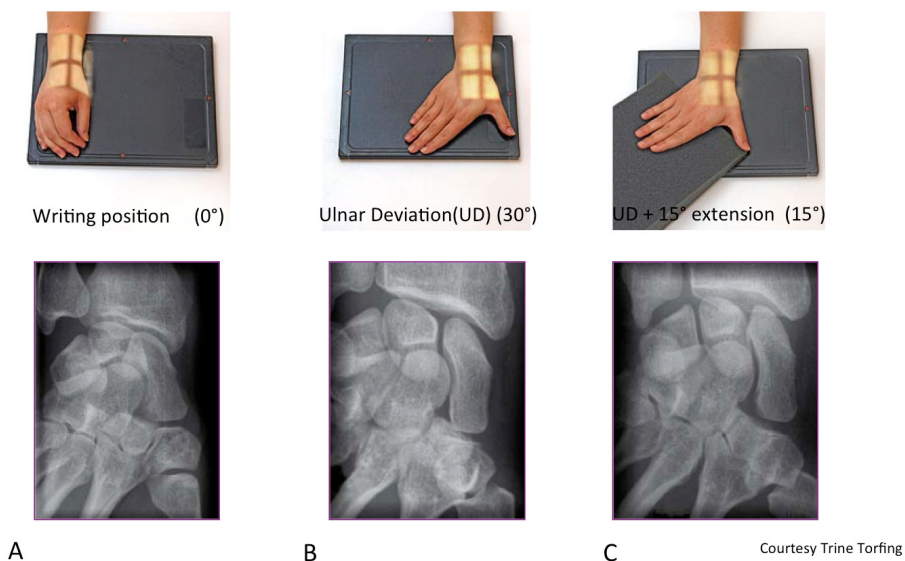


Figure 17: Three Scaphoid views aiming to project all scaphoid joints.

(A) Wrist in writing position slightly extended and supinated will project the scaphoid tubercle. (B) Wrist in ulnar deviation and x-ray beam tilted 30° caudally will project the SL joint and the full length of the scaphoid. (C) Wrist in ulnar deviation and 15° of extension, and x-ray beam tilted 15° caudally will project the STT joint (Illustrations with permission from Trine Torfing).

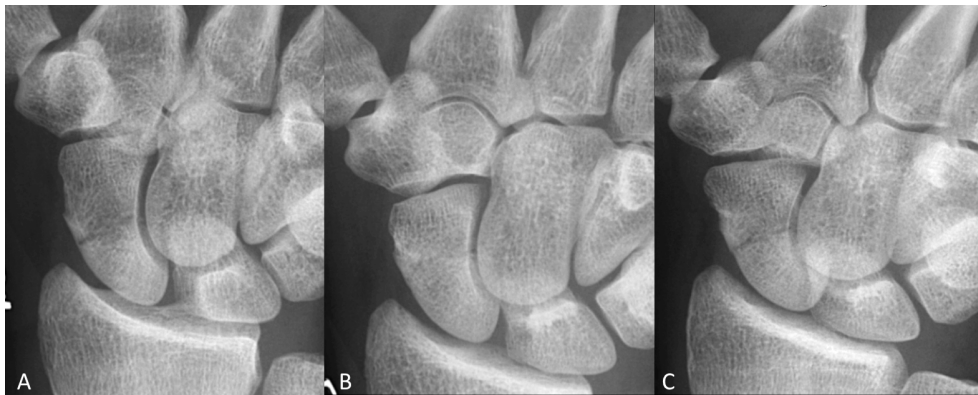

Figure 18: A transverse scaphoid waist fracture (best seen in A and C with wrist 30° extended where the x-ray beam will be parallel to the fracture line).

(A) Scaphoid waist fracture in 30° extension. (B) Scaphoid waist fracture in 15° extension. (C) Scaphoid waist fracture in writing position.

Radiographs with scaphoid views have a high specificity close to 100% but a low sensitivity ranging from 11% to 49% [56, 57]. Radiographs have low sensitivity even on detecting displacement [58], for which CT is significantly better [59]. Repeated radiographs at 2 weeks have 91.1% sensitivity and 99.8% specificity according to a recent latent class meta-analysis [60].

The injured wrist with negative radiographs and clinically suspect scaphoid fractures is an everyday problem in the orthopaedic clinic. The next line of investigation is still debated, and different modalities have been proposed to improve immediate diagnosis and reduce overtreatment.

Tomosynthesis

Tomosynthesis is a digital version of conventional tomography. It is mainly used for mammography but is also available for whole-body imaging [61]. Providers of equipment for orthopaedic use are limited, and its use is restricted to centres that already have the equipment. It is capable of taking tomographic images of a thickness of as low as 1 mm. The fracture diagnosis is based on a cortical breakage as the anatomic noise disturbs the interpretation of trabecular bone. The advantage of its use is mainly logistic as the patient with a suspected scaphoid fracture and negative primary radiographs can continue, at the same visit, with a tomosynthesis at the same radiographic laboratory. It is therefore time efficient, cheaper than CT and has the same or a lower radiation as CT [62]. It has been evaluated by Ottenin et al. who concluded that tomosynthesis is superior to radiographs but inferior to CT [63]. (Three independent observers. Radiographs: sensitivity/specificity 61-80%/65-83%; Tomosynthesis: sensitivity/specificity 77-87%/76-82%; CT: sensitivity/specificity 93-95%/86-95%).

Computed tomography

CT was invented in 1967 and first used for clinically purposes in 1971 [64]. The high resolution of modern CT scanners makes them ideal for confirming suspected scaphoid fractures, to determine fracture displacement and comminution and finally to evaluate fracture healing. CT is available in most institution around the clock and has a rapid protocol and is relatively cheap. The drawback is the radiation load to the patient, which, however, is moderate in wrist projections. A wrist investigation taken in prone position with the hand above the head gives a radiation dose of 0.03mS corresponding to one-week background radiation [65].

With the multi-slice technique and digital reconstruction of <1 mm thickness in the long axis of the scaphoid (Fig. 19) [66-69] it is possible to visualize most scaphoid fractures and the sensitivity and specificity are reported to be very high [70, 71].

According to the latest meta-analysis [60] by using latent test analyses the sensitivity for CT diagnosing a scaphoid fracture is 85.2% compared with 97.7% for MRI. This corresponds well with the ACR appropriate criteria [54], which recommend MRI as the first choice in second-line investigations when radiographs fail to confirm a clinically suspected scaphoid fracture.

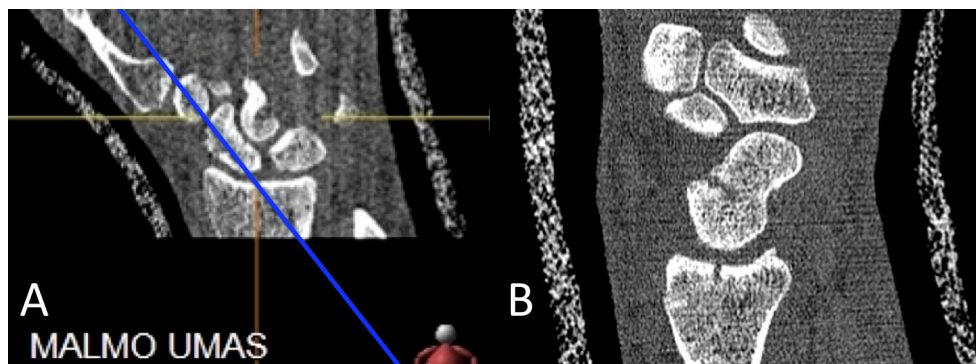


Figure 19: Digital reconstructions in the long axis of the scaphoid (Sectra©).

(A) The definition of the long axis of the scaphoid in coronal plane (blue line). B Sagittal scaphoid reconstruction using the in (A) defined long axis.

CT is superior to plain radiography in detecting displacement [72, 73]. CT has a higher spatial resolution than MRI and the advantage of allowing reconstruction in the long axis of the scaphoid. Therefore CT is superior in evaluating displacement [61].

Adding a 3D reconstruction (Fig. 20) helps the treating surgeon to evaluate displacement, estimate comminution and concomitant fractures, and decide on optimal treatment and its detailed planning [74].

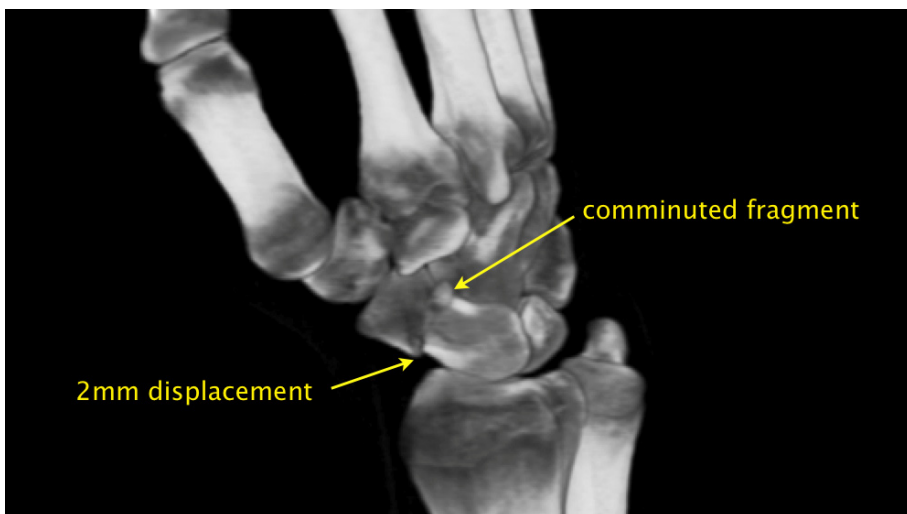


Figure 20:

Three-dimensional CT reconstruction of displaced comminuted scaphoid fracture (arrows). This fracture appeared undisplaced on radiographs.

Union of scaphoid fractures assessed by using radiographs do not provide reliable and reproducible evidence of healing [75]. CT has been advocated as the gold standard for scaphoid union [67, 76]; however, consensus has been lacking on the methods for defining and quantifying union. Grewald et al. [77] recently proposed a modified version of Singh's methods for evaluating scaphoid union. Both methods were compared and used with reconstruction in the long axis of the scaphoid, and union was classified as <50%, 50-74%, and 75-100% measured in each sagittal slice. The methods of measuring the slices and the calculations were slightly different but statistically both methods had a high inter-rater reliability. The simple method as proposed by Singh [76] was appraised as the clinically most feasible. These methods are now used scientifically for the estimation of scaphoid union [77, 78].

In the near future extremity cone-beam CT scanners will be available with a higher spatial resolution than conventional CT [79]. By adding digital detectors on the patient these compact mobile units will assist the surgeon during osteosynthesis to help navigate a guide-wire to an exact central placement in the narrow scaphoid bone [80, 81].

Bone scan

Widespread clinical use of nuclear medicine began in the early 1950s and for several decades, isotope scanning or BS has been a popular second-line investigation for suspected scaphoid fractures, as it is a good method for ruling out a fracture. It has a high sensitivity (94-100%). However, it is an invasive procedure involving injection of

radioactive isotopes (Technetium-99m) that have an affinity to osteoblast activity, as seen in a fracture repair process after a minimum of 72 h. The injected Technetium-99m binds to hydroxyapatite crystals and is accumulated at the fracture site within 2-6 hours. This means the investigation will be time consuming, as the patient has to wait approximately 4 hours for the radioactive imaging. The relative radiation level is 10-fold higher than for CT (1-10 mSv)[54].

The binding of the radioisotope to areas with osteoblast activity means that areas with bone bruise, synovitis, and, in particular, osteoarthritis, which is not uncommon in the elderly population, may appear as a hot spot and yield a false-positive results [82]. The spatial resolution is poor, and the interpretation of whether an uptake is in the distal pole of the scaphoid, in the STT-joint, or in the trapezium is difficult (Fig. 21). This can explain why the specificity is low [60].

To enhance the spatial resolution, a fusion of BS and radiographs has been proposed and used in scaphoid fractures imaging [83]. This technique might play a role in assessing patients for scaphoid fractures when CT and MRI are not possible.

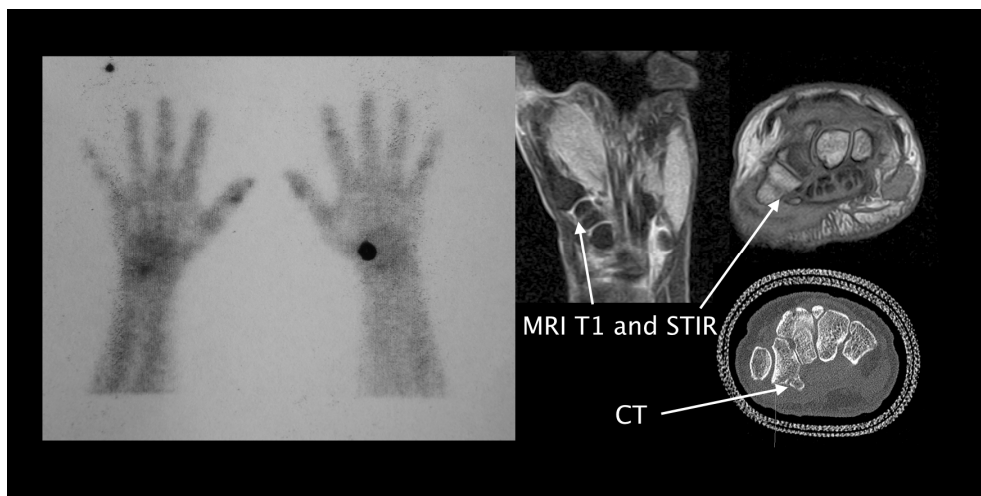

Figure 21: A 62-year-old woman with wrist trauma.

The bonescan is suggestive of a scaphoid fracture. MRI and CT show trapezium fracture (arrows).

SPECT/CT

In single-photon emission computed tomography and CT (SPECT/CT), the improved anatomical localization of the scintigraphic lesion (hot spot) superimposed on a CT scan creates very specific pictures of the lesion site. This might have future use in cases for which MRI is contraindicated [84].

Ultrasound

Several studies have reported on the use of high-spatial-resolution sonography in suspected scaphoid fractures. It has the advantage of being non-invasive, cheap and easy accessible. Furthermore it is easy to examine the uninjured side as reference in this method. The disadvantage is that ultrasound is not able to evaluate the entire scaphoid and, furthermore, it is highly examiner dependent and the dynamic nature of the images makes documentation difficult. Comparative studies have shown inferior diagnostic performance compared with BS, CT, and MRI [85, 86].

Magnetic resonance imaging

The first useful MRI picture was produced in 1976 [87]; however, it was not until the 1980s that the technique was put in clinical use. MRI, like ultrasound, shows soft tissue better than techniques in which x-ray are used. There is no ionizing radiation involved.

Different MRI protocols are used to visualize different kinds of tissues. Coronal short tau inversion recovery (STIR) and coronal turbo spin-echo T1-weighted (T1) are the standard sequences in diagnosing fractures. In STIR sequences, fluid will become white, a fracture oedema will lighten up, and T1 sequences will produce a low-signal dark line as a marker of the fracture line (Fig. 22). MRI has been considered the gold standard for second-line scaphoid fracture investigation. It has excellent sensitivity and a very high specificity (close to 100%) for the assessment of scaphoid fractures [60]. The inter-observer reliability is generally good, and it has no radiation hazards. It is possible to detect occult fractures and bone bruising in the scaphoid and other carpal bones, as well as any soft tissue injury. Because of its high sensitivity in detecting bone marrow oedema it can be difficult to distinguish between bone bruise, fractures and revascularization resulting in false positive results. In children, a high T2 signal has been reported in the carpus during growth, with a maximum around 7-11 years of age [88] and this could be misinterpreted as a pathologic bone marrow oedema. Another drawback is the limited availability, high cost, and relatively time-consuming scanning protocol, which could hamper the image quality, because of motion artefacts.

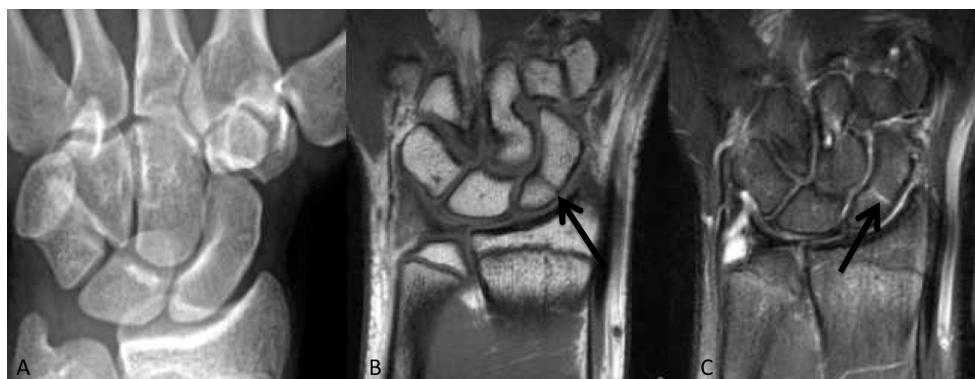

Figure 22: Scaphoid proximal pole fracture.

(A) Fracture not visible on radiographs. (B) Black fracture line on T1 weighted image. (C) White fracture line on STIR sequences.

Several studies have investigated the cost-effectiveness of this relatively expensive investigation (scaphoid MRI priced 150€ Malmö 2014), and all studies have concluded that this second-line modality is cost-effective considering that the patients often are young active men. One recent Danish study [89] showed a reduced sick leave by 16 days when using a MRI protocol for suspected scaphoid fractures, saving almost 3000€ per patient.

Many institutions now use MRI as an early investigation if radiographs are negative but clinical suspicion of scaphoid fracture exists. In this way, a high proportion of patients (74-94%) [51, 86, 90, 91] eventually will undergo MRI investigation, and this leads to the diagnosis of many occult carpal fractures that otherwise would never be found [92, 93]. The clinical implication of these occult fractures is unclear; however, it certainly explains why many patients complain of pain after a wrist trauma with negative radiographs. Many other injuries besides fractures are found, and the term ‘wrist sprain’ covers a wide span of different soft tissue injuries such as ligament, triangularfibrocartilage complex (TFCC), and tendon injuries not visualized on radiographs [94].

Gadolinium contrast injection (‘indirect arthrography’) has been used increasingly in the recent years. The contrast is administered intravenously to enhance the wrist ligament structures such as TFCC, SL and LT ligaments [95, 96]. It is; however, time consuming, adds further costs and it is difficult to adopt in the acute settings.

Arthrography

Arthrography is an adjunct available in radiographs, CT, and MRI. It is an invasive technique and is dependent on a skilful radiologist. During contrast arthrography, contrast solution is injected into the three wrist compartments in a logical sequence

starting in the midcarpal joint, followed by the distal radioulnar joint, and finally the radiocarpal joint. It is usually not appropriate in the acute setting with a swollen wrist but is more suitable later in the posttraumatic case with chronic wrist pain. The sensitivity of x-ray arthrography is low [97]. MRI can be helpful when there is suspicion of an intra-articular ligament injury, especially if an acute fovea detachment of the TFCC is present; however, without arthrography, the sensitivity and specificity are relatively low compared with the gold standard of arthroscopy [98, 99]. Lunotriquetral ligament injury is difficult to visualize with MRI without arthrography, and in the acute situation it is only accessible by using arthroscopy.

To obtain an overview of the most appropriate modality to use in the acute and sub-acute settings, the ACR has introduced an Appropriate Scale protocol [54]. A modification and simplification is shown in Table 2 concerning imaging in a suspected scaphoid fracture.

Table 2: Recommended line of investigation for a suspected acute scaphoid fracture according to the ACR.

1. Suspected acute scaphoid fracture: radiographs posteroanterior, lateral, and scaphoid three views.
2. Suspected scaphoid fracture. Radiographs normal: MRI within 1-3 days or CT (if MRI is unavailable) or cast and repeated radiographs in 2 weeks.
3. Suspected scaphoid fracture and second radiographs normal: MRI or CT (if MRI is unavailable).

Treatment

Conservative treatment

Most scaphoid fractures are treated conservatively with a plaster of Paris for at least 6 weeks. If the fracture is treated while it is acute, 85-95% [46, 100-102] will achieve union within 6-12 weeks of plaster treatment whereas the union rate is diminished with a delay in treatment of > 4 weeks [46]. The proper type of immobilization has been debated for decades; however, most authors agree that a below-the-elbow plaster with the thumb being free is sufficient [103, 104]. No one has been able to show that an above-the-elbow plaster including the thumb gives a better union rate [105].

There is increasing evidence that fracture-specific factors such as fracture location and degree of dislocation influence the time to and the likelihood of union. Anatomically, the proximal pole has sparse blood supply, and this is thought to influence the healing time as vessels have to propagate retrogradely from distal to proximal across the fracture line in the case of a proximal pole fracture [15] (Fig. 8). A proximal pole fracture is the least common fracture localization (6-10%) [44, 45]. The union rate is reported to be

25-40% [46, 102] [101, 106] with conservative treatment. A delay in treatment (>4weeks) seems to be particular critical in proximal pole fractures [46].

In a meta-analysis by Singh et al. 2012, conducted on 1401 conservatively treated displaced fractures, a four times higher non-union rate was found compared with 157 surgically treated displaced fractures [107]. The evaluation of displacement and union was primarily based on wrist radiographs.

Displaced fractures, diagnosed on plain radiographs, are relatively uncommon with a rate around 20% [101, 107, 108] and the non-union rate is reported to vary between 14% [101] and 92% [109] when treated conservatively. This wide span in reported non-unions could be due to a lack of uniform methods for investigation and measurement of initial displacement and, furthermore, to a difference in the basic population. CT is superior in assessing fracture dislocation [72, 73], and it has been shown that displacement, angulation and comminution significantly increase the time to union (CT verified) and are related to higher risks of non-union [77]. The attributable risk of non-union will approximately double for each half a millimetre the translation is increased [77] (Fig. 23), reaching a clinically critical level with >1mm of displacement. Displacement, angulation, and comminution 'were independently significant in increasing the time required to achieve union and were shown to have an overall additive effect.' [77].

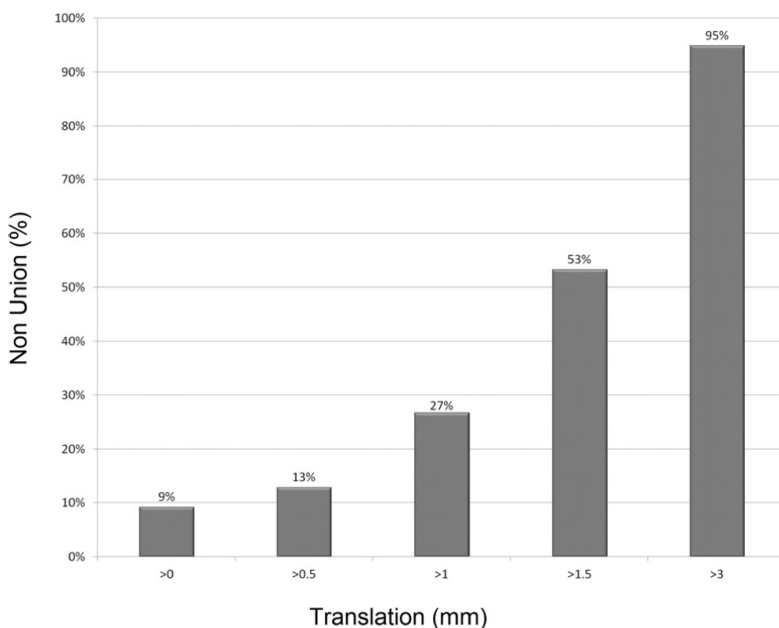


Figure 23: Relationship between risk of non-union (%) and fracture displacement (mm) in conservatively treated scaphoid fractures (From Grewal [77] permission granted from publisher).

In a recent study with arthroscopy, Buijze et al. showed that displaced scaphoid waist fractures are almost always unstable but unstable fractures are not always displaced [59]. Most of the patients in that study were from our study cohort in Malmö. In another study on the same cohort, it was shown that fracture comminution was strongly correlated with fracture instability when assessed arthroscopically [110].

How long the patient should be immobilized in a plaster is a dilemma for the clinician. With the use of radiographic union, as seen on plain radiographs, even with use of six views or carpal box technique [111] and a doubtful tenderness around the scaphoid, it is difficult to decide whether to mobilize the patient or keep the plaster for another couple of weeks. The patient is most often a young male person desiring early revival of his professional or sporting activity, and the treating doctor, in the presence of doubt, becomes reluctant to discontinue the plaster treatment.

For a more definite decision to terminate treatment, CT has been proposed to confirm the time of union in the healing scaphoid fracture [73, 112]. The definition for union based on sagittal CT is described in Singh et al.'s paper from 2005 [76]. They concluded that a partial union of the scaphoid (25-74%) at 12-18 weeks was a common occurrence (33%) but they all progressed to union without plaster treatment. With this knowledge it has been shown that many undisplaced scaphoid fractures will unite after 4 weeks of treatment with a plaster [78] and most minor displaced fractures (<2 mm gap) will unite with further plaster immobilization [113, 114].

In conclusion most undisplaced scaphoid fractures will unite after conservatively treating for 4-8 weeks with a plaster. Sagittal CT is the best investigation to assess healing and to decide the termination of treatment.

Some factors have been identified as crucial for time to union and the likelihood of union:

- *Proximal pole* fracture has a non-union rate of 30-40% with conservative treatment and a delay in presentation (>4 weeks) increases the non-union rate substantially. Conservative treatment often involves >3 months of plaster treatment.
- *Fracture displacement* of >1 mm increases the non-union rate. Conservative treatment is prolonged significantly.
- *Comminution* increases the non-union rate. Conservative treatment is prolonged significantly.
- *Humpback* deformity increases the non-union rate.
- *Smoking* [115, 116], *non-steroidal anti-inflammatory drugs* [117], *cortisone and certain heart and pulmonary diseases (low oxygen saturation)* can prolong and influence the outcome of scaphoid fracture treatment.

On the basis of these recommendations, it is possible to discuss with the patient which treatment would be preferable, taking non-union rates into consideration and the estimated time to union with a plaster. An important factor is the patient's occupation. Is the patient a white or blue-collar worker, and will it be possible to work with a plaster? The alternative, which is surgery, is described to have a more predictable union rate [118] and often a faster return to former activity. However, it has the risk of potential intra- and postoperative complications, including anaesthetic hazards; technical surgery-related problems; nerve, vessel, and tendon injuries; bleeding; infection; nerve entrapment; complex regional pain syndrome; and non-union.

Operative treatment

In 1954, McLaughlin was the first to describe an operative treatment of a scaphoid fracture [119], by using a vitallium screw to stabilize the fractured scaphoid. Different kinds of hardware have been developed and used: K-wires, lag screws, Ender plates, and compression staples; however, with the invention of the double threaded twin pitch headless screw (Fig. 24) by Herbert and Fischer in the late 1970s and its clinical introduction in 1984 [120] the operative treatment gained increasing popularity.




Figure 24: The double-threaded twin pitch headless Herbert© screw.

The tiny twisted scaphoid bone, 80% covered with joint cartilage and lying angulated by 45° in both planes deep in the wrist, has caused great frustrations among wrist surgeons concerning correct placement of the intramedullary screw. Fortunately, the design of headless screws has evolved, and most of the >50 screw designs available today are cannulated, allowing for the placement of a guidewire to facilitate the correct position of the screw in the narrow bone marrow of the scaphoid, regardless if it is done open or percutaneously. The screws are produced in different sizes, some with variable pitch, or with different technical solutions to regulate the compression force needed [121] (Fig. 25). The material used is frequently a titanium alloy or stainless steel; however, even absorbable materials containing poly-L-lactide have been used [122]. The same type of screw is used in acute fractures and non-unions. The use of an image intensifier is mandatory during operation even for the most skilled surgeon.

In general, proximal pole fractures or non-unions are approached from the dorsal side, and distal fractures and waist non-unions from the volar side. Waist fractures could be approached either way. The dorsal approach is easily obtainable as the proximal pole

lies between the third and fourth extensor compartment and pops up when the wrist is flexed. The incision is transverse (2-3 cm), and there is only a thin joint capsule covering the joint surface and no ligaments have to be incised (Fig. 7). The proximal pole can be easily visualized through a mini-arthrotomy (Fig. 26), and the SL ligament is appropriately inspected. The percutaneous approach is similar between the third and fourth extensor compartment.

The volar approach is a 4-5 cm zigzag incision over the FCR tendon keeping the radial artery radially. The scaphoid is situated deep in the incision and is reached by incising the joint capsule and ligaments from the scaphoid tubercle and proximal trapezium. To visualize the scaphoid this way, the important volar support from the RSC and STT ligaments (Fig. 7) has to be partly detached from the scaphoid. Some authors recommend osteotomy of the distal trapezium to obtain the optimal entrance point for the screw [123]. The percutaneous approach is from the proximal trapezium/scaphoid tubercle where the entry point for the guidewire is visualized by using an image intensifier. Whether the dorsal or the volar approach is superior is debated but their clinically outcomes are comparable [124]. If minimally invasive surgery is used and arthroscopic assistance is added, the most popular approach is dorsal [125, 126] (Fig. 27A). Many authors prefer the percutaneous volar approach [127, 128] with radiographic guidance of screw placement and without arthroscopy (Fig. 27B).

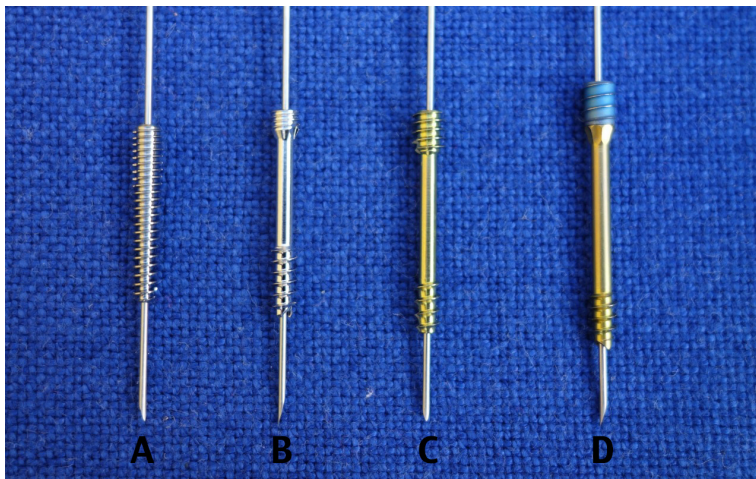


Figure 25: Four different headless cannulated scaphoid compression screws.

(A) Acutrak© Compression by variable thread pitch. (B) HCS© Compression by different thread pitch (compression adjustable by screwdriver). (C) HBS© Compression by different thread pitch (available in two different degree of compressions). (D) Twinfix© Compression by different thread pitch (compression adjustable by turnable head).

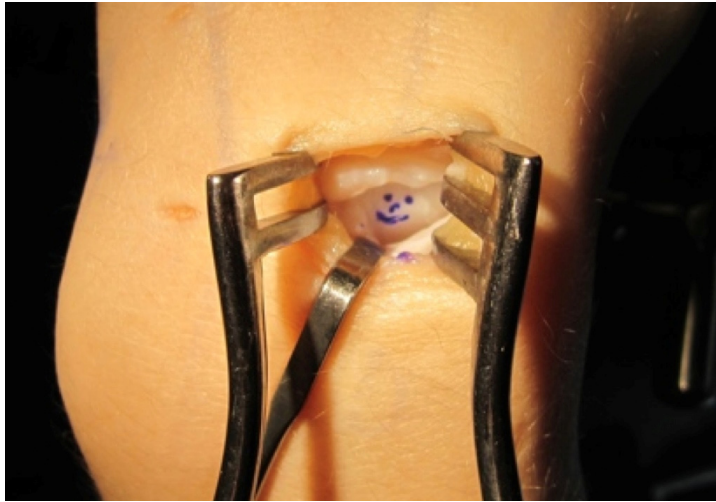


Figure 26: Dorsal approach to the proximal pole between the extensor pollicis longus and extensor digitorum communis.

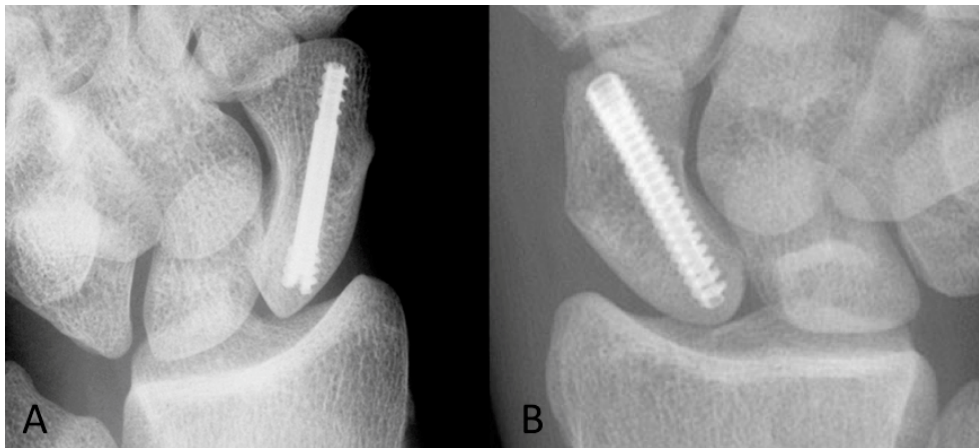
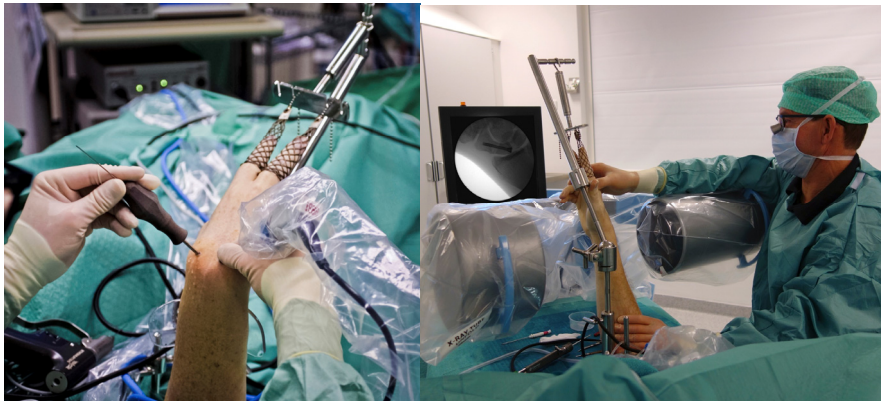


Figure 27: Intramedullary cannulated compression screws in the scaphoid

(A) Dorsally inserted arthroscopy-assisted Herbert-Whipple© screw. (B) Volarly inserted percutaneous radiography-guided Acutrak© screw.

The advantage of the arthroscopy-assisted dorsal approach is the visualization of the fracture from the midcarpal portals with the possibilities of removing the interposed debris, capsule, or ligaments and reducing displaced fractures. The correct entry point is determined with arthroscopy through radiocarpal portals, and concomitant ligament injuries are inspected and eventually treated. Finally, the degree of compression and stability is judged through a midcarpal inspection. To facilitate the procedure, specially designed wrist traction towers (WristFastTrac©) and image intensifiers are used (Orthoscan©) (Fig. 28).



A

B

Figure 28: Intraoperative settings for arthroscopy-assisted screw fixation of scaphoid fractures.

(A) WristFastTrac© tower with the wrist in flexion to facilitate the dorsal insertion of the cannulated screw into the scaphoid. (B) Orthoscan© image intensifier designed for hand and wrist surgery used to check the placement of the screw.

Postoperatively, the patients are treated with a cast for 1-2 week, although some surgeons mobilize patients directly after the operation.

The outcome of minimally invasive scaphoid fixation in both undisplaced and displaced fractures has been encouraging, with union rates close to 100% [118, 129-132]. This is without the long immobilization period and the drawbacks such as stiffness, decreased grip power, potential skincare problems, and work disability [133]. An early return to function will decrease the time off work and potentially be a benefit for both the patient and society, in particularly in blue-collar workers [134-136].

When an invasive treatment is introduced, the inevitable complications will emerge. The amount and type of complications are important when deciding on the appropriate treatment for the patient. The open volar approach is a relatively extensive intervention to the wrist, and therefore minimally invasive techniques are almost mandatory when surgical stabilization is offered for undisplaced or minimally displaced fractures, considering that 95% of these fractures will unite with conservative treatment.

Few randomized studies with a long follow-up have been conducted to investigate the differences between conservatively and surgically treated patients. A significant radiographic (visualized by CT) STT osteoarthritis in patients operated with an open volar approach has been described by two authors with >10 years follow up [137, 138]; however, no clinical impact on wrist function was found during follow-up. A systematic review has recently been published [103] comparing six randomized studies (three minimally invasive, three open, all volar approach) comparing conservative and surgical treatment of acute scaphoid fractures. In the group treated surgically, the rate of non-

union was three times less. These patients had a quicker return to function but had more complications such as infection, complex regional pain syndrome, screw protrusion, scar problems, and later osteoarthritis were registered. Symes et al. concluded that patients with minimally displaced (<1 mm) waist and distal fractures 'may well benefit from surgery if they cannot work with a plaster and in whom a slightly earlier return to function outweighs the risk of complications'.

Combined scaphoid injuries

Simultaneous fracture of the scaphoid and the distal radius is reported in 5% of scaphoid fractures cases [9] and in 5% of distal radius fracture cases [139, 140]. Scaphoid fractures in combination with other carpal fractures have been considered rare [141-143] and are mainly described as part of greater arc injuries or perilunate fracture dislocations [38], most often involving high-energy traumas [37]. Fenton's syndrome is described as a combined scaphoid and capitate fracture with dislocation [144] and is often referred to as scaphocapitate syndrome and several anecdotal case stories are found [145-147].

With the introduction of more sophisticated imaging technique new patterns of injury have appeared. Studies with MRI have shown that the occurrence of more than one carpal fractures at the same time is not uncommon [92, 93, 148]. Furthermore, several variants of simultaneous carpal fractures without dislocation have been reported [149-151].

It was long believed that an undisplaced scaphoid fracture would effectively exclude the occurrence of an associated scapholunate ligament injury although it has been described in high-energy perilunate fracture dislocations [37, 152]. Braithwaite published the first detailed report on the simultaneous occurrence of acute scaphoid fracture and SL ligament injury in 1992 [153], followed by Filan and Herbert 1996 [154]. Some studies describe radiographic sign of SL ligament injury combined with scaphoid fracture [155, 156]; however, it is questionable to use radiographs for the diagnosis of acute SL ligament injury [157]. The coexistence of SL ligament injuries has been reported in scaphoid non-unions, and it has been suggested that a concomitant SL ligament injury in patients with a scaphoid fracture increases the risk of fracture non-union [158].

After the introduction of arthroscopy-assisted scaphoid fracture treatment several reports have described the existence of acute scaphoid fracture in combination with a SL ligament injury, with incidences ranging from 0% to 50% [159-163]. The clinical implication of this combined injury is still unknown; however, in such a case, the proximal part of the scaphoid is highly unstable, 'floating', when disconnected both at the fracture site and at the torn ligament (Fig. 29) and it is thus potentially avascular [160]. A similar term, 'floating lunate', is used to describe a lunate with ruptured intercarpal ligament at both sides [164].

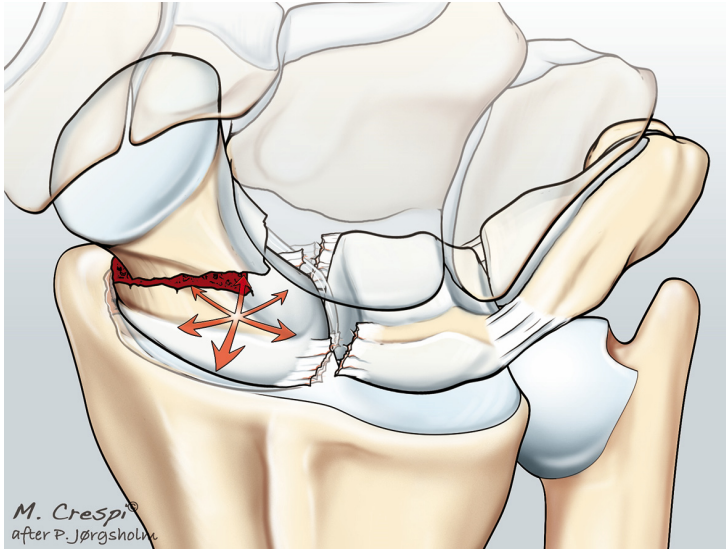


Figure 29: The combined unstable scaphoid fracture and complete SL ligament rupture.
The 'floating' proximal scaphoid fracture fragment with minimal vascular supply.

Biomechanically, these combined injuries have been explained as part of lesser or greater arc injuries [165]. Lesser arc injuries are mainly ligament injuries and dislocations around the lunate, and greater arc injuries are mainly trans-carpal fracture dislocations. As many variants of these injuries exist [146, 151, 166], and not all are explained by the lesser and greater arch theory, Bain and co-workers have proposed that translunate (Fig. 30) and inferior arc injuries (Fig. 31) [167] should be added.

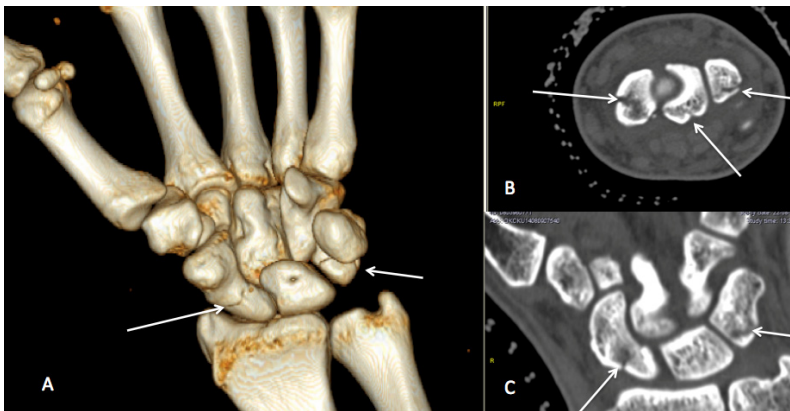


Figure 30: A translunate arc injury

(A) Three-dimensional CT with the scaphoid and triquetral fractures visible. (B) Transectional view showing all three fractures (scaphoid, lunate and triquetral fractures). (C) Coronal view showing scaphoid and triquetral fractures.

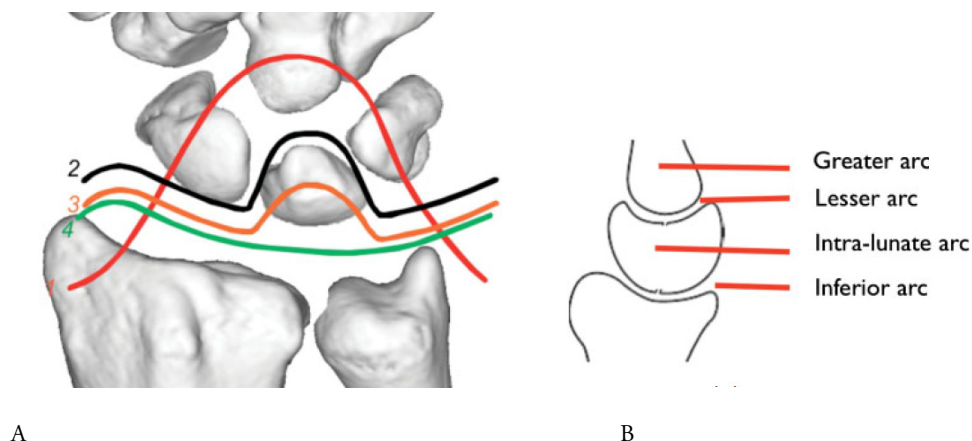


Figure 31: Arc injuries.

(A) Arc injuries, coronal plane. 1: greater arc; 2: lesser arc; 3:transunate arc, 4: inferior arc. (B) Arc injuries, sagittal plane (Illustration from Bain et al. [167] permission granted from publisher).

Herzberg has suggested a new classification of combined carpal injuries without dislocation and has proposed to call them perilunate injuries, not dislocated (PLIND) [168]; furthermore, he argues that these injuries initially could have been dislocated and spontaneously reduced themselves.

Complications

The natural history of scaphoid fractures is unknown. One of the pioneers in research into scaphoid fractures, Nicholas Barton, wrote: ‘We cannot rule out the possibility that some people fracture their scaphoid without knowing and *it* does unite’ [169]. Anecdotal cases exist where a patient sustains a radiographically verified scaphoid fracture but never receive treatment for different reasons (administrative failure, poor compliance, etc.), and then several years later present for radiographic examination for another reason at which time the scaphoid fracture has spontaneously united (Adolfsson, Jørgsholm unpublished cases). This even occurs in some patients with non-unions. Most wrist surgeons have experienced a patient with a established non-union on the waiting list who presents for surgery and in whom new radiographs or CT scans reveal the non-union united without any treatment [170] (Fig. 32). Sehat et al. assessed their hospital’s radiology reports database and analysed almost 3000 radiographs of the wrist taken during a year. They found four undiagnosed scaphoid non-unions, giving a prevalence of 0.14%, and concluded that unrecognized scaphoid non-unions are rare [171].

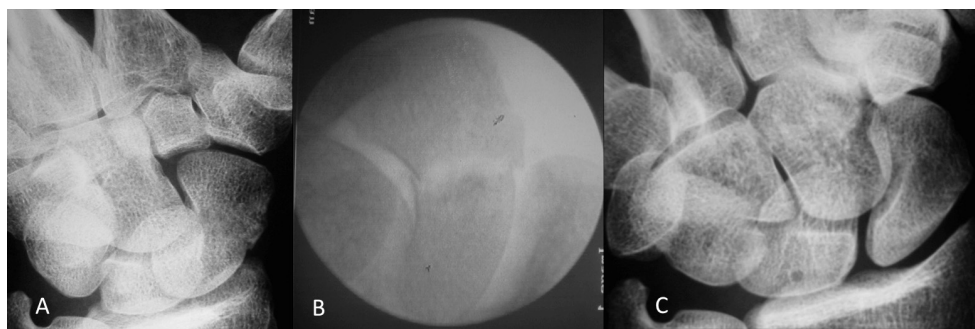

Figure 32: Spontaneous union of a scaphoid fracture that never received any treatment.

(A) 38-year-old clerk with wrist pain 6 month after a fall. (B) Flourescopic close up view of the unstable mobile scaphoid non-union. (C) Radiographs at 12 months after trauma prior to scheduled scaphoid bone grafting and screw fixation. Radiographs indicated union of fracture that was confirmed with arthroscopy and later CT.

The late consequences of a scaphoid non-union are investigated in several studies [172-174]. In conclusion, a non-union will develop into a sclerotic non-union, carpal collapse (humpback), radiocarpal osteoarthritis, midcarpal osteoarthritis, and ultimately global osteoarthritis in the wrist joint (Fig. 33). This sequential process is named scaphoid non-union advanced collapse or SNAC wrist. Patients with an SNAC wrist could be without symptoms for years or even decades; however, all will develop radiographic signs of osteoarthritis after 10 years [174] and 85% will have clinical symptoms after a mean of 26.8 years (12-43years) [173]. Lindström and Nyström concluded that non-union in most cases would progress to symptomatic osteoarthritis with pain, stiffness, and weakness. All these authors recommended an active attitude towards early reconstruction of the scaphoid non-union even in asymptomatic patients, to avoid the aggressive arthritic progression in untreated scaphoid non-unions.

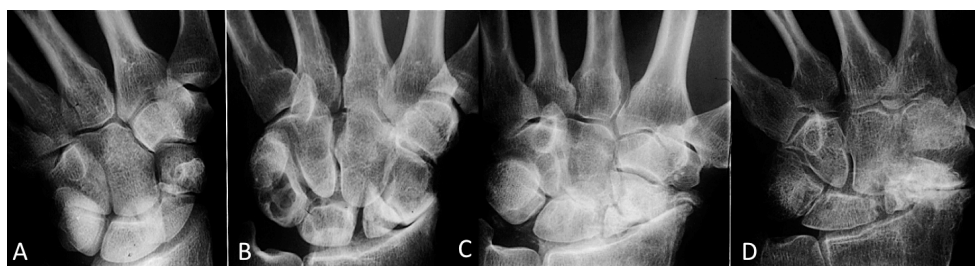

Figure 33: The sequences of SNAC wrist development.

(A) Sclerotic non-union (5-10years). Reconstruction is still possible. (B) Radioscaphoid osteoarthritis (10-20 years). Salvage either with arthroscopic styloidectomy and wrist denervation or proximal row carpectomy. (C) Radiocarpal and midcarpal osteoarthritis (>20 years). Salvage by four corner fusion. (D) Pan wrist osteoarthritis (>30 years). Salvage by wristfusion or total wrist implant. *Indication of time is approximately.*

The Hand Group in Wrightington [175] has proposed a guideline for the prognosis of the reconstruction of scaphoid non-unions. The prognosis will worsen the more proximally the non-union is located and with time from injury to diagnosis. By using advanced statistical calculations (multivariate logistic regression analyses), they depicted a line graph allowing the surgeon to make a prediction about the likelihood of success.

Well-treated scaphoid fractures and non-unions will in the long term develop some degree of osteoarthritis as well; however, they rarely become symptomatic [100, 137, 138, 176-178].

The combined scaphoid fracture and SL ligament injury has a reasonably good prognosis if diagnosed and treated early [155], although less favourable than that of an isolated scaphoid fracture [160, 161].

Complex combined injuries are often high-energy traumas, and some of them part of a dislocation and it is expected that the prognosis is unfavourable even with treatment [145, 153]. Herzberg et al. reported on 104 trans-scaphoid perilunate fracture dislocations, and a long-term follow-up demonstrated poor results in terms of missed diagnosis and cases with open injury. Delay in treatment of more than a week had an adverse effect on outcome. Cases treated with open reduction and internal fixation of fractures, and pinning of ligament injuries had a good clinical outcome; however, radiographic osteoarthritis was common [37].

Aim of Thesis

The overall aims of this thesis were to study the epidemiology of scaphoid fractures and concomitant injuries using radiographs, MRI, CT, and arthroscopy and to compare conservative and surgical treatments of scaphoid fractures.

The specific aims were:

- To describe fractures diagnose by MRI in patients with clinically suspected scaphoid fractures and to assess the diagnostic value of radiographs and CT, using MRI as a reference (paper I and II).
- To compare skeletally mature and immature patients in relation to scaphoid fracture pattern (paper II).
- To determine the incidence of concurrent ligament injuries in scaphoid waist fractures observed with arthroscopy (paper III).
- To evaluate radiologic factors associated with arthroscopic fracture displacement and instability (paper IV).
- To compare time-to-union in scaphoid waist fractures treated conservatively or with arthroscopy-assisted surgery (paper V).

Patients

The study was approved by the Regional Ethical Board at Lund University (LU459-03). The Institutional Review Board at Harvard Medical School, Boston, USA, approved the aspect of the study that involved patients recruited from Boston as described in paper IV. All patients provided informed consent to participate.

Skåne University Hospital, Malmö, serves a population of approximately 280,000 inhabitants. During the period 2004-03-01 to 2007-02-28 440 patients attended our Emergency Department because of posttraumatic radial sided wrist pain, and all patients were asked to participate in a scientific study on wrist trauma. As a result 425 patients agreed to participate in the study and they compose the basis of this thesis.

Paper IV was performed in collaboration with the Hand and Upper Extremity Service, Massachusetts General Hospital, Boston, USA, using patients treated with arthroscopic-assisted screw fixation of scaphoid fractures. Fifteen patients from Boston were included during a four-year period (2006-09-19 to 2010-09-07) and 43 patients from Malmö during a three-year period (2004-03-01 to 2007-02-28).

In paper V, 101 patients were included from Malmö from 2007-03-01 to 2008-02-29. These patients were added to the existing cohort and made up the basis of study V.

Fig. 34 shows an overview of the patients and a timeline of the different studies.

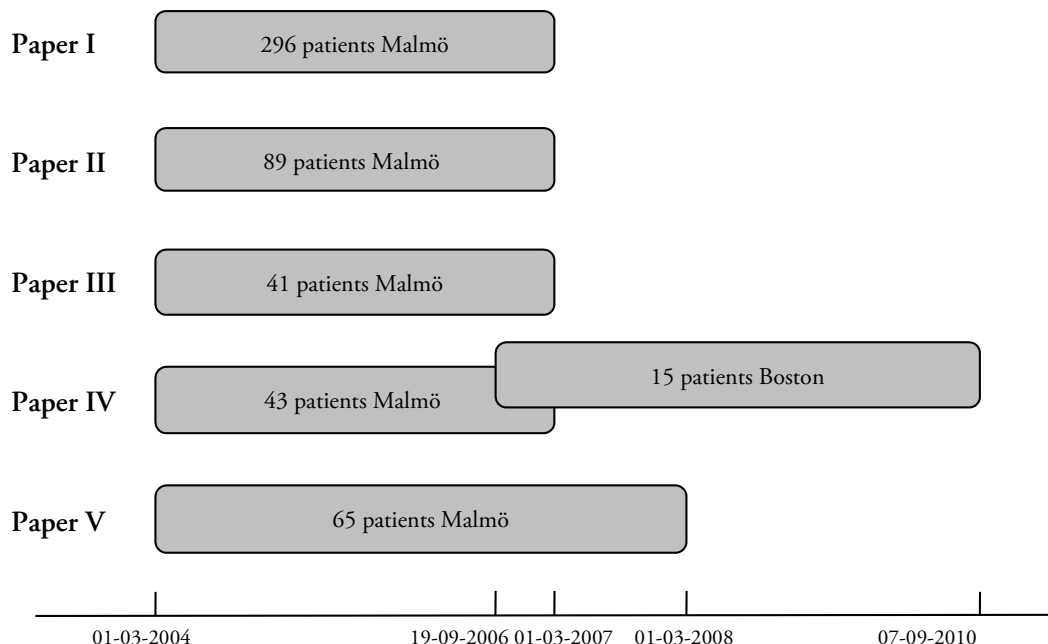


Figure 34: A Schematic timeline and the number of patients in the five studies.

Paper I-II

During a three-year period (2004-03-01 to 2007-02-28), 440 consecutive patients who attended the Emergency Department with clinically suspected scaphoid fractures were asked to participate in a study in which an MRI would be included with the standard radiographic investigation. This resulted in 425 patients who agreed to participate in the study. These 425 patients (431 wrists) were registered in our database. Seven patients were excluded because of an insufficient or unavailable MRI data. Furthermore 33 patients were excluded because more than 14 days had elapsed between the initiation of the injury and the MRI. Therefore, 385 patients (390 wrists) were included in the study. All patients with a confirmed scaphoid fracture on the radiographs or MRI scans underwent a supplementary CT scan.

In paper I, 296 patients (300 wrists) aged ≥ 18 years were studied, with a focus on fracture diagnosis and diagnostic performance of radiographs and CT using MRI as a reference.

In paper II, 89 patients (90 wrists) aged <18 years were studied, with a focus on fracture diagnosis and the diagnostic performance of radiographs and CT using MRI as a reference.

Paper III

During a three-year period (2004-03-01 to 2007-02-28), 129 consecutive patients who attended the Hand Surgery Department with acute scaphoid waist fractures, as diagnosed by radiographic, MRI and CT imaging, were invited to participate in a study on concomitant ligament injuries in scaphoid fractures. All displaced fractures were offered arthroscopy-assisted screw fixation while non- and minimally-displaced fractures were randomized to cast treatment or arthroscopy-assisted screw fixation. Overall, 40 patients (with 41 scaphoid waist fractures), who were selected for surgical treatment, accepted the invitation to participate in the study.

Paper IV

During a six-and-a-half-year period (2004-03-01 to 2010-09-07) at two institutions, consecutive adult patients (≥ 18 years) with isolated acute scaphoid fracture as diagnosed using radiographic and CT investigations were invited to participate in a study on arthroscopically determined displacement and stability. The prospective cohort of surgically treated patients consisted of all radiologically confirmed displaced fractures and a selection of undisplaced fractures based on a preference to avoid cast immobilization (both institutions) or on randomization as part of another study (our institution). The final cohort of 58 patients consisted of 43 patients who attended the Hand Surgery Department, Malmö, and 15 patients who attended the Hand and Upper Extremity Service, Boston, USA.

Paper V

During a four-year period (2004-03-01 to 2008-02-29) consecutive patients aged 16 to 64 years who attended the Hand Surgery Department with acute scaphoid waist fractures as diagnosed with radiographic, MRI and CT investigations were enrolled. This study focused on the time-to-union assessed with CT regardless of conservative or surgical treatment. Overall, 64 patients with 65 scaphoid waist fractures met the eligibility criteria.

Methods

Clinical examination

The attending orthopaedic surgeon at the Emergency Department examined all patients with posttraumatic radial sided wrist pain, who were suspected of having a scaphoid fracture. The clinical examinations consisted of three diagnostic tests: A. tenderness in the anatomical snuffbox (ASB); B. scaphoid tubercle tenderness (STT); and C. pain on longitudinal compression of the thumb (LTC) (Fig. 15). If any of these tests were positive, the patients were referred for a radiographic investigation of the wrist. On the same day, or within one working day, an MRI of the wrist was conducted. If a scaphoid fracture was diagnosed on either investigation, a subsequent CT scan was immediately performed. The patients attended the Department of Hand Surgery directly after completing these radiographic investigations and were interviewed by a research nurse, examined by a hand surgeon, and invited to participate in one of our study-arms depending on the diagnosed injury. If the patient accepted the invitation, they were enrolled in a prospective database, that included a patient questionnaire (appendix 1) that sought information on sex, age, activity when the injury occurred (sport, traffic, work, or other), type of injury (fall, blow, or other), pathomechanism (extension, flexion, or other), and high-energy trauma (defined as a fall from > 1 m of height).

Radiologic examination

The initial radiologic examination (AXIOM Aristos FX; Siemens AG, Forchheim, Germany) of the wrist included posteroanterior and lateral views of the wrist and four views of the scaphoid (posteroanterior with ulnar deviation, and the x-ray beam centred over the anatomical snuffbox angled 10° cranially, 10° caudally, 20° ulnarly, and 20° radially).

The MRI of the wrist was performed with the patient placed prone with arm extended, and pronated (palm down) in the “superman” position. The hand was placed in an MRI wrist coil and secured to minimize patient motion. The MRI was performed on a study-dedicated 0.23 Tesla, low-field MRI unit (PROVIEW; Marconi Medicals

Systems, Vantaa, Finland). The following study protocol was used: coronal STIR, 3 mm slice thickness, coronal T1, 2 mm slice thickness, axial T1 3.5 mm slice thickness and sagittal T1, 2 mm slice thickness.

The wrist CT was performed with patient in the prone position with the hand above the head ("superman" position) to minimize the exposure to radiation. A 16-slice CT scanner (SOMATOM Sensation 16; Siemens AG, Forchheim, Germany) was used for the CT scanning. A scout view was obtained before the scan. Axial sections of 0.6 mm thick slices were obtained with 1 or 2 mm thick reconstructions in the coronal and sagittal planes. A reconstruction for fracture diagnosis along the long axis of the scaphoid was obtained (Fig. 19). Finally 3D images of the wrist were created.

Using radiographs, a fracture was defined as a break in the continuity of bone, while the criteria for fracture on CT images was the presence of a sharp lucent line within the trabecular bone, a break in the continuity of the cortex, or a dislocation of bone fragments. We considered MRI images to be positive for a fracture when cortical and trabecular fractures were present, causing intramedullary hyperintensity on the STIR as well as intramedullary hypointensity on T1-weighted images extending to the cortices. We diagnosed bone marrow oedema when only a zone of diffusely increased signal intensity on STIR images was present without cortical engagement.

The type of fracture was defined according to whether the major part (50%) of the fracture line was situated in the proximal, middle, or distal third of the bone. This was applied to the radiographic oblique view in which the scaphoid is the longest (Fig. 11A). This was supplemented with the information obtained in the 3D reconstructions and the same senior musculoskeletal radiologist (J.B.) evaluated all examinations of the patients from Malmö.

In study IV, a slightly different radiographic protocol was used on the Boston patients. It consisted of two wrist views (posteroanterior and lateral) and two scaphoid views (posteroanterior with ulnar deviation, and semi-pronated oblique). One of three musculoskeletal radiologists (two in Boston one in Malmö) and the treating physician evaluated all radiological examinations to reach a consensus on a fracture (defined as discontinuity of bone), displacement (either gapping and/or translation greater than 1 mm, or dorsal tilting of the lunate greater than 15° with respect to the radius on a true lateral radiograph with the third metacarpal parallel to the radius), and comminution (more than 2 fracture fragments), of the scaphoid fracture. On static imaging (radiographs and CT), nondisplaced fractures were defined as stable, and displaced fractures as unstable. These evaluations were performed as part of the prospective study, with the exception of the fracture location relative to the apex on the dorsal ridge of the scaphoid, which was performed for the purposes of this specific study, and thus was performed at a later date. A musculoskeletal radiologist determined: (1) whether the fracture location was situated distal or proximal to the apex on the dorsal ridge of the scaphoid by looking for the distal cortical discontinuity in relation to the anatomical landmark of the apex; and (2) whether the fracture was located in the proximal, middle, or distal third by measuring whether the major part (50%) of the fracture line was situated in the proximal, middle, or distal third of the bone. This was applied to the

radiographic oblique view in which the scaphoid was the longest, supplemented with the information obtained from the 3D reconstructions of the CT scans.

In study V, the same senior musculoskeletal radiologist (JB), together with one of the senior authors (NT), did a consensus evaluation of the radiographic examinations. Fracture gap and translation (step-off) were assessed on the coronal and sagittal images of the initial CT scan. The maximum value measured was used to categorize the fracture as: minimal ($\leq 0.5\text{mm}$), moderate (1mm), or severe ($\geq 1.5\text{mm}$) displacement [179]. The degree of union was retrospectively calculated using the sagittal CT reconstructions as described by Singh et al. [76]. The percentage of bone contact over the fracture cross-section at follow-up was graded as 0 to 24%, 25 to 49%, 50 to 74%, 75 to 99% or 100%. The grading was estimated by using average measurements from four sagittal, and coronal cuts. Ultimately, it was determined whether the fracture had united, and defined as, not just bone contact, but as a continuous trabecular pattern over more than 50% of the cross-section of the fracture [78, 114]. CT scans were obtained at injury and then at 6 weeks, 10 weeks, and 14 weeks, and 6 months and 12 months.

Arthroscopic surgery

The surgeries performed in paper III, IV and V all used a similar set up. The arthroscopy was performed under an axillary block or general anaesthesia with the patient lying supine, with the arm on the arthroscopy table, the elbow flexed 90°, and the forearm pronated in a wrist support. A tourniquet on the upper arm was inflated to 200-250 mm Hg and the hand was positioned in a vertical traction tower (Fig. 28). Three to five kilogram of traction was applied using fingertraps on the index and long fingers. A 1.9-mm or 2.7-mm arthroscope was used in combination with a motorized shaver to clear the joint of blood, debris, and synovitis. The arthroscopic cannula allowed water in-flow by gravity and out-flow through either a 16 or 18 gauge needle. The standard 3–4 and 4–5 intercompartmental portals and the 6R (radial) and 6U (ulnar) on each side of the sixth compartment were used in the radiocarpal joint. In the midcarpal joint, the standard radial and ulnar portals were used and, in some cases, supplemented with the STT joint portal; no volar portals were used.

The guidewire and the cannulated screw were inserted through the 3–4 portal while the scope was in the 4–5 portal. With the wrist in maximum flexion (60–70°) and slight ulnar deviation (Fig. 28A) a 1.0 mm guidewire was introduced into the scaphoid, as volar as possible in the proximal pole close to the SL ligament. The guidewire was drilled 45° in the radial direction aiming centrally toward the thumb base into the proximal pole. The scope was then introduced to the midcarpal joint and any interposition in the fracture interval removed by probe and shaver. If any displacement was seen, reduction was performed by manipulation in the traction tower and/or by using probes/periosteal elevators. In some cases 1.25 mm K-wires were used as joysticks in proximal and distal portion of the scaphoid to manipulate the fragments. When reduction was achieved, the guidewire was drilled into the distal fragment and advanced

into the STT joint to secure it and the position was controlled on the image intensifier. Drilling over the guidewire was performed with simultaneous fluoroscopic guidance and the midcarpal arthroscopy during placement of the cannulated screw was performed to verify fracture compression. If any sign of distraction was observed during screw insertion either further drilling or shorter screw length was chosen. Finally, screw placement was documented with fluoroscope (Fig. 28B). When complete scapholunate ligament injury was diagnosed, supplementary scapholunate repositioning was secured with two 1.25 mm K-wires as seen in Fig. 35.

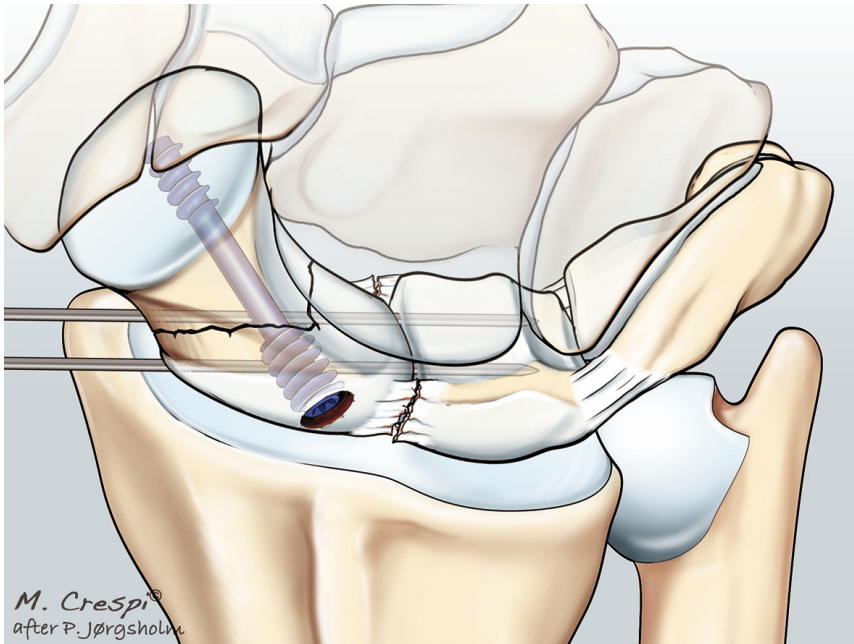


Figure 35: The combined injury scaphoid waist fracture and SL ligament rupture.

Arthroscopy-assisted screw fixation of the scaphoid fracture and temporary percutaneous K-wire fixation of the SL joint.

Headless Bone Screw© (Martin, Tutlingen, Germany) diameter 3.0 mm, Twinfix© (Stryker, Kalamazoo, MI, USA) diameter 3.2 mm and Headless Compression Screw© (Synthes, Oberdorf, Switzerland) diameter 3.0 mm were used for fracture fixation (Fig. 25).

All surgical procedures were performed by one or two of the authors (P.J., N.T., or A.B.) and the responsible surgeon completed the arthroscopic protocol.

A protocol for arthroscopic evaluation was designed to facilitate uniform reporting (Appendix 2). The different ligaments were defined on a figure, and the surgeon had the option of making his own drawings on a schematic view of a left or right wrist. The SL and lunotriquetral (LT) ligament injuries were categorized according to Geissler [180], while the triangular fibrocartilage complex (TFCC) injuries were categorized

according to Palmer [181]. Injuries to the volar extrinsic ligaments and to the dorsal capsule were categorized as haemorrhage, partial tear, or complete rupture. The volar extrinsic ligaments investigated were the radioscaphocapitate ligament, the long radiolunate ligament, and the short radiolunate ligament, as well as the ulnolunate and the ulnotriquetral ligament.

Conservative treatment

Conservative treatment consisted of immobilization in a standard below-elbow plaster cast, incorporating the thumb up to the interphalangeal joint.

Statistical analysis

All statistical analyses were performed using the statistical software StatXact-6 (Cytel Software Corp., Cambridge, MA, USA), SPSS 20.0 for Windows (SPSS Inc., Chicago, IL, USA), and Microsoft Excel. Statistical methods for binary outcome variables were used in all studies and p-values below 0.05 were regarded as statistically significant. An exact method (Clopper-Pearson) was used for calculation of 95% confidence intervals (CI) in the studies with small sample sizes. Fisher's exact test, chi-square test, the binominal test and the Linear-by-Linear association test were used for hypothesis testing and comparisons of prevalences across groups, and to evaluate trends. The Mann-Whitney U test was used to assess differences in continuous variables across independent groups. p-values below 0.05 were regarded as statistically significant in all studies. Logistic regression was used in one of the studies (paper IV) to identify factors associated with arthroscopic displacement and instability.

Paper I-II

Sensitivity and specificity with 95% confidence intervals (CI) for proportions were calculated using either the standard approximation formula (paper I) or the exact method by Clopper-Pearson (paper II) for the radiographs and for CT (only sensitivity). MRI was used as the reference standard.

Paper III

Fisher's exact test was used to investigate differences in the prevalence of various types of ligament injuries for various fracture types. We also calculated prevalence ratios (PRs) and exact 95% confidence intervals (CIs). An exact test was used, based on the binomial distribution, to test whether the prevalence of selected (binary) outcomes such as high-energy trauma, differed significantly from 50%. Finally the Mann-Whitney test

was used to compare the number of ligament injuries with scaphoid fracture displacement, concomitant fractures, and high-energy trauma.

Paper IV

For bivariate analysis of predictors of arthroscopic displacement and instability, the independent (or explanatory) variables that we investigated included age, sex, energy of trauma, fracture comminution on radiographs, fracture location (proximal third, middle third, or distal third), fracture location relative to the apex on the dorsal ridge on CT, scapholunate ligament injury detected during arthroscopy, and surgical delay. We evaluated continuous explanatory variables (e.g., surgical delay) with the Mann Whitney U test, and categorical variables (e.g., comminution) with the chi-square test or Fisher's exact test.

We included factors with p-values <0.10 in bivariate analysis into backward stepwise multivariable logistic regression models seeking to identify factors associated with arthroscopic instability and displacement.

Paper V

The presence of a linear trend between the degree of fracture dislocation and fracture union at 6 weeks was tested using the Linear-by-Linear association test. We evaluated differences in union of randomized non-, or minimally-displaced scaphoid waist fractures with a Fisher's exact test.

Results

Paper I Radiographs and CT are less sensitive in diagnosing carpal fractures compared to MRI.

The aim of this study was to describe fractures revealed by MRI in skeletally mature patients with posttraumatic radial wrist pain and clinically suspected of having a scaphoid fracture. Furthermore, to evaluate the diagnostic performance of radiographs and CT with MRI as the reference. This study consisted of 296 consecutive adult patients (330 wrists) with an acute wrist trauma (<2 weeks).

We identified 224 fractures in 196 of 300 investigated wrists (Fig. 36A). Overall, 125 scaphoid fractures were found, of which, 18 were associated with another fracture. The most common fracture combination was scaphoid and distal radius (n=10) followed by a combined fracture of the scaphoid and the capitate (n=7) (Fig 36B). MRI revealed a scaphoid fracture in 42% of the injured wrists. The overall sensitivity of radiographs for diagnosing a fracture was 54%, with MRI as the reference. The sensitivity was 70% for diagnosing a scaphoid fracture and 59% for triquetral fractures and below 50% for distal radius, metacarpal and other carpal fractures. Using CT imaging, it was possible to visualize 116 scaphoid fractures corresponding to 95% sensitivity, all hamate fractures (100% sensitivity), 7 distal radius fractures (78% sensitivity) and 6 capitate fractures (75% sensitivity).

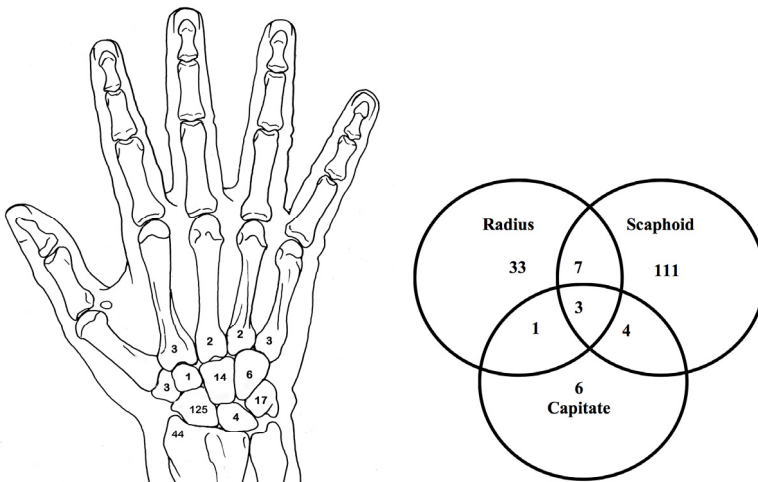


Figure 36:

(A) Fracture distribution in 196 wrists.

(B) Distribution of combined fractures in 165 wrists.

Paper II Children and adolescents have a specific fracture pattern dependent on skeletal maturity.

The aim of this study was to describe fractures revealed by MRI in patients below 18 years of age with posttraumatic radial wrist pain and clinically suspected to have a scaphoid fracture. Assessing the diagnostic performance of radiographs and CT with MRI as the reference, was also an aim of the study. Finally, we wanted to describe the location of the scaphoid fractures and compare scaphoid fracture patterns between skeletal immature and mature patients. The study consisted of 89 consecutive paediatric patients (90 wrists) with an acute wrist trauma (<2 weeks).

We found 73 fractures in 61 of 90 investigated wrists. Forty-eight scaphoid fractures were found of which 10 were in association with another fracture. The most common fracture combination was scaphoid and capitate fractures ($n=5$) followed by combined fractures of the scaphoid and the distal radius ($n=3$). MRI revealed a scaphoid fracture in 53% of the injured wrists. The overall sensitivity of radiographs for diagnosing a fracture was 47%, with MRI as reference, while sensitivities of 54% and 50% were found for diagnosing scaphoid and distal radius fractures, respectively. A sensitivity below 50% was revealed for the other carpal fractures. Using CT imaging it was possible to visualize 43 scaphoid fractures corresponding to 96% sensitivity, all distal radius, hamate and trapezoid fractures (100% sensitivity), 4 capitate fractures (67% sensitivity), and half of metacarpal and triquetral fractures (50% sensitivity). The anatomical distribution of all 48 scaphoid fractures, detected on MRI, is summarized in Figure 37A. The fracture patterns in patients with open physes were different from patients with closed physes; but, not significantly ($p>0.05$). In skeletally immature patients (open first metacarpal physes), distal and waist fractures were equal common and no proximal fractures were found (Fig. 37B). In skeletally mature patients (closed first metacarpal physes) waist fractures were the most common fracture (Fig. 37C).

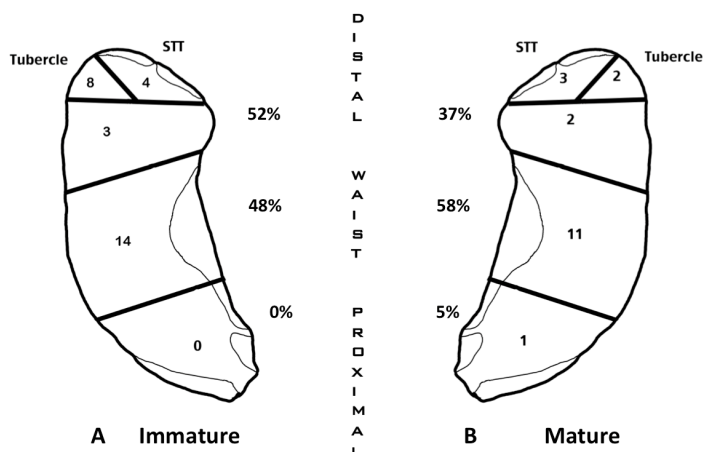


Figure 37: Anatomical distribution of scaphoid fractures.

(A) Fractures in immature scaphoids (open physe 1st metacarpal). (B) Fractures in mature scaphoids.

Paper III Scapholunate ligament injury is common in patients with scaphoid waist fractures.

The aim of study III was to determine the incidence of intrinsic and extrinsic ligament injuries using arthroscopy as the reference, in 40 patients with scaphoid waist fractures. During arthroscopy we found SL ligament injuries in 29 of 41 injured wrists, of which 10 had a complete tear (Fig. 38) and the overall number of SL ligament injuries did not differ between undisplaced and displaced fractures ($p>0.30$). No significant differences were demonstrated between the severity of the SL ligament injury (Geissler grade 1–2 vs. Geissler grade 3–4) and scaphoid fracture displacement ($p>0.30$). In patients with partial SL ligament tears, the injuries were found in the dorsal ligament component in 17 of 19 wrists. We found partial LT ligament injury in 8 wrists. There was no difference in the number of LT ligament injuries between undisplaced and displaced fractures ($p>0.30$). When comparing the number of minor LT ligament injuries (Geissler grade 1–2) with that of major ligament injuries (Geissler grade 3–4), no significant differences could be found between the severity of the LT ligament injury (Geissler grade 1–2 vs. Geissler grade 3–4) and scaphoid fracture displacement ($p>0.30$). An acute traumatic tear of the TFCC was observed in 11 wrists. Furthermore there were significantly more dorsal capsule ruptures among patients with displaced fractures ($p<0.001$). The number of intrinsic ligament injuries did not correlate with any of the following factors: fracture displacement, concomitant fracture, or the involvement of high energy ($p>0.30$; $p=0.14$; $p>0.30$).

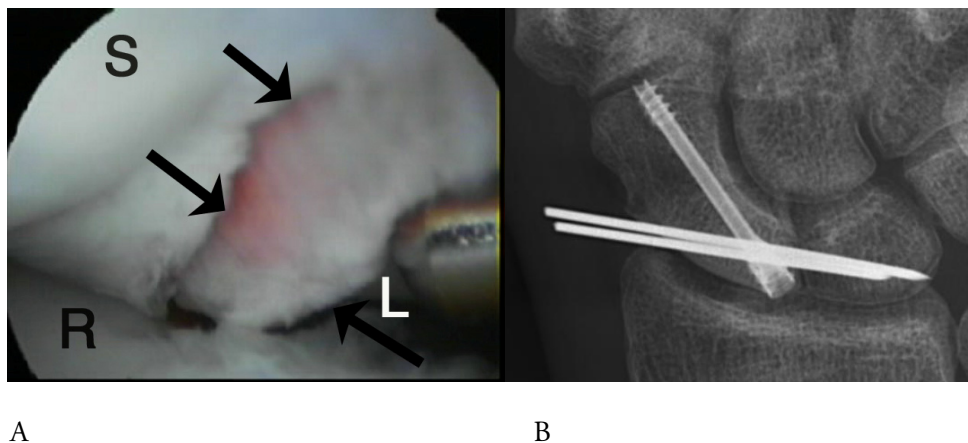


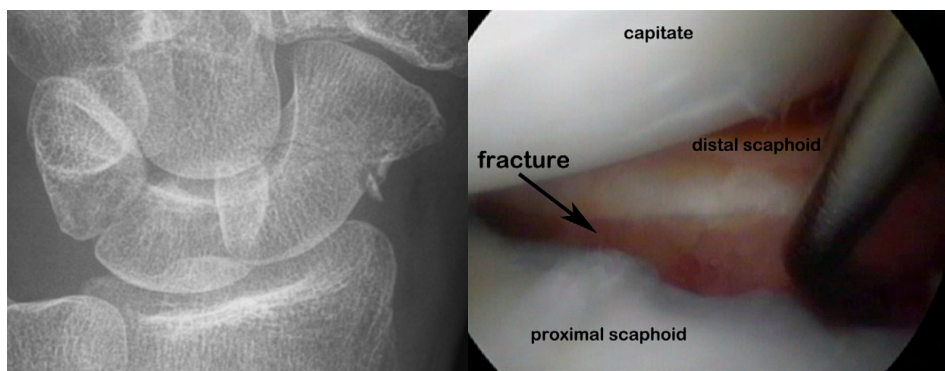
Figure 38: Complete SL ligament rupture was found in 24% of scaphoid waist fractures.

(A) Radiocarpal joint in a right wrist (S, scaphoid; R, radius; L, lunate). Arrows indicate fresh, sharp edges, and hemorrhage in a completely torn SL ligament. Shaver blade seen far right. (B) Same wrist after arthroscopy-assisted screw fixation of the scaphoid fracture and K-wire pinning of the SL joint.

Paper IV Radiographic scaphoid comminution is associated with fracture instability.

The aim of study IV was to identify radiographic factors associated with arthroscopically diagnosed fracture displacement and instability in 58 consecutive patients with a scaphoid fracture.

Arthroscopy revealed 38 unstable fractures (66%), 27 of which were also displaced (47%). One of 31 arthroscopically undisplaced fractures and 18 of 27 arthroscopically displaced fractures exhibited radiographic comminution. There was no comminution in the 20 arthroscopically stable fractures, and 19 of 38 arthroscopically unstable fractures exhibited comminution (Fig. 39AB). The odds of a comminuted fracture correlating with displacement and instability were about 50 times greater than for a non-comminuted fracture ($p \leq 0.001$). In other words, fracture comminution was strongly associated with both displacement and instability.



A

B

Figure 39: Comminuted scaphoid fractures are unstable.

(A) Radiographically comminuted undisplaced scaphoid waist fracture. (B) Arthroscopy showed that the fracture was unstable and could easily be displaced with the probe.

Paper V Ninety percent of non- or minimally-displaced waist fractures unite after six weeks of conservative treatment.

The aim of study V was to assess the union of scaphoid waist fractures based on CT scans at six weeks on all fractures. Furthermore to compare the time-to-union between conservative treatment and arthroscopy-assisted screw fixation in a randomized subgroup with non- or minimally-displaced waist fractures. In this study, we enrolled 65 consecutive patients with scaphoid waist fracture.

Fracture comminution, represented by a separate cortico- or cortico-spongy fragment on the radial side of the scaphoid, on radiographs was common (54%), even in the non- or minimally-displaced fractures (34%). In the conservatively treated group, the CT scans at six weeks demonstrated that 27 of 30 (90%) of the non- or minimally-

displaced fractures had united. In the operatively treated group the union rate at six weeks for non- or minimally-displaced fractures was 82% and decreased to 40% for the severely displaced fractures. It was noticed that severe displaced waist fractures (Fig. 40 B) had a tendency toward longer time to union ($p=0.06$) and furthermore, two weeks of immobilization seems sufficient after stable screw fixation. In the randomized subgroup of patients with non-, or minimally-displaced scaphoid waist fracture, 23 were treated with cast immobilization, and 15 went through an arthroscopy-assisted screw fixation. In the conservative group 19 (83%) of the fractures were united after six weeks, 22 (96%) after 10 weeks, and all 23 at 14 weeks. All four fractures that united later than after six weeks were comminuted (Fig. 40 A). In the operated group 12 fractures (80%) had united after six weeks, increasing to 14 (94%) after 10 weeks. One fracture did not unite until one year.

We were not able to demonstrate any significant difference in union rate between the two treatment groups at any measure point ($p=1.00$). The majority of non-, or minimally-displaced scaphoid waist fractures united after six weeks of conservative treatment with a cast (Fig 40 C & D).

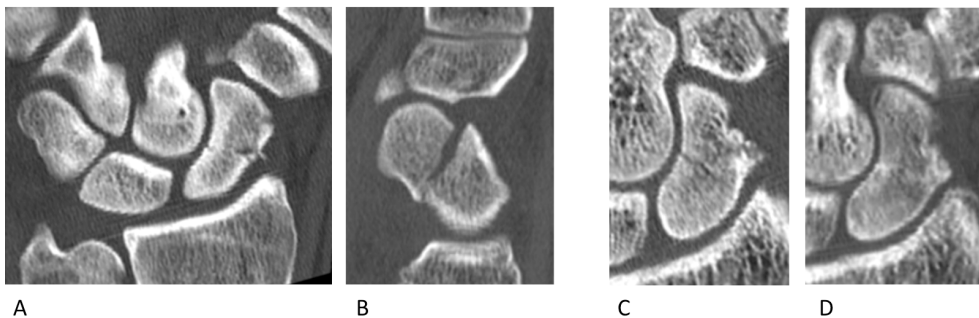


Figure 40: Different types of scaphoid waist fractures.

(A) Comminuted waist fracture. (B) Displaced waist fracture. (C) Undisplaced waist fracture (D) Same fracture as C united at 6 weeks.

Discussion

During one-year Larsen and co workers [182] found 460 distal radius fractures and 57 scaphoid fractures in patients ≥ 15 years in a population of 250,000 inhabitants. The incidence of distal radius fractures was 8 times as high as the incidence of scaphoid fractures. A Medline database search (November 2014) on scaphoid fracture revealed 2351 published articles compared to 5166 publications on distal radius fractures. Apparently more is written about scaphoid fractures taken in account that they are less frequent. The difficulties around the fractured scaphoid are numerous. The diagnosis is difficult, the classification controversial and the treatment has been debated for decades and no consensus has been reached.

The classical clinical tests on patients with posttraumatic radial wrist pain is agreed to be anatomical snuffbox tenderness, scaphoid tubercle tenderness and pain at longitudinal compression of the thumb. Combined they will have a better specificity without losing the sensitivity [183, 184]. The allocation of patients in this thesis was depending on these initial three clinical tests at the time when the patient attended the Emergency Department. In paper I and II the interval from trauma to clinical examination was less than 2 weeks. As the timeline ranged from hours to weeks we enrolled all patients with one or more positive tests (ASB, ST, and LCT)(Fig. 15) [51, 53]. Thereby we theoretically missed few patients with potential false negative clinical tests.

The clinical tests were done when the patients had their first visit at the Emergency Department. Prior to the initiation of this thesis, doctors at the Orthopaedic Department, who are serving the trauma unit, were instructed in these clinical tests. During the entire study period all investigating doctors were orthopaedic surgeons with at least 2 years of experience.

Radiology

There is general consensus that the first-line of radiologic investigation in patients with a suspected scaphoid fracture is wrist radiographs with an addition of two to four scaphoid views. Radiographs are good at ruling in a fracture (high specificity) [54, 60]. All our patients had two wrist views and four scaphoid views except for the Boston patients, who had two wrist views and two scaphoid views. If radiographs are negative and clinical suspicion persist, the second-line of investigation is controversial.

BS has been in clinical use since the early 1980's [185] and was the gold standard in clinical suspected scaphoid fractures with negative radiographs for decades. It has a very high sensitivity, which means it is good at ruling out a scaphoid fracture. It has a low specificity compared to MRI and CT [60] and furthermore a 10 times as high radiation load compared to CT [54]. For these reasons we chose not to use BS in our studies.

The use of CT in scaphoid fractures has been in practise since the late 1980's initially to evaluate scaphoid non-union [66, 67]. With the introduction of multi-slice technique and better software the quality of the produced pictures has been improved and it has gained increased popularity as second-line investigation in suspected scaphoid fractures [70, 186, 187]. Often it has a good availability and a fast protocol. It has been reported to have a lower sensitivity than BS and MRI [60] and a certain radiation load to the patient, although less than BS. We used CT scan in this thesis on all scaphoid fractures that were confirmed by radiographs or MRI to evaluate CT's sensitivity with MRI as the gold standard. Furthermore fracture location and type was noted for allocation to the different clinical studies (paper III-V).

Since the work with this thesis started the technical development has evolved and the 16-slice scanner used in these studies has been bypassed, and 64-slice and 128-slice scanners are now standard in many hospitals. These new scanners probably have an increased sensitivity in diagnosing carpal fractures. A reconstruction in the long axis of the scaphoid with slices < 1 mm [68] is of vital importance in scaphoid fracture diagnostics with CT scans. Earlier the CT scanning was done in the long axis of the scaphoid [67], but today it is often reconstructed digitally from thin axial slices (Fig. 19).

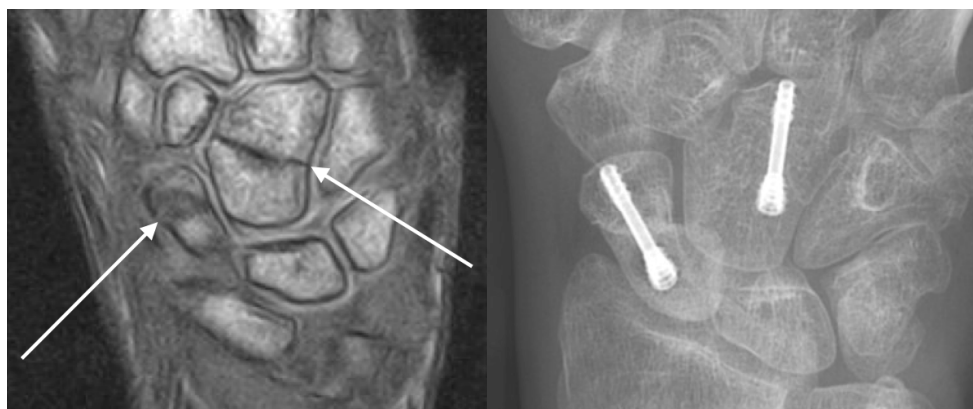
All patient in the cohort from Malmö had MRI investigation regardless of the findings on the radiographs. We used a low-field MRI scanner of 0.23 Tesla as this was available for scientific purposes. In this thesis 531 wrists were scanned during a four years period. That would not have been possible with the capacity of high-field scanners at our Radiologic Department at the time being. We did not report on soft tissue injury, as the quality of our images was not sufficient for the diagnosis of ligament injuries. On the other hand, we found the quality of images of a low-field MRI scanner adequate to differentiate the relevant fracture characteristics in our study, and we were able to distinguish between a bone bruise and a real fracture. We did not encounter any false positive MRI scans among the patients in our arthroscopy studies. Some of these fractures were not detectable on radiographs or even CT, but easily visible during midcarpal arthroscopy. Low-field MRI scanners have been used in several scaphoid fracture studies with a reported high sensitivity and specificity [188-191]. Low-field scanners are often termed dedicated extremity scanners [192].

High-field scanners of 3.0 Tesla strength combined with dedicated wrist joint software and Gadolinium injection (indirect arthrography) would probably increase the sensitivity for diagnosing ligament injuries.

In paper I and II we found a high incidence of fractures in adult and paediatric patients with posttraumatic radial wrist pain. In both MRI studies approximately 65% of the patients had a fracture, and scaphoid fracture was the most common fracture found in 42% of the attending adults and 53% of the attending paediatric patients. This is in contrast to true scaphoid incidences found in other studies. The true incidence of scaphoid fracture is reported to range from 14% [90] relying on radiographs at 2 weeks as reference and 16-26% [40, 51, 86] relying on advanced imaging as the second-line reference. In this thesis the investigating orthopaedic surgeon at the Emergency Department had not less than two years of experience and was confident in acute wrist examination. This could be one factor of importance for the high true scaphoid incidence found. We generally found more fractures than previously reported probably because MRI was used in all patients.

Many radiographic occult fractures were found. When we calculated the sensitivity of radiographs in adults it reached 70% in scaphoid fractures, 59% in triquetrum fracture and 43% in distal radius fractures. For other fractures the sensitivity was poor and especially for capitate and hamate fractures, where it only reached 7% and 0%, respectively. Using CT imaging the sensitivity reached 100% in hamate fractures, 95% in scaphoid fractures, 78% in distal radius fractures, and 75% in capitate fractures. In paediatric patients the sensitivity of radiographs was found to be 54% in scaphoid fractures, 50% in distal radius fractures, 33% in triquetral fractures, and 0% in other carpal fractures. Using CT imaging the sensitivity reached 100% in distal radius, hamate fractures, and trapezoid fractures, 96% in scaphoid fractures, and 67% in capitate fractures.

As these calculations show, radiographs have sensitivity below 50% for detecting other carpal fractures than the scaphoid and triquetrum fractures. A capitate fracture is unlikely to be diagnosed by plain radiographs (Fig. 41A). In the paediatric patients the sensitivity of radiographs is even lower and only one other carpal fracture, than scaphoid fracture, was found (triquetrum fracture). CT imaging has a higher sensitivity than radiographs, but surprisingly low sensitivity in certain carpal fractures as the capitate. Apparently radiographs and CT scans have less sensitivity for immature paediatric carpal bones.



A

B

Figure 41: Combined scaphoid and capitate fracture in an adult patient after high-energy trauma. The capitate fracture not visible on radiographs.

(A) Coronal T1 weighted MRI scan with white arrows indicating the scaphoid and capitate fracture lines. (B) Postoperative AP radiographs with stabilizing cannulated screws (arthroscopy-assisted surgery).

The explanation for the slightly different fracture pattern found in paediatric patients is speculative: the ossification starts in the capitate and thus this bone is relatively hard and brittle even in the youngest patients in our cohort and more likely to fracture than the soft and cushioned surrounding immature bone. This could account for the higher incidence of capitate fractures in children and adolescents. The ossification of the scaphoid starts distal, which could explain the higher numbers of distal scaphoid fractures in the younger immature patients, whereas waist fractures become more common with increased maturity.

In the paediatric cohort we compared the fracture location in skeletal mature and immature patients and found more distal fractures than reported by Gholson et al. [49]. We used the closed physes of the first metacarpal as indicator for a mature scaphoid. An explanation for the difference could be, that the physes of the distal radius were used in Gholson et al. comparative study. Furthermore we had initial MRI and CT on all patients, whereas Gholson et al. reported that only 64% of the patients had MRI or CT often at a later date. As radiographs will diagnose only half of the paediatric scaphoid fractures and the distal scaphoid fractures are most likely to be missed, – this could be an explanation to the difference.

Combined fractures were found in adult and paediatric wrists in 7 and 11%, respectively. In adults the most common fracture combinations were scaphoid and radius fractures (n=10) followed by scaphoid and capitate fractures (n=7)(Fig. 41). In children and adolescents scaphoid and capitate fractures (n=5) were most common followed by scaphoid and radius fractures (n=3). MRI studies in wrist traumas are numerous [71, 93, 193, 194]. All these investigations of clinically suspected scaphoid

fractures are patients with negative radiographs. In our studies all patients attending with radial sided wrist pain, regardless of findings on radiographs had a MRI investigation. To our knowledge no study with this design has been published before. The use of MRI could explain the high number of combined fractures found in our studies, as many obvious scaphoid fractures would never proceed to advanced imaging and many occult combined carpal fractures thereby never diagnosed. In our entire cohort of 198 scaphoid fractures a concomitant fracture was found in 33 (17%) often a carpal fracture.

The clinical implication of these findings is that a good clinical investigation for patients with posttraumatic radial wrist pain is essential. By using a algorithm (Appendix 3) and narrowing the amount of patients with clinically suspected carpal fracture and negative radiographs fewer patients will need an early MRI wrist scan. This has been shown to be a cost-effective strategy [53, 89, 195]. The MRI findings of other carpal fractures will explain why some 'x-ray negative sprains' [94] have an extended period with pain. Unnecessary repeated fracture clinic visits could be avoided by early diagnosis. The combined fractures (more than one fracture) often are high-energy traumas and CT scan will tell, whether these are displaced, comminuted and maybe part of a perilunate injury, not dislocated (PLIND), that needs special surgical attention. We therefore recommend MRI or CT scans to all high-energy trauma patients with radial wrist pain regardless of radiographic findings.

Arthroscopy

Prior to our study series, we experienced some patients with undisplaced scaphoid waist fractures, where we had unexpected findings. These patients had been offered arthroscopic surgery, and intraoperatively we found serious concomitant ligament injuries. This observation made us aware of possible combined injuries, and we decided to have a dedicated protocol for arthroscopic findings during our arthroscopic scaphoid studies.

In paper III 41 scaphoid waist fractures were allocated for surgery and 29 had some degree of scapholunate ligament injury. Ten wrists had a complete rupture of the SL ligament and thereby a proximal scaphoid fragment, that had lost its distal and proximal anchoring points (Fig. 42). We decided to treat these injuries with screw fixation of the scaphoid fracture and K-wires fixation of the SL joint (Fig. 35 & 38B) and a postoperative plaster treatment for six weeks. Many minor ligament and TFCC injuries were found, but these were rated as less clinically important and not treated. The ligament injuries were independent of fracture displacement or level of energy. The many SL injuries and the high frequency of dorsal capsule injury suggest, that such injuries might represent a subluxation or dislocation injury that subsequently reduced spontaneously recently named PLIND by Herzberg [168] (Fig. 42).

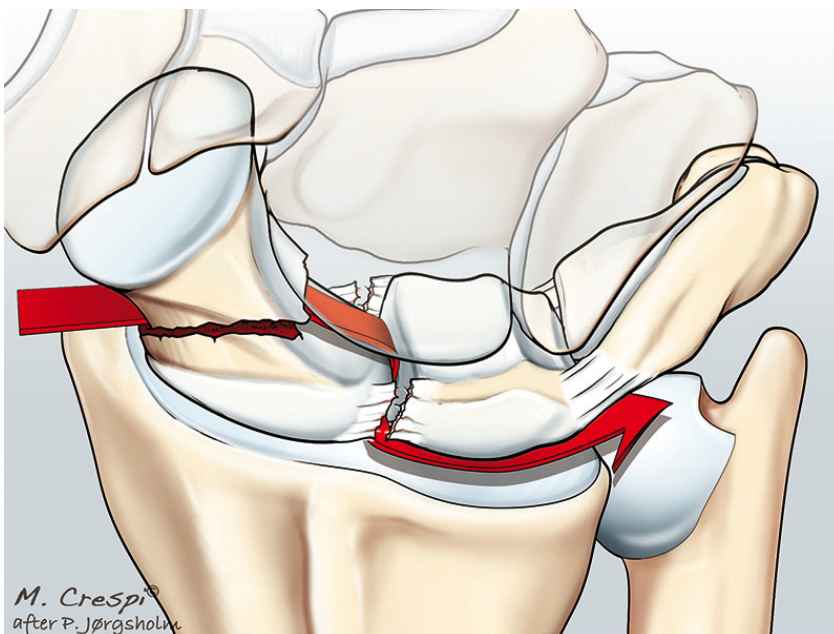


Figure 42: Combined scaphoid fracture and SL ligament rupture

Perilunate injury without dislocation (PLIND) – transscaphoid perilunate variant.

These injuries are very unstable and the vascular supply to the proximal scaphoid is disrupted at the fracture and rupture site and potentially at risk of developing a non-union. Given our findings in paper III, we recommend arthroscopy to assess and treat associated intrinsic ligament injuries, if the treatment offered for the scaphoid fracture is stable fixation and mobilization. Scaphoid non-unions are not as common, as the SL ligament ruptures found, and late SLAC-wrists are rarely found clinically in united scaphoid fractures. Therefore we assume that these combined injuries most often heal by conservative treatment. Long term follow up (13-15 years) of distal radius fracture with concomitant SL ligament injury (Geissler grade 3) has not been able to show any sign of static SL dissociation or development of SLAC-wrist [203].

Radiology and arthroscopy

During our arthroscopic registration of the scaphoid fractures we noted that it was difficult to predict fracture stability, as judged by arthroscopy from the radiographs. Our colleagues from Boston had encountered the same problem, and after a joint meeting, we decided to explore if any radiographic sign could predict fracture stability. Displacement is often used interchangeably with instability, and displacement is considered a risk factor for non-union [77]. Some studies have suggested, that non-unions placed distal to the apex of the dorsal ridge of the scaphoid usually are unstable

[196, 197] and that it may apply for acute fractures as well. In the two-centre study our patient cohorts were investigated prospectively but pooled retrospectively. All patients had relevant radiographs and CT scans with reconstructions in two planes, defined by the long axis of the scaphoid, and all had midcarpal arthroscopy.

We found no correlation between the fracture localisation in relation to the apex of the dorsal ridge of the scaphoid and arthroscopic verified instability. However, we found a strong correlation between fracture comminution and both displacement and instability. The combination of displacement and comminution is described to cause instability. It was surprising that comminution in non- or minimally-displaced fractures was correlated with instability. Herbert et al. 1984 described a type B5 comminuted and unstable fracture type in his first published paper on scaphoid fracture classification [120]. In 1998 Compson et al. in a radiographic study described a comminuted fracture type, which was potentially unstable [198]. In 2003 Cooney described this fracture type as unstable, and recommended comminution as an indication for open reduction and screw fixation [199]. These comminuted fractures were often displaced, and we have not been able to find any reports on undisplaced comminuted fractures that exhibit instability as judged by direct palpation.

Conservative and operative treatment

Most authors agree that the majority of scaphoid fractures will unite when treated in a cast for sufficient time [45, 76, 78, 113, 200]. As the patients most often are young active persons the traditional treatment in a cast for several months may have inherent compliance problems, a substantial impact on daily living and a socioeconomic burden for society. Mink van der Molen et al. reported the time off work in carpal injuries to be 155 days in a cohort of 447 patients treated conservatively (98%). Most patients were young men with manual work [133].

The development of minimal invasive techniques in combination with an increasing demand from professional athletes of a quick functional recovery has evolved wrist surgeons globally toward offering percutaneous screw fixation of even undisplaced waist fractures to avoid plaster immobilization [201, 202].

In paper V we evaluated time to union in scaphoid waist fractures by CT at six weeks and compared surgically treated and conservative treated patients (n=65). In a subgroup of randomized patients (n=38) with non- and minimally displaced fractures, time-to-union was followed continuously at 6 weeks, 10 weeks, and 14 weeks and 6 months and 12 months.

We did not find any difference in time-to-union in the surgically treated and conservative treated scaphoid waist fractures. Surprisingly 90% of the non- or minimally-displaced fractures (Fig. 42) treated conservatively had united at six weeks,

which was also the case with 82% of the surgically treated. All conservatively treated fractures from this randomized subgroup, with prolonged time to union, were comminuted demonstrating a radial cortico- or cortico-spongy fragment (Fig. 43).



A

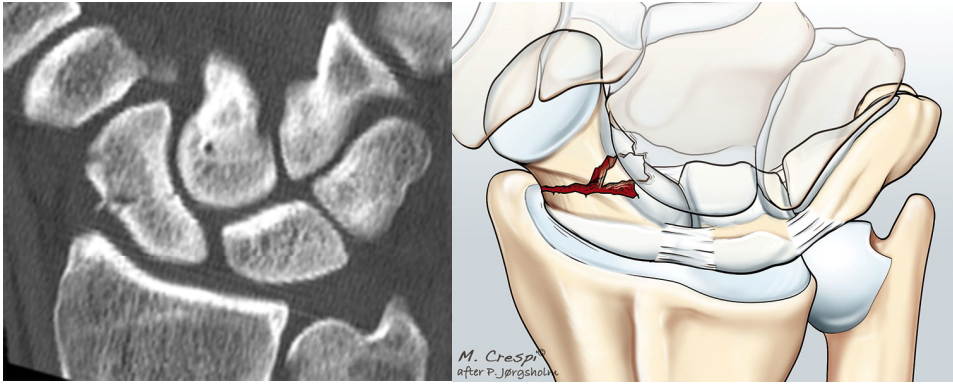
B

Figure 42: Most non- or minimally displaced scaphoid waist fractures unite in a cast.

(A) Coronal CT scan of undisplaced scaphoid waist fracture. (B) Below elbow scaphoid cast ('One down 205 bones to go' Snickers©).

The important clinical conclusion in paper V is, that most non- or minimally-displaced fractures will unite after only six weeks in a cast. The clinical implication of paper IV and V would be, that radiographic scaphoid comminution, often seen radially as a tiny separate fragment (Fig. 43), will warrant CT scan, and information to the patient of a likely prolonged plaster treatment. Minimal invasive surgical treatment could be discussed with the patient, depending on fracture characteristics on the CT scan, the occupation and demands of the patient and his/hers general medical condition.

A comparative larger scale study is needed to determine differences in functional outcome after conservative versus operative treatment.



A

B

Figure 43: Radial comminution in scaphoid waist fracture.

(A) Coronal CT scan with radial cortical comminution. (B) Drawing illustrating the instability in comminuted waist fractures.

Strength and limitations

The strength of this thesis relates to the prospective design with a large cohort from a well-defined area, where the treatment of scaphoid fractures is centralized to our hospital. We had uniform clinical tests as inclusion criteria, standardized protocol for radiographs, MRI scans were done on all patients, and CT scans on all scaphoid fractures. Furthermore we had a randomized subgroup including non- and minimal-displaced fractures. Only the three co-authors participated in the intervention studies in Malmö.

The limitations refer to the fact that we did not perform CT scan on all patients, as it was not feasible at the time being. We used a low-field MRI scanner and a first generation multi-slice CT scanner both with less diagnostic capability compared to standard advanced imaging of today (2014). Low patient numbers in the arthroscopic studies and in the outcome study hampered the possibility to find significant differences among the small groups. In study IV the evaluation of fracture instability was done at two different institutions. Concomitant carpal fractures and SL ligament injuries found in patients randomized for arthroscopic surgery had a different treatment protocol for ethical reasons, and this hampered the outcome study as the operative group was diminished.

Clinical implications

- Diagnostic algorithm for suspected scaphoid fractures (Appendix 3)
- Three view radiographs (PA, Lateral and fist closed and ulnar deviation)
- Fast protocol extremity MRI scanner at the Emergency Department
- Multi-slice CT scans of all carpal fractures
- Treatment algorithm for confirmed carpal fracture (Appendix 4)
- Arthroscopy mandatory in percutaneous screw fixation
- CT scan as routine at six weeks in 'simple' scaphoid fractures
- CT scan at 10-14 weeks in all conservative and surgical treated

Future perspective

- Study on the natural history of combined scaphoid fracture and SL injury
- Study on the sensitivity of low- and high-field MRI scanners
- Study on the sensitivity and specificity of multi-slice CT
- Study on cost-effectiveness of CT to assess union at 6, 10, and 14 weeks
- Study on high-field MRI Gadolinium enhanced scanning of SL injuries
- MRI soft and hardware improvement for SL diagnostics
- CT soft and hardware improvement for fracture characteristics
- Cone-beam CT scanners for diagnostic and intraoperative use
- Stereotactic computer-guided surgery of the scaphoid
- Bone growth factors added intraoperatively in scaphoid fractures

Conclusion

- Radiographs and CT are less sensitive in diagnosing carpal fractures compared to MRI.
- Children and adolescents have a specific fracture pattern dependent on skeletal maturity.
- MRI reveals many concomitant carpal fractures and the most common combination is that of a scaphoid and a capitate fracture
- Scapholunate ligament injury is common in patients with scaphoid waist fractures.
- Radiographic scaphoid comminution is associated with fracture instability.
- Ninety per cent of non- or minimally displaced waist fractures unite after six weeks of conservative treatment.

Summary in Swedish

Populärvetenskaplig sammanfattning

Båtbenet är ett lite ben i handloven som är väsentlig för handledens funktion. Båtbenet kan skadas om man ramlar och tar emot med handen, och den skadade är ofta en ung man, som inte sällan håller på med sport. Man ser ingen felställning på handledens utsida, men patienten upplever ofta smärta på handledens tummsida. Röntgen har svårt att påvisa ett brott, eftersom båtbenet ligger djupt inne i handleden och skymms av de andra handlovsbenen och dessutom måste röntgenstrålarna träffa exakt parallellt med brottet, för att det ska synas. Båtbensbrott, som ej gipsas direkt, läker ofta inte och kan då medföra kroniska handledsmärtor. För att inte riskera och missa att behandla ett brott, så gipsar man alla personer med misstänkt båtbensbrott, även om den första röntgenundersökningen inte visar något brott. Efter 2 veckor upprepar man röntgenundersökningen, och då kan man se ett eventuellt brott eftersom läkning synas på röntgen. Magnetkamera undersökning (MR) har däremot en stor träffsäkerhet när det gäller att hitta båtbensbrott, men tyvärr är undersökningen fyra gånger så dyr och tar lång tid.

Under en fyra-årsperiod (2004-03-01 till 2008-02-28) tillfrågades alla patienter, som sökte på akutmottagningen vid Skånes universitetssjukhus i Malmö med ett misstänkt båtbensbrott, om de ville delta i en forskningsstudie. Femhundrajugosex patienter accepterade att delta och de utgör basen för denna avhandling. Våra två första studier undersökte, hur mycket bättre MR är jämfört med vanlig röntgen och datoriserad skiktröntgen (datortomografi, CT). Vi hittade enbart 7 av 10 båtbensbrott med vanlig röntgen men mer än 9 av 10 båtbensbrott med CT undersökning. Hos barn (<18 år) syntes enbart hälften av båtbensbrotten på vanlig röntgen. Många andra brott i handloven hittades enbart med MR. I vår tredje studie gjorde vi titthålskirurgi på patienter med båtbensbrott, och hittade förvånansvärt många ledbandsskador. Ett av de absolut viktigaste ledbanden, det mellan båt- och månbenet, var helt av hos var fjärde patient, och krävde åtgärd med fixering och lång tids gipsbehandling. I den fjärde studie jämförde vi hur båtbensbrott såg ut på vanlig röntgen och CT, med hur brottet såg ut när man opererade med titthåls teknik. Vi kunde konstatera att om båtbenet var brutit med ett mindre benfragment i mellan (splittrat brott), då var brottet mycket ostadigt, och precis detta misstänkas förorsaka långsam eller utebliven läkning. I den sista studien undersökte vi läkningstiden med röntgen och CT hos patienter med brott på mellersta delen av båtbenet. Patienterna lottades till antingen att behandlas med gips eller opereras. Operationen var med titthåls teknik och vi använde en liten special utvecklad skruv till att drar ihop brottet. De patienter som lottades till gipsbehandling var gipsade i minst

6 veckor. Oavsett behandlingsmetod läkte brotten på samma tid, men de patienter som opererades behövde bara ha gips i 1-2 veckor. Brott med förskjutning och/eller splittring hade en benägenhet till att läka långsammare.

Sammanfattningsvis kan man säga att patienter med misstänkt båtbensbrott kan ha många olika skador i handleden, och att vanlig röntgen är dålig på att hitta dessa skador. En akut MR undersökning kan göra att ett stort antal patienter slipper onödig gipsbehandling (cirka 250 patienter per år i Malmö med 280 000 invånare). Nittio procent av alla enkla brott i mellersta delen av båtbenet, vilket är den vanligaste typen, läker med sex veckors gipsbehandling. Patienter som opereras och enbart skall ha gips en eller två veckor, bör undersökas med titthålsteknik för att utesluta att det finns en alvarlig ledbandsskada, som kräver längre tids gipsning.

Summary in Danish

Populærvidenskabeligt resume

Bådbenet er en lille knogle i håndroden, som er vigtig for håndleddets funktion. Brud på bådbenet opstår oftest efter et fald, hvor man tager fra med udstrakt hånd. Den tilskadekomne er typisk en ung sportsaktiv mand. Man kan ikke umiddelbart se nogen fejlstilling eller hævelse af håndleddet, men der vil være en ømhed ved bådbenet. En røntgenundersøgelse har ofte svært ved at påvise et brud, da det kræver, at røntgenstrålerne rammer lige ned parallelt med bruddet. Bådbensbrud, som ikke behandles korrekt, har stor tendens til ikke at hele, hvilket på langt sigt leder til slidgigt, som hos de fleste vil give kroniske håndledssmerter. Derfor behandler man alle mistænkte bådbensbrud med gipsskinne i 14 dage, selvom røntgenundersøgelsen har været normal. Efter 14 dage gentager man røntgenundersøgelsen, og et eventuelt brud vil da ofte kunne ses på røntgen. Kun hver femte person, som kommer på skadestuen med et mistænkt bådbensbrud, viser sig at have et sådant. Mange bliver derfor unødvendigt gipsbehandlet, mens de venter på den anden røntgenundersøgelse. Allerede samme dag man kommer til skade, viser en magnet resonans undersøgelse (MR) med stor sikkerhed, om man har et bådbensbrud, men desværre er undersøgelsen 4 gange så dyr og tager lang tid.

Gennem en fireårsperiode (01-03-2004 til 28-02-2008) blev samtlige patienter som indkom til skadestuen på Skånes universitetshospital i Malmø med mistænkt brud på bådbenet adspurgt om de ville deltage i et forskningsprojekt. 526 patienter accepterede at deltage, og de udgør grundmaterialet i denne disputats. Vores første to studier gik ud på at se, hvor meget bedre en MR undersøgelse er til at vise et bådbensbrud, sammenlignet med en almindelig røntgenundersøgelse og en computer tomografi (CT). Vi fandt kun 7 ud af 10 bådbensbrud med røntgen og mere end 9 ud af 10 ved CT undersøgelsen. Ved børn (<18 år) var kun halvdelen af bådbensbruddene synlige på almindelig røntgen. Mange andre brud i håndroden var kun synlig ved MR undersøgelsen. Hos børn er bruddene oftere lokaliserede i den nedre del af bådbenet. I vore tredje studie foretog vi en kikkertundersøgelse af patienter med bådbensbrud, og fandt overraskende mange ledbåndsskader. Det vigtige ledbånd mellem bådben og måneben var revet helt over i hver fjerde tilfælde og krævede behandling med operativ fiksering og længere varende gipsbehandling. I det fjerde studie sammenlignede vi røntgen og CT fund med stabiliteten af bådbensbruddet, som vi fandt ved en kikkertoperation. Vi kunne konstatere, at hvis bruddet havde et lille separat knoglefragment (splitret brud), så var bruddet ustabil, og netop denne øgede bevægelighed, mistænker vi, kan forårsage langsom eller udebleven healing. I det sidste

studie undersøgte vi, ved hjælp af CT, helingstiden af brud i midten af bådbenet. Ved lodtrækning var nogle patienter udvalgt til operation med kikkerteknik, hvor man med en specielt udviklet skrue trækker bruddet sammen, mens en anden gruppe fik gipsbehandling af håndleddet i mindst 6 uger. Uanset behandlingsmetode helede brudene på samme tid, dog kunne de patienter, som blev opereret, nøjes med gips i 1-2 uger. Forskudte og splitrede brud havde en tendens til langsommere heling.

Som resume konkludere vi, at en akut MR undersøgelse hos patienter med mistænkt bådbensbrud kan stille en præcis diagnose med det samme. Således undgås unødvendig gipsbehandling (cirka 160 patienter per år i Odense med 170.000 indbyggere). Desuden vil en MR undersøgelse kunne påvise eventuelle andre skader. Ved uforkudte bådbensbrud i mellemste tredjedel heler 90% efter 6 ugers gipsbehandling. Hvis man tilbyder operation og tidlig mobilisering, anbefales det, at man ved kikkertundersøgelse sikre sig, at der ikke findes alvorlige ledbåndsskader, som i sig selv kræver speciel behandling og længere varende gipsbehandling.

Acknowledgement

This thesis is the result of years of work during which I received the advice, help and support from many people. This thesis could not have been completed without the participation of the patients and their great patience

In particular, I wish to thank:

Anders Björkman and Niels Thomsen; my latest supervisors from the Department of Hand Surgery, Malmö. For taking over halfway and patiently pace me to the very finish.

Sven Olof Abrahamsson and Göran Lundborg; my first supervisors from the Department of Hand Surgery, Malmö. For letting me start this project from the very beginning.

Jack Besjakov; from Department of Radiology, Malmö. For doing the hard work examining the images over and over again, always in an impressive pace.

Jonas Björk; from the Department Epidemiology, Lund. For excellent guiding in the difficult world of statistics.

Jens Lauritsen; from Accident Analysis Group, Odense. Statistical advice initially.

Per Olof Josefsson; from the Department of Orthopaedic Surgery, Malmö. For invaluable cooperation concerning the patient flow from the Emergency Department.

Anette Persson; from Department of Hand Surgery, Malmö. For excellent assistance in patient and protocol logistics in the different studies.

Fredrik Järnkrants and Marianne Neving; from Department of Hand Surgery, Malmö. For all the work with clinical scoring and patient follow-up.

Tina Folker; Department of Hand Surgery, Malmö. For invaluable secretarial support.

All colleagues and staff at the Department of Hand Surgery. For their friendship and support.

Last, but not least my family for patience and support.

Leslie my wife for linguistic and grammatical corrections of the entire manuscript.

Jens my oldest son for designing the database for paper III.

Bjørn my youngest son for designing the database for paper II.

Appendix 1

Case Report Form 0 Screeningformulär

Screening vid misstänkt scaphoideumfraktur

- Handkirurgmottagning

Screeningsnummer: · _ · _ · _ ·
(röda Pärmen)

Patientinitialer: · _ · _ ·

Ansvarig prövare: Peter Jørgsholm (MD)

Flödesschema

	Screening Akutmott (i rutinsjukvården)	√	Day 1 – 5 Hand.kir.mott	√
Besöksdag				
Läkar.us.	x		x	
Gipsskena	x			
Röntgen	x			
MR			x	
CT (vid scaphoideumfraktur)			x	
Hand.kir.mott			x	
Screening för studier			x	

Handkirurgiska kliniken
Universitetssjukhuset
Malmö

Inklusionskriterier

- | | | |
|--|-----------------------------|------------------------------|
| 1. Patienten har en misstänkt scaphoideumfraktur | Ja <input type="checkbox"/> | Nej <input type="checkbox"/> |
| 2. Patienten är mellan 18 – 65 år | Ja <input type="checkbox"/> | Nej <input type="checkbox"/> |
| 3. Skadan har skett de senaste 7 dagarna | Ja <input type="checkbox"/> | Nej <input type="checkbox"/> |

*Alla inklusionskriterier ovan ska vara besvarade med ja:***Exklusionskriterier**

- | | | |
|--|-----------------------------|------------------------------|
| 1. Annan orsak, som enligt ansvarig läkares bedömning, kan påverka bedömning av utvärdering av patientens data i studien | Ja <input type="checkbox"/> | Nej <input type="checkbox"/> |
|--|-----------------------------|------------------------------|

*Exklusionskriteriet ska vara besvarat med nej:*Vid exklusion önskas följande undersökning:

Klinik 1: Ömhet Tabatieren:	Ja	Nej
Klinik 2: Ömhet axiellt MC I	Ja	Nej
Klinik 3: Ömhet tuber scaphoidei:	Ja	Nej
Annan ömhet: Ja Nej	Var:.....	

Skadeorsak:	Sport_	Trafik_	Arbete_	Annat_	Vad:.....
Skademekanisme:	Fall_	Slag_	Annat_	Högenergi_	Lågenergi_
Handled i:	Extension_	Flexion_	Vet ej _		

Datum för skada	____-____-____
	åå -mm- dd

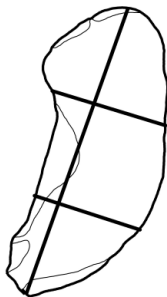
Datum för röntgen av handled	____-____-____
	åå -mm- dd

Datum för MR undersökning	____-____-____
	åå - mm - dd

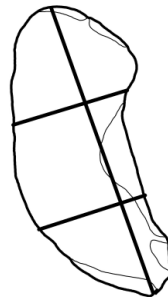
Datum för evt. CT undersökning (vid scaphoideumfraktur)	____-____-____
	åå -mm- dd

Instruktioner för ifyllande av CRF sida 4:

- Fyll i det datum patienten gör sitt besök på handkirurgmottagningen.
- Bocka av i respektive ruta resultatet av röntgen och MR.
- Kryssa för om frakturen är dislocerad, dvs. mer än 1mm diastas eller förskjutning från CT eller mätas med lineal på röntgenbilden direkt.
- Kryssa i vilken 1/3 frakturen är placerad och markera på skissen. (>50% av frakturspalten ska vara i den förkryssade tredjedelen på den rttg projektion där scaphoideum är störst)



Vä



Hö

- Avgör därefter om patienten uppfyller kriterierna för att delta i någon av delstudierna. Bocka av det alternativ som patienten tar plats i.
- Patientinformation och samtycke enligt studieprotokol
- CRF formulär och uppföljning ska ske enligt varje delstudie.
- Intyga med namnteckning att handläggningen av patienten är klar.

Verifierar att patienten är handlagd enligt studieplaneringen enligt någon av ovanstående delstudier om inte patienten avböjt att delta.

.....
Läkare som handlagt och ansvarat för patienten på hand.kir.mott. Datum

SCREENING PÅ HAND KIR. MOTTAGNINGEN ÄR KLAR

Detta CRF formulär sparas i patientpärmén eller vid exklusion i exklusionspärmén.

Rtg resultat:	Pos(scaphoideum) [†]	Neg(scaphoideum) [†]	Pos(annat) [†]
MR resultat:	Pos(scaphoideum) [†]	Neg(scaphoideum) [†]	Pos(annat) [†]
CT resultat:	Pos(scaphoideum) [†]	Neg(scaphoideum) [†]	Pos(annat) [†]
	Dislokation > 1mm	Ja _	Nej _
Frakturplacering:	Proximala 1/3 [†]	Mellersta 1/3 [†]	Distala 1/3 [†]

Beroende på resultatet från röntgenundersökning och MR undersökning tillfrågas patienten om att delta i någon av nedanstående delstudie.

För att fortsätta:

Tag korrekt CRF formulär inklusive patientinformation för rätt studie beroende på vilka kriterier patienten uppfyller.

Sätt kryss för aktuellt studie

Positiv Rtg för scaphoideum och positiv MR för scaphoideum

STUDIE 1 Odislocerad midjefraktur: *Studie av skruvfixering jämfört med gips vid scaphoideumfraktur. (Studie med röd markering)*

☐

STUDIE 2 Dislocerade och proximala frakturer: *Studie av operationsresultat av odislocerade jämfört med dislocerade och proximala scaphoideumfrakturer.*

☐

STUDIE 3 Odislocerade distala frakturer: *Studie av gipsimmobilisering.*

☐

Negativ MR och negativ Rtg

STUDIE 4 Ingen fraktur: *Studie av fri mobilisering jämfört med gipsimmobilisering. (Studie med blå markering)*

☐

Positiv MR för annat och negativ Rtg för scaphoideum (ev. pos för annat)

STUDIE 5 Annan fraktur eller ledbandsskada: *Studie av annan skada hittat vid misstänkt scaphoideumfraktur.*

☐

STUDIE 6 Scaphoideumfraktur som ej syns på primärröntgen: *Studie av gipsbehandling vid scaphoideumfraktur.*

☐

Appendix 2

Artroskopi (Handled) UMAS



Handkirurgen Malmö
Version 040208PJ/NT/ABN

Patientnamn :

CPR-nr. :

Studie-nr. :

PREOPERATIV STATUS

TRAUMA	ARBETSDIAGNOSER	UNDERSÖKNINGAR
OKÄND		RÖNTGEN
>1vecka		PROVOKATIONSBILDER
< 1mdr		ARTHROGRAFI
< 3mdr		SCINTIGRAFI
< 6mdr		ULTRALJUD
< 12mdr		CT-SCANNING
> 12mdr		MR-SCANNING

- EJ UTFÖRT + UTFÖRT

PEROPERATIV STATUS

OP.DATUM	OP.LÄK	HÖ.	VÄ.
ANESTESI	LEDVÄTSKA	PROV	METOD
LOKAL	INGEN	MIKROSKOPI	1-2 MCR
IVRA	SERÖS	ODLING	3-4 MCU
PLEXUS	BLODIG	SEROLOGI	4-5 STT
NARKOS	GRUMLIG	BIOPSI	6R DRUJ
BLODTOMHET	PURULENT	KRISTALLER	6U ARTROTOMI

SYNOVIALIS	RADIOCARPALT	MIDCARPALT
NORMAL	SCAPHOID-	SCAPHOIDEUM
OSPECIFIK SYNOVIT	LUNATE-FOVEA	LUNATUM
HYPERTROFISK VILLÖS	SCAPHOIDEUM	TRIQUETRUM
KRISTALLER	LUNATUM	CAPITATUM
BLODIG	TRIQUETRUM	HAMATUM
	DRUJ	STT

BROSK (1 ciffer):

- EJ VISUALISERAT

0. NORMAL

1. MJUK, (evt.svullen eller missfärgat)

2. YTLLIG FIBRILLERING

3. GROV FIBRILLERING

4. DESTRUKTION TILL BEN

FRAKTUR: (2. ciffer):

- EJ VISUALISERAT

0. INGEN

1. KONDRAL

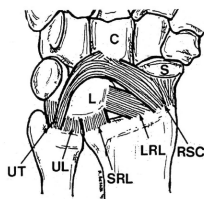
2. OSTEOKONDRAL

3. EGENTLIG FRAKTUR

DORSAL KAPSEL
NORMAL
RUPTUR
GANGLION
EJ VISUALISERAT

TFCC (PALMER CLASS)
NORMAL
IA. CENTRAL PERFORATION
IB. ULNAR AVULSION
IC. DISTAL AVULSION
ID. RADIAL AVULSION
II. DEGENERATIVA FÖRÄNDRINGAR

EXTRINSIC LIGAMENT
RADIO-SCAPO-CAPITATE (RSC)
LONG RADIO-LUNATE (LRL)
SHORT RADIO-LUNATE (SRL)
ULNO-LUNATE (UL)
ULNO-TRIQUETRAL (UT)
DORSAL KAPSEL (DC)



INTRINSIC LIGAMENT	
SCAPHO-LUNÄRA (SL)	
LUNO-TRIQUETRALE (LT)	

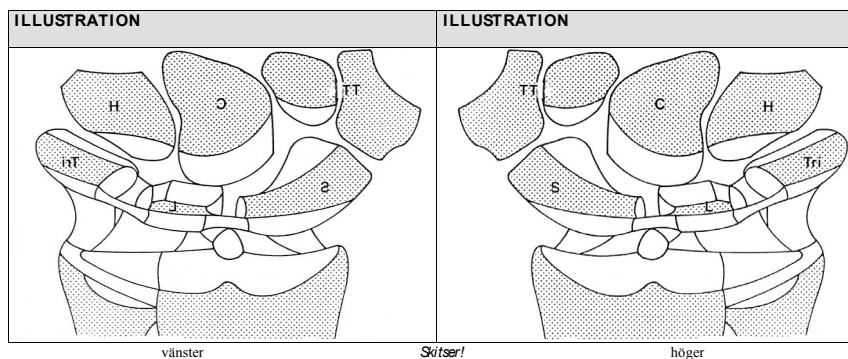
GEISSLER

- EJ VISUALISERAT

	MIDKARPAL DIASTAS	ARTROSKOPI STEP-OFF
0. NORMAL	0	0
1. HEMATOM/DISTENSION	0	0
2. SOM 1. OCH/ELLER PARTIELL RUPTUR	0-1mm	<2mm
3. PARTIELL ELLER TOTAL RUPTUR	1-2mm	<2mm
4. TOTAL RUPTUR	>2mm	>2mm

FRAKTUR	
STABIL (testad med kroken)	
INSTABIL grad I (öpnas som en bok)	
INSTABIL grad II (skopet kan föres ner mellan fragmenten)	
DEFEKT ulnart	
DEFEKT radiale	
INTERPONAT	
STABIL (efter osteosyntes) JA	
STABIL (efter osteosyntes) OSÄKERT	
STABIL (efter osteosyntes) NEJ	
REPOSITION (efter osteosyntes) EXAKT	
REPOSITION (efter osteosyntes) < 1mm ledyttehak	
REPOSITION (efter osteosyntes) > 1mm ledyttehak	

OSTOSYNTES	
SKRUV (HBS/TWINFIX)	
TYP (Standard, Mini)	
KOMPRESSIONSGRAD (guld, silver)	
LANGD (mm)	
ANNAT	



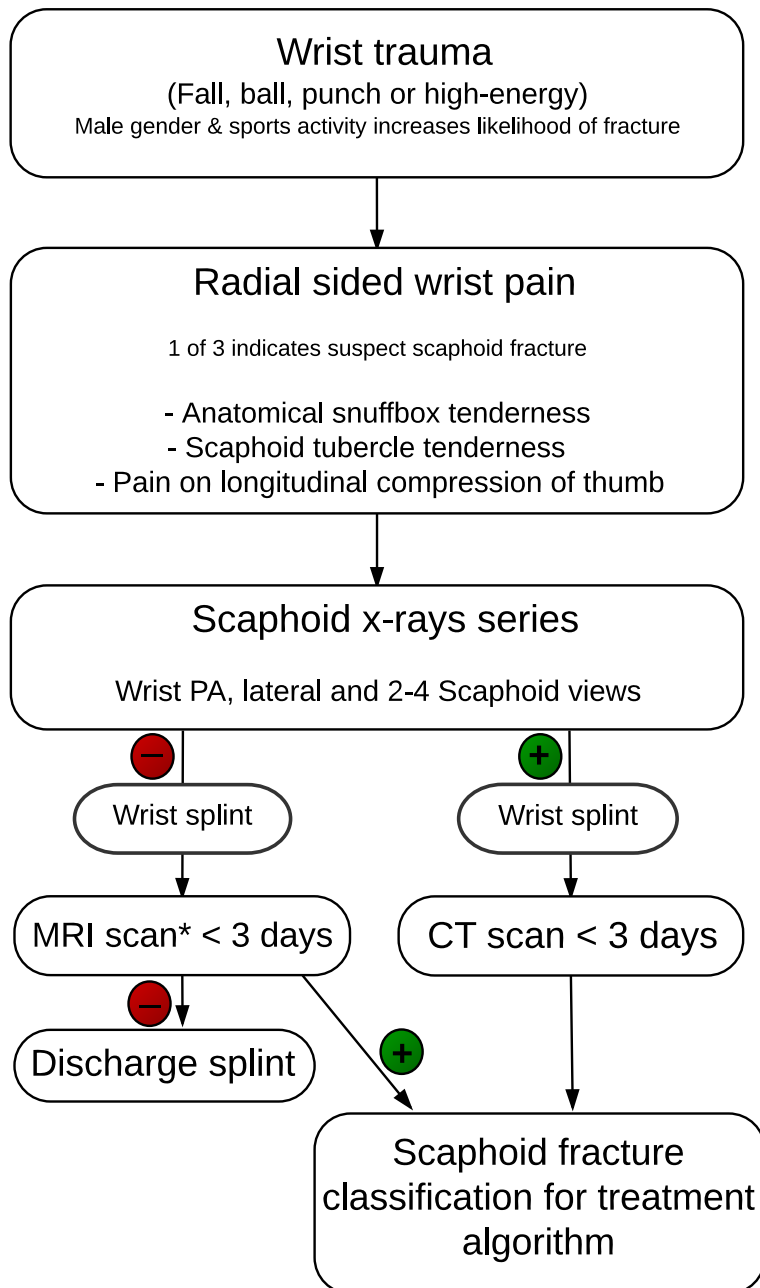
HUVUDDIAGNOS	OPERATIONSKODER									
1										
2										
3										
4										

DOKUMENTATION			
VIDEO	RADIOCARPALT	TUMME	
FOTO	MIDTCARPALT	ANNAN LED	

FRI TEXT:

Scaphoid fracture diagnostic algorithm

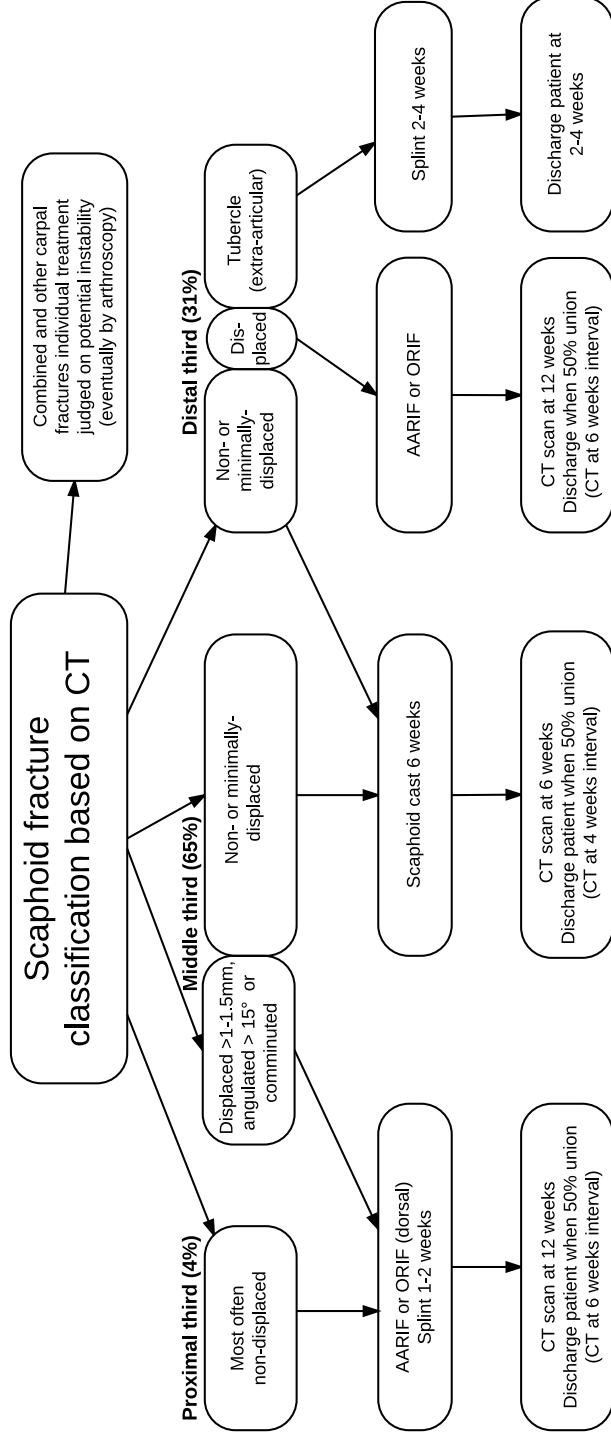
Proposed algorithm based on current literature and this thesis



*CT scan if MRI is contra-indicated or not available

Scaphoid fracture treatment algorithm

Proposed algorithm based on current literature and this thesis



AARIF: arthroscopy-assisted reduction & internal fixation ORIF: open reduction & internal fixation

References

1. Schultz, A.H., Characters common to higher primates and characters specific to man. *Q Rev Biol*, 1936. 11: p. 259-283.
2. Weidenreich, F., Giant Early Man from Java and South China. *Science*, 1944. 99(2581): p. 479-82.
3. Napier, J., The evolution of the hand. *Sci Am*, 1962. 207: p. 56-62.
4. Marzke, M.W., Upper-limb evolution and development. *J Bone Joint Surg Am*, 2009. 91 Suppl 4: p. 26-30.
5. Tocheri, M.W., Orr CM, Larson SG, Sutikna T, Jatmiko, Saptomo EW, et al., The primitive wrist of *Homo floresiensis* and its implications for hominin evolution. *Science*, 2007. 317(5845): p. 1743-5.
6. Kivell, T.L., Kibii JM, Churchill SE, Schmid P, Berger LR., *Australopithecus sediba* hand demonstrates mosaic evolution of locomotor and manipulative abilities. *Science*, 2011. 333(6048): p. 1411-7.
7. Wolfe, S.W., Crisco JJ, Orr CM, Marzke MW, The dart-throwing motion of the wrist: is it unique to humans? *J Hand Surg Am*, 2006. 31(9): p. 1429-37.
8. Lundborg, G., The hand, the brain and the tool., in *The hand and the brain*. 2014, Springer: London. p. 31-35.
9. Hove, L.M., Epidemiology of scaphoid fractures in Bergen, Norway. *Scand J Plast Reconstr Surg Hand Surg*, 1999. 33(4): p. 423-6.
10. Crisco, J.J., Coburn JC, Moore DC, Upal MA., Carpal bone size and scaling in men versus in women. *J Hand Surg Am*, 2005. 30(1): p. 35-42.
11. Buijze, G.A., Lozano-Calderon SA, Strackee SD, Blankevoort L, Jupiter JB, Osseous and ligamentous scaphoid anatomy: Part I. A systematic literature review highlighting controversies. *J Hand Surg Am*, 2011. 36(12): p. 1926-35.
12. Lee, S.B., Kim HJ, Chun JM, Lee CS, Kim SY, Kim PT, et a., Osseous microarchitecture of the scaphoid: Cadaveric study of regional variations and clinical implications. *Clin Anat*, 2012. 25(2): p. 203-11.
13. Chloros, G.D., Themistocleous GS, Wiesler ER, Benetos IS, Efsthathopoulos DG, Soucacos PN., Pediatric scaphoid nonunion. *J Hand Surg Am*, 2007. 32(2): p. 172-6.
14. Reddy, R.S. and J. Compson, Examination of the wrist—surface anatomy of the carpal bones. *Current Orthopaedics*, 2005. 19: p. 171-179.
15. Gelberman, R.H. and J. Menon, The vascularity of the scaphoid bone. *J Hand Surg Am*, 1980. 5(5): p. 508-13.

16. Berger, R.A. and J.M. Landsmeer, The palmar radiocarpal ligaments: a study of adult and fetal human wrist joints. *J Hand Surg Am*, 1990. 15(6): p. 847-54.
17. Tan, J., J. Chen, and J.B. Tang, In vivo length changes of wrist ligaments at full wrist extension. *J Hand Surg Eur Vol*, 2014. 39(4): p. 384-90.
18. Tengrootenhuysen, M., van Riet R, Pimontel P, Bortier H, Van Glabbeek F., The role of the transverse carpal ligament in carpal stability: an in vitro study. *Acta Orthop Belg*, 2009. 75(4): p. 467-71.
19. Berger, R.A., The anatomy of the ligaments of the wrist and distal radioulnar joints. *Clin Orthop Relat Res*, 2001(383): p. 32-40.
20. Berger, R.A., The gross and histologic anatomy of the scapholunate interosseous ligament. *J Hand Surg Am*, 1996. 21(2): p. 170-8.
21. Corella, F., Del Cerro M, Ocampos M, Larrainzar-Garijo R., Arthroscopic ligamentoplasty of the dorsal and volar portions of the scapholunate ligament. *J Hand Surg Am*, 2013. 38(12): p. 2466-77.
22. Buijze, G.A., Dvinskikh NA, Strackee SD, Streekstra GJ, Blankevoort L., Osseous and ligamentous scaphoid anatomy: Part II. Evaluation of ligament morphology using three-dimensional anatomical imaging. *J Hand Surg Am*, 2011. 36(12): p. 1936-43.
23. Moojen, T.M., Snel JG, Ritt MJ, Kauer JM, Venema HW, Bos KE, Three-dimensional carpal kinematics in vivo. *Clin Biomech (Bristol, Avon)*, 2002. 17(7): p. 506-14.
24. Kobayashi, M., Berger RA, Nagy L, Linscheid RL, Uchiyama S, Ritt M., Normal kinematics of carpal bones: a three-dimensional analysis of carpal bone motion relative to the radius. *J Biomech*, 1997. 30(8): p. 787-93.
25. Short, W.H., Werner FW, Green JK, Sutton LG, Brutus JP., Biomechanical evaluation of the ligamentous stabilizers of the scaphoid and lunate: part III. *J Hand Surg Am*, 2007. 32(3): p. 297-309.
26. Kitay, A. and S.W. Wolfe, Scapholunate instability: current concepts in diagnosis and management. *J Hand Surg Am*, 2012. 37(10): p. 2175-96.
27. Cooney, W.P., Non-union of the carpus, in *Hand Surgery*, R.A.W. Berger, A.P., Editor. 2004, Lippincott: Philadelphia, USA. p. p 426.
28. Weber, E.R. and E.Y. Chao, An experimental approach to the mechanism of scaphoid waist fractures. *J Hand Surg Am*, 1978. 3(2): p. 142-8.
29. Cockshott, W.P., Distal avulsion fractures of the scaphoid. *Br J Radiol*, 1980. 53(635): p. 1037-40.
30. Vahvanen, V. and M. Westerlund, Fracture of the carpal scaphoid in children. A clinical and roentgenological study of 108 cases. *Acta Orthop Scand*, 1980. 51(6): p. 909-13.
31. Christodoulou, A.G. and C.L. Colton, Scaphoid fractures in children. *J Pediatr Orthop*, 1986. 6(1): p. 37-9.
32. Nafie, S.A., Fractures of the carpal bones in children. *Injury*, 1987. 18(2): p. 117-9.
33. Wilson, E.B., T.F. Beattie, and A.G. Wilkinson, Epidemiological review and proposed management of 'scaphoid' injury in children. *Eur J Emerg Med*, 2011. 18(1): p. 57-61.

34. Rongieres, M., Mansat M, Le Bail B, Samaran P, Leclair O, Bonneville P, [Fractures of the proximal pole of the scaphoid bone. Anatomico-clinical and therapeutic entity]. *Ann Chir Main Memb Super*, 1991. 10(2): p. 119-23.
35. Green, J.R., GM, Scaphoid fractures in soccer goalkeepers. *J Okla state Med Assoc*, 1997. 90(Feb): p. 45-47.
36. Horii, E., Nakamura R, Watanabe K, Tsunoda K., Scaphoid fracture as a "puncher's fracture". *J Orthop Trauma*, 1994. 8(2): p. 107-10.
37. Herzberg, G., Comtet JJ, Linscheid RL, Amadio PC, Cooney WP, Stalder J., Perilunate dislocations and fracture-dislocations: a multicenter study. *J Hand Surg Am*, 1993. 18(5): p. 768-79.
38. Mayfield, J.K., R.P. Johnson, and R.K. Kilcoyne, Carpal dislocations: pathomechanics and progressive perilunar instability. *J Hand Surg Am*, 1980. 5(3): p. 226-41.
39. Larsen, C.F., V. Brøndum, and O. Skov, Epidemiology of scaphoid fractures in Odense, Denmark. *Acta Orthop Scand*, 1992. 63(2): p. 216-8.
40. Duckworth, A.D., Jenkins PJ, Aitken SA, Clement ND, Court-Brown CM, McQueen MM., Scaphoid fracture epidemiology. *J Trauma Acute Care Surg*, 2012. 72(2): p. E41-5.
41. Hove, L.M., Fjeldsgaard K, Reitan R, Skjeie R, Sørensen FK., Fractures of the distal radius in a Norwegian city. *Scand J Plast Reconstr Surg Hand Surg*, 1995. 29(3): p. 263-7.
42. Wolf, J.M., Mountcastle SB, Owens BD., The incidence of scaphoid fracture in a military population. *Injury*, 2009. 40(12): p. 1316-9.
43. Van Tassel, D.C., B.D. Owens, and J.M. Wolf, Incidence estimates and demographics of scaphoid fracture in the U.S. population. *J Hand Surg Am*, 2010. 35(8): p. 1242-5.
44. Brøndum, V., C.F. Larsen, and O. Skov, Fracture of the carpal scaphoid: frequency and distribution in a well-defined population. *Eur J Radiol*, 1992. 15(2): p. 118-22.
45. Leslie, I.J. and R.A. Dickson, The fractured carpal scaphoid. Natural history and factors influencing outcome. *J Bone Joint Surg Br*, 1981. 63-B(2): p. 225-30.
46. Langhaff, O. and J.L. Andersen, Consequences of late immobilization of scaphoid fractures. *J Hand Surg Br*, 1988. 13(1): p. 77-9.
47. Ahmed, I., Ashton F, Tay WK, Porter D., The pediatric fracture of the scaphoid in patients aged 13 years and under: an epidemiological study. *J Pediatr Orthop*, 2014. 34(2): p. 150-4.
48. Stanciu, C. and A. Dumont, Changing patterns of scaphoid fractures in adolescents. *Can J Surg*, 1994. 37(3): p. 214-6.
49. Gholson, J.J., Bae DS, Zurakowski D, Waters PM., Scaphoid fractures in children and adolescents: contemporary injury patterns and factors influencing time to union. *J Bone Joint Surg Am*, 2011. 93(13): p. 1210-9.
50. Journeau, P., [Carpal injuries in children]. *Chir Main*, 2013. 32 Suppl 1: p. S16-28.

51. Parvizi, J., Wayman J, Kelly P, Moran CG., Combining the clinical signs improves diagnosis of scaphoid fractures. A prospective study with follow-up. *J Hand Surg Br*, 1998. 23(3): p. 324-7.
52. Bergh, T.H., Lindau T, Soldal LA, Bernardshaw SV, Behzadi M, Steen K., Clinical scaphoid score (CSS) to identify scaphoid fracture with MRI in patients with normal x-ray after a wrist trauma. *Emerg Med J*, 2014. 31(8): p. 659-64.
53. Duckworth, A.D., Buijze GA, Moran M, Gray A, Court-Brown CM, Ring D, et al., Predictors of fracture following suspected injury to the scaphoid. *J Bone Joint Surg Br*, 2012. 94(7): p. 961-8.
54. American College of Radiology. Appropriateness Criteria. Acute Hand and Wrist Trauma. 2013 [cited 1998]. Available at: <http://www.acr.org/-/media/ACR/Documents/AppCriteria/Diagnostic/AcuteHandAndWristTrauma.pdf>
55. Stecher, W., Roentgenography of the carpal navicular bone. *Am J Roentgenol*, 1937. 37: p. 704-705.
56. Tiel-van Buul, M.M., van Beek EJ, Broekhuizen AH, Nooitgedacht EA, Davids PH, Bakker AJ., Diagnosing scaphoid fractures: radiographs cannot be used as a gold standard! *Injury*, 1992. 23(2): p. 77-9.
57. Low, G. and N. Raby, Can follow-up radiography for acute scaphoid fracture still be considered a valid investigation? *Clin Radiol*, 2005. 60(10): p. 1106-10.
58. Bernard, S.A., P.M. Murray, and M.G. Heckman, Validity of conventional radiography in determining scaphoid waist fracture displacement. *J Orthop Trauma*, 2010. 24(7): p. 448-51.
59. Buijze, G.A., Jørgsholm P, Thomsen NO, Björkman A, Besjakov J, Ring D., Diagnostic performance of radiographs and computed tomography for displacement and instability of acute scaphoid waist fractures. *J Bone Joint Surg Am*, 2012. 94(21): p. 1967-74.
60. Yin, Z.G., Zhang JB, Kan SL, Wang XG., Diagnostic accuracy of imaging modalities for suspected scaphoid fractures: meta-analysis combined with latent class analysis. *J Bone Joint Surg Br*, 2012. 94(8): p. 1077-85.
61. Geijer, M. Diagnosis of scaphoid fracture: optimal imaging techniques. 2013. 57–69.
62. Geijer, M., A.M. Borjesson, and J.H. Gothlin, Clinical utility of tomosynthesis in suspected scaphoid fracture. A pilot study. *Skeletal Radiol*, 2011. 40(7): p. 863-7.
63. Ottenin, M.A., Jacquot A, Grospretre O, Noel A, Lecocq S, Louis M, et al., Evaluation of the diagnostic performance of tomosynthesis in fractures of the wrist. *AJR Am J Roentgenol*, 2012. 198(1): p. 180-6.
64. Goodman, L.R., The Beatles, the Nobel Prize, and CT scanning of the chest. *Radiol Clin North Am*, 2010. 48(1): p. 1-7.
65. Biswas, D., Bible JE, Bohan M, Simpson AK, Whang PG, Grauer JN., Radiation exposure from musculoskeletal computerized tomographic scans. *J Bone Joint Surg Am*, 2009. 91(8): p. 1882-9.

66. Sanders, W.E., Evaluation of the humpback scaphoid by computed tomography in the longitudinal axial plane of the scaphoid. *J Hand Surg Am*, 1988. 13(2): p. 182-7.
67. Bain, G.I., Clinical Utilisation of Computed Tomography of the Scaphoid. *Hand Surg*, 1999. 4(1): p. 3-9.
68. Ring, D., Patterson JD, Levitz S, Wang C, Jupiter JB., Both scanning plane and observer affect measurements of scaphoid deformity. *J Hand Surg Am*, 2005. 30(4): p. 696-701.
69. Mallee, W.H., Doornberg JN, Ring D, Maas M, Muhl M, van Dijk CN, et al., Computed tomography for suspected scaphoid fractures: comparison of reformations in the plane of the wrist versus the long axis of the scaphoid. *Hand (N Y)*, 2014. 9(1): p. 117-21.
70. Groves, A.M., Cheow HK, Balan KK, Bearcroft PW, Dixon AK., 16 detector multislice CT versus skeletal scintigraphy in the diagnosis of wrist fractures: value of quantification of 99Tcm-MDP uptake. *Br J Radiol*, 2005. 78(933): p. 791-5.
71. Memarsadeghi, M., Breitenseher MJ, Schaefer-Prokop C, Weber M, Aldrian S, Gabler C, et al., Occult scaphoid fractures: comparison of multidetector CT and MR imaging--initial experience. *Radiology*, 2006. 240(1): p. 169-76.
72. Nakamura, R., Imaeda T, Horii E, Miura T, Hayakawa N., Analysis of scaphoid fracture displacement by three-dimensional computed tomography. *J Hand Surg Am*, 1991. 16(3): p. 485-92.
73. Buijze, G.A., Wijffels MM, Guitton TG, Grewal R, van Dijk CN, Ring D, et al., Interobserver reliability of computed tomography to diagnose scaphoid waist fracture union. *J Hand Surg Am*, 2012. 37(2): p. 250-4.
74. Guo, Y., Tian GL, Chen S, Tapia C., Establishing a central zone in scaphoid surgery: a computational approach. *Int Orthop*, 2014. 38(1): p. 95-9.
75. Dias, J.J., Taylor M, Thompson J, Brenkel IJ, Gregg PJ., Radiographic signs of union of scaphoid fractures. An analysis of inter-observer agreement and reproducibility. *J Bone Joint Surg Br*, 1988. 70(2): p. 299-301.
76. Singh, H.P., Forward D, Davis TR, Dawson JS, Oni JA, Downing ND., Partial union of acute scaphoid fractures. *J Hand Surg Br*, 2005. 30(5): p. 440-5.
77. Grewal, R., N. Suh, and J.C. Macdermid, Use of computed tomography to predict union and time to union in acute scaphoid fractures treated nonoperatively. *J Hand Surg Am*, 2013. 38(5): p. 872-7.
78. Geoghegan, J.M., Woodruff MJ, Bhatia R, Dawson JS, Kerslake RW, Downing ND, et al., Undisplaced scaphoid waist fractures: is 4 weeks' immobilisation in a below-elbow cast sufficient if a week 4 CT scan suggests fracture union? *J Hand Surg Eur Vol*, 2009. 34(5): p. 631-7.
79. Zbijewski, W., De Jean P, Prakash P, Ding Y, Stayman JW, Packard N, et al., A dedicated cone-beam CT system for musculoskeletal extremities imaging: design, optimization, and initial performance characterization. *Med Phys*, 2011. 38(8): p. 4700-13.

80. Smith, E.J., R.E. Ellis, and D.R. Pichora, Computer-assisted percutaneous scaphoid fixation: concepts and evolution. *J Wrist Surg*, 2013. 2(4): p. 299-305.
81. Niederwanger, C., Widmann G, Knoflach M, Schullian P, Hoermann R, Bale R., Kirschner wire placement in scaphoid bones using intraoperative CT-guided stereotaxy. *Minim Invasive Ther Allied Technol*, 2013. 22(3): p. 165-70.
82. Tiel-van Buul, M.M., Roolker W, Broekhuizen AH, Van Beek EJ., The diagnostic management of suspected scaphoid fracture. *Injury*, 1997. 28(1): p. 1-8.
83. Henriksen, O.M., Lonsdale MN, Jensen TD, Weikop KL, Holm O, Duus B, et al., Two-dimensional fusion imaging of planar bone scintigraphy and radiographs in patients with clinical scaphoid fracture: an imaging study. *Acta Radiol*, 2009. 50(1): p. 71-7.
84. Querellou, S., Arnaud L, Williams T, Breton S, Colin D, Le Roux PY, et al., Role of SPECT/CT compared with MRI in the diagnosis and management of patients with wrist trauma occult fractures. *Clin Nucl Med*, 2014. 39(1): p. 8-13.
85. Ring, D. and S. Lozano-Calderon, Imaging for suspected scaphoid fracture. *J Hand Surg Am*, 2008. 33(6): p. 954-7.
86. Jenkins, P.J., Slade K, Huntley JS, Robinson CM., A comparative analysis of the accuracy, diagnostic uncertainty and cost of imaging modalities in suspected scaphoid fractures. *Injury*, 2008. 39(7): p. 768-74.
87. Smith, H.J., [From zero priority to Nobel Prize]. *Tidsskr Nor Laegeforen*, 2003. 123(23): p. 3352.
88. Shabshin, N. and M.E. Schweitzer, Age dependent T2 changes of bone marrow in pediatric wrist MRI. *Skeletal Radiol*, 2009. 38(12): p. 1163-8.
89. Hansen, T.B., Petersen RB, Barckman J, Uhre P, Larsen K., Cost-effectiveness of MRI in managing suspected scaphoid fractures. *J Hand Surg Eur Vol*, 2009. 34(5): p. 627-30.
90. Munk, B., Frøkjær J, Larsen CF, Johannsen HG, Rasmussen LL, Edal A, et al., Diagnosis of scaphoid fractures. A prospective multicenter study of 1,052 patients with 160 fractures. *Acta Orthop Scand*, 1995. 66(4): p. 359-60.
91. Shetty, S., Sidharthan S, Jacob J, Ramesh B., 'Clinical scaphoid fracture': is it time to abolish this phrase? *Ann R Coll Surg Engl*, 2011. 93(2): p. 146-8.
92. Pierre-Jerome, C., Moncayo V, Albastaki U, Terk MR., Multiple occult wrist bone injuries and joint effusions: prevalence and distribution on MRI. *Emerg Radiol*, 2010. 17(3): p. 179-84.
93. Kirkeby, L., V. Kairelyte, and T.B. Hansen, Early magnetic resonance imaging in patients with a clinically suspected scaphoid fracture may identify occult wrist injuries. *J Hand Surg Eur Vol*, 2013. 38(5): p. 571-2.
94. Bergh, T.H., Lindau T, Bernardshaw SV, Behzadi M, Soldal LA, Steen K, et al., A new definition of wrist sprain necessary after findings in a prospective MRI study. *Injury*, 2012. 43(10): p. 1732-42.

95. Herold, T., Lenhart M, Held P, Babel M, Ruf S, Feuerbach S, et al., [Indirect MR Arthrography of the wrist in the diagnosis of TFCC-Lesions]. *Rofo*, 2001. 173(11): p. 1006-11.
96. Haims, A.H., Schweitzer ME, Morrison WB, Deely D, Lange RC, Osterman AL, et al., Internal derangement of the wrist: indirect MR arthrography versus unenhanced MR imaging. *Radiology*, 2003. 227(3): p. 701-7.
97. Smith, T.O., Drew BT, Toms AP, Chojnowski AJ., The diagnostic accuracy of X-ray arthrography for triangular fibrocartilaginous complex injury: a systematic review and meta-analysis. *J Hand Surg Eur Vol*, 2012. 37(9): p. 879-87.
98. Smith, T.O., Drew B, Toms AP, Jerosch-Herold C, Chojnowski AJ., Diagnostic accuracy of magnetic resonance imaging and magnetic resonance arthrography for triangular fibrocartilaginous complex injury: a systematic review and meta-analysis. *J Bone Joint Surg Am*, 2012. 94(9): p. 824-32.
99. Lee, R.K., Ng AW, Tong CS, Griffith JF, Tse WL, Wong C, et al., Intrinsic ligament and triangular fibrocartilage complex tears of the wrist: comparison of MDCT arthrography, conventional 3-T MRI, and MR arthrography. *Skeletal Radiol*, 2013. 42(9): p. 1277-85.
100. Lindström, G. and A. Nystrom, Incidence of post-traumatic arthrosis after primary healing of scaphoid fractures: a clinical and radiological study. *J Hand Surg Br*, 1990. 15(1): p. 11-3.
101. Clay, N.R., Dias JJ, Costigan PS, Gregg PJ, Barton NJ., Need the thumb be immobilised in scaphoid fractures? A randomised prospective trial. *J Bone Joint Surg Br*, 1991. 73(5): p. 828-32.
102. Terkelsen, C.J. and J.M. Jepsen, Treatment of scaphoid fractures with a removable cast. *Acta Orthop Scand*, 1988. 59(4): p. 452-3.
103. Symes, T.H. and J. Stothard, A systematic review of the treatment of acute fractures of the scaphoid. *J Hand Surg Eur Vol*, 2011. 36(9): p. 802-10.
104. Buijze, G.A., Goslings JC, Rhemrev SJ, Weening AA, Van Dijkman B, Doornberg JN, et al., Cast immobilization with and without immobilization of the thumb for nondisplaced and minimally displaced scaphoid waist fractures: a multicenter, randomized, controlled trial. *J Hand Surg Am*, 2014. 39(4): p. 621-7.
105. Alshryda, S., Shah A, Odak S, Al-Shryda J, Ilango B, Murali SR., Acute fractures of the scaphoid bone: Systematic review and meta-analysis. *Surgeon*, 2012. 10(4): p. 218-29.
106. Gellman, H., Caputo RJ, Carter V, Aboulafia A, McKay M., Comparison of short and long thumb-spica casts for non-displaced fractures of the carpal scaphoid. *J Bone Joint Surg Am*, 1989. 71(3): p. 354-7.
107. Singh, H.P., N. Taub, and J.J. Dias, Management of displaced fractures of the waist of the scaphoid: meta-analyses of comparative studies. *Injury*, 2012. 43(6): p. 933-9.
108. Amadio, P.C., Berquist TH, Smith DK, Ilstrup DM, Cooney WP, 3rd, Linscheid RL., Scaphoid malunion. *J Hand Surg Am*, 1989. 14(4): p. 679-87.

109. Eddeland, A., Eddeland A, Eiken O, Hellgren E, Ohlsson NM., Fractures of the scaphoid. *Scand J Plast Reconstr Surg*, 1975. 9(3): p. 234-9.
110. Buijze, G.A., Jørgsholm P, Thomsen NO, Björkman A, Besjakov J, Ring D., Factors associated with arthroscopically determined scaphoid fracture displacement and instability. *J Hand Surg Am*, 2012. 37(7): p. 1405-10.
111. Toth, F., Mester S, Cseh G, Bener A, Nyarady J, Lovasz G., Modified carpal box technique in the diagnosis of suspected scaphoid fractures. *Acta Radiol*, 2003. 44(3): p. 319-25.
112. Hannemann, P.F., Brouwers L, van der Zee D, Stadler A, Gottgens KW, Weijers R, et al., Multiplanar reconstruction computed tomography for diagnosis of scaphoid waist fracture union: a prospective cohort analysis of accuracy and precision. *Skeletal Radiol*, 2013. 42(10): p. 1377-82.
113. Amirfeyz, R., Bebbington A, Downing ND, Oni JA, Davis TR., Displaced scaphoid waist fractures: the use of a week 4 CT scan to predict the likelihood of union with nonoperative treatment. *J Hand Surg Eur Vol*, 2011. 36(6): p. 498-502.
114. Grewal, R., Frakash U, Osman S, McMurtry RY., A quantitative definition of scaphoid union: determining the inter-rater reliability of two techniques. *J Orthop Surg Res*, 2013. 8: p. 28.
115. Little, C.P., Burston BJ, Hopkinson-Woolley J, Burge P., Failure of surgery for scaphoid non-union is associated with smoking. *J Hand Surg Br*, 2006. 31(3): p. 252-5.
116. Dinah, A.F. and R.H. Vickers, Smoking increases failure rate of operation for established non-union of the scaphoid bone. *Int Orthop*, 2007. 31(4): p. 503-5.
117. Aspenberg, P., Drugs and fracture repair. *Acta Orthop*, 2005. 76(6): p. 741-8.
118. Dias, J.J., Wildin CJ, Bhowal B, Thompson JR., Should acute scaphoid fractures be fixed? A randomized controlled trial. *J Bone Joint Surg Am*, 2005. 87(10): p. 2160-8.
119. McLaughlin, L.H., Fracture of the carpal navicular (scaphoid) bone; some observations based on treatment by open reduction and internal fixation. *J Bone Joint Surg Am*, 1954. 36-A(4): p. 765-74.
120. Herbert, T.J. and W.E. Fisher, Management of the fractured scaphoid using a new bone screw. *J Bone Joint Surg Br*, 1984. 66(1): p. 114-23.
121. Assari, S., K. Darvish, and A.M. Ilyas, Biomechanical analysis of second-generation headless compression screws. *Injury*, 2012. 43(7): p. 1159-65.
122. Ya'ish, F., Bailey CA, Kelly CP, Craigen MA., Bioabsorbable fixation of scaphoid fractures and non-unions; analysis of early clinical outcomes. *Hand Surg*, 2013. 18(3): p. 343-9.
123. Meermans, G. and F. Verstreken, A comparison of 2 methods for scaphoid central screw placement from a volar approach. *J Hand Surg Am*, 2011. 36(10): p. 1669-74.
124. Jeon, I.H., Micic ID, Oh CW, Park BC, Kim PT., Percutaneous screw fixation for scaphoid fracture: a comparison between the dorsal and the volar approaches. *J Hand Surg Am*, 2009. 34(2): p. 228-36 e1.

125. Slade, J.F., 3rd, A.P. Gutow, and W.B. Geissler, Percutaneous internal fixation of scaphoid fractures via an arthroscopically assisted dorsal approach. *J Bone Joint Surg Am*, 2002. 84-A Suppl 2: p. 21-36.
126. Saint-Cyr, M., Oni G, Wong C, Sen MK, LaJoie AS, Gupta A., Dorsal percutaneous cannulated screw fixation for delayed union and nonunion of the scaphoid. *Plast Reconstr Surg*, 2011. 128(2): p. 467-73.
127. Haddad, F.S. and N.J. Goddard, Acutrak percutaneous scaphoid fixation. *Tech Hand Up Extrem Surg*, 2000. 4(2): p. 78-80.
128. Geurts, G.F., Van Riet RP, Meermans G, Verstreken F., Volar percutaneous transtrapezial fixation of scaphoid waist fractures: surgical technique. *Acta Orthop Belg*, 2012. 78(1): p. 121-5.
129. Bond, C.D., Shin AY, McBride MT, Dao KD., Percutaneous screw fixation or cast immobilization for nondisplaced scaphoid fractures. *J Bone Joint Surg Am*, 2001. 83-A(4): p. 483-8.
130. McQueen, M.M., Gelbke MK, Wakefield A, Will EM, Gaebler C., Percutaneous screw fixation versus conservative treatment for fractures of the waist of the scaphoid: a prospective randomised study. *J Bone Joint Surg Br*, 2008. 90(1): p. 66-71.
131. Slade, J.F., 3rd and T. Gillon, Retrospective review of 234 scaphoid fractures and nonunions treated with arthroscopy for union and complications. *Scand J Surg*, 2008. 97(4): p. 280-9.
132. Dias, J.J. and H.P. Singh, Displaced fracture of the waist of the scaphoid. *J Bone Joint Surg Br*, 2011. 93(11): p. 1433-9.
133. van der Molen, A.B., Groothoff JW, Visser GJ, Robinson PH, Eisma WH., Time off work due to scaphoid fractures and other carpal injuries in The Netherlands in the period 1990 to 1993. *J Hand Surg Br*, 1999. 24(2): p. 193-8.
134. Papaloizos, M.Y., Fusetti C, Christen T, Nagy L, Wasserfallen JB., Minimally invasive fixation versus conservative treatment of undisplaced scaphoid fractures: a cost-effectiveness study. *J Hand Surg Br*, 2004. 29(2): p. 116-9.
135. Davis, E.N., Chung KC, Kotsis SV, Lau FH, Vijan S., A cost/utility analysis of open reduction and internal fixation versus cast immobilization for acute nondisplaced mid-waist scaphoid fractures. *Plast Reconstr Surg*, 2006. 117(4): p. 1223-35; discussion 1236-8.
136. Vinnars, B., F.A. Ekenstam, and B. Gerdin, Comparison of direct and indirect costs of internal fixation and cast treatment in acute scaphoid fractures: a randomized trial involving 52 patients. *Acta Orthop*, 2007. 78(5): p. 672-9.
137. Saeden, B., Törnkvist H, Ponzer S, Höglund M., Fracture of the carpal scaphoid. A prospective, randomised 12-year follow-up comparing operative and conservative treatment. *J Bone Joint Surg Br*, 2001. 83(2): p. 230-4.
138. Vinnars, B., Pietreanu M, Bodestedt A, Ekenstam F, Gerdin B., Nonoperative compared with operative treatment of acute scaphoid fractures. A randomized clinical trial. *J Bone Joint Surg Am*, 2008. 90(6): p. 1176-85.

139. Komura, S., Yokoi T, Nonomura H, Tanahashi H, Satake T, Watanabe N., Incidence and characteristics of carpal fractures occurring concurrently with distal radius fractures. *J Hand Surg Am*, 2012. 37(3): p. 469-76.
140. Heo, Y.M., Kim SB, Yi JW, Lee JB, Park CY, Yoon JY, et al., Evaluation of associated carpal bone fractures in distal radial fractures. *Clin Orthop Surg*, 2013. 5(2): p. 98-104.
141. Rtaimate, M., et al., [Atypical Fenton syndrome]. *Chir Main*, 2001. 20(4): p. 303-6.
142. Arbter, D., Piatek S, Wichlas F, Winckler S., [The scaphocapitate fracture syndrome (Fenton)]. *Handchir Mikrochir Plast Chir*, 2009. 41(3): p. 171-4.
143. Thomsen, N.O., A dorsally displaced capitate neck fracture combined with a transverse shear fracture of the triquetrum. *J Hand Surg Eur Vol*, 2013. 38(2): p. 210-1.
144. Fenton, R.L., The naviculo-capitate fracture syndrome. *J Bone Joint Surg Am*, 1956. 38-A(3): p. 681-4.
145. Apergis, E., Darmanis S, Kastanis G, Papanikolaou A., Does the term scaphocapitate syndrome need to be revised? A report of 6 cases. *J Hand Surg Br*, 2001. 26(5): p. 441-5.
146. Apostolides, J.G., S.D. Lifchez, and M.R. Christy, Complex and rare fracture patterns in perilunate dislocations. *Hand (N Y)*, 2011. 6(3): p. 287-94.
147. Garg, B., T. Goyal, and P.P. Kotwal, Triple jeopardy: transscaphoid, transcapitate, transtriquetral, perilunate fracture dislocation. *J Orthop Traumatol*, 2013. 14(3): p. 223-6.
148. Lohman, M., Kivisaari A, Vehmas T, Kinnunen J, Karaharju E, Kaukonen JP, et al., MR imaging in suspected acute trauma of wrist bones. *Acta Radiol*, 1999. 40(6): p. 615-8.
149. Robison, J.E. and J.J. Kaye, Simultaneous fractures of the capitate and hamate in the coronal plane: case report. *J Hand Surg Am*, 2005. 30(6): p. 1153-5.
150. Takase, K. and K. Yamamoto, Unusual combined scaphoid and lunate fracture of the wrist: a case report. *J Hand Surg Am*, 2006. 31(3): p. 414-7.
151. Buijze, G.A. and C.S. Mudgal, Nondisplaced fractures of the proximal carpal row: case report. *J Hand Surg Am*, 2011. 36(8): p. 1310-2.
152. Schakel, M. and P.C. Dell, Trans-scaphoid palmar lunate dislocation with concurrent scapholunate ligament disruption. *J Hand Surg Am*, 1986. 11(5): p. 653-5.
153. Braithwaite, I.J. and W.A. Jones, Scapho-lunate dissociation occurring with scaphoid fracture. *J Hand Surg Br*, 1992. 17(3): p. 286-8.
154. Filan, S.L. and T.J. Herbert, Herbert screw fixation of scaphoid fractures. *J Bone Joint Surg Br*, 1996. 78(4): p. 519-29.
155. Vender, M.I., Watson HK, Black DM, Strickland JW., Acute scaphoid fracture with scapholunate gap. *J Hand Surg Am*, 1989. 14(6): p. 1004-7.
156. Ahovuo, J., Saarinen O, Hovi I, Kinnunen J, Paavolainen P., Bone malalignment in acute injuries of the wrist. *Ann Chir Gynaecol*, 1991. 80(3): p. 282-4.
157. Vitello, W. and D.A. Gordon, Obvious radiographic scapholunate dissociation: X-ray the other wrist. *Am J Orthop (Belle Mead NJ)*, 2005. 34(7): p. 347-51.

158. Monsivais, J.J., P.A. Nitz, and T.J. Scully, The role of carpal instability in scaphoid nonunion: casual or causal? *J Hand Surg Br*, 1986. 11(2): p. 201-6.
159. Ho, P.C., L.K. Hung, and T.K. Lung, Acute ligamentous injury in scaphoid fracture. *J Bone Joint Surg* 2000. 82B:82.
160. Schadel-Hopfner, M., A. Junge, and G. Bohringer, Scapholunate ligament injury occurring with scaphoid fracture--a rare coincidence? *J Hand Surg Br*, 2005. 30(2): p. 137-42.
161. Wong, T.C., T.H. Yip, and W.C. Wu, Carpal ligament injuries with acute scaphoid fractures - a combined wrist injury. *J Hand Surg Br*, 2005. 30(4): p. 415-8.
162. Caloia, M.F., Gallino RN, Caloia H, Rivarola H., Incidence of ligamentous and other injuries associated with scaphoid fractures during arthroscopically assisted reduction and percutaneous fixation. *Arthroscopy*, 2008. 24(7): p. 754-9.
163. Thomsen, L. and M.O. Falcone, Lesions of the scapholunate ligament associated with minimally displaced or non-displaced fractures of the scaphoid waist. Which incidence? *Chir Main*, 2012. 31(5): p. 234-8.
164. Badia, A. and P. Khanchandani, The floating lunate: arthroscopic treatment of simultaneous complete tears of the scapholunate and lunotriquetral ligaments. *Hand (N Y)*, 2009. 4(3): p. 250-5.
165. Johnson, R.P., The acutely injured wrist and its residuals. *Clin Orthop Relat Res*, 1980(149): p. 33-44.
166. Reichel, L.M., Bell BR, Michnick SM, Reitman CA., Radial styloid fractures. *J Hand Surg Am*, 2012. 37(8): p. 1726-41.
167. Bain, G.I., S. Pallapati, and K. Eng, Translunate perilunate injuries-a spectrum of this uncommon injury. *J Wrist Surg*, 2013. 2(1): p. 63-8.
168. Herzberg, G., Perilunate Injuries, Not Dislocated (PLIND). *J Wrist Surg*, 2013. 2(4): p. 337-45.
169. Barton, N.J., Twenty questions about scaphoid fractures. *J Hand Surg Br*, 1992. 17(3): p. 289-310.
170. Divecha, H.M., J.V. Clarke, and S.J. Barnes, Established non-union of an operatively managed trans-scaphoid perilunate fracture dislocation progressing to spontaneous union. *J Orthop Traumatol*, 2011. 12(3): p. 159-62.
171. Sehat, K.R. and G.C. Bannister, The prevalence of established scaphoid fracture non-union found on incidental radiography. *Injury*, 2000. 31(4): p. 275-6.
172. Ruby, L.K., J. Stinson, and M.R. Belsky, The natural history of scaphoid non-union. A review of fifty-five cases. *J Bone Joint Surg Am*, 1985. 67(3): p. 428-32.
173. Lindstrom, G. and A. Nystrom, Natural history of scaphoid non-union, with special reference to "asymptomatic" cases. *J Hand Surg Br*, 1992. 17(6): p. 697-700.
174. Inoue, G. and M. Sakuma, The natural history of scaphoid non-union. Radiographical and clinical analysis in 102 cases. *Arch Orthop Trauma Surg*, 1996. 115(1): p. 1-4.

175. Ramamurthy, C., Cutler L, Nuttall D, Simison AJ, Trail IA, Stanley JK., The factors affecting outcome after non-vascular bone grafting and internal fixation for nonunion of the scaphoid. *J Bone Joint Surg Br*, 2007. 89(5): p. 627-32.
176. D ppe, H., Johnell O, Lundborg G, Karlsson M, Redlund-Johnell I., Long-term results of fracture of the scaphoid. A follow-up study of more than thirty years. *J Bone Joint Surg Am*, 1994. 76(2): p. 249-52.
177. Daecke, W., Wieloch P, Vergetis P, Jung M, Martini AK., Occurrence of carpal osteoarthritis after treatment of scaphoid nonunion with bone graft and herbert screw: a long-term follow-up study. *J Hand Surg Am*, 2005. 30(5): p. 923-31.
178. Reigstad, O., Grims gaard C, Thorkildsen R, Reigstad A, R kkum M., Long-term results of scaphoid nonunion surgery: 50 patients reviewed after 8 to 18 years. *J Orthop Trauma*, 2012. 26(4): p. 241-5.
179. Bhat, M., McCarthy M, Davis TR, Oni JA, Dawson S., MRI and plain radiography in the assessment of displaced fractures of the waist of the carpal scaphoid. *J Bone Joint Surg Br*, 2004. 86(5): p. 705-13.
180. Geissler, W.B., Freeland AE, Savoie FH, McIntyre LW, Whipple TL., Intracarpal soft-tissue lesions associated with an intra-articular fracture of the distal end of the radius. *J Bone Joint Surg Am*, 1996. 78(3): p. 357-65.
181. Palmer, A.K., Triangular fibrocartilage complex lesions: a classification. *J Hand Surg Am*, 1989. 14(4): p. 594-606.
182. Larsen, C.F. and J. Lauritsen, Epidemiology of acute wrist trauma. *Int J Epidemiol*, 1993. 22(5): p. 911-6.
183. Burrows, B., Moreira P, Murphy C, Sadi J, Walton DM., Scaphoid fractures: a higher order analysis of clinical tests and application of clinical reasoning strategies. *Man Ther*, 2014. 19(5): p. 372-8.
184. Mallee, W.H., Henny EP, van Dijk CN, Kamminga SP, van Enst WA, Kloen P., Clinical diagnostic evaluation for scaphoid fractures: a systematic review and meta-analysis. *J Hand Surg Am*, 2014. 39(9): p. 1683-1691 e2.
185. Brismar, J., Skeletal scintigraphy of the wrist in suggested scaphoid fracture. *Acta Radiol*, 1988. 29(1): p. 101-7.
186. Cruickshank, J., Meakin A, Breadmore R, Mitchell D, Pincus S, Hughes T, et al., Early computerized tomography accurately determines the presence or absence of scaphoid and other fractures. *Emerg Med Australas*, 2007. 19(3): p. 223-8.
187. Ilica, A.T., Ozyurek S, Kose O, Durusu M., Diagnostic accuracy of multidetector computed tomography for patients with suspected scaphoid fractures and negative radiographic examinations. *Jpn J Radiol*, 2011. 29(2): p. 98-103.
188. Lepisto, J., Mattila K, Nieminen S, Sattler B, Korman  M., Low field MRI and scaphoid fracture. *J Hand Surg Br*, 1995. 20(4): p. 539-42.
189. Van Gelderen, W., R.S. Gale, and A.H. Steward, Short tau inversion recovery magnetic resonance imaging in occult scaphoid injuries: effect on management. *Australas Radiol*, 1998. 42(1): p. 20-4.

190. Raby, N., Magnetic resonance imaging of suspected scaphoid fractures using a low field dedicated extremity MR system. *Clin Radiol*, 2001. 56(4): p. 316-20.
191. Brydie, A. and N. Raby, Early MRI in the management of clinical scaphoid fracture. *Br J Radiol*, 2003. 76(905): p. 296-300.
192. Bretlau, T., Christensen OM, Edström P, Thomsen HS, Lausten GS., Diagnosis of scaphoid fracture and dedicated extremity MRI. *Acta Orthop Scand*, 1999. 70(5): p. 504-8.
193. Mallee, W., Doornberg JN, Ring D, van Dijk CN, Maas M, Goslings JC., Comparison of CT and MRI for diagnosis of suspected scaphoid fractures. *J Bone Joint Surg Am*, 2011. 93(1): p. 20-8.
194. Fallahi, F., Oliver R, Mandalia SS, Jonker L., Early MRI diagnostics for suspected scaphoid fractures subsequent to initial plain radiography. *Eur J Orthop Surg Traumatol*, 2014. 24(7): p. 1161-6.
195. Bergh, T.H., Steen K, Lindau T, Soldal LA, Bernardshaw SV, Lunde L, et al., Costs analysis and comparison of usefulness of acute MRI and 2 weeks of cast immobilization for clinically suspected scaphoid fractures. *Acta Orthop*, 2014: p. 1-7.
196. Moritomo, H., Murase T, Oka K, Tanaka H, Yoshikawa H, Sugamoto K., Relationship between the fracture location and the kinematic pattern in scaphoid nonunion. *J Hand Surg Am*, 2008. 33(9): p. 1459-68.
197. Leventhal, E.L., Wolfe SW, Moore DC, Akelman E, Weiss AP, Crisco JJ., Interfragmentary motion in patients with scaphoid nonunion. *J Hand Surg Am*, 2008. 33(7): p. 1108-15.
198. Compson, J.P., The anatomy of acute scaphoid fractures: a three-dimensional analysis of patterns. *J Bone Joint Surg Br*, 1998. 80(2): p. 218-24.
199. Cooney, W.P., 3rd, Scaphoid fractures: current treatments and techniques. *Instr Course Lect*, 2003. 52: p. 197-208.
200. Böhler, L., E. Trojan, and H. Jahna, The results of treatment of 734 fresh, simple fractures of the scaphoid. *J Hand Surg Br*, 2003. 28(4): p. 319-31.
201. Whipple, T.L., The role of arthroscopy in the treatment of wrist injuries in the athlete. *Clin Sports Med*, 1998. 17(3): p. 623-34.
202. Rettig, A.C., Athletic injuries of the wrist and hand. Part I: traumatic injuries of the wrist. *Am J Sports Med*, 2003. 31(6): p. 1038-48.
203. Tägil, M., Mrkonjic, A., Geijer M., Lindau, T., The Natural Course Of Arthroscopically Diagnosed SL Ligament Injuries In Distal Radial Fractures. A 13 To 15-year Clinical And Radiographical Follow-up. ORS 2014 Annual Meeting Poster No: 1922.

The Benefit of Magnetic Resonance Imaging for Patients With Posttraumatic Radial Wrist Tenderness

Peter Jørgsholm, MD, Niels O. B. Thomsen, PhD, Jack Besjakov, PhD, Sven-Olof Abrahamsson, PhD, Anders Björkman, PhD

Purpose To describe fractures revealed by magnetic resonance imaging (MRI) in a series of skeletally mature patients with radial wrist pain after an acute injury and clinically suspected to have a scaphoid fracture. Additionally, we attempted to assess the diagnostic value of radiographs and computed tomography (CT) in patients with scaphoid and other carpal fractures verified by MRI.

Methods We conducted the study prospectively over a 3-year period on skeletally mature patients presenting at our emergency department with tenderness on the radial side of the wrist after an injury. A total of 300 wrists in 296 patients underwent clinical and radiographic examination. We performed low-field, 0.23-T MRI of all injured wrists within 3 working days from inclusion in the study. If the radiographs or MRI revealed a scaphoid fracture, we immediately carried out a supplementary 16-slice CT scan of the wrist. We calculated the sensitivity and specificity of radiographs and CT for the diagnosis of scaphoid fractures using MRI as the reference standard.

Results We diagnosed a total of 224 fractures in 196 wrists using MRI; 42% were scaphoid fractures, 15% were distal radius fractures, 6% were triquetrum fractures, and 5% were capitate fractures. The most commonly found fracture combinations were that of the scaphoid and distal radius, followed by scaphoid and capitate fracture. The sensitivity of radiographs for visualization of scaphoid fractures was 70% and the specificity was 98%. Radiographic sensitivity for other fractures was less than 60%. The sensitivity of CT for visualization of scaphoid fractures was 95%, and between 75% and 100% for other fractures.

Conclusions Low-field MRI showed a high incidence of fractures in patients with posttraumatic radial wrist tenderness and demonstrated more fractures than radiographs and CT. A scaphoid fracture was by far the most common injury. However, it is not clear whether diagnosis of subtle injuries only demonstrated on MRI improves outcomes. (*J Hand Surg* 2013;38A:29–33. Copyright © 2013 by the American Society for Surgery of the Hand. All rights reserved.)

Type of study/level of evidence Diagnostic I.

Key words Carpal, CT, fracture, MRI, scaphoid.

THE MANAGEMENT OF posttraumatic radial wrist tenderness is potentially complicated by the possibility of missing a scaphoid fracture, because a delay in diagnosis or inadequate treatment may result in nonunion and progressive carpal degeneration.

Posttraumatic radial wrist tenderness is present in a wide spectrum of injuries from the base of the thumb to the distal radius. These patients remain a challenge, because palpation of an injured wrist can be difficult to interpret owing to the close proximity of the anatomical

From the Departments of Hand Surgery and Radiology, Skåne University Hospital, Malmö, Sweden.

Received for publication June 9, 2011; accepted in revised form September 25, 2012.

The authors acknowledge Jonas Björk, PhD, for assistance with the statistical analysis.

Supported by grants from Region Skåne and the Skåne University Hospital Foundation.

No benefits in any form have been received or will be received related directly or indirectly to the subject of this article.

Corresponding author: Peter Jørgsholm, MD, Department of Hand Surgery, Skåne University Hospital, SE-20502 Malmö, Sweden; e-mail: peter.jorgsholm@med.lu.se.

0363-5023/13/38A01-0005\$36.00/0
http://dx.doi.org/10.1016/j.jhsa.2012.09.034

structures. A combination of clinical signs has been proposed to detect scaphoid fractures. Although they demonstrate good sensitivity to detect an injury, the specificity is not more than 75%.¹ In addition, the most appropriate diagnostic modality for the detection of injuries in patients with posttraumatic wrist tenderness is not known. Different radiological modalities, such as computed tomography (CT)² and magnetic resonance imaging (MRI),³ have been recommended, in addition to radiographs to establish early and definitive diagnosis. Both CT and MRI have drawbacks. Computed tomography is not recommended for use in children and pregnant women because of its high radiation, and MRI has limited availability and higher costs. Knowledge remains limited concerning both the distribution of fractures in patients with posttraumatic radial wrist tenderness and the diagnostic performance of radiographs, CT, and MRI in carpal fractures.

The primary aim of this prospective study was to describe the fracture epidemiology revealed by MRI in a series of skeletally mature patients with radial wrist pain after acute trauma and clinically suspected to have a scaphoid fracture. In addition, we assessed the diagnostic value of radiographs and CT in patients with scaphoid and other carpal fractures verified by MRI.

MATERIALS AND METHODS

Patients

Over a 3-year period (2004–2007), we asked skeletally mature patients presenting at our emergency department with posttraumatic radial wrist tenderness to participate in the study. The regional ethics committee approved the study design and we obtained written consent.

The inclusion criterion was that the patient experienced tenderness on the radial side of the wrist after an injury. We based the selection on an interview and physical examination, which included testing for tenderness along the anatomical snuffbox and at the scaphoid tubercle and for radial-sided wrist pain by pressing the thumb longitudinally. Exclusion criteria were age under 18 years ($n = 89$) and a delay of more than 14 days from injury to MRI ($n = 34$). A total of 317 patients met the eligibility criteria. However, 15 patients declined to participate in the study, 3 patients were lost because of logistical or technical problems, and 3 patients with perilunate dislocation were operated on immediately without MRI and were not asked to participate. Thus, the study group was composed of 296 patients (300 wrists) with posttraumatic radial wrist tenderness.

Imaging

Patients were referred from the emergency department for wrist and scaphoid radiographs. Regardless of the result, we scheduled MRI of the injured wrist and performed it within 3 working days from inclusion in the study. If the radiographs or MRI revealed a scaphoid fracture, we immediately carried out a supplementary CT scan of the wrist.

We took radiographs of the wrist in dorsovolar and lateral projections with an additional 4 views of the scaphoid.

We used a 0.23-T low-field MRI unit (Proview; Marconi Medicals Systems, Vantaa, Finland) for MRI of the wrist with a dedicated small joint coil and the following study protocol: coronal short tau inversion recovery (STIR), 3-mm slice thickness; coronal T1 field echo 3-dimensional, 2-mm slice thickness; axial T1 fast spin-echo, 3.5-mm slice thickness; and sagittal T1 field echo 3-dimensional, 2-mm slice thickness.

We used a 16-slice CT scanner (Somatom Sensation 16; Siemens AG, Forchheim, Germany) for CT scanning. We obtained a scout view before the scan. Axial sections of 0.6-mm-thick slices were obtained with 1- or 2-mm-thick reconstructions in the coronal and capital planes defined by the long axis of the scaphoid as well as the creation of a 3-dimensional image of the wrist.

On the radiographs, a fracture was defined as a break in the continuity of bone. Criteria for fracture on CT images were the presence of a sharp lucent line within the trabecular bone, a break in the continuity of the cortex, a sharp step in the cortex, or a dislocation of bone fragments.⁴ We considered MRI images to be positive for a fracture when cortical and trabecular fractures were present, causing intramedullary hyperintensity on the STIR as well as intramedullary hypointensity on T1-weighted images extending to the cortices.^{5,6} We diagnosed bone marrow edema when only a zone of diffusely increased signal intensity on STIR images⁴ was present.

The same senior musculoskeletal radiologist (J.B.) evaluated all examinations.

Statistical analysis

We calculated sensitivity and specificity, with 95% confidence intervals (CIs) for the radiographs and for CT (only sensitivity) by means of standard formulas. We used MRI as the reference standard for comparison.

RESULTS

We carried out MRI within a mean of 3 days (range, 0–14 d; median, 2 d) from injury in 296 patients (179

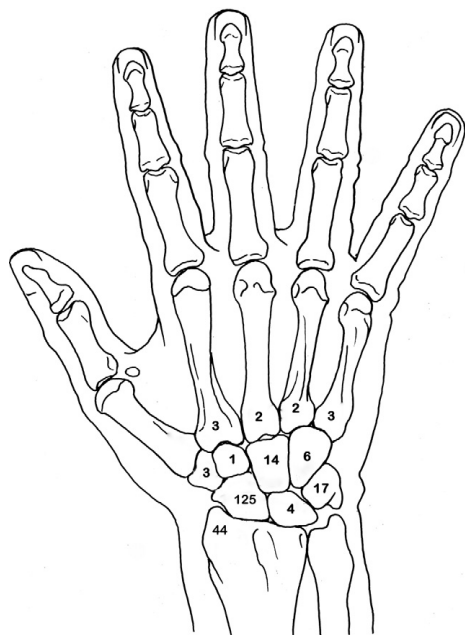


FIGURE 1: Distribution of 224 fractures in 196 wrists diagnosed by MRI.

men and 117 women, with a mean age of 39 y [range, 18–92 y; median, 33 y].

Using MRI as the diagnostic reference standard, we found 224 fractures in 196 of the 300 investigated wrists. An isolated scaphoid fracture was shown in 107 wrists, and a scaphoid fracture in association with other fractures was found in 18 wrists. Thus, MRI revealed a scaphoid fracture in 42% of the investigated wrists with posttraumatic radial wrist tenderness. Furthermore, in 71 wrists (23%), MRI demonstrated other fractures.

The 224 fractures included 170 fractures of carpals, 44 distal radius fractures, and 10 fractures of the metacarpal base. Figure 1 shows the detailed fracture distribution. The most commonly observed fracture combination was scaphoid and distal radius fractures ($n = 10$) (Fig. 2), followed by combined fracture of the scaphoid and the capitate ($n = 7$). In 1 case, a scaphoid fracture diagnosed on radiographs was seen in combination with fractures of the capitate, triquetrum, radial styloid, and metacarpal, none of which were visible on the radiographs. Magnetic resonance imaging showed 9 wrists (3%) with bone edema, located primarily in the scaphoid ($n = 4$) and the capitate ($n = 2$).

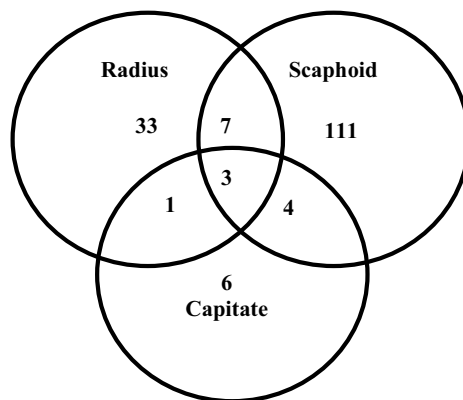


FIGURE 2: Distribution of concomitant fractures of the scaphoid, capitate, and distal radius in 165 injured wrists (Venn diagram).

In none of the patients did radiographs show signs of scapholunate dissociation measured by an increased scapholunate joint space (≥ 5 mm) or an increased scapholunate angle ($\geq 60^\circ$).

A comparison of radiographs with MRI showed that 121 of the 224 fractures could be diagnosed by x-rays alone, corresponding to an overall 54% sensitivity. Sensitivity in the diagnosis of scaphoid fractures reached 70%, for triquetrum fractures reached 59%, and for distal radius fractures reached 43%. Sensitivity for other carpal fractures was poor (Table 1). Radiographs showed 3 false-positive scaphoid fractures among the 175 negatives according to MRI, resulting in a specificity of 98% (95% CI 95% to 100%).

We performed a CT scan in 122 of the 125 wrists that were MRI positive for a scaphoid fracture. Thus, we performed supplementary CT in 4 of 6 hamate, 9 of 44 distal radius, and 8 of 14 capitate fractures. Using CT imaging, it was possible to visualize 116 scaphoid fractures corresponding to 95% sensitivity (95%, CI 91% to 97%), all hamate fractures (100% sensitivity; 95%, CI 40% to 100%), 7 distal radius fractures (78% sensitivity; 95%, CI 40% to 97%), and 6 capitate fractures (75% sensitivity, 95%, CI 35% to 97%).

DISCUSSION

We demonstrated a high incidence of carpal fractures as well as distal radius and metacarpal fractures in patients with posttraumatic radial wrist tenderness. The variety of fractures revealed probably resulted from a common trauma mechanism involving a fall onto an outstretched hand. The overall distribution of fractures is in agree-

TABLE 1. Sensitivity of Plain Radiographs Compared With MRI in Suspected Scaphoid Fractures

	Scaphoid	Triquetrum	Distal Radius	Metacarpal	Lunate	Capitate	Hamate
MRI (n)	125	17	44	10	4	14	6
Plain radiographs (n)	87	10	19	3	1	1	0
Sensitivity (95% CI)	70% (61–78)	59% (33–82)	43% (28–59)	30% (7–65)	25% (0.6–81)	7% (0.2–34)	0% (0.0–46)

ment with earlier epidemiological studies and reports on carpal fractures.^{7–10}

Delayed diagnosis and treatment of the most common carpal fracture—the scaphoid fracture—is a matter of concern because of the risk for nonunion and degenerative changes. The true incidence of scaphoid fracture in patients with acute wrist injury presenting with clinical signs suggestive of scaphoid fracture has been reported to range from 15% to 26%,^{1,8} based on initial radiographs and follow-up radiographs at 10 to 14 days. This is in clear contrast to the incidence found in our study, which was as high as 42%. There are several reasons for this discrepancy. Our results are based on MRI findings and not radiographs alone, which have a lower sensitivity for detection of scaphoid fractures than MRI, as we have shown in this study. The results from earlier MRI studies are not comparable with ours because those studies were performed on patients with suspected scaphoid fracture—that is, patients in whom there was a clinical suspicion of scaphoid fracture, but whose initial radiographs were negative and thus did not include fractures detected on initial radiographs.^{11,12} As part of an epidemiological investigation, we explored posttraumatic radial wrist tenderness and not solely scaphoid fractures. Therefore, we included all cases regardless of findings on the initial radiographs.

We found 1 or more additional fractures in 14% of the wrists diagnosed as having a scaphoid fracture. The incidence of capitate fractures was higher than previously described, and it was the most common carpal fracture to occur in association with a scaphoid fracture. Fenton¹³ popularized the view that a scaphocapitate fracture syndrome occurs when the capitate impacts on the dorsal rim of the radius. Although a capitate fracture-dislocation is rare, it is clear that a hyperextension injury to the wrist can cause a nondisplaced capitate fracture. In such cases, associated scapholunate ligament injury should be suspected, according to Mayfield et al.¹⁴ We detected the capitate fractures in our study mainly using MRI. We found the sensitivity when using radiographs (7%) to be substantially lower than using CT (75%). The improved ability of MRI to visualize trabecular fracture patterns could explain these differ-

ences.¹⁵ In this study, we used a low-field MRI scanner and a first-generation multi (16)-slice CT scanner. High-field strength MRI equipment, which is standard in most hospitals today, offers major advantages for musculoskeletal imaging compared with the low-field MRI equipment used in this study.¹⁶ The better signal-to-noise ratio in high-field scanners can be used to obtain superior imaging of cartilage, ligaments, and soft tissue lesions. However, high-field scanners have not been clearly shown to be required for diagnosis of carpal fractures because fracture edema is easily detectable on a 0.23-T scanner. Today, 64 and 128 multi-slice CT scanners are standard equipment in many institutions. They offer several advantages over a 16-slice CT scanner in detecting carpal pathology.

The results of MRI depend largely on the paradigm for the investigation. To assess a fast protocol that could easily be implemented in daily practice, Beeres et al¹² performed only coronal MRI with a relatively large field of view. However, in our experience this type of investigation is unreliable because of the risk of false-negative results, which can be avoided by performing additional MRI views or sequences.

Although we did not include 3 patients with perilunate dislocation, it is interesting that the radiographs did not demonstrate scapholunate dissociation in any of the included patients. We chose not to report on suspected lesions of intrinsic ligaments or the triangular fibrocartilage complex based on MRI because of the low-field equipment used and the fact that no reference standard, such as arthroscopy, was available in all cases. However, we know from a study we published earlier¹⁷ that some patients with nondisplaced scaphoid fractures actually had a complete scapholunate ligament rupture. This confirmed our clinical experience that scapholunate dissociation is rarely demonstrated on radiographs in the initial phase after traumatic rupture.

The strength of our study is that it represents a large prospective cohort. A more reliable comparison between MRI and CT might have been provided had CT been performed on all patients. The best diagnostic reference standard is debatable,¹⁸ but we believe that using our definition for MRI in diagnosing a fracture

will provide few false-positive results. We acknowledge the difficulties in distinguishing bone edema from fracture. Nevertheless, in a previously published study,¹⁷ we used a specific arthroscopic protocol to verify MRI fracture signs and subtle unicortical lines seen on CT, and we were unable to demonstrate false-positive findings to indicate bone bruise instead of a fracture.

An important question is whether all fractures described in this study needed treatment and if diagnosing them was beneficial for the patient or led to overprotection and overtreatment of injuries that would have healed well without treatment. Some fractures described in this study would likely have healed without specific treatment. However, we believe that a better understanding of the epidemiology of posttraumatic radial wrist tenderness and improved knowledge of the optimal diagnostic modality for this patient group provide the treating doctor with good possibilities to administer the best treatment for the patient, whether it is advanced surgical procedures or no treatment at all. Furthermore, it is valuable to explain long-term symptoms in patients when radiographs are normal, and there is a potential advantage in being able to rule out a fracture by MRI, because the patient would then avoid unnecessary immobilization while waiting for repeated examination and radiographs.

REFERENCES

1. Parvizi J, Wayman J, Kelly P, Moran CG. Combining the clinical signs improved diagnosis of scaphoid fractures. *J Hand Surg Br.* 1998;23(3):324–327.
2. Pincus S, Weber M, Meakin A, Breadmore R, Mitchell D, Spencer L, et al. Introducing a clinical practice guideline using early CT in the diagnosis of scaphoid and other fractures. *West J Emerg Med.* 2009;10(4):227–232.
3. Ring D, Lozano-Calderon S. Imaging for suspected scaphoid fracture. *J Hand Surg Am.* 2008;33(6):954–957.
4. Memarsadeghi M, Breitenesher MJ, Schaefer-Prokop C, Weber M, Aldrian S, Gabler C, et al. Occult scaphoid fractures: comparison of multidetector CT and MR imaging—initial experience. *Radiology.* 2006;240(1):169–176.
5. Zanetti M, Bischof TP, Hodler J. Magnetic resonance tomography of the hand: current status [in German]. *Praxis (Bern 1994).* 1994; 83(45):1261–1266.
6. Breitenesher MJ, Metz VM, Gilula LA, Gaebler C, Kukla C, Fleischmann D, et al. Radiographically occult scaphoid fractures: value of MR imaging in detection. *Radiology.* 1997;203(1):245–250.
7. Hove LM. Fractures of the hand: distribution and relative incidence. *Scand J Plast Reconstr Surg Hand Surg.* 1993;27(4):317–319.
8. Munk B, Frokjaer J, Larsen CF, Johannsen HG, Rasmussen LL, Edal A, et al. Diagnosis of scaphoid fractures: a prospective multicenter study of 1,052 patients with 160 fractures. *Acta Orthop Scand.* 1995;66(4):359–360.
9. Lohman M, Kivisaari A, Vehmas T, Kinnunen J, Karaharju E, Kaukonen JP, et al. MR imaging in suspected acute trauma of wrist bones. *Acta Radiol.* 1999;40(6):615–618.
10. Hey HW, Chong AK, Murphy D. Prevalence of carpal fracture in Singapore. *J Hand Surg Am.* 2011;36(2):278–283.
11. Brydie A, Raby N. Early MRI in the management of clinical scaphoid fracture. *J Radiol.* 2003;76(905):296–300.
12. Beeres FJ, Rhemrev SJ, den Hollander P, Kingma LM, Meylaerts SA, le Cessie S, et al. Early magnetic resonance imaging compared with bone scintigraphy in suspected scaphoid fractures. *J Bone Joint Surg Br.* 2008;90(9):1205–1209.
13. Fenton RL. The navicular-capitate fracture syndrome. *J Bone Joint Surg Am.* 1956;38(3):681–684.
14. Mayfield JK, Johnson RP, Kilcoyne RK. Carpal dislocations: pathomechanics and progressive perilunar instability. *J Hand Surg Am.* 1980;5(3):226–241.
15. Newberg A, Dalinka MK, Alazraki N, Berquist TH, Daffner RH, DeSmet AA, et al. Acute hand and wrist trauma: American College of Radiology: ACR Appropriateness Criteria. *Radiology.* 2000; 215(suppl):375–378.
16. Ramnath RR. 3T MR imaging of the musculoskeletal system (Part II): clinical applications. *Magn Reson Imaging Clin N Am.* 2006; 14(1):41–62.
17. Jørgsholm P, Thomsen NO, Bjorkman A, Besjakov J, Abrahamsson SO. The incidence of intrinsic and extrinsic ligament injuries in scaphoid waist fractures. *J Hand Surg Am.* 2010;35(3):368–374.
18. Mallee W, Doornberg JN, Ring D, van Dijk CN, Maas M, Goslings JC. Comparison of CT and MRI for diagnosis of suspected scaphoid fractures. *J Bone Joint Surg Am.* 2011;93(1):20–28.

Paper II

MRI findings in children and adolescents with clinical symptoms of a scaphoid fracture.

Peter Jørgsholm, Niels Thomsen, Jack Besjakov, Sven Abrahamsson, Anders Björkman.

Department of Hand Surgery and Radiology, Skåne University Hospital Malmö, Sweden.

Correspondance to:

Peter Jørgsholm

Department of Hand Surgery

Skåne University Hospital

SE-205 02 Malmö

Sweden

E-mail: peter.jorgsholm@med.lu.se

Running title: MRI in pediatric carpal fractures.

Key words: Pediatric, scaphoid, carpal, fracture, radiographs, CT, MRI

ABSTRACT

Purpose To describe fractures revealed by magnetic resonance imaging (MRI) in a prospective pediatric population with radial wrist tenderness after an acute injury and clinically suspected to have a scaphoid fracture. Additionally, we assess the diagnostic value of radiographs and computed tomography (CT) in children and adolescents with scaphoid and other carpal fractures verified by MRI.

Methods During 2004 to 2007 all patients, below the age of 18 years presenting at our emergency department with tenderness on the radial side of the wrist after an injury, were included in the study. A total of 90 wrists in 89 patients (57 males and 32 females) underwent clinical and radiographic examination. A low-field, 0.23T MRI was performed of all injured wrists within 3 working days from inclusion in the study. If the radiographs or MRI revealed a scaphoid fracture, a supplementary 16-slice CT scan of the wrist was carried out immediately. The sensitivity and specificity of radiographs and CT for the diagnosis of scaphoid fractures was calculated using MRI as reference standard.

Results A total of 74 fractures were diagnosed in 61 out of 90 wrists using MRI; 53% of the wrists had a scaphoid fracture, 9% a distal radius fracture, 8% a capitate fracture and 3% a triquetrum fracture. The most common fracture combination was that of the scaphoid and capitate. The sensitivity of radiographs for visualization of scaphoid fractures was 54% and the specificity was 100%. Radiographic sensitivity for other fractures was less than 50%. The sensitivity of CT for visualization of scaphoid fractures was 96% and between 33% and 100% for other fractures.

Conclusions MRI showed a high incidence of fractures in pediatric patients with posttraumatic radial wrist tenderness and demonstrated more fractures than radiographs and CT. A scaphoid fracture was by far the most common carpal injury, followed by a fracture of the capitate.

Type of study/level of evidence Diagnostic study, level I.

INTRODUCTION

Carpal fractures in children, age under 16 years, are rare, comprising about 1% of all childhood fractures compared with fractures of the adjacent distal radius which count for 27% of all fractures [1]. Among carpal fractures a scaphoid fractures is the most common but it represents only 5 % of all childhood hand and carpal fractures [1].

The management of suspected scaphoid injury in a pediatric population (age under 18 years) has largely been based on current knowledge on similar injuries in adults for which there is no clear evidence. There are important differences between the pediatric and adult patient. The clinical picture in a pediatric patient is often more difficult to interpret. Point tenderness in the anatomical snuffbox is sometimes not obvious and the young patient often finds it difficult to separate the location of pain on the radial side of the wrist and carpus [2, 3]. The immature skeleton is softer and one rarely see the typical transverse fracture of the carpal bones but rather a buckle fracture [4].

Pediatric scaphoid fractures are believed to mainly involve the distal pole as the ossification pattern of the scaphoid proceeds from distal to proximal [5-7]. However, recent studies on epidemiology [8, 9] have shown a fracture pattern more similar to what is found in the skeletal mature patient. Thus, at present it is thought that waist fractures represent two-thirds of all scaphoid fractures in children older than 10 years whereas distal pole fractures are more common in those younger than 10 years [9].

The optimal diagnostic modality for the detection of wrist injuries in the pediatric patient with posttraumatic radial tenderness and a suspected scaphoid fracture is not known [10]. Standard radiographic evaluation, including four views, is the first line of investigation. Radiographs alone are not enough to rule out a scaphoid fracture [11, 12]. The second line of investigations such as computed tomography (CT) and magnetic resonance imaging (MRI) have been recommended to establish early and definitive diagnosis [11]. CT is easily available and the examination is fast,

however the child is exposed to radiation [13]. MRI has proven useful in assessing adult patients with posttraumatic radial wrist pain [14] and is advocated as the most reliable diagnostic modality in children with suspected scaphoid fractures [11]. However, MRI has limited availability and higher costs compared to radiographs and CT.

Most previous studies on children and adolescents with posttraumatic radial sided wrist pain have been based on radiographs while modern imaging techniques have been selected only in cases where the initial radiographs were normal. Thus, knowledge remains limited concerning both the incidence and distribution of fractures in children with posttraumatic radial wrist tenderness.

Furthermore the diagnostic performance of radiographs, CT and MRI in pediatric carpal fractures is not known.

The primary aim of this study was to describe fracture epidemiology revealed by MRI in patients less than 18 years of age with posttraumatic radial wrist tenderness and clinically suspected to have a scaphoid fracture. As a secondary aim we assessed the diagnostic performance of radiographs and CT on patients with carpal fractures verified by MRI.

MATERIALS AND METHODS

Patients

Over a 3-year period (01.03.2004-28.02.2007) all patients presenting at our emergency department with posttraumatic radial wrist tenderness were asked to participate in the study. The regional ethics committee approved the study design (LU 459-03) and written consent was obtained.

The inclusion criterion was age under 18 years and tenderness on the radial side of the wrist after an injury. The selection was based on an interview and physical examination. The physical examination included testing for tenderness along the anatomical snuffbox and at the scaphoid tubercle and for radial-sided wrist pain by pressing the thumb longitudinally. Exclusion criteria

were age ≥ 18 years and a delay of more than 14 days from injury to MRI. One patient was excluded due to a perilunar injury and one patient declined to have a MRI investigation. A total of 89 patients met the eligibility criteria corresponding to 90 wrists with posttraumatic radial wrist tenderness.

Imaging

The patients were referred from the emergency department for wrist and scaphoid radiographs. Regardless of the result, MRI of the injured wrist was scheduled and performed within 3 working days from inclusion in the study. If the radiographs or MRI revealed a scaphoid fracture, a supplementary CT scan of the wrist was performed immediately.

Radiographs of the wrist in posteroanterior (PA) and lateral projections were taken with an additional 4 views of the scaphoid (posteroanterior with ulnar deviation, with the central beam angled 10° cranially, 10° caudally, 20° ulnarly and 20° radially).

A 0.23 Tesla low-field MRI unit was used (Proview, Marconi Medicals Systems, Vantaa, Finland) for MRI of the wrist with a dedicated small joint coil and the following study protocol: coronal short tau inversion recovery (STIR), 3 mm slice thickness; coronal T1 field echo 3-dimensional (FE3D), 2 mm slice thickness; axial T1 fast spin-echo (FSE), 3.5 mm slice thickness; and sagittal T1 field echo 3-dimensional (FE3D), 2 mm slice thickness.

A 16-slice CT scanner (Somatom Sensation 16; Siemens AG, Forchheim, Germany) was used for the CT scanning. The patient was placed prone with the hand to be examined above the head (superman position). A scout view was obtained before the scan. Axial sections of 0.6 mm thick slices were obtained with 1 or 2 mm thick reconstructions in the coronal and capital planes defined by the long axis of the scaphoid as well as the creation of a 3-dimensional image of the wrist. The radiation dose was calculated to approximately 0.02 mSv, (equivalent to 7 days of background radiation).

On the radiographs, a fracture was defined as a break in the continuity of bone. The epiphyses were considered open when the 1st metacarpal had a visible fully open epiphyseal line on the PA projection on the radiographs and closed when 1st metacarpal epiphyseal line was closed. The criteria for fracture on CT images were the presence of a sharp lucent line within the trabecular bone, a breakage in the continuity of the cortex, a sharp step in the cortex, or a dislocation of bone fragments [15]. MRI was considered positive for a fracture when cortical and trabecular fractures were present, causing intramedullary hyperintensity on the STIR as well as intramedullary hypointensity on T1-weighted images extending to the cortices [16, 17]. Bone marrow edema was diagnosed when only a zone of diffusely increased signal intensity on STIR images [15] was present.

The same senior musculoskeletal radiologist (JB) evaluated all the examinations.

Statistical analysis

Sensitivity and specificity with 95% confidence intervals (CI) for proportions, were calculated using the exact method by Clopper-Pearson [18] for the radiographs and for CT (only sensitivity). MRI was used as the reference standard for the comparison.

RESULTS

MRI was carried out within a mean of 3 days (range, 0-14; median 2) from injury in 89 patients (57 males and 32 females, with a mean age of 13.4 years (range, 8-17; median 14)).

Using MRI as the reference standard we found 74 fractures in 61 (68%) of the 90 investigated wrists. An isolated scaphoid fracture was seen in 38 wrists, and a scaphoid fracture in association with other fractures was found in 10 wrists. Thus, MRI revealed a scaphoid fracture in 53% of the investigated wrists with posttraumatic radial wrist tenderness. Furthermore, in 13 wrists (14%) MRI demonstrated other fractures.

The 74 fractures included 48 scaphoid fractures, 12 fractures of other carpal bones, 8 distal radius fractures, and 6 fractures of the metacarpal base (Fig 1). The most commonly observed fracture combination was a scaphoid and a capitate fracture (N=5) (Fig. 2) followed by combined fracture of the scaphoid and the distal radius (N=3) and scaphoid and triquetrum (N=2). In one case a metacarpal fracture diagnosed on radiographs was seen in combination with fractures of the capitate, hamate, and trapezoid, none of which were visible on the radiographs. MRI showed one wrist with bone edema, located in the capitate.

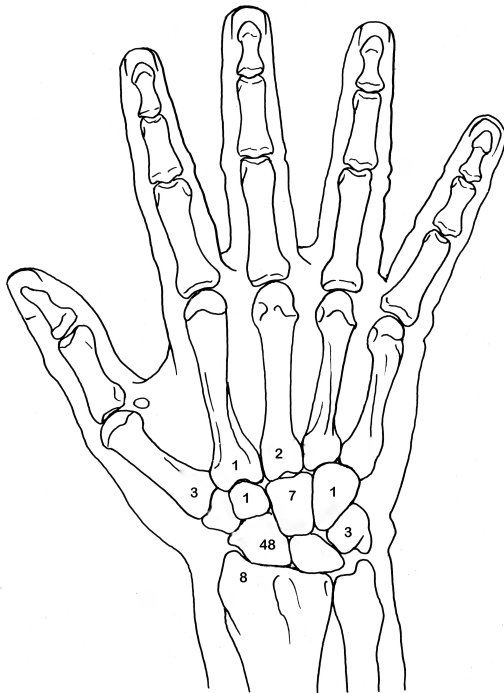


FIG. 1: Distribution of 74 fractures in 90 wrists diagnosed by MRI.

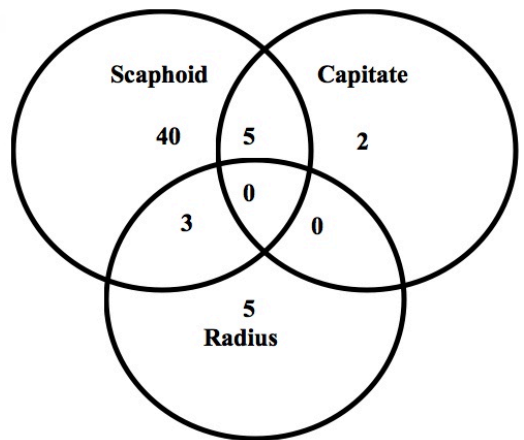


FIG. 2: Distribution of concomitant fractures of the scaphoid, capitate and distal radius in 90 injured wrists.

A comparison of radiographs with MRI showed that 34 of the 74 fractures could be diagnosed by radiographs alone, corresponding to an overall sensitivity of 46%. Sensitivity in the diagnosis of scaphoid fractures reached 54%, distal radius fractures 50%, metacarpal fractures 50% and triquetral fractures 33%. Sensitivity for other carpal fractures was poor (Table 1). Radiographs showed no false positive scaphoid fractures according to MRI, resulting in a specificity of 100% (95% CI 92-100%).

A CT scan was performed in 45 of the 48 wrists that were MRI-positive for a scaphoid fracture. Three scaphoid fractures did not have the scheduled CT scan for administrative reasons. Thus, CT was performed in 6 out of 7 capitate fractures, 3 out of 8 distal radius fractures and 2 out of 6 metacarpal fractures. Using CT it was possible to visualize 43 scaphoid fractures corresponding to 96% sensitivity, 4 capitate fractures (67% sensitivity), 3 distal radius fractures (100% sensitivity) and 1 metacarpal fractures (50% sensitivity) (Table 2).

Table 1.

TABLE 1. Sensitivity of radiographs compared with MRI in pediatric patients with radial wrist tenderness							
	Scaphoid	Distal radius	Capitate	Metacarpal	Triquetrum	Hamate	Trapezoid
MRI (n)	48	8	7	6	3	1	1
Plain radiographs (n)	26	4	0	3	1	0	0
Sensitivity (95% CI)	54% (39-69)	50% (18-90)	0% (0-41)	50% (12-88)	33% (1-91)	0% (0-98)	0% (0-98)

Table 2.

TABLE 2. Sensitivity of CT compared with MRI in pediatric patients with radial wrist tenderness							
	Scaphoid	Distal radius	Capitate	Metacarpal	Triquetrum	Hamate	Trapezoid
MRI (n)	48	8	7	6	3	1	1
CT (n) [CT investigated]	43 [45]	3 [3]	4 [6]	1 [2]	1 [2]	1 [1]	1 [1]
Sensitivity (95% CI)	96% (85-99)	100% (16-100)	67% (22-96)	50% (1-99)	50% (1-99)	100% (3-100)	100% (3-100)

The anatomic distribution of all 48 scaphoid fractures, detected on MRI, is summarized in Figure 3A. Twenty-five scaphoid fractures (52%) were localized in the waist and 22 in the distal pole (46%) and one in the proximal pole (2%). The fracture pattern in patients with open physes varied from those in patients with closed physes, but not significantly ($p>0.05$). In skeletal immature patients (open 1st metacarpal physes) distal and waist fractures were equal common and no proximal fractures were found (Fig. 3B). In patients with closed 1st metacarpal physes waist fractures were the most common fracture (Fig. 3C).

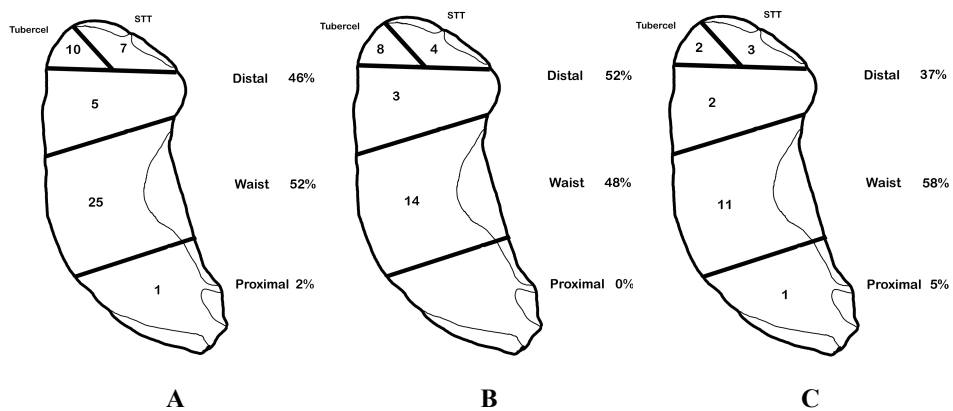


FIG. 3: Anatomic distribution of scaphoid fractures. A: All scaphoid fractures in pediatric patients. B: Fractures in immature scaphoid. C: Fractures in mature scaphoid.

DISCUSSION

In this study we show that carpal fractures are common among children and adolescents attending hospital due to posttraumatic radial wrist tenderness. A scaphoid fracture is the most common carpal fracture (80%) followed by a capitate fracture (12%). 2/3 of the attending patients have a hand or wrist fracture. We also show that radiographs have a poor diagnostic performance in detecting carpal fractures whereas CT has a good diagnostic performance in detecting radius, scaphoid and some, but not all carpal fractures.

The carpal bones have an individual and progressive ossification, starting in the capitate and

hamate, through triquetrum and lunatum, scaphoid, trapezium and trapezoid and finally the pisiforme. The ossification pattern of the scaphoid proceeds from distal to proximal. It is said to terminate at 15 years and 3 months in boys and at 13 years and 4 months in girls [19] with a wide span [20]. The 1st metacarpal has a simultaneous ossification as the scaphoid and is a good indicator on scaphoid maturity [19]. Which carpal bone is likely to fracture and the way that it fractures will depend on the degree of ossification. The capitate is the first carpal bone to ossify [19], which might explain why we find 10% of the fractures to be capitate fractures in the present study compared to 6% among adults [14].

In the skeletal immature patients (open physes) we find distal and waist scaphoid fractures equally common (Fig. 3B). Gholson et al [9] found more than twice as many waist fractures as distal fractures (68%/26%) in patients with open physes. Whether these patients had open physes in distal radius/ulna or 1st metacarpal is not fully clear. Furthermore the study had a limited use of MRI and the overall study population was somewhat older than the present. This might be an explanatory factor to the discrepancy.

The actual study differs from most previous studies as we investigated all patients with posttraumatic radial sided wrist pain with a MRI and not only those, which had a normal radiograph [2, 21].

In an earlier study from our institution analyzing the adult population [14] we found a similar frequency of fractures in general (68% in children and 65% in adults) but a higher frequency of scaphoid fractures (53% versus 42%). In the above mentioned study in skeletal mature patients [14] radiographs detected 70% of scaphoid fractures and 7% of capitate fractures. In this present study the radiographic performance in detecting scaphoid fractures are only 54% and 0% to detect capitate fractures. It seems as if carpal fractures in children and adolescents are difficult to visualize on radiographs. This leads us to suggest that it is even more important in a pediatric patient with

posttraumatic radial wrist tenderness and negative radiography to proceed to a second line investigation. Approximately one-third of children (<16 years) with clinically suspected scaphoid fracture will not become radiographically evident until follow-up at two weeks [3, 22]. Scaphoid non-unions are a concern in the pediatric population (< 18years) as almost one-third present late with non-unions and these fractures have a poor prognosis if not operated [9].

We see one or more additional fractures in 20% of the wrists diagnosed as having a scaphoid fracture. A Capitate fractures is the most common carpal fracture to occur in association with a scaphoid fracture. We find the sensitivity to detect a capitate fracture when using radiographs to be poor (0%) but still surprisingly low when using CT (67%). Today 64 and 128 multi-slice CT scanners are standard equipment in many institutions. They offer several advantages over the 16-slice CT scanner used in this study and may have increased the diagnostic performance in detecting other carpal fractures.

A concern in CT investigations in the pediatric patient is the radiation load. Nevertheless, we find that CT projections with the arms above the head (superman position) will keep the radiation dose to a minimum [23].

We used a low-field, 0.23T, MR scanner but today high field scanners are standard at most hospitals. They offer a better signal to noise ratio and provide improved images although high field scanners have not proven superior in detecting carpal fractures as the fracture edema is easily detected on a 0.23 T scanner. As a MRI investigation requires that the patient do not move during the procedure, children can be challenging to examine. After all, we had a scanning time of 12-15 minutes and none of the pediatric patients aborted the examination or needed sedation and all acquired examinations were of a good diagnostic quality.

The strength of our study is that it represents a large prospective cohort. A more reliable comparison between MRI and CT may have been provided had CT been performed on all patients.

The best diagnostic reference standard is debatable [24], but we find, when using our definition for MRI in diagnosing a scaphoid fracture will provide few false positive results. In a previously published study including adolescents [25] an arthroscopic protocol was used to verify MRI scaphoid fracture signs and subtle unicortical lines seen on CT, and we were unable to demonstrate false positive findings to indicate bone bruise instead of fracture. In children a high T2 signal has been reported in the carpus during growth with a maximum around 7-11 years of age which theoretically could produce false positive results in this age group [26].

Detecting scaphoid fractures in children and adolescents is important in order to avoid development of nonunion and degenerative changes. However the question is whether all fractures described in this study needed treatment and if diagnosing them were beneficial for the patient. Some fractures described in this study would likely have healed without specific treatment. Never the less, we believe that a better understanding of the epidemiology of the pediatric patient attending with symptoms suggestive of scaphoid fracture is important. Improved knowledge of the optimal diagnostic modality for this patient group would provide the treating doctor with the best possibility to chose the optimal treatment for the patient. Finally there is a an potential advantage in being able to rule out a fracture by MRI, as the patient will avoid unnecessary immobilization while waiting for repeated examinations and radiographs with inevitable accumulated radiation.

In conclusion MRI in pediatric patients with clinically sign of a scaphoid fracture will diagnose many fractures in the radial side of the hand and wrist not seen on plain radiographs.

Acknowledgement

The authors would like to acknowledge Jonas Björk, PhD, for his assistance with the statistical analysis and Mikael Gunnarsson, PhD for his assistance in calculating the radiation load.

REFERENCES

1. Brudvik, C. and L.M. Hove, *Childhood fractures in Bergen, Norway: identifying high-risk groups and activities*. J Pediatr Orthop, 2003. **23**(5): p. 629-34.
2. Wilson, E.B., T.F. Beattie, and A.G. Wilkinson, *Epidemiological review and proposed management of 'scaphoid' injury in children*. Eur J Emerg Med, 2011. **18**(1): p. 57-61.
3. Evenski, A.J., et al., *Clinically suspected scaphoid fractures in children*. J Pediatr Orthop, 2009. **29**(4): p. 352-5.
4. Hernandez, J.A., et al., *Scaphoid (navicular) fractures of the wrist in children: attention to the impacted buckle fracture*. Emerg Radiol, 2002. **9**(6): p. 305-8.
5. Mussbichler, H., *Injuries of the carpal scaphoid in children*. Acta radiol, 1961. **56**: p. 361-8.
6. Vahvanen, V. and M. Westerlund, *Fracture of the carpal scaphoid in children. A clinical and roentgenological study of 108 cases*. Acta Orthop Scand, 1980. **51**(6): p. 909-13.
7. Christodoulou, A.G. and C.L. Colton, *Scaphoid fractures in children*. J Pediatr Orthop, 1986. **6**(1): p. 37-9.
8. Stanciu, C. and A. Dumont, *Changing patterns of scaphoid fractures in adolescents*. Can J Surg, 1994. **37**(3): p. 214-6.
9. Gholson, J.J., et al., *Scaphoid fractures in children and adolescents: contemporary injury patterns and factors influencing time to union*. J Bone Joint Surg Am, 2011. **93**(13): p. 1210-9.
10. Fotiadou, A., et al., *Wrist injuries in young adults: the diagnostic impact of CT and MRI*. Eur J Radiol, 2011. **77**(2): p. 235-9.
11. Johnson, K.J., S.F. Haigh, and K.E. Symonds, *MRI in the management of scaphoid fractures in skeletally immature patients*. Pediatr Radiol, 2000. **30**(10): p. 685-8.
12. Goddard, N., *Carpal fractures in children*. Clin Orthop Relat Res, 2005(432): p. 73-6.
13. Brody, A.S., et al., *Radiation risk to children from computed tomography*. Pediatrics, 2007. **120**(3): p. 677-82.
14. Jorgsholm, P., et al., *The benefit of magnetic resonance imaging for patients with posttraumatic radial wrist tenderness*. J Hand Surg Am, 2013. **38**(1): p. 29-33.
15. Memarsadeghi, M., et al., *Occult scaphoid fractures: comparison of multidetector CT and MR imaging--initial experience*. Radiology, 2006. **240**(1): p. 169-76.

16. Zanetti, M., T.P. Bischof, and J. Hodler, [*Magnetic resonance tomography of the hand: current status*]. Praxis (Bern 1994), 1994. **83**(45): p. 1261-6.
17. Breitenseher, M.J., et al., *Radiographically occult scaphoid fractures: value of MR imaging in detection*. Radiology, 1997. **203**(1): p. 245-50.
18. Hollander M, W.D., *Nonparametric statistical methods*. 2nd edition ed. 1999, New Yourk: John Wiley & Sons.
19. Stuart, H.C., et al., *Onsets, completions and spans of ossification in the 29 bonegrowth centers of the hand and wrist*. Pediatrics, 1962. **29**: p. 237-49.
20. Hagg, U. and J. Taranger, *Skeletal stages of the hand and wrist as indicators of the pubertal growth spurt*. Acta Odontol Scand, 1980. **38**(3): p. 187-200.
21. Ahmed, I., et al., *The pediatric fracture of the scaphoid in patients aged 13 years and under: an epidemiological study*. J Pediatr Orthop, 2014. **34**(2): p. 150-4.
22. Nafie, S.A., *Fractures of the carpal bones in children*. Injury, 1987. **18**(2): p. 117-9.
23. Biswas, D., et al., *Radiation exposure from musculoskeletal computerized tomographic scans*. J Bone Joint Surg Am, 2009. **91**(8): p. 1882-9.
24. Mallee, W., et al., *Comparison of CT and MRI for diagnosis of suspected scaphoid fractures*. J Bone Joint Surg Am, 2011. **93**(1): p. 20-8.
25. Jorgsholm, P., et al., *The incidence of intrinsic and extrinsic ligament injuries in scaphoid waist fractures*. J Hand Surg Am, 2010. **35**(3): p. 368-74.
26. Shabshin, N. and M.E. Schweitzer, *Age dependent T2 changes of bone marrow in pediatric wrist MRI*. Skeletal Radiol, 2009. **38**(12): p. 1163-8.

Paper III

The Incidence of Intrinsic and Extrinsic Ligament Injuries in Scaphoid Waist Fractures

Peter Jørgsholm, MD, Niels O. B. Thomsen, PhD, Anders Björkman, PhD, Jack Besjakov, PhD, Sven-Olof Abrahamsson, PhD

Purpose To determine the incidence of associated intrinsic and extrinsic ligament injuries in patients with a nondisplaced or displaced scaphoid waist fracture.

Methods During a 3-year period, a study of all scaphoid fractures was performed at our institution. Diagnosis was confirmed by plain radiographs, computed tomography, and magnetic resonance imaging. A 3-part anatomic classification was used to categorize the scaphoid fractures. The study population comprised 40 patients with 41 scaphoid waist fractures who had wrist arthroscopy for treatment and evaluation of the scaphoid fracture and associated carpal injuries.

Results We observed fresh intrinsic ligament injuries in 34 of 41 wrists. In 29 cases, the scapholunate ligament was injured, with complete rupture occurring in 10 wrists. The lunotriquetral ligament was injured in 8 wrists, and the triangular fibrocartilage complex was injured in 11 wrists. Statistically, the number of intrinsic ligament injuries did not differ between nondisplaced and displaced scaphoid fractures ($p > .30$).

Conclusions In this study of acute scaphoid waist fractures, the overall incidence of associated ligament injuries was surprisingly high, at 34 of 41 wrists. Complete scapholunate ligament rupture was found in 10 of 41 wrists. This incidence is higher than previously reported and emphasizes the need for careful assessment of the intrinsic and extrinsic ligaments, particularly the scapholunate ligament, before deciding on treatment. (*J Hand Surg* 2010;35A:368–374. Copyright © 2010 by the American Society for Surgery of the Hand. All rights reserved.)

Key words Arthroscopy, intrinsic ligament injury, scaphoid fracture, scapholunate ligament injury.

MOST SCAPHOID FRACTURES are traditionally treated with cast immobilization. The influence of surgical and technological developments, combined with an increasing demand from

young and active patients, has moved treatment toward surgical fixation and early mobilization. One of the latest techniques involves arthroscopic-assisted, percutaneous screw fixation.¹ During an arthroscopic procedure, the surgeon can also assess concurrent intrinsic and extrinsic ligament injuries, as these injuries can be difficult to diagnose clinically or radiographically.² A concomitant ligamentous injury represents a potentially more serious injury and can affect the management and clinical outcome of the scaphoid fracture.³

Previously, the accepted view has been that a nondisplaced scaphoid fracture would effectively exclude the occurrence of an associated scapholunate (SL) ligament injury,^{4,5} although such a simultaneous occurrence has been described in high-energy perilunate fracture–dislocations.^{6–10} Other studies have described the occurrence of SL ligament tears in association with

From the Department of Hand Surgery and Department of Radiology, Malmö University Hospital, University of Lund, Sweden.

Received for publication February 11, 2009; accepted in revised form December 16, 2009.

The authors would like to acknowledge Jonas Björk, PhD, for his assistance with the statistical analysis and the Scania Regional Scientific Grants and Malmö University Hospitals Grants for financial support.

The authors were supported by grants from Scania Regional Scientific and Malmö University Hospitals. No benefits in any form have been received or will be received related directly or indirectly to the subject of this article.

Corresponding author: Peter Jørgsholm, MD, Department of Hand Surgery, University Hospital Malmö, SE-20502 Malmö, Sweden; e-mail: peter.jorgsholm@med.lu.se.

0363-5023/10/35A03-0002\$36.00/0
doi:10.1016/j.jhsa.2009.12.023

isolated scaphoid fractures.^{8–10} Some of these studies relied on standard, static, radiographic investigations^{11,12} based on whether SL dissociation or dorsal intercalated segment instability was present and, in 1 study, on the appearance of the SL ligament during volar surgical approach.¹³ Two recent arthroscopic studies have reported a higher percentage of concomitant scaphoid fracture and SL ligament injury, leading the authors to question the previously accepted pathomechanism of wrist injuries.^{3,14} These 2 reports, however, rely either on retrospective data or only partly on arthroscopic findings.

The purpose of our study was to determine the incidence, as determined arthroscopically, of associated intrinsic and extrinsic ligament injuries in a series of patients with displaced or nondisplaced scaphoid waist fractures.

MATERIALS AND METHODS

Patients

During a 3-year period (2004–2007), all patients presenting to our emergency unit with a suspected scaphoid fracture were asked to participate in a scaphoid study. The study protocol was approved by the ethics committee of Lund University, and all patients gave their written consent to participate. A total of 217 consecutive scaphoid fractures were diagnosed by means of clinical examination, plain radiographs, magnetic resonance imaging (MRI), and computed tomography (CT). All 3 diagnostic imaging modalities were used for all patients. Nineteen patients were excluded either because they had an associated perilunate dislocation ($n=4$) or because they declined to participate in the study ($n=15$). The remaining 198 scaphoid fractures were categorized according to whether they were proximal, middle third, or distal, based on plain radiographs and CT scans. We found 125 distal third (distal), 67 middle third (waist), and 6 proximal third (proximal) scaphoid fractures. Only those patients with confirmed fracture of the waist region were enrolled in the study ($n=67$). Fifteen patients had displaced waist fractures (>1 mm dislocation or diastasis and/or $>15^\circ$ volar angulation) as seen on their CT scan, and all were included. As part of another study, 52 patients with nondisplaced waist fractures were randomized to receive either surgical or nonsurgical treatment. Twenty-six patients with nondisplaced waist fractures were randomized to arthroscopic surgery. Forty patients with displaced and nondisplaced waist fractures were enrolled in our prospective database, which included a patient questionnaire. Gender, age, activity when injured (sport, traffic, work, or other), type of injury (fall,

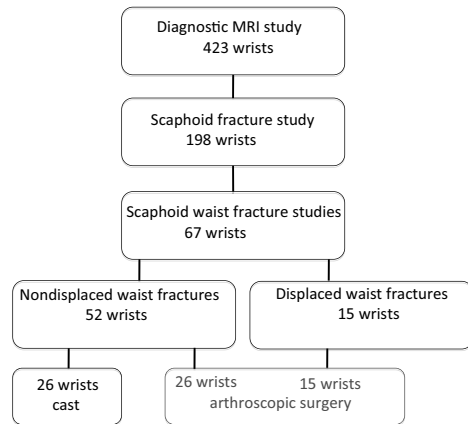


FIGURE 1: Diagram of the different scaphoid fracture studies.

blow, or other), pathomechanism (extension, flexion, or other), and high-energy trauma, defined as a fall from more than 1 m of height,¹⁵ were recorded. Finally, 41 wrists had arthroscopy and were included in this study (Fig. 1).

Radiology

Conventional plain radiographic films (AXIOM Aristos FX; Siemens AG, Forchheim, Germany) of the wrist in dorsovolar and lateral projections were obtained, with an additional 4 views of the scaphoid bone. A 16-slice CT scanner (Somatom Sensation 16; Siemens AG, Forchheim, Germany) was used. A scout view was obtained before the scan. Axial sections of 0.6-mm thick slices were obtained with 1- or 2-mm-thick reconstructions in the coronal and sagittal planes, and 3-dimensional images were also obtained.

For MRI of the wrist, a 0.23-T, low-field MRI unit was used (Proview; Marconi Medical Systems, Vantaa, Finland) with a dedicated small joint coil and the following study protocol: coronal short tau inversion recovery, 3 mm slice thickness; coronal T1 field echo 3-dimensional, 2 mm slice thickness; axial T1 fast spin-echo, 3.5 mm slice thickness; and sagittal T1 field echo 3-dimensional, 2 mm slice thickness.

All examinations were evaluated by the same senior musculoskeletal radiologist (J.B.), and a fracture was defined as a breakage in the continuity of bone. We regarded an MRI as positive for a fracture of the scaphoid if the short tau inversion sequences presented with intramedullary hyperintensity in the scaphoid zone and if the T1-weighted sequences were seen with a in-

Erratum

Peter Jørgsholm; Scaphoid Fractures.
Epidemiology, diagnosis and treatment.

Paper III, page 369, Material and methods, Patients, line 17:
Should be changed to:

‘We found 63 distal third (distal), 128 middle third (waist),
and 7 proximal third (proximal) scaphoid fractures.’

TABLE 1. Classification of Tears of the Scapholunate Interosseous Ligament According to Geissler¹⁸

Grade	Description
1	Attenuation or hemorrhage of interosseous ligament as seen from radiocarpal space. No incongruence of carpal alignment in midcarpal space.
2	Attenuation or hemorrhage of interosseous ligament as seen from radiocarpal space. Incongruence or stepoff of carpal space. There might be a slight gap (less than width of probe) between carpal bones.
3	Incongruence or stepoff of carpal alignment as seen from both radiocarpal and midcarpal space. Probe can be passed through gap between carpal bones.
4	Incongruence or stepoff of carpal alignment as seen from both radiocarpal and midcarpal space. There is gross instability with manipulation. A 2.7-mm arthroscope can be passed through gap between carpal bones.

tramedullary zone of hypointensity, extending to the cortices.^{16,17}

The fracture type was defined according to whether the major part (>50%) of the fracture line was situated in the proximal, middle, or distal third of the bone. This was applied to the radiographic oblique view in which the scaphoid had the maximum length, supplemented with the information obtained in the 3-dimensional reconstructions of the CT scans.

Surgical procedure

A protocol for arthroscopic evaluation was designed to facilitate uniform reporting. The different ligaments were defined on a figure, and the surgeon had the option of making his own drawings on a schematic view of a left or right wrist. The SL and lunotriquetral (LT) ligament injuries were categorized according to Geissler¹⁸ (Table 1). The triangular fibrocartilage complex (TFCC) injuries were categorized according to Palmer.¹⁹ Injuries to the volar extrinsic ligaments and to the dorsal capsule were categorized as hemorrhage, partial tear, or complete rupture. The volar extrinsic ligaments investigated were the radioscapophcapitate ligament, the long radiolunate ligament, and the short radiolunate ligament, together with the ulnolunate and the ulnotriquetral ligament.

Arthroscopy was performed under axillary block or general anesthesia with a tourniquet on the upper arm and the hand in a vertical traction tower (Parko, Kerteminde, Denmark). Using fingertraps on the index and long fingers, 5 kg of traction was applied. A 1.9-mm or 2.7-mm arthroscope (Smith & Nephew, Andover, MA) was used in combination with a motorized shaver (Apex small joint shaver; Linvatec, Largo, FL) to clear the joint of blood, debris, and synovitis. The standard 3–4 and 4–5 intercompartmental portals and the 6R (radial) and 6U (ulnar) on each side of sixth compartment were used in the radiocarpal joint. In the midcarpal joint, the standard radial and ulnar portals were used

and, in some cases, supplemented with the scaphotrapezotrapezoid joint portal; no volar portals were used. An image intensifier (Fluoroscanner; Hologic, Bedford, MA) was used in all procedures.

All surgical procedures were performed by 1 of the authors (P.J., N.T., or A.B.). The senior author (P.J.) performed the surgery in 27 cases and assisted in 10 cases. The other 2 authors (N.T. and A.B.) performed 10 and 4 cases, each with assistance of the senior author in 7 and 3 cases, respectively. The responsible surgeon completed the arthroscopic protocol.

Statistical analysis

All statistical analyses were performed using statistical software (StatXact-6; Cytel Software Corp., Cambridge, MA), with a *p* value <.05 being regarded as statistically significant. Fisher's exact test was used to investigate differences in the prevalence of various types of ligament injuries for various fracture types. We also calculated prevalence ratios (PRs) and exact 95% confidence intervals (CIs). An exact test was used, based on the binomial distribution, to test whether the prevalence of selected (binary) outcomes such as high-energy trauma, differed significantly from 50%. Finally the Mann-Whitney test was used to compare the number of ligament injuries with scaphoid fracture displacement, concomitant fractures, and high-energy trauma.

RESULTS

Arthroscopic surgery was performed on 41 scaphoid waist fractures in 40 patients (30 men and 10 women) at a mean age of 32 years (range, 14–71 y; median, 27 y) within a mean of 11 days (range, 2–65 d; median, 7 d) after injury. The most common mechanism of injury was a fall (36/41), and the positioning of the wrist was reported to be in extension by 25/41. Many injuries occurred during sporting activities (17/41) such as playing soccer, skateboarding, or snowboarding. In 14 wrists, the patients had sustained a high-energy trauma.

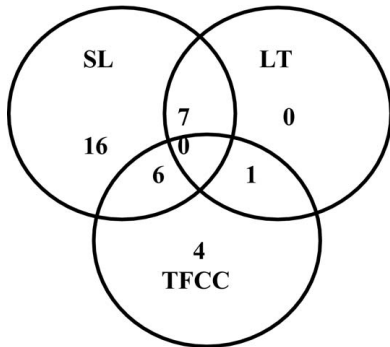


FIGURE 2: Distribution of concomitant intrinsic ligament injuries in 41 scaphoid waist fractures (Venn diagram).

TABLE 2. Number and Type of SL Ligament Injuries in Nondisplaced and Displaced Scaphoid Waist Fractures

SL Injury (Geissler Grade ¹⁸)	Nondisplaced Fracture (n=25)	Displaced Fracture (n=16)	Total (n=41)
1	4	3	7
2	6	3	9
3	1	2	3
4	7	3	10
Total	18	11	29

Overall, 34 wrists had injuries to 1 or more intrinsic ligaments (Fig. 2).

At arthroscopy, we found SL ligament injuries in 29 wrists, of which 10 had a complete tear (Geissler grade 4; Table 2). The overall number of SL ligament injuries did not differ between nondisplaced and displaced fractures ($p>.30$). No significant difference could be demonstrated between the severity of the SL ligament injury (Geissler grade 1–2 vs Geissler grade 3–4) and scaphoid fracture displacement ($p>.30$). In the partial SL ligament tears, the injuries were found in the dorsal component in 17 of 19 wrists. The location of 2 partial SL tears was not recorded.

We found partial LT ligament injury in 8 wrists (Table 3). There was no difference in the number of LT ligament injuries between nondisplaced and displaced fractures ($p>.30$). When comparing the number of minor ligament injuries (Geissler grade 1–2) with that of major ligament injuries (Geissler grade 3–4), no significant differences could be found between scaphoid frac-

TABLE 3. Number and Type of LT Ligament Injuries in Nondisplaced and Displaced Scaphoid Waist Fractures

LT Injury (Geissler Grade ¹⁸)	Nondisplaced Fracture (n=25)	Displaced Fracture (n=16)	Total (n=41)
1	3	1	4
2	0	2	2
3	1	1	2
4	0	0	0
Total	4	4	8

ture displacement and the severity of LT ligament injury ($p>.30$).

In 11 wrists, we observed acute traumatic tear to the TFCC (Palmer 1), and in 1 wrist, we found degenerative changes (Palmer 2). Six wrists had Palmer 1A injuries, and 5 had Palmer 1D injuries. The number of injuries did not differ between nondisplaced and displaced fractures (6/25 vs 5/16; $PR=1.3$; 95% $CI=0.41$ – 4.1 ; $p>.30$).

Nine wrists had injuries to their volar extrinsic ligaments. However, we found only 9 minor injuries, such as hemorrhages or partial tears, and none with complete rupture. The number of volar extrinsic ligament injuries did not differ between nondisplaced and displaced fractures (6/25 vs 3/16; $PR=1.3$; 95% $CI=0.37$ – 9.4 ; $p>.30$).

Of a total of 16 injuries to the dorsal capsule, 8 wrists had a rupture of the entire dorsal capsule, 7 wrists had a partial rupture, and 1 wrist had only a hemorrhage. There were significantly more ruptures in displaced fractures (3/25 vs 13/16; $PR=6.8$; 95% $CI=2.5$ – 36 ; $p<.001$).

Seven wrists had 1 or more concomitant fractures (4 radius, 3 capitate, 2 triquetral, 1 lunate, and 1 base of metacarpal). All these fractures were nondisplaced and closed. The metacarpal base, the lunate, and the capitate fractures were all intra-articular.

The number of intrinsic ligament injuries did not correlate with any of the following factors: fracture displacement, concomitant fracture, or the involvement of high energy ($p>.30$; $p=.14$; $p>.30$).

DISCUSSION

In our arthroscopic evaluation of displaced and nondisplaced scaphoid waist fractures, we found that 71% had associated acute SL-ligament injuries and 24% had a complete SL ligament rupture. The overall number of

SL-ligament injuries is high compared to findings in previous studies involving arthroscopic examination, where incidences of between 14% to 50% have been reported.^{3,14,20–22} In these studies, complete SL ligament ruptures were reported, but none was classified as Geissler grade 4.

There could be several explanations for the high incidence of SL ligament injuries found in our study. One is that we specifically searched for intrinsic ligament injuries using defined diagnostic parameters. Another explanation might be the use of different classification systems and their interpretation.^{18,23} Using Geissler's classification, Schädel-Höpfner and co-workers found no grade 4 injuries.¹⁴ On the other hand, using Krimmer's classification, they still classified 10 of 13 as complete SL ligament injuries. We found 10 complete SL ligament injuries, and all were classified as Geissler grade 4, in which we could pass the arthroscope through the gap between the scaphoid and lunate. A high incidence of ligament injuries might also occur if chronic tears were included. However, this was not the case in our study, as most SL ligament injuries showed signs of acute injury, with either hemorrhage or fresh, sharp edges (Fig. 3). In 2 patients with SL ligament injury and scaphoid fracture, we had an interval of more than 3 weeks from injury to arthroscopy. One had a Geissler grade 4 injury but no sign of osteoarthritis and no history of previous injury. The other patient had a Geissler grade 2 injury with attenuation but no hemorrhage. In this latter patient, it was hard to decide whether it was a chronic tear. Seventeen of the 19 partial SL ligament tears involved the dorsal component, and none were reported to be in the membranous or volar part.

We found an LT ligament injury in 20% of the wrists examined arthroscopically, but no complete ruptures were observed. In 27% of the wrists, we diagnosed a TFCC injury. These results are comparable with others where associated LT ligament injury has been found in 17% to 25% and associated TFCC injury in 14% to 66% of patients.^{3,21,23}

Few previous studies have examined the incidence of extrinsic ligament injuries. We found an incidence of volar extrinsic ligament injuries of 22% (9/41) compared to the 8% (2/24) found by Caloia and co-workers.²¹ In both studies, all extrinsic ligament injuries were partial injuries. We also found rupture of the dorsal capsule in 37% of the fractures, which was not noted in other studies.

The pathomechanism involved in creating a scaphoid fracture is forceful hyperextension of the wrist. In an experimental setting, Mayfield and colleagues⁵ pre-

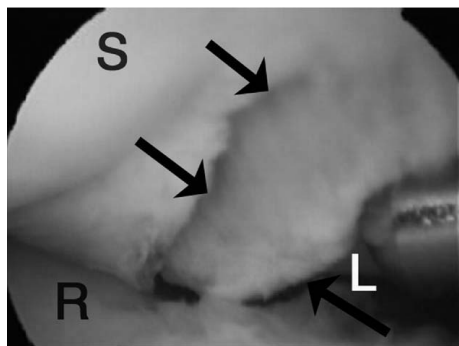


FIGURE 3: Radiocarpal joint in a right wrist (S, scaphoid; R, radius; L, lunate). Arrows indicate fresh, sharp edges and hemorrhage in a completely torn SL ligament. Shaver blade seen far right.

sented the concept of “progressive perilunar instability” to explain the sequence by which intrinsic ligament injuries progress from perilunate to lunate dislocation. The mechanism of injury included hyperextension, ulnar deviation, and intercarpal supination. The term *lesser arc injury* describes a perilunate dislocation with ligament injuries only, whereas a *greater arc injury* involves perilunate carpal fractures and potential ligament injuries. Johnson stated that any combination of these injuries could be found, but scaphoid fracture and complete scapholunate disruption were unlikely to occur simultaneously.⁴ In our study, we found the combination of scaphoid fracture and complete scapholunate ligament disruption in 24% of the injuries. We believe that the *in vivo*, 3-dimensional injury mechanisms, with varying degrees of compressing and rotational force, explain our findings. The fact that 7 of the 8 LT injuries were seen in combination with SL injuries (Mayfield perilunate dislocation stage 3),⁵ and the high frequency of dorsal capsule injury suggest that such injuries might represent a subluxation or dislocation injury that subsequently reduced spontaneously.

Case presentations have shown that various combinations of ligament injuries and scaphoid fractures are possible.^{8,24,25} These are often high-energy, dislocative injuries, resulting in a free-floating proximal scaphoid pole, with or without an attached lunate. Wong and co-workers³ suggested that the incidence and severity of these associated injuries were determined by the energy of the trauma. However, in our study, even low-energy injuries produced a combined scaphoid fracture and complete SL ligament rupture.

Conservative treatment, in most cases, will lead to scaphoid fracture union, as shown in several studies with a larger number (>200) of patients.^{26–32} With the development of minimally invasive techniques for scaphoid fracture fixation, it has become increasingly popular to offer surgical fixation of even nondisplaced waist fractures in order to avoid long immobilization. However, the benefit of this has been questioned.³³ A high incidence of SL ligament injuries found in scaphoid nonunions has raised the possibility of an association between the 2 injuries.³⁴ Our result suggests that there is an indication for arthroscopy even in nondisplaced scaphoid fractures if surgical fixation and early mobilization is offered to avoid detrimental effects of an undiagnosed ligament tear. The advantage is that arthroscopy allows for evaluation of associated ligament injuries not seen in standard imaging, and it helps to confirm both fracture reduction and the absence of screw protrusion after osteosynthesis.

There are some limitations to our study. The relatively small sample size might hamper the possibility of detecting meaningful associations, particularly regarding ligament injuries in important subgroups, based on fracture displacement or low- or high-energy trauma. The confidence intervals for the prevalence ratios were also generally wide, reflecting the high statistical uncertainty in a relatively small study such as ours. Thus, although we did not observe any association between fracture and type of ligament injury, we should be cautious in concluding that such associations do not exist. Furthermore, we included 1 patient with bilateral wrist injury, but we decided to ignore this statistical dependence because it was expected to have a minor impact on our results. Regarding MRI, we had no false positive fractures confirmed at arthroscopy. However, we could not rule out the occurrence of false negative MRI investigations. Some patients excluded on the basis of MRI scans that did not show scaphoid fractures had scaphoid bone bruises on MRI.

We found a high incidence of intrinsic ligament injuries in patients with scaphoid waist fracture. The ligament injuries were independent of fracture displacement or level of trauma energy. The diagnostic accuracy and clinical relevance of the partial ligament tears is uncertain. Complete SL ligament ruptures were found in 24% of the scaphoid waist fractures. We believe that the combination of these 2 lesions is clinically important because it might lead to an increased risk of developing scaphoid nonunion. This is certainly evident in the displaced fracture with a complete SL ligament rupture, where a high degree of instability can be observed arthroscopically, combined with a poten-

tially poor vascularity of the proximal pole with torn vessels on both the fracture and the ligament side. However, this remains to be proven in the clinical setting. Given our findings, we recommend arthroscopy or dorsal mini-arthrotomy to assess and treat associated intrinsic ligament injuries if the treatment offered for the scaphoid fracture is stable fixation and mobilization.

REFERENCES

- Whipple TL. Stabilization of the fractured scaphoid under arthroscopic control. *Orthop Clin North Am* 1995;26:749–754.
- Schadel-Hopfner M, Iwinska-Zelder J, Braus T, Bohringer G, Klose KJ, Gotzen L. MRI versus arthroscopy in the diagnosis of scapholunate ligament injury. *J Hand Surg* 2001;26B:17–21.
- Wong TC, Yip TH, Wu WC. Carpal ligament injuries with acute scaphoid fractures—a combined wrist injury. *J Hand Surg* 2005;30B:415–418.
- Johnson RP. The acutely injured wrist and its residuals. *Clin Orthop Relat Res* 1980;33–44.
- Mayfield JK, Johnson RP, Kilcoyne RK. Carpal dislocations: pathomechanics and progressive perilunar instability. *J Hand Surg* 1980;5:226–241.
- Campbell RD Jr, Thompson TC, Lance EM, Adler JB. Indications for open reduction of lunate and perilunate dislocations of the carpal bones. *J Bone Joint Surg* 1965;47A:915–937.
- Weiss C, Laskin RS, Spinner M. Irreducible trans-scaphoid perilunate dislocation. A case report. *J Bone Joint Surg* 1970;52A:565–568.
- Schakel M, Dell PC. Trans-scaphoid palmar lunate dislocation with concurrent scapholunate ligament disruption. *J Hand Surg* 1986;11A:653–655.
- Braithwaite II, Jones WA. Scapho-lunate dissociation occurring with scaphoid fracture. *J Hand Surg* 1992;17B:286–288.
- Herzberg G, Comtet JJ, Linscheid RL, Amadio PC, Cooney WP, Stalder J. Perilunate dislocations and fracture-dislocations: a multicenter study. *J Hand Surg* 1993;18A:768–779.
- Vender MI, Watson HK, Black DM, Strickland JW. Acute scaphoid fracture with scapholunate gap. *J Hand Surg* 1989;14A:1004–1007.
- Ahovuo J, Saarinen O, Hovi I, Kinnunen J, Paavolainen P. Bone malalignment in acute injuries of the wrist. *Ann Chir Gynaecol* 1991;80:282–284.
- Filan SL, Herbert TJ. Herbert screw fixation of scaphoid fractures. *J Bone Joint Surg* 1996;78B:519–529.
- Schadel-Hopfner M, Junge A, Bohringer G. Scapholunate ligament injury occurring with scaphoid fracture—a rare coincidence? *J Hand Surg* 2005;30B:137–142.
- NOMESCO. Classification of external causes of injuries. 3rd ed. Copenhagen: NOMESCO, 1997:39.
- Zanetti M, Bischof TP, Hodler J. Magnetic resonance tomography of the hand: current status [in German]. *Praxis (Bern)* 1994;83:1261–1266.
- Breitseher MJ, Metz VM, Gilula LA, Gaebler C, Kukla C, Fleischmann D, et al. Radiographically occult scaphoid fractures: value of MR imaging in detection. *Radiology* 1997;203:245–250.
- Geissler WB, Freeland AE, Savoie FH, McIntyre LW, Whipple TL. Intracarpal soft-tissue lesions associated with an intra-articular fracture of the distal end of the radius. *J Bone Joint Surg* 1996;78A:357–365.
- Palmer AK. Triangular fibrocartilage complex lesions: a classification. *J Hand Surg* 1989;14A:594–606.
- Bohringer G, Schadel-Hopfner M, Lemke T, Gotzen L. Arthroscopically controlled minimal invasive screw fixation of scaphoid fractures. A pilot study [in German]. *Unfallchirurg* 2000;103:1086–1092.
- Caloia MF, Gallino RN, Caloia H, Rivarola H. Incidence of ligamentous and other injuries associated with scaphoid fractures during arthroscopically assisted reduction and percutaneous fixation. *Arthroscopy* 2008;24:754–759.

22. Ho PC, Hung LK, Lung TK. Acute ligamentous injury in scaphoid fracture. *J Bone Joint Surg* 2000;82B:82.
23. Krimmer H, Hahn P, Prommersberger KJ, Sauerbier M, Lanz U. Current treatment of scapholunate dissociation [in German]. *Aktuelle Traumatologie* 1996;26:264–269.
24. Ekerot L. Palmar dislocation of the trans-scaphoid-lunate unit. *J Hand Surg* 1995;20B:557–560.
25. Chamarthi SK, Nunna S, Kumar AA, Kiranmayi AL. Transscaphoid lunate dislocation with ejection of proximal pole of scaphoid into forearm. *Indian J Radiol Imaging* 2006;16:272–274; <http://www.ijri.org/article.asp?issn=0971-3026;year=2006;volume=16;issue=2;epage=272;epage=274;aulast=Chamarthi>. Accessed January 6, 2010.
26. Bohler L, Trojan E, Jahna H. Treatment of 734 cases of fresh fracture of the scaphoid bone of the hand [in German]. *Wiederherstellungschir Traumatol* 1954;II:86–111.
27. Russe O. Fracture of the carpal navicular. Diagnosis, non-operative treatment, and operative treatment. *J Bone Joint Surg* 1960;42A:759–768.
28. Leslie JJ, Dickson RA. The fractured carpal scaphoid. Natural history and factors influencing outcome. *J Bone Joint Surg* 1981;63B:225–230.
29. Langhoff O, Andersen JL. Consequences of late immobilization of scaphoid fractures. *J Hand Surg* 1988;13B:77–79.
30. Lindstrom G, Nystrom A. Incidence of post-traumatic arthrosis after primary healing of scaphoid fractures: a clinical and radiological study. *J Hand Surg* 1990;15B:11–13.
31. Clay NR, Dias JJ, Costigan PS, Gregg PJ, Barton NJ. Need the thumb be immobilised in scaphoid fractures? A randomised prospective trial. *J Bone Joint Surg* 1991;73B:828–832.
32. London PS. The broken scaphoid bone. The case against pessimism. *J Bone Joint Surg* 1961;43A:237–244.
33. Dias JJ, Wildin CJ, Bhowal B, Thompson JR. Should acute scaphoid fractures be fixed? A randomized controlled trial. *J Bone Joint Surg* 2005;87A:2160–2168.
34. Monsivais JJ, Nitz PA, Scully TJ. The role of carpal instability in scaphoid nonunion: casual or causal? *J Hand Surg* 1986;11B:201–206.

Paper IV

Factors Associated With Arthroscopically Determined Scaphoid Fracture Displacement and Instability

Geert A. Buijze, MD, Peter Jørgsholm, MD, Niels O. B. Thomsen, MD, PhD, Anders Björkman, MD, PhD, Jack Besjakov, MD, PhD, David Ring, MD, PhD

Purpose To identify factors associated with arthroscopically diagnosed scaphoid fracture displacement and instability.

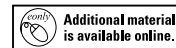
Methods This was a secondary use of data from 2 prospective cohort studies. The studies included 58 consecutive adult patients with a scaphoid fracture who elected arthroscopy-assisted operative fracture treatment: some for displacement, some as part of a prospective protocol, and others to avoid a cast. All patients had preoperative computed tomography with reconstructions in planes defined by the long axis of the scaphoid.

Results Arthroscopy revealed 38 unstable fractures (movement between fracture fragments; 66%), 27 of which were also displaced. All arthroscopically determined displaced fractures were unstable, and 11 of the 31 arthroscopically determined, nondisplaced fractures were unstable. There was a significant correlation between radiographic comminution (more than 2 fracture fragments) and arthroscopically determined displacement and instability.

Conclusions Radiographic comminution is associated with displacement and instability as determined by arthroscopy. (*J Hand Surg* 2012;37A:1405–1410. Copyright © 2012 by the American Society for Surgery of the Hand. All rights reserved.)

Type of study/level of evidence Prognostic II.

Key words Scaphoid fracture, diagnosis of displacement, instability, computed tomography, wrist arthroscopy.



DISPLACEMENT IS A RISK factor for nonunion of a scaphoid waist fracture.^{1–5} The words “displacement” and “instability” are often used interchangeably when referring to scaphoid waist fractures,^{6–10} but it is worthwhile to distinguish movement

of the fracture fragments with gentle manipulation (instability) from fracture fragments that are out of position (displacement). At the scaphoid waist, displaced fractures are almost always unstable, but unstable fractures are not always displaced.

With respect to scaphoid nonunion, studies suggest that nonunions located distal to the apex on the dorsal ridge of the scaphoid are usually unstable (the fracture fragments are mobile), whereas nonunions located proximal to the apex are usually stable.^{11–14} If the same proved true for acute scaphoid fractures, fracture location might be a relative indication for surgery.

We tested the null hypothesis that there was no relationship between fracture location relative to the apex on the dorsal ridge of the scaphoid and arthroscopically evaluated scaphoid fracture displacement and instability. Furthermore, we tested whether

From the Orthopaedic Hand and Upper Extremity Service, Massachusetts General Hospital, Harvard Medical School, Boston, MA; and the Departments of Hand Surgery and Radiology, Skåne University Hospital, University of Lund, Malmö, Sweden.

G.A.B. thanks the Netherlands Organization for Scientific Research for support.

Received for publication October 12, 2011; accepted in revised form April 5, 2012.

No benefits in any form have been received or will be received related directly or indirectly to the subject of this article.

Corresponding author: David Ring, MD, PhD, Orthopaedic Hand and Upper Extremity Service, Massachusetts General Hospital, Harvard Medical School, Yawkey Center, Suite 2100, 55 Fruit Street, Boston, MA 02114; e-mail: dring@partners.org.

0363-5023/12/37A07-0016\$36.00/0
http://dx.doi.org/10.1016/j.jhssa.2012.04.005

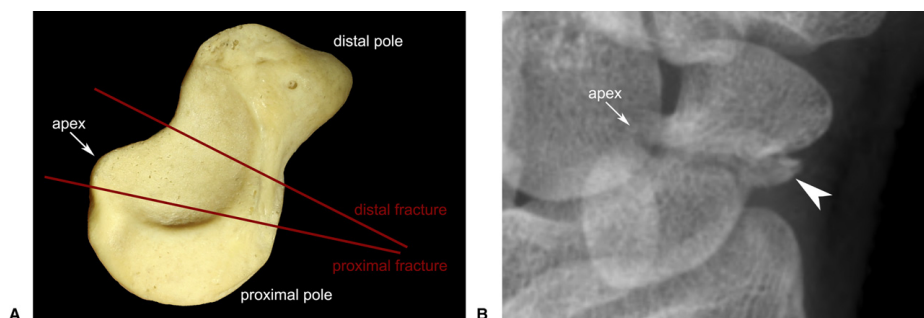


FIGURE 1: **A** Schematic image of the scaphoid showing lines indicating a fracture positioned proximal and distal of the apex on the dorsal ridge. **B** Example of a fracture through the apex with a comminuted fragment (arrowhead) seen on oblique radiography.

other demographic and injury characteristics could explain arthroscopic displacement and instability of scaphoid fractures.

MATERIALS AND METHODS

The institutional review board at both institutions approved the secondary use of data from 2 prospective cohort studies of patients undergoing arthroscopy-assisted surgery for a scaphoid waist fracture. The original study evaluated the diagnostic performance characteristics (eg, sensitivity and specificity) of radiography and computed tomography (CT) for arthroscopic evaluation of scaphoid displacement and instability and was published separately. The database created by the 2 studies consisted of all adult patients (age 18 y or greater) with an isolated fracture of the scaphoid (irrespective of fracture displacement and location) and without previous history of trauma to the affected wrist who elected operative treatment during a 3-year period (2004–2007) at 1 institution and a 4-year period (2006–2010) at the other institution. We obtained informed consent from all patients. The prospective cohort of operated patients consisted of all radiologically displaced scaphoid fractures and a selection of nondisplaced scaphoid fractures based on preference, to avoid cast immobilization (both institutions), or on randomization as part of another study (1 institution).

The total cohort consisted of 58 patients (Malmö, $n = 43$; Boston, $n = 15$). There were 44 men and 14 women, with a mean age of 34 years (range, 18–76 y). All patients were treated by arthroscopy-assisted surgery within a mean of 15 days after injury (range, 2–80 days) and had preoperative radiographs and CT. Demographic and injury characteristics were

prospectively recorded, with the exception of the fracture location relative to the apex on the dorsal ridge on CT, which was retrospectively recorded. Demographic characteristics included age and sex. Injury characteristics included the energy of trauma (high or low, as determined by the treating surgeon), fracture comminution on radiographs (more than 2 fracture fragments), fracture location (proximal third, middle third, or distal third), fracture location relative to the apex on the dorsal ridge on CT (proximal, distal, or through apex), scapholunate ligament injury detected during arthroscopy (no rupture or partial/total rupture), and surgical delay (days between injury and surgery).

Imaging protocols

We obtained radiographs of the wrist with at least 4 views of the scaphoid: posteroanterior, lateral, posteroanterior with ulnar deviation, and semi-pronated oblique. In addition, all patients had CT of the wrist with reconstructions in the coronal and sagittal planes, defined by the long axis of the scaphoid.¹⁵ One of 3 musculoskeletal radiologists and the treating physician evaluated all radiological examinations to reach consensus on a fracture (defined as discontinuity of bone), displacement (either gapping and/or translation greater than 1 mm or dorsal tilting of the lunate greater than 15° with respect to the radius on a true lateral radiograph with the third metacarpal parallel to the radius), and comminution (more than 2 fracture fragments) of the scaphoid fracture (Fig. 1). On static imaging (radiographs and CT), nondisplaced fractures were defined as stable, and displaced fractures as unstable.^{9,16} We performed these evaluations as part of the prospective study, with the exception of the fracture location relative to the apex on the dorsal ridge of the scaphoid,

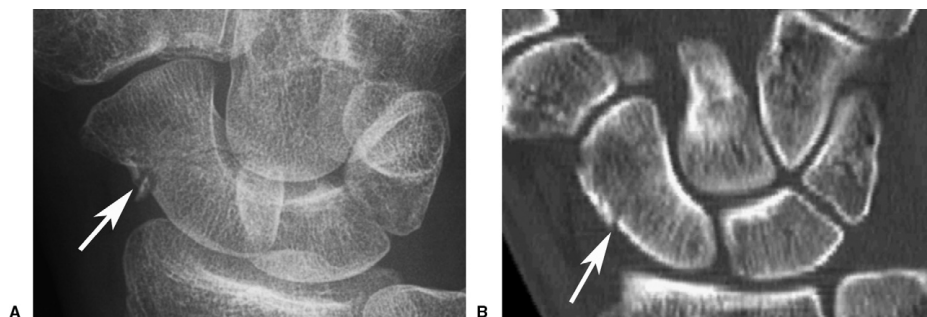


FIGURE 2: Example of radiographically comminuted and nondisplaced or minimally displaced fracture (arrow) on radiographs **A** and the same fracture (arrow) CT **B** that was arthroscopically displaced and unstable (see Video 1 [available on the *Journal's* Web site at www.jhandsurg.org]).

which was done for the purposes of this specific study, and was thus performed at a later date. A musculoskeletal radiologist determined: (1) whether the fracture location was situated distal or proximal to the apex on the dorsal ridge of the scaphoid by looking for the distal cortical discontinuity in relation to the anatomical landmark of the apex (Fig. 1); and (2) whether the fracture was located in the proximal, middle, or distal third by measuring whether the major part (> 50%) of the fracture line was situated in the proximal, middle, or distal third of the bone. This was applied to the radiographic oblique view in which the scaphoid had the maximum length, supplemented with the information obtained in the 3-dimensional reconstructions of the CT scans.

Surgical procedure

We performed arthroscopy under brachial plexus block or general anesthesia with a tourniquet on the upper arm and the hand in a vertical traction tower. Using finger traps on the index and middle fingers, we applied up to 5 kg of traction. We used a 1.9- or 2.7-mm arthroscope, sometimes in combination with a motorized shaver to clear the joint of blood, debris, and synovitis. At 1 institution, we used the standard 3–4, 4–5, 6R, and 6U portals in the radiocarpal joint; at the other institution, we used only the 3–4 portal because the scaphoid fracture can rarely be visualized with the arthroscope in the radiocarpal joint. In the midcarpal joint, we used the standard radial and ulnar portals. In some cases, we supplemented them with the scaphotrapezotrapezoid joint portal; we did not use volar portals. We employed a small image intensifier in all procedures. One of 4 surgeons at the 2 institutions performed all surgical procedures.

We collected data from both institutions in the prospective cohort studies and applied the following definitions. During arthroscopy with up to 5 kg of traction across the wrist, we defined static malalignment (gapping, translation, or angulation of the fracture) as arthroscopic displacement. Arthroscopic instability was diagnosed if the fracture fragments could be moved with gentle manipulation of the bone by applying external pressure on the distal pole of the scaphoid, by deviating the wrist in radial and ulnar direction, or by inserting a probe between the fracture fragments. In other words, we diagnosed a fracture as arthroscopically displaced when the fragments were out of position, and diagnosed a fracture as arthroscopically unstable when the fragments could be moved out of position. At 1 institution, the scapholunate ligament was routinely inspected.¹⁷

Statistical analysis

For bivariate analysis of predictors of arthroscopic displacement and instability, the independent (or explanatory) variables that we investigated included age, sex, energy of trauma, fracture comminution on radiographs, fracture location (proximal third, middle third, or distal third), fracture location relative to the apex on the dorsal ridge on CT, scapholunate ligament injury detected during arthroscopy, and surgical delay. We evaluated continuous explanatory variables (eg, surgical delay) with the Mann Whitney U test, and categorical variables (eg, comminution) with the chi-square test or Fisher exact test.

We included factors with *P* less than .10 in bivariate analysis into backward stepwise multivariable logistic regression models seeking factors associated with arthroscopic instability and displacement. A post hoc

power analysis determined that 58 patients provided 84% power to identify factors with an odds ratio 3.0 or higher using logistic regression.

RESULTS

Arthroscopy revealed 38 unstable fractures (66%), 27 of which were also displaced (47%). All arthroscopically displaced fractures were unstable and 11 of the 31 arthroscopically nondisplaced fractures were unstable (Fig. 2, Video 1 [available on the *Journal's* Web site at www.jhandsurg.org]).

On CT, 39 fractures were located distal to the apex on the dorsal ridge of the scaphoid, 16 were located proximal to the apex, and 3 were located at the apex, separating it in 2 parts (Fig. 1B). A total of 19 arthroscopically displaced fractures and 20 arthroscopically nondisplaced fractures were located distal to the apex on the dorsal ridge of the scaphoid. In addition, 27 arthroscopically unstable fractures and 12 arthroscopically stable fractures were located distal to the apex on the dorsal ridge of the scaphoid. These differences were not significant for either arthroscopically determined displacement ($P = .08$) or instability ($P = .17$).

In bivariate analysis of factors associated with arthroscopic displacement, only comminution was significant ($P < .001$) (Table 1). One of 31 arthroscopically nondisplaced fractures and 18 of 27 arthroscopically displaced fractures exhibited comminution. There was no comminution in the 20 arthroscopically stable fractures, and 19 of 38 arthroscopically unstable fractures exhibited comminution.

In multivariable analysis, comminution was the only variable that was significant and explained 41% of the variability of arthroscopic displacement (adjusted $r^2 = 0.41$; $P < .001$). The odds of a comminuted fracture correlating with displacement were 50 times greater than for a noncomminuted fracture.

In bivariate analysis of factors associated with intraoperative instability, only comminution was significant ($P < .001$) (Table 2). According to logistic regression, 21% of the variability of arthroscopic instability is explained by comminution (adjusted $r^2 = 0.30$; $P = .001$). The odds of a comminuted fracture correlating with instability were 54 times greater than for a noncomminuted fracture.

DISCUSSION

Theoretically, an acute scaphoid fracture distal to the apex on the dorsal ridge could result in flexion of the distal fragment because the apex coincides with the attachment of the dorsal intercarpal ligament and the dorsal part of the scapholunate interosseous ligament, both

TABLE 1. Bivariate Analysis of Factors Associated With Arthroscopically Diagnosed Displacement

Variable	Nondisplaced (n = 31)	Displaced (n = 27)	P Value
Age (y)	34.7 (18–76)	33.2 (20–71)	.76
Sex (%)			.35
Male	22 (71)	22 (81)	
Female	9 (29)	5 (19)	
Trauma energy (%)			.83
Low	21 (68)	19 (70)	
High	10 (32)	8 (30)	
Comminution (%)			< .001
No	30 (97)	9 (33)	
Yes	1 (3)	18 (67)	
Location (%)			.25
Proximal third	3 (10)	0	
Middle third	26 (84)	26 (96)	
Distal third	2 (6)	1 (4)	
Location relative to apex (%)			.08
Proximal	11 (35)	5 (19)	
Distal	20 (65)	19 (70)	
Through	0	3 (11)	
Scapholunate ligament injury (%)			.61
No	15 (65)	14 (70)	
Partial	1 (4)	2 (10)	
Total	7 (31)	4 (20)	
Surgical delay (d)	14.4 (3–47)	15.0 (2–80)	.67

Continuous variables are reported as mean (range).

important stabilizers of the scaphoid.¹⁸ We found no such relationship based on arthroscopic diagnosis of displacement and instability. Fracture comminution was the only factor associated with displacement and instability diagnosed arthroscopically.

The typical pattern of scaphoid waist fracture comminution is a separate fragment on the radial side.¹⁹ Herbert and Fisher²⁰ classified comminuted fractures as unstable, and noted that they are difficult to repair. With the exception of 1 comminuted but stable fracture, our data agree with the observations of Herbert and Fisher. The high incidence of comminution in our sample (33%) is likely related to the overrepresentation of radiographically displaced fractures (ie, spectrum bias).

TABLE 2. Bivariate Analysis of Factors Associated With Arthroscopically Diagnosed Instability

Variable	Stable (n = 20)	Unstable (n = 38)	P Value
Age (y)	33.3 (20–62)	34.4 (18–76)	.88
Sex (%)			.16
Male	13 (65)	31 (82)	
Female	7 (35)	7 (18)	
Trauma energy (%)			.90
Low	14 (70)	26 (68)	
High	6 (30)	12 (32)	
Comminution (%)			< .001
No	20 (100)	19 (50)	
Yes	0	19 (50)	
Location (%)			.99
Proximal third	1 (5)	2 (5)	
Middle third	18 (90)	34 (90)	
Distal third	1 (5)	2 (5)	
Location relative to apex (%)			.17
Proximal	8 (40)	8 (21)	
Distal	12 (60)	27 (71)	
Through	0	3 (8)	
Scapholunate ligament injury (%)			.56
No	8 (57)	21 (72)	
Partial	1 (7)	2 (7)	
Total	5 (36)	6 (21)	
Surgical delay (d)	15.5 (3–47)	14.3 (2–80)	.74

Continuous variables are reported as mean (range).

Our main finding of the high percentage of arthroscopically unstable fractures among radiographically nondisplaced fractures (traditionally regarded as stable) in the original study prompted this study of factors associated with displacement and instability. Given the fact that over 90% of radiologically nondisplaced scaphoid waist fractures (with presumably similar rates of instability) heal with cast immobilization, instability may not be a risk factor for nonunion.^{6,21–23} Further study is warranted.

The study has limitations. The first relates to the relatively small sample that had been used for prior analyses. The prospective arthroscopic diagnosis of displacement and instability makes it a valuable data set, but the findings of these studies need verification with

different patient samples. Second, the studied population may be subject to spectrum bias compared with previous series, because radiologically displaced fractures were overrepresented (50% vs 10% to 30%).^{2–4,24} Third, the use of 5 kg traction and insertion of the arthroscope might affect fracture alignment and instability. Fourth, we based the arthroscopic findings on subjective measurements performed by 4 different surgeons in 2 centers, which were subject to the possibility of interobserver variability. Fifth, this study did not address the reliability of the diagnosis of fracture location with respect to the apex of the dorsal ridge on CT.

Our data suggest that scaphoid fracture relative to the apex of the dorsal ridge is not associated with arthroscopically diagnosed displacement and instability. Fracture comminution is strongly associated with both displacement and instability. The clinical relevance of the mobility between well-aligned fracture fragments (instability) is unknown.

REFERENCES

- Eddeland A, Eiken O, Hellgren E, Ohlsson NM. Fractures of the scaphoid. *Scand J Plast Reconstr Surg* 1975;9:234–239.
- Szabo RM, Manske D. Displaced fractures of the scaphoid. *Clin Orthop Relat Res* 1988;230:30–38.
- Dabezies EJ, Mathews R, Faust DC. Injuries to the carpus: fractures of the scaphoid. *Orthopedics* 1982;5:1510–1515.
- Bhat M, McCarthy M, Davis TR, Oni JA, Dawson S. MRI and plain radiography in the assessment of displaced fractures of the waist of the carpal scaphoid. *J Bone Joint Surg* 2004;86B:705–713.
- Langhoff O, Andersen JL. Consequences of late immobilization of scaphoid fractures. *J Hand Surg* 1988;13B:77–79.
- Schadel-Hopfner M, Marent-Huber M, Gazyakan E, Tanzer K, Werber KD, Siebert HR. Acute non-displaced fractures of the scaphoid: earlier return to activities after operative treatment. A controlled multicenter cohort study. *Arch Orthop Trauma Surg* 1117;130:1117–1127.
- Buijze GA, Doornberg JN, Ham JS, Ring D, Bhandari M, Poolman RW. Surgical compared with conservative treatment for acute non-displaced or minimally displaced scaphoid fractures: a systematic review and meta-analysis of randomized controlled trials. *J Bone Joint Surg* 2010;92A:1534–1544.
- Chen AC, Chao EK, Hung SS, Lee MS, Ueng SW. Percutaneous screw fixation for unstable scaphoid fractures. *J Trauma* 2005;59:184–187.
- Cooney WP III. Scaphoid fractures: current treatments and techniques. *Instr Course Lect* 2003;52:197–208.
- Burge P. Closed cast treatment of scaphoid fractures. *Hand Clin* 2001;17:541–552.
- Oka K, Moritomo H, Murase T, Goto A, Sugamoto K, Yoshikawa H. Patterns of carpal deformity in scaphoid nonunion: a 3-dimensional and quantitative analysis. *J Hand Surg* 2005;30A:1136–1144.
- Moritomo H, Viegas SF, Elder KW, Nakamura K, Dasilva MF, Boyd NL, et al. Scaphoid nonunions: a 3-dimensional analysis of patterns of deformity. *J Hand Surg* 2000;25A:520–528.
- Moritomo H, Murase T, Oka K, Tanaka H, Yoshikawa H, Sugamoto K. Relationship between the fracture location and the kinematic pattern in scaphoid nonunion. *J Hand Surg* 2008;33A:1459–1468.
- Leventhal EL, Wolfe SW, Moore DC, Akelman E, Weiss AP, Crisco JJ. Interfragmentary motion in patients with scaphoid nonunion. *J Hand Surg* 2008;33A:1108–1115.

15. Sanders WE. Evaluation of the humpback scaphoid by computed tomography in the longitudinal axial plane of the scaphoid. *J Hand Surg* 1988;13A:182–187.
16. Caloia MF, Gallino RN, Caloia H, Rivarola H. Incidence of ligamentous and other injuries associated with scaphoid fractures during arthroscopically assisted reduction and percutaneous fixation. *Arthroscopy* 2008;24:754–759.
17. Jørgsholm P, Thomsen NO, Bjorkman A, Besjakov J, Abrahamsson SO. The incidence of intrinsic and extrinsic ligament injuries in scaphoid waist fractures. *J Hand Surg* 2010;35A:368–374.
18. Viegas SF, Yamaguchi S, Boyd NL, Patterson RM. The dorsal ligaments of the wrist: anatomy, mechanical properties, and function. *J Hand Surg* 1999;24A:456–468.
19. Compson JP. The anatomy of acute scaphoid fractures: a three-dimensional analysis of patterns. *J Bone Joint Surg* 1998;80B:218–224.
20. Herbert TJ, Fisher WE. Management of the fractured scaphoid using a new bone screw. *J Bone Joint Surg* 1984;66B:114–123.
21. Bond CD, Shin AY, McBride MT, Dao KD. Percutaneous screw fixation or cast immobilization for nondisplaced scaphoid fractures. *J Bone Joint Surg* 2001;83A:483–488.
22. Dias JJ, Wildin CJ, Bhowal B, Thompson JR. Should acute scaphoid fractures be fixed? A randomized controlled trial. *J Bone Joint Surg* 2005;87A:2160–2168.
23. Vinnars B, Pietreanu M, Bodestedt A, Ekenstam F, Gerdin B. Non-operative compared with operative treatment of acute scaphoid fractures. A randomized clinical trial. *J Bone Joint Surg* 2008;90A:1176–1185.
24. Thorleifsson R, Karlsson J, Sigurjonsson K. Fractures of the scaphoid bone. A follow-up study. *Arch Orthop Trauma Surg* 1984;103:96–99.

Paper V

Union of scaphoid waist fractures assessed by CT scan.

M. Clementson, MD¹, P. Jørgsholm, MD¹, J. Besjakov, MD, PhD², A.
Björkman, MD, PhD¹, N.O.B. Thomsen, MD, PhD¹

¹Department of Clinical Sciences Malmö – Hand Surgery, Lund University, Skåne
University Hospital, S-205 02 Malmö, Sweden

²Department of Radiology, Skåne University Hospital, S-205 02 Malmö, Sweden

Key words

arthroscopy, bone union, CT scan, scaphoid fracture, wrist

Grants

Financial support has been received from Region Skåne and Skåne University
Hospital.

Ethics

The Regional Ethics Committee at Lund University approved the study (LU 459-03)

Address for correspondence:

N.O.B. Thomsen, MD, PhD. Department of Hand Surgery, Skåne University
Hospital, SE-205 02 Malmö, Sweden. (niels.thomsen@med.lu.se)

Abstract

Background Union of scaphoid fractures are difficult to assess on a standard series of radiographs. An unnecessary and prolonged immobilization is inconvenient and may impair functional outcome. While operative treatment permits early mobilization, the influence on time to union is still uncertain.

Purpose To assess union of scaphoid waist fractures based on CT scan at 6 weeks, and to compare time to union between conservative treatment and arthroscopically assisted screw fixation.

Patients and methods CT scan in the longitudinal axis of the scaphoid was used to provide fracture characteristics, and to assess bone union at 6 weeks in 65 consecutive patients with scaphoid waist fractures. In a randomized subgroup from this cohort with non-displaced fractures, we compared time to union between conservative treatment (n=23) and arthroscopically assisted screw fixation (n=15).

Results Overall, at 6 weeks we found a 90% union rate for non- or minimally displaced fractures, treated conservatively and 82% for those who underwent surgery. In the randomized subgroup of non-displaced fractures, no significant difference in time to union was demonstrated between those treated conservatively, and those who underwent surgery. The conservatively treated fractures from this subgroup with prolonged time to union (10 to 14 weeks) were comminuted, demonstrating a radial cortico- or cortico-spongyous fragment.

Conclusion The majority of non- or minimally displaced scaphoid waist fractures are sufficiently treated with 6 weeks in a cast. Internal fixation does not reduce time to fracture union, compared to conservative treatment.

Introduction

After adequate conservative or operative management, union is achieved for approximately 90% of non-displaced scaphoid waist fractures,¹⁻³ while prolonged time to union as well as a higher non-union rate was demonstrated for displaced scaphoid fractures.^{4, 5} The serious consequences of non-union, such as progressive degenerative changes and carpal collapse, have resulted in a restrictive treatment regime with immobilization of non-displaced scaphoid waist fractures for 8 to 12 weeks.^{6, 7}

There is an on-going debate on the advantages of internal fixation versus conservative management of non-displaced scaphoid waist fractures. A possible advantage of internal fixation is reduced time to union, which could allow earlier mobilization and thereby improve functional outcome. However, these benefits may come with an increased rate of complications due to the surgical intervention.⁸ So far, comparative studies on time to union, are mainly based on radiographs and not on CT scans. Nevertheless, the latter has proven more reliable and accurate in the assessment of scaphoid fracture characteristics and union.^{9, 10} Arthroscopically assisted screw fixation of scaphoid waist fractures is a well-established procedure.^{11, 12} It has numerous advantages compared to an entirely percutaneous technique such as: direct visualization of fracture reposition, aids to optimal guide-wire positioning, to check countersinking of screw threads, assessment of fixation stability and furthermore, allows evaluation of associated ligament injuries.

We have previously performed a study on consecutive scaphoid fractures, using MRI and CT reconstructions in the coronal and sagittal planes of the wrist.¹³ Since then, it has been suggested that many scaphoid fractures are probably over-treated and could safely be mobilized much earlier than previously recommended.^{14, 15}

The aim of this study was to re-evaluate the CT scans obtained at 6 weeks, with reconstruction in the longitudinal axis of the scaphoid, to assess union of the scaphoid waist fractures. Furthermore, from a randomized subgroup of the patients with non-, or minimal displaced scaphoid waist fracture, we were able to evaluate if time to union differs between conservative management in a cast and arthroscopically assisted screw fixation.

Patients and Methods

During a four-year period (2004-2008) consecutive patients presenting at our Emergency Department with post-traumatic radial wrist tenderness, were asked to participate in a prospective study on diagnosis and treatment of scaphoid fractures. One study arm encompassed all patients with scaphoid waist fracture regardless of the degree of fracture displacement. A subgroup from this prospective cohort with non-, or minimally displaced scaphoid waist fractures ($< 1\text{ mm}$ displacement and/or $< 15^\circ$ volar angulation)¹⁶ were randomized, using a blinded envelope system, to cast immobilization or arthroscopically assisted screw fixation (► **Fig. 1**). The Regional Ethics Committee at Lund University approved the study (LU 459-03) and a written informed consent was obtained from all eligible patients.

For the purpose of this study, only patients who, in addition to the initial CT scan, had a CT scan done at 6 weeks of follow-up were included. We excluded patients: with a fracture of the distal or proximal third of the scaphoid, associated perilunate injuries, age below 16 or above 65 years, and patients with a delay from injury to treatment of more than 14 days. However, we allowed inclusion of patients with concomitant non-displaced distal radius, or carpal fracture that would not require

an immobilization period longer than the one necessary for treatment of the scaphoid fracture. The randomized subgroup of patients with non-, or minimal displaced scaphoid waist fracture, had been followed with CT scans at 10 and 14 weeks, and 6 and 12 months.

Imaging protocol

Conventional Radiographs (AXIOM Aristos FX; Siemens AG, Forchheim, Germany) of the wrist, posteroanterior and lateral projections, were obtained together with four views of the scaphoid (posteroanterior with ulnar deviation, with the central beam angled 10° cranially, 10° caudally, 20° ulnarly. and 20° radially). Computed tomography (Somatom Sensation 16; Siemens AG, Forchheim, Germany) was performed with the patient positioned prone on the CT table, with the arm above the head, the forearm in pronation, and the wrist in neutral flexion and neutral radial-ulnar deviation. Scout images were taken to ensure correct scanning plane. Axial sections of 0.6 mm thick slices were obtained, allowing 1 or 2 mm thick reconstructions in the coronal and sagittal planes, defined by the long axis of the scaphoid.

The same senior musculoskeletal radiologist (JB), together with one of the senior authors (NT), did a consensus evaluation of the radiographic examinations. Fracture gap and translation (step-off) were assessed on the coronal and sagittal images of the initial CT scan (► **Fig.2**). The maximum value measured was used to categorize the fracture as: minimal displaced ($\leq 0.5\text{mm}$), moderate (1mm), or severely displaced ($\geq 1.5\text{mm}$).⁵ The percentage of bone contact over the fracture cross-section at follow-up was graded as 0 to 24%, 25 to 49%, 50 to 74%, 75 to 99% or 100%.¹⁷ The grading was estimated by using average measurements from four sagittal, and coronal cuts. Ultimately, it was assessed whether the fracture had united, and defined

as, not just bone contact, but as a continuous trabecular pattern over more than 50% of the cross-section of the fracture.^{5, 14} Our reference standard to confirm fracture union, was based on an additional CT-scan obtained at least 6 months after treatment.¹⁸

Treatment regime

Conservative treatment consisted of immobilization in a standard below-elbow plaster cast, incorporating the thumb up to the interphalangeal joint.

Using a 2.7 mm arthroscope, standard radiocarpal and midcarpal arthroscopy was performed with the hand in a vertical traction tower. We applied 3 to 5 kg of traction. As needed, blood, debris and synovitis were removed with a shaver. To allow placement of a guide-wire in the central axis of the scaphoid, the wrist was flexed and kept in slight ulnar deviation. Fracture reduction was obtained with a small periosteal elevator inserted through the radial mid-carpal portal, or by using K-wires as joysticks to manipulate the proximal and distal fragments. For this purpose an additional scaphotrapeziotrapezoid portal was created, if required. After fracture reduction a central guide wire was inserted in an antegrade fashion from the proximal to the distal pole. Osteosynthesis was performed with a headless compression screw (HBS 3.0mm, KLS Martin Group, Mühlheim Germany or TwinFix 3.2mm, Stryker, Kalamazoo, MI USA). Fracture reduction and position of the compression screw, was confirmed by mid-carpal arthroscopy and fluoroscopy at multiple angles. Fracture stability was assessed during arthroscopy by deviating the wrist in ulnar and radial direction, and by manipulating with a probe at the fracture site. When the fracture fixation was considered stable, the wrists of the patients in the randomized group were immobilized in a cast for two weeks, followed by wrist mobilization. Those who did belong to the randomized subgroup were immobilized until the treating surgeon

considered the fracture to be united. If fracture reduction or stability could not be achieved by the arthroscopic technique, we immediately converted to a standard, open volar approach followed by screw fixation, which was inserted in a retrograde fashion.

Study population

We identified 103 consecutive patients with 104 scaphoid waist fractures (► Fig. 1). Thirteen patients were excluded because of inadequate CT scan follow-up, 19 due to age criterion, two because of a delay in treatment of more than 14 days, and five who had K-wire fixation due to a complete (i.e Geissler grade IV) scapho-lunate ligament disruption, found in association with the scaphoid fracture. This left 65 scaphoid fractures in 64 patients included in the study. Thirty-nine fractures (34 males and 5 females, median age of 28, range 17 to 62 years) were treated conservatively in a plaster cast. Twenty-six fractures were treated operatively (22 males and 4 females, median age of 31, range 16 to 63 years). Out of the 65 fractures, 38 non-, or minimal displaced scaphoid waist fracture ($< 1\text{mm}$ displacement and/or $< 15^\circ$ volar angulation) had been randomized to cast immobilization or arthroscopically assisted screw fixation.

Twenty-seven non-, as well as displaced fractures, not being part of a randomized protocol, were treated according to the clinical judgement of the surgeon, of which 3 cases with severe fracture displacement were converted from arthroscopic technique to open volar approach. The department protocol recommended operative treatment when fracture displacement was $> 1\text{mm}$.

Statistics

The presence of a linear trend between the degree of fracture dislocation and fracture union at 6 weeks was tested using the Linear-by-Linear association test. We evaluated differences in union of randomized non-, or minimal displaced scaphoid waist fracture with Fischer's exact test. Statistical analysis was performed using SPSS 20.0 for Windows (SPSS Inc., Chicago, IL, USA). $P < 0.05$ was considered statistically significant.

Results

Fracture characteristic are specified in ► **Table I** and **II**. Fracture comminution represented by a separate cortico- or cortico-spongyous fragment on the radial side of the scaphoid was common (54%), even for the non- or minimally displaced scaphoid fractures (34%)(► **Fig. 3**). Two cases of concomitant distal radius fracture were found in both treatment groups. In addition, the conservatively treated group included one wrist with concomitant capitate fracture, and one with a combined capitate and triquetrum fracture. The operated group included one wrist with a concomitant capitate fracture. With the exception of three, the associated fractures were only visible on MRI.

In the conservatively treated group (► **Table I**) twenty-four fractures were immobilized in a cast for 5 to 8 weeks, eleven for 10 to 12 weeks, and four from 13 to 16 weeks. The 6-week CT-scan demonstrated that 27/30 or 90 % of the non- or minimal displaced fractures had united (► **Fig. 4**). The number of patients with moderate or severe fracture displacement was too small to provide valid frequencies on fracture union. Therefore, a linear association between fracture displacement and fracture union could not be demonstrated ($P=0.47$). Of the five fractures with

uncertain union at 6 weeks, four were classified as healed after 10 weeks, and one after 14 weeks.

In the operatively treated group (► **Table II**) seventeen fractures were immobilized in plaster for two weeks, two for 3 to 4 weeks, five for 6 weeks and 2 for 10 weeks. In this group the union rate at 6 weeks for non- or minimal displaced fractures were 82% and dropping to 40% for the severely displaced fractures. However, the numbers in the moderate and severe displacement groups were too small to make conclusions with regards to any association between fracture displacement and fracture union ($P=0.06$). At 6 weeks, of the eight fractures with uncertain union, four were classified as united at 10 weeks, one at 6 months, two at 12 months, and one had developed into a non-union. All fractures with prolonged time to union (> 14 weeks) were primarily classified as severely displaced.

In the randomized subgroup of patients (► **Table III**) with non-, or minimally displaced scaphoid waist fracture, 23 were treated with cast immobilization, and 15 underwent arthroscopically assisted screw fixation. Eleven of the conservatively treated fractures were immobilized in a cast for 6 to 8 weeks, nine for 10 to 12 weeks, and three for 13 to 16 weeks. After 6 weeks 83% of these fractures were united, 96% after 10 weeks, and 100% at 14 weeks. All four fractures that united later than 6 weeks were comminuted. In the operated group, 11 were immobilized in a cast for two weeks, three for 6 weeks, and 1 for 10 weeks. After 6 weeks 80% had united, increasing to 94% after 10 weeks. One fracture did not unite until one year after surgery. We were not able to demonstrate any significant difference in union rate between the two treatment groups at any measure point ($P=1.00$).

Discussion

In this study, we focus on how a detailed radiographic assessment of fracture union, using CT scan in the longitudinal axis of the scaphoid could help shortening the period of cast immobilization. Furthermore, we had the possibility to compare time to union between screw fixation, and cast immobilization of non- or minimally displaced scaphoid waist fractures. We found that 90% of non- or minimally displaced scaphoid waist fractures were sufficiently treated with 6 weeks of immobilization in a cast. In a randomized subgroup of the non-displaced scaphoid fractures, we were not able to demonstrate any difference in time to union between those who were treated conservatively in a cast, and those who underwent screw fixation. Finally, we observed that the presence of fracture comminution might be associated with prolonged time to fracture union.

Generally, a scaphoid waist fracture with a displacement $> 1\text{ mm}$ has been considered unstable and thereby a candidate for internal fixation.¹⁶ We found that fractures with a displacement $< 1.5\text{ mm}$ healed uneventfully, within 6 to 10 weeks of conservative treatment. In a recent study, scaphoid waist fractures with dorsal or volar gapping of $\leq 2\text{ mm}$ all united after conservative treatment, and approximately 40% of those with $\geq 3\text{ mm}$ of gapping united. The authors advocated $\geq 3\text{ mm}$ of gapping as an indication for internal fixation.¹⁵ The apparent differences in recommendation for treatment based on fracture displacement may illustrate that CT scans cannot be relied on to determine whether a displaced or non-displaced fracture is actually unstable.¹⁹ Further knowledge on the association between radiologic fracture displacement, biomechanical instability and development of non-union are needed.

A large number of non- or minimally displaced fractures demonstrated comminution in terms of a radial sided cortico or cortico-spongyous fragment.

Previously, a strong correlation was demonstrated between scaphoid fracture comminution and arthroscopically verified fracture instability.²⁰ While this association seems comprehensible for displaced scaphoid fractures, the importance for non-displaced fractures are undetermined. Even though instability has been demonstrated by arthroscopy of radiographical non-displaced fractures, our results suggest that the clinical importance is relatively minor, though a somewhat longer time to union could be expected (10 weeks). A larger scale study is needed to determine the influence of fracture comminution on healing of non-, or minimally displaced scaphoid waist fractures.

In randomized trials on treatment of non- or minimally displaced scaphoid fractures, time to union varied considerably.^{1, 3, 7} Fractures treated with internal fixation were reported to unite faster, with a mean value of 6 and 9 weeks, compared to those who were treated conservatively, from 10 to 14 weeks.^{1, 3, 7} However, these results are based on evaluation of radiographs, which have been proven less accurate than CT scans for assessment of scaphoid fracture union.^{9, 10} Firstly, the general definition of union is debatable. Secondly, it is difficult to obtain good quality radiographs in the same plane as the fracture line. Finally, various patterns of partial union may obscure interpretation.^{17, 18} Even when using CT scans, interpretation of fracture union can be a challenge. In non-displaced fractures, bone contact over the fracture site will be substantial, which does not necessarily mean that there is trabecular bridging. Also, if anatomic reduction and good compression is achieved after screw fixation the fracture will look as united straightaway.

The period of immobilization is not comparable between our patient groups. During the treatment period, this discrepancy displays the traditional cautiousness of the treating surgeon in order to avoid non-union and its complications. In the current

study, it reflects that results from the detailed CT evaluation were not available at the time of treatment. Nevertheless, our results suggest that the majority of non-, or minimally displaced scaphoid waist fractures, unite after six weeks of conservative treatment in a cast. Furthermore, two weeks of immobilization seems sufficient after stable screw fixation. A general recommendation on conservative management versus operative treatment, requires data on long-term functional and radiological outcome.

A strategy of aggressive conservative management of non-, or minimally displaced scaphoid waist fractures recommends operative treatment, if CT scan at 6 weeks demonstrates uncertain union.⁸ We found that fractures, which had not united at 6 weeks, eventually united within 14 weeks of cast immobilization. The aggressive management strategy could therefore lead to unnecessary surgical intervention. For those with uncertain union, we advocate to postpone a decision to operate until after a CT scan at 14 weeks. We acknowledge, that a repeated CT scan will result in an increased radiation load for the patient. However, as long as it is done with the injured wrist kept above the head, the effective radiation dose is as low as 0.03mSv, which is equivalent to one week of background radiation.²¹

Our study encompasses a consecutive series of patients with scaphoid waist fracture. However, there are several limitations. One weakness is the small sample size, which hamper our ability to compare time to union between fractures with different categories of displacement. Our reference standard for union is incomplete as seven of the patients did not attend a 6 or 12 month CT scan. In our region (Southern part of Sweden) treatment of scaphoid non-union are centralized at our department, why patients with prolonged symptoms, or who later on develops a non-union, are most likely to be referred back to us. Either way, we looked through the regional radiology database, and did not find any sign of non-union among those who

later on, for some reason, had had a radiographic examination of the hand in question. We did not test the inter-observer reproducibility of the diagnosis of fracture union on the CT scans. Instead, resembling clinical practice, we did a consensus reading by the radiologist, and one of the surgeons. However, it is reassuring that a substantial agreement has been demonstrated, among multiple observers who evaluated scaphoid union on CT scans.²²

With these limitations in mind, the clinical implication of our results is that we now treat non-, or minimally displaced scaphoid waist fractures with 6 weeks of immobilization in a cast. In cases of uncertain union, a decision to recommend surgical intervention awaits a repeated CT scan at 14 weeks.

References

1. Bond CD, Shin AY, McBride MT, Dao KD. Percutaneous screw fixation or cast immobilization for nondisplaced scaphoid fractures. *J Bone Joint Surg Am.* 2001;83-A:483-488.
2. Adolfsson L, Lindau T, Arner M. Acutrak screw fixation versus cast immobilisation for undisplaced scaphoid waist fractures. *J Hand Surg Br.* 2001;26:192-195.
3. McQueen MM, Gelbke MK, Wakefield A, Will EM, Gaebler C. Percutaneous screw fixation versus conservative treatment for fractures of the waist of the scaphoid: a prospective randomised study. *J Bone Joint Surg Br.* 2008;90:66-71.
4. Clay NR, Dias JJ, Costigan PS, Gregg PJ, Barton NJ. Need the thumb be immobilised in scaphoid fractures? A randomised prospective trial. *J Bone Joint Surg Br.* 1991;73:828-832.
5. Bhat M, McCarthy M, Davis TR, Oni JA, Dawson S. MRI and plain radiography in the assessment of displaced fractures of the waist of the carpal scaphoid. *J Bone Joint Surg Br.* 2004;86:705-713.
6. Ram AN, Chung KC. Evidence-based management of acute nondisplaced scaphoid waist fractures. *J Hand Surg Am.* 2009;34:735-738.
7. Arora R, Gschwentner M, Krappinger D, et al. Fixation of nondisplaced scaphoid fractures: making treatment cost effective. Prospective controlled trial. *Arch Orthop Trauma Surg.* 2007;127:39-46.
8. Ibrahim T, Qureshi A, Sutton AJ, Dias JJ. Surgical versus nonsurgical treatment of acute minimally displaced and undisplaced scaphoid waist fractures: pairwise

- and network meta-analyses of randomized controlled trials. *J Hand Surg Am.* 2011;36:1759-1768 e1751.
9. Dias JJ, Taylor M, Thompson J, Brenkel IJ, Gregg PJ. Radiographic signs of union of scaphoid fractures. An analysis of inter-observer agreement and reproducibility. *J Bone Joint Surg Br.* 1988;70:299-301.
 10. Grewal R, Suh N, Macdermid JC. Use of computed tomography to predict union and time to union in acute scaphoid fractures treated nonoperatively. *J Hand Surg Am.* 2013;38:872-877.
 11. Slade JF, 3rd, Gillon T. Retrospective review of 234 scaphoid fractures and nonunions treated with arthroscopy for union and complications. *Scandinavian journal of surgery.* 2008;97:280-289.
 12. Slutsky DJ, Trevare J. Use of arthroscopy for the treatment of scaphoid fractures. *Hand Clin.* 2014;30:91-103.
 13. Jorgsholm P, Thomsen NO, Besjakov J, Abrahamsson SO, Bjorkman A. The benefit of magnetic resonance imaging for patients with posttraumatic radial wrist tenderness. *J Hand Surg Am.* 2013;38:29-33.
 14. Geoghegan JM, Woodruff MJ, Bhatia R, et al. Undisplaced scaphoid waist fractures: is 4 weeks' immobilisation in a below-elbow cast sufficient if a week 4 CT scan suggests fracture union? *J Hand Surg Eur Vol.* 2009;34:631-637.
 15. Amirfeyz R, Bebbington A, Downing ND, Oni JA, Davis TR. Displaced scaphoid waist fractures: the use of a week 4 CT scan to predict the likelihood of union with nonoperative treatment. *J Hand Surg Eur Vol.* 2011;36:498-502.
 16. Cooney WP, Dobyns JH, Linscheid RL. Fractures of the scaphoid: a rational approach to management. *Clin Orthop Relat Res.* 1980;90:90-97.

17. Singh HP, Forward D, Davis TR, et al. Partial union of acute scaphoid fractures. *J Hand Surg Br.* 2005;30:440-445.
18. Dias JJ. Definition of union after acute fracture and surgery for fracture nonunion of the scaphoid. *J Hand Surg Br.* 2001;26:321-325.
19. Buijze GA, Jorgsholm P, Thomsen NO, et al. Diagnostic performance of radiographs and computed tomography for displacement and instability of acute scaphoid waist fractures. *J Bone Joint Surg Am.* 2012;94:1967-1974.
20. Buijze GA, Jorgsholm P, Thomsen NO, et al. Factors associated with arthroscopically determined scaphoid fracture displacement and instability. *J Hand Surg Am.* 2012;37:1405-1410.
21. Biswas D, Bible JE, Bohan M, et al. Radiation exposure from musculoskeletal computerized tomographic scans. *J Bone Joint Surg Am.* 2009;91:1882-1889.
22. Buijze GA, Wijffels MM, Guitton TG, et al. Interobserver reliability of computed tomography to diagnose scaphoid waist fracture union. *J Hand Surg Am.* 2012;37:250-254.

Fig. 1: Flow chart of included fractures.

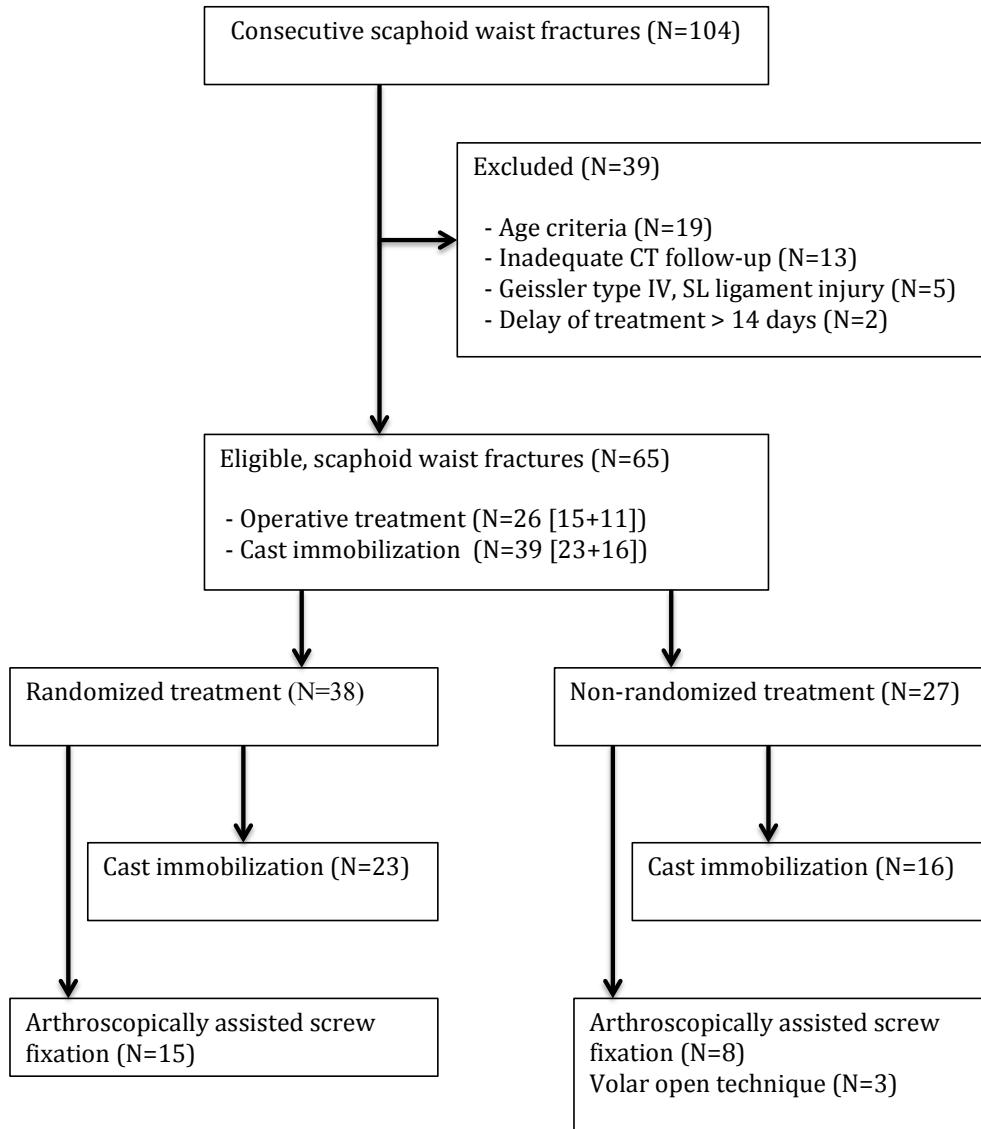


Fig. 2: Sagittal CT scan of a displaced scaphoid waist fracture demonstrating fracture gap and translation (step-off).

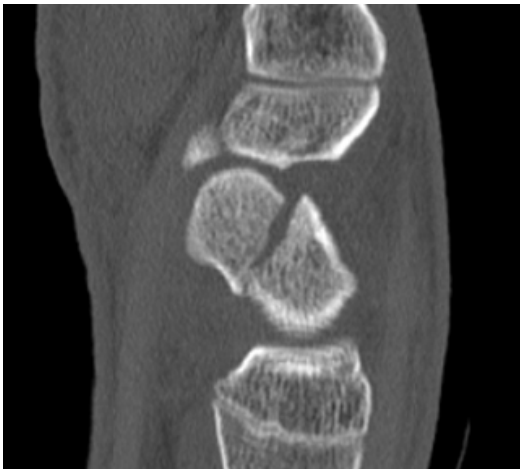

Fig. 3: CT scan of a non-displaced scaphoid waist fracture with a comminuted radial fragment.

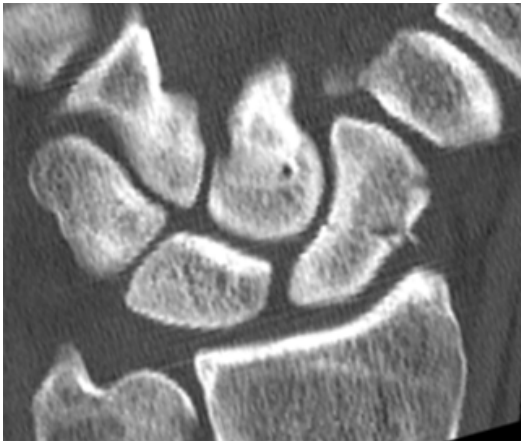


Fig. 4: CT scan of a non-displaced scaphoid waist fracture (A), which at 6 weeks had united throughout the cross section of the fracture (B).

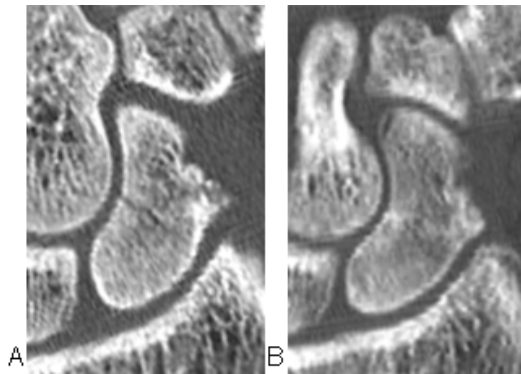


Table I. CT investigation on 39 conservatively treated scaphoid waist fractures

	Non or minimal displacement (N=30)	Moderate displacement (N=6)	Severe displacement (N=3)
Fracture characteristics			
Transverse	23	5	1
Oblique	7	1	2
Comminuted	11	4	3
Bone contact (6wk)			
100%	18	3	0
75 – 99%	11	2	2
50 – 74%	0	0	0
25 – 49%	1	1	0
0 – 24%	0	0	1
Overall assessment of fracture union (6wk)			
Union	27	5	2
Uncertain union	3	1	1

Table II. CT investigation on 26 operatively treated scaphoid waist fractures

	Non or minimal displacement (N = 11)	Moderate displacement (N = 5)	Severe displacement (N = 10)
Fracture characteristics			
Transverse	10	3	6
Oblique	1	2	4
Comminuted	3	5	9
Bone contact (6wk)			
100%	10	2	1
75 – 99%	1	3	5
50 – 74%	0	0	1
25 – 49%	0	0	0
0 – 24%	0	0	3
Overall assessment of fracture union (6wk)			
Union	9	5	4
Uncertain union	2	0	6

Table III. CT investigation of union on a randomized sub-group of non-, or minimally displaced scaphoid waist fractures

	6 wks	10 wks	14 wks	6 mo	12 mo
Cast immobilization (N=23)					
Union	19	22	23	23	23
Uncertain union	4	1	0	0	0
Internal fixation (N=15)					
Union	12	14	14	14	15
Uncertain union	3	1	1	1	0

