



# LUND UNIVERSITY

## Pharmacological manipulation of fracture healing and bone remodeling

Harding, Anna Kajsa

2010

[Link to publication](#)

*Citation for published version (APA):*

Harding, A. K. (2010). *Pharmacological manipulation of fracture healing and bone remodeling*. [Doctoral Thesis (compilation), Orthopaedics (Lund)]. Department of Orthopaedics, Lund University.

*Total number of authors:*

1

### General rights

Unless other specific re-use rights are stated the following general rights apply:

Copyright and moral rights for the publications made accessible in the public portal are retained by the authors and/or other copyright owners and it is a condition of accessing publications that users recognise and abide by the legal requirements associated with these rights.

- Users may download and print one copy of any publication from the public portal for the purpose of private study or research.
- You may not further distribute the material or use it for any profit-making activity or commercial gain
- You may freely distribute the URL identifying the publication in the public portal

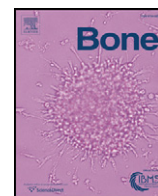
Read more about Creative commons licenses: <https://creativecommons.org/licenses/>

### Take down policy

If you believe that this document breaches copyright please contact us providing details, and we will remove access to the work immediately and investigate your claim.

LUND UNIVERSITY

PO Box 117  
221 00 Lund  
+46 46-222 00 00



# A single dose zoledronic acid enhances pin fixation in high tibial osteotomy using the hemicallotaxis technique. A double-blind placebo controlled randomized study in 46 patients

Anna Kajsa Harding <sup>a,\*</sup>, Sören Toksvig-Larsen <sup>b</sup>, Magnus Tägil <sup>a</sup>, Annette W-Dahl <sup>a</sup>

<sup>a</sup> Department of Orthopedics, Clinical Sciences Lund University and Lund University Hospital, SE-221 85 Lund, Sweden

<sup>b</sup> Department of Orthopedics, Hässeholm Hospital, Hässeholm, Sweden

## ARTICLE INFO

### Article history:

Received 21 September 2009

Revised 30 October 2009

Accepted 30 October 2009

Available online 11 November 2009

Edited by: T. Einhorn

### Keywords:

Pin fixation

Zoledronic acid

External fixator

Tibial osteotomy

Osteoarthritis

## ABSTRACT

**Introduction:** Bisphosphonates have been shown to reduce osteoclastic activity and enhance pin fixation in both experimental and clinical studies. In this prospective, randomized study of high tibial osteotomy using the hemicallotaxis (HCO) technique, we evaluate whether treatment by one single infusion of zoledronic acid can enhance the pin fixation.

**Materials and methods:** 46 consecutive patients (35–65 years) were operated on for knee osteoarthritis by the HCO technique. After the osteotomy, two hydroxyapatite-coated pins were inserted in the metaphyseal bone and two non-coated pins in the diaphyseal bone. The insertion torque was measured by a torque force screw driver. Four weeks postoperatively, the patients were randomized to either one infusion of zoledronic acid or sodium chloride intravenously. At time for removal of the pins, the extraction torque forces of the pins were measured.

**Results:** All osteotomies healed and no difference was found in time to healing. The mean extraction torque force in the non-coated pins in the diaphyseal bone was doubled in the zoledronic treated group (4.5 Nm, SD 2.1) compared to the placebo group (2.4 (SD 1.0,  $p < 0.0001$ ). The mean extraction torque forces of the hydroxyapatite-coated pins in the metaphyseal bone were similar in the zoledronic acid group (4.7 Nm, SD 1.3) and in the placebo group (4.0 Nm, SD 1.3).

**Discussion:** A single infusion of zoledronic acid improved twofold the fixation of non-coated pins in diaphyseal bone. Bisphosphonates might be an alternative to hydroxyapatite-coated pins in nonosteoporotic bone.

© 2009 Elsevier Inc. All rights reserved.

## Introduction

A stable pin fixation is a prerequisite during treatment by external fixation to minimize the risk of complications such as pin loosening, delayed healing, non-union and pin site infection [1]. Various pin and screw designs have been compared to optimize the thread and tip design in order to enhance the fixation [2–4]. In several, both animal and clinical studies, improved fixation and reduced rates of pin site infection have been described with the use of hydroxyapatite (HA)-coated pins in both cancellous and cortical bone [1,5–7]. A novel approach to influence the bone–pin interface is to delay the bone resorption around the pins and maybe prevent early loosening by systemic administration of a bisphosphonate [8–12].

Bisphosphonates have been shown to reduce the osteoclastic catabolic activity in experimental studies, not only in osteoporosis but also in other orthopaedic indications, such as osteonecrosis [13,14],

fracture healing [15,16] and prosthetic fixation [17,18]. Bisphosphonates bind to the bone mineral and when the bone is resorbed by the osteoclasts, bisphosphonates are released and internalized by the osteoclast. This leads to apoptosis of the osteoclast by interference with the cell metabolism [19] and resorption is delayed. By reducing the resorption of the bone surrounding an implant, theoretically an increased fixation can be achieved. Bisphosphonate treatment of the bone adjacent to a screw has been shown mechanically effective in pull-out tests of screws experimentally. Both by local and systemical treatment, an enhanced extraction torque was found by 56% and for pull-out strength between 15–30% [8]. Also for HA-coated [20] or porous implants [21] the osseointegration was accelerated by administration of bisphosphonates.

The first randomized clinical study in humans showed that weekly administration of alendronate improved pin fixation in cancellous bone but not in cortical bone in osteoporotic elderly female hip fracture patients treated with external fixation [10]. In the present study, which was designed primarily to decrease the time to fracture healing by delaying the resorption of the forming callus, a delayed distribution of the bisphosphonate was chosen, which has been

\* Corresponding author.

E-mail address: [anna\\_kajsa.harding@med.lu.se](mailto:anna_kajsa.harding@med.lu.se) (A.K. Harding).

shown to be more effective in fracture healing in animal studies [22]. For pin fixation, an immediate or even pre-treatment would have been theoretically better.

High tibial osteotomy by the hemicallotasis technique (HCO) is a treatment option for younger and/or physically active patients with unicompartmental knee osteoarthritis or knee deformities. HCO is an open wedge technique, based on an external fixation, and both HA-coated and -uncoated pins are used [23]. The angle deformity is successively corrected postoperatively under radiographic control. The advantages of the HCO include an easy surgical technique and improved possibility to achieve the planned correction. HCO is also a procedure with high demands on pin fixation, due to early weight bearing combined with forces necessary for the angular correction. All this makes the HCO an appropriate and repeatable clinical model for studying bone and fracture healing including pin fixation, and to investigate the effect of a bisphosphonate.

During a pilot-study of bisphosphonate treatment on bone healing in patients operated on by the HCO [24], it was noted that the extraction torque of the non-coated pins in the diaphyseal bone was higher in those treated with bisphosphonate compared to non-treated patients. In the present full size randomized study, with fracture healing as primary outcome, our secondary aim was to evaluate if treatment by a single infusion of 4 mg zoledronic acid intravenously affected the pin fixation during the HCO.

## Materials and methods

Between February 2006 and May 2007, 46 consecutive patients (10 women and 36 men) with a median age of 50 years (range 37–63) (Table 1) were operated on by HCO. Patients between 35 and 65 years with osteoarthritis or deformities of the knee were included and exclusion criteria were kidney, liver or odontological disorders, rheumatoid arthritis or bisphosphonate treatment during the 2-year period prior to the operation. Preoperatively, the patients were given both written and verbal study information and an informed consent was obtained. The study was approved by the local ethics committee at Lund University as well as the Swedish Medical Product Agency and the study was externally monitored. The study was registered at the European Community data base EudraCT with the number 2005-002985-12. All patients that met the inclusion criteria were prescribed daily oral calcium and vitamin-D3 the first 6 weeks postoperatively to avoid hypocalcaemia if given the active drug. The flow of the participants through each stage of the trial is outlined in a flow diagram (Fig. 1).

## Surgery and randomization

The HCO was performed as an out-patient procedure using the Orthofix® T-garche as external fixator (Fig. 2). The two proximal holes in the metaphyseal bone were made with a 3.2-mm drill and the distal holes in cortical bone with a 4.8-mm drill. Four conical stainless steel pins were inserted (6/5-mm diameter), whereof two

hydroxyapatite (HA)-coated (Orthofix® Bussolengo, Italy) in the metaphyseal bone and two un-coated pins in the diaphyseal bone (Orthofix®). The HA coating was applied by plasma spraying, with an HA-layer thickness of 45–70 µm [23]. The pins must penetrate the posterior cortex with 2–3 threads for best fixation, which was controlled in fluoroscopy. A 5-cm longitudinal skin incision was done ventral to the tibial tuberosity. The osteotomy was done at the level of the distal third of the tibial tuberosity. The osteotomy was tested and judged to be sufficient if the gap could easily be opened 4–5 mm. For valgus deformity, the surgical procedure was identical except that a fibulotomy was performed 10–15 cm below the head of the fibula [23]. The patients were allowed free mobilization and full weight bearing after the operation. No prophylactic antibiotic was used. Pin site care was carried out once a week using chlorhexidine moistened gauzes as dressings in the orthopaedic outpatient clinic. In case of pin site infections oral antibiotic treatment (flucloxacillin 1 g×3) was given for 7 days.

At 4 weeks postoperatively, inclusion and exclusion criteria were re-evaluated and randomization was performed by one of the authors (AWD) using closed envelopes. The patient received either an infusion of zoledronic acid 4 mg (Zometa®, Novartis Pharma GmbH, Basel, Switzerland) or sodium chloride 9 mg/ml prepared by the unblinded nurse. The infusion of zoledronic acid was prepared by diluting 4 mg zoledronic acid in 100 ml sodium chloride 9 mg/ml and was given as a 15-min intravenous infusion. If a patient had signs of hypocalcaemia at the follow up, the serum calcium was measured.

## Outcome

Both the insertion and extraction torque forces (Nm) of the pins were measured using a torque force screwdriver (range 0–1100 Ncm; Orthofix® SRL, Italy). The torque screw pin driver was set to zero before starting. One torque force screwdriver was available at the operating theatre and another in the outpatient clinic. The pins were inserted by the surgeon in a slow clockwise turn. The torque was measured during the whole insertion procedure and the peak torque was registered as the pin engaged the second cortex. The extraction was done in a slow counter clockwise turn and the maximum peak torque recorded immediately as the screw loosened. The decision to remove the fixator was made by the treating surgeon (STL), who was blinded to the type of infusion given at 4 weeks and to any side effects of the drugs experienced by the patient. The decision was based on a combination of radiological and ultrasound examination of the osteotomy healing and a weight-bearing test—i.e. walking, for a couple of hours to days, without the fixator but with the pins still in situ [25]. If the patient reported symptoms of incomplete healing, mainly pain by loading, the fixator was reapplied for additional 2 weeks. This procedure was repeated every second week until the osteotomy healing was clinically satisfying. The pins were removed in the out-patient clinic.

The pin performance index (PPI) was used as primary outcome and was calculated from the insertion and extraction torque. PPI is the ratio of extraction to insertion torque and expressed as percentage [26]. An equal insertion and extraction torque would result in a PPI of 100%. The PPI gives the information of how the fixation proceeds over time. The need (number of patients) and use (days/treated patient) of antibiotics were used as outcomes of pin site infection. All drug-related side-effects and adverse events were registered prospectively during the study. Complications such as delayed healing (by definition >16 weeks in external fixation [25]), non-union, septic arthritis, deep venous thrombosis, loss of correction and others (including replacement of pins and difficulties of correction) were recorded. At 10 weeks postoperatively dual energy X-ray absorptiometry (DEXA) of the operated lower leg and bilateral proximal femur was performed. The total T-score of the

**Table 1**  
Patient characteristics.

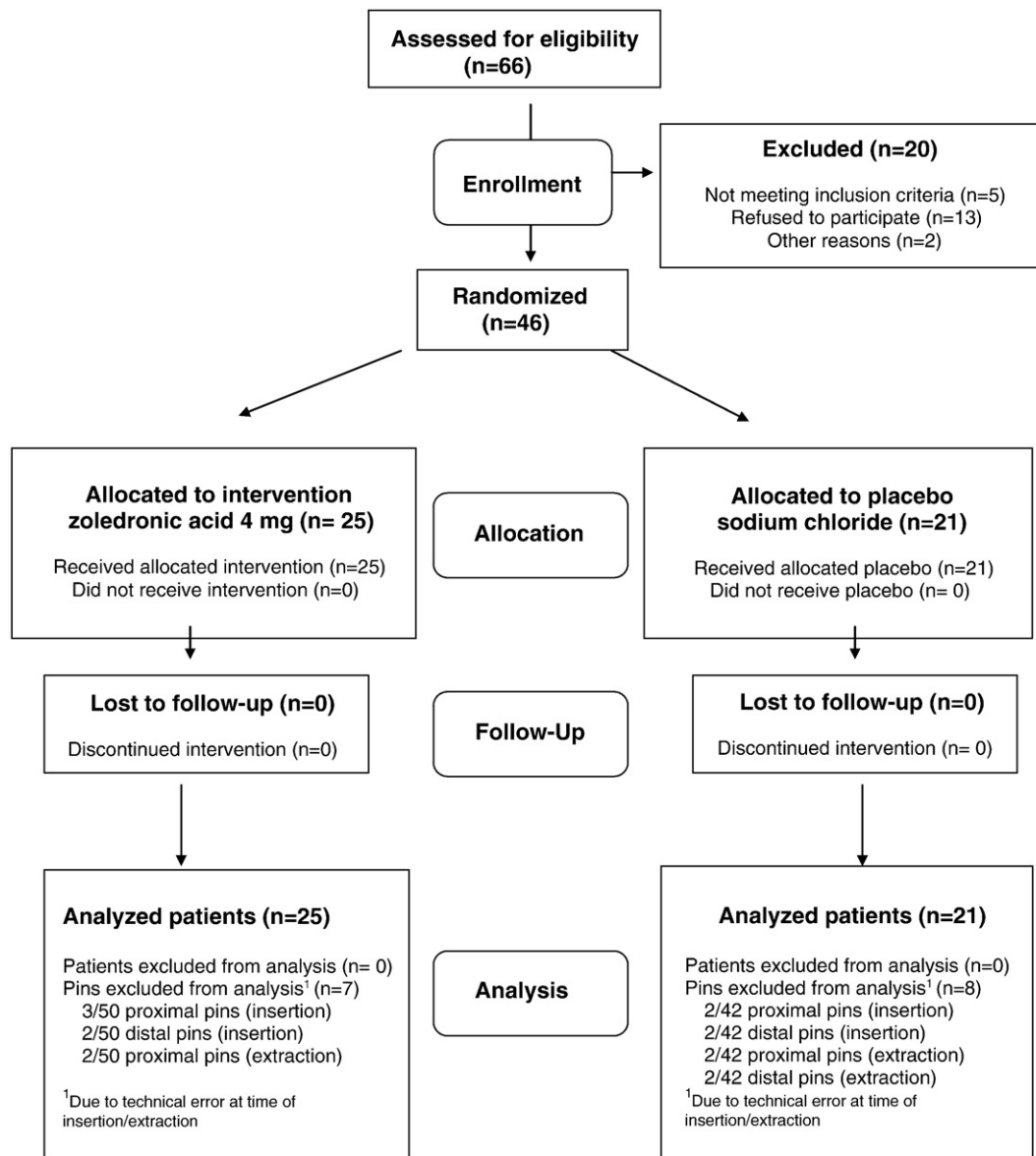
	Zoledronate, n = 25	Control, n = 21
Men/women	19:6	17:4
Age (years) <sup>a</sup>	49 (37–63)	50 (42–61)
Pre-HKA(degrees) <sup>b</sup>	173 ± 6	173 ± 5
BMI (kg/m <sup>2</sup> ) <sup>b</sup>	28 ± 3	26 ± 3
Smoker	4	7
Smokeless tobacco user	4	6

HKA = Hip-knee-ankle angle (<180 degrees = varus).

BMI = Body Mass Index.

<sup>a</sup> The value given as median and range.

<sup>b</sup> The value given as the mean and the standard deviation.



**Fig. 1.** A Consolidated Standards of Reporting Trials (CONSORT) flow diagram depicting patient recruitment, randomization, patient flow, and follow-up in the study.

proximal femur was used to evaluate if the patients had osteoporosis, osteopenia or normal bone.

### Statistical methods

A power analysis was performed based on the data from the pilot study as well as previous pin design studies. 25 samples were needed in each group to obtain a power of 85% at  $p = 0.05$  in a two-sided test, with an estimated mean difference of insertion and extraction torque force of 1.00 Nm (SD 1.5) between the bisphosphonate and control group. For each patient the mean value of the two proximal pins and the mean value of the two distal pins were calculated and used for the statistical analysis. For bilateral procedures, the index operation was used for statistical analysis.

All data were expressed as the mean and standard deviation of the mean. For Pin Performance Index (PPI), the mean difference and 95% CI of the difference was calculated. Independent samples  $t$  test was performed to test the differences between the groups.  $p < 0.05$  was considered statistically significant. Statistical analysis was carried out with the Statistical Package for the Social Sciences (SPSS) Software (version 16.0; SPSS, Chicago, Illinois).

### Source of funding

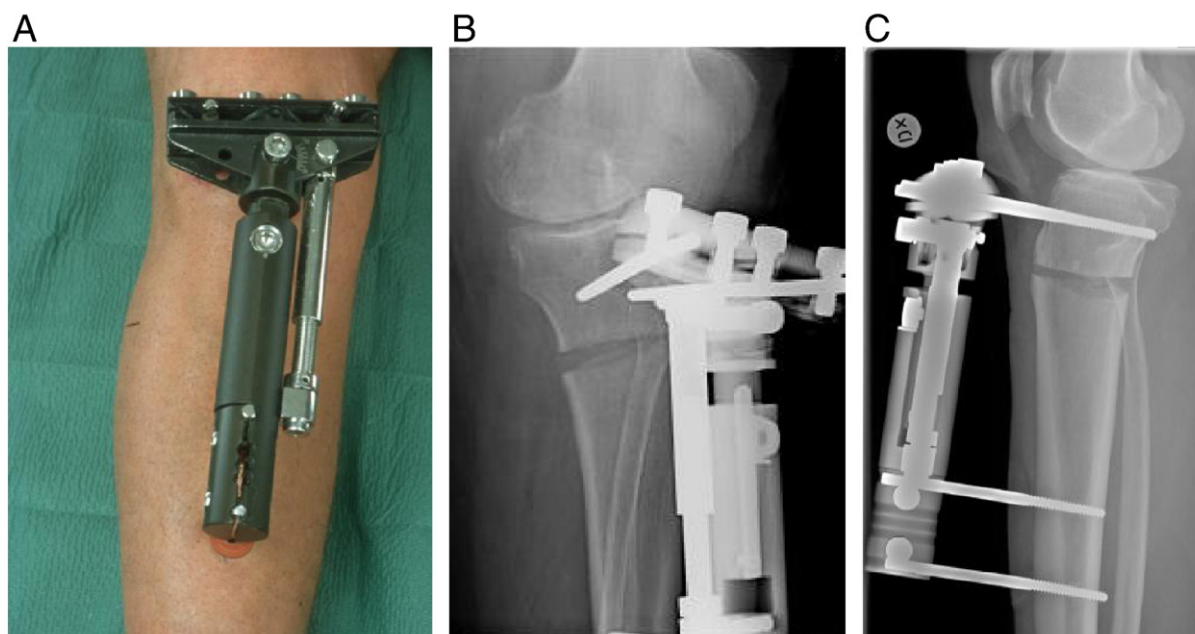
Funding was received from hospital and government research funds. The study was carried out independently from manufacturers of used pharmaceuticals and devices.

### Results

In both groups all osteotomies healed and there was no delayed healing or non union in either of the groups. The healing time was 77 (SD 7) days in the zoledronic group and 77 (SD 7) days in the placebo group (NS). No patients had signs of hypocalcemia. None of the patients had osteoporosis but three patients in the zoledronic treated group had osteopenia and six in the control group. Six patients underwent bilateral procedures, four were in the zoledronate group and two in the placebo group.

### HA-coated pins

In the proximal HA-coated pins in the metaphyseal bone, zoledronic acid did not significantly increase the PPI (Table 2). The



**Fig. 2.** Hemicallotasis osteotomy using the Orthofix® T-garche as external fixator (A). Antero-posterior (B) and lateral (C) radiographs.

insertion torque force for the HA-coated proximal pins in metaphyseal bone was 2.0 Nm (SD 0.6) for the zoledronic group and 1.5 Nm (SD 0.6) for the placebo groups ( $p = 0.02$ ). The extraction torque force was 4.7 Nm (SD 1.3) in the zoledronic group and 4.0 Nm (SD 1.3) in the placebo group ( $p = 0.12$ ) and the ratio expressed as PPI for the proximal HA-coated pins was 257% (SD 106) in the zoledronic group and 289% (SD 115) in the placebo group, mean difference -27 (95%CI 101 to 37,  $p = 0.4$ ). 9 proximal pins in 5 patients were excluded (5 in the zoledronic group and 4 in the control group) due to missed measurement at time for insertion and/or extraction. In two patients (one in the zoledronic group, one in the control group) the insertion torque force of both pins was not measured and in two patients (one in the zoledronic group, one in the control group) the extraction torque force of both pins was not measured. We did not exclude these patients in the calculation of the insertion and extraction torque forces respectively but it was not possible to calculate PPI. In one patient (zoledronic group) the insertion torque force of the medial pin was not measured. For this patient the PPI was calculated using the measurement of the lateral pin.

#### Standard pins

In the standard distal pins in the diaphyseal bone there was a difference between the bisphosphonate treated group and the controls (Table 2). The insertion torque force for the distal standard

pins in the diaphyseal bone was 7.0 Nm (SD 2.0) for the zoledronic acid group and 7.0 Nm (SD 1.7) for the placebo group ( $p = 0.9$ ). The extraction torque force was higher in the zoledronic acid group 4.5 Nm (SD 2.1) than in the control group 2.4 Nm (SD 1.0) ( $p < 0.0001$ ) and the corresponding PPI for the standard pins in the diaphyseal bone was 62% (SD 22.9) in the zoledronic group compared to the 35% (SD 14.3) in the placebo group, mean difference 27 (95%CI 15 to 39,  $p < 0.0001$ ). 6 distal pins in 3 patients were excluded (2 in the zoledronic group and 4 in the control group) due to missed measurement at time of insertion and/or extraction. In two patients (one in the zoledronic group, one in the control group) the insertion torque force of both pins was not measured and in one patient (control group) the extraction torque force of both pins was not measured. We did not exclude these patients in the calculation of insertion and extraction torque force respectively, but it was not possible to calculate PPI.

#### Pin site infection and complications

There was no difference in pin site infections between the two groups evaluated as the need and use of antibiotics. 5/25 patients in the zoledronic group had antibiotic treatment during the time in external fixation compared to 7/21 in the placebo group RR 0.6 (95% CI 0.23 to 1.57,  $p = 0.33$ ). The use of antibiotics per treated patient was 8 (SD 3) days in the zoledronic group and 11 (SD 5.5) days in the placebo group ( $p = 0.4$ ). No differences were found regarding complications between the groups. One DVT was observed in the control group. 13/25 patients reported muscle pain and flu symptoms in the zoledronic group compared to 2/21 in the placebo group (RR 5.04, 95% CI 1.3 to 20,  $p = 0.004$ ). One serious adverse event was registered in the zoledronic group in form of chest pain due to pneumonia.

#### Discussion

HA coating of pins for external fixation has been developed and proven effective to increase the fixation in both cancellous and cortical bone in HCO [1,5]. In some situations the HA-coating by itself seems to be of more importance than the pin design [7] but the effect differs greatly between cancellous and cortical bone. In lengthening

**Table 2**

Insertion/Extraction Torque and Pin Performance Index (PPI) in metaphyseal and diaphyseal bone.

	Zoledronate, $n = 25$	Control, $n = 21$	$p$ value
Metaphyseal bone			
Pin Insertion Torque (Nm)	$2.0 \pm 0.6$	$1.5 \pm 0.6$	0.02
Pin Extraction Torque (Nm)	$4.7 \pm 1.3$	$4.0 \pm 1.3$	NS <sup>a</sup>
PPI (%)	$257 \pm 106$	$289 \pm 115$	NS <sup>a</sup>
Diaphyseal bone			
Pin Insertion Torque (Nm)	$7.0 \pm 2.0$	$7.0 \pm 1.7$	NS <sup>a</sup>
Pin Extraction Torque (Nm)	$4.5 \pm 2.1$	$2.4 \pm 1.0$	$< 0.0001$
PPI (%)	$62 \pm 23$	$35 \pm 14$	$< 0.0001$

The values given as the mean and the standard deviation.

<sup>a</sup> NS = not significant.



procedures where the implantation time and the mechanical loads are substantial, the HA-coated pins were superior to uncoated pins with extraction torques being almost 90 times higher [27]. In our clinical model the pin fixation is satisfactory with HA-coated pins in the metaphyseal bone and standard pins in the diaphyseal. HA-coated pins in the diaphyseal bone can be too well fixed and thereby painful and difficult to remove in the out patient clinic [6]. However, in other situations, HA-coated pins may be necessary depending of the quality of the bone, the length of the treatment and the increased forces depending on the type of treatment. In these situations bisphosphonate treatment, whether systemically or locally applied, might be an alternative in the future but more studies have to be made to find the optimum dose, timing and mode of application.

High tibial osteotomy by HCO is a clinical fracture model where both HA-coated and standard pins are used and with high demands on pin fixation due to early weight bearing combined with large forces at the angular correction [5]. A high load is carried by the pins and the contact pressure at the interface between pin and bone might be high enough to induce resorption around the pin, especially during the hemicallotasis procedure/correction phase, and could lead to pin loosening.

The use of bisphosphonates in orthopaedic conditions other than osteoporosis and bone metastasis is limited but increasing and the drug has been used also to improve the fixation of orthopaedic pins. Bisphosphonates are effective in increasing the fixation measured as the extraction torque, both in animal models [8] as well as in human series [10]. Delaying the hypothetical resorption around the pins due to such pressure induced resorption, micro cracks [28] or thermal injury [29], bisphosphonate treatment appears attractive to improve pin fixation during fracture healing, especially since animal studies implicate a positive effect on fracture healing due to a better retention of the new formed callus [16].

In the present study, we could show an improved fixation, in patients operated on by the HCO and treated with a single dose of zoledronic acid, of the non-coated pins in the cortical diaphyseal bone distally but not of the HA-coated pins in the cancellous metaphyseal bone proximally. In a previous study using the same technique, uncoated proximal standard pins in cancellous bone all became loose in contrast to the HA-coated [5], which is why HA pins are used proximally in the clinical practice. In the same study, no such loosening was found in the diaphysis in either group, but the standard pins lost about 40% of their fixation during the fixation time, in contrast to the HA-coated pins, which increased the fixation/insertion torque. In the present study, only using standard pins distally in the cortical bone, an increase by 88% was found in the zoledronic acid group compared to the placebo, an effect similar to the HA coating found previously.

In a recently published, randomized study, bisphosphonates increased the fixation also in HA pins [10]. Hip fractures were fixed with two HA-coated pins in the femoral neck as well as two HA-coated pins in the femoral shaft. The patients were given weekly peroral alendronate for 3 months. An almost doubled extraction torque was found in the bisphosphonate-treated group in the cancellous but not in the cortical bone. Several explanations can be discussed to these diverging findings compared to our study. In the present study, the patients are osteoarthritic and younger (50 years, range 37–69) than the hip fracture patients (83 and 86 years  $\pm$  4–7) and thus the degree of osteoporosis substantially less. The pin fixation therefore might be better already at insertion and the insertion torques are higher in the present study of osteoarthritis patients than in the hip fracture patients. In hip fracture fixation, the pins in the femoral head are relying on cancellous bone fixation only, whereas in the knee each cancellous pin still has a bicortical grip. Further, in the present study, the bisphosphonate was given as a single injection intravenously after 4 weeks compared to weekly peroral distribution for 3 months starting the first week after surgery in the Moroni study. The effect of

the bisphosphonate would hypothetically be better if given initially, delaying the resorption of any bone necrosis in the pin holes caused by the surgical trauma. The rationale for single delayed injection in our study was based on animal experiments in regard to healing of the osteotomy. In fracture healing, a superior effect has been found with a delayed administration compared to administration immediately after the fracture. Bisphosphonates are taken up by the callus at the time of distribution and has greater effect on the strength with a delayed distribution as the callus has started to form [22]. Using a single dose and a delayed dosing also decreased the risk of interfering too early with the bone formation and fracture healing. However, if an increased pin fixation is the target, the bisphosphonate should be administered immediately to avoid the early resorption around the pins due to heat or mechanical necrosis.

Pin fixation is associated to pin site infection and a loose pin may lead to a pin site infection as well as a pin site infection may lead to pin loosening. HA coating of external fixation pins increases the stability and thereby reduces the risk of pin site infection [30]. In a previous study comparing infected to un-infected pin sites at removal, no differences were found in pin extraction torque force with HA-coated pins, whereas in the standard pin group there was a significant lower extraction torque force in pins classified as infected pin sites than in un-infected [1]. However, the amount of clinically relevant infections in that study was low with only 4 clinically relevant grade 2 infections according to the Checkett–Otterburns classification [31] in the standard pin group and none in the HA-coated pin group. In the present study, the need (33% of the patients) and use (11 days/treated patient) of antibiotics during the time in external fixation were the same in the control group as in our prior studies [32,33]. There was no statistically significant difference in extraction torque force between patients treated with antibiotics or not treated, during the time in the external fixator.

Finally, the price of the drug must be considered and cheaper peroral alternatives exist. In the present study a single injection was chosen to ensure full compliance in the clinical trial situation. Further, the patients in the zoledronate treated group reported muscle pain and flu symptoms significantly more than in the control group. These symptoms are known side effects of the intravenously administered bisphosphonates and can be avoided using peroral administration. The long term side effects of bisphosphonates are arising in patients treated for years and will hardly appear in a single-dose or short-term regimen. Further studies are thus necessary to investigate mode of administration, dosing, frequency and whether it is possible to treat the bone locally, either by coating the pin itself or by implanting the bisphosphonate in the drill hole [8,11,12] before bisphosphonates are recommended in addition when using an external fixator.

In conclusion, an almost 100% improved pin fixation was found in the uncoated pin in diaphyseal bone whereas no effect was found in the HA-coated pin in metaphyseal bone. Maybe bisphosphonate treatment, systemically or preferably locally, can be an alternative when non-coated pins are used but in our model a bisphosphonate does not seem to improve fixation additionally compared to HA coating alone.

## Acknowledgments

The project was supported by Region Skåne, Lund University Hospital, the Swedish Medical Research Council (project 09509), Thure Carlsson, Alfred Österlund, Greta and Johan Kock and Maggie Stephens foundations and the Faculty of Medicine, Lund University.

## References

- [1] Moroni A, Heikkilä J, Magyar G, Toksvig-Larsen S, Giannini S. Fixation strength and pin tract infection of hydroxyapatite-coated tapered pins. *Clin Orthop Relat Res* 2001;388:209–17.

- [2] Asnis SE, Ernberg JJ, Bostrom MP, Wright TM, Harrington RM, Tencer A, et al. Cancellous bone screw thread design and holding power. *J Orthop Trauma* 1996;10:462–9.
- [3] Rovinsky D, Haskell A, Liu Q, Paiement GD, Robinovitch S. Evaluation of a new method of small fragment fixation in a medial malleolus fracture model. *J Orthop Trauma* 2000;14:420–5.
- [4] Gausepohl T, Mohring R, Pennig D, Koebke J. Fine thread versus coarse thread. A comparison of the maximum holding power. *Injury* 2001;32(Suppl 4):SD1–7.
- [5] Magyar G, Toksvig-Larsen S, Moroni A. Hydroxyapatite coating of threaded pins enhances fixation. *J Bone Jnt Surg Br* 1997;79:487–9.
- [6] Moroni A, Aspenberg P, Toksvig-Larsen S, Falzarano G, Giannini S. Enhanced fixation with hydroxyapatite coated pins. *Clin Orthop Relat Res* 1998;346:171–7.
- [7] Moroni A, Cadossi M, Romagnoli M, Faldini C, Giannini S. A biomechanical and histological analysis of standard versus hydroxyapatite-coated pins for external fixation. *J Biomed Mater Res B Appl Biomater* 2008;86B:417–21.
- [8] Skoglund B, Holmertz J, Aspenberg P. Systemic and local ibandronate enhance screw fixation. *J Orthop Res* 2004;22:1108–13.
- [9] Miyaji T, Nakase T, Azuma Y, Shimizu N, Uchiyama Y, Yoshikawa H. Alendronate inhibits bone resorption at the bone-screw interface. *Clin Orthop Relat Res* 2005;430:195–201.
- [10] Moroni A, Faldini C, Hoang-Kim A, Pegreff F, Giannini S. Alendronate improves screw fixation in osteoporotic bone. *J Bone Jnt Surg Am* 2007;89:96–101.
- [11] Wermelin K, Tengvall P, Aspenberg P. Surface-bound bisphosphonates enhance screw fixation in rats-increasing effect up to 8 weeks after insertion. *Acta Orthop* 2007;78:385–92.
- [12] Tengvall P, Skoglund B, Askendal A, Aspenberg P. Surface immobilized bisphosphonate improves stainless-steel screw fixation in rats. *Biomaterials* 2004;25:2133–8.
- [13] Ramachandran M, Ward K, Brown RR, Munns CF, Cowell CT, Little DG. Intravenous bisphosphonate therapy for traumatic osteonecrosis of the femoral head in adolescents. *J Bone Jnt Surg Am* 2007;89:1727–34.
- [14] Aya-ay J, Athavale S, Morgan-Bagley S, Bian H, Bauss F, Kim HK. Retention, distribution, and effects of intraosseously administered ibandronate in the infarcted femoral head. *J Bone Miner Res* 2007;22:93–100.
- [15] Amanat N, Brown R, Bilston LE, Little DG. A single systemic dose of pamidronate improves bone mineral content and accelerates restoration of strength in a rat model of fracture repair. *J Orthop Res* 2005;23:1029–34.
- [16] Li C, Mori S, Li J, Kaji Y, Akiyama T, Kawanishi J, et al. Long-term effect of incadronate disodium (YM-175) on fracture healing of femoral shaft in growing rats. *J Bone Miner Res* 2001;16:429–36.
- [17] Peter B, Gauthier O, Laib S, Bujoli B, Guicheux J, Janvier P, et al. Local delivery of bisphosphonate from coated orthopedic implants increases implants mechanical stability in osteoporotic rats. *J Biomed Mater Res A* 2006;76:133–43.
- [18] Mochida Y, Bauer TW, Akisue T, Brown PR. Alendronate does not inhibit early bone apposition to hydroxyapatite-coated total joint implants: a preliminary study. *J Bone Jnt Surg Am* 2002;84:226–35.
- [19] Rogers MJ. New insights into the molecular mechanisms of action of bisphosphonates. *Curr Pharm Des* 2003;9:2643–58.
- [20] Eberhardt C, Habermann B, Muller S, Schwarz M, Bauss F, Kurth AH. The bisphosphonate ibandronate accelerates osseointegration of hydroxyapatite-coated cementless implants in an animal model. *J Orthop Sci* 2007;12:61–6.
- [21] Bobyn JD, Hacking SA, Krygier JJ, Harvey EJ, Little DG, Tanzer M. Zoledronic acid causes enhancement of bone growth into porous implants. *J Bone Joint Surg Br* 2005;87:416–20.
- [22] Amanat N, McDonald M, Godfrey C, Bilston L, Little D. Optimal timing of a single dose of zoledronic acid to increase strength in rat fracture repair. *J Bone Miner Res* 2007;22:867–76.
- [23] Magyar G, Toksvig-Larsen S, Lindstrand A. Open wedge tibial osteotomy by callus distraction in gonarthrosis. Operative technique and early results in 36 patients. *Acta Orthop Scand* 1998;69:147–51.
- [24] Tägil MWDA, Åstrand J, Little DG, Toksvig-Larsen S. Decreasing the catabolic response by a single bisphosphonate infusion shortens the healing time in hemicallotasis operation. *Bone* 2006;38:S84–5.
- [25] W-Dahl A, Toksvig-Larsen S. Cigarette smoking delays bone healing: a prospective study of 200 patients operated on by the hemicallotasis technique. *Acta Orthop Scand* 2004;75:347–51.
- [26] Lawes TJ, Scott JC, Goodship AE. Increased insertion torque delays pin-bone interface loosening in external fixation with tapered bone screws. *J Orthop Trauma* 2004;18:617–22.
- [27] Piza G, Caja VL, Gonzalez-Viejo MA, Navarro A. Hydroxyapatite-coated external-fixation pins. The effect on pin loosening and pin-track infection in leg lengthening for short stature. *J Bone Jnt Surg Br* 2004;86:892–7.
- [28] Verborgt O, Gibson GJ, Schaffler MB. Loss of osteocyte integrity in association with microdamage and bone remodeling after fatigue *in vivo*. *J Bone Miner Res* 2000;15:60–7.
- [29] Wikenheiser MA, Markel MD, Lewallen DG, Chao EY. Thermal response and torque resistance of five cortical half-pins under simulated insertion technique. *J Orthop Res* 1995;13:615–9.
- [30] Moroni A, Aspenberg P, Toksvig-Larsen S, Falzarano G, Giannini S. Enhanced fixation with hydroxyapatite coated pins. *Clin Orthop* 1998;346:171–7.
- [31] Checketts RGOM, Mac Eachern AG. Pin track infection; definition, incidence and prevention. *Int J Orthop Trauma* 1993;3:16–8.
- [32] W-Dahl A, Toksvig-Larsen S. Pin site care in external fixation sodium chloride or chlorhexidine solution as a cleansing agent. *Arch Orthop Trauma Surg* 2004;124:555–8.
- [33] W-Dahl A, Toksvig-Larsen S. Infection prophylaxis: a prospective study in 106 patients operated on by tibial osteotomy using the hemicallotasis technique. *Arch Orthop Trauma Surg* 2006;126:441–7.