



LUND UNIVERSITY

Herniographic findings in athletes with unclear groin pain.

Kesek, Pavel; Ekberg, Olle; Westlin, N

Published in:
Acta Radiologica

DOI:
[10.1034/j.1600-0455.2002.430612.x](https://doi.org/10.1034/j.1600-0455.2002.430612.x)

2002

[Link to publication](#)

Citation for published version (APA):

Kesek, P., Ekberg, O., & Westlin, N. (2002). Herniographic findings in athletes with unclear groin pain. *Acta Radiologica*, 43(6), 603-608. <https://doi.org/10.1034/j.1600-0455.2002.430612.x>

Total number of authors:
3

General rights

Unless other specific re-use rights are stated the following general rights apply:

Copyright and moral rights for the publications made accessible in the public portal are retained by the authors and/or other copyright owners and it is a condition of accessing publications that users recognise and abide by the legal requirements associated with these rights.

- Users may download and print one copy of any publication from the public portal for the purpose of private study or research.
- You may not further distribute the material or use it for any profit-making activity or commercial gain
- You may freely distribute the URL identifying the publication in the public portal

Read more about Creative commons licenses: <https://creativecommons.org/licenses/>

Take down policy

If you believe that this document breaches copyright please contact us providing details, and we will remove access to the work immediately and investigate your claim.

LUND UNIVERSITY

PO Box 117
221 00 Lund
+46 46-222 00 00

HERNIOGRAPHIC FINDINGS IN ATHLETES WITH UNCLEAR GROIN PAIN

P. KESEK¹, O. EKBERG¹ and N. WESTLIN²

¹Department of Diagnostic Radiology and ²Section of Sports Medicine, Department of Orthopedic Surgery, Malmö University Hospital, Malmö, Sweden.

Abstract

Background: Groin pain in athletes is a common symptom and may, among many other entities, be caused by skeletal changes in the symphysis and the pubic bone or hernia.

Material and Methods: Herniographies in 51 athletes – mainly soccer players – with unclear groin pain were reviewed. The prevalence of various hernias and skeletal changes at the symphysis and os pubis was registered. A questionnaire was also sent to the patients 3–20 years after the herniography.

Results: A hernia was found in 13 patients. Four patients had an indirect inguinal hernia. Eight patients had a direct inguinal hernia and 1 had an obturator hernia. The prevalence of direct inguinal hernia was higher than expected in young men. This may be explained by strain at physical exercise. Bone changes at the pubic symphysis were found in 32 patients, 21 of whom had advanced changes.

Conclusion: A hernia can be found with herniography in one-fourth of athletes with long-standing unclear groin pain. Therefore herniography should be included in the diagnostic procedure. Lesions of the symphysis may be the result of strain of tendons, ligaments and fascias. This may predispose for an inguinal hernia as well.

Key words: Athletes, hernia; peritoneography.

Correspondence: Olle Ekberg, Department of Diagnostic Radiology, Malmö University Hospital, SE-205 02 Malmö, Sweden. FAX + 46 40 96 99 77.

Accepted for publication 8 July 2002.

Pain in the groin is a common problem in many athletes, particularly in soccer-, handball- and ice hockey players (15). In different studies 2% to 28% of all injuries and pain conditions are found in the hip and groin region (11, 19). The true incidence of injuries and groin pain in soccer players is estimated to 0.8/1000h of exposure (7) and the prevalence to 55% in male and to 28% in female players (1). In spite of treatment, chronic groin pain may be severe enough to prevent all kind of sports activity for several months.

The cause of groin pain may be trauma, e.g., fracture, tendon or muscle rupture, or overuse, e.g., symphysitis (osteitis pubis), tendinosis, stress osteopathy of the femoral head, stress fracture, apo-

physitis and infection-osteomyelitis. Other causes are different hernias – inguinal, femoral or obturator hernia and groin insufficiency (sportsman's hernia). Possible diagnoses are also prostatitis, sacroiliitis, disc hernia or nerve entrapments (6, 7, 15, 21).

The diagnostic procedure is often difficult and has to be based on history, clinical examination, laboratory tests, conventional radiography, MR imaging, scintigraphy and herniography (6).

Inguinal hernia has been claimed to be a frequent cause of pain in the groin in athletes. Such a hernia is usually diagnosed at a clinical examination. However, small and even large inguinal hernias may sometimes not be palpable. In different

studies, hernias have been found in 30% of the patients with unclear groin pain (8), but in acute groin injuries this figure is even higher, 56% (7).

Radiological changes in the pubic bone are frequently seen in athletes and have been found in 75% of athletes with chronic groin pain (10, 12).

The aim of this study was to retrospectively review herniographic findings in athletes with unclear groin pain in order to evaluate the frequency

of a non-palpable inguinal hernia and to evaluate the persisting symptoms after treatment.

Material and Methods

At the Department of Radiology, Malmö University Hospital, 1100 herniographies were performed during the years 1977–94 in patients with unclear long-standing groin pain and no palpable hernia (3, 8).

Before the examination the patient should void. 50 ml of contrast medium (iohexol 180 mg I/ml, Omnipaque; Nycomed Amersham) was injected

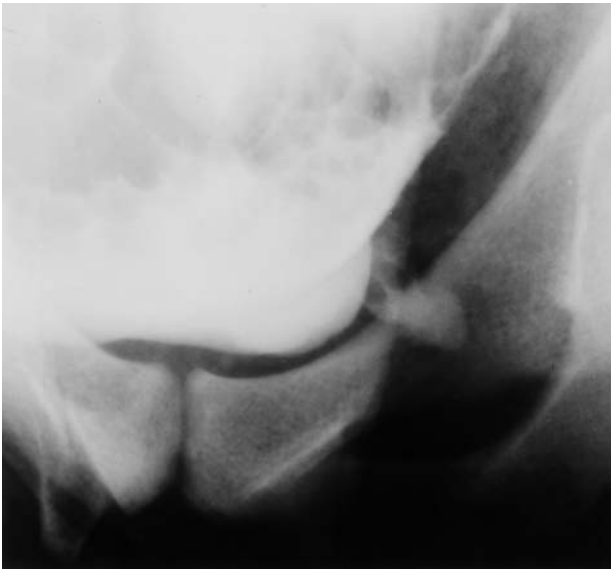

Fig. 1. Direct diverticular hernia. Soccer player, 26 years old, with pain in his left groin for 6 months. At herniography, a small direct diverticular hernia was found in his left groin. This hernia could not be found at operation but hernioplasty was performed. 17 years later the patient was asymptomatic and still exercising.

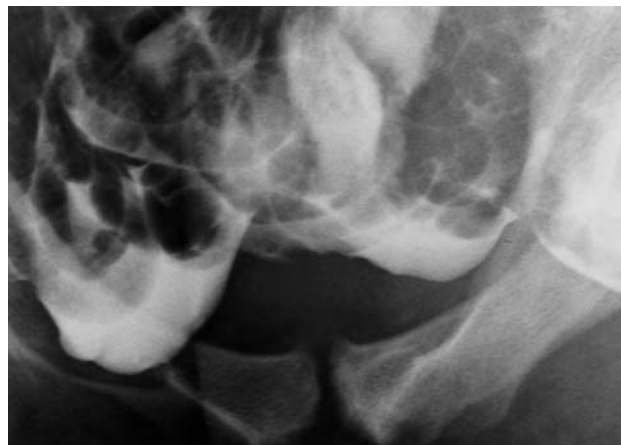

Fig. 3. Broad-based direct inguinal hernia. Soccer player, 26 years old, with pain in his left groin. Herniography showed a broad-based direct inguinal hernia on the contralateral side. Advanced bone changes at the pubic symphysis – erosions and beaking – are seen as well. He was not operated on but was asymptomatic and still training at the follow-up 3 years later.

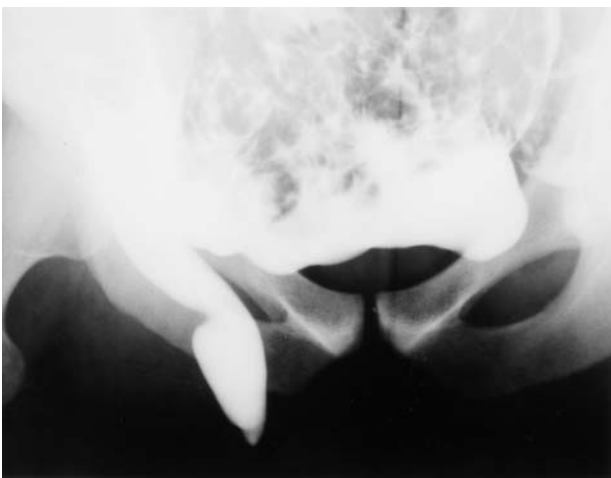

Fig. 2. Indirect inguinal hernia. Soccer player, 23 years old, who had bilateral groin pain, more on the right side. Herniography revealed an 8-cm-long indirect inguinal hernia in his right groin, protruding through the superficial ring of the inguinal canal. The finding was confirmed at operation and the patient has been asymptomatic and is still training at follow-up 12 years later.

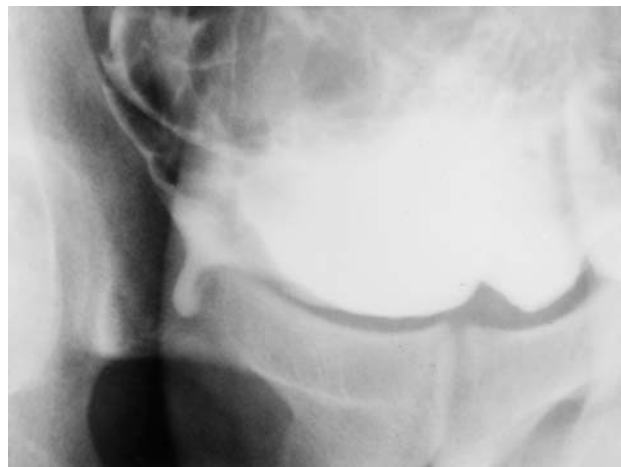


Fig. 4. Obturator hernia. Handball-player, 32 years old, who had pain in his right groin for almost 2 years. A right-sided obturator hernia was seen at herniography. He was operated on and was asymptomatic 20 years after the operation.

into the peritoneal cavity, usually in the midline below the umbilicus. After the injection the patient turned to a prone position and the head of the table was raised. Oblique and posterior-anterior views were obtained with the X-ray tube angled 25° caudally. All exposures were obtained with the patient straining. The patient was also examined in the erect position. Hernias are usually easily seen as protrusions from the abdominal cavity (Figs 1–4).

From the 1100 patients, all cases where the referring surgeon had noticed sports activity were selected for the study. Fifty-one athletes were found. All were males, 17–47 years old (mean 26 years). The duration of symptoms was 1–48 months (mean 6 months). No patient had a palpable hernia.

The history of the patients was reviewed and the films were re-evaluated. A questionnaire was sent to the patients enquiring about the course of the symptoms.

Results

In 51 patients we found 14 hernias (Table 1). One patient had bilateral hernias. Nine patients had a hernia in the symptomatic groin and 3 on the asymptomatic side. Eight hernias were direct, 4 indirect. Groin insufficiency (sportsman's hernia) (Fig. 5) was found in 3 patients.

Seven patients were operated on. Three had an indirect inguinal hernia, 1 an obturator hernia. One patient had a direct diverticular hernia seen at herniography but it could not be found at surgery. The surgeon decided to repair the abdominal wall (Fig. 1). One patient had an open pro-

cessus vaginalis, which was primarily considered to be an indirect inguinal hernia (Fig. 6). At herniography, 1 patient had 2 hernias in his right groin: 1 was considered to be femoral and 1 broad-based direct inguinal hernia. An indirect inguinal hernia was found at operation.

A triangular outpouching from the lateral inguinal fossa (Fig. 7) was found in 5 patients, in 3 of them on the side of symptoms. A patent processus vaginalis was found in 8 patients, in 3 of them on the side of the symptoms. The 5 remaining had symptoms in the other or in both groins.

Most of the 29 patients who have answered our questionnaire have become asymptomatic (Table 2) and they were exercising on average 10 years after herniography. There were more asymptomatic patients among those who had pathological hernio-

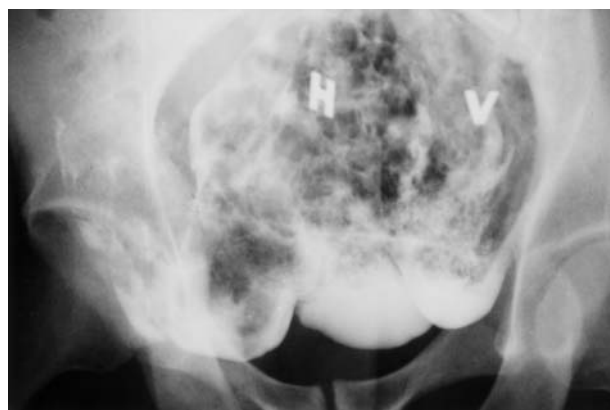

Fig. 5. Groin insufficiency. Soccer player, 23 years old, with pain in his left groin for about 6 months. Herniography showed groin insufficiency most pronounced on the contralateral side. The patient is still exercising 19 years after herniography and he has fewer symptoms than before.

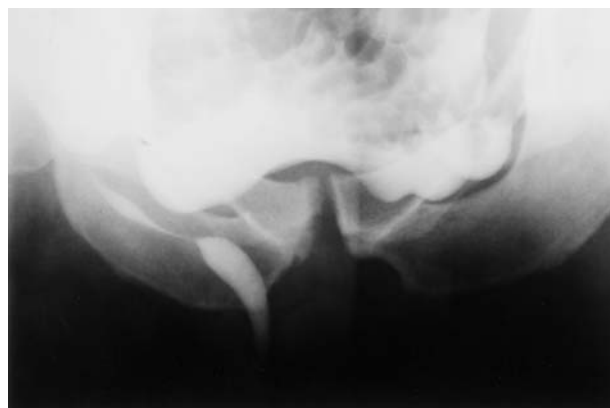

Fig. 6. Processus vaginalis. Soccer player, 26 years old, with pain in his right hip region for about 5 months. At herniography a long processus vaginalis was found. It was primarily considered to be a hernia and was operated. Finally, the symptoms were considered to emanate from the skeleton.

Table 1

Herniographic findings in 51 male athletes 17–47 years old

Finding	Patients, n
<i>Normal herniography</i>	34
Processus vaginalis	8
Triangular outpouching	5
Uncertain finding	2
<i>Pathological finding</i>	16
Indirect inguinal hernia	4
Direct inguinal hernia	8
Diverticular	3
Broad-based	5
Femoral hernia	1
Obturator hernia	1
Groin insufficiency	3

1 patient has been counted twice. He had a femoral and a broad-based direct inguinal hernia in his right groin. An indirect inguinal hernia was found at operation.

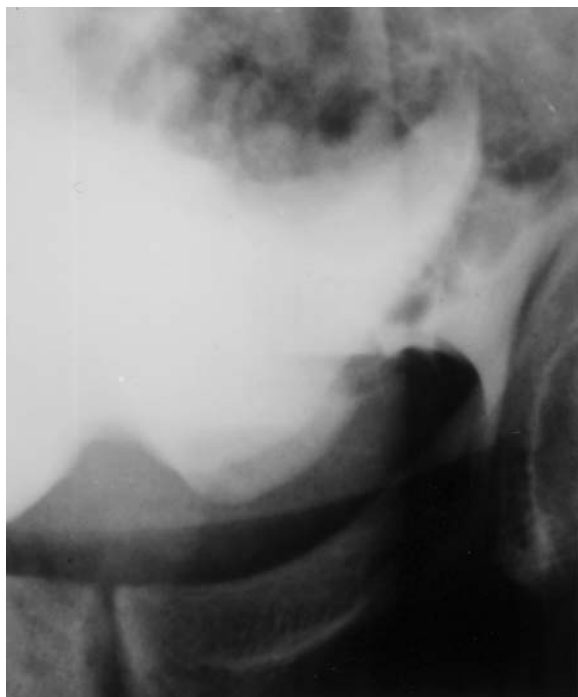


Fig. 7. Triangular outpouching. Soccer player, 36 years old, with bilateral groin pain. The herniography was normal. There was a large triangular outpouching in his left lateral inguinal fossa. This is a normal finding.

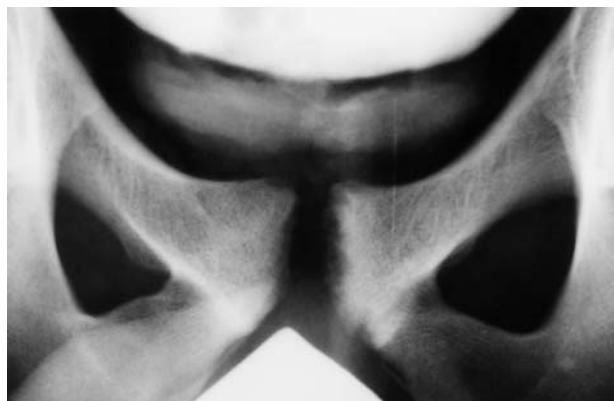

Fig. 8. Symphysisitis. Soccer player, 19 years old, with groin pain for a long time. At herniography there was no hernia but he had advanced bone changes – multiple erosions and moderate sclerosis – at the symphysis pubis.

occurred in 24 of 33 patients with normal herniography but in only 8 of 17 patients with pathological herniography (Fig.8) (chi-square test, $p=0.13$). Advanced skeletal changes were found in 21 patients. There was no difference in outcome at follow-up between patients with and without skeletal changes.

graphy than among those who had a normal one. Nine of 12 patients who had pathological herniography are still exercising at follow-up compared to 13/17 with normal findings. The differences were not significant (Table2).

Skeletal changes in the symphysis and the os pubis were found in 32 of our 51 patients. Changes

Discussion

Inguinal hernia is one of the etiologic possibilities that should be considered in athletes with chronic groin pain when an explanation cannot be found in the musculoskeletal system. In the present study a hernia was found in 13 of 51 athletes with unclear groin pain and normal or unclear palpatory

Table 2
Follow-up in 29 of 51 examined patients

	Number of patients, n				
	Total	Still exercising	Asymptomatic	Improved	Persisting symptoms
Herniographic finding					
Normal	17	13	9	5	3
Pathological	12	9	10	2	
Hernia operated	5	4	4	1	
Hernia not operated	4	3	4		
Groin insufficiency	3	2	2	1	
Total	29	22	19	7	3

Two of the 5 patients who were operated on had an indirect inguinal hernia. The others had had a direct diverticular hernia, an obturator hernia (he is no longer exercising, but 20 years have passed since herniography) and the 1 who had a direct and a femoral hernia at herniography but an indirect hernia at operation. Two of the patients who were not operated on had a direct diverticular hernia and 2 had a direct broad-based hernia. The 3 patients with persisting symptoms are exercising. Their herniography was normal, 1 of them had advanced skeletal changes. Four of 7 patients who have stopped exercising are asymptomatic and 3 have improved.

findings. It has been claimed that almost all patients (87–100%) with unclear groin pain and with hernia found at herniography are cured by surgery (17, 22). The reliability of herniography in detecting a hernia has been proved in many previous studies (3, 8).

Surgical exploration of the groin may be very difficult. It has been claimed that only a preperitoneal approach (*ad modum* Nyhus) may reveal all hernias. In 4 of 7 of our operated patients the herniographic finding was confirmed at operation. In 2 patients the findings at herniography were only partially confirmed at operation (Figs 1 and 6). In 1 case the two judgments were different (femoral hernia at herniography, indirect inguinal hernia at operation).

The most common pathological findings at herniography have been described previously (3, 8). It has been pointed out that all hernias that are found at herniography may not be symptomatic (16). In a study of 303 patients, 18% had a hernia in the asymptomatic groin (4). However, SMEDBERG (16) claimed that all indirect inguinal and femoral hernias should be operated, as they may potentially become symptomatic.

The prevalence of hernia in our study of patients with unclear groin pain was 25%, i.e., about the same as in previous studies of various groups of patients with unclear groin pain examined with herniography. In previous studies a hernia was found in up to 35% of the patients (20). Therefore it seems as if a hernia is not more common in athletes with groin pain than in other cohorts with similar problems. However, for athletes the prevalence of hernia in our study may be considered to be rather low. GULLMO (8) found some pathological changes in almost all of his 50 athletes with groin pain. The most common finding was direct inguinal hernia. SMEDBERG et al. (18) examined 78 male athletes with groin pain by herniography. They found a hernia in 112 of 156 groins (72%). The most frequent herniographic finding was direct inguinal hernia. However, our material is not comparable to that of SMEDBERG et al. since they found 8 hernias at physical examination before herniography and our study did not include patients with palpable hernia. In a study of 60 football players with unclear groin pain YILMAZLAR et al. (22) found a hernia in 51 (85%).

Our study does not allow any conclusion about the overall incidence of groin hernia in athletes, only the prevalence in those with unclear groin pain. Athletes may in fact also suffer from more classic palpable groin hernia.

Most of the hernias found in previous herniographic studies were indirect (63–80%), while 20–

25% were direct. In a large review of 4879 herniographies from 8 Swedish hospitals (13), 600 operations were performed on men under 40 years of age. Of the operated hernias, 72% were indirect, 21% direct and 1% femoral. The high prevalence of direct inguinal hernia found in athletes – 8 of 15 in the present study – has been noticed earlier (8, 14, 18). The direct inguinal hernia has been described in adults exposed to heavy straining and in elderly (2, 9). In athletes the high prevalence of direct inguinal hernia could be explained by weakness of the posterior wall of the inguinal canal (transversal fascia) due to repeated strain at physical exercise. SMEDBERG et al. (18) suggested the same explanation.

The finding of a triangular outpouching (Fig. 6) of the lateral inguinal fossa and of a patent processus vaginalis (Fig. 7) is as frequent in other materials (5) as in our previous study (chi-square test, $p > 0.05$). They have been found in the symptomatic as well as in the non-symptomatic groin. This confirms our previous conclusion that these findings are normal.

From the 29 patients whom we could follow longitudinally for up to 20 years, the ones with pathological herniography seemed to have less groin pain than the normal ones but the difference was not significant (Table 2). The patients with normal herniography might have had other diagnoses.

The prevalence of bone lesions at the symphysis among our patients was rather high (64%), but was somewhat lower than in previous studies (10, 12). As the pubic rami are attachments of the adductor muscles as well as the inguinal ligament, this may be considered to be a sign of stress reaction. A correlation of the prevalence of bone lesions and the athletic ability has been proven (10). On the other hand, repeated microtrauma during sports activity may lead to stress reaction as well as to a weakness of the transversal fascia, which is a predisposing factor for a direct inguinal hernia. The repeated stress at sports activity may thus predispose for direct hernia as well as for symphysisitis. According to SMEDBERG (16), athletic activity in predisposed individuals, who have a hereditary weakness of collagen, may lead to much earlier development of their hernia.

Conclusion: Our study showed that hernia is a common finding in athletes suffering from pain in the groin and without a diagnosis. Herniography is useful in evaluating these patients as hernia can usually be defined or excluded. Herniography is probably the best method for studying the prevalence of inguinal hernia since the result is not dependent on one examiner as in surgery or ultrasonography, images may be saved and re-evalu-

ated, and the findings may be easily compared with other tests. In our opinion, it should be performed on all patients with groin pain and without a palpable hernia before a surgical exploration.

ACKNOWLEDGMENTS

We would like to acknowledge the contributions of the Groin Pain Research Group at the Malmö University Hospital, Sweden. This group consists of Nils Westlin, Fredrik Nyquist, Håkan Magnusson, and Richard Dahan from the Department of Orthopedics, Jack Besjakov, Christina von Scheele, Olle Ekberg, and Pavel Kesek from the Department of Radiology, Åke Lasson from the Department of Surgery, Per-Anders Abrahamsson from the Department of Urology, and Ola Thorsson from the Department of Clinical Physiology.

REFERENCES

1. DAHAN R. W. N.: The prevalence of groin pain in male and female soccer players. (In Swedish.) Swed. Soc. Sports Med. Spring Meeting, Ystad 1999, p. 15.
2. EAMES N. W., DEANS G. T., LAWSON J. T. & IRWIN S. T.: Herniography for occult hernia and groin pain. *Br. J. Surg.* 81 (1994), 1529.
3. EKBERG O.: Inguinal herniography in adults. Technique, normal anatomy, and diagnostic criteria for hernias. *Radiology* 138 (1981), 31.
4. EKBERG O., FRITZDORF J. & BLOMQUIST P.: Herniographic appearance of contralateral inguinal hernia. *Acta Radiol. Diagn.* 25 (1984), 125.
5. EKBERG O. & KESEK P.: Herniographic appearance of the lateral inguinal fossa. *Acta Radiol.* 28 (1987), 563.
6. EKBERG O., PERSSON N. H., ABRAHAMSSON P. A., WESTLIN N. E. & LILJA B.: Longstanding groin pain in athletes. A multidisciplinary approach. *Sports Med.* 6 (1988), 56.
7. EKSTRAND J. & HILDING J.: The incidence and differential diagnosis of acute groin injuries in male soccer players. *Scand. J. Med. Sci. Sports* 9 (1999), 98.
8. GULLMO A.: Herniography. The diagnosis of hernia in the groin and incompetence of the pouch of Douglas and pelvic floor. *Acta Radiol. Suppl.* 361 (1980).
9. HACKNEY R. G.: The sports hernia. A cause of chronic groin pain. *Br. J. Sports Med.* 27 (1993), 5.
10. HARRIS N. H. & MURRAY R. O.: Lesions of the symphysis in athletes. *Br. Med. J.* 4 (1974), 211.
11. KARLSSON J., SWÄRD L., KÄLEBO P. & THOMÉE R.: Chronic groin injuries in athletes. *Sports Med.* 17 (1994), 141.
12. MAJOR N. M. & HELMS C.: A. Pelvic stress injuries. The relationship between osteitis pubis (symphysis pubis stress injury) and sacroiliac abnormalities in athletes. *Skeletal Radiol.* 26 (1997), 711.
13. NILSSON E., KALD A., ANDERBERG B. et al.: Hernia surgery in a defined population. A prospective three year audit. *Eur. J. Surg.* 163 (1997), 823.
14. POLGLASE A. L., FRYDMAN G. M. & FARMER K. C.: Inguinal surgery for debilitating chronic groin pain in athletes. *Med. J. Aust.* 155 (1991), 674.
15. RENSTRÖM P. & PETERSON L.: Groin injuries in athletes. *Br. J. Sports Med.* 14 (1980), 30.
16. SMEDBERG S.: Operative treatment/abdominal wall repair in care and treatment of injuries related to sports and motion. Part 2, p. 113. Injuries of lower extremity. (In Swedish.) Rhone Poulenc Rorer, Helsingborg, Sweden 1997.
17. SMEDBERG S. G., BROOMÉ A. E., ELMÉR O. & GULLMO A.: Herniography in the diagnosis of obscure groin pain. *Acta Chir. Scand.* 151 (1985), 663.
18. SMEDBERG S. G., BROOMÉ A. E., GULLMO A. & ROOS H.: Herniography in athletes with groin pain. *Am. J. Surg.* 149 (1985), 378.
19. SMOLANKA V.: Groin pain in soccer players. *Phys. Sportsmed.* 8 (1980), 57.
20. TOLLEFSEN I., HELGELAND E., ANDERSEN E. & BJERKESET O.: Herniography. A 3-year material from a central hospital. (In Norwegian.) *Tidsskr. Nor. Laegeforen.* 115 (1995), 50.
21. WESTLIN N.: Groin pain in athletes from southern Sweden. *Sports Med. Arthrosc. Rev.* 5 (1997), 280.
22. YILMAZLAR T., KIZIL A., ZORLUOGLU A. & OZGUC H.: The value of herniography in football players with obscure groin pain. *Acta Chir. Belg.* 96 (1996), 115.