



LUND UNIVERSITY

Intravitreal sustained-release ganciclovir implants for severe bilateral cytomegalovirus retinitis after stem cell transplantation.

Ghosh, Fredrik; Hansson, Lars-Jörgen; Bynke, Gunnel; Békássy, Albert

Published in:
Acta Ophthalmologica Scandinavica

DOI:
[10.1034/j.1600-0420.2002.800121.x](https://doi.org/10.1034/j.1600-0420.2002.800121.x)

2002

[Link to publication](#)

Citation for published version (APA):
Ghosh, F., Hansson, L.-J., Bynke, G., & Békássy, A. (2002). Intravitreal sustained-release ganciclovir implants for severe bilateral cytomegalovirus retinitis after stem cell transplantation. *Acta Ophthalmologica Scandinavica*, 80(1), 101-104. <https://doi.org/10.1034/j.1600-0420.2002.800121.x>

Total number of authors:
4

General rights

Unless other specific re-use rights are stated the following general rights apply:
Copyright and moral rights for the publications made accessible in the public portal are retained by the authors and/or other copyright owners and it is a condition of accessing publications that users recognise and abide by the legal requirements associated with these rights.

- Users may download and print one copy of any publication from the public portal for the purpose of private study or research.
- You may not further distribute the material or use it for any profit-making activity or commercial gain
- You may freely distribute the URL identifying the publication in the public portal

Read more about Creative commons licenses: <https://creativecommons.org/licenses/>

Take down policy

If you believe that this document breaches copyright please contact us providing details, and we will remove access to the work immediately and investigate your claim.

LUND UNIVERSITY

PO Box 117
221 00 Lund
+46 46-222 00 00

Intravitreal sustained-release ganciclovir implants for severe bilateral cytomegalovirus retinitis after stem cell transplantation

Fredrik Ghosh¹, Lars-Jörgen Hansson¹, Gunnel Bynke¹ and Albert N. Békássy²

¹Departments of Ophthalmology and ²Pediatrics, University Hospital, Lund, Sweden

ABSTRACT.

Purpose: To describe the treatment of cytomegalovirus (CMV) retinitis with intravitreal sustain-release ganciclovir devices in a 16-year-old patient in third remission of acute lymphoblastic leukemia after stem cell transplantation.

Methods: The patient received a stem cell transplant from an unrelated bone marrow donor after which he contracted a serious CMV infection manifested in the lungs and retinae. His immune system at this time was almost completely depleted. Implantation of a sustained-release ganciclovir device was performed in both eyes when retinitis progressed in spite of aggressive antiviral intravenous treatment.

Results: No per- or postoperative complications were noted. Infiltrates, hemorrhages and macular edema present preoperatively dissolved over a period of six months. The final visual acuity was 1.0 in both eyes. The patients immune system and lung function slowly recovered during the same time period.

Conclusions: The intravitreal ganciclovir implant provides safe and effective therapy against CMV retinitis, and should be considered in patients acquiring the infection after stem cell transplantation.

Key words: acute lymphoblastic leukemia (ALL) – bone marrow transplant (BMT) – immune reconstitution – immunosuppression – stem cell transplantation (SCT) – vitreoretinal surgery.

Acta Ophthalmol. Scand. 2002; 80: 101–104

Copyright © Acta Ophthalmol Scand 2002. ISSN 1395-3907

Cytomegalovirus (CMV) retinitis is an infection affecting up to one third of patients (range 5.7–37%) with acquired immunodeficiency syndrome (AIDS; Jacobson et al. 1988; Jabs 1995). A selective T-cell dysfunction, more specifically a low CD4 T lymphocyte count predispose AIDS patients to the infection (Pertel et al. 1992). In other immunosuppressed patient categories, the incidence of CMV retinitis is comparatively low. One such category is represented by leukemia patients treated with stem cell transplantation (SCT). These

patients undergo a conditioning regimen before the infusion of bone marrow to deplete the recipient's bone marrow, thereby allowing repopulation of the bone marrow with donor cells, and minimizing the risk of graft rejection. Additionally, these patients are kept on immunosuppressive therapy postoperatively to prevent the much feared complication of graft-versus-host disease (GvHD). As a consequence of the immunosuppression, CMV infections after SCT are quite common and affects various organs (Gutotat et al. 1987), but CMV retinitis has

been reported only sporadically (Kaulfersch et al. 1989; McAuliffe et al. 1997). We here report the successful treatment of a 16-year-old patient, suffering from bilateral CMV retinitis following SCT.

Case Report

The patient was diagnosed with acute lymphoblastic leukemia at the age of five. He was treated according to Swedish Children Leukemia Group protocol with intense combined chemotherapy for 3 years. Remission was induced, but two relapses occurred subsequently at 11 and 14 years of age. While in his third remission, induced by chemotherapy, he received an allogeneic stem cell graft from an unrelated bone marrow donor at the age of 16. The preparative regimen included total body irradiation and chemotherapy (high-dose Ara-C and cyclophosphamide). He made an uneventful hematological recovery and was managed on ciklosporine-A, as a GvHD prophylaxis.

CMV reactivation occurred five weeks post grafting, verified by quantitative PCR in the broncho-alveolar lavage and body excretas. Serious and rapidly progressing pneumonia was diagnosed on chest X-ray within a week. A routine eye examination at this time revealed 1.0 (Monoyer) visual acuity (VA) in both eyes and a normal fundus appearance. In spite of aggressive antiviral intravenous treatment with immunoglobulin and ganciclovir for four weeks, the condition of the pa-

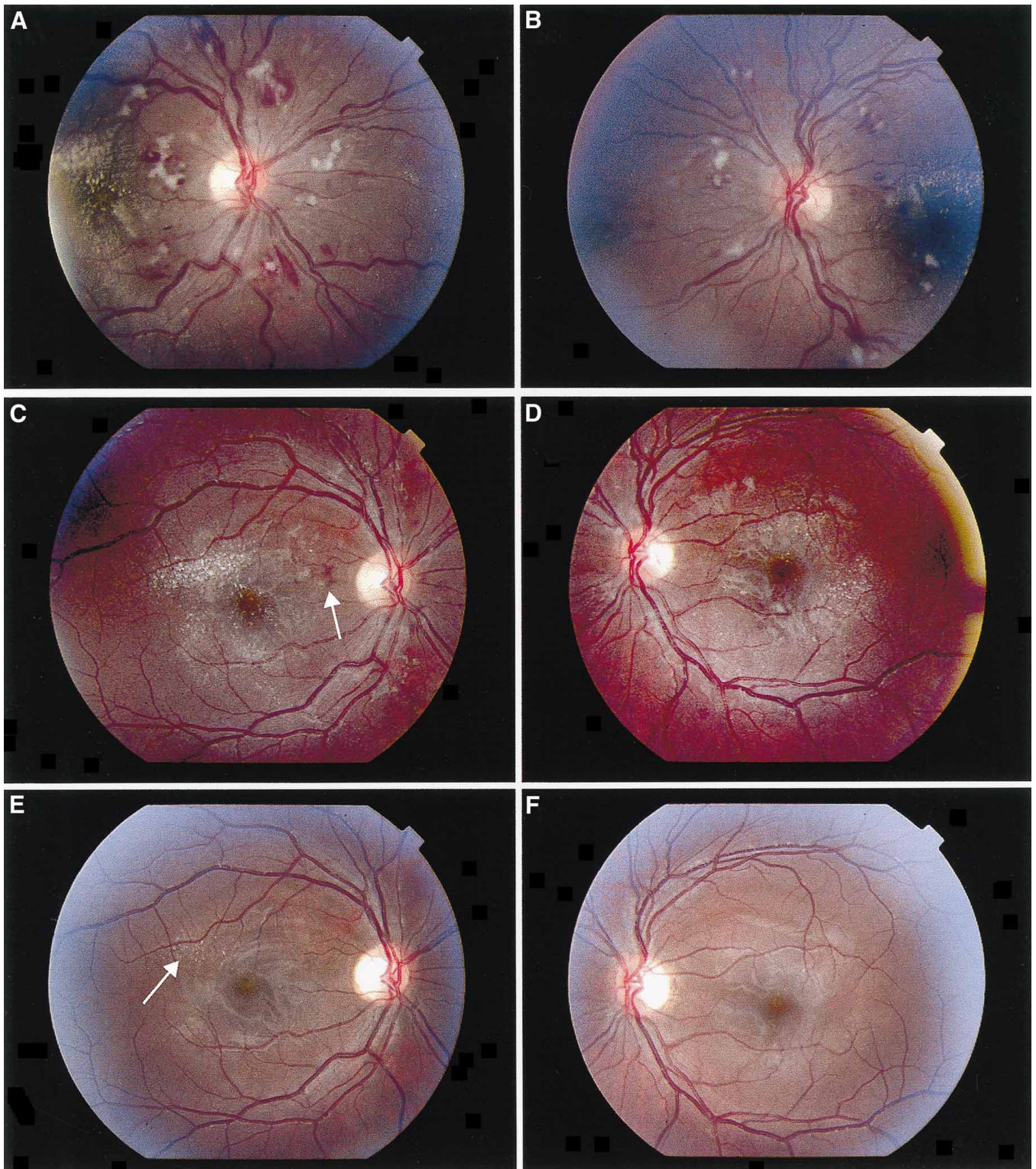


Fig. 1. Fundus appearance after implantation of intravitreal sustained-release ganciclovir implants. (A and B) Five days after implantation. In the right (A) and left (B) fundi, multiple hemorrhages and whitish infiltrates can be seen in all quadrants. Macular edema is present in both eyes. The visual acuity (VA) is 0.04 in the right and 0.3 in the left eye. (C and D) Two months after implantation. One hemorrhage is still present in the right eye (→), but none can be found in the left eye. No infiltrates are present, but a macular edema is evident in both eyes. The VA is 0.6 in the right and 0.9 in the left eye. (E and F) Six months after implantation. No hemorrhages, infiltrates or macular edema can be seen. Minimal retinal atrophies in the right eye (→) is the only remaining sign of the CMV retinitis. The VA is 1.0 in both eyes.

tient deteriorated, and he became oxygen dependent. Cyclosporine-A immunosuppression was discontinued three months after transplantation with no occurrence of GvHD. Thoracoscopic lung biopsy one month later showed a morphology of heavy viral pneumonia resembling obliterative bronchiolitis. The cause was identified by immunohistochemistry as a co-infection of CMV and Influenza A virus.

The patient now started to complain of dim vision and VA had fallen to 0.4 in both eyes. CMV retinitis was diagnosed, with both eyes displaying multiple whitish retinal infiltrates and hemorrhages as well as low grade macular edema. Treatment was intensified to include both ganciclovir and foscarnet intravenously, but the retinitis progressed with more infiltrates, hemorrhages and increasing exudative lesions in both maculae. To save the retinae, intravitreal injections of ganciclovir according to the protocol developed by Young et al. (1998) was started in both eyes, five months after the stem cell transplant. The patient was completely immune depleted at this time judged by CD4 count $0.08 \times 10^9/L$ (normal value is $0.5-1.6 \times 10^9/L$) and markedly low T cell reactivity measured by phytohemagglutinin (PHA) stimulation test. The deteriorating state of the patient and the need for general anesthesia to perform the procedure, made planning of the required weekly intravitreal injections difficult. Instead a sustained-release ganciclovir device was implanted in each eye.

The implantation procedure was, with a few exceptions, identical to the one described by Sanborn et al. (1992). The patient was put under general anesthesia. The ganciclovir containing device (Vitraser[®], Bausch & Lomb Surgical Inc., Claremont, California, USA) was prepared by trimming the anchoring strut and passing a double armed 9-0 nylon suture through the base. A conjunctival peritomy was performed in the lower temporal quadrant and a 5-mm limbus parallel sclerotomy was made 4mm from the limbus with a microvitrectomy blade. The device was now grasped with smooth forceps and introduced into the vitreous cavity. The anchoring suture was passed through either side of the scleral incision and tied. Additional 9-0 nylon sutures were placed to close the wound and the conjunctiva was closed with 8-0 vicryl sutures. Bethametasone and gentamicin were injected subconjunctivally. An indirect fundus examination was performed confirming the proper

position of the implants. No perioperative complications were noted.

Five days after implantation the fundus appeared unchanged from preoperative examination and the patient had a VA of 0.04 RE and 0.3 LE (Figs 1A and B). The pathological findings in the fundus subsequently diminished, and the visual acuity 19 days postoperatively was 0.7 in both eyes. Two months after surgery, the VA was 0.6 RE, and 0.9 LE (Figs 1C and D). Most hemorrhages and all infiltrates had disappeared at this time, but exudative lesions were still present in both maculae (Figs 1C and D). Six months after implantation (11 months after the SCT), the VA was 1.0 in both eyes, and no macular edema, infiltrates or hemorrhages could be seen (Figs 1E and F). Minimal retinal atrophies could be detected in the right eye as the only remaining sign of the CMV retinitis. At no time did the patient report any discomfort locally or visual field disturbances from the implants.

The general condition of the patient, i.e. his lung capacity, gradually improved seven months after the stem cell transplantation (SCT) and oxygen requirement was discontinued. He was, however, kept on systemic intense combined antiviral therapy. By this time, CMV quantitative PCR analysis of the body excretes showed weak positive reaction, but gene sequencing of the CMV isolate verified ganciclovir-resistant C607Y genotypic mutation. As clinical improvement and immune recovery was already evident (by reoccurrence of PHA tested T-cell reactivity and CD4 count reaching the so called 'magical' $0.2 \times 10^9/L$ limit), all systemic antiviral treatment was stopped. At follow up, 11 months after the SCT, the general condition of the patient was completely restored. Immunological screening showed CD4 count at the lower limit of the normal range and PHA-induced T-cell stimulatory response was normal.

Discussion

The introduction of ganciclovir and foscarnet has radically changed the poor prognosis of CMV retinitis. One of the more recent additions to the armamentarium of treatments is the sustained-release intravitreal ganciclovir implant which has been successfully used in AIDS patients (Sanborn et al. 1992; Martin et al. 1994). Reported complications of the operation include endophthalmitis,

extrusion of the implant, retinal detachment, vitreous hemorrhage and placement of the implant in the suprachoroidal space (Sanborn et al. 1992; Anand et al. 1993). We found the implant procedure fairly simple to perform, and did not experience any per- or postoperative complications during the six-month follow-up in the patient reported here.

Intravitreal administration of ganciclovir is a treatment for CMV retinitis only, and cannot be given as single therapy when systemic infection is present. On the other hand intravitreal ganciclovir is more efficient in treating CMV retinitis than intravenous (i.v.) administration of the drug (Young et al. 1998), which is well illustrated in our patient who received both foscarnet and ganciclovir i.v., but still progressed in his retinitis. Additionally, local ganciclovir therapy minimizes the hazardous side-effects of i.v. ganciclovir (bone marrow suppression) and foscarnet (nephrotoxicity), and has shown very little, if any, adverse effects on the ocular tissues (Charles & Steiner 1996; Young et al. 1998). The sustained-release device remains active for six to seven months, after which time it can be replaced or supplemented by a second device at a different operation site if sustained therapy is required (Morley et al. 1995).

Reports on the implant being used in patients suffering from CMV retinitis after bone marrow transplant are few and include only the adult population (McAuliffe et al. 1997). To our knowledge the present case represents the first pediatric patient treated with the ganciclovir implant after stem cell transplantation.

Cytomegalovirus infection in the immunosuppressed patient represents a reactivation of a latent primary infection. When and if immune competence is regained, the virus is controlled and the CMV virus returns to its previously latent stage. A reconstitution of the immune system is thus of utmost importance in any immunosuppressed patient displaying signs of active CMV infection.

Our patient was CMV positive at the time of his stem cell transplant but the donor was not. As a consequence, no immunologic memory was established in the donor immune system and the CMV infection was reactivated since the patients own immune cells were obliterated by the conditioning and postgrafting immunosuppressive treatment. The very slow reconstitution of the immune system in spite of the early discontinuation of im-

munosuppressive therapy allowed the CMV to ravage systemically, in the lungs and retinae. Antiviral therapy under such conditions is directed at stopping the progress of the disease until immunological reconstitution is achieved. The rapid improvement of the CMV retinitis of our patient suggests that the intravitreal ganciclovir implant controlled the CMV retinitis directly, but the long duration of the sustained-release preparation also gave the patient enough time to reconstitute his new immune system, without irreversible damage to the retina.

To summarize, we have illustrated that the intravitreal sustained-release ganciclovir device can be effective in treating CMV retinitis in a severely immunosuppressed patient. We suggest that the device should be considered not only in adult patients suffering from AIDS but also in young patients with CMV retinitis after stem cell transplantation.

References

- Anand R, Nightingale SD, Fish RH, Smith TJ & Ashton P (1993): Control of cytomegalovirus retinitis using sustained release of intraocular ganciclovir. *Arch Ophthalmol* **111**: 223–227.
- Charles NC & Steiner GC (1996): Ganciclovir intraocular implant. A clinicopathologic study. *Ophthalmology* **103**: 416–421.
- Guyotat D, Gibert R, Chomel J, Archimbaud E, Bossard S, Maupas J, Fiere D & Aymard M (1987): Incidence and prognosis of cytomegalovirus infections following allogeneic bone marrow transplantation. *J Med Virol* **23**: 393–399.
- Jabs DA (1995): Ocular manifestations of HIV infection. *Trans Am Ophthalmol Soc* **93**: 623–683.
- Jacobson MA, O'Donnell JJ, Porteous D, Brodie HR, Feigal D & Mills J (1988): Retinal and gastrointestinal disease due to cytomegalovirus in patients with the acquired immune deficiency syndrome: prevalence, natural history, and response to ganciclovir therapy. *Q J Med* **67**: 473–486.
- Kaulfersch W, Urban C, Hauer C, Lackner H, Gamillscheg A, Slavic I & Langmann G (1989): Successful treatment of CMV retinitis with ganciclovir after allogeneic marrow transplantation. *Bone Marrow Transplant* **4**: 587–589.
- Martin DF, Parks DJ, Mellow SD et al. (1994): Treatment of cytomegalovirus retinitis with an intraocular sustained-release ganciclovir implant. A randomized controlled clinical trial. *Arch Ophthalmol* **112**: 1531.
- McAuliffe PF, Hall MJ, Castro-Malaspina H & Heinemann MH (1997): Use of the ganciclovir implant for treating cytomegalovirus retinitis secondary to immunosuppression after bone marrow transplantation. *Am J Ophthalmol* **123**: 702–703.
- Morley MG, Duker JS, Ashton P & Robinson MR (1995): Replacing ganciclovir implants. *Ophthalmology* **102**: 388–392.
- Pertel P, Hirschtick R, Phair J, Chmiel J, Pogensee L & Murphy R (1992): Risk of developing cytomegalovirus retinitis in persons infected with the human immunodeficiency virus. *J Acquir Immune Defic Syndr* **5**: 1069–1074.
- Sanborn GE, Anand R, Torti RE, Nightingale SD, Cal SX, Yates B, Ashton P & Smith T (1992): Sustained-release ganciclovir therapy for treatment of cytomegalovirus retinitis. Use of an intravitreal device. *Arch Ophthalmol* **110**: 188–195.
- Young S, Morlet N, Besen G, Wiley CA, Jones P, Gold J, Li Y, Freeman WR & Coroneo MT (1998): High-dose (2000 – microgram) intravitreal ganciclovir in the treatment of cytomegalovirus retinitis. *Ophthalmology* **105**: 1404–1410.

Received on March 16th, 2001.
Accepted on September 19th, 2001.

Correspondence:
Fredrik Ghosh, MD
Department of Ophthalmology
Lund University Hospital
S-221 85 Lund
Sweden
Phone: +46 46 2220765
Fax: +46 46 2220774
e-mail: fredrik.ghosh@oft.lu.se