LUND UNIVERSITY

Interventions for portal hypertension in patients with portal vein occlusion and possible effects of a stent-graft on hepatic circulation

Keussen, Inger

2007

Link to publication

Citation for published version (APA):
Keussen, I. (2007). *Interventions for portal hypertension in patients with portal vein occlusion and possible effects of a stent-graft on hepatic circulation*. [Doctoral Thesis (compilation), Radiology Diagnostics, Malmö]. Diagnostic Radiology, (Lund).

Total number of authors:
1

General rights
Unless other specific re-use rights are stated the following general rights apply:
Copyright and moral rights for the publications made accessible in the public portal are retained by the authors and/or other copyright owners and it is a condition of accessing publications that users recognise and abide by the legal requirements associated with these rights.
• Users may download and print one copy of any publication from the public portal for the purpose of private study or research.
• You may not further distribute the material or use it for any profit-making activity or commercial gain
• You may freely distribute the URL identifying the publication in the public portal

Read more about Creative commons licenses: https://creativecommons.org/licenses/

Take down policy
If you believe that this document breaches copyright please contact us providing details, and we will remove access to the work immediately and investigate your claim.

LUND UNIVERSITY

PO Box 117
221 00 Lund
+46 46-222 00 00

INTERVENTIONS FOR PORTAL HYPERTENSION IN PATIENTS WITH PORTAL VEIN OCCLUSION AND POSSIBLE EFFECTS OF A STENT-GRAFT ON HEPATIC CIRCULATION

Interventions for Portal Hypertension in Patients with Portal Vein Occlusion and Possible Effects of a Stent-graft on Hepatic Circulation

Inger Keussen

Akademisk avhandling

Som med vederbörligt tillstånd av Medicinska Fakulteten vid Lunds Universitet
för avläggande av doktorsexamen i medicinsk vetenskap kommer att offentligen försvaras
i Rune Grubb salen, (BMC), Sölvegatan 19, Lund, torsdagen 20 december, 2007, kl 9.00.

Fakultetsopponent:
Professor Rickard Nyman
Röntgen/BFC, Akademiska sjukhuset
Uppsala

LUND UNIVERSITY
Faculty of Medicine

Lund 2007
Diagnostic Radiology
Department of Clinical Sciences

Organization
LUND UNIVERSITY
Diagnostic Radiology
Department of Clinical Sciences

Document name
DOCTORAL DISSERTATION

Date of issue
November 8, 2007

Sponsoring organization

Author(s)
Inger Keussen

Title and subtitle
Interventions for Portal Hypertension in Patients with Portal Vein Occlusion and Possible Effects of a Stent-graft on Hepatic Circulation

Abstract

Symptomatic portal hypertension (PH), is often treated with transjugular intrahepatic portosystemic shunt (TIPS). Patients with PH, caused by prehepatic portal vein occlusion, require recanalisation with stent or stent-graft often followed by additional TIPS. Stent-grafts used for TIPS, may occlude the outflow from the adjacent hepatic vein, potentially disturbing the circulation through the adjoining part of the liver.

In paper I, results of interventional treatment in children with PH, secondary to occlusion of the portal vein were reported. Interventional treatment was feasible, but re-intervention and follow up were important for improvement of results. In paper IV, interventional radiological treatment in 24 patients with PH and occlusion of the splanchnic veins was evaluated retrospectively. In the majority of cases treatment was technically successful, with subsequent improvement of symptoms.

Paper II and III report results of experimental studies. Possible negative effects of hepatic vein occlusion by the stent-graft were evaluated with interventional, scintigraphic, radiopharmaceutical and histopathological methods. In the first experiment we found that arterial supply to the liver was diminished directly after hepatic vein occlusion. In the second experimental study, the outflow from the hepatic vein was evaluated directly after TIPS and re-evaluated after two weeks. Stent-grafts used for TIPS occlude the hepatic vein, but do not have prolonged circulatory effect and do not affect the liver parenchyma.

In conclusion, interventional treatment of patients with PH and occlusion of splanchnic veins is feasible and use of stent-grafts for TIPS has no long-lasting negative effect on the liver circulation.

DOKUMENTDATABLAD enl SIS 61 41 21

Key words:
portal vein occlusion, TIPS, portal hypertension, recanalisation, children, stent, hepatic vein occlusion, scintigraphy

Classification system and/or index terms (if any):

Supplementary bibliographical information:

Language
English

ISSN and key title: 1652-8220

ISBN 978-91-85897-35-3

Recipient's notes

Number of pages 84

Price

Security classification

Distribution by (name and address)
Inger Keussen, Diagnostic Radiology, Department of Clinical Sciences, Lund University, Sweden.

I, the undersigned, being the copyright owner of the abstract of the above-mentioned dissertation, hereby grant to all reference sources permission to publish and disseminate the abstract of the above-mentioned dissertation.

Signature  Date November 8, 2007

To my family

Live as if you were to die tomorrow.
Learn as if you were to live forever.

Mahatma Gandhi

© 2007 Inger Keussen and authors of included articles
Layout & typography: Maria Näslund/Formfaktorn
Printed by Media Tryck, Lund 2007

ISBN 978-91-85897-35-3
ISSN 1652-8220

Contents

List of papers 9

Abbreviations 10

Introduction 11

Historical background 11

Overview of the structure and the function of the liver 11

Portal hypertension; etiology, causes and assessment 12

Portal hypertension; symptoms and treatment 14

TIPS 17

Recanalisation of splanchnic veins 22

Aims 24

Material and Methods 24

Experimental studies 24

Clinical studies 27

Results 34

Experimental studies 34

Clinical studies 35

Discussion 38

Conclusions 41

Future perspectives 41

Populärvetenskaplig sammanfattning 42

Acknowledgements 43

References 44

Papers

Paper I 53

Paper II 63

Paper III 69

Paper IV 75

Errata paper I–IV 83

List of Papers

This thesis is based on the following published papers, which will be referred to in the text by their Roman numerals. The papers are appended at the end of the thesis.

I. Cwikiel W, **Keussen I,** Larsson L, Solvig J, Kullendorff CM. Interventional treatment of children with portal hypertension secondary to portal vein occlusion. *Eur J Pediatr Surg* 2003 Oct;13(5):312–18.

II. **Keussen I,** Song HY, Bajc M, Cwikiel W. Changes in the distribution of hepatic arterial blood flow following tips with uncovered stent and stent-graft: an experimental study. *Cardiovasc Intervent Radiol* 2002 Jul–Aug; 25(4):314–17.

III. **Keussen I,** Bergqvist L, Rissler P, Cwikiel W. Acute effects of liver vein occlusion by stent-graft placed in transjugular intrahepatic portosystemic shunt channel: an experimental study. *Cardiovasc Intervent Radiol* 2006 Jan-Feb;29(1):120–23.

IV. Semiz-Oysu A, **Keussen I,** Cwikiel W. Interventional radiological management of prehepatic obstruction of the splanchnic venous system. *Cardiovasc Intervent Radiol* 2007; Jul–Aug;30(4):688–95.

Papers are reprinted with kind permission from Springer Science and Business Media and Georg Thieme Verlag KG.

Abbreviations

CT	computerized tomography
ePTFE	expandable poly tetra fluoro ethylene
$^{99}Tc^{m}$ –HSA	$^{99}Tc^{m}$ labelled human serum albumin
HE	hepatic encephalopathy
IPVB	intra hepatic portal vein branches
IVC	inferior vena cava
MRA	magnetic resonance angiography
MR/MRI	magnetic resonance/magnetic resonance imaging
PH	portal hypertension
PV	portal vein
PVO	portal vein occlusion
ROI	region of interest
TIPS	transjugular intrahepatic portosystemic shunt
USG	ultrasonography

Introduction

Historical background

The ancient Egyptians had already associated liver disease with ascites which was documented in medical scripts from the middle ages (Henderson). A relationship between cirrhosis, varices and gastrointestinal bleeding was not identified until 1900. Ascites, cirrhosis and elevated portal pressure were linked together with the term portal hypertension, (PH), introduced by two French doctors, Gilbert and Villaret, 1906 (Henderson). At the beginning of the 20th century the "forward flow theory" still existed, assuming that portal hypertension resulted from an enlarged spleen rather than causing it. Different types of surgical treatment have been used for the management of portal hypertension such as shunts, splenectomy, omentopexy and oesophageal transsection. The introduction of the liver transplantation in the 1980's had an even greater impact on the management of portal hypertension (Carithers 2000). Proposed in 1969 by Rösch (Rösch *et al.* 1969), the first transjugular intrahepatic portosystemic shunt, (TIPS) was successfully created in patients at the beginning of the 1990's. Using this less invasive, interventional radiological method, elevated portal pressure could be significantly decreased, with the resulting elimination of symptoms.

Overview of the structure and the function of the liver

The liver is the largest gland in the human body, with a weight of approximately 1500 g in a healthy adult. It is separated into the right and left lobes and further subdivided into segments. The most commonly used anatomical segmental classification was introduced by Couinaud. This classification divides the liver into eight independent segments, each of which has its own vascular supply, outflow and biliary drainage. The main cell type in the liver is the hepatocyte, which contributes to 80% of the liver volume and to 60% of the total cell population (Boyer *et al.* 2006). Most of the functions carried out by the liver, are accomplished by the hepatocytes, which extract and transform substances from the blood and has an exocrine and endocrine secretory function. The remaining cells consist of sinusoidal endothelial cells, perisinusoidal stellate cells and Kuppfer cells. Hepatocytes are organized into plates or laminae and between these plates the hepatic sinusoids are located. A liver sinusoid is a small blood vessel, similar to a capillary, where oxygen-rich blood from the hepatic artery and the nutrient-rich blood from the portal vein are mixed. The sinusoids are highly permeable and are lined with discontinuous endothelium. The fenestrations of up to 2 μm in diameter, allow the passage of most macromolecules. The caliber of the sinusoids can increase more than ten times and is limited by the extracellular room, the space of Disse. The Kuppfer cells, the immunocompetent component of the sinusoid wall, can take up and destroy foreign substances.

The liver has a dual blood supply through the portal and arterial systems, making the normal liver resistant to anoxia. The poorly oxygenated portal blood contributes to about 80% of the total blood supply to the liver. The remaining, approximately 20%, consists of well oxygenated blood from the hepatic artery. The PV gathers blood from the intestine, the pancreas, the spleen, the stomach and the gallbladder with contribution from the superior and inferior mesenteric veins, the splenic and gastric veins. Within the liver, the PV divides into two major branches, to the left and right liver lobe respectively. The portal venous system transports the nutrients from the gastrointestinal tract, as well as hormones, e.g. insulin and glucagon. These substances reach the liver in high concentrations and may be

metabolized here. The sinusoids have a vast cross-sectional area, creating a low transsinusoidal vessel resistance, pressure gradient and flow velocity. In order to cause an increase in portal pressure it has been calculated that 80% of the portal profile must be obliterated (Hulek *et al.* 2001), which is one of the most serious consequences of chronic liver disease. The drainage from the sinusoids is carried out by the hepatic veins. The main hepatic veins enter the inferior vena cava, IVC, just before it passes through the diaphragm.

Portal hypertension; etiology, causes and assessment

At normal pressure the hepatic sinusoids maintain a flow of 1500ml/minute (Boyer *et al.* 2006), which increases after food intake. 5–10 mmHg is defined as normal portal venous pressure and PH is portal venous pressure exceeding 10 mmHg (1.3 kPa). However, these values are relative and depend on the pressure in the central venous circulation. It seems clear that varices do not de-

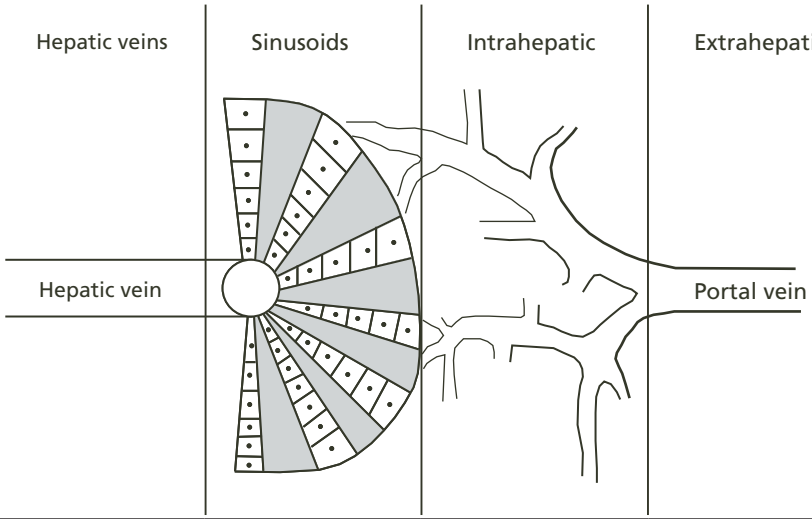

Budd-Chiari syndrome	Cirrhosis	Schistosomiasis	Thrombosis
Veno-occlusive disease	Autoimmune liver disease, Wilson´s disease, sclerosing cholangitis, hemocromatosis, primary liver fibrosis	Congenital hepatic fibrosis	Infection
Stenosis after liver transplant		Primary biliary cirrhosis	Trauma
Right sided heart failure		Sarcoidosis	Coagulation disorder
	Idiopathic origin	Malaria	Malignant disease
			Anastomotic stenosis after liver transplant

Fig 1. Causes and sites of block for portal hypertension.

velop when the porto-systemic pressure gradient is below 10 mmHg and variceal bleeding rarely occurs with a gradient below 12 mmHg (Vorobioff *et al.*1996).

PH is classified into three groups, presinusoidal, sinusoidal and postsinusoidal (Fig 1).

Presinusoidal PH may be either extrahepatic or intrahepatic. The extra- or prehepatic obstruction is usually caused by thrombosis, malignancy, or stenosis following liver transplantation, whereas sepsis and hypercoagulability are less common causes. Among the intrahepatic reasons schistosomiasis, congenital hepatic fibrosis, sarcoidosis, malaria, primary biliary cirrhosis are described. World wide schistosomiasis is the main contributor of PH. In Europe and North America the sinusoidal cause of PH is associated with cirrhosis of the liver in more than 90% of the patients, mostly secondary to alcohol abuse. Other causes of PH are infectious and toxic hepatitis, primary liver fibrosis, hemochromatosis, Wilson's disease, primary biliary cirrhosis and extrahepatic biliary obstruction. The main factor determining the clinical course, management and outcome for patients with PH is the status of the underlying liver disease.

The severity of liver disease is most often classified according to the MELD score and/or the Child-Pugh classification. The MELD (Model for end-stage liver disease) score is determined by three blood tests, bilirubin, prothrombin time (PT) measured as international normalized ratio (INR) and creatinine. The MELD score is calculated using the following equation:

3.8 x log (e) (bilirubin mg/dL) + 11.2 x log (e) (INR) + 9.6 log (e) (creatinine mg/dL)

The score ranges from 6–40, where the lowest number indicates the least ill patient and the highest score the most severe condition. The MELD score is used for evaluation before TIPS, for patients on a transplant list, to gauge the mortality in patients with alcoholic hepatitis and also for assessment of a liver malignancy (Dunn *et al.* 2005;Montgomery *et al.* 2005).

For Child-Pugh classification see table 1.

The most common causes of post hepatic obstruction are Budd-Chiari syndrome, stenosis of liver veins or IVC after liver transplantation, whereas veno-occlusive disease is an even rarer condition. The Budd-Chiari syndrome is an entity of diseases, characterized by a restriction of the hepatic vein outflow, mainly due to thrombotic occlusion of the hepatic veins. In veno-occlusive disease the IVC and liver veins are patent, but non-thrombotic obliteration is seen in the postsinusoidal liver venules, often affecting patients after bone marrow transplantation.

Table 1. Child-Pugh classification: Grade A 5–6 points, Grade B 7–9 points, Grade C 10–15 points

Parameter	1 point	2 points	3 points
Bilirubin (μmol/l)	<34	34–50	>50
Albumin (g/l)	>35	28–35	<28
Protrombin time(s) or INR	<4 <1.7	4–6 1.7–2.3	>6 >2.3
Ascites	None	Slight	Moderate
Encephalopathy	None	Minimal	Advanced

Increased resistance to portal venous flow in PH results in development of porto systemic collaterals and dilatation of the vessels in the splanchnic venous bed. Varices which develop from these collaterals and continue to enlarge carry an increased risk of bleeding. The blood from the splanchnic venous bed, drained directly into the systemic circulation through collaterals, by-passes the functional liver parenchyma. This has several negative consequences such as hormonal and metabolic imbalance, disturbed microbial filter mechanism, deterioration of the clearance of vasoactive substances, producing a hyperkinetic systemic circulation. Splanchnic vascular changes of vasodilatation and hyperemia occur and in parallel there is an increase in plasma volume. A hyperdynamic situation develops including high cardiac output, low total systemic vascular resistance and a low systemic blood pressure (Boyer *et al.* 2006).

Assessment of portal hypertension can be made by different methods. Results of clinical examination, laboratory tests, liver biopsy and radiological assessments contribute to diagnosis. Laboratory tests also give information about coagulopathy, renal and liver function, systemic infection, electrolytes and make assessment possible of the Child-Pugh and MELD scores. It is necessary to exclude occlusion of the portal vein or occlusion of its tributaries and branches, as well as the hepatic veins. The best methods are computerized tomography, CT, and magnetic resonance angiography, MRA, providing information about the anatomy and other associated findings as splenomegaly and developed collaterals. Ultrasonography, (USG), with Doppler is another method for visualisation of the portal and hepatic circulation, including information about presence, direction and character of the blood flow. Quantitative evaluation of flow velocity and flow volume in larger vessels can also be assessed. Contrast enhanced USG may sometimes provide additional information (Ueno *et al.* 2006, Venturi *et al.* 2007). Digital subtraction angiography is a traditional method for visualisation of the PV, either by transvenous or transarterial approach. Invasive methods also include carbon dioxide portography and direct transhepatic or transsplenic portography. Portal venous pressure can be measured by insertion of an end-hole catheter in a wedge position in a peripheral hepatic vein. A small amount of contrast is injected under fluoroscopic control to confirm correct position of the catheter. The measurement is repeated in several veins and the highest pressure is recorded. The pressure in the IVC or in the right atrium is subtracted from the wedged hepatic venous pressure and the difference represents the gradient (Boyer *et al.* 2006). Another method, also available for patients with hepatic vein thrombosis, is the direct transhepatic puncture of the portal veins. Although, most of the portal pressure measurements are obtained during the TIPS procedure.

Portal hypertension; symptoms and treatment

Ascites and encephalopathy are the two clinical manifestations indicating decompensation. In contrast bleeding from varices, hypersplenism and splenomegaly may be indicators of compensated disease and has a worse prognosis (Henderson).

Ascites

Ascites is the result of a shift in the balance between production and resorption of free fluid in the peritoneal space. The fluid, rich in protein, is filtered to the extra cellular space in the sinusoids, but not in a sufficient way when PH is present. Sinusoidal hypertension alone is not enough to create ascites, which also requires plasma volume expansion, sodium retention and the activation of neurohumeral systems amongst others. In cirrhotic patients

about 10% will develop refractory ascites, defined as not responding to high doses of diuretics (Boyer *et al.* 2006). The prognosis for a patient with refractory ascites is poor, about 50% will die within a year.

Hepatic encephalopathy

Hepatic encephalopathy (HE) is a complex neuropsychiatric syndrome that accompanies severe liver disorder or is due to a significant shunting between portal and systemic circulation, thus seen both after placement of a surgical porto-systemic shunt as well as in TIPS creation. Acute HE is associated with fulminate hepatic failure which can result in hepatic coma and death. Chronic HE in PH, is due to insufficient detoxification function of the liver with toxic products by-passing the liver and entering the systemic circulation. The toxins include nitrogenous products from the gut. Clinically chronic HE may be difficult to diagnose and is often reversible. It can be revealed by neuropsychological tests and MR spectroscopy (Grover *et al.* 2006). In the clinically manifest form confusion, agitation and other psychiatric disturbances are present (Hulek *et al.* 2001). Potential factors contributing to post shunt encephalopathy, include loss of prograde portal perfusion and loss of venous hypertension with increased ammonia absorption (Somberg *et al.* 1995).

Hydrothorax and hepatorenal syndrome

Other severe events related to PH are hepatic hydrothorax and heptorenal syndrome. Hepatic hydrothorax is predominantly right-sided and is in the majority of cases seen in patients with end-stage liver disease. Ascites is almost always present and leakage of ascites through the diaphragm has been suggested for the pathogenesis. These patients are potential candidates for liver transplantation (Roussos *et al.* 2007). Heptorenal syndrome is a complication of PH, where renal insuffiency is developed including impaired ability to excrete sodium and water. Vasoconstriction of the renal circulation is seen, followed by reduction of renal blood flow and glomerular filtration rate. Usually sodium retention is the earliest alteration in function and the impaired kidney function usually follows the severity of the hepatic disease (Boyer *et al.* 2006). Spontaneous improvement of renal function after development of hepatorenal syndrome is extremely rare. Patients with this disorder are usually divided into two groups. In the first group the renal insuffiency develops rapidly, within days. The other group has a course of events over several months. The development can be augmented by excessive diuretic therapy and/or nefrotoxic drugs. Sodium retention is associated with fluid retention, causing expansion of extracellular fluid volume and increased amounts of fluids in the interstitial tissue. This leads to oedema, especially in the lower extremity. Abdominal wall hernias may develop; the ascites may increase and sometimes be infected. In the extra renal circulation arterial vasodilatation is seen, which results in reduction of total systemic resistance and arterial hypotension.

Splenomegaly

Splenomegaly is a common finding in a patient with PH, but there is poor correlation between the portal venous pressure and the size of the spleen. Splenomegaly may be associated with hypersplenism. In numerous cases leucopenia, thrombocytopenia and anaemia are present, which can cause clinical problems such as bleeding and infection.

Varices

The portal circulation has an extensive collateral system, which may be activated when an increase in pressure occurs. The ma-

jor sites for collateral pathways are gastro-oesophageal, haemorrhoidal, periumbilical and retroperitoneal. The gastric and oesophageal collaterals cause the major clinical problems and are often revealed at endoscopy at an early stage. Variceal bleeding is a medical emergency, which carries a mortality rate of 30%, where most deaths are found in the group with a Child-Pugh score ≥ 8 points (deFranchis 2005). Re-bleeding in the first 7–10 days after the first bleed is a poor prognostic sign. However, only 30% of patients with cirrhosis have oesophageal varices and only 30% of these will bleed from them (Collini *et al.* 1990). Most haemorrhages occur within two years from diagnosis which is usually made by endoscopy (Boyer *et al.* 2006). Valves are present in the perforating veins of the oesophagus, but they become insufficient in some patients with PH, leading to an increase in variceal size. The oesophageal varices are classified in 4 grades. The low risk varices, grade 1, are small-sized, easy to compress by the endoscope and seldom revert spontaneously. The most severe varices, grade 4, have red spots developed on the surface, have weakened wall and rupture easily (Hulek *et al.* 2001). Similar classification is used for gastric varices. The umbilical vein may open and drain the portal blood towards the abdominal wall creating "caput medusae"– a network of enlarged subcutaneous veins around the umbilicus. Other large venous shunts may be found at other places in the upper abdomen, like spleno-renal shunts, which are occasionally as large as the surgically created shunts (Boyer *et al.* 2006). Another well-known complication from PH is bleeding from rectal, colonic, jejunal and duodenal varices (Vidal *et al.* 2005). Porto systemic venous collaterals can also develop around the stoma from a colostomy or ileostomy. Enlargement of these may result in development of stoma varices, which sometimes require interventional treatment (Nayar *et al.* 2006).

Treatment

Management of PH is based on different types of treatment which include; therapy of the underlying liver disease, pharmacological treatment, balloon tamponade, endoscopic, interventional and surgical procedures. Today the surgical procedures have been replaced to a large extent by TIPS. Termination of alcohol abuse, anitviral and pharmacological therapy including beta-blockers, vasodilatators, vasoconstrictors and somatostatin, may be helpful in the early stages of the disease. Antibiotics are given to prevent bacterial complications and lactulose to prevent HE. Temporary arrest of acute bleeding can be established with a double lumen balloon, Sengstaken tube, which can be left in place for 24 hours. Two different types of endoscopic therapy are available. Sclerotherapy includes use of thrombotic agents, injected directly into the varix or in its proximity, creating fibrosis in the mucosa overlying a varix. Variceal banding is a different approach, where the varix is sucked into an applicator and a strangulating rubber band is applied. Both these methods are used primarily in the treatment of bleeding oesophageal varices but are more difficult to apply in cases of bleeding from gastric varices. Endoscopic ligation has been reported to be superior to combined ligation and sclerotherapy (Saeed *et al.* 1997). Coagulopathy and hepatic failure may also be present, complicating the management of the patient.

For long-term management of PH, surgery was previously a method to be considered in patients not responding to conventional therapy and has been in clinically use since 1940's. These surgical options include portocaval shunts, mesocaval, mesorenal or mesoatrial shunts, gastric devascularisation procedures, oesophageal transaction, distal splenorenal shunts and Rex shunts, in which the superior mesenteric vein is linked to the left portal vein (Bambini *et al.* 2000; Dasgupta *et al.* 2006; Kim *et al.* 2005; Shaked *et*

al. 1991). The incidence of post shunt encephalopathy is unknown but has been reported to be around 10–50% (Rikkers *et al.* 1992). The shunts can be divided into total and selective shunts. The total shunts decompress both the portal and variceal venous system. In contrast the selective shunts only decompress the variceal system, leaving the portal flow unchanged. The incidence of HE after selective shunts was reported significantly lower than after total shunts (Galambos *et al.* 1976). Direct gastric and oesophageal devascularization procedures have almost ceased completely in clinical practise. Bleeding from stoma varices can be treated by embolisation with coils and/or sclerosing agents, after superselective catheterisation, with or without TIPS.

Some patients with intrinsic liver disease can only be treated by liver transplantation, which represents the definite therapy. This revolutionary method has altered the prognosis, especially in patients with severe liver disease (Child-Pugh class C). After experimental studies in the 1950's the first liver transplantation in man was performed 1963. The initial results were poor, but with medical antirejection treatment improvements and better organ preservation the results improved substantially. 5 year survival rate is now close to 80% in patients with non-malignant disease (Björnsson *et al.* 2005). Globally the most common indication is chronic hepatitis C and alcohol cirrhosis. In the Nordic countries the most common reason for transplantation is primary sclerosing cholangitis but the amount of patients with hepatitis C is increasing. The survival rate is lower for patients with previous alcohol liver disease. PVO has previously been considered a contraindication for orthotopic liver transplantation, but in the last 15 years surgical vascular technique has been successfully developed (Yan *et al.* 2003). Thus PVO no longer remains an absolute contraindication for transplantation but represents a higher surgical risk (Shaked *et al.* 1991) and extension of thrombus into the remaining splanchnic vessels can result in grafts failure (Senzolo *et al.* 2006).

TIPS

The TIPS technique was first proposed by Rösch (Rösch *et al.* 1969). A transjugular approach to the portal system was found by an inadvertent puncture, during clinical attempts to enter the biliary system. Rösch realized that patients with severe PH were in a bad condition, were a poor surgical risk and could benefit from a procedure lowering the portal pressure. TIPS in dogs, in the initial experiments, had short patency, since the parenchymal tract recoiled almost immediately, closing the connection between the portal and systemic circulation. The introduction of modern angioplasty catheters in 1970's made it possible to improve the patency, but even so the results were not convincing in the beginning.

In 1982 the first clinical TIPS was performed by Colapinto (Colapinto *et al.* 1982). A shunt was created using a 9 mm balloon inflated for 12 hours, which accomplished considerable decrease in the portal pressure. The long term results were, however, still not satisfactory. The use of metallic stents stabilizing the TIPS channel, improved the long term patency of the shunt. Palmaz reported in 1985 that TIPS created with balloon expandable stents in dogs with PH, had prolonged patency in comparison to previous experiments (Palmaz *et al.* 1985). At autopsy the stents were covered by a thin layer of pseudointima, 1.0–1.5 mm thick and completely endothelialised. In 1988 Richter performed the first clinical TIPS with stents, reported in 1990 (Richter *et al.* 1990). They created a shunt, dilated to 9 mm diameter and stabilized with two Palmaz stents placed coaxially. The patient's portal pressure decreased from 38 to 18 mm Hg and the clinical condition improved significantly. The technique was thereafter refined, adopted by interventional radiologists and documented in large studies.

Indications and contraindications for TIPS

The main indication for a TIPS shunt is bleeding, which is uncontrolled by pharmacological and/or endoscopic therapy. TIPS can be performed in both an emergency situation, as well as in an elective procedure in patients with repeated bleeding episodes (Boyer *et al.* 2005;Bilbao *et al.* 2002). The criteria and definitions regarding bleeding episodes are stated in the Baveno IV consensus workshop (deFranchis 2005).

All indications and contraindications are summarized in Table 2 and 3 (Boyer *et al.* 2005).

Since every TIPS procedure is assessed due the patient's clinical status, a malignant or cystic liver disease may not be a contraindication in an emergency situation.

Preprocedural assessments

The portal venous anatomy should be evaluated either by CT or MRA. These modalities will also reveal large collaterals, splenomegaly, ascites, size, structure and possible focal lesions of the liver. Any venous disturbances, as well as spatial abnormalities, will be exposed. USG with Doppler and possible contrast enhancement, verifies patency of the portal vein and may add information about the collaterals and of the flow directions and velocities. Laboratory tests give information about coagulopathy, renal and liver function, systemic infection, electrolytes and make assessments possible of the Child-Pugh and MELD scores. If applicable, improvement of the patient's clinical status is accomplished, such as correction of pathological coagulation and/or electrolyte status, drainage of ascites and/or hepatic pleural effusion (Roussos *et al.* 2007). Prophylactic broad spectrum antibiotics are given on the day of the procedure and continued for at least two more days. Favourable prognostic factors for TIPS are age less than 60 years, female gender, preserved liver function (Bilirubin < 50 micromol/ l), absence of chronic HE, preserved renal function and serum sodium (>125 mmol/l) (Hulek *et al.* 2001). Montgomery *et al.* have reported that elective patients with MELD score > 24 should not be endorsed for TIPS procedures (Montgomery *et al.* 2005).

Table 2. Indications for TIPS placement

Efficacy determined by controlled trials
- –Secondary prevention variceal bleeding
- –Refractory cirrhotic ascites

Efficacy assessed in uncontrolled series
- –Refractory acutely bleeding varices
- –Bleeding gastric varices
- –Portal hypertensive gastropathy
- –Gastric antral vascular ectasia
- –Refractory hepatic hydrothorax
- –Heptorenal syndrome (Type 1 or type 2)
- –Budd-Chiari syndrome
- –Veno-occlusive disease
- –Hepatopulmonary syndrome

Table 3. Contraindications to TIPS placement

Absolute
- –Primary prevention of variceal bleeding
- –Congestive heart failure
- –Multiple hepatic cysts
- –Uncontrolled systemic infection or sepsis
- –Unrelieved biliary obstruction
- –Severe pulmonary hypertension

Relative
- –Hepatoma, especially if central
- –Obstruction of all hepatic veins
- –Portal vein thrombosis
- –Severe coagulapathy (INR >5)
- –Thrombocytopenia (<20,000/cm3)
- –Moderate pulmonary hypertension

TIPS technique

The TIPS procedure is performed with the patient in full anaesthesia, but may be done under conscious sedation with local anaesthesia. Access to the internal jugular vein, on either the right or left side, is established through visualisation of the vein in the neck by ultrasound. After administration of local aesthetic, vein puncture is performed and a guide-wire and a catheter are inserted into the superior vena cava, passing the right atrium into the IVC. An angulated catheter is used to enter a hepatic vein, usually the right, and the tip is advanced distally. The correct position is verified with contrast injection and thereafter a 10 Fr sheath is advanced over a stiff guide wire. Subsequently, access to the PV is established from the hepatic vein. Since the viscosity of the carbon dioxide is 400 times lower than that of liquid contrast media, the gas, injected through the catheter in wedged position in the hepatic vein, can pass the sinusoids in an amount large enough to visualize the portal venous tree. This can provide necessary information for successful puncture, thus reduce the risk of complications. The access may be performed either by blind puncture, based on anatomical information from CT or MRI, or on previous carbon dioxide portography. Puncture can also be facilitated by simultaneously performed USG. After the puncture contrast injection confirms correct position in the PV. An optimal parenchymal tract should be created within 1 cm from the confluence of the hepatic vein and the IVC, entering a right portal vein branch 1–2 cm peripherally to the portal bifurcation. Measurements of the pressure in the right atrium, hepatic vein and in the PV are recorded. The highest resistance to the dilatation of the channel is found in the entrances of the hepatic and portal veins. The shunt device, a stent or a stent-graft (8–10 mm) is chosen, according to the patient's clinical state, porto- systemic pressure gradient, age, existing HE and indication. The stent-graft should cover the entire intrahepatic tract and the hepatic vein, to minimize the risk of stenosis. The placement is confirmed by contrast injection and any irregularity in the shunt can be corrected by balloon dilatation. Following repeated pressure measurements and portography, the procedure is terminated.

Stent and stent-graft selection

The initial trials with stents to maintain patency in a TIPS were performed with balloon expandable metallic stents. This type of stent is a stainless steal tube, expanding to the desired size determined by the size of the inflated balloon. The final stent diameter can be chosen according to the porto-systemic gradient. A Wallstent, a self-expanding bare stent, was and probably still is, the most commonly used stent for TIPS creation. It is also made of stainless steal, has great flexibility, but undesired shortening may create problems with accurate placement. Also dacron-covered Wallstents, Wallgrafts have been used, but with poor results (Haskal *et al.* 1999). Self-expanding nitinol stents have also been used, but more seldom due to difficulties with removal in the case of liver transplantation (Clavien *et al.* 1998) and possible fracture of the stent (Robertson *et al.* 2007). Since 2000 a self-expanding stent-graft, especially designed for TIPS, Viatorr, has been in commercial use (Rose *et al.* 2001). This stent-graft, has a nitinol stent skeleton and is covered by polytetrafluoroethylene,(PTFE) graft. This device has two different functional segments. The cranial, main portion, consists of the graft-lined segment (4, 5, 6, 7 or 8 cm), outlining the intrahepatic tract, extending into the hepatic vein up to the IVC. The minor part of the stent-graft is bare, two cm long and is positioned in the PV. A circumferential radio opaque gold marker indicates the beginning of the graft covered portion of the stent. An additional gold marker is located in the graft



Fig 2. Viatorr stent-grafts.

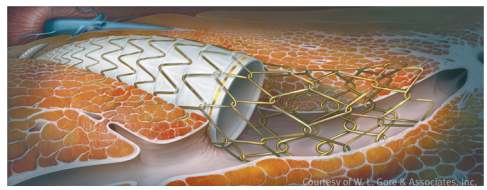

Fig 3. Bare part in the portal vein.

covered cephalic end. The Viatorr is available in diameter of 8, 10 or 12 mm.

This stent-graft has no foreshortening and the correct length of the device can be easily chosen. If a bare stent is used for TIPS, the flow from the hepatic vein into the IVC is unhindered but if a stent-graft is used, the outflow from the hepatic vein is blocked. The effects of such an occlusion were not known. Therefore use of a stent-graft could be contraindicated in a patient with already deteriorated liver function. Study of this problem was the aim of our animal experiments.

Complications of TIPS procedures

Complications can be divided into procedural and post procedural. Bleeding is the most serious of the major complications but occurs in less than 2%, with a procedural and post procedural mortality rate of 1 and 3% respectively, reported in the early days of TIPS procedures (Rössle *et al.* 1996). Haemorrhage may occur from perforation of the liver capsule, from the puncture site outside the liver and rarely from perforation of the right atrium (Terrrini *et al.* 2007). Multi organ failure, ARDS (adult respiratory distress syndrome), severe sepsis, renal or hepatic failure are reported, with a higher incidence in unfavourable MELD or Child-Pugh scores. Minor complications include small intraperitoneal haemorrhage, puncture of bile ducts, arteries, gallbladder or right kidney. Also transient decrease in liver function, sepsis, haemolysis, pancreatitis and encephalopathy are described. Thrombosis of the TIPS usually occurs early and can happen within 24 hours of TIPS creation (Boyer *et al.* 2005). Use of anticoagulation has not improved long-term patency of the shunt (Shiffman 1996).

The most frequent post procedural complications are shunt dysfunction and HE. Shunt dysfunction may be secondary to pseudointimal hyperplasia, which consists of formation of connective tissue, mesenchymal cells, endothelial cells and fibroblasts. Macrophages may also be present (Haskal *et al.* 1999). This results in stenosis of the channel, with recurrence of PH and thereby related symptoms,

and the complication has been a limiting factor for the use of bare stents in TIPS. The frequency is reported to vary from 18–78% and the shunt dysfunction should be reduced by the use of covered stents (Boyer *et al.* 2005). Another limiting factor for long time patency is the true intimal hyperplasia in the drained hepatic vein, creating stenosis, which requires reintervention. In the intimal hyperplasia proliferation of endothelial cells is seen. This problem is mostly observed in TIPS created with bare stents. Dilatation with a balloon catheter is the first treatment option. In cases of persistent stenosis, additional stent placement is performed.

Longterm results

TIPS and endoscopic treatment have been compared in several studies, demonstrating a significant reduction of re-bleedings with TIPS, to the price of more HE without any improvement on survival rates (Papatheodoridis *et al.* 1999;Burroughs *et al.* 2002). The same results were found for surgical shunts. More recent studies conclude, however, that TIPS is more effective and show a tendency to improve survival rates (Rössle *et al.* 2004).

The permanent shunting of portal blood away from the liver may increase the risks of liver failure and HE. The initial TIPS created with bare stents, had a high failure rate due to shunt dysfunction, which required repeated radiological interventions. Since the introduction of Viatorr, the pseudointimal hyperplasia formation has been reduced (Rössle *et al.* 2006), reported also in a randomized study (Bureau *et al.* 2007). In a long-term retrospective study (Rössle *et al.* 2006) the shunt patency in 100 patients implanted with Viatorr, was evaluated and the two year patency rate was reported to be 74–76 %. The chosen diameter for the stent-graft can thereby be smaller, which reduces the incidence of HE. HE is a serious complication, where the reports on frequency have been conflicting in the literature. Somberg *et al.* report rates of 10-50% of all TIPS procedures (Somberg *et al.*1995). De novo or deterioration of a preexisting HE is seen in 20–41% of cases (Huoncker *et al.* 1999; Somberg *et al.*1995). Studies have demonstrated an increase in HE after TIPS, when pressure gradient < 12 mm Hg. It has therefore been suggested that the aim of the individual reduction should be about 40–50% of the baseline (Rössle *et al.* 2001). If liver function or HE deteriorates progressively an arterio-portal fistula should be excluded. It results in reduced arterial blood supply, which may place the patient in a critical situation. An immediate occlusion or shunt reduction is necessary. Directly after the shunt is opened the systemic pressure and the cardiac output increase about 30% accompanied by a further reduction in the low vascular resistance. These changes return towards baseline levels after a few hours, with a 10% residual change (Huoncker *et al.* 1999).

The development or worsening of preexcisting HE has been described in 20–31% (Somberg *et al.* 1995). Unfavourable factors for the development of HE include high age, advanced liver disease, previous encephalopathy and large shunt diameter. “De novo” encephalopathy after TIPS placement is most likely to respond to treatment with lactulose and/or neomycin. If the patient develops refractory HE, either the TIPS diameter can be reduced or the shunt can be occluded, in order to improve the symptoms. The incidence of HE after surgical procedures has been reported to range from 20–50%, usually with lower frequency in small-diameter shunts and in with Child-Pugh A and B patients (Somberg *et al.* 1995).

Another possible disadvantage of TIPS may be circulatory disturbances in the liver, not to neglect since these patients already have an impaired liver function. A stent-graft used in a TIPS blocks the drainage from the liver vein into the IVC and circulatory effects have been noted (Bureau *et al.* 2002; Walser *et al.*

2000). This has not been fully investigated and was the focus of our experimental studies (Paper II and III).

TIPS in children

Even if TIPS procedures in adults are relatively common, the experiences of TIPS in children are limited. The technical success rate is lower than in adults, 75–90% vs 95% in adults (Fasulakis *et al.* 2006). The smaller size of the venous structures, the smaller liver and the presence of anatomical variants are limiting factors in paediatric cases. The small amounts of contrast medium which can be used, can also be a limiting factor. Modification of the usual technique in TIPS may be needed in children for technical success.

Recanalisation of splanchnic veins

Portal vein occlusion, PVO, is a rare condition, which predominantly occurs in cirrhotic patients (Van Ha *et al.* 2006) and may be secondary to hypercoagulapathy, inflammatory processes, malignancies and mechanical manipulation of the PV (Vivas *et al.* 2000). PVO can be intra- or extra hepatic and acute or chronic. Anatomically PVO can be classified into categories depending on how much of the vein and its tributaries that are involved, which may have a prognostic relevance. Patients with thrombus involvement of the mesenteric vasculature carry a higher risk of bowel infarction and a lower risk of variceal bleeding, than those with isolated PVO (Webster *et al.* 2005). Symptoms may be diffuse and should be considered in patients with unspecific abdominal pain, in cases of deterioration in patients with known liver disease or if signs of PH are present in patients without simultaneous liver disease. In children the most common cause is infection, mostly originating from umbilical vein catheterisation. PVO may be associated with growth retardation in children (Bellomo-Brandão *et al.* 2003). In the chronic form porto-portal or porto-systemic collaterals are developed and/or cavernous transformation (periportal collaterals) can be detected. The first symptom may be gastrointestinal bleeding but in many cases very few symptoms are present or may be absent altogether. In some patients, abdominal pain, fever, nausea and signs of mechanical bowel obstruction or ascites are found. Benign stenosis of the PV is a known complication of liver transplantation and is commonly found at the site of the anastomosis. Spontaneous recanalisation of PVO, is very rare and treatment options for symptomatic patients are pharmacological therapy, splenectomy and surgical shunts. Endoscopic treatment may be useful in patients with variceal bleeding. Benign stenosis are in most cases, responding to balloon dilatation.

Surgical shunting has previously been indicated in rare cases, where bleeding cannot be controlled by medical means, although earlier reports suggested high mortality and morbidity rates (Webb *et al.* 1979). In children the surgical complications include HE, rebleeding, shunt occlusion and technical difficulties due to small vessel size (Senyüz *et al.* 2001). The selection of shunting procedures for PVO, total or selective, has been a matter of debate (Mosiman *et al.* 1990). It has been suggested that children with PVO may have subtle deficiencies in liver function and that chronic diversion of portal flow from the liver may lead to progressive liver dysfunction (Bambini *et al.* 2000). The distal splenorenal shunt (Warren shunt) has been advocated for the treatment of children with severe hypersplenism secondary to the PVO. Restoration of portal flow to the liver by bypassing the PVO, normalizes the portal venous pressure and successfully decompresses the spleen which inhibits consumption of platelets and leucocytes (Shilyanski *et al.* 1999). In patients with patent IPVB the Rex shunt restores normal hepatopetal physiological flow, prevents

HE and has been used for patients with extra hepatic PH. This shunt uses an autologous vein graft, classically the left internal jugular vein, and extends from the mesenteric vein to the left branch of the portal vein (Bambini *et al.* 2000). The Rex shunt was originally reported as a method of treating PV thrombosis after liver transplantation (Audet *et al.* 2002). Late shunt stenosis and technical difficulties in patients with liver transplants have been reported after Rex shunt surgery (Bambini *et al.* 2000). Reconstructive surgery may be technically challenging or impossible due to non-availability of suitable vessels. Longstanding PVO may cause liver cirrhosis and if the IPVB are occluded transplantation of the liver is the necessary treatment. However, vein-grafts used for liver transplantation has limited long-term patency (Sugawara *et al.* 2006). The incidence of PV thrombosis in patients being considered for transplantation varies between 5 and 15%. The most widely used techniques are surgical thrombectomy and shunting with a venous graft. Portal thrombosis recurrence rates may be as high as 30% (Charco *et al.* 2005). PVO is not an absolute contraindication for liver transplantation but extension of thrombus into the remaining splanchnic vessels can severely reduce the inflow from the splanchnic veins and result in a graft failure (Shaked *et al.* 1991).

Development of interventional radiological tools and methods made attempts possible to recanalise occluded veins. Interventional treatment of PVO was previously reported only in few cases. Paper I and table7 summarizes results of treatment of patients with PVO.

Aims

The purpose of this thesis was to evaluate interventional treatment in patients with portal hypertension and occlusion of the portal vein and further to evaluate if stent-graft used for TIPS had any negative effects on hepatic circulation.

The specific aims were:

- To evaluate possibilities for interventional treatment in children with portal vein occlusion (Paper I).
- To evaluate if changes in hepatic circulation, following placement of stent-grafts used for TIPS, which occlude the hepatic vein, had negative consequences for the liver circulation (Paper II and III).
- To evaluate results of interventional treatment in patients with portal hypertension and occlusion of the splanchnic veins (Paper IV).

Material and Methods

Experimental studies

Paper II and III report results of experimental studies. Possible negative effects of hepatic vein occlusion by the stent-graft were evaluated with interventional, scintigraphic, radiopharmaceutical and histopathological methods. All experiments were performed after approval by the Animal Ethics Committee of Lund University.

Animals

14 healthy, domestic pigs were used in the experiments. In the first study (paper II) their body weight were approximately 20 kg and in the second study (paper III) approximately 36–40 kg. In the second study the animals were transferred to and kept in the animal care facilities for two weeks, when the second part of the experiments were performed. All animals were fed with regular food without any dietary restrictions. All procedures were performed under general anaesthesia, induced by intramuscular injection of 2 mg/kg azaperone (Stresnil Vet, Leo, Helsingborg, Sweden) followed by intravenous injection of 2–4 ml thiopenthal 5% solution (Sodium Pentothal, Abbott Laboratories, N.Chicago, IL, USA). After intubation, anaesthesia was maintained by artificial ventilation with a mixture of oxygen and nitric oxide and continuous infusion of ketamin-hydrocloride (Ketalar, Parke-Davis, Solna, Sweden) 1 mg/min and midazolam (Dormicum, Roche, Stockholm, Sweden) 5 mg/hour. At the end of the experiments, all animals were sacrificed by an intracardial injection of an overdose of potassium.

Interventional methods

All procedures were performed in experimental animal facilities. The diagnostic, interventional and TIPS procedures were performed on the angiography table (paper II and III) and the pigs were transported to the gamma camera for the scintigraphic examinations (paper II). After surgical cut-down, the left jugular vein was catheterized. A 5 Fr Cobra catheter was inserted into the superior vena cava and advanced via the IVC into the right hepatic vein. Contrast injection verified correct position in a peripheral branch and the tip of the catheter was used as a target for the percutaneous puncture to follow. The puncture, performed with a 0.9 mm needle, was replaced over a 0.018 inch guide wire, to a 5 Fr cannula. Free outflow from the right hepatic vein was checked by contrast injection. The technique for creating a TIPS was similar in both studies and identical to the technique in humans (Richter *et al.* 1990). For transhepatic PV access, the PV was punctured blindly, from the right hepatic vein.

Paper II

Through a cut-down, a 7 Fr introducer sheath was placed in the right femoral artery. Using angiographic technique a 4 Fr catheter was advanced into the gastroduodenal artery, which was embolised with pieces of Gelfoam and thereby excluded from any involvement in the assessment. The tip of the catheter was thereafter placed in the common hepatic artery. Information about the anatomy was obtained by hepatic angiography. Scintigrapic examination followed by injection of $^{99}Tc^{m}$ labelled human serum albumin ($^{99}Tc^{m}$ –HSA) through the catheter remaining in the common hepatic artery. For a pilot study performed in one pig, a 10 mm occlusion balloon catheter, inserted by a transjugular route, into the right hepatic vein was used. Scintigraphic examinations were performed with an inflated respectively non-inflated balloon, to determine if possible changes in the arterial supply to the liver were measurable.

Following transhepatic puncture, predilatation of the TIPS channel was performed with an 8 mm balloon, followed by insertion of an 8x40 mm stent. A new $^{99}Tc^{m}$ –HSA injection was performed, after the post TIPS portography. Subsequently a 12x40 mm stent-graft was inserted in the cranial part of the shunt and dilated with a 10 mm balloon. (Fig 4) The hepatic vein occlusion was confirmed by contrast injection through the transhepatic cannula (Fig 5). Repetition of the scintigraphic examination was performed.

Scintigraphic methods

In our study we used $^{99}Tc^{m}$ labelled human serum albumin ($^{99}Tc^{m}$ –HSA) (Mallinckrodt Medical B.V., Petten, Holland), a substance frequently used for circulation and blood flow studies (Goins *et al.* 1996;Mallinckrodt 1995). Changes in the arterial blood flow were evaluated with scintigraphic methods. Before TIPS was created, 40 MBq of $^{99}Tc^{m}$ –HSA was injected in the common hepatic artery. For the second (after stent placement) and third (after stent-graft placement) assessments, the injected isotope doses were

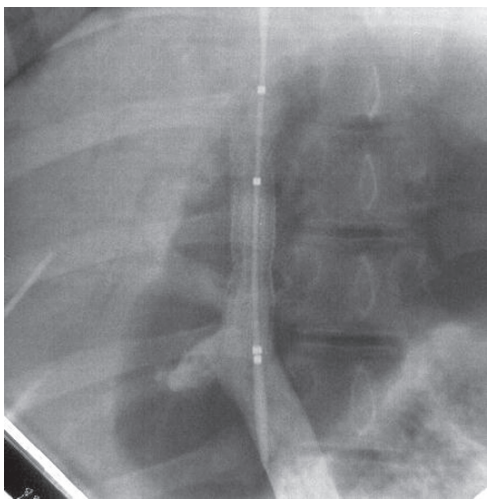

Fig 4. Blood flow through the TIPS channel.

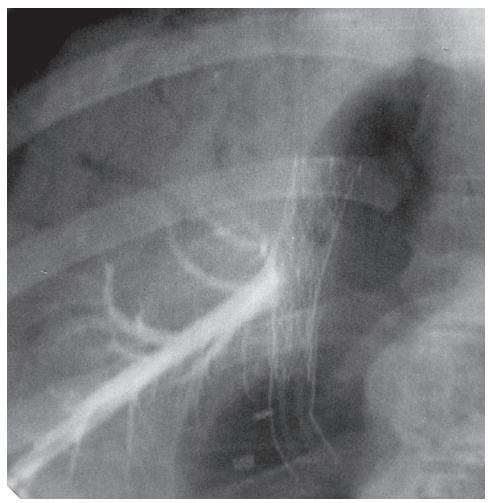

Fig 5. Percutaneous contrast injection in the right hepatic vein. Outflow is blocked by the stent-graft.

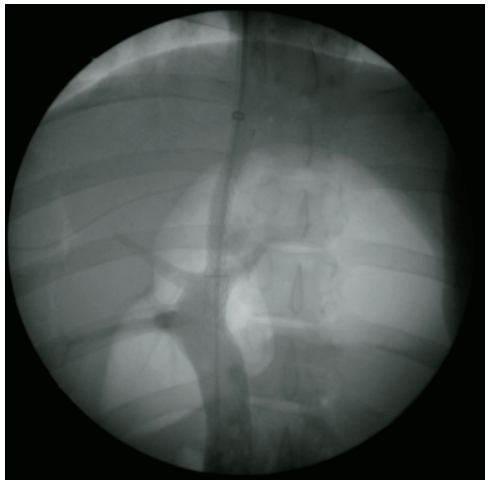

Fig 6. Portography after TIPS shows blood flow through the channel.

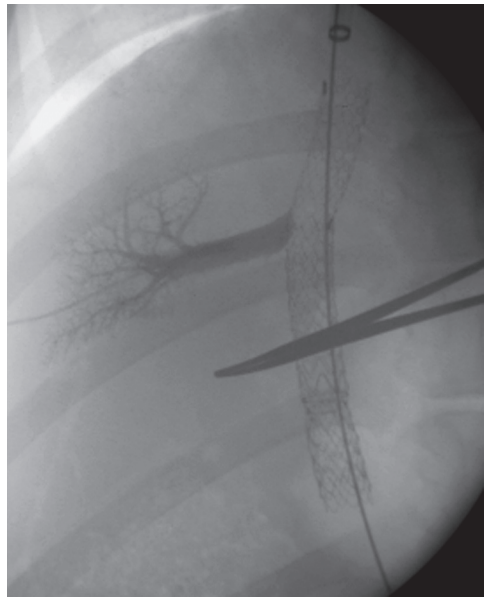

Fig 7. Percutaneous contrast injection shows blockage of the outflow from the hepatic vein by the Viatorr.

increased three-fold to 120 and 360 MBq of $^{99}Tc^{m}$ –HSA, in order to minimize the necessary background subtraction. With the pig in supine position planar static images were obtained in anterior and posterior projections with a double head camera. The background activity was subtracted in anterior and posterior scans immediately before the second and third studies. A region of interest, ROI, was defined for each pig, to be the region of the liver drained by the right liver vein, which was blocked by the stent-graft. The ROI was determined according to the angiographic and venographic examinations, obtained before creation of TIPS. Due to anatomic variations the ROI was somewhat different for each pig. This area was used for measurements of the changes in the arterial blood flow, assessed by scintigraphy. For statistical evaluation of the results, Friedman´s test was used for comparing the activities before TIPS, after stent and after stent-graft placement, respectively. Provided an overall significant difference was detected, Wilcoxon's signed-rank test was used for further comparisons.

Paper III

After transjugular insertion of a catheter in the right hepatic vein, a percutaneous transhepatic puncture of this vein was performed. A subcutaneous reservoir, a port-a cath, was implanted subcutaneously, lateral to the liver, with the tip positioned in the right hepatic vein, approximately five mm from the confluence into the IVC. This reservoir was intended to be used for repeated radionuclide injections for the entire study. An access to the portal system was then created, using the previously described technique, by a transjugular route. Subsequently the radionuclide was injected through the port-a-cath, into the right hepatic vein. Blood samples were obtained after 1, 3, 5 and 10 minutes from a peripheral vein in the left ear. Then TIPS was created with a 10x40 mm stent-graft (Viatorr,

Endoprotesis, GORE®, Flagstaff, AZ, USA) and dilated with a 10x40 mm balloon after the placement. Portography confirmed free flow through the shunt (Fig 6). Contrast injection through the port-a-cath verified occlusion of the outflow from the hepatic vein by the stent-graft (Fig 7). Injection of radionuclide in the occluded hepatic vein through the port-a-cath was performed, followed by peripheral blood samplings at the intervals described above.

Repeated study was implemented after two weeks. Unfortunately all the port-a-caths had dislodged from their locations in the hepatic veins and were found in the peritoneal space. Therefore transhepatic puncture of the right hepatic vein was performed under fluoroscopic control, towards the cephalic portion of the stent-graft. Contrast injection demonstrated the correct position of the needle tip in the vein. The $^{99}Tc^{m}$–HSA was injected in the hepatic vein and sampled from a peripheral vein at the same intervals, 1, 3, 5 and 10 minutes after the injection.

Radiopharmaceutical methods

In our study we used Techne Scan® HSA (Mallinckrodt Medical B.V., Petten, Holland) which was labelled with $^{99}Tc^{m}$ according to the manufacturer's instructions (Mallinckrodt). After 15 minutes incubation time the preparation was ready for use. The amount of free pertechnetate varied between 0.04% and 0.45% (mean 0.25%). Blood samples were weighed and measured for activity in a gamma counter. The percentage of the injected radioactivity leakage to the peripheral blood was calculated, assuming that the blood volume of the pig consisted of 8% of the total body weight.

Histological methods

After the animals were killed, the livers were removed en bloc and three different specimens from each of the livers were sent for histopathological examination. One sample was obtained from the part of the right liver lobe drained by the occluded liver vein, one sample from the left liver lobe and the third sample was including the stent-graft. The tissues were fixed in 10% natural buffer formalin and embedded in paraffin. Slides were prepared and stained with hematoxylin and eosin according to the standard protocols.

Clinical studies

Paper I

Patients

Five children, 8–14 years old, four boys and one girl, were treated. All children had symptoms from PH, due to PVO. In three of the children, the PVO was caused by neonatal catheterization of the umbilical vein. In the remaining two children infection and coagulation disorder were the reasons. All children had 1–5 bleeding episodes from oesophageal varices. Thrombocytopenia, with platelet counts of 24–53 secondary to splenomegaly, was also seen in all children. Two of the children required repeated endoscopic sclerotherapy, whereas the other three only received pharmacological treatment.

Methods

All children were examined before the interventional procedures with Doppler USG and CT or MRI. All the patients were treated in the angiography suite under general anaesthesia. Blood pressure in the systemic and portal circulation was checked repeatedly. Recanalisation of the occluded part of the PV was intended in all patients. In one child, the recanalisation was performed three months after partial embolisation of the spleen for safety reasons. This child's parents banned possible blood transfusion for religious reasons. Partial embolisation of the spleen was performed in four children. In these children a selective angiography of the splenic artery

was performed to obtain anatomic information and to plan the embolisation. A 5 Fr Cobra catheter was thereafter inserted into the splenic artery from a femoral approach, followed by super selective catheterisation of the intrasplenic branches with a 3 Fr co-axial microcatheter. The embolisation of the 50–70% caudal portion of the spleen was intended. A mixture of polyvinyl alcohol particles 250–355 µm, 1 g benzylpenicillin, 80 mg garamycin, 5 ml NaCl solution and 10 ml contrast medium (Omnipaque 300 mg I/ml) was used for the embolisation. Under fluoroscopic control the mixture was injected until the flow ceased in the embolised branches. The result was checked directly after embolisation with contrast injection and with CT of the upper abdomen after 3–7 days. The IPVB were punctured by common TIPS technique (Richer *et al.* 1990), either from the right or the middle hepatic vein, by paediatric or adult TIPS set. Percutaneous transhepatic puncture of the IPVB was achieved with a 15 cm long 0.9 mm needle. Puncture was performed under biplane fluoroscopy with the needle slowly withdrawn under simultaneous, gentle injection of contrast medium, until the tip was in the IPVB. The needle was thereafter replaced over a 0.018 Cope mandrill wire (William Cook, Europe, Bjaeverskov, Denmark), by a 5 Fr catheter and portography was accomplished by contrast injection. Transsplenic puncture was always performed after arterial splenic embolisation, below the costal arch in order to minimize the movements of the needle due to respiration. If necessary the access to the splenic or portal vein was reinforced by a 5 or 7 Fr introducer sheath. Recanalisation of occluded PV was attempted using glide wires and different angiographic catheters. Palmaz stents, Jomed stent graft and a Wallstent were used for stabilization of the recanalised segment and the TIPS channel. After the interventional treatment the patients were observed in the intensive care unit for 24 hours, before they were transferred to the ward. Regular check-ups with repeated laboratory tests, clinical examination and USG examination were scheduled every three months during the first year, thereafter once a year. One boy received a TIPS, was additionally set up for shunt phlebography after six and twelve months.

Paper IV

In paper IV, interventional radiological treatment in 24 patients was evaluated retrospectively.

Patients

All patients had symptomatic PH secondary to occlusion of the splanchnic veins. There were 9 females and 15 males, from 9 months to 79 years old (mean 36. 4 years). The diagnoses were based on USG, CT or MRI examinations. The symptoms and signs are stated in Table 4. Symptoms included gastrointestinal bleeding ($n=15$), intraperitoneal bleeding ($n=1$), abdominal pain, nausea, and/or vomiting ($n=9$) and jaundice secondary to biliary compression by portal collaterals ($n=1$). At the time of referral for treatment thrombocytopenia ($n=14$), splenomegaly ($n=12$), refractory ascites ($n=4$) and encephalopathy ($n=4$) also were present.

Methods

The procedures were performed under general anaesthesia ($n=14$) or local anaesthesia with systemic sedation ($n=10$). Vital signs such as heart rate, blood pressure and oxygen saturation were monitored during the interventions. Venograms were performed by injection of ionated contrast medium or carbon dioxide. Due to the preprocedural findings on USG, CT, or MRI, percutaneous transhepatic, transsplenic and/or transjugular access to the portal circulation was obtained according to the technique described earlier (paper I). Thrombolysis was performed by an infusion catheter positioned through the PV obstruc-

tion from the transjugular access. Tissue plasminogen activator was used at a rate of 1 mg/hour for 24 hours. Two different mechanical trombectomy devices, Amplatz Thrombectomy Device (Microvena, White Bear Lake, MN, USA) or Arrow-Trerotola percutaneous thrombolytic device (Arrow International Inc., Reading, PA, USA) were used, inserted through the transhepatic or transjugular portal venous sheath. Hydrophilic guide wires and angiographic catheters were used to pass the venous occlusions. The used stents and stent-grafts are summarized in Table 5. When a transsplenic or transhepatic route was used the tract was embolised with coils and/or gelatine sponge. A partial splenic embolisation was accomplished to decrease inflow of blood to the portal system and/or decrease symptoms secondary to hypersplenism as described previously (paper I). If TIPS was necessary, modified technique was used according to the location and extension of the PVO. In several patients the puncture of the PV from the hepatic veins was performed towards the percutaneously inserted catheters, used as a target. All patients were kept in the intensive care unit for minimum of 24 hours after the procedures. Patients treated with TIPS or recanalisations were followed-up according to the routine at the institution where the intervention was performed. Additional information was obtained from records from medical journals, laboratory data and imaging studies. Patients without active bleeding, treated with stents or stent-grafts, received antiplatelet medication for six weeks.

Table 4. Clinical presentation, cause and site of splanchnic venous obstruction.

Number	Age	Sex	Symptoms and signs	Cause	Site
1	59	F	GIB	Chronic thrombosis	Main PV + Intrahepatic PVs
2	64	F	Refractory ascites, GIS	Tumor encasement	Main PV (partial) + SMV
3	34	M	GIB+ GIS	Chronic thrombosis	Main PV + mesenteric veins
4	62	M	GIS	Acute thrombosis	Main PV
5	54	M	GIB	Acute + chronic thrombosis	Main PV
6	79	M	GIB, encephalopathy, thrombocytopenia	Chronic thrombosis	Main PV
7	43	M	GIB, splenomegaly, thrombocytopenia	Chronic thrombosis	Main PV
8	45	M	GIS, encephalopathy, thrombocytopenia	Chronic thrombosis	Main PV + Occluded TIPS
9	41	F	GIB	Chronic thrombosis	Main PV + Intrahepatic PVs
10	65	M	Intraperitoneal bleeding, ascites, encephalopathy, thrombocytopenia	Acute + chronic thrombosis	Main PV + Intrahepatic PVs
11	35	M	Ascites, GIS, splenomegaly, bleeding from PTC tube	External compression by biliary Wallstents	Main PV
12	39	M	GIB, abdominal pain, thrombocytopenia	Chronic thrombosis	Main PV + SV + SMV

13	23	M	GIB, splenomegaly, thrombocytopenia, GIS	Chronic thrombosis	Main PV + Intrahepatic PVs
14	49	F	Ascites, splenomegaly, thrombocytopenia, TIPS occlusion	Chronic thrombosis	Main PV + Occluded TIPS
15	48	F	Huge varices, thrombocytopenia	Chronic thrombosis	Main PV + Intrahepatic PVs
16	4	F	Splenomegaly, enlarged abdominal sc veins	Chronic thrombosis	Intrahepatic PVs
17	0.75	F	GIB	Chronic thrombosis	Intrahepatic PVs
18	8	M	GIB, splenomegaly, thrombocytopenia	Chronic thrombosis	Main PV
19	12	F	GIB, splenomegaly, thrombocytopenia	Chronic thrombosis	Main PV+ SV
20	16	M	GIB, splenomegaly, thrombocytopenia	Chronic thrombosis	Main PV+ SV
21	13	M	GIB, GIS, splenomegaly, thrombocytopenia	Chronic thrombosis	Main PV + Intrahepatic PVs
22	14	M	GIB, splenomegaly, thrombocytopenia	Chronic thrombosis	Main PV
23	24	F	GIS, jaundice, splenomegaly	Chronic thrombosis	Main PV
24	43	M	GIB, encephalopathy, thrombocytopenia, splenomegaly	Acute + chronic thrombosis	Main PV + SMV + SV

GIB: Gastrointestinal bleeding, GIS: Gastrointestinal symptoms, PV: Portal vein,
SMV: Superior mesenteric vein, SV: splenic vein, TIPS: Transjugular intrahepatic portosystemic shunt

Table 5: Interventions performed and outcome of patients with splanchnic venous obstruction.

Number	Access	Embolization	Recanalization	TIPS	Gradient before (mmHg)	Gradient after (mmHg)	Interval (months)	Improvement
1	TJ	-	One 10x94 mm WS, one 25 mm Palmaz stent	Yes	13	4	0.25*	No
2	TJ	-	Two 12x40 mm SMART stents	No	20	5	12	Yes
3	TH	-	Two 10x40 Jomed stent-grafts	No	52	18	2*	Yes
4	TJ	-	PT, MT, 10x68 mm WS	Yes	31	14	24	Yes
5	TJ+TH	-	Three 10x38 mm Palmaz stents, 10x94 mm WS, 10x40 mm Symphony stent	No	22	12	12	Yes
6	TH	-	Two 12x40 mm SMART stents	No	19	2	8	Yes
7	TJ+TH	Partial splenic (70%)	10X94 mm WS, two 10x68 mm WS, 10x42 mm WS	Yes	15	6	1*	Yes
8	TJ+TH	-	10x94 mm WS, 10x68 mm WS	Yes (existing TIPS revised)	25	7	3	Yes
9	TJ+TH	-	Three 10x94 mm WS, 10x42 mm WS	Yes	30	5	1	Yes
10	TJ+TH	-	MT, two 10x94 mm WS, two 10x68 mm WS	Yes	35	8	0.1*	No
11	TH	-	12x40 mm SMART stent	No	26	18	3	Yes
12	TJ+TH	-	Three Fluency stent-grafts, two WS, MT	Yes	15	0	3*	Yes

13	TJ	-	10x94 mm WS	Yes	13	4	4	Yes
14	TJ+TS	-	Two 10x80 mm Viatorr stent-grafts, 12x60 mm Viatorr stent-graft, 10x42 mm WS	Yes (existing TIPS revised)	24	32	24	Yes
15	TJ+TS	-	DIAGNOSTIC ONLY	No	32	-	-	-
16	TH	-	DIAGNOSTIC ONLY	No	11	-	-	-
17	TH	GE variceal	-	No	25	-	4	Yes
18	TH	-	Two 40 mm Palmaz stents	Yes	17	0	58	Yes
19	TS	Partial splenic (75%)	-	No	-	-	48	Yes
20	TS	Partial splenic (70%)	-	No	-	-	40	Yes
21	TJ+TS	Partial splenic (70%)	Two 40 mm Jomed stent-grafts, 10x42 mm WS	Yes	28	11	36	Yes
22	TH	Partial splenic (65%)	36 mm Palmaz stent	No	21	0	24	Yes
23	TH	-	12x60 mm SMART stent, 12x40 mm SMART stent, MT	No	14	4	1	Yes
24	TJ+TH	Splenorenal shunt	MT, 12x40 mm WS, 10x68 mm WS, 10x100 mm Viatorr stent-graft, 10x80 mm Viatorr stent-graft	Yes	14	9	1	Yes

*Expired
TIPS: Transjugular intrahepatic portosystemic shunt, TJ: Transjugular, TH: Transhepatic, TS: Transsplenic, GE: Gastroesophageal, WS: Wallstent, PT: Pharmacological thrombolysis, MT: Mechanical thrombolysis

Table 6. Activity in the region of interest drained by the right hepatic liver vein as a percentage of total liver activity

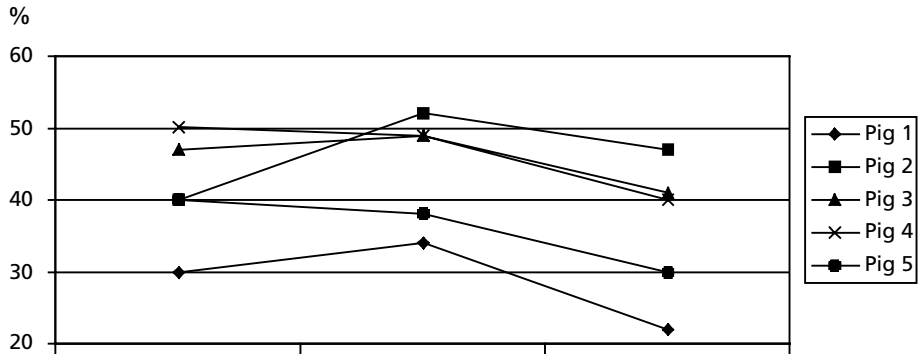

	Before	After TIPS	After stent-graft
Pig 1	30	34	22
Pig 2	40	52	47
Pig 3	47	49	41
Pig 4	50	49	40
Pig 5	40	38	30

Results

Experimental studies

Paper II

The pilot study showed reduced uptake of $^{99}Tc^{m}$-HSA in the ROI after inflation of the balloon, which occluded the liver vein. In one pig, dislodgement of the catheter had occurred during transportation to the scintigraphy room and another pig died due to respiratory problems during the experiments. These two pigs were excluded from the data analysis. In one pig the stent-graft was placed too caudally and had to be extended with an additional stent-graft. Distribution of $^{99}Tc^{m}$-HSA showed similar pattern on planar scintigraphic images. The results are summarized in Table 6.

Accumulation of $^{99}Tc^{m}$-HSA calculated over a ROI was unchanged in all pigs after stent placement except for one pig, in which it increased ($p = 0.25$ before vs after stent). After placement of a stent-graft the activity decresed in all pigs ($p = 0.06$ after stent vs after stent-graft).

Paper III

Due to an anatomical variation, the hepatic vein was not completely blocked by the stent-graft in one pig and this animal was excluded from the study. In another pig the inserted stent-graft was too short and its bare part did not reach far enough into the portal vein. To optimize the flow in the shunt, an additional stent (12x80 mm Smart stent, Cordis) was inserted. One pig died of respiratory failure, just prior to the last radionuclide injection. This animal was included in the first part of the radionuclide study as well as in the histological assessments, but had to be excluded from the final part. One minute after the isotope injection post TIPS, decreased outflow was seen from the occluded vein, compared to the measurements obtained before TIPS. However, already after three minutes the flow

Table 7. Summary of treatment and reinterventions

Patient	Recanalisation	Splenic embolisation	Reintervention
1	Occluded segment of PV	Not necessary	Repeated balloon dilatation and insertion of additional stent
2	Not possible	70 % of caudal portion	-
3	Not possible	75 % of caudal portion	-
4	TIPS necessary	70 % of caudal portion	Repeated balloon dilatation and insertion of additional stent
5	Partial recanalisation	60 % of caudal portion	Intended new splenic embolisation

was normalized. The values remained mainly unchanged in the studies after two weeks. Statistical analysis was not conclusive due to the limited number of animals.

Histological evaluation was done in five pigs. Four animals had normal acinar pattern, without any macroscopic evidence of fibrosis, steatosis, cirrhosis or sign of congestion. One animal had a different pattern and showed macroscopic cirrhosis, with marked infiltration of neutrofils, lymphocytes and plasmacells, findings most likely related to chronic changes. In two more samples, from two different pigs and from different lobes, there were light portal fibrosis with mild infiltration of neutrofils, lymphocytes and plasma cells, but no fibrosis around central veins. Also these changes were most likely unrelated to the experiment. Only one pig had a fully patent stent-graft. The remaining four stent-grafts were occluded to 75–100%.

Clinical studies

Paper I

All children had large gastro-oesophageal varices. Two had extensive PVO, which included the splenic vein. The other three children had a short PVO extending 3–4 cm from the liver hilum. The treatment is summarized in table 7.

In four children partial splenic embolisation was successfully performed. All children had fever and severe pain after the embolisation, which was treated by morphine chloride administration in three of them. One patient required epidural anaesthesia for two days. After 4–7 days the pain decreased and could be managed by oral analgetics for a few days. Transjugular puncture of the IPVB was attempted in four children, but further recanalisation from this approach was impossible in all of them. Percutanous transhepatic access to the IPVB was feasible in four children. In one patient (patient no 1) stent recanalisation of the occluded segment of the PV was done and an additional stent was inserted due to re-stenosis 46 months after recanalisation. In another child (patient no 3) a guide-wire could be passed from the IPVB to the collaterals in the cavernous transformation, but could not be advanced further to the PV due to the tortuousity of these vessels. However, after dilatation and stenting of the stenosis between the IPVB and the cavernous transformation, a pressure gradient of 12 mm Hg disappeared and the inflow of the portal blood to the right liver lobe improved. Percutaneous trans-splenic puncture to the portal vein

branches was performed in three children. In two children the splenic vein was occluded, but catheterization of the collaterals was possible. However it was not possible to pass the occlusion and these children were treated only by partial embolisation of the spleen.

In the third child (patient no 4) contrast injection confirmed large collaterals along the gallbladder and large gastro-oesophageal varices, also visualized previously at MRI and USG examinations. Only small, very peripheral portal vein branches remained open in the liver and the PV was occluded 2–3 cm outside liver hilum. Due to the high pressure gradient of 28 mm Hg between the portal vein and the systemic circulation, a portosystemic shunt was created. The puncture tract in the liver had partly an intraperitoneal route, although the PVO stretched outside the liver. To prevent intraperitoneal bleeding insertion of a 4 cm long, balloonexpandable stent-graft (Jomed) was intended in the intraperitoneal portion of the shunt channel. However, the first stent-graft was accidentally pushed out from the sheath into the splenic vein and could not be retrieved. This stent-graft had to be expanded and was left in the splenic vein. Subsequently, a similar stent-graft was inserted in the intended position. During placement of this stent-graft minor peritoneal bleeding occurred, but ceased as soon as the stent-graft was balloon expanded. The cranial portion of the shunt was kept open by a 10x40 mm Wallstent. A 24 mm long Palmaz stent was inserted distally to prevent migration of a stent-graft, stretching into the PV. All stents and stent-grafts were dilated with an 8x40 mm angioplasty balloon, which reduced the pressure gradient from the initial 28 to 11 mmHg. No other immediate complications were recorded. After six months shunt phlebography showed pronounced stenosis at the cephalic edge of the Wallstent in the hepatic vein. An additional 28 mm long Palmaz stent was placed through the stenosis and dilated with 10 mm-diameter balloon, which normalised the pressure.

Paper IV

Access to the portal circulation was obtained by percutanous transhepatic (n=15), transsplenic (n=5), and transjugular (n=14) route. The site of occlusion was the main PV (n=22), with additionally occluded IPVB (n=8), mesenteric veins (n=4), and/or splenic vein (n=4). The cause of occlusion was chronic thrombosis (n=18), acute thrombosis (n=1), acute and chronic thrombosis (n=3), tumour encasement (n=1) and right PV compression by biliary stents (n=1) See table 4.

In two patients intervention were not attempted, due to findings on venograms. One of these patients turned out to be a possible candidate for liver transplant and in the other patient intervention was estimated too risky. Thus interventional treatment was performed in 22 patients. Another patient was also found to be a transplant candidate and only embolisation of oesophageal varices was done. Two patients were treated only by partial splenic embolisation. Recanalisation of occlusion with or without TIPS placement was carried out in 19 patients. See table 5.

Recanalised segment was stabilized with stents (n=14) or stent-grafts (n=5). A new TIPS (n=10) was placed in order to maintain adequate blood flow through the recanalised venous segment. In two patients, the existing occluded TIPS were recanalised to gain access into the occluded PV. In one of these patients puncture of the occluded TIPS was done using a Colapinto needle by transjugular approach. In the other patient, puncture of the occluded TIPS stent-graft by percutaneous transhepatic route was followed by advancement of a guidewire through the stent-graft towards the right atrium. Using through and through technique subsequent recanalisation of occluded TIPS and PV was possible. After recanalisation additional stents were deployed, covering the occluded PV segments and TIPS channel. Recanalisation of the splanchnic veins was successfully achieved in

all attempted patients at the completion of the procedures. After recanalisation, pressure gradient over occluded segments decreased in all patients but one, from 24 mmHg to 8 mmHg following treatment. In this patient, portal pressure remained unchanged after recanalisation and TIPS, while the right atrial pressure decreased. Despite good flow through in the recanalised channel and through the TIPS, the gradient increased. However, during follow-up and subsequent revisions the gradient decreased considerably. Successful mechanical thrombfragmentation was performed after failed pharmacological thrombolysis in one patient with acute thrombosis of the PV. Two patients with acute and chronic thrombosis and two patients, who developed acute thrombus during the procedure, were also successfully treated with mechanical thrombfragmentation. Partial embolisation of the spleen was performed in five patients in order to reduce symptoms secondary to hypersplenism and/or decrease inflow of blood to the PV system.

Three patients (13.6%) died within 30 days following the procedure. Two of them passed away due to continual bleeding. In one of them, bleeding was a result of hemorrhagic diathesis. In the other patient, the origin of intraperitoneal bleeding was not found. One patient died due to hepatorenal syndrome and sepsis. Another patient died eight weeks later, following development of intraperitoneal abscess. In one patient two days after the procedure, Doppler USG showed no flow through the TIPS, however, the bleeding stopped and re-intervention was considered unnecessary at that time. This patient expired three months later due to intractable gastro-intestinal bleeding. In these five patients further interventional radiological treatment was not indicated, due to their poor general condition.

Improvement of symptoms after procedure was seen in 91% of the treated patients. Follow-up of remaining patients ranged between 2 days and 48 months. Five patients required repeated stent placements secondary to occlusion or stenosis, 3–48 months after the initial recanalisation.

Discussion

In the normal splanchnic system, the intestinal, splenic, pancreatic and gastric venous drainage unite to form the PV. Pressure in the normal PV is slightly higher than in the systemic veins and the pressure gradient between the two systems generates filtration through the sinusoids in the liver. Obstruction of the flow in the PH leads to development of collaterals from the high pressure portal system to the low pressure systemic circulation. Varices may develope from these collaterals, especially around the oesophagus, stomach, rectum and umbilicus, and occasionally around the duodenum, jejunum or colon. Ascites, gastrointestinal bleeding, splenomegaly and HE are other findings associated with PH. When PH is caused by reasons other than obstruction in the liver parenchyma, good liver function may be present with preserved filtering of the blood and sufficient production of all necessary proteins.

Symptomatic PH due to hepatic or posthepatic obstruction is treated in different ways. The definitive treatment is liver transplantation, whereas symptomatic treatment include several options; pharmacological therapy, endoscopic, surgical and interventional treatment. Introduction of the TIPS procedure was a breakthrough in the symptomatic treatment of hepatic and posthepatic PH. Further improvement in TIPS technique, including simultaneous embolisation of varices and the introduction of new devices, especially designed for TIPS, have improved long-time results. Splenic embolisation, which is another approach, may be accomplished to decrease inflow of the blood in the PV system. Balloon-occluded retrograde transvenous obliteration (BRTO), introduced in recent years, has further extended the possibilities of interventional treatment (Choi *et al.* 2003). Pathophysiologically two mechanisms will occur in patients with PVO, when the liver loses portal perfusion. The first consists of an arterial response, resulting in an immediate vasodilatation of the arterial bed. The second is a relatively rapid development of collateral veins, by-passing the occluded portion of the PV, resulting in cavernous transformation (Boyer *et al.* 2006; Harmanci *et al.* 2007). As a result of these compensatory mechanisms, the hepatic venous pressure gradient is initially preserved and the portal pressure is elevated proximal to the occlusion. The portal pressure will further increase over time with elevated risk of variceal bleeding.

The prevalence of PVO has been estimated to 1% in a material of more than 23, 000 patients (Ögren *et al.* 2006). In this material, based on autopsies, 28% of the patients had cirrhosis, 67% had liver malignancy (primary or metastatic), 10% had inflammatory intraabdominal disease and only 3% had myeloproliferative disease. The cause of prehepatic obstruction in our material of 24 patients was chronic thrombosis (n=18), acute thrombosis (n=1), combined acute and chronic thrombosis (n=3), tumour encasement (n=1), and external compression of a biliary stent (n=1). Acute thrombosis can be treated with transcatheter thrombolysis, sometimes in combination with mechanical thrombusfragmentation. Intra-arterial thrombolytic agents can also be infused in the superior mesenteric artery. Though the use of anticoagulation is under debate (Webster *et al.* 2005)

The splanchnic obstruction may be classified due to the extension and the localization of the thrombus. Most patients in paper IV had occlusion of the main PV (n=22), with additionally occluded IPVB (n=8), mesenteric veins (n=4), and/or splenic vein (n=4). Isolated occlusion of the IPVB was found in two patients. The incidence of cirrhosis and malignancy in the material was not investigated.

The goal for the medical treatment is to decrease the inflow of blood to the splanchnic circulation and/or dilate the mesenteric veins and thereby reduce the pressure gradi-

ent. If the pressure gradient is kept below 10–12 mm Hg (Vorobioff *et al.* 1996) or a reduction of 25–50% of initial pressure gradient is achieved the risk of variceal bleeding is very low (Rössle *et al.* 2001). Interventional treatment of patients with PVO requires a different approach, to that of patients with intrinsic liver disease. TIPS is not the first option for patients with prehepatic obstruction, but additional TIPS is often necessary in patients where the IPVB are also occluded (Kori *et al.* 2006). Surgical shunts are sometimes used and selective shunts are favoured (Galambos *et al.* 1976).

In the treatment of PH, the access to the portal venous system depends on the patency of the PV and the possible extent and localisation of the occlusion. In a patient with a patent PV, the portal system can be reached by a transjugular approach. This is the traditional route to perform a TIPS (Richter *et al.* 1990) and is the method of choice if the IPVB are patent. In patients with very small or occluded IPVB, transjugular access can be very difficult or impossible and other possibilities must be chosen. Interventional treatment through a percutaneous transhepatic access was introduced by Lunderquist (Lunderquist *et al.* 1974), who performed percutaneous transhepatic embolisations of gastroesophageal varices. With the percutaneous technique, either by blind or USG guided puncture, a short distance access is provided to the portal circulation. This technique was used in our patients (n=15), in order to gain access to an occluded TIPS or to create a new shunt. In patients with large amounts of ascites laparocentesis is preferred prior to the transhepatic puncture. A patent paraumbilical vein can easily be punctured under USG guidance and be used as an entrance to the portal branches, a technique useful in hepatic PH. Transsplenic puncture to gain access to the PV system was performed in our material after partial splenic embolisation. A number of our patients had a catheter or a glide-wire inserted from a transsplenic approach, which was then used as a target during the attempts to pass an occlusion or to create a TIPS. In one of the children, where the PVO stretched outside the liver, the puncture tract had a partly intraperitoneal route. A guide-wire inserted by a TIPS catheter was caught by a goose-neck snare, inserted from a transsplenic puncture. When this child was treated, the Viatorr was not available and we used balloonexpandable stent-grafts to cover the extrahepatic portion of the shunt channel. During reintervention for hepatic vein stenosis in this patient, we did not know the possible consequences of occlusion of the hepatic vein when using a stent-graft and a bare stent was therefore used. Reported experiences in children were limited at that time (Citron *et al.* 1998;Heyman *et al.* 1997;Huppert *et al.* 2002).The management of this patient stimulated our interest to study the possible circulatory effects of a stent-graft and resulted in the experimental studies (paper II and III).

In case of prehepatic obstruction it is important, especially in children, to restore the portal flow through the liver, in order to maintain the hepatic functions of growth, exocrine and endocrine secretory functions etc. Therefore recanalisation was intended in all patients with PVO. This intervention may be complicated, especially if the occlusion has been longstanding and if cavernous transformation has been formed. Stents and stents-grafts should be used to support the recanalised segments. In patients with symptomatic PH, caused by intrinsic factors, TIPS has become a relatively common procedure. When we started our clinical studies, the stent-grafts dedicated for TIPS, were not available. Initial high rates of dysfunction, approximately 50% in a year (Sanyal *et al.* 1997), led to the improvement of the shunt devices. Stent-graft separate the shunt channel from transected bile ducts and blood vessels, which reduces the formation of pseudointimal hyperplasia (Haskal *et al.* 1992, Haskal *et al.* 1997, Sze *et*

Fig 8. Good flow through the Viatorr. Coilembolised collateral to the right.

al. 1999). Stent-grafts have also been used to stop haemorrhages after extra hepatic puncture of the portal vein in TIPS procedures (Broutzos *et al.* 2000). During the last decade different graft materials for the stent-grafts have been tested. Polyethylene terephthalate (polyester), polycarbonate urethane and silicone have been proven equal to or in some cases less adequate, than conventional TIPS, due to intrinsic thrombogenicity, excessive porosity and propencity to induce inflammatory reactions (Haskal *et al.* 1999;Tanihata *et al.* 1997; Bloch *et al.* 1998). The majority of trials have favoured the ePTFE covered stent-grafts (Haskal *et al.* 1999;Cejna *et al.* 2001;Rossi *et al.* 2004;Bureau *et al.* 2007). Since 2000, the ePTFE covered selfexpanding stent-graft, Viatorr, has been in commercial use. In order to obtain high patency rate in Viatorr, the ePTFE covered portion should stretch into the hepatic vein and up to the IVC. See fig 8. However, stent-grafts in this position block the outflow from the hepatic vein.

Prior to these clinical publications (paper I and IV) there were only few reports of reestablishing PV patency after recanalisation (Bezzi *et al.* 1995, Matsui *et al.* 1996; Cwikiel *et al.* 2000). In paper IV recanalisation with stents and stent-grafts as the only interventional treatment was performed in seven patients. In cases of slow portal flow after the recanalisations or occlusion of IPVB combined treatment with TIPS was necessary (n=10). Partial splenic embolisations were performed as an isolated treatment (n=2) or in combination with recanalisation (n=3). In the two patients where partial splenic embolisation was the only feasible treatment, recanalisation was not possible. In these children embolisation provided enough reduction in PV pressure to stop the bleeding and endoscopic follow-up showed reduction of varices. Embolisation of gastro-oesophageal varices was the only treatment in one patient, with improvement in symptoms. Reduction of mean pressure gradient was seen in all but one of the treated patients, with a reduction from 24 mmHg to 8 mmHg following treatment. Improvement of symptoms was observed in 91% of the treated patients. Two patients were not treated at all. One was a suitable transplant candidate and in the case of the other patient the risk of intervention was too high.

Two experimental studies were performed (paper II and III), where we wanted to evaluate if occlusion of the hepatic vein by a stent-graft had any negative consequences for the liver circulation or the liver parenchyma. Possible effects had not been studied previously. Meanwhile segmental ischemia after PTFE covered stent-graft was described by Bureau *et al.* 2002, but without any sequel for the patient. We could only perform studies in a relatively small number of animals, due to the limited number of stent-grafts provided by the company and due to the complexity of the experiments. TIPS creation was successful in all but one animal, which was excluded from analysis do to an anatomic variant. Due to the limited number of animals statistical evaluation did not show significant values. We could therefore only demonstrate a tendency.

Conclusion

Interventional treatment of patients with PH and occlusion of splanchnic veins is feasible, but the treatment must be individualised. On occasion, recanalisation in combination with TIPS gave good results with improvement of symptoms and reduction of pressure gradients.

Stent-grafts used for TIPS have no long-lasting negative effects, neither on the liver circulation, nor on the liver parenchyma.

Future perspectives

TIPS has been in clinical use for nearly 20 years and has almost completely replaced surgical shunts. Early absolute contraindications, like portal vein thrombosis or Budd-Chiari syndrome have become relative and new indications have emerged.

Transplantation is the curative treatment for a patient with liver disease, whereas TIPS represents an alternative management. TIPS may also be useful prior to major abdominal surgery to prevent intra- and postoperative complications. Obstruction in the splanchnic veins usually requires other forms of treatment. We showed the advantage of a more aggressive management in patients with prehepatic obstruction. Further improvement of these methods is desirable. Development of new shunt devices e g longer stent-grafts suitable for treatment of intra- and extrahepatic PVO, can be expected. Interventions with, or in combination with, methods like USG and MRI which are not using ionising radiation are desired, in order to limit the radiation doses to both the patient and the interventionalist.

Populärvetenskaplig sammanfattning

Bakgrund:

Blod från tarmarna, magsäcken, mjälten och bukspottskörteln flyter samman till portavenen. Vid vissa sjukdomstillstånd i levern får man en ökning av trycket i portavenen, som står för större delen av leverns blodtillförsel. Detta tillstånd kallas för portal hypertension, PH, och kan vara orsakat av förändringar i levern eller i blodtillförseln till eller från levern. Hos barn är den vanligaste orsaken förändringar i blodtillförseln, som t ex inflammation i portavenen, medan orsaken hos vuxna domineras av förändringar i levervävnaden. Med tryckökningen i portavenen följer en hel del komplikationer som kan vara potentiellt livshotande, t ex blödning i blodkärl i anslutning till magsäck och matstrupe. Man får oftast även en förstoring av mjälten, som påverkar blodets levringsförmåga. PH är ofta svårbehandlad, p g a omfördelningen av flödet i portakärlet. Om inte sjukdomstillståndet svarar på sedvanlig behandling t ex medikamentell, görs ibland en s k TIPS, transjugular intrahepatiskt portosystemisk shunt. Detta är en konstgjord förbindelse, shunt, mellan leverns portakretslopp och systemcirkulationen, som gör att blodet kan passera levern, utan att behöva flöda igenom levervävnaden. Man kan då förhindra att blodet stockar sig och kan på så sätt minska trycket i de kärl som förser portavenen med blod. TIPS är en metod som infördes i början av 1990-talet och man använde sig initialt av stentar (ett slags metallnät) för att hålla den konstgjorda kanalen öppen. På senare tid har man mest använt en s k stent-graft, ett metallnät som är omgivet av ett semipermeabelt material, som har bättre långtidseffekt än bara metallnätsbehandling.

Portavenstrombos innebär att portakärlet täpps till, helt eller delvis, i hela eller delar av tillflödet. Detta är ett ovanligt tillstånd som ofta behöver en annan behandling än den vid PH, och kan i en del fall kompletteras med TIPS. Bakomliggande orsak kan vara leversjukdom (fr a cirros), tumörsjukdom i buken eller rubbning i blodets levringsförmåga. En stent-graft täpper till avflödet från levern in till systemcirkulationen, vilket skulle kunna ha negativa effekter på leverns cirkulation hos patienter, som redan har nedsatt funktion i levern.

Utförda studier och resultat:

Med de utförda experimentella djurstudierna ville vi ta reda på om stent -grafterna hade en negativ påverkan på levercirkulationen. Vid den första djurexperimentella studien undersökte vi hur den arteriella cirkulationen påverkades av TIPS med stent resp stent-graft. Vid den studien fann vi en nedsättning av den arteriella cirkulationen efter stent-graft, men fyndet var inte statistiskt säkerställt.

I den andra experimentella studien undersökte vi om stent-graften påverkade det venösa avflödet, dels direkt efter TIPS, och dels vid upprepning av försöket efter två veckor. Då undersöktes även levern histopatologiskt, där leverns struktur bedömdes i mikroskop. Resultatet visade att det direkt efter insättningen av en stent-graft för TIPS fanns en viss nedsättning av avflödet av blod, som i det närmaste normaliserades redan efter tre minuter.

De två andra artiklarna är studier som sammanfattar resultat och uppföljning av patienter, som behandlats med interventionella ingrepp. Den första studien omfattar barn som behandlats p g a tilltäppning av portavenen. Den andra kliniska studien är retrospektiv och omfattar ett patientmaterial på 24 patienter, som behandlats med interventionella metoder p g a portavens tilltäppning och portal hypertension.

Studierna har visat att interventionell behandling av patienter med portal hypertension och tilltäppning av portavenen eller dess tillförande kärl är möjlig att utföra och att användning av stent-grafter vid TIPS inte har några långtidsverkande negativa effekter på levercirkulationen.

Acknowledgements

I want to express my sincere gratitude to all colleagues, co-workers, family and friends, who in different ways assisted me in completing this thesis. Especially I want to thank:

Associate professor **Wojciech Cwikiel,** my supervisor in my academic work, tutor in interventional radiology and friend, who introduced me to interventions and research. Thank you for your never ending enthusiasm, help and positive input any time of the day and anywhere in the world..…...

My present head of departments, **Peter Leander** and **Martin Malina**, and current professors **Olle Ekberg** and **Krassi Ivancev,** for encouragement and for giving me time.

My former head of departments, **Hans Stridbeck** and **Peter Hochbergs** for support in interventional radiology.

All the colleagues at the gastrointestinal units, Lund and Malmö University Hospitals and at the endovascular unit, Malmö University Hospital, for friendship and collaboration.

Associate professor **Christer Lundstedt**, for believing in me when I made my first attempts in interventions.

My co-author, **Lennart Bergqvist** for explaining the role of radionuclides.

Peter Mangell, for friendship and practical advice with this book.

My friends **Vicky** and **Anders Nilsson**, for language assistance and "keep cool" attitude.

Lennart, my husband and my love, for encouragement, enormous patience and never ending support.

Our children **Axel** and **Hedvig**, who make me see what is important in life. Thank you for borrowed time!

References

Altman DG. *Practical statistics for medical research.* London: Chapman & Hall; 1991.

Andrews RT, Saxon RR, Bloch RD, Petersen BD, Uchida BT, Rabkin JM, Loriaux MM, Keller FS, Rosch J. Stent-Grafts for de novo TIPS: Technique and early results. *J Vasc Interv Radiol* 1999 10:1371–8.

Audet M, Baiocchi GL, Portolani N, Becmeur F, Caga M, Giulini SM, Cinqualbre J, Jaeck D, Wolf P. A surgical solution to extrahepatic portal thrombosis and portal cavernoma: the splanchnic-intrahepatic portal bypass. *Dig Liver Dis* 2003 Dec;35(12):903–6.

Bambini DA, Superina R, Almond PS, Whitington PF, Alonso E. Experience with the Rex shunt (mesenterico-left portal bypass) in children with extrahepatic portal hypertension. *J Pediatr Surg* 2000;35:13–8.

Bellomo-Brandão MA, Morcillo AM, Hessel G, Cardoso SR, Servidoni Mde F, da-Costa-Pinto EA. Growth assessment in children with extra-hepatic portal vein obstruction and portal hypertension. *Arq Gastroenterol* 2003 Oct–Dec;40(4):247–50.

Bezzi M, Broglia L, Lemos AA, Rossi P. Transjugular intrahepatic portosystemic shunt in portal vein thrombosis: role of the right gastric vein with anomalous insertion. *Cardiovasc Intervent Radiol* 1995;18(2):102–5.

Bilbao JI, Quiroga J, Herrero JI, Benito A. Transjugular intrahepatic portosystemic shunt (TIPS): current status and future possibilities. *Cardiovasc Intervent Radiol* 2002 Jul–Aug;25(4):251–69.

Björnsson E, Olsson J, Rydell A, Fredriksson K, Eriksson C, Sjöberg C, Olausson M, Backman L, Castedal M, Friman S. Long-term follow-up of patients with alcoholic liver disease after liver transplantation in Sweden: impact of structured management on recidivism. *Scand J Gastroenterol* 2005 Feb;40(2):206–16.

Bloch R, Pavcnik D, Uchida BT, Krajina A, Kamino T, Timmermans H, Loriaux M, Hulek P. Polyurethane-coated Dacron-covered stent-grafts for TIPS: results in swine. *Cardiovasc Intervent Radiol* 1998 Nov–Dec;21(6):497–500.

Boyer TD, Haskal ZJ; American Association for the Study of Liver Diseases. The role of transjugular intrahepatic portosystemic shunt in the management of portal hypertension. *Hepatology* 2005 Feb;41(2):386–400.

Boyer TD, Wright T, Manns M. Zakim D, editor. *Zakim and Boyer's Hepatology. A textbook of liver disease.* 5th ed. Philadelphia PA, USA: Saunders, Elsevier; 2006.

Brountzos EN, Alexopoulou E, Koskinas I, Thanos L, Papathanasiou MA, Kelekis DA. Intraperitoneal portal vein bleeding during transjugular intrahepatic portosystemic shunt: Treatment with stent-graft placement. *Am J Roentgenol* 2000 Jan;174(1):132–4.

Bureau C, Otal P, Chabbert V, PeronJM, Rousseau H, Vinel JP. Segmental liver ischemia after TIPS procedure using a new PTFE-covered stent. *Hepatology* 2002 Dec 36(6):1554.

Bureau C, Pagan JC, Layrargues GP, Metivier S, Bellot P, Perreault P, Otal P, Abraldes JG, Peron JM, Rousseau H, Bosch J, Vinel JP. Patency of stents covered with polytetrafluoroethylene in patients treated by transjugular intrahepatic portosystemic shunts: long-term results of a randomized multicentre study. *Liver Int* 2007 Aug;27(6):742–7.

Burroughs AK, Patch D. Transjugular intrahepatic portosystemic shunt. *Semin Liver Dis* 1999 19:457–73.

Burroughs AK, Vangeli M. Transjugular intrahepatic portosystemic shunt versus endoscopic therapy: randomized trials for secondary

prophylaxis of variceal bleeding: an updated meta-analysis. *Scand J Gastroenterol* 2002 Mar;37(3):249–52.

Carithers RL Jr. Liver transplantation. American Association for the Study of Liver Diseases. *Liver Transpl* 2000 Jan;6(1):122–35.

Cejna M, Peck-Radosavljevic M, Thurnher S, Hittmair K, Schoder M, Lammer J. Creation of transjugular intrahepatic portosystemic shunts with stent-grafts: initial experiences with a polytetrafluoroethylene-covered nitinol endoprosthesis. *Radiology* 2001 Nov;221(2):437–46.

Cejna M, Peck-Radosavljevic M, Thurnher S, Schoder M, Rand T, Angermayr B, Lammer J. ePTFE-covered stent-grafts for revision of obstructed transjugular intrahepatic portosystemic shunt. *Cardiovasc Intervent Radiol* 2002 25:365–72.

Cejna M, Thurnher S, Pidlich J, Kaserer K, Schoder M, Lammer J. Primary implantation of polyester-covered stent-grafts for transjugular intrahepatic portosystemic stent shunts (TIPSS): A pilot study. *Cardiovasc Intervent Radiol* 1999 22:305–10.

Charco R, Fuster J, Fondevila C, Ferrer J, Mans E, Garcia-Valdecasas JC. Portal vein thrombosis in liver transplantation. *Transplant Proc* 2005 Nov;37(9):3904–5.

Choi YH, Yoon CJ, Park JH, Chung JW, Kwon JW, Choi GM. Balloon-occluded retrograde transvenous obliteration for gastric variceal bleeding: its feasibility compared with transjugular intrahepatic portosystemic shunt. *Korean J Radiol* 2003 Apr–Jun;4(2):109–16.

Citron SJ, Brantley SD. TIPS in portal vein occlusions: facilitation with percutaneous splenic access. *J Vasc Interv Radiol* 1998 9:363–4.

Clavien PA, Selzner M, Tuttle-Newhall JE, Harland RC, Suhocki P. Liver transplantation complicated by misplaced TIPS in the portal vein. *Ann Surg* 1998 Mar;227(3):440–5.

Colapinto RF, Stronell RD, Birch SJ, Langer B, Blendis LM, Greig PD, Gilas T. Creation of an intrahepatic portosystemic shunt with a Grüntzig balloon catheter. *Can Med Assoc J* 1982 Feb 1;126(3):267–8.

Collini F, Brener B. Portal hypertension. *Surg. Gynecol.Obstetr* 1990;170:171–92.

Cwikiel W. Interventional procedures involving portal vein circulation: A review. *Acta Radiol* 2006 47:145–56.

Cwikiel W, Solvig J, Schrøder H. Stent recanalization of chronic portal vein occlusion in a child. *Cardiovasc Intervent Radiol* 2000 23:309–11.

Dasgupta R, Roberts E, Superina RA, Kim PC. Effectiveness of Rex shunt in the treatment of portal hypertension. *J Pediatr Surg* 2006 41:108–12.

DeFranchis R. Evolving consensus in portal hypertension. Report of the Baveno IV consensus workshop on methodology of diagnosis and therapy in portal hypertension. *J Hepatol* 2005 Jul;43(1):167–76.

Dunn W, Jamil LH, Brown LS, Wiesner RH, Kim WR, Menon KV, Malinchoc M, Kamath PS, Shah V. MELD accurately predicts mortality in patients with alcoholic hepatitis. *Hepatology* 2005 Feb;41(2):353–8.

Fasulakis S, Rerksuppaphol S, Hardikar W, Vrazas J, Brooks M. Alternative technique for transjugular intrahepatic portosystemic shunt in a young child. *Australas Radiol* 2006 Oct;50(5):447–50.

Foshager MC, Ferral H, Nazarian GK, Castaneda-Zuniga WR, Letourneau JG. Duplex sonography after transjugular intrahepatic portosystemic shunts (TIPS): Normal hemodynamic findings and efficacy in predicting shunt patency and stenosis. *Am J Roentgenol* 1995 165:1–7.

Galambos JT, Rudman D, Warren WD.Portal hypertension. A new beginning for an old problem. *Am J Dig Dis* 1976 Sep;21(9):827–32.

Goins B, Phillips WT, Klipper R. Blood-pool imaging using technetium-99m-labeled liposomes. *J Nucl Med* 1996 Aug;37(8): 1374–9.

Grover VP, Dresner MA, Forton DM, Counsell S, Larkman DJ, Patel N, Thomas HC, Taylor-Robinson SD. Current and future applications of magnetic resonance imaging and spectroscopy of the brain in hepatic encephalopathy. *World J Gastroenterol* 2006 May 21;12(19):2969–78.

Harmanci O, Bayraktar Y. Portal hypertension due to portal venous thrombosis: etiology, clinical outcomes. *World J Gastroenterol* 2007 May 14;13(18):2535–40.

Haskal ZJ, Brenneke LJ. Porous and nonporous polycarbonate urethane stent-grafts for TIPS formation: Biologic responses. *J Vasc Interv Radiol* 1999 Oct 10(9):1255–63.

Haskal ZJ, Brenneke LJ. Transjugular intrahepatic portosystemic shunts formed with polyethylene terephthalate-covered stents: Experimental evaluation in pigs. *Radiology* 1999 213:853–9.

Haskal ZJ, Davis A, McAllister A, Furth EE. PTFE-encapsulated endovascular stent-graft for transjugular intrahepatic portosystemic shunts: Experimental evaluation. *Radiology* 1997 205:682–8.

Haskal ZJ, Ring EJ, LaBerge JM, Peltzer MY, Radosevich PM, Doherty MM, Gordon R. Role of parallel transjugular intrahepatic portosystemic shunts in patients with persistent portal hypertension. *Radiology* 1992 185:813–7.

Henderson M. Corson JD, Williamson RCN editors. *Surgery*. London: Mosby International; 2001. Section 3, chapter 12. p. 12.1–12.14.

Heyman MB, LaBerge JM, Somberg KA, Rosenthal P, Mudge C, Ring EJ, Snyder JD. Transjugular intrahepatic portosystemic shunts (TIPS) in children. *J Pediatr* 1997 131:914–9.

Hidajat N, Stobbe H, Griesshaber V, Felix R, Schroder RJ. Imaging and radiological interventions of portal vein thrombosis. *Acta Radiol* 2005 46:336–43.

Hulek P, Krajina A, editors. *Current practice of TIPS*. Olga Stambergová. Hradek Králové, Czech Rebublic. 2001.

Huonker M, Schumacher YO, Ochs A, Sorichter S, Keul J, Rossle M. Cardiac function and haemodynamics in alcoholic cirrhosis and effects of the transjugular intrahepatic portosystemic stent shunt. *Gut* 1999 May;44(5):743–8.

Huppert PE, Astfalk W, Brambs HJ, Schweizer P, Schott U, Pereira P, Duda SH, Dopfer RE, Claussen CD. Transjugular intrahepatic portosystemic shunt in children. Initial clinical experiences and literature review. *Rofo* 1998 168:595–603.

Huppert PE, Goffette P, Astfalk W, Sokal EM, Brambs HJ, Schott U, Duda SH, Schweizer P, Claussen CD. Transjugular intrahepatic portosystemic shunts in children with biliary atresia. *Cardiovasc Intervent Radiol* 2002 Nov–Dec;25(6):484–93.

Israel DM, Hassall E, Culham JA, Phillips R. Partial splenic embolization in children with hypersplenism. *J Pediatr* 1994 124:95–100.

Janssen HL, Wijnhoud A, Haagsma EB, van Uum SH, van Nieuwkerk CM, Adang RP, Chamuleau RA, van Hattum J, Vleggaar FP, Hansen BE, Rosendaal FR, van Hoek B. Extrahepatic portal vein thrombosis: aetiology and determinants of survival. *Gut* 2001 49:720–4.

Kawamata H, Kumazaki T, Kanazawa H, Takahashi S, Tajima H, Hayashi H. Transjugular intrahepatic portosystemic shunt in a patient with cavernomatous portal vein occlusion. *Cardiovasc Intervent Radiol* 2000 23:145–9.

Keussen I, Song H Y, Bajc M, Cwikiel W. Changes in the distribution of hepatic arterial blood flow following TIPS with uncovered stent and stent-graft: An experimental study. *Cardiovasc Intervent Radiol* 2002 25:314–7.

Kim HB, Pomposelli J, Lillehei C, Jenkins R, Jonas M, Krawczuk L, Fishman S. Mesogonadal shunts for extrahepatic portal vein thrombosis and variceal hemorrhage. *Liver transpl* 2005 Nov;11(11):1389–94.

Kori I, Bar-Zohar D, Carmiel-Haggai M, Samuels D, Nakache R, Oren R, Kessler A, Szold O, Ben-Haim M. Budd-Chiari syndrome and acute portal vein thrombosis: management by a transjugular intrahepatic portosystemic shunt (TIPS) and portal vein interventions via a TIPS. *J Gastrointest Surg* 2006 Mar;10(3):417–21.

Kuran S, Oguz D, Parlak E, Asil M, Cicek B, Kilic M, Disibeyaz S, Sahin B. Secondary prophylaxis of esophageal variceal treatment: Endoscopic sclerotherapy, band ligation and combined therapy - long-term results. *Turk J Gastroenterol* 2006;17:103–9.

Lake JR. The role of transjugular portosystemic shunting in patients with ascites. *N Engl J Med* 2000 Jun 8;342(23):1745–7.

Lunderquist A, Vang J. Transhepatic catheterization and obliteration of the coronary vein in patients with portal hypertension and esophageal varices. *N Engl J Med* 1974 Sep 26;291(13):646–9.

Maleux G, Pirenne J, Vaninbroukx J, Aerts R, Nevens F. Are TIPS stent-grafts a contraindication for future liver transplantation? *Cardiovasc Intervent Radiol* 2004 27: 140–2.

Mallinckrodt´s product summary. Mallinckrodt Medical B.V., Le Petten, Holland;1995.

Mathias K, Bolder U, Lohlein D, Jäger H. Percutaneous transhepatic angioplasty and stent implantation for prehepatic portal vein obstruction. *Cardiovasc Intervent Radiol* 1993 16:313–5.

Matsui O, Yoshikawa J, Kadoya M, Gabata T, Takashima T, Urabe T, Unoura M, Kobayashi K. Transjugular intrahepatic portosystemic shunt after previous recanalization of a chronically thrombosed portal vein via a transmesenteric approach. *Cardiovasc Intervent Radiol* 1996 19:352–5.

Montgomery A, Ferral H, Vasan R, Postoak DW. MELD score as a predictor of early death in patients undergoing elective transjugular intrahepatic portosystemic shunt (TIPS) procedures. *Cardiovasc Intervent Radiol* 2005 May–Jun;28(3):307–12.

Mosimann F, Berger D, Cuenoud PF, Mosimann R. Portal vein thrombosis of the adolescent: indications for autologous internal jugular vein interposition meso-caval shunt. *Z Kinderchir* 1990 45:189–91.

Nayar M, Saravanan R, Rowlands PC, McWilliams RG, Evans J, Sutton RJ, Gilmore IT, Smart HL, Lombard MG. TIPSS in the treatment of ectopic variceal bleeding.*Hepatogastroenterology* 2006 Jul–Aug;53(70):584–7.

Ögren M, Bergqvist D, Björck M, Acosta S, Eriksson H, Sternby NH. Portal vein thrombosis: prevalence, patient characteristics and lifetime risk: a population study based on 23,796 consecutive autopsies. *World J Gastroenterol* 2006 Apr 7;12(13):2115–9.

Palmaz JC, Sibbitt RR, Reuter SR, Garcia F, Tio FO. Expandable intrahepatic portacaval shunt stents: early experience in the dog. *Am J Roentgenol* 1985 Oct;145(4):821–5.

Papatheodoridis GV, Goulis J, Leandro G, Patch D, Burroughs AK. Transjugular intrahe-

patic portosystemic shunt compared with endoscopic treatment for prevention of variceal rebleeding: A meta-analysis. *Hepatology* 1999 Sep;30(3):612–22.

Radosevich PM, Ring EJ, LaBerge JM, Peltzer MY, Haskal ZJ, Doherty MM, Gordon R. Transjugular intrahepatic portosystemic shunts in patients with portal vein occlusion. *Radiology* 1993 186:523–7.

Rees CJ, Nylander DL, Thompson NP, Rose JD, Record CO, Hudson M. Do gastric and oesophageal varices bleed at different portal pressures and is TIPS an effective treatment? *Liver* 2000 20:253–6.

Richter GM, Noeldge G, Palmaz JC, Roessle M, Slegerstetter V, Franke M, Gerok W, Wenz W, Farthman E. Transjugular intrahepatic portocaval stent shunt. Preliminary clinical results. *Radiology* 1990 174:1027–30.

Rikkers LF, Sorrell WT, Jin G. Which portosystemic shunt is best? *Gastroenterol Clin North Am* 1992 Mar;21(1):179–96.

Robertson SW, Ritchie RO. In vitro fatigue-crack growth and fracture toughness behavior of thin-walled superelastic Nitinol tube for endovascular stents: A basis for defining the effect of crack-like defects. *Biomaterials* 2007 Feb;28(4):700–9.

Rösch J, Hanafee WN, Snow H. Transjugular portal venography and radiologic portacaval shunt: an experimental study. *Radiology* 1969 Apr;92(5):1112–4.

Rose JDG, Pimpalwar S, Jackson RW. A New Stent-Graft for Transjugular Intrahepatic Portosystemic Shunts. *British Journal of Radiology* 2001 74:908–12.

Rossi P, Salvatori FM, Fanelli F, Bezzi M, Rossi M, Marcelli G, Pepino D, Riggio O, Passariello R. Polytetrafluoroethylene-covered nitinol stent-graft for transjugular intrahepatic portosystemic shunt creation: 3-year experience. *Radiology* 2004 Jun;231(3):820–30.

Rössle M, Grandt D. TIPS: an update. *Best Pract Res Clin Gastroenterol* 2004 Feb;18(1):99–123.

Rössle M, Haag K, Blum HE. The transjugular intrahepatic portosystemic stent-shunt: a review of the literature and own experiences. *J Gastroenterol Hepatol* 1996 11:293–8.

Rössle M, Olschewski M, Siegerstetter V, Berger E, Kurz K, Grandt D. The Budd-Chiari syndrome: outcome after treatment with the transjugular intrahepatic portosystemic shunt. *Surgery* 2004 Apr;135(4):394–403.

Rössle M, Siegerstetter V, Euringer W, Olschewski M, Kromeier J, Kurz K , Langer M. The use of a polytetrafluoroethylene-covered stent graft for transjugular intrahepatic portosystemic shunt (TIPS): Long-term follow-up of 100 patients. *Acta Radiol* 2006 47(7):660–6.

Rössle M, Siegerstetter V, Olschewski M, Ochs A, Berger E, Haag K. How much reduction in portal pressure is necessary to prevent variceal rebleeding? a longitudinal study in 225 patients with transjugular intrahepatic portosystemic shunts. *Am J Gastroenterol* 2001 Dec;96(12):3379–83.

Roussos A, Philippou N, Mantzaris GJ, Gourgouliannis KI. Hepatic hydrothorax: Pathophysiology diagnosis and management. *J Gastroenterol Hepatol* 2007 Sep;22(9):1388–93.

Ryckman FC, Alonso MH. Causes and management of portal hypertension in the pediatric population *Clin Liver Dis* 2001 5:789–818.

Saeed ZA, Stiegmann GV, Ramirez FC, Reveille RM, Goff JS, Hepps KS, Cole RA. Endoscopic variceal ligation is superior to combined ligation and sclerotherapy for esophageal varices: a multicenter prospective randomized trial. *Hepatology* 1997 Jan;25(1):71–4.

Sanyal A, Freedman A, Luketic V, Purdum P 3rd, Shiffman M, DeMeo J, Cole P, Tisnado J. The natural history of portal hypertension after transjugular intrahepatic portosystemic shunts. *Gastroenterology* 1997 Mar;112(3):889–98.

Saxon R, Ross P, Mendel-Hartvig J, Barton R, Benner K, Flora K, Petersen B, Lakin P, Keller F. Transjugular intrahepatic portosystemic shunt patency and the importance of stenosis location in the development of recurrent symptoms. *Radiology* 1998 207:683–93.

Senyüz OF, Yesildag E, Emir H, Tekant G, Yeker Y, Bozkurt P. Sugiura procedure in portal hypertensive children. *J Hepatobiliary Pancreat Surg* 2001 8:245–9.

Senzolo M, Tibbals J, Cholongitas E, Triantos CK, Burroughs AK, Patch D. Transjugular intrahepatic portosystemic shunt for portal vein thrombosis with and without cavernous transformation. *Aliment Pharmacol Ther* 2006 Mar 15;23(6):767–75.

Shaked A, Busuttil RW. Liver transplantation in patients with portal vein thrombosis and central portacaval shunts. *Ann Surg* 1991 Dec; 214(6): 696–702.

Shiffman M. Can anticoagulation enhance TIPS patency? *Hepatology* 1996 Dec;24(6):1533–5.

Shilyansky J, Roberts EA, Superina RA. Distal splenorenal shunts for the treatment of severe thrombocytopenia from portal hypertension in children. *J Gastrointest Surg* 1999 Mar–Apr;3(2):167–72.

Shimizu T, Onda M, Tajiri T, Yoshida H, Mamada Y, Taniai N, Aramaki T, Kumazaki T. Bleeding portal-hypertensive gastropathy managed successfully by partial splenic embolization. *Hepatogastroenterology* 2002 49:947–9.

Somberg KA, Riegler JL, LaBerge JM, Doherty-Simor MM, Bachetti P, Roberts JP, Lake JR. Hepatic encephalopathy after transjugular intrahepatic portosystemic shunts: incidence and risk factors. *Am J Gastroenterol* 1995 90:549–55.

Sugawara Y, Makuuchi M, Tamura S, Matsui Y, Kaneko J, Hasegawa K, Imamura H, Kokudo N, Motomura N, Takamoto S. Portal vein reconstruction in adult living donor liver transplantation using cryopreserved vein grafts. *Liver Transpl* 2006 Aug;12(8): 1233–6.

Svoboda P, Kantorova I, Brhelova H, Vasickova J, Ochmann. Recent position of transjugular intrahepatic portosystemic shunt in the treatment of portal hypertension. *Hepatogastroenterology* 1997 44:647–55.

Sze D, Vestring T, Liddel R, Kato N, Semba C, Razavi M, Kee S, Dake M. Recurrent TIPS failure associated with biliary fistulae: Treatment with PTFE-covered stents. *Cardiovasc Intervent Radiol* 1999 22:298–304.

Tanihata H, Saxon R, Kubota Y, Pavcnik D, Uschida B, Rosch J, Keller F, Yamada R, Sato M. Transjugular intrahepatic shunt with silicone-covered Wallstents: results in a swine model. *Radiology* 1997 205: 181–4.

Terreni N, Vangeli M, Raimondo ML, Tibballs JM, Patch D, Burroughs AK. Late intrahepatic hematoma complicating transjugular intrahepatic portosystemic shunt for Budd-Chiari syndrome. *Cardiovasc Intervent Radiol* 2007 Mar–Apr;30(2):335–8.

Ueno N, Kawamura H, Takahashi H, Fujisawa N, Yoneda M, Kirikoshi H, Sakaguchi T, Saito S, Togo S. Characterization of portal vein thrombus with the use of contrast-enhanced sonography *J Ultrasound Med* 2006 25:1147–52.

Valla DC, Condat B. Portal vein thrombosis in adults: pathophysiology, pathogenesis and management. *J Hepatol* 2002 32: 865–71.

Van Ha TG, Hodge J, Funaki B, Lorenz J, Rosenblum J, Straus C, Leef J. Transjugular intrahepatic portosystemic shunt placement in patients with cirrhosis and concomitant portal vein thrombosis. *Cardiovasc Intervent Radiol* 2006 Sep–Oct;29(5):785–90.

Vargas JH. Splenic embolization for portal hypertension in children. *J Pediatr* 1994 125:505–6.

Venturi A, Piscaglia F, Silvagni E, Righini R, Fabbrizio B, Cescon M, Bolondi L. Role of real-time contrast-enhanced ultrasound in the assessment of metastatic portal vein thrombosis. *Ultraschall Med* 2007 Feb;28(1): 75–8.

Vidal V, Joly L, Perreault P, Bouchard L, Lafortune M, Pomier-Layrargues G. Usefulness of transjugular intrahepatic portosystemic shunt in the management of bleeding ectopic varices in cirrhotic patients. *Cardiovasc Intervent Radiol* 2006 Sep–Oct;29(2): 216–9.

Vivas I, Bilbao JI, Martinez-Cuesta A, Benito A, Delgado C, Velazquez P. Combination of various percutaneous techniques in the treatment of pylephlebitis. *J Vasc Interv Radiol* 2000 Jun;11(6):777–80.

Vogelzang RL, Reddy SG, Braun MA, Nemcek AA. Extrahepatic portal venous stenosis: treatment with percutaneous transhepatic stent placement. *J Vasc Interv Radiol* 1996 Mar–Apr 7(2): 269–71.

Vorobioff J, Groszmann RJ, Picabea E, Gamen M, Villavicencio R, Bordato J, Morel I, Audano M, Tanno H, Lerner E, Passamonti M. Prognostic value of hepatic venous pressure gradient measurements in alcoholic cirrhosis: a 10-year prospective study. *Gastroenterology* 1996 Sep;111(3):701–9.

Walser EM, DeLa Pena R, Villanueva-Meyer J, Ozkan O, Soloway R. Hepatic perfusion before and after the transjugular intrahepatic portosystemic shunt procedure: impact on survival. *J Vasc Interv Radiol* 2000 11:913–8.

Webb LJ, Sherlock S. The aetiology, presentation and natural history of extra-hepatic portal venous obstruction. *Q J Med* 1979 Oct;48(192):627–39.

Webster GJ, Burroughs AK, Riordan SM. Review article: portal vein thrombosis—new insights into aetiology and management. *Aliment Pharmacol Ther* 2005 Jan 1;21(1): 1–9.

Yan P, Yan LN. Cavoportal hemitransposition in liver transplantation: a new technique. *Hepatobiliary Pancreat Dis Int* 2003 2; 202–5.