



LUND UNIVERSITY

Perfusion Monitoring During Oculoplastic Reconstructive Surgery - Opportunities for Optimization of Surgical Techniques

Memarzadeh, Khashayar

2018

Document Version:

Publisher's PDF, also known as Version of record

[Link to publication](#)

Citation for published version (APA):

Memarzadeh, K. (2018). *Perfusion Monitoring During Oculoplastic Reconstructive Surgery - Opportunities for Optimization of Surgical Techniques*. [Doctoral Thesis (compilation), Department of Clinical Sciences, Lund]. Lund University, Faculty of Medicine.

Total number of authors:

1

Creative Commons License:

Unspecified

General rights

Unless other specific re-use rights are stated the following general rights apply:

Copyright and moral rights for the publications made accessible in the public portal are retained by the authors and/or other copyright owners and it is a condition of accessing publications that users recognise and abide by the legal requirements associated with these rights.

- Users may download and print one copy of any publication from the public portal for the purpose of private study or research.
- You may not further distribute the material or use it for any profit-making activity or commercial gain
- You may freely distribute the URL identifying the publication in the public portal

Read more about Creative commons licenses: <https://creativecommons.org/licenses/>

Take down policy

If you believe that this document breaches copyright please contact us providing details, and we will remove access to the work immediately and investigate your claim.

LUND UNIVERSITY

PO Box 117
221 00 Lund
+46 46-222 00 00




Perfusion Monitoring During Oculoplastic Reconstructive Surgery

Opportunities for Optimization of Surgical Techniques

KHASHAYAR MEMARZADEH

DEPARTMENT OF CLINICAL SCIENCES, LUND | LUND UNIVERSITY



Perfusion Monitoring During Oculoplastic Reconstructive Surgery

Perfusion Monitoring During Oculoplastic Reconstructive Surgery

Opportunities for Optimization of Surgical
Techniques

Khashayar Memarzadeh, MD



LUND
UNIVERSITY

DOCTORAL DISSERTATION

by due permission of the Faculty of Medicine, Lund University, Sweden.
To be defended the conference room of the Eye Clinic, SUS, Kioskgatan 1, Lund.
Friday 30th of November 2018 at 09.00.

Faculty opponent

Maria Mani, MD, PhD

Associate Professor of Plastic Surgery, Department of Surgical Sciences
Uppsala University, Uppsala, Sweden

Organization LUND UNIVERSITY Department of Clinical Sciences Lund, Ophthalmology, Lund, Sweden		Document name DOCTORAL DISSERTATION	
		Date of issue: 2018-11-30	
Title: Perfusion Monitoring During Oculoplastic Reconstructive Surgery-Opportunities for Optimization of Surgical Techniques			
<p>Existing oculoplastic reconstructive surgical techniques are based on empirical knowledge and were established long before perfusion monitoring was possible. It is believed that an avascular graft should always be placed on a vascular bed or flap and also that the viable length of a flap depends on the width of its pedicle. The actual role of the length, width and thickness of a random flap in its survival is still not clear. Modern imaging techniques now enable monitoring of perfusion and reconsideration of how to optimize the reconstructive surgical procedures. In the present thesis, different surgical techniques were studied, namely tarsoconjunctival flaps using the modified Hughes procedure, random pattern skin advancement flaps and full-thickness eyelid axial flaps. Perfusion was assessed using laser Doppler velocimetry, laser speckle, thermography and tissue oxygenation (pO₂) measurements.</p> <p>The results from the tarsoconjunctival flaps in pigs (Paper I) showed that perfusion decreased gradually during dissection and advancement of the tarsoconjunctival flap. At the time when the flap was sutured into place, there was virtually no perfusion or oxygenation of the distal end of the flap. A recent study shows that the same is true for tarsoconjunctival flaps in patients (Paper II). Using a free eyelid composite graft may be an alternative reconstructive surgical technique and this has now been performed in a first case (Paper III).</p> <p>The results from the random pattern advancement skin flaps in pigs (Paper IV) show that the flap length may be more important than the length to width ratio. Perfusion decreased gradually from the base to the tip of the flap, reaching ~20% at 2.5 cm from the base of the flap, with virtually no perfusion 3.0 cm from the base of the flap. Making the flap longer does not seem meaningful and a free transplant may then be considered. The length to width ratio of the flap did not determine perfusion or oxygenation. Perfusion were preserved to a greater extent in the thick flaps (~40%) than in the thin flaps (~20%).</p> <p>On the other hand a full-thickness composite eyelid flap (paper V), which is an axial flap, there is only a slight decrease in perfusion. The results support the view that plastic surgery of the eyelids is permissive, and the rich vascularization of the eyelid due to the anastomotic network of vessels in the tarsal plate may increase the likelihood of flap survival and surgical success.</p> <p>In conclusion, modern techniques enables detailed flap monitoring and opens opportunities to optimize some surgical procedures.</p>			
Key words: Perfusion, oculoplastic, reconstructive surgery, flap, graft			
Classification system and index terms (if any)		Language: English	
Supplementary bibliographical information		ISBN: 978-91-7619-710-3	
ISSN and key title: 1652-8220 Perfusion Monitoring During Oculoplastic Reconstructive Surgery		Number of pages: 56	
Recipient's notes		Security classification	Price

Signature



Date 2018-10-25

Perfusion Monitoring During Oculoplastic Reconstructive Surgery

Opportunities for Optimization of Surgical
Techniques

Khashayar Memarzadeh, MD



LUND
UNIVERSITY

With Special thanks to my talented dear friend Ania Sabet for the cover art

Copyright Khashayar Memarzadeh (1-56)

Paper 1 © LWW Journals

Paper 2 © LWW Journals

Paper 3 © LWW Journals (Authors retain copyrights)

Paper 4 © Open Science Company. LLC (Authors retain copyrights)

Paper 5 © Open Science Company. LLC (Authors retain copyrights)

ISSN 1652-8220

ISBN 978-91-7619-710-3

Lund University, Faculty of Medicine Doctoral Dissertation Series 2018:142

Printed in Sweden by Media-Tryck, Lund University

Lund 2018



MADE IN SWEDEN 

Media-Tryck is an environmentally
certified and ISO 14001 certified
provider of printed material.
Read more about our environmental
work at www.mediatryck.lu.se

Look deep into nature, and then you will understand everything better.

- Albert Einstein

Table of Contents

Table of Contents.....	8
Abstract	10
Papers included in this thesis	11
Thesis at a glance	12
Introduction	13
Perfusion monitoring.....	14
Clinical tests	15
Chemical techniques.....	15
Radioactive isotopes.....	16
Hydrogen gas clearance.....	16
Skin temperature probes and thermography.....	17
Tissue oxygen tension	17
Spectroscopy	18
Laser-based techniques.....	18
Radiological techniques.....	20
Aims	21
Methods	23
Ethical considerations	23
Animal preparation.....	23
Perfusion measurements.....	24
Laser Doppler velocimetry	24
Laser speckle contrast imaging	25
Limitations of laser-based techniques	26
Tissue oxygenation measurements	27
Limitations of oxygenation measurements.....	28
Thermography	28
Limitations of Thermography.....	29

Tarsoconjunctival flaps	29
Human study	31
Free eyelid composite graft.....	32
Random advancement skin flap	33
Full-thickness eyelid axial flap	34
Results and discussion	35
Tarsoconjunctival flaps and free eyelid composite grafts	35
Random advancement skin flaps.....	39
Full-thickness eyelid axial flap	42
Conclusions	45
Populärvetenskaplig sammanfattning Popular scientific summary in Swedish	47
Acknowledgements	51
References	53

Abstract

Existing oculoplastic reconstructive surgical techniques are based on empirical knowledge and were established long before perfusion monitoring was possible. It is believed that an avascular graft should always be placed on a vascular bed or flap and also that the viable length of a flap depends on the width of its pedicle. The actual role of the length, width and thickness of a random flap in its survival is still not clear. Modern imaging techniques now enable monitoring of perfusion and reconsideration of how to optimize the reconstructive surgical procedures. In the present thesis, different surgical techniques were studied, namely tarsoconjunctival flaps using the modified Hughes procedure, random pattern skin advancement flaps and full-thickness eyelid axial flaps. Perfusion was assessed using laser Doppler velocimetry, laser speckle, thermography and tissue oxygenation (pO₂) measurements.

The results from the tarsoconjunctival flaps in pigs (Paper I) showed that perfusion decreased gradually during dissection and advancement of the tarsoconjunctival flap. At the time when the flap was sutured into place, there was virtually no perfusion or oxygenation of the distal end of the flap. A recent study shows that the same is true for tarsoconjunctival flaps in patients (Paper II). Using a free eyelid composite graft may be an alternative reconstructive surgical technique and this has now been performed in a first case (Paper III).

The results from the random pattern advancement skin flaps in pigs (Paper IV) show that the flap length may be more important than the length to width ratio. Perfusion decreased gradually from the base to the tip of the flap, reaching ~20% at 2.5 cm from the base of the flap, with virtually no perfusion 3.0 cm from the base of the flap. Making the flap longer does not seem meaningful and a free transplant may then be considered. The length to width ratio of the flap did not determine perfusion or oxygenation. Perfusion was preserved to a greater extent in the thick flaps (~40%) than in the thin flaps (~20%).

On the other hand, a full-thickness composite eyelid flap (paper V), which is an axial flap, there is only a slight decrease in perfusion. The results support the view that plastic surgery of the eyelids is permissive, and the rich vascularization of the eyelid due to the anastomotic network of vessels in the tarsal plate may increase the likelihood of flap survival and surgical success.

In conclusion, modern techniques enable detailed flap monitoring and opens opportunities to optimize some surgical procedures.

Papers included in this thesis

This thesis is based on the following five papers, which will be referred to in the text by their Roman numerals. The papers are reproduced with the permission of the respective publisher.

- I. **Memarzadeh K**, Gustafsson L, Blohmé J, Malmsjö M. Evaluation of the microvascular blood flow, oxygenation, and survival of tarsoconjunctival flaps following the modified hughes procedure. *Ophthal Plast Reconstr Surg*. 2016 Nov/Dec;32(6):468-472.
- II. Tenland, K, **Memarzadeh K**, Berggren, J, Nguyen, CD, Dahlstrand, U, Hult, J, Engelsberg, K, PhD, Lindstedt, S, Sheikh, R, Malmsjö, M. Perfusion monitoring shows minimal perfusion from the flap pedicle to the tarsoconjunctival flap. *Ophthal Plast Reconstr Surg*. In press.
- III. ***Memarzadeh K**, Engelsberg K, Sheikh R, Malmsjö M. Large eyelid defect repair using a free full-thickness eyelid graft. *Plast Reconstr Surg Glob Open*. 2017 Jul 26;5(7):e1413.
- IV. **Memarzadeh K**, Sheikh R, Blohmé J, Torbrand C, Malmsjö M. Perfusion and oxygenation of random advancement skin flaps depend more on the length and thickness of the flap than on the width to length ratio. *Eplasty*. 2016 Feb 19;16:e12.
- V. Sheikh R, **Memarzadeh K**, Torbrand C, Blohmé J, Lindstedt S, Malmsjö M. Blood perfusion in a full-thickness eyelid flap, investigated by laser doppler velocimetry, laser speckle contrast imaging, and thermography. *Eplasty*. 2018 Feb 15;18:e9.

*Study III is a case report and not an original publication.

Thesis at a glance

The studies described in this thesis are summarized in the table below.

Study	Aim	Species	Type of flap	Methods
I	To investigate the microvascular blood perfusion, oxygenation, and survival of a tarsoconjunctival flap in an experimental porcine model of the modified Hughes procedure.	Pig	Tarsoconjunctival flap	Laser Doppler velocimetry Tissue oxygenation (pO ₂) measurements Histology
II	To monitor perfusion in tarsoconjunctival flaps in patients with large lower eyelid defects resulting from tumor surgery.	Human	Tarsoconjunctival flap	Laser Doppler velocimetry Laser speckle contrast imaging
III	Case report of a patient with a large upper eyelid defect which was reconstructed using a free full-thickness eyelid graft from the lower eyelid.	Human	Free eyelid composite graft	Clinical observation and follow up
IV	To investigate the relationship between the dimensions (length, width and thickness) of random advancement skin flaps and retained tissue perfusion in an experimental porcine model.	Pig	Random advancement skin flap	Laser Doppler velocimetry Tissue oxygenation (pO ₂) measurements Thermography
V	To study the blood perfusion changes in dissection of an eyelid, to provide a full-thickness eyelid flap.	Pig	Full-thickness eyelid axial flap	Laser Doppler velocimetry Laser speckle contrast imaging Thermography

Introduction

Plastic surgery is concerned with restoration of form and function of the human body. It is used in the repair and reconstruction of defects following damage or loss of tissue from injury or disease or from their treatment. It is used in the correction of congenital deformities. It also includes aesthetic or cosmetic surgery, which involves the treatment of developmental or naturally acquired changes in body. There have been many advances in plastic surgery in recent years, one of the most important ones being the recognition and application of several hundreds of cutaneous, myocutaneous and other axial and random flaps. There are different types of flaps. Axial flaps are supplied by a named artery and vein. This allows for a larger area to be freed from surrounding and underlying tissue, leaving only a small pedicle containing the vessels. Random flaps are simpler and have no named blood supply. Rather, they are supplied by generic vascular networks

The modified Hughes tarsoconjunctival flap, a mucosal random flap, is one of the most commonly used techniques for reconstructing the posterior lamella of full thickness eyelid defects after cutaneous malignancy excision. The procedure is indicated for full-thickness lower eyelid defects extending horizontally over more than 60% of the lid length and that cannot be closed effectively with a one-stage procedure, such as a Tenzel semicircular flap. The basic principle of full-thickness eyelid reconstruction is to combine a vascularized flap, which constitutes one lamella, with a free graft providing the other lamella, to preserve the blood supply of the reconstructed tissues. The basic principle of full-thickness eyelid reconstruction is to combine a vascularized flap for one lamella with a free graft for the other lamella, to preserve the blood supply to the reconstructed tissues. Examples of this surgical principle have been described in numerous reports, beyond the modified Hughes procedure. Hawes et al. described the use of free autogenous tarsoconjunctival grafts combined with a skin-muscle flap in humans (1), Stephenson et al. described the use of an autogenous tarsus as a free graft combined with a vascularized skin flap in humans (2), while Beyer et al. reported on a tarsoconjunctival graft combined with a vascularized advancement skin graft from the cheek. Paridaens et al. combined free posterior and anterior lamellar grafts with an orbicularis muscle advancement flap (3), and Hawes et al. compared the outcome of a free tarsoconjunctival graft combined with a mucocutaneous advancement flap, to a Hughes tarsoconjunctival flap with a skin graft (4). Toft

described a method in which a free tarsal plate graft and a laterally based myocutaneous pedicle flap were combined with a free skin graft (5). Werner et al described free, full-thickness grafts from the contralateral eyelid in humans combined with a vascularized orbicularis flap, a technique first described by Putterman in 1978 (6, 7).

Existing reconstructive surgical techniques are based on empirical knowledge, and were established in the early 1900's, long before tissue imaging and perfusion measurements was possible. It is believed that an avascular graft should always be placed on a vascular bed or flap and also that the viable length of a flap depends on the width of its pedicle. The actual role of the length, width and thickness of a random flap in its survival is still not clear. Modern techniques now enable non-invasive monitoring of perfusion and oxygenation during reconstructive surgical procedures. The implementation of modern imaging and monitoring techniques is a necessity for the development of effective reconstructive surgical procedures. This can lead to improved surgical outcomes, which benefit both the patients and the health care service, with fewer and easier interventions, and fewer complications.

In the present thesis, three principally different surgical techniques were studied, namely tarsoconjunctival flaps using the modified Hughes procedure, random pattern skin advancement flaps and full-thickness eyelid axial flaps. Laser Doppler velocimetry. Laser speckle monitoring, tissue oxygen concentrations measurements and thermography, to monitor perfusion.

Perfusion monitoring

Accurate assessment of the blood perfusion of tissue transfers has always been a challenge. The complex flap microcirculation are difficult to assess, despite all the subjective and objective examination techniques available today.

The aim of per/post-operative surveillance is the early recognition of flap compromise to improve chances of flap salvage and lower morbidity and mortality rates.

Different types of tissue transfer today have a high success rate, which is partly due to the monitoring of flap/graft circulation post-operatively. Recent advances in technology and improvements in surgical technique have led to reported success rates of between 95% and 98%.

Blood perfusion monitoring peroperatively also helps us to have a better understanding of different reconstructive surgical techniques which will lead to optimizing our surgical techniques for a better clinical outcome.

Clinical tests

Of the techniques currently available to monitor grafts and flaps post-operatively, clinical assessment is the most commonly used (8). Clinical tests consist of monitoring skin colour of the flap, skin turgor, surface temperature, capillary refill time and bleeding time following pinprick. Clinical tests are cheap, non-invasive and repeatable. It must be accepted, however, that simple clinical assessment has certain limitations. There is a need for experienced interpretation. Perception of colour is markedly affected by ambient lighting, and transferred skin colour may also be different from that of the recipient site. Subjective assessment of surface temperature is often unreliable (9). Even more importantly, clinical changes may be subtle, initially, and, by the time they are clinically apparent, salvage of the flap may be impossible because of irreversible tissue damage. It has been demonstrated that capillary bleeding on pinprick, in terms of colour (bright red vs cyanotic) and speed (brisk vs slow), is a particularly reliable indication of microvascular status (10).

Chemical techniques

Several chemical techniques for monitoring of free flaps have been used historically. Sodium fluorescein is a hygroscopic orange–red powder, readily soluble in water, which assumes an intense yellow–green colour, visible by the naked eye, when viewed under a Wood’s lamp in a darkened room. It is an organic dye that is injected intravenously to monitor skin perfusion. The fluorescein test involves the injection of sodium fluorescein, intravenously, at 15 mg/kg for 1 min. The dye diffuses across the capillary wall to the extracellular fluid compartment within 10–15 min but does not penetrate cells. The distribution is then observed. The result can even be photographed with a blue filter to allow a record to be kept. The technique is relatively straightforward and inexpensive but is cumbersome to perform, and allergic reactions can occur (11). This technique is (12) only suitable for the monitoring of cutaneous tissue transfers. In addition, it allows only a single assessment over 24 h, because the high dose of dye required for visual assessment stains the skin for 12–18 h.

These limitations led to the search for a technique that would improve the precision and accuracy of assessing skin flap viability and that would also permit repeated assessments of skin fluorescence post-operatively. Silverman et al. (13) reported in 1980 the use of a fiberoptic dermofluorometer for assessment of skin fluorescence in animal models. It was subsequently demonstrated that skin fluorometry could also be used for repeated assessment of skin fluorescence, post-operatively, to allow accurate prediction of skin viability in random pattern skin flaps, island skin flaps and skin free flaps in the rabbit as well as myocutaneous flaps in the pig. More recently, in 1996 Issing and Naumann (8), utilising an animal model, concluded that

fluorescein staining with computer-aided digital morphometry (CADM) represented a more precise predictor of flap survival when compared with pH and temperature monitoring.

Because of the severity of the potential side effects of fluorescein, and its unfavourable pharmacokinetic properties, another fluorescent dye, indocyanine green, with far better pharmacokinetic properties, has been investigated. Initial clinical results were promising (Eren et al., in 1995 (14)). This dye has such diverse uses as monitoring heart function (15) and guiding sentinel lymph node biopsies. Little work has been done with indocyanine green and flap monitoring. Further research is needed before it becomes a practical alternative.

Monitoring of tissue pH levels is a technique that has been utilised in the post-operative assessment of tissue transfers. Impairment of tissue perfusion causes an increase in anaerobic metabolic products and an accumulation of acid metabolites. The resulting increased concentration of hydrogen ions causes a pH drop in the affected tissues. Subcutaneously and intramuscularly placed pH probes have been described. Raskin et al. (16) described three patients in whom there was a pH drop of 0.35 units during the first 2 h post-operatively, which led to free-flap exploration. Clinical observation alone had not yielded this diagnosis. This technique may be particularly useful for muscle flaps because their colour is difficult to observe.

Radioactive isotopes

Radioactive isotopes have been studied as a means of directly measuring tissue perfusion. The basis of the radioactive tracer techniques is centered on the Fick dilution principle. The ideal tracer should be metabolically inert and diffuse between blood and tissue with no significant impairment (Kety, 1951 (17)). Many different isotopes have been used for assessing tissue clearance, such as ^{85}Kr , ^{133}Xe , ^{22}Na and $^{99\text{m}}\text{Tc}$. The major disadvantages were that measurements with this technique could only be repeated once per day, at most, due to remaining background radioactivity, and, like other radioactive techniques, it suffers from the costly problems of radioactive waste decontamination and unavoidable radiation dose to the patient. Continuous monitoring and early intervention for flap salvage failure is not practicable.

Hydrogen gas clearance

The technique of hydrogen gas clearance (Aukland (18) in 1964) is based on the same principle as radioactive tracer clearance. It allowed quantitative measurement of tissue perfusion in millilitres per gram per minute, using an implantable probe in animal models. Glogovac et al. (19) found this technique useful, clinically, in a

small number of patients after finger re-plantation. The advantage of implantable probes is that they can be used for monitoring both superficial and buried flaps. Repeated and quantitative measurements of tissue perfusion are possible in different tissue areas at the same time, and the complete monitoring system is available commercially for a relatively low price.

Skin temperature probes and thermography

Surface-temperature recording is one of the oldest and simplest methods of monitoring free flaps. Its usefulness, however, remains poorly documented, and its problems are poorly understood. Skin temperature can be easily and continually monitored with simple, inexpensive equipment (20), and therefore, much experience has been gathered about temperature monitoring since the 1970s. The perfusion to the skin is related to blood pressure and microcirculation but not in a consistent fashion (21). It can also be influenced by many factors, including core temperature, ambient air temperature, humidity, light and vasomotor responses. There are generally two types of temperature monitors available, namely infrared thermometry for prognostic assessment of pedicled skin and subcutaneous flaps in animals, and thermoelectric thermometers, as described by Jones (9). Cutaneous thermocouples are made of two different metals that produce a small voltage that varies with slight changes in skin temperature. Kaufman's study (22) of muscle flaps suggested that temperature monitoring was not a reliable indicator of flap perfusion unless all environmental influences were monitored and kept absolutely constant so that perfusion was the only variable. Similarly, Issing and Naumann (8) found temperature measurements in their experiments on skin flaps difficult to measure objectively, due to fluctuations in room temperature, convection and individual variations in body temperature. When properly applied and interpreted, large studies have shown the sensitivity of surface-temperature recording to be 98% and its predictive value to be 75%, making it a simple, inexpensive, and reliable technique of free-flap monitoring (23) .

Thermography, using a high-resolution infrared camera, can be used for measurements of tissue temperature (thermal radiation). The camera's thermal sensitivity and resolution allows for measurement of temperature variation at the skin's surface. Change in temperature may be extrapolated to change in perfusion, with an increase in perfusion resulting in increased temperature and vice versa.

Tissue oxygen tension

Tissue oxygen tension is increasingly recognised as a sensitive and reliable index of tissue perfusion, and preliminary studies suggest that it might be of value in the assessment of flap viability. The tissue oxygen tension can be monitored by

implantable or surface probes. The pulseoximeter measures the percentage of oxygen saturation of haemoglobin, using two separate wavelengths of light (660 nm and 940 nm) to distinguish between oxygenated and deoxygenated haemoglobin by light absorption differences.

Mahoney and Lista (24) described in 1980 an implantable and disposable tissue oxygen tension monitor. Their initial experience with the technique suggested that a value of less than 20 mmHg was an indication of vascular compromise and the need for careful appraisal of the flap. This technique is simple in its application, disposable and easily placed in the soft tissue of any flap. The sensor also provides digital data that are easy to interpret. Hirigoyen et al. (25) described in 1997 the use of an implantable microcatheter oxygen sensor in a rabbit model. This sensor (Licox Catheter) was sensitive, rapidly responsive and easily interpreted and can measure continuously the oxygen partial pressure in body fluids and tissues.

Spectroscopy

Spectroscopy based methods like near-infrared spectroscopy (NIRS) or diffuse reflectance spectroscopy (DRS) can be used to determine the degree of oxygenation of the tissue by irradiating the tissue with light in the wavelength range of 500-650 nm, in which the reflection by hemoglobin changes upon oxygenation (26, 27). By measuring the degree of hemoglobin oxygenation, perfused and non-perfused tissues can be distinguished.

Laser-based techniques

Laser Doppler velocimetry (LDV) and laser speckle contrast imaging (LSCI) are two well-known methods for blood perfusion measurements using laser-based technology (28) (29) .

Laser Doppler velocimetry

Laser Doppler velocimetry is a technique for the measurement of blood perfusion, and it has been applied extensively to measure perfusion in flaps during plastic surgery procedures (30). The skin is illuminated by a beam of laser light using a fiber-optic probe. Light reflected by moving blood cells undergoes a change in wavelength, i.e. the Doppler shift, while light reflected from static objects is unchanged (31). The change in wavelength is interpreted as the velocity of blood cells, i.e. perfusion (32). However, invasive probes must be used to obtain reproducible results, and it is only possible to study the perfusion in a very small region ($\sim 1 \text{ mm}^3$ surrounding the probe) (33). LDV is frequently used to measure

perfusion in flaps during surgery (30), especially plastic surgery. The measurement depth of LDV, in forearm skin, is about 1 mm (31).

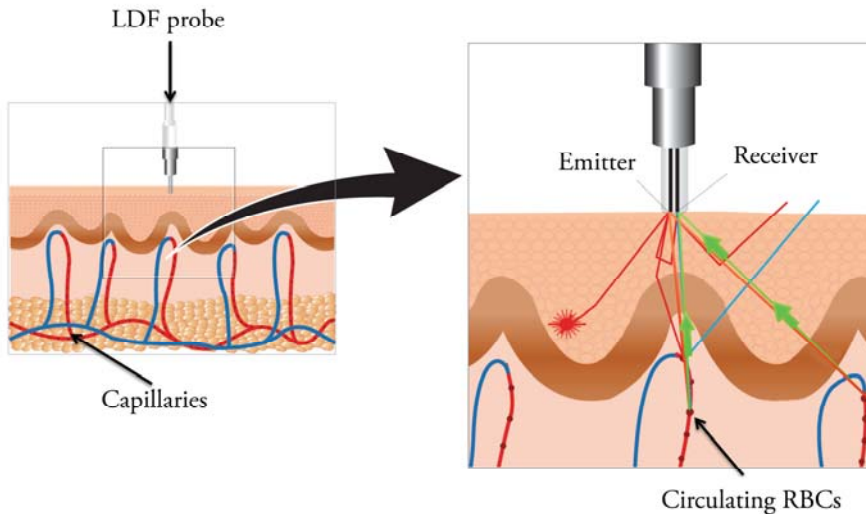


Figure 1

The basic principle of laser Doppler flowmetry. Laser light is emitted into the tissue (red beams). Most of the light is absorbed or reflected in the tissue (red and blue beams), but some of the light is reflected back to the laser Doppler probe (green arrows). Light impinging on a moving object such as a red blood cell (RBC) undergoes a Doppler shift. The figure is used with permission from Perimed AB Sweden.

Laser speckle contrast imaging

A more recently developed non-invasive technique is LSCI. The object is illuminated by laser light, and the backscattered light, which forms a random interference pattern called a speckle pattern, is used to determine perfusion (34). Movement, such as the flow of red blood cells in a tissue, causes the speckle pattern to change, allowing the blood perfusion to be quantified. LSCI is a fast, full-field technique for the imaging of microvascular perfusion (33). Current LSCI equipment can produce representative images of the perfusion in the surface of tissue over a relatively large area (up to 24 x 24 cm). LSCI is now an established technique in, for example, experimental vascular brain research and plastic surgery.

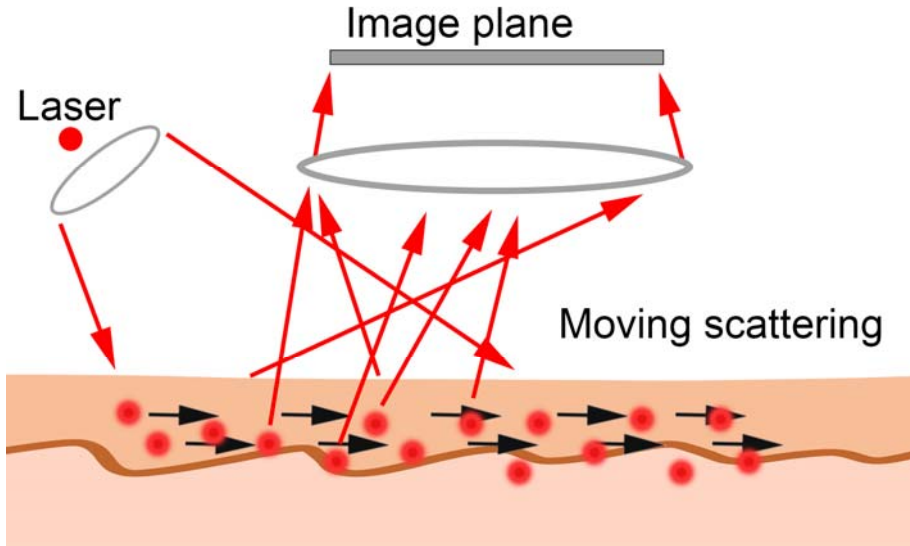


Figure 2

The basic principle of laser speckle contrast imaging. The object is illuminated by laser light, and the backscattered light, which forms a random interference pattern which is called a speckle pattern, movement, such as the flow of red blood cells in a tissue, causes the speckle pattern to change allowing the blood perfusion to be determined.

Radiological techniques

A small group of experimental radiological techniques has been described in the literature to monitor free-tissue transfers, using magnetic resonance imaging. Magnetic resonance imaging (35) and nuclear magnetic resonance spectroscopy have been shown to be experimentally useful for examining microsurgical flaps; however, these techniques are too complicated and impracticable for clinical use at present.

Aims

The principal aims of the work presented in this thesis were to investigate the blood perfusion changes during the surgical preparation of different flaps and to explore the possibility of optimizing our surgical technique by doing so.

The specific aims were:

- To investigate the perfusion, oxygenation, and survival of a tarsoconjunctival flap.
- To investigate the relationship between the dimensions (length, width and thickness) of random advancement skin flaps and retained tissue perfusion.
- To study the blood perfusion changes in dissection of an eyelid, to provide a full-thickness eyelid axial flap.
- To investigate the impact of different perfusion measurement techniques, including laser Doppler flowmetry, tissue oxygenation (pO_2) measurements, laser speckle contrast imaging and thermography on understanding the above and optimization of our surgical techniques.

Methods

Ethical considerations

Study I, IV and V were carried out in a porcine model. The experimental protocol for these studies was approved by the Ethics Committee for Animal Research at Lund University, Sweden. It shall be noted that we plan and combine our experiments in order to reduce the number of animals required. Each animal was used for different purposes; in these cases, experimental studies were performed at different wound locations, in the same animal. Using a single animal for several purposes reduces the number of animals needed drastically but must always be weighed against the possibility of interference between experiments. We cannot be certain, but we do not believe that using the same animal for different experiments has affected the results of these studies. However, it is important for the reader to know that the animals have been used for more than one purpose. Refining the experiments is a continuous process. The animals are fully anesthetized throughout the whole experiment. Heart rate, respiratory rate, breathing reflex, eye-lash reflex and muscular response are continuously monitored to ensure that the level of anaesthesia is adequate. The animals never regain consciousness after the experiments but are euthanized by an intravenous bolus dose of potassium chloride.

Study II was performed in patient and study III describes a case report of a patient. The study protocol for study II was approved by the Ethics Committee at Lund University, Sweden. All patients included in the studies (II and III) gave their fully informed consent. The research adhered to the tenets of the Declaration of Helsinki as amended in 2008.

Animal preparation

The research described in this thesis could not be carried out using an *in vitro* model. A porcine model was therefore chosen, as the properties of their skin are comparable to those of humans. Smaller animals such as rabbits, rats, and mice are often used in reconstructive surgery studies as they are less expensive, and easier to handle. However, the skin of smaller animals differs from human skin in several respects.

For example, small animals have a thick layer of fur, and a thinner epidermis and dermis, while pigs have an epidermis and dermis of about the same thickness as humans. Moreover, porcine dermal collagen is similar to that in humans (36). Thus, the pig offers the best model of humans with regard to skin anatomy and physiology.

The pigs were healthy, with a mean body weight of 70 kg. Reconstructive surgery were made under general anaesthesia, which was maintained throughout the experiments. At the end of each experiment a lethal dose of potassium chloride was administered intravenously. Detailed descriptions of the animal preparation and the anaesthesia can be found in the respective papers.

Perfusion measurements

Laser Doppler velocimetry

Perfusion was measured by laser Doppler velocimetry, in Studies I, II, IV and V, using a 4-channel Perimed PF5010 unit (Perimed, Stockholm, Sweden). The present experiments were performed using filament probes. The filament probe (MT A500-0 straight microtip with slanted tip; Perimed, Stockholm, Sweden) was attached to a master probe (Probe 418), which was then connected to the laser Doppler equipment. The filament probe was 120 mm in length and had a 0.5 mm flexible microtip. The distal end of the tip has been polished to give it a slight angle to improve its optical properties. The probe was inserted into the tissue with a 22 G venflon infusion cannula. The filament probe was inserted through a cannula and the cannula was then withdrawn approximately 5 mm to expose the tip of the probe to the tissue. The probes were then connected to the laser Doppler equipment. Data were recorded continuously. Perfusion is given in arbitrary units (perfusion units, PU). One way of controlling the problem with movement artefacts is to make sure that the recordings are zero when there is no perfusion, as in the present work, after the perfusion to the pedicle of the flap have been mechanically occluded. For details see Studies I, II, IV



Figure3
The experimental setup using laser Doppler and filament probes.

Laser speckle contrast imaging

Perfusion was measured by laser speckle contrast imaging, in Studies II and V. A LSCI system (PeriCam PSI HR System, Perimed) was used to obtain images of perfusion over the surface of a larger tissue area (24 x24 cm). The system uses a 785-nm invisible laser beam that is spread over the skin surface by a diffuser creating a speckle pattern. A speckle pattern is the pattern of dark and bright areas formed by random interference in the backscattered light of the area illuminated by laser. Blood perfusion is calculated by analyzing the variations in the speckle pattern. The speckle pattern is recorded in real time at a rate of up to 100 images per second, with a high resolution of 100 $\mu\text{m}/\text{pixel}$, resulting in an instantaneous image of the motion of red blood cells (interpreted as perfusion). For details see Studies II and V.

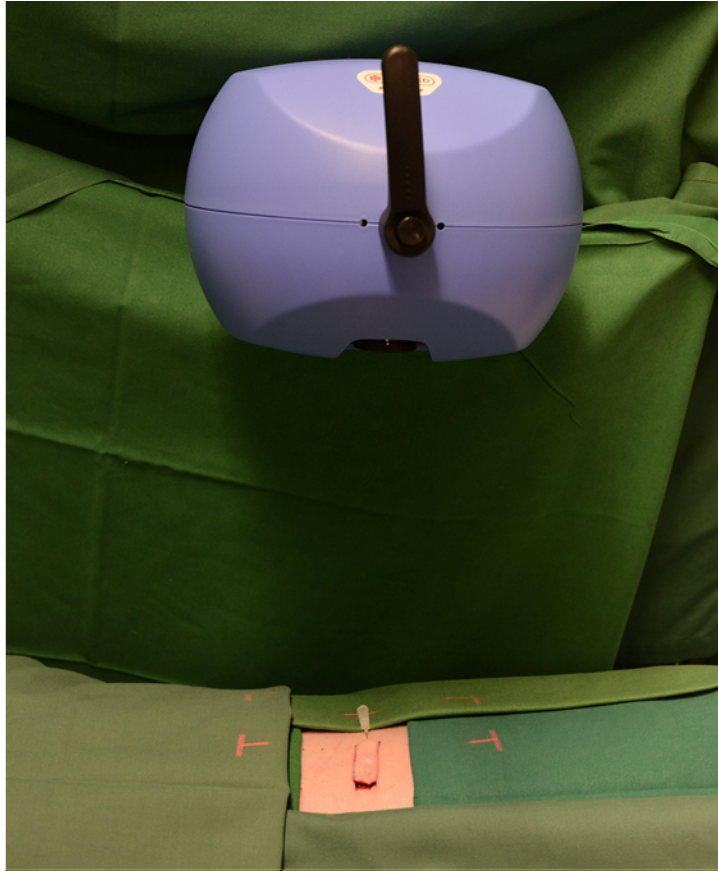


Figure 4
The experimental setup using laser speckle contrast imaging. In this image, perfusion is monitored in a random advancement skin flap on the pig back.

Limitations of laser-based techniques

Although laser-based techniques are widely used to measure perfusion, the use has been criticized (37), as they are sensitive to all kinds of tissue movement, for example due to breathing or heartbeats. For LDV, it is therefore vital to ensure that the probes are properly anchored in the tissue, and to reduce involuntary movements. Furthermore, LDV uses a small sampling volume (about 1 mm³) (38), which means that the technique only provides information on the perfusion in a very small region surrounding the probe. Thus, the perfusion in the surrounding tissue may be higher or lower than that in the volume being investigated due to variations in vascular density. It is therefore important to use more than one probe, and to supervise the real-time readings of the probes, to avoid non-physiological values. Where possible, it is also important to include other techniques for measuring

perfusion, to confirm the LDV values. This was done in Study I and IV where both LDV and tissue oxygenation was measured. Study II, where both LDV and thermodiffusion were used to measure perfusion. In Study V blood perfusion was measured using, laser LDV, laser speckle contrast imaging and thermography.

Tissue oxygenation measurements

Tissue oxygenation in flaps was investigated in Studies I and IV. The measurements were done using a Licox CC1.SB system (Integra Neuroscience, Saint Priest, France), with a Clarke-type electrode inserted into the tissue using a 22 G venflon infusion cannula. The mechanism with which this probe works is based on oxygen diffusion through an electrolyte chamber, which generates an electrical current. O₂ diffuses through a permeable membrane surrounding the probe. Once inside the probe the O₂ enters into an electrolyte solution within the probe which creates an electrical current within the solution proportional to the O₂ tension of the blood/tissue being measured. This charge carried to the external Licox monitor display which converts the electrical current to mmHg and displays the PbtO₂. The unit is calibrated with each use through a “smart card” that is found on the packaging of the catheters themselves and inserted into the external monitor prior to use. The suitability and reliability of this probe have been demonstrated previously (39-41). For details see Studies I and IV.




Figure 5

The Licox system for monitoring oxygen tension by a Clarke-type electrode inserted into the tissue.

Limitations of oxygenation measurements

Clarke-type electrode is rather large (approximately 1 mm) in diameter and may thus apply pressure on the surrounding tissue as it is introduced in the tissues. Another limitation is that the change in electrolyte balance occurs relatively slowly and there is a time lag in the recordings.

Thermography

Tissue temperature (thermal radiation) measurements were performed in Study IV and V using a high-resolution IR camera (FLIR A655sc; FLIR Systems AB, Danderyd, Sweden). The IR camera was placed approximately 50 cm above the animal, on a Manfrotto 244 Variable Friction Magic Arm that was mounted on a Manfrotto 190 series tripod. The software ThermaCAM Researcher Pro 2.10 from FLIR Systems was installed in a laptop PC, and used for IR image capturing and post processing. The IR camera was connected to the laptop through the Ethernet interface using a two-meter shielded Ethernet cable. The camera's thermal sensitivity and resolution allows for measurement of temperature variation at the skin's surface. Change in temperature may be extrapolated to change in perfusion, with an increase in perfusion resulting in increased temperature and vice versa. For details see Study IV and V.

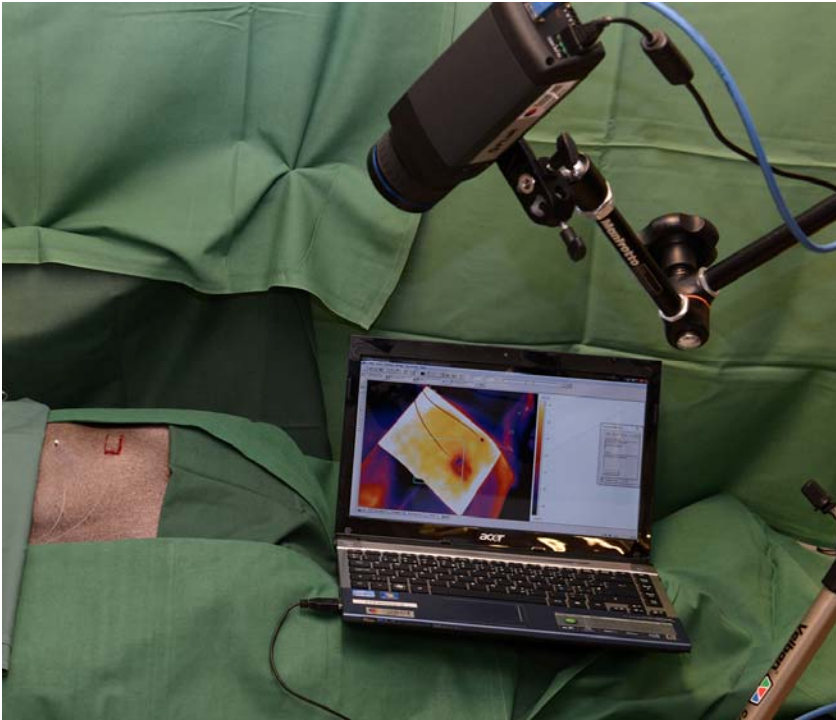


Figure 6
Thermography of a flap on the pig back using a high-resolution IR camera.

Limitations of Thermography

The change in skin temperature is believed to be proportional to changes in microcirculation, but may also be by other metabolic processes in the cells such as inflammatory responses and thermoregulatory enzymes. However, this limitation may be of less importance for interpretation of the present results, since the focus was on temperature changes rather than actual temperature.

Tarsoconjunctival flaps

Porcine study

In Study I, a lower eyelid defect was created in a porcine model measuring 15 to 21 mm horizontally and 8 to 10 mm vertically. The lower eyelid was reconstructed using a modified Hughes flap procedure. A cannula was introduced into the edge of the tarsal flap, just posterior to the tarsus, but anterior to the tarsal conjunctiva, for laser Doppler and tissue oxygenation measurements. The flap was sutured to the

lower eyelid defect using 6-0 Vicryl sutures. laser Doppler and tissue oxygenation measurements were performed at different steps of lengthening the flap and concluded by occluding the blood supply to the pedicle of the flap was using a suture (Figure). After the full surgical procedure, had been completed, the eyelid was allowed to stabilize for 12 hours before that last registration of perfusion and oxygenation were made and the pig was euthanized. No experiments were made beyond 12 hours. For detailed study protocol see Study I.

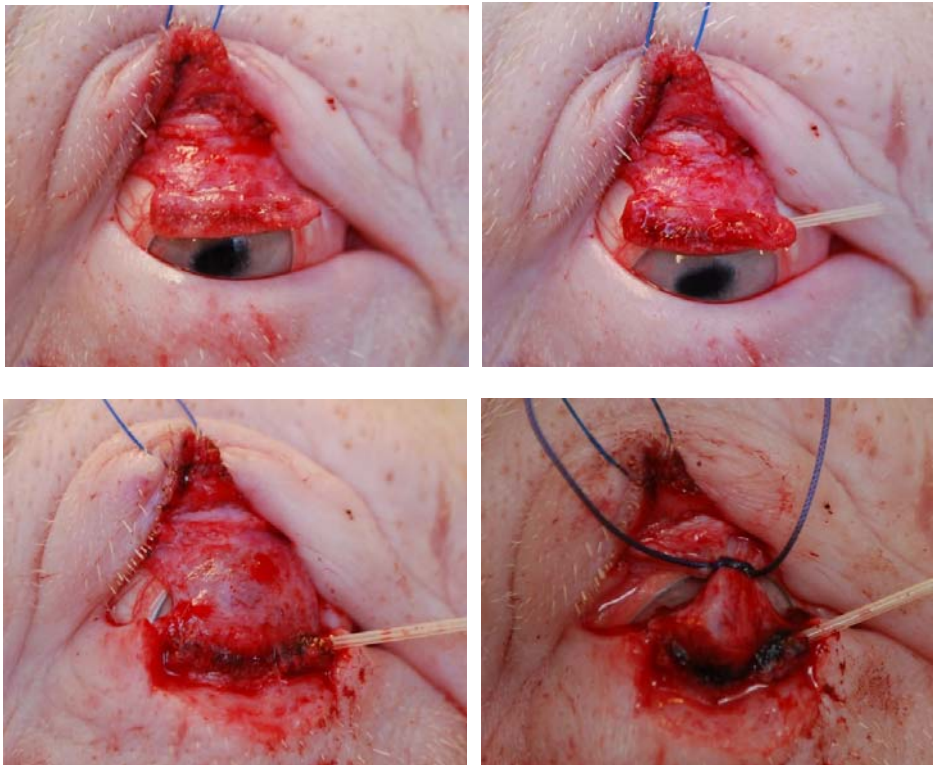


Figure 7

Reconstruction of the lower eyelid using a modified Hughes flap procedure in a pig. The top left image shows how the tarsus was incised from the conjunctival side, 2 mm above and parallel to the eyelid margin. Two vertical tarsal incisions were made at each end of the horizontal incision, towards the upper border of the tarsus. A pedicle of conjunctiva and Muller's muscle was raised. The top right image shows how a cannula, for introducing laser Doppler and pO₂ measurement's probes, was introduced into the lower edge of the tarsal flap, just posterior to the tarsus, but anterior to the tarsal conjunctiva. The bottom left image shows how the flap was sutured to the lower eyelid defect using 6-0 Vicryl sutures. Oxygenation and microvascular perfusion in the flap were measured after the tarsalconjunctival flap had been dissected to different lengths. The bottom right image shows how mechanical occlusion of perfusion was performed using a ligature.

Human study

In Study II, eleven patients were recruited from among patients admitted to the department of ophthalmology, Skåne University Hospital. The inclusion criterion was lower eyelid defects after surgery large enough to require a tarsoconjunctival flap. The lower eyelid defects were reconstructed using a modified Hughes flap procedure as follows. Perfusion measurements were carried out on the first two patients using laser Doppler velocimetry (LDV), while laser speckle contrast imaging (LSCI) was used on the remaining nine patients. The reason for this was that the LSCI equipment became available after the first two patients had been examined. The advantage of LSCI is that the perfusion can be visualized over a larger area, and it is non-invasive. Measurements were also made after applying gentle, but sufficient, pressure to occlude the perfusion to the flap. This was done to obtain a value for zero perfusion, as both laser-based techniques measure the perfusion in arbitrary units, rather than absolute units. During the perfusion measurements, the flap was stabilized with a suture but without applying any noticeable traction. A medium size corneal shield was used to protect the eye from the laser (Ellman international, inc, Oceanside, NY). A thin plastic shield was applied under the flap to prevent interference due to the laser signal resulting from perfusion in the underlying tissues. After completion of the perfusion measurements, the tarsoconjunctival flap was sutured to the lower eyelid defect in order to reconstruct the posterior lamella. The anterior lamella was thereafter reconstituted using a free skin transplant from the upper eyelid or the arm (Figure). For detailed study protocol see Study II.

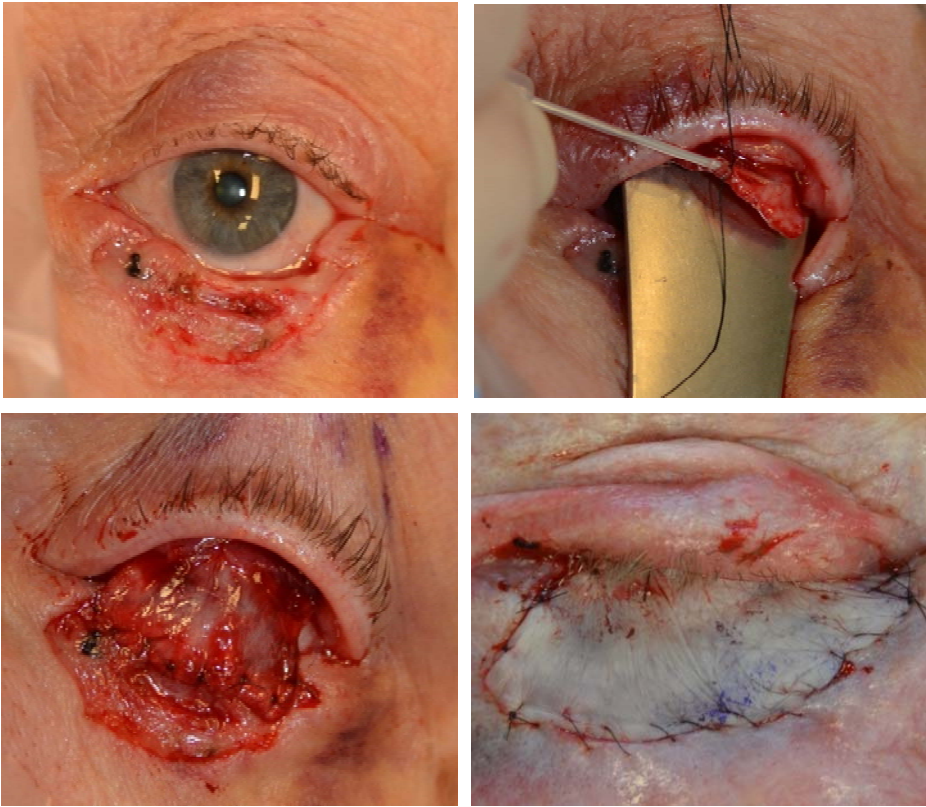


Figure 8

Lower eyelid defect following tumor surgery reconstructed using a modified Hughes flap procedure. Perfusion was measured using laser Doppler velocimetry in this patient.

Free eyelid composite graft

Study III is a case of a 60-year-old male who required extensive excision of the left upper eyelid (50% of the width) due to squamous cell carcinoma *in situ*. The upper eyelid defect was reconstructed using a free full-thickness eyelid graft (a mucocutaneous-tarsoconjunctival graft without a pedicle) from the lower eyelid (Figure). This was done since the patient wanted to avoid the occlusion of vision associated with a Cutler Beard two-stage procedure. He also expressed the desire to minimize the number of surgical interventions, and with the proposed approach there is no need for a second operation to cut the pedicle

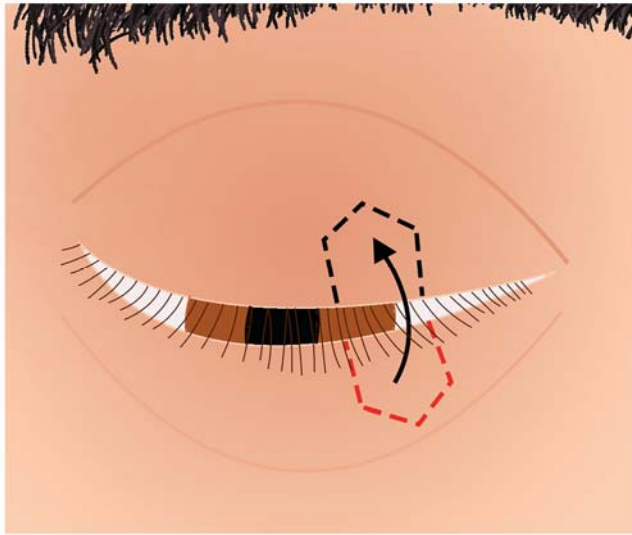


Figure 9

Schematic illustration of how a free full-thickness eyelid graft was excised on the lower eyelid and inserted on the upper eyelid.

Random advancement skin flap

In Study IV, rectangular random advancement flaps of different dimensions were dissected on the pig's flank. Short-term experiments were performed to study the immediate effects of surgery. The flaps were made either 0.5 cm or 1.0 cm wide, and either thin or thick. The thick flaps were dissected all the way through the subcutaneous tissue down to the muscle fascia, giving a thickness of about 0.8-0.9 cm, while thin flaps were only dissected half-way through the subcutaneous tissue, having a thickness about 0.3-0.4 cm. Plastic cannulae were inserted along the length of the flaps, for Laser Doppler and tissue oxygenation measurements. After the perfusion an oxygenation measurements were complete, the blood supply to the pedicle of the flap was occluded using a ligature. This procedure was performed to establish a reference value in which microvascular perfusion and pO_2 were both assumed to be zero. Laser Doppler and tissue oxygenation measurements were performed after 1 and 8 hours. For detailed study protocol see Study IV.

Tissue temperature measurements were performed using a high-resolution infrared camera. Measurements were performed one hour after surgery. Imaging was performed in thin and thick flaps and representative examples were presented.

Full-thickness eyelid axial flap

In Study V, the eyelid was divided with a 10-mm vertical incision at 5mm from the medial canthus, and the incision was extended 30 mm horizontally (Figure) to produce a full-thickness eyelid flap on a pedicle. Both upper and lower eyelids were used in the study. Perfusion was imaged by LDV, LSCI, and thermography at different measurement points as shown in the figure. For detailed study protocol see Study V.

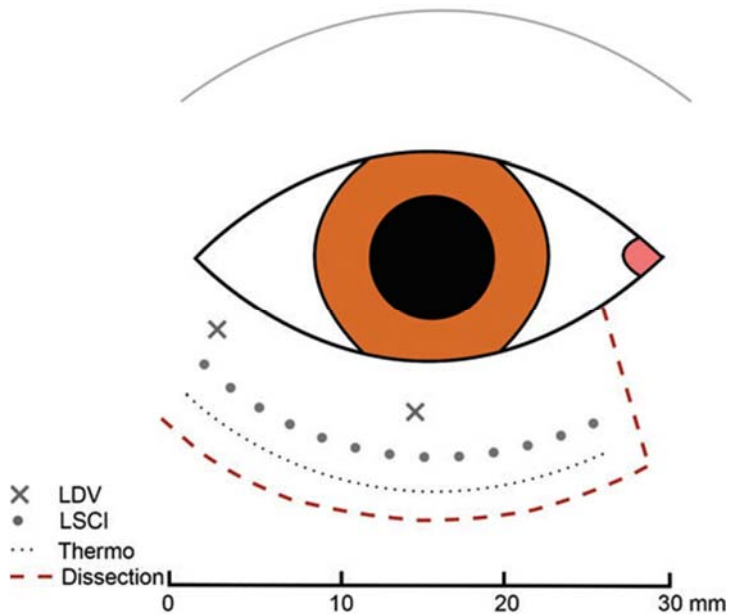


Figure 10

Schematic illustration of the location of the measurement points along the length of a full-thickness eyelid flap (dissection). Blood perfusion was measured using LDV and LSCI. Tissue temperature (Thermo) was measured with a high-resolution infrared camera. LDV indicates laser Doppler velocimetry; LSCI, laser speckle contrast imaging.

Results and discussion

Tarsoconjunctival flaps and free eyelid composite grafts

The results of Study I (pigs) and II (patients) show that there is virtually zero perfusion in the distal end of a tarsoconjunctival flap. In Study I (pigs), perfusion and oxygenation decreased gradually during dissection and advancement of the tarsoconjunctival flap, first to obtain a short flap and then to obtain a long flap. At the time when the flap was sutured into place, there was virtually no perfusion or oxygenation of the tissue. The injection of verapamil into the flap did not ameliorate the hypoperfusion or hypo-oxygenation, ruling out the possibility of surgical vasospasm. Furthermore, the hypoperfusion or hypo-oxygenation was remained unchanged 12 hours after surgery. In Study II (patients), the results of the perfusion measurements were similar using LDV and LSCI, perfusion decreased gradually from the pedicle base to the end of the flap and was 19% at the flap base, 11% in the middle of the flap, and 4% in the distal end of the flap showing minimal perfusion in the distal end of the flap.

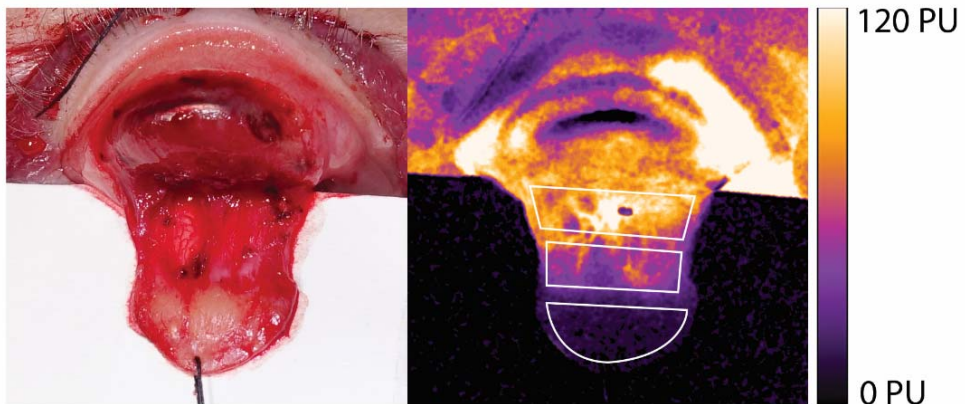


Figure 11

Representative example showing the dissected human tarsoconjunctival flap (left) and corresponding LSCI recording (right). In this case, a few strands of Müller's muscle remain. The areas in which perfusion was measured is shown in the image, i.e. in the proximal, middle, and distal segment of the flap. Note the very low blood perfusion in the distal end of the flap

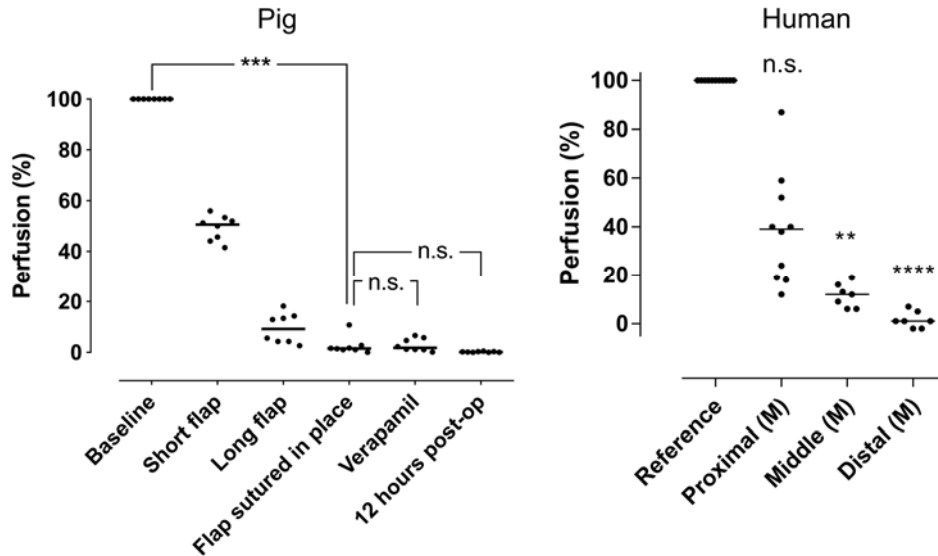


Figure 12

Scatter plots showing the perfusion in tarsokonjunctival flaps in pigs (left graph) and patients (right graph). For the pigs, laser Doppler measurements were performed before dissection (baseline) and on the short flap, long flap, when the flap was sutured in place, after injection with verapamil, and 12 hours after surgery. For the patients, laser Doppler and laser speckle measurements were performed in the proximal, middle and distal parts of the tarsoconjunctival flaps with the remaining strands of Müller's muscle (M). For details, see Studies I and II. Note that there is virtually zero perfusion in the distal end of the flap.

Interestingly, the clinical outcome was excellent in the patients, the flaps survived and there was no tissue necrosis. Likewise, in the pigs, histology showed that there were no pyknotic cell nuclei or other microscopic signs of necrosis in the tarsoconjunctival flap 12 hours after surgery.

We have initiated a study in which the free skin graft that is sused to reconstruct the anterior lamella is monitored using LSCI during the postoperative period. The preliminary results indicate that the graft is perfused within a month.

Day of surgery

After three weeks

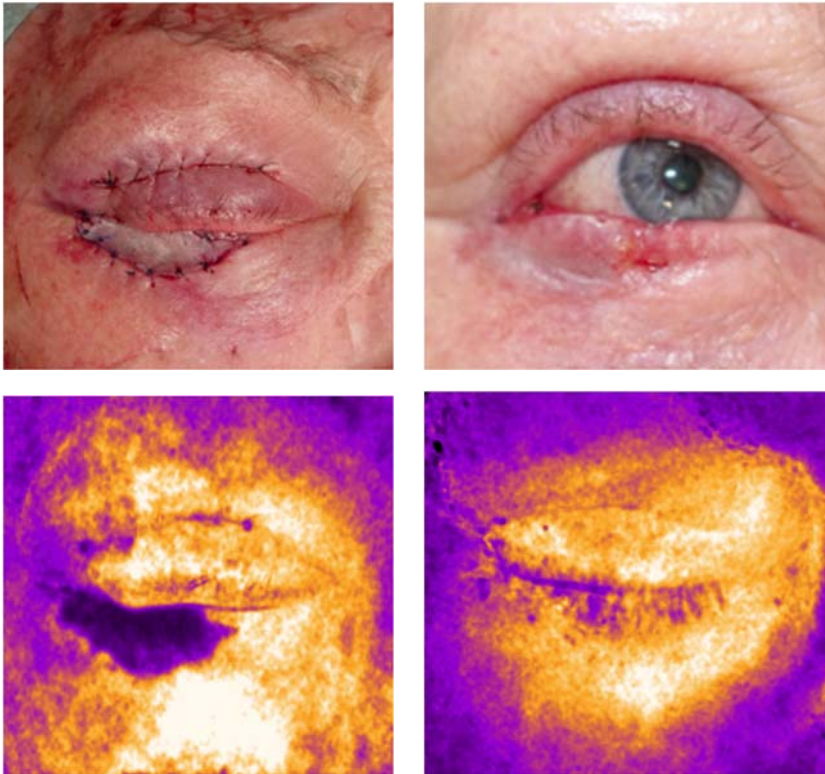


Figure 13

Free skin graft covering a tarsoconjunctival flap according to the modified Hughes procedure. The images show photographs of the free graft on the day of surgery and after three weeks (top) and the corresponding LSCI images (bottom) in one patient. It can be seen that the graft is almost fully perfused after three weeks.

The reason for this excellent flap survival despite lack of perfusion may be that the tarsus and skin graft are nourished by the rich vascular supply of the remaining eyelid, and the conjunctival flap is a secondary, nonessential contributor. Indeed, the extremely rich vascularity of the eyelids has been shown to be surprisingly forgiving, and the tear film has the same spectrum of nutrients as the blood (42). In two studies by McNab and colleagues satisfactory results were achieved when the conjunctival pedicle is divided already two weeks after the initial procedure (43, 44). This finding is consistent with a previous report by Hargiss (45), who proposed that two tubed conjunctival flaps would provide satisfactory vascular support equivalent to an apron flap. Furthermore, Leone and Van Gemert (46) demonstrated that a free tarsoconjunctival graft could survive if covered by a bipedicle skin-muscle flap. Leibsohn and associates (47) intentionally created a small optical

buttonhole in the Hughes tarsoconjunctival flap without compromising the flap. A shorter delay before dividing the conjunctival pedicle has been proposed, especially if a bipedicle orbicularis oculi flap can be mobilized from residual eyelid tissue to provide additional nourishment to the tarsoconjunctival flap (48, 49). Bartley et al., reported on premature flap dehiscence occurring 1 to 11 days postoperatively, as a result of accidental trauma in 8 of approximately 100 patients who underwent the modified Hughes procedure. Surgical repair of the dehiscence was unsuccessful and the eyelids were allowed to heal spontaneously (50). The ultimate functional and esthetic outcomes were surprisingly good, and it was suggested that elective division of the conjunctival pedicle could be performed relatively soon after the primary reconstructive procedure (50). Boboridis et al., speculated that a vascularized pedicle may not be necessary for tarsal flaps less than 13 mm in width (51). This suggestion was based on four patients who underwent reconstructive surgery using a combination of a free mucosal graft (one nasal mucoperichondrium and three buccal mucosa) for the posterior lamella and a free skin graft for the anterior lamella (51). All grafts were viable and healed with no signs of ischemia. In a different study, Beyer et al., suggested a single-stage lower eyelid reconstruction procedure (52). Based on these previous reports and the results of the present study, a single-stage grafting procedure of free full-thickness eyelid graft may be a possibility for the future,

Taken together the results of Study I and II indicate that free eyelid composite graft could offer an alternative for the reconstruction of large eyelid defects. Indeed, Study III describes a case in which an upper eyelid defect was reconstructed using a free eyelid composite graft from the lower eyelid of the same eye. No complications arose, and the graft healed well, with excellent functional and cosmetic results. Since that first case another five patients has been operated using a free composite graft. The defect has in all cases been following tumour surgery and the graft has been taken from the lower eyelid of the other eye. The graft has never been more that one centimetre in width and the tension in the eyelids has in most cases been alleviated by Tensel flaps. There has been no complications and the grafts have all held well.

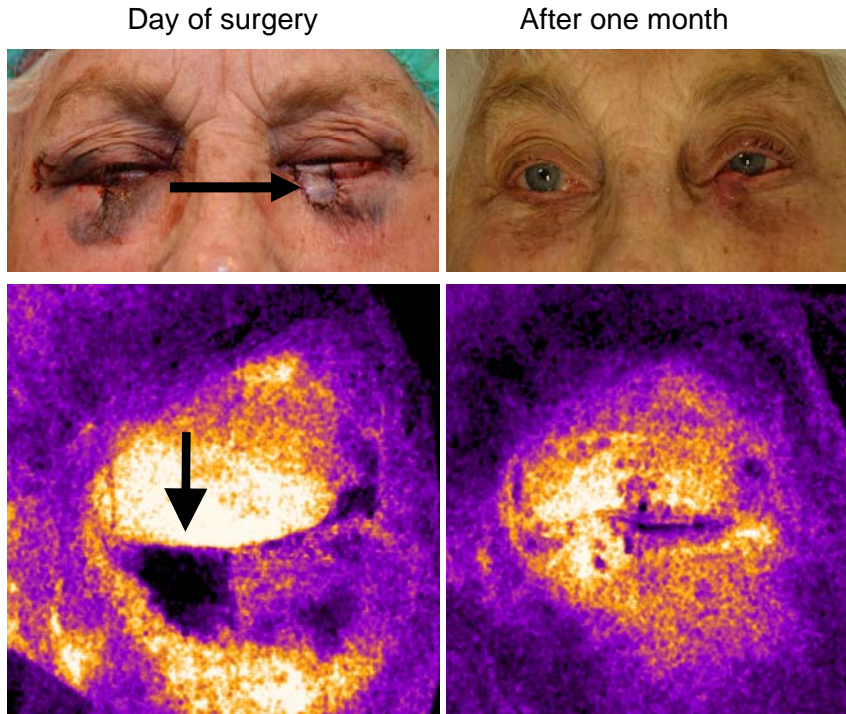


Figure 14

Reconstruction of the left lower eyelid defect following tumour surgery. A free composite graft was taken from the right lower eyelid and the tension was alleviated by bilateral Tensel flaps. The left panels show the day of surgery and the right panel shows one month after surgery. The lower panels are LSCI in which the graft is marked with an arrow. It can be seen that there is no perfusion in the graft at the day of surgery and is completely reperused after a month.

One function of the pedicle in the tarsoconjunctival flap is the vertical lifting during healing by supporting the skin graft of the anterior lamella during healing. However, the disadvantage of this procedure is that the eyelids must be sewn together for several weeks. Occlusion of vision in one eye may be particularly troublesome the patient has poor vision on the other eye. It would also be an advantage to both the patients and the health care organization if the second surgical procedure to divide the flap could be avoided. Furthermore, it has been shown by Klein-Theyer et al. that the Hughes tarsoconjunctival flap may affect the Meibomian glands, causing tear film dysfunction and damage to the corneal surface (53).

Random advancement skin flaps

In clinical practice the design of random advancement flaps is largely determined by empirical rules and it is believed that these should be of constant width to length

ratio (54, 55). A width to length ratio of approximately 1:3 is presumed to ensure adequate perfusion. In study IV we investigated the relationship between the dimensions (length, width, and thickness) of random advancement skin flaps and retained tissue perfusion and oxygenation by laser Doppler velocimetry, tissue oxygenation (pO₂) measurements and thermography. Flaps were raised on the flanks of pigs. The results show that perfusion depend more on the length and thickness of the flap than on the width to length ratio.

Specifically, perfusion decreased gradually from the base to the tip of the flap and was ~40 % of pre-surgical values when measured 2.0 cm from the base, and ~20% when measured 2.5 cm from the base. There was virtually no perfusion nor oxygen tension 3.0 cm from the base.

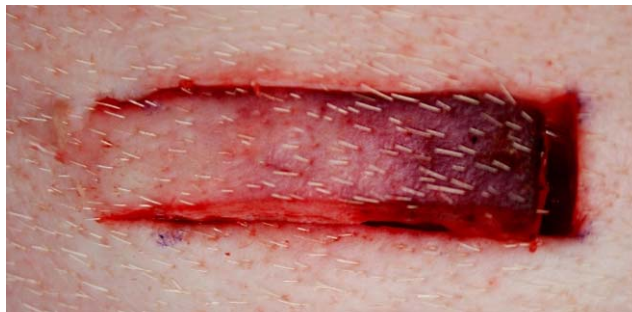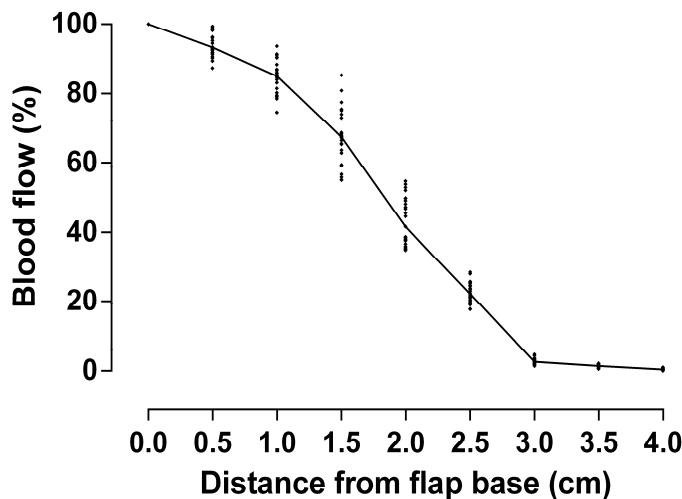


Figure 15

Graph showing blood perfusion at increasing distances from the flap base on the pig flank measured by laser Doppler. Photograph showing a 1 × 4 cm skin flap 1 hour after surgery. It can be seen that approximately the distal 2 cm of the flap is discoloured. The results show the importance of the length of the flap in retaining blood perfusion.

Interestingly, in a follow up study by our research group, on upper eyelid flaps dissected as part of a blepharoplasty procedure, a similar drop in blood perfusion could be seen with distance from the flap base(56).

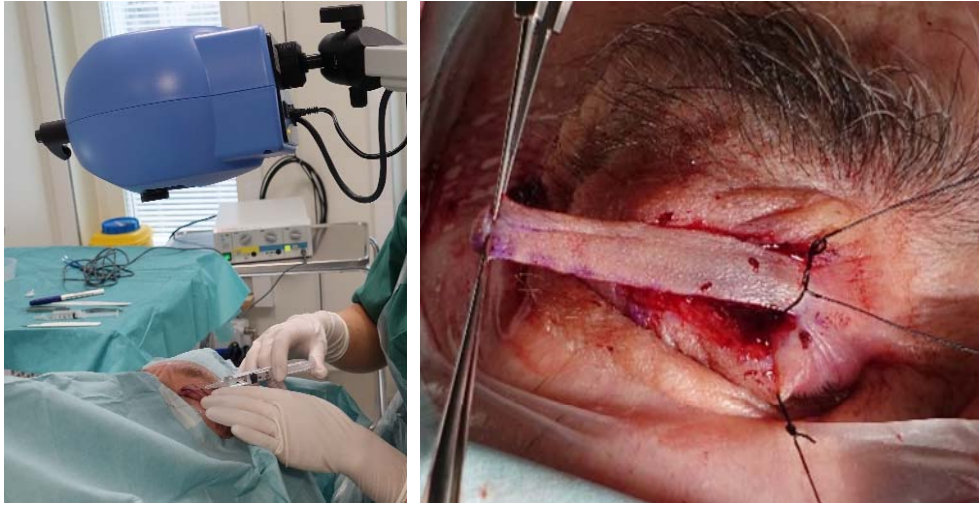


Figure 16
Image from an upper eyelid flap dissected as part of a blepharoplasty procedure and imaged by LSCI. The results were recently published (Nguyen et al. 2018) and are similar to those in the skin flaps in the pig flank

In Study IV, the width to length ratio of the flap did not determine the perfusion or oxygenation. For example, in two different flaps, both with a width to length ratio of 1:4, about 30 % of the perfusion was preserved 2 cm from the base in a 0.5 cm wide and 2.0 cm long flap, while no perfusion was seen 4 cm from the base in a 1.0 cm wide and 4.0 cm long flap. Interestingly, the literature suggests that survival cannot be increased by increasing the width of the base.(57) This is supported by the results of the present study, in which perfusion and oxygenation were reduced to ~40 % of the pre-surgical values when the flap was 2.0 cm long and to ~20% when it was 2.5 cm long. Virtually no perfusion was seen in the tip of the flap 3.0 cm from the base. The findings regarding perfusion and oxygenation were supported by the observation of discoloration of the tip of the flap one hour after dissection.

The results of Study IV show that perfusion and oxygenation were preserved to a greater extent in the thick flaps (~40%) than in the thin flaps (~20%) when measured 2.0 cm from the flap base. The thick flap was dissected all the way through the subcutaneous tissue down to the muscle fascia, while the thin flap was only dissected halfway through the subcutaneous tissue. It is well known that the blood supply to random advancement skin flaps is derived from the dermal and subdermal vascular plexuses, and they have no specific vascular pedicle. The perfusion derives from the segmental artery that gives off branches that penetrate the muscle layers

and run into the skin perpendicularly, each branch supplying a small area of skin. The reason that the perfusion is better preserved in a thick flap is probably because the vascular network connected to the pedicle and the flap is larger than in a thin flap.

Full-thickness eyelid axial flap

Dividing the eyelid from its blood supply is common during blepharotomy procedures, entropion repair with, for example, a Quickert procedure, or reconstructive procedures after tumor surgery, for example, Tenzel flap, or “switch flap” that is a full-thickness eyelid flap on a pedicle. No study has yet been conducted to examine how perfusion in an eyelid is affected by dissection, using modern imaging techniques. In Study V, a full-thickness eyelid axial flap was created in a porcine model. Perfusion was assessed using both laser Doppler velocimetry and laser speckle contrast imaging. The results showed a decrease in perfusion over the length of the full-thickness eyelid flaps. However, perfusion is as high as 83% at 10 mm from the pedicle base, 79% at 20 mm, and 80% at 30 mm, indicating good perfusion in the entire flap. The reason for this well-maintained perfusion is presumably that a full-thickness eyelid flaps include all layers (including the anterior and posterior lamellae with skin, the orbicularis muscle, tarsal plate, and conjunctiva) and that it is well vascularized with blood supply through the attachment at the lateral canthus, where a branch of the lateral palpebral artery supplies the tarsal arcades (58-60). A skin flap on the eyelid will have less perfusion as a result of less vasculature entering it, which is shown in one of the research groups recent studies in humans (56). The rich vascular supply of the periorbital region is probably why full-thickness eyelid flap are so permissive, and ischemia and necrosis seldom occur postsurgically (61) It allows the use of surgical reconstructions whose design would be inappropriate in other areas of the body (60-62).

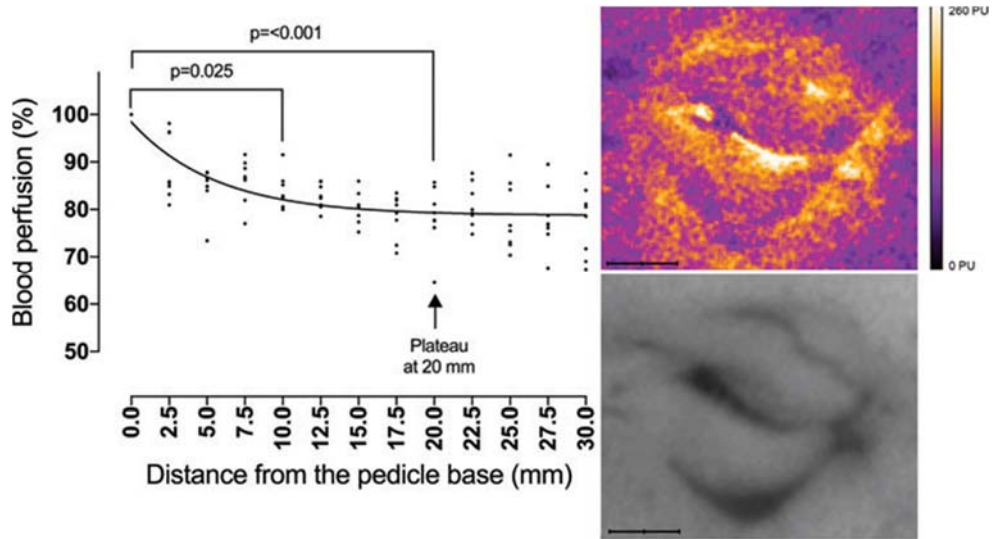


Figure 17

Laser speckle contrast imaging measurements showing a decrease in perfusion along the length of a full-thickness eyelid flap as the percent decrease in blood perfusion at increasing distance from the pedicle base. Nonlinear regression analysis showed that perfusion reached a plateau and stabilized at 20 mm from the base (95% CI, 16-23). Statistical analysis was performed using the Friedman matched-pair test with Dunn's posttest ($n = 8$). The images on the right are representative examples of the laser speckle pattern (top) and the corresponding gray scale image (bottom) of the upper and lower eyelids.

Conclusions

In Study I and II, perfusion was measured using LDV, LSCI in tarsokonjunktival flaps in in pigs and in humans. The results show that the flap pedicle does not contribute to perfusion of the graft. However, this does not appear to compromise graft survival, as we also obtained excellent clinical outcomes. These results are in line with previous findings that dehisced grafts and a free full-thickness eyelid graft also healed well. It may be that the tarsus and skin graft are nourished by the rich vascular supply of the remaining eyelid, and that the conjunctival flap is a secondary, nonessential contributor. If this is indeed the case, single-stage grafting of a free full-thickness eyelid, avoiding the occlusion of vision and a second surgical procedure, may be an attractive alternative for remediating large eyelid defects. Indeed, we have performed a first few cases with a free full thickness composite eyelid graft with excellent clinical outcome, whereof the first case is presented in Study III.

In Study IV, perfusion was measured by LDV, tissue oxygenation (pO_2) measurements and thermography in random advancement skin flaps on the pig back. The results show that the perfusion cannot be predicted by the width to length ratio. Instead, the thickness and length of the flap is of importance.

In Study V, perfusion was measured using LDV, LSCI, and high-resolution thermography in full-thickness eyelid flaps in pigs. The results show that there is only a slight drop in perfusion over the length of the full-thickness eyelid flaps. In total, 80% perfusion is maintained even if the flap was 3 cm long. The good perfusion in the eyelid flaps may be due to the rich vascularization by the anastomotic network of blood vessels in the tarsal plate, which may increase the likelihood of flap survival and surgical success.

Perfusion measurement techniques enables monitoring of plastic reconstructive surgery. The work in the present theses show that LSCI is especially well suited for determining perfusion during surgery. It is an advantage to use multiple techniques to validate the results an in the present thesis we also performed LDV, tissue oxygenation (pO_2) measurements, and thermography.

- LSCI is a non-invasive and easy method of measuring superficial microvascular perfusion in skin, but motion artifacts must be considered.

- LDV is a reliable technique but it can only measure perfusion in a very small tissue volume, and is also sensitive to motion artifacts.
- Tissue oxygenation measurements with Licox catheter was sensitive and can measure continuously the oxygen partial pressure in tissues. It is a promising technique for measuring the characteristics of tissue, but it only provides information on the indirect effects of changes in perfusion.
- Thermography has the potential to quantify changes in perfusion in tissue, but is impractical as it is very sensitive to radiant heat from surrounding sources. Furthermore, metabolic processes in the tissue also control temperature, which makes this technique not so sensitive and slow responding.

Future studies with monitoring reconstructive surgery and understanding perfusion will hopefully result in the optimization of our surgical

Populärvetenskaplig sammanfattning

Popular scientific summary in Swedish

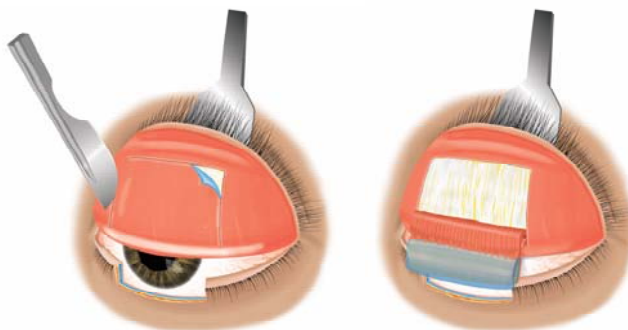
Det mikrovaskulära blodflödet i vävnaden kallas för blodperfusionen. Blodperfusionen transporterar syrgas och näringsämnen till kroppens celler och koldioxid och slaggprodukter bort från cellerna. Det är ett distributionsnät av små blodkärl, som är till för att upprätthålla balans i vävnader och organ i kroppen. Perfusionens betydelse för vävnaders välbefinnande, samt för återhämtning och läkning efter kirurgiska ingrepp, har varit en viktig del i denna avhandling. Det centrala har varit att bedriva forskning som löser kliniska problem och som kan ge direkta förbättringar för patienterna och har gjorts genom mätningar och undersökningar av blodflödet i samband med vissa kirurgiska ingrepp. Detta har bidragit till bättre förståelse för vad som sker i vävnaderna vid dessa operationsmetoder och har givit uppslag till hur de skulle kunna förbättras eller ändras till mer skonsamma ingrepp för patienterna.

Dagens plastikkirurgiska tekniker bygger på empirisk kunskap och fastställdes långt innan perfusionsövervakning var möjlig. Det finns en uppfattning om att avaskulära (utan kärlförsörjning) transplanterat alltid ska placeras på en kärlbädd eller lambå med blodförsörjning för att inte riskera att gå under av syre- och näringsbrist. En annan uppfattning är att en lambå måste göras med ett visst bredd:längd-förhållande för att ha fullgod blodperfusion. Den faktiska rollen av en lambås längd, bredd och tjocklek för dess överlevnad är fortfarande inte klarlagd. Moderna mättekniker möjliggör nu övervakning av perfusionen i vävnaden och optimering av de rekonstruktiva kirurgiska förfarandena.

Jag har studerat olika kirurgiska rekonstruktiva tekniker; (1) tarsokonjunktiv-allambå på både grisar och människor, (2) glidlambå på ryggen av grisar, s.k. *random advancement skin flaps* och (3) glidlambå på ögonlock på grisar, s.k. *full-thickness eyelid axial flaps*. Blodflödet monitorerades med laser Doppler, laser speckle, termografi och syrgastensionsmätningar.

Tarsokonjunktivallambå

En tarsokonjunktivallambå dissekteras fram från insidan av det övre ögonlocket och består av bindehinna (konjunktiva) och kollagenplatta (tarsalplatta). Denna dras sedan ner till nedre ögonlocket för att rekonstruera defekter här, exempelvis efter tumörkirurgi.



Figur 18

Schematisk illustration av en tarsokonjunktivallambå ritad av Jenny Hult.

Det är tänkt att blodförsörjningen sker via små kvarvarande blodkärl från basen i övre ögonlocket. Patienterna behöver därför gå med ögat hopsytt under läkningstiden (3 till 4 veckor). Först när man tror att nya kärl har hunnit växa in i lambå från nedre ögonlocket klipper man av lambå-basen och öppnar ögat. Denna tid har empiriskt ansetts som nödvändig för att lambå ska läka på plats och reperfunderas, men ingen har tidigare undersökt blodperfusionen. Att ha ett öga hopsytt under nästan en månad kan vara ett stort handikapp, speciellt för äldre patienter som kanske redan har nedsatt synförmåga i det andra ögat.

Resultaten från min studie om tarsokonjunktivallambåer på gris (Studie I) visade att blodflödet minskar successivt när man dissekerar fram lambå och när den har sytts på plats i nedre ögonlocket är blodflödet försumbart. Vi gjorde en uppföljande studie på människa som visade samma sak (Studie II). En alternativ kirurgisk teknik skulle kunna vara att istället ta en genomgripande kil av ett ögonlock, ett s.k. fritt transplantat, från den friska sidan. Patienterna skulle då inte behöva ha en synstörande lambå och inte heller behöva komma tillbaka för att klippa upp lambå. Vi har nu gjort några få operationer med denna teknik, varav den första presenteras i en fallbeskrivning (Studie III). Det fria transplantatet läkte fint på plats och det

blev inte några komplikationer. Detta kan vara en ny teknik som man kan använda i framtiden för att underlätta för patienterna.

Random advancement skin flap

I min studie om glidlambåer, *random advancement skin flaps* (Studie IV), ville jag undersöka bredd:längd-förhållandet och tjocklekens betydelse för perfusionen. Resultaten visar att den faktiska längden av en glidlambå är viktigare än längd:bredd-förhållandet. I en lambå som görs 1 cm bred så minskar perfusionen gradvis från basen till spetsen av lambån. 2,5 cm från basen var det bara 20 procent blodperfusion kvar och 3 cm från basen var det praktiskt taget ingen perfusion alls. Det är således ingen vits att göra glidlambåer längre än så utan då kan istället ett fritt transplantat övervägas. Därutöver visade det sig att tjocka lambåer hade bättre perfusion än tunna lambåer, vilket har att göra med att man bevarar en större del av hudens vaskulära nätverk.

Full-thickness eyelid axial flap

Jag studerade även glidlambåer på ögonlock på grisar, s.k. *full-thickness eyelid axial flap* (Studie V), där man inte bara mobiliserar huden utan inkluderar även underliggande muskel, bindvävsplatta och bindehinna. Denna lambå dissekeras ofta fram för att kunna göra t.ex. entropionoperationer eller en rotationslambå för att ersätta en defekt efter en tumör på motsatta ögonlocket. Denna lambå har ett tillförande blodkärl (palpebralarartär) och har därmed bättre blodförsörjning än glidlambåerna i Studie IV. Tre cm från basen var perfusionen hela 80%. Detta har även att göra med att ansiktet generellt är väldigt rikligt vaskulariserat, vilket gör rekonstruktiv kirurgi i ögonområdet förlåtande.

Sammanfattningsvis så kan man med nya tekniker monitorera blodflödet vid rekonstruktiv kirurgi. Genom att klarlägga perfusionen så kan man i vissa fall optimera de kirurgiska tillvägagångssätten

Acknowledgements

I am grateful to all of those with whom I have had the pleasure to work during my PhD project. Each of you has provided me extensive personal and professional guidance and support, and taught me a great deal about both scientific research and life in general. This work would not have been possible without you.

I would especially like to thank:

Malin Malmsjö, my main supervisor, for her invaluable guidance, incredible energy, unending patience, generous friendship and unwavering support. Thinking out of the box and connecting the dots and focusing on possibilities during difficult times has been a big part of why she is the bright shining star of the ophthalmic research community and it has been an honour to have been a member of her team.

Jonas Blohmé, the godfather of oculoplastic and strabismus surgery. He is the artist who asks the questions, gives you the possible answers and let you work hard on it for 5-6 years to come to the conclusion that he had the right answers from the start. It earns you your PhD degree and he will never shy away from giving you a helping hand or advice during the journey.

Karl Engelsberg, my co-supervisor, for always being a great motivator, encouraging and giving valuable advice.

Sandra Lindstedt Ingemansson, Christian Torbrand, Johan Bengzon, for all their valuable guidance.

Rafi Sheikh, research colleague and aspiring surgeon. He is the rising star of this research team and go-to-guy for the technical know-how. I am especially grateful for our interesting and long-lasting chats.

Ulf Dahlstrand, Jenny Hult, Kajsa Tenland, Johanna Berggren, Magdalena Naumovska, Tove Faxén, Cu Ansson, members of our research team and colleagues. I am so grateful for their unfailing support and assistance.

Lotta Gustafsson, research colleague who made histology so much more interesting.

Hans Remanius, colleague. for his understanding and support.

Fredrik Ghosh, professor for his insightful comments and guidance.

Sten Andréasson, professor for his immense knowledge and encouragements.

Björn Hammar, colleague for his vast knowledge of brain and pedagogy. He is also great in winning teaching awards and Bowling trophies.”

Anders Bergström, colleague and maestro. The teacher that opened the door for me and many others, into the world of ophthalmic surgery.

Hans Holmberg, colleague, great surgeon and a perfectionist who is always available when one needs support and good advice.

Sten Kjellström, head of the clinic, for helping me to juggle my way through research and clinical work.

Parviz Memarzadeh and **Nahid Aber** my parents and my biggest fans in life. None of this would have happened without your unconditional love and encouragement.

Maziar Memarzadeh, my brother who has been a great support and help in all matters of life.

Noel, Isabell, Ellie, my children for being the brightest light in my life whenever everything else appears to be dark.

And finally, **Maria Holgersson**, my wonderful, encouraging partner for her never ending support.

References

1. Hawes MJ. Free autogenous grafts in eyelid tarsoconjunctival reconstruction. *Ophthalmic surgery*. 1987;18(1):37-41.
2. Stephenson CM, Brown BZ. The use of tarsus as a free autogenous graft in eyelid surgery. *Ophthalmic plastic and reconstructive surgery*. 1985;1(1):43-50.
3. Paridaens D, van den Bosch WA. Orbicularis muscle advancement flap combined with free posterior and anterior lamellar grafts: a 1-stage sandwich technique for eyelid reconstruction. *Ophthalmology*. 2008;115(1):189-94.
4. Hawes MJ, Grove AS, Jr., Hink EM. Comparison of free tarsoconjunctival grafts and Hughes tarsoconjunctival grafts for lower eyelid reconstruction. *Ophthalmic plastic and reconstructive surgery*. 2011;27(3):219-23.
5. Toft PB. Reconstruction of large upper eyelid defects with a free tarsal plate graft and a myocutaneous pedicle flap plus a free skin graft. *Orbit*. 2016;35(1):1-5.
6. Werner MS, Olson JJ, Putterman AM. Composite grafting for eyelid reconstruction. *American journal of ophthalmology*. 1993;116(1):11-6.
7. Putterman AM. Viable composite grafting in eyelid reconstruction. *American journal of ophthalmology*. 1978;85(2):237-41.
8. Issing WJ, Naumann C. Evaluation of pedicled skin flap viability by pH, temperature and fluorescein: an experimental study. *J Craniomaxillofac Surg*. 1996;24(5):305-9.
9. Jones BM. Monitors for the cutaneous microcirculation. *Plastic and reconstructive surgery*. 1984;73(5):843-50.
10. Dagum AB, Dowd AJ. Simple monitoring technique for muscle flaps. *Microsurgery*. 1995;16(11):728-9.
11. Morykwas MJ, Hills H, Argenta LC. The safety of intravenous fluorescein administration. *Ann Plast Surg*. 1991;26(6):551-3.
12. Kreidstein ML, Levine RH, Knowlton RJ, Pang CY. Serial fluorometric assessments of skin perfusion in isolated perfused human skin flaps. *Br J Plast Surg*. 1995;48(5):288-93.
13. Silverman DG, LaRossa DD, Barlow CH, Bering TG, Popky LM, Smith TC. Quantification of tissue fluorescein delivery and prediction of flap viability with the fiberoptic dermo-fluorometer. *Plastic and reconstructive surgery*. 1980;66(4):545-53.
14. Eren S, Rubben A, Krein R, Larkin G, Hettich R. Assessment of microcirculation of an axial skin flap using indocyanine green fluorescence angiography. *Plastic and reconstructive surgery*. 1995;96(7):1636-49.

15. Utoh J, Kunitomo R, Sakaguchi H, Hagiwara S, Uemura S, Uemura K, et al. [Indocyanine green (TCG) clearance as a monitor to evaluate right heart function]. *Kyobu Geka*. 2000;53(3):212-4.
16. Raskin DJ, Erk Y, Spira M, Melissinos EG. Tissue pH monitoring in microsurgery: a preliminary evaluation of continuous tissue pH monitoring as an indicator of perfusion disturbances in microvascular free flaps. *Ann Plast Surg*. 1983;11(4):331-9.
17. Kety SS. The theory and applications of the exchange of inert gas at the lungs and tissues. *Pharmacol Rev*. 1951;3(1):1-41.
18. Aukland K, Bower BF, Berliner RW. Measurement of Local Blood Flow with Hydrogen Gas. *Circ Res*. 1964;14:164-87.
19. Glogovac SV, Bitz DM, Whiteside LA. Hydrogen washout technique in monitoring vascular status after replantation surgery. *J Hand Surg Am*. 1982;7(6):601-5.
20. Sloan GM, Reinisch JF. Flap physiology and the prediction of flap viability. *Hand Clin*. 1985;1(4):609-19.
21. Tsuchida Y. Rate of skin blood flow in various regions of the body. *Plastic and reconstructive surgery*. 1979;64(4):505-8.
22. Kaufman T, Granick MS, Hurwitz DJ, Klain M. Is experimental muscle flap temperature a reliable indicator of its viability? *Ann Plast Surg*. 1987;19(1):34-41.
23. Khouri RK. Avoiding free flap failure. *Clin Plast Surg*. 1992;19(4):773-81.
24. Mahoney JL, Lista FR. Variations in flap blood flow and tissue PO₂: a new technique for monitoring flap viability. *Ann Plast Surg*. 1988;20(1):43-7.
25. Hirigoyen MB, Blackwell KE, Zhang WX, Silver L, Weinberg H, Urken ML. Continuous tissue oxygen tension measurement as a monitor of free-flap viability. *Plastic and reconstructive surgery*. 1997;99(3):763-73.
26. Thorniley MS, Sinclair JS, Barnett NJ, Shurey CB, Green CJ. The use of near-infrared spectroscopy for assessing flap viability during reconstructive surgery. *Br J Plast Surg*. 1998;51(3):218-26.
27. Kasler M, von Glass W, Albrecht HP, Lang T. [Noninvasive intraoperative measurement of intracapillary hemoglobin oxygenation and relative hemoglobin concentration in surgical skin flaps]. *HNO*. 1990;38(10):375-8.
28. Zotterman J, Bergkvist M, Iredahl F, Tesselaar E, Farnebo S. Monitoring of partial and full venous outflow obstruction in a porcine flap model using laser speckle contrast imaging. *J Plast Reconstr Aesthet Surg*. 2016;69(7):936-43.
29. Jones BM, Mayou BJ. The Laser Doppler flowmeter for microvascular monitoring: a preliminary report. *Br J Plast Surg*. 1982;35(2):147-9.
30. Zografos GC, Martis K, Morris DL. Laser Doppler flowmetry in evaluation of cutaneous wound blood flow using various suturing techniques. *Ann Surg*. 1992;215(3):266-8.
31. Fredriksson I, Larsson M, Stromberg T. Measurement depth and volume in laser Doppler flowmetry. *Microvasc Res*. 2009;78(1):4-13.
32. Leahy MJ, de Mul FF, Nilsson GE, Maniewski R. Principles and practice of the laser-Doppler perfusion technique. *Technol Health Care*. 1999;7(2-3):143-62.

33. Allen J, Howell K. Microvascular imaging: techniques and opportunities for clinical physiological measurements. *Physiological measurement*. 2014;35(7):R91-R141.
34. Yamamoto Y, Ohura T, Nohira K, Sugihara T, Minakawa H, Igawa H, et al. Laserflowgraphy: a new visual blood flow meter utilizing a dynamic laser speckle effect. *Plastic and reconstructive surgery*. 1993;91(5):884-94.
35. Elias DL, Nelson RC, Herbst MD, Zubowicz VN. Magnetic resonance imaging for detection of arterial and venous occlusion in canine muscle flaps and bowel segments. *Ann Surg*. 1987;206(5):624-7.
36. Sullivan TP, Eaglstein WH, Davis SC, Mertz P. THE PIG AS A MODEL FOR HUMAN WOUND HEALING. *Wound Repair Regen*. 2001;9(2):66-76.
37. Kairinos N, McKune A, Solomons M, Hudson DA, Kahn D. The flaws of laser Doppler in negative-pressure wound therapy research. *Wound Repair Regen*. 2014;22(3):424-9.
38. Allen J, Howell K. Microvascular imaging: techniques and opportunities for clinical physiological measurements. *Physiological measurement*. 2014;35(7):R91.
39. Dings J, Meixensberger J, Amschler J, Roosen K. Continuous monitoring of brain tissue PO₂: a new tool to minimize the risk of ischemia caused by hyperventilation therapy. *Zentralblatt für Neurochirurgie*. 1996;57(4):177-83.
40. Maas AI, Fleckenstein W, de Jong DA, van Santbrink H. Monitoring cerebral oxygenation: experimental studies and preliminary clinical results of continuous monitoring of cerebrospinal fluid and brain tissue oxygen tension. *Acta neurochirurgica Supplementum*. 1993;59:50-7.
41. Vassallo S, Hartstein M, Howard D, Stetz J. Traumatic retrobulbar hemorrhage: emergent decompression by lateral canthotomy and cantholysis. *The Journal of emergency medicine*. 2002;22(3):251-6.
42. Jalbert I. Diet, nutraceuticals and the tear film. *Exp Eye Res*. 2013;117:138-46.
43. McNab AA. Early division of the conjunctival pedicle in modified Hughes repair of the lower eyelid. *Ophthalmic surgery and lasers*. 1996;27(6):422-4.
44. McNab AA, Martin P, Bengier R, O'Donnell B, Kourt G. A prospective randomized study comparing division of the pedicle of modified hughes flaps at two or four weeks. *Ophthalmic plastic and reconstructive surgery*. 2001;17(5):317-9.
45. Hargiss JL. Bipedicle tarsoconjunctival flap. *Ophthalmic plastic and reconstructive surgery*. 1989;5(2):99-103.
46. Leone CR, Jr., Van Gemert JV. Lower lid reconstruction using tarsoconjunctival grafts and bipedicle skin-muscle flap. *Archives of ophthalmology*. 1989;107(5):758-60.
47. Leibsohn JM, Dryden R, Ross J. Intentional buttonholing of the Hughes' flap. *Ophthalmic plastic and reconstructive surgery*. 1993;9(2):135-8.
48. Doxanas MT. Orbicularis muscle mobilization in eyelid reconstruction. *Archives of ophthalmology*. 1986;104(6):910-4.
49. Lowry JC, Bartley GB, Litchy WJ. Electromyographic studies of the reconstructed lower eyelid after a modified Hughes procedure. *American journal of ophthalmology*. 1995;119(2):225-8.

50. Bartley GB, Messenger MM. The dehiscent Hughes flap: outcomes and implications. *Transactions of the American Ophthalmological Society*. 2002;100:61-5; discussion 5-6.
51. Boboridis KG. Modified Hughes flap. *Ophthalmology*. 2005;112(12):2239-40; author reply 40-1.
52. Beyer CK, Bathrick ME. One-stage lower eyelid reconstruction. *Ophthalmic surgery*. 1982;13(7):551-4.
53. Klein-Theyer A, Horwath-Winter J, Dieter FR, Haller-Schober EM, Riedl R, Boldin I. Evaluation of ocular surface and tear film function following modified Hughes tarsoconjunctival flap procedure. *Acta Ophthalmol*. 2014;92(3):286-90.
54. Gilies H. *Plastic Surgery of the Face*. Plastic Surgery of the Face: Hodder and Stoughton; 1920. p. 22.
55. Milton SH. Pedicled skin-flaps: the fallacy of the length: width ratio. *The British journal of surgery*. 1970;57(7):502-8.
56. Nguyen CD, Hult J, Sheikh R, Tenland K, Dahlstrand U, Lindstedt S, et al. Blood Perfusion in Human Eyelid Skin Flaps Examined by Laser Speckle Contrast Imaging-Importance of Flap Length and the Use of Diathermy. *Ophthalmic Plast Reconstr Surg*. 2018;34(4):361-5.
57. Stell PM. The viability of skin flaps. *Annals of the Royal College of Surgeons of England*. 1977;59(3):236-41.
58. Codner MA, McCord CD, Mejia JD, Lalonde D. Upper and lower eyelid reconstruction. *Plastic and reconstructive surgery*. 2010;126(5):231e-45e.
59. Erdogmus S, Govsa F. The arterial anatomy of the eyelid: importance for reconstructive and aesthetic surgery. *J Plast Reconstr Aesthet Surg*. 2007;60(3):241-5.
60. Lopez R, Lauwers F, Paoli JR, Boutault F, Guitard J. The vascular system of the upper eyelid. Anatomical study and clinical interest. *Surgical and radiologic anatomy : SRA*. 2008;30(3):265-9.
61. Patrinely JR, Marines HM, Anderson RL. Skin flaps in periorbital reconstruction. *Survey of ophthalmology*. 1987;31(4):249-61.
62. McCord C, Nunnery W. *Reconstructive procedures or the lower eyelid and outer canthus*. Oculoplastic surgery. 1981;New York Raven Press:194-8.

Perfusion Monitoring During Oculoplastic Reconstructive Surgery



Khashayar Memarzadeh was born in Iran. He received his medical degree from Lund University, Lund, Sweden, in 1994. He is an Ophthalmologist and is specialized in cataract, refractive and corneal surgery. Currently his main areas of research interest are oculoplastic surgery and microvascular blood flow.

