



LUND UNIVERSITY

Untreated congenital and posttraumatic high dislocation of the hip treated by replacement in adult age: 22 hips in 16 patients followed for 1-8 years.

Carlsson, Åke; Björkman, Anders; Ringsberg, K; Schewelov, T von

Published in:
Acta Orthopaedica Scandinavica

DOI:
[10.1080/00016470310017677](https://doi.org/10.1080/00016470310017677)

2003

[Link to publication](#)

Citation for published version (APA):
Carlsson, Å., Björkman, A., Ringsberg, K., & Schewelov, T. V. (2003). Untreated congenital and posttraumatic high dislocation of the hip treated by replacement in adult age: 22 hips in 16 patients followed for 1-8 years. *Acta Orthopaedica Scandinavica*, 74(4), 389-396. <https://doi.org/10.1080/00016470310017677>

Total number of authors:
4

General rights

Unless other specific re-use rights are stated the following general rights apply:
Copyright and moral rights for the publications made accessible in the public portal are retained by the authors and/or other copyright owners and it is a condition of accessing publications that users recognise and abide by the legal requirements associated with these rights.

- Users may download and print one copy of any publication from the public portal for the purpose of private study or research.
- You may not further distribute the material or use it for any profit-making activity or commercial gain
- You may freely distribute the URL identifying the publication in the public portal

Read more about Creative commons licenses: <https://creativecommons.org/licenses/>

Take down policy

If you believe that this document breaches copyright please contact us providing details, and we will remove access to the work immediately and investigate your claim.

LUND UNIVERSITY

PO Box 117
221 00 Lund
+46 46-222 00 00

Untreated congenital and posttraumatic high dislocation of the hip treated by replacement in adult age

22 hips in 16 patients followed for 1–8 years

Åke Carlsson, Anders Björkman, Karin Ringsberg and Thord von Schewelov

Department of Orthopedics, Malmö University Hospital, SE-205 02 Malmö, Sweden.

Correspondence: ake.carlsson@orto.mas.lu.se

Submitted 02-04-09. Accepted 02-11-16

ABSTRACT Between 1993 and 2001, we replaced 22 hips in 16 patients with high dislocation of the hip. All but 1 case was due to congenital dislocation. In all cases the femur was osteotomized below the lesser trochanter and a straight uncemented stem inserted in the medullary canal. The acetabular prostheses were inserted at the site of the original acetabulum, usually after augmenting the acetabular rim by using the medial half of the resected proximal femur. The lateral part of the proximal femur with the intact attachment of the gluteus medius muscle was transposed and fixed to the femoral diaphysis thereby restoring direction of muscle pull. The HHS score increased from a median value of 42 points preoperatively to a median of 86 points after median 25 months of follow-up. Limp, which before surgery was severe in all cases, was less marked or had disappeared at follow-up. The legs had been lengthened median 2.5 (1.0–4.5) cm. No postoperative infections occurred. Palsy or loss of sensory function was not observed in any patient.

Dislocation was the commonest complication. It occurred in 3 hips, 2 of which had to be revised to ensure stability.

Untreated, high dislocation of the hip, either congenital or posttraumatic, is a rare condition today. When pain in the hip or lower back becomes hard to bear, hip replacement should be considered. Conventional techniques are not applicable, therefore several other methods have been proposed to restore the anatomy during the last few decades. In

1990, Paavolainen et al. described a new surgical technique which entailed few complications and good abductor strength. We used it in 22 dislocated hips in 16 patients and evaluated the radiographic and functional results.

Patients and methods

Between 1993 and 2001, we replaced 21 hips with untreated congenital dislocation of the hip (CDH) in 15 patients. 15 hips were type C, using Eftekhari's classification (1978) and 6 were of type D. In addition, we replaced 1 hip of type D in a 76-year-old man (case 7) who sustained a traumatic dislocation in his 20ies. 13 were women (19 hips) and 3 men (3 hips). Their median age at surgery was 55 (23–80) years. The time of follow-up was median 25 (8–94) months (Table 1).

Surgical technique

Preoperative planning is important. Templates should be used to estimate a suitable size of the socket and stem and the placement of structural grafts. In almost every case, the femoral osteotomy should be performed in the distal part of the lesser trochanter so as implant the stem correctly and ensure that the trochanteric fragment is long enough to obtain secure fixation to the femoral diaphysis. With these calculations, the leg lengthening will not exceed 4–5 cm.

We followed in all essential details the technique described by Paavilainen et al. (1990, 1993) for

Table 1. Demographic data, prosthetic components and functional results

A	B	C	D	E	F	G	H	I	J	K	L	M	N	O	P	Q	R	S	T
1	F	23	1993	C	Omnifit	BOC	Yes	1.5	78	10	50	44	85	3	1	2	0	19	75
2	F	68	1994	C	Omnifit	BOC	No	3.0	94	10	35	40	67	3	2	3	1	–	–
3	F	80	1996	D	Omnifit	Cone	No	1.0	51	10	25	44	91	3	1	2	0	26	100
4a-sin	F	61	1996	D	Charnley	Cone	No	3.0	69	10	40	44	95	3	0	0	0	25	80
4b-dx	F	62	1997	D	Charnley	Cone	No	1.5	57	20	54	44	95	3	0	–	–		
5	M	54	1998	C	Trilogy	Cone	No	2.5	44	20	42	44	85	3	2	2	0	20	79
6a-sin	F	56	1998	C	Trilogy	Dyspl. II	Yes	4.0	39	10	32	44	92	3	1	0	0	28	68
6b-dx	F	56	1998	C	Charnley	Dyspl. II	Yes	4.5	34	10	32	44	92	3	1	–	–		
7	M	76	1999	D	Trilogy	Cone	No	2.5	34	10	41	40	86	2	2	2	0	25	86
8	F	69	1999	C	Trilogy	Cone	No	2.5	14	10	26	40	64	3	2	2	–	–	–
9a-sin	F	64	1999	D	Trilogy	Dyspl. II	No	3.0	33	20	43	40	70	3	2	2	0	31	64
9b-dx	F	64	1999	C	Trilogy	Cone	Yes	3.5	24	30	53	30	60	3	2	–	–		
10	F	31	1999	C	Trilogy	Cone	No	4.0	26	10	50	44	97	3	1	2	0	17	87
11a-sin	F	34	1999	C	Biomet	Dyspl. I	Yes	2.0	21	10	46	44	95	3	1	0	0	20	75
11b-dx	F	35	2000	C	Trilogy	Cone	Yes	1.5	18	20	61	44	94	3	1	–	–		
12	F	63	2000	D	Trilogy	Cone	No	1.5	22	20	37	44	83	3	2	0	0	39	51
13a-sin	F	25	2000	C	Trilogy	Cone	Yes	3.5	14	10	30	30	69	3	2	0	0	40	33
13b-dx	F	26	2001	C	Trilogy	Cone	Yes	3.0	8	10	31	40	79	3	2	–	–		
14a-sin	F	25	2000	C	Trilogy	Cone	No	1.5	12	20	52	40	80	3	2	3	0	25	n.a.
14b-dx	F	25	2001	C	Trilogy	Cone	No	1.5	8	20	52	44	84	3	2	–	–		
15	F	54	2000	D	Trilogy	Cone	No	1.0	12	10	30	40	86	3	1	0	0	21	85
16	M	47	2001	C	Trilogy	Cone	No	2.0	8	40	68	44	97	2	1	2	0	19	90

Omnifit (Stryker, New Jersey, USA), Charnley (DePuy Int., Leeds, UK), Trilogy (Zimmer, Warsaw, Indiana, USA), Biomet uncemented socket, Dysplastic I and Dysplastic II (Biomet Inc, USA), BOC (Custom-made screw-stem made of pure titanium), Cone (Sulzer Medica, Baar, Switzerland.)

A Case no.
B Gender
C Age at surgery
D Year
E Type of deformity
F Type of primary cup
G Type of primay stem
H Protrusio acetabuli technique
I Increase in leg length on radiograph (cm)
J Follow-up, months
K HHS pain preoperatively
L HHS total preoperatively
M HHS pain postoperatively

N HHS total postoperatively
O Limp preoperatively
P Limp follow-up
Q Back pain preoperatively
R Back pain postoperatively
O–P
0 none
1 slight
2 moderate
3 severe
S Walking speed, sec., at follow-up
T Walking speed, percent of normal
n.a. not available

type C and D dislocations. However, we did not always visualize the sciatic nerve, but kept close to bony structures. In short, the surgical technique includes exposure via a posterior approach, a square osteotomy of the femur 7–9 cm below the tip of the greater trochanter and sagittal osteotomy of the proximal fragment. The lateral part of the proximal fragment with intact attachments of the gluteus medius muscle and the anterior part of the vastus lateralis muscle are held anteriorly. The medial part of the proximal fragment is removed and usually used as a graft to reinforce the rim of the acetabulum. Thereafter, the elongated capsule

is identified and followed down to the original acetabulum, which is very small and shallow in type C. The acetabulum is enlarged posteriorly with curved chisels and thereafter with reamers. We recommend starting with reamers having a diameter of 40–42 mm, and at least in type C hips, the bone stock does not usually allow reamers exceeding 46–48 mm in diameter. Today, we prefer uncemented metal-backed sockets and underreaming of 2 mm (Figures 1 and 2).

If the original acetabulum is too shallow to contain the intended socket size, the medial wall can be detached, pushed medially and packed

with spongy bone before inserting the socket. This so-called “protrusion socket technique”, described by Hess and Umber (1978), creates a controlled fracture. It frequently has to be combined with a solid graft reinforcing the rim of the acetabulum. This technique was used in 7 of our type C cases.

With the technique described above, what remains for anchoring the stem is a straight tube with cortical walls. In type C hips, the canal can be as narrow as 6 mm. For these reasons, we used a straight, uncemented stem with small dimensions in all our cases—usually the Cone design (Figure 3).

After implantation of the components, the leg was abducted and the 7–9 cm long trochanteric fragment advanced distally and fixated to the femur with screws and/or cables. In 6 cases, only cables were used, in 5 cases, 2–3 screws and in 11 cases, both cables and 1–2 screws. Today, we prefer 3 cables (Zimmer, Warsaw, Indiana) without screws.

Bilateral cases were operated on with an interval of about 4 months.

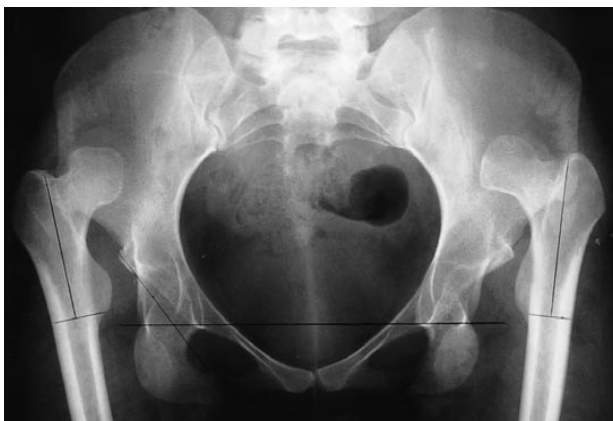Partial weight bearing was allowed immediately after surgery and full weight bearing after 2 months.

Evaluation of function

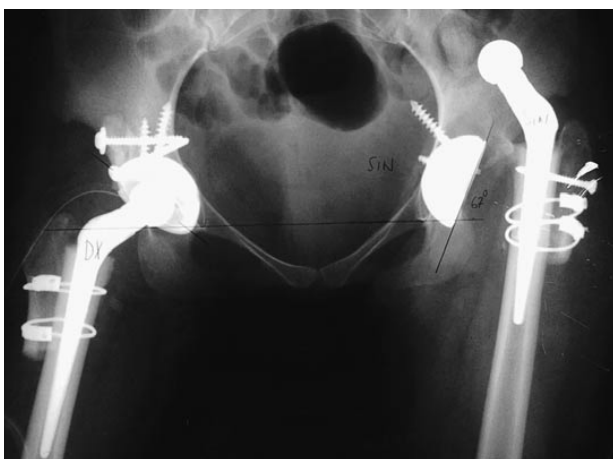The Harris hip score (HHS) (Harris 1969) was used to evaluate function before surgery and at follow-up. The patients were asked both before and after surgery about back pain, which was classified as severe, moderate and slight.

Gait was tested indoors. The walking speed was assessed for a distance of 30 meters with one turn (Lundgren-Lindquist et al. 1983, Ekdahl et al. 1989, Johansson and Jarnlo 1991, Sonn et al. 1995). If needed, the patients used their ordinary walking-aids and they were asked to walk as fast as possible. The values were compared to

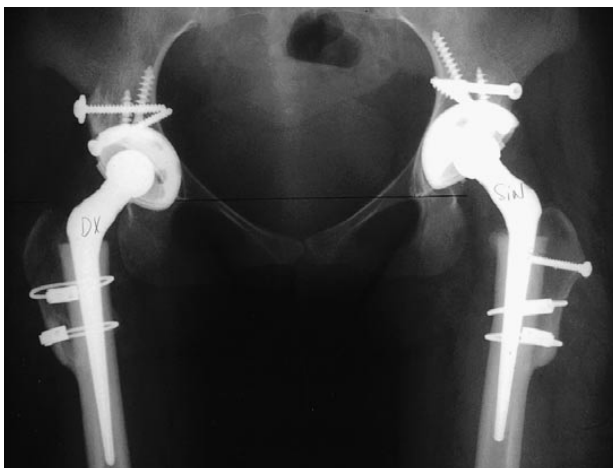
Figure 1. Cases 14 a and b. For details, see results/complications.



a. 25-year-old woman with bilateral dislocation due to CDH.

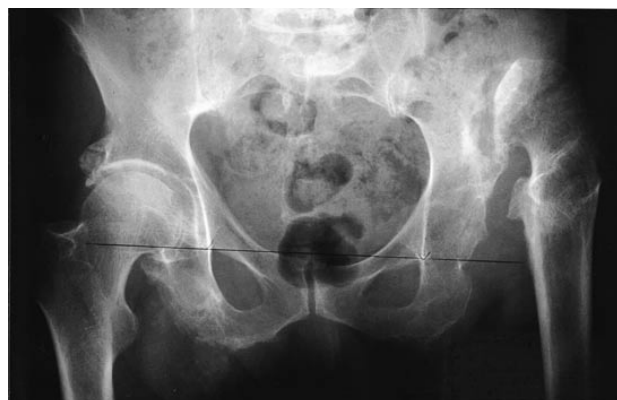

b. 4 months after surgery on her left hip and immediately after surgery on her right hip.

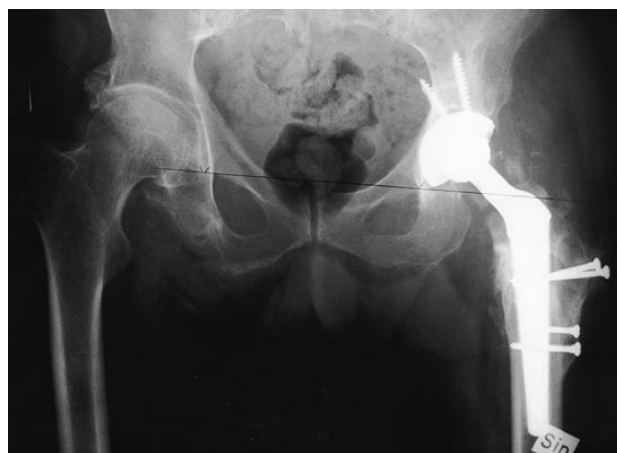

c. 12 and 8 months after index surgery on the left and right hips, respectively.

Figure 2. Case 7. A 76-year-old man with untreated traumatic dislocation of his hip, which he had sustained at the age of 21.



a. Before and



b. 34 months after surgery

age-matched data for a normal population (Ringsberg et al. 1998). The evaluation of walking speed was done only at follow-up. Case 8 was excluded because of neurological disease not related to the hip surgery. Case 2 was excluded from this part of the study because she developed arthrosis in the contralateral hip

Radiographic evaluation

We examined the whole series of radiographs for signs of loosening of either component, healing of the transposed trochanteric fragment and the augmented acetabulum.

An increase in leg length was measured as follows. First, the length of the transposed trochanteric fragment was measured and transferred to

the preoperative film. The length from this point to a reference line through the pelvis—usually the “tear drop”-line—was measured. On the postoperative film, we measured the distance from the proximal end of the osteotomized femoral diaphysis to the same reference line. The difference in length to the reference line on the pre- and postoperative films equaled the increase in leg length after correction for magnification.

Statistics

We used nonparametric tests for the statistical analysis.

Results (Table 1)

The total HHS score increased from a preoperative median value of 42 (25–68) points to a median value of 86 (60–97)

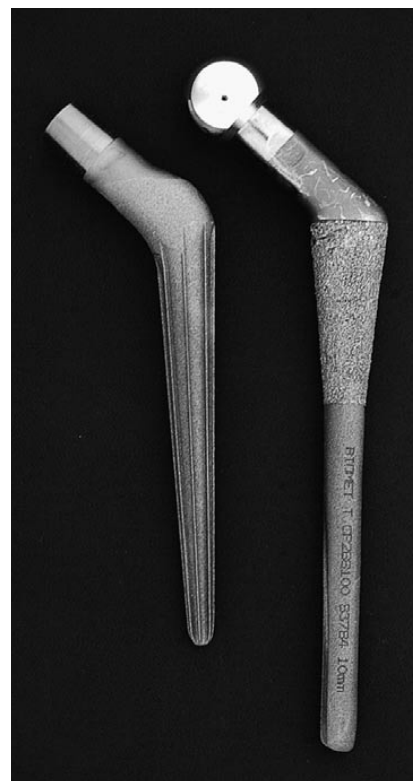


Figure 3. Stem prostheses. Dysplastic I (right) and Cone size 13 (left).

Table 2. Complications

A	B	C	D	E	F	G	H	I	J
1:1	No	23	1993	Omnifit	BOC	30	Bone resorption proximal femur	Exchange to Cone stem	Inferior socket design
1:2	"-	"-	"-	"-	"-	42	Socket wear and loosening	Socket exchange	"-
9a-sin	Yes	64	1999	Trilogy	Dysplastic II	3	Dislocation-rotated stem	Exchange to Cone stem	Dislocation detected late
9b-dx	Yes	64	1999	Trilogy	Cone	4	Central migration of the socket	Reinforcement ring and cemented socket	Technical mistake at index surgery
13a-sin	Yes	25	2000	Trilogy	Cone	1.5	Dislocation	Open reduction	Dislocation detected late
14a-sin	Yes	25	2000	Trilogy	Cone	4	Dislocation	Bone grafting and exchange of socket	Technical mistake at index surgery
A Case							F Type of primary stem		
B Bilateral hip surgery							G Interval index surgery-revision (months)		
C Age at surgery							H Cause of revision		
D Year of index surgery							I Type of revision		
E Type of primary cup							J Conclusion		

points at follow-up. The HSS pain score can reach a maximum of 44 points. Before surgery, only 2 hips had a value exceeding 20 and the median value was 10 (10–40) points. At follow-up, the median value was 44 (30–44) points.

Before surgery, the limp was severe in 20 patients and moderate in 2. After surgery, the limp became less marked in all but case no. 8 whose limp was moderate both before surgery and at follow-up. 2 cases had no limp and 9 only a slight limp after surgery.

Walking speed at follow-up ranged from 17–40 seconds, which corresponded to median 79 (33–100)% of the age-related values in a normal population.

Leg length increased in all cases. The radiographic increase in leg length, corrected for magnification, was median 2.5 (1.0–4.5) cm. Palsy or sensory disturbances were not observed in any of our cases.

All transposed trochanteric fragments healed by bony union to the femoral diaphysis and the grafts used to augment the acetabular rim healed. We found no signs of loosening of the Cone stem but 1 custom-made stem and 1 Dysplastic II stem were replaced. However, the reason why these stems had to be exchanged was related to socket wear and dislocation, respectively. The details are presented below and in Table 2.

In 10 patients back pain was an additional reason for surgery. 2 patients said that their back pain was severe before surgery, but only slight afterwards. In 7 of the 8 patients whose back pain was moderate, it had disappeared at follow-up. Case 8 could not be evaluated about this after surgery.

Complications (Table 2)

No infections were detected. 5 complications occurred in 4 patients, 3 of whom had bilateral CDH. 2 revisions were done in case no. 1, but these were due to the same cause.

Case 1, a 23-year-old woman with unilateral type C dislocation, received an uncemented Omnifit cup (Stryker Inc, New Jersey, USA) and an uncemented custom-made stem of pure titanium. After 2 years, she started to complain of pain in the groin and radiographs revealed resorption on the medial side of the proximal femur. At revision, the stem showed no signs of loosening and had to be removed by a hole-drill. Thereafter, a Cone stem was inserted. However, she continued to have pain and 1 year after the first revision, we again explored her hip and found the socket to be loose and worn. Socket wear was obviously the reason for resorption of the proximal femur seen at the first revision.

Another patient with bilateral hip dislocation—type C on one side and type D on the

other—dislocated her prostheses after operation on the left and right sides. The dislocation of the hip first operated on (case 9a) was detected after 3 months when she was admitted for an operation on the other hip. We revised the dislocated hip, which was also surrounded by a large amount of ectopic bone. The Dysplastic II stem prosthesis inserted at the index operation had rotated posteriorly and was replaced by a Cone stem. Since then, this hip has been stable. The operation on the other hip was postponed for 5 months. This hip (case 9b) also dislocated, but because of central migration of the screw-fixated Trilogy socket. Too much bone had been removed from the posterior wall of the acetabulum for an acetabular component with a larger diameter. At revision, 4 months after index surgery, we reinforced the acetabulum by a metal ring in which we cemented a Charnley socket. 10 days after revision, this hip dislocated, but after closed reduction, it has remained stable.

In a 25-year-old woman, who also had bilateral disease, the hip first operated on (case 13a) became dislocated. She continued to have pain in her thigh after surgery and, apart from the dislocation phlebography showed a massive thrombosis, which also involved the femoral vein. After open reduction 6 weeks after the index operation, her hip became stable. The operation on the second hip (case 13b), 6 months after the first one, was uneventful.

In a patient with bilateral type C hips, dislocation of the hip first operated on (case 14a) was detected on admission for surgery on the second hip about 4 months later. We operated on the second one (case 14b) as planned and 2 weeks later we replaced the socket of the first hip. The socket had been implanted without bone grafting and with too high an inclination. On revision, the acetabular rim was augmented and a new Trilogy socket inserted in a correct position (Figure 1).

Discussion

We have shown that high congenital and traumatic dislocation of the hip can be successfully treated by total hip replacement at adult age, using the technique described by Paavilainen et al. (1990, 1993). The HSS scores increased dramatically in

all cases. The limp also became less marked, and in a few cases disappeared.

The values for walking speed were usually lower than in a normal population. However, a median value of 79%, must be considered a satisfactory result in view of the underlying hip disease.

In our series, as in most others, dislocation was the commonest complication. All of them occurred in patients with bilateral CDH and were usually due to improper placement of the socket and failure to reinforce the acetabular rim at index surgery. After revision, all dislocated hips have remained stable.

Complications leading to revision or reoperation in 5 hips may seem to be a high figure. However, we consider it acceptable, in view of the circumstances. We managed them without great difficulty. This resulted in a stable hip and good or adequate function. The poor socket design used in case no. 1, which made it necessary to perform 2 revisions, has been taken off the market. It is, of course, impossible to avoid incorrect implantation or a less than optimal position of a socket. The fact that neither the patient nor the physiotherapist may understand that the patient's hip has dislocated is a main concern. Very precise oral and written information should be given to the patient and physiotherapist to ensure that the patient returns to the hospital without delay in order to permit a closed reduction of a dislocated hip.

This is the only series, except for Paavilainen's, in which the technique described above has been used. However, in most of our cases we inserted a different stem prosthesis, which we found was safe and technically easier to use (Figure 3).

In 1990, Paavilainen et al. reported 100 cases of severely dysplastic or totally dislocated hips, 21 of which were of type C or type D, that had been operated on using the same technique as in our study. In 1993, Paavilainen et al. reported a further 31 such cases. They had excellent functional results with great improvements in gait pattern and abduction strength, and only a few complications apart from a 50% loosening of the smooth-threaded acetabular component used early in their series.

Although a severe limp is common in cases with a high dislocation of the hip, it should not be the only indication for surgery. Thus, intractable pain in the hip or pain in the lower back due to severe

lumbar lordosis was always present and, in some of our patients, incipient ipsilateral knee problems was a further reason for surgery.

Today, there is a consensus that the socket should be implanted close to the original acetabulum, which means that some method must be used to shorten the femur. This is also needed to prevent overlengthening, which in turn may cause nerve injury. Eggli et al. (1999) found no correlation between the amount of lengthening and nerve damage in 508 hips operated on because of developmental dysplasia. They concluded that direct or indirect trauma is responsible in most cases. This view is supported by the findings in a study by Dunn and Hess (1976). In 22 cases with a high dislocation, the average lengthening was 5 cm and the maximal lengthening 9 cm. Sciatic nerve palsy occurred in 1 case, which had been lengthened 4 cm, but there were technical difficulties in positioning the stem. Nevertheless, most authors recommend a maximal lengthening of 4 cm (Edwards et al. 1987). In our series with radiographic lengthening ranging from 1.0–4.5 cm, we had no case with damage to nerve function.

Many patients felt that their leg length had increased more than our measurements indicated on the radiographs. This is because the patients measured their leg length while standing and, especially in type C hips, the femur telescopes in the elongated joint capsule. The radiographs, on the other hand, were taken in the supine position.

The femur may also be shortened in a stepwise fashion below the lesser trochanter. Our experience is limited, but we find this technique complicated. It has been recommended after Schantz osteotomies. However, this type of osteotomy seems to heal slowly and revision surgery for nonunion may be necessary (Paavilainen et al. 1990, Papagelopoulos et al. 1996). Femoral osteotomy has also been performed as a square subtrochanteric resection (Bruce et al. 2000) or as a double-chevron subtrochanteric osteotomy (Becker and Gustilo 1995).

For reattachment of the trochanteric fragment to the femoral diaphysis, we found that 2–3 screws may be difficult to use. The femoral diaphysis usually has a very small diameter and, when inserting a screw, there is a great risk of damaging the femoral stem. Therefore, we have now abandoned screws and use only 2–3 cables, which give a firm

grip. We have had no non-unions so far.

Mini- or micro-mini versions of cemented standard stem prostheses have been used by many authors (Dunn and Hess 1976, Harris et al. 1977, Fredin and Unander-Scarlin 1980, Woolson and Harris 1983, Hartofilakidis et al. 1998, Di Fazio et al. 2002). In our opinion, such designs have serious drawbacks. The offsets are usually too short and the stems are not straight enough. Although the dimensions of the stems have been very much reduced, the fixation will be suboptimal because there is too little space left for the bone cement. The technique described by Paavilainen et al. (1990, 1993) solves these problems.

We think that, in order to reduce the number of complications, patients with a high dislocation of a hip, due either to CDH or posttraumatic dislocation, should be referred to a few centers specializing in this field. It is also essential to determine whether a candidate for surgery is prepared to undergo this procedure and can follow the rehabilitation program.

Becker D A, Gustilo R B. Double-chevron subtrochanteric shortening derotational femoral osteotomy combined with total hip arthroplasty for the treatment of complete congenital dislocation of the hip in the adult. *J Arthroplasty* 1995; 10: 313–8.

Bruce W J M, Rizkallah S M, Kwon Y-M, Goldberg J A, Walsh W R. A new technique of subtrochanteric shortening in total hip arthroplasty—surgical technique and results of 9 cases. *J Arthroplasty* 2000; 15: 617–26.

Di Fazio F, Shon W Y, Salvati E A, Wilson Jr P J. Long-term results of total hip arthroplasty with a cemented custom-designed swan-neck femoral component for congenital dislocation or severe dysplasia. *J Bone Joint Surg (Am)* 2002; 84: 204–7.

Dunn H K, Hess W E. Total hip reconstruction in chronically dislocated hips. *J Bone Joint Surg (Am)* 1976; 58: 838–45.

Edwards B N, Tullos H S, Noble P C. Contributory factors and aetiology of sciatic nerve palsy in total hip arthroplasty. *Clin Orthop* 1987; 218: 136–41.

Eftekhari N S. Principles of total hip arthroplasty. C.V. Mosby, St. Louis 1978; 437–55.

Eggli S, Hankemayer S, Müller M E. Nerve palsy after lengthening in total replacement arthroplasty for developmental dysplasia of the hip. *J Bone Joint Surg (Br)* 1999; 81: 843–5.

Ekdahl C, Jarnlo G B, Andersson S I. Standing balance in healthy subjects. *Scand J Rehab Med* 1989; 21: 187–95.

Fredin H O, Unander-Scarlin L E. Total hip replacement in congenital dislocation of the hip. *Acta Orthop Scand* 1980; 51: 799–802.

- Harris W H. Traumatic arthritis of the hip after dislocation and acetabular fractures: Treatment by mold arthroplasty. An end-result study using a new method of result evaluation. *J Bone Joint Surg (Am)* 1969; 51: 37-55.
- Harris W H, Crothers O, Oh I. Total hip replacement and femoral-head bone-grafting for severe acetabular deficiency in adults. *J Bone Joint Surg (Am)* 1977; 59: 752-9.
- Hartofilakidis G, Stamos K, Karachalios T. Treatment of high dislocation of the hip in adults with total hip arthroplasty. *J Bone Joint Surg (Am)* 1998; 80: 510-7.
- Hess W E, Umber J S. Total hip arthroplasty in chronically dislocated hips: follow-up study on the protrusio socket technique. *J Bone Joint Surg (Am)* 1978; 60: 948-54.
- Johansson G, Jarnlo G B. Balance training in 70-year-old women. *Physiother Theor Practice* 1991; 7: 121-5.
- Lundgren-Lindquist B, Aniansson A, Rundgren Å. Functional studies in 79-year-olds. III: Walking performance and climbing capacity. *Scand J Rehab Med* 1983; 15: 125-31.
- Paavilainen T, Hoikka V, Solonen K A. Cementless total replacement for severely dysplastic or dislocated hips. *J Bone Joint Surg (Br)* 1990; 72: 205-11.
- Paavilainen T, Hoikka V, Paavolainen P. Cementless total hip arthroplasty for congenitally dislocated or dysplastic hips *Clin Orthop* 1993; 297: 71-81.
- Papagelopoulos P J, Trousdale R T, Lewallen D G. Total hip arthroplasty with femoral osteotomy for proximal femoral deformity. *Clin Orthop* 1996; 332: 151-62.
- Ringsberg K, Gärdsell P, Johnell O, Jönsson B, Obrant K, Sernbo I. Balance and gait performance in an urban and rural population. *JAGS* 1998; 46: 65-70.
- Sonn U, Frändin K, Grimby G. Instrumental activities of daily living related to impairments and functional limitations in 70-year-olds and changes between 70 and 76 years of age. *Scand J Rehab Med* 1995; 27: 119-28.
- Woolson S T, Harris W H. Complex total hip replacement for dysplastic or hypoplastic hips using miniature or microminiature components. *J Bone Joint Surg (Am)* 1983; 65:1099-107.