



LUND UNIVERSITY

Stroboscopy - a pertinent laryngological examination

Kitzing, Peter

Published in:
Journal of Otolaryngology

1985

[Link to publication](#)

Citation for published version (APA):

Kitzing, P. (1985). Stroboscopy - a pertinent laryngological examination. *Journal of Otolaryngology*, 14(3), 151-157.

Total number of authors:

1

General rights

Unless other specific re-use rights are stated the following general rights apply:

Copyright and moral rights for the publications made accessible in the public portal are retained by the authors and/or other copyright owners and it is a condition of accessing publications that users recognise and abide by the legal requirements associated with these rights.

- Users may download and print one copy of any publication from the public portal for the purpose of private study or research.
- You may not further distribute the material or use it for any profit-making activity or commercial gain
- You may freely distribute the URL identifying the publication in the public portal

Read more about Creative commons licenses: <https://creativecommons.org/licenses/>

Take down policy

If you believe that this document breaches copyright please contact us providing details, and we will remove access to the work immediately and investigate your claim.

LUND UNIVERSITY

PO Box 117
221 00 Lund
+46 46-222 00 00

Stroboscopy — a pertinent laryngological examination

P. KITZING, M.D.

Malmö, Sweden

Abstract. When observing the vocal fold movements in their laryngoscopic examination, most laryngologists seem to be trained to consider only the gross respiratory movements of the folds, *i.e.* abduction and adduction. These movements constitute an essential part of the vitally important valve function of the larynx, preventing aspiration and providing parts of the mechanisms for normal swallowing, coughing, and straining. The second important function of the larynx is to serve as a transducer of aerodynamic to acoustic energy; the voice function. Probably for reasons of tradition, the examination of the voice function is generally left to the speech pathologists, who can make an auditory perceptual evaluation of the voice qualities, possibly supplemented by electro-acoustic analyses.

By focussing also on the small vibratory movements of the vocal folds during phonation, using laryngeal stroboscopy, the laryngologist can contribute considerably to the diagnosis of voice disorders. For the laryngeal surgeon stroboscopy should be of particular interest, as it is a useful tool for early detection of (cancerous) invasion and for the evaluation of laryngeal paresis. This paper describes the clinical procedure of laryngeal stroboscopy, based on some introductory remarks on vocal anatomy and function.

Recently, *The Journal of Otolaryngology* dedicated a special issue to voice function and the management of vocal disorders¹. It was comprehensive and most informative, but fell short of familiarizing the reader with the methodology for examination of the larynx by laryngeal stroboscopy, which in other parts of the world, such as Germany and Japan, holds a central position in the clinical evaluation of voice disorders. The lack of awareness of the benefits of laryngeal stroboscopy was commented upon by the Japanese laryngologist Hirano² in a discussion recently: "We find it difficult to understand why the stroboscope is not very popular in the United States"; he was answered by an American colleague: "I am not sure I get information with it on dys-

phonias that I can't get with the flexible fiberscope".

Since the author is rooted in the tradition of phoniatrics, in which laryngeal stroboscopy has occupied a central part of the investigation of voice disorders for decades, this paper will try to point out what additional information besides fiberscope findings can be expected from laryngeal stroboscopy, and how the method can be carried out. It will be shown that laryngeal stroboscopy is of interest not only to the voice physician or phoniatrician, but to the laryngeal surgeon as well; and also that the early detection of neoplasm or the outcome of laryngeal paresis might benefit from the use of a stroboscope. Moreover, there is no controversy between the use of the flexible fiberscope and the stroboscope, as the two methods can be combined. However, a necessary prerequisite for the understanding of stroboscopic findings is the knowledge of some anatomic and physiologic principles of laryngeal function. These will be summarized before proceeding to describe the method of laryngeal stroboscopy.

LARYNGEAL VIBRATORY PATTERN EXPLAINED BY STRUCTURE OF THE VOCAL FOLDS

Early scholars thought of the voice generator as a flute or a whistle and that the sound originated from eddies in the air current³. In 1741 Ferrein³ showed by animal experiments that the vocal folds are essential for voice production. However, he thought that the vibrating folds produced the sound directly, much in the same way as a pair of strings on a violin. This concept is reflected in the older terminology of vocal "chords" and a conceptual model of the voice generator as a pair of narrow bands moving only to and fro in the transverse (medio-lateral) direction.

A more detailed review of the physiological theories of vocal sound production may be found in van den Berg's work of 1958⁴. He especially stresses the fact that the vocal folds are thin and pointed only under the special condition of head register, when the cricothyroid muscle exerts marked tension on the vocal ligament. In the chest register, which is the voice quality used in ordinary speech, the margins of the folds have a more blunt and rounded configuration and the folds can make contact over a vertical depth of several millimeters (Figure 1).

Since the famous Bell high speed film on vibratory movements of the human vocal folds⁵, it has been well recognized among voice physiologists, that because of the thickness of their margins the folds vibrate not only in the transverse but also in the vertical direction and that there is a phase difference between the lower and upper border of the margins.

From the Department of Phoniatrics, General Hospital, Malmö, Sweden.

Address reprint requests to Dr. P. Kitzing, Department of Phoniatrics, General Hospital, S-214 01, Sweden.

Received August 1, 1984, accepted January 7, 1985.

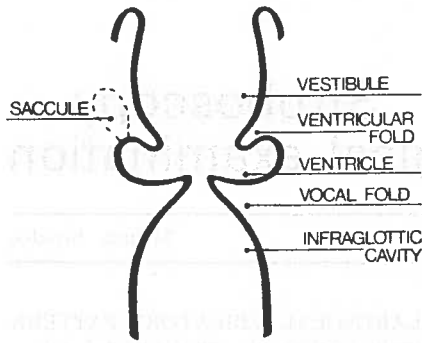


Fig. 1a. Schematic presentation of the vocal folds according to the traditional view: thin and pointed margins²⁰.

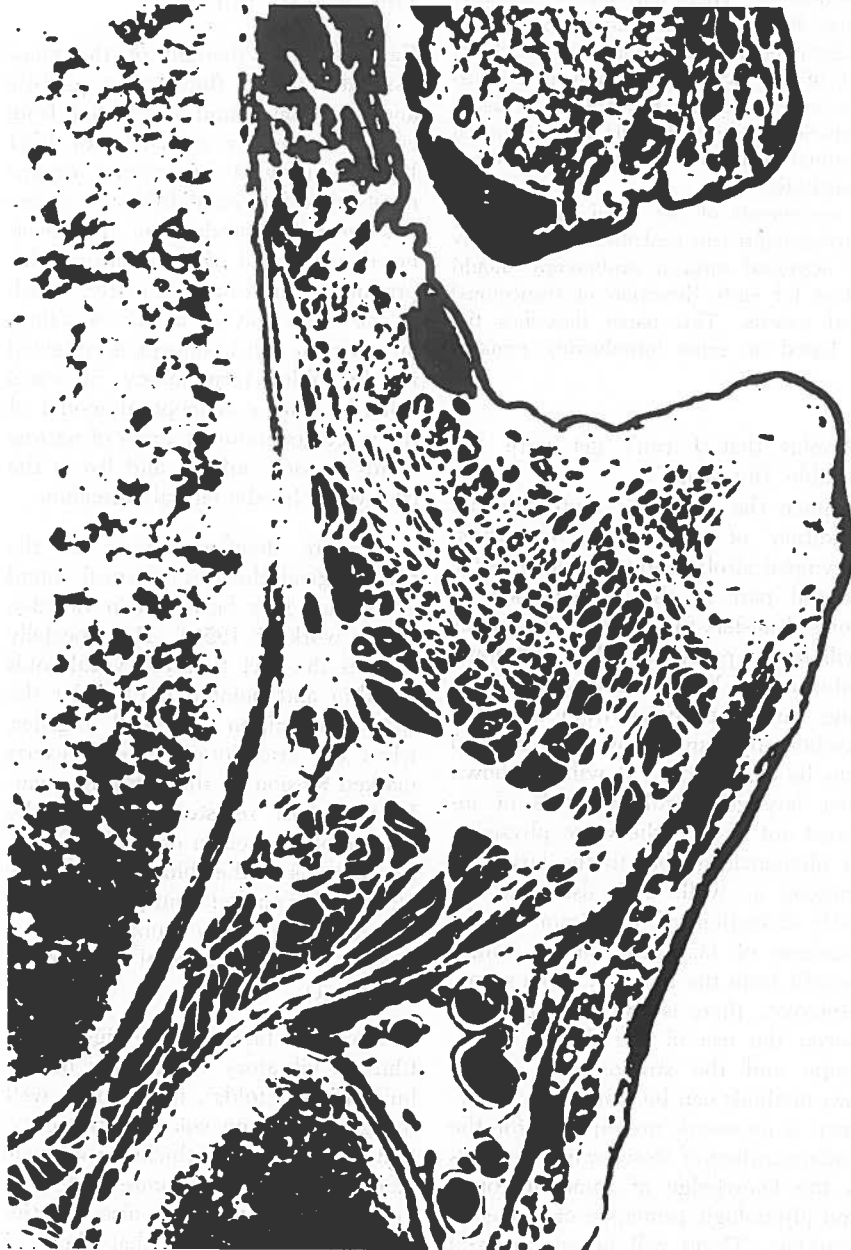

Fig. 1b. Transversal section through vocal fold from adult. The vertical extension of the vocal fold margin can clearly be seen.

Or, to cite the description issued with the film: "At the lowest pitches . . . vibration takes place throughout a considerable depth, from above and downwards toward the trachea. Assuming the closed position of the cycle the opening appears to begin from underneath, toward the trachea, progressing upward and outward. In other words, there exists a phase difference between different vertical positions" (*cit. from 4*).

Several theories have been put forward to explain the vertical phase difference between the upper and lower borders of the vocal fold margins. Van den Berg⁴ thought it to be due to a combination of the laxness of the vocal ligament in chest register, an internal shift between the fibers of the vocal muscle and the looseness of the upper surface of the vocal folds. Stevens⁶ proposed a two-mass mechanical model (Figure 2a) and more complex models have been elaborated by Titze⁷ on the basis of computer simulations. The thinking of laryngologists interested in voice function in Northern Europe has been highly influenced by the "membrane-cushion" (*i.e.* mucosa-muscle) theory put forward by Svend Smith. Based on careful observations of the Bell high-speed film and his own classical stroboscopic film⁸ as well as on experiments with rubber models of the larynx⁹, he inferred that the phase shift was due to the free mobility of the vocal fold mucous membrane on the fibrous ligament attached to the stiffer underlying muscle. Van den Berg⁴ criticized this theory, as he felt the anatomical basis for Smith's rubber models to be insufficient and that they overestimated the role of the mucous membrane.

However, in a series of thorough investigations on the layer structure of the vocal folds, Hirano and his group at the Kurume University seem to have substantiated Smith's theory. Analogous to the "membrane-cushion" model Hirano proposed the notion of a "body-cover" complex (Figure 2b) making up the structure of the vocal fold^{10,11}.

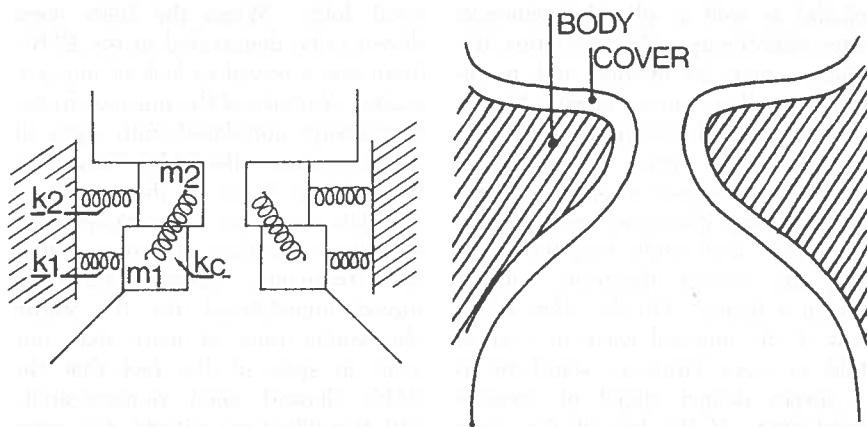


Fig. 2. Conceptions of vocal fold mechanics. a) Two-mass mechanical model according to Stevens⁶. b) Layered structure, permitting displacement of the soft submucous "cover" on the stiffer muscular "body" of the vocal fold, according to Hirano¹⁰.

CLINICAL IMPLICATIONS OF THE VOCAL FOLD LAYER STRUCTURE

The phase difference between the lower and the upper edges of the vocal fold margins is explained by the layer structure in the following way (Figure 3). With the vocal folds in the phonatory (adducted) position and starting from the moment of opening in the glottal vibratory cycle, the subglottic air current through the glottis acts on the lower parts of the margins by aerodynamic sucking forces due to the Bernoulli effect. Parts of the loose mucosa, the "cover", will be forced medially until they make contact with the opposite vocal fold and close the glottal chink. The air current is interrupted momentarily, but at the same time there is a subglottic pressure building up against the closed glottis, forcing the vocal folds apart when the pressure has become strong enough to overcome the muscular and elastic forces in the folds. This means that the upper parts of the loose marginal cover can still accomplish the final part of their vibration by moving laterally, while the lower parts already are sucked medially to start the next vibratory cycle. On high speed films and in laryngeal stroboscopy, this can be seen as a vertical travelling wave in the loose superficial layer. In German, this movement has been named "marginal edge displacement" (Randkantenverschiebung) and in Scandina-

vian countries it is called glottic wave (Swedish: glottisvåg). Often the term glottal wave is used to designate one cycle of the entire vibratory movement of the glottis. Therefore, in accordance with Hirano¹² it is suggested that *mucosal* (travelling) *wave* be used in English.

So, simply speaking, there are in principle two vibratory movements of the vocal folds: the transverse movements of the muscular "body" and the vertical travelling wave movements of the mucosal "cover". In practice this means that the displacements of the vocal fold mucosa can be visualized by laryngeal stroboscopy in much the same way as the skin and the underlying soft tissues of

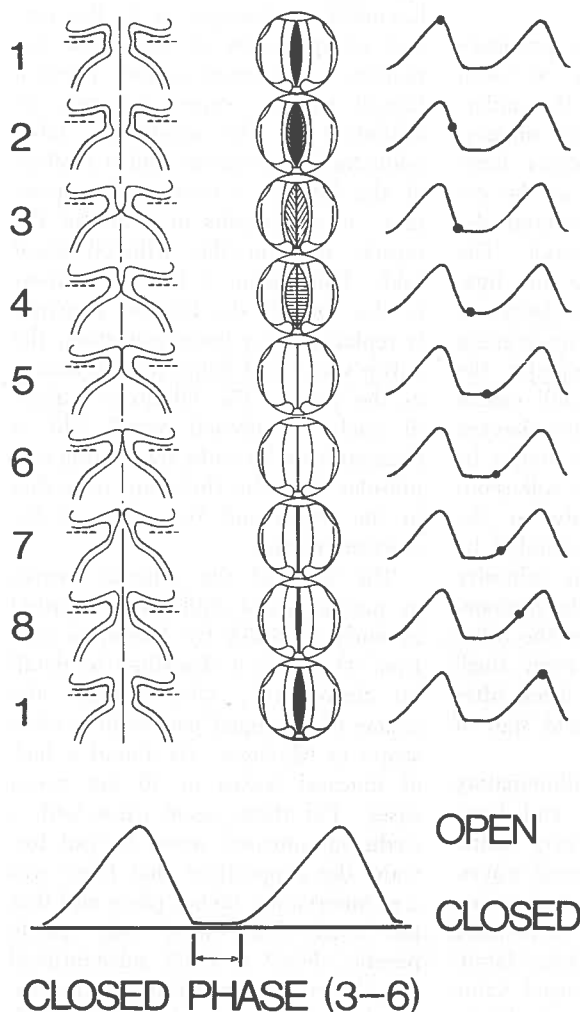


Fig. 3. Schematic presentation of the vocal fold vibratory pattern during phonation in normal chest register. Left column: frontal section¹¹. Middle column: view from above as perceived in the laryngeal mirror¹³. Right column: area function of the glottis.

the body can be felt moving freely over the deeper bony and muscular tissues. This has at least three clinical implications:

1. Phonatory function

The size of the mucosal waves and the vibratory amplitudes are closely correlated. They increase with falling pitch and rising intensity. Diminished mucosal waves (and amplitudes) in a low-pitched (chest) register voice of rather loud intensity usually are a sign of inappropriate tension in the laryngeal muscles during phonation. This finding substantiates the diagnosis of (hyper-) functional dysphonia and should return to normal after successful voice therapy, provided, of course, that the patient is able to use his new and healthier voice during the examination.

2. Adhesions and invasive processes

The most common cause of vocal fold mucosal adhesions to the underlying "body" is extensive surgery, when the deeper submucous loose tissue has been included in the extirpation of polyps or polypoid degeneration (Reinke's edema). The epithelialization directly of the ligamentous or even muscular layers of the vocal folds without intervening soft submucous tissue impedes the normal vibratory pattern and causes severe hoarseness. No mucosal wave can be detected and there might be a complete vibratory arrest. Adhesions of the epithelium directly to the "body" should be strictly avoided by laryngologists as much as adhesive processes of the drum to the promontory are by otologists. On the other hand the recurrence of even small mucosal waves within a week after vocal fold surgery is a good sign of uncomplicated recovery.

Circumscribed deep inflammatory lesions (like tuberculosis) and keratotic or fibrous tissue may cause localized arrest of the mucosal waves. However, the most important cause of absent mucosal waves is invasive vocal fold cancer. Therefore, laryngeal stroboscopy is of special value for following cases of chronic laryngitis and laryngeal keratosis (leuko-

plakia) as well as glottal carcinomas after radiotherapy. In such cases, the mucosa may be opaque and macerated, so that cancer cannot be excluded without taking a specimen, usually at the price of voice impairment. However a normal mucosal wave during phonation excludes invasiveness and might help to ascertain the correct diagnosis without taking a biopsy. On the other hand, loss of the mucosal wave in a vocal fold or even vibratory stand-still is a severe danger signal of invasive carcinoma. If the loss of the wave is limited to a special area of the fold, then the laryngeal surgeon has an excellent indication of where to take a biopsy.

3. Laryngeal paresis

The least well-known function of laryngeal stroboscopy is in the correct interpretation of vocal fold immobility. Laryngeal paresis, being a flaccid paresis, causes not only an inhibition of the respiratory (ab-/adductory) movements and a fixation of the fold in a near median position. It also results in a loss of the muscle tone in the afflicted vocal fold. This means a loss of stiffness in the "body"; the layered structure is replaced by a homogenization, the entire vocal fold being just as flaccid as the cover. The vibratory pattern of such a softened vocal fold is characterized by wide, undulating amplitudes (like the fluttering of a flag in the wind) and by a *loss of the mucosal waves*.

The lack of the mucosal waves in parietic vocal folds was reported as early as 1953 by Heymann (*cit. from 4*) and it is described in detail by Schönhärl¹³, who studied the course of laryngeal paresis by stroboscopy in 62 cases. He found a lack of mucosal waves in all but seven cases. For these seven cases with a (reduced) mucosal wave, he put forward the supposition that there was a re-innervation taking place and that the vocal folds were only partly parietic. Fex¹⁴ in 1973, substantiated this theory by correlating electromyography of the vocal muscle with laryngeal stroboscopy in 24 parietic

vocal folds. When the folds were shown to be denervated in the EMG, there was a complete lack of mucosal waves. A return of the mucosal waves was always correlated with signs of re-innervation in the EMG. This could be the first stage in the course of complete remission, *i.e.* regained ab-/adductory mobility in some cases. Most frequently, however, the folds stayed immobilized for the entire observation time of more than one year, in spite of the fact that the EMG showed good re-innervation, and the vibratory pattern was completely normalized with excellent mucosal waves. At the same time, the patients noted total remission of their previous parietic dysphonia.

Based on his re-innervation studies, Fex^{15,16} stated that re-innervation could take place by misdirected nerve fibers not conveying the correct signals to regain normal gross mobility, but re-establishing the tonus of the vocal muscle and thereby the layered "cover-body" structure of the vocal fold. This condition being fulfilled, the quality of the voice returned completely to normal. By the same token, voice function may be entirely normal when the vocal folds are immobilized because of ankylosis of the crico-arytenoid joint. In such cases, the vibratory pattern is normal with perfect mucosal waves.

In summary, watching the mucosal waves by means of laryngeal stroboscopy may be recommended for the differential diagnosis of vocal fold paresis *vs.* crico-arytenoid joint ankylosis, and for monitoring the course of laryngeal paresis. Re-innervation can be shown by EMG as well as by stroboscopy, but this is more complicated and invasive. Scientific reports on the outcome of laryngeal paresis can hardly be accepted as complete without an examination of the state of denervation or re-innervation. Even if the immobility might be complete in both states, re-innervation makes a significant difference in the function of the voice.

THE STROBOSCOPIC METHOD

The vibratory movements of the vocal folds during phonation are too fast

to be observed directly by the human eye, appearing only as a blur. Some kind of slow motion device is needed for detailed observation of the vibrations. One convenient method of getting a slow motion effect is by using the stroboscopic phenomenon. Most people are acquainted with this phenomenon from watching rotating spokes on wagon wheels and airplane propellers in the movies or TV, or from controlling the speed of their record player turntables with the aid of a stroboscopic disc in the light from a bulb connected to alternating current. If a regularly vibrating object is illuminated by short light flashes of the same frequency as the vibrations, the object will appear immobile in the very phase of the vibrations which is illuminated. If the vibratory period of the flashes is somewhat longer than the vibrations of the object, each period of the object's vibrations will be illuminated in a somewhat later phase than the previous period. Because of the positive after-images on our retina (duration 0.2 seconds according to Talbot's law), the visual impressions from the succeeding phases will merge and appear as a slow motion. The frequency of the observed motion is determined by the difference between the vibratory frequency of the object and that of the flashes. An appropriate frequency difference for laryngeal stroboscopy is about 1.5 Hz. It should be noted, that the pattern of

the slow, observed vibrations is identical to the vibratory pattern of the object (Figure 4).

The stroboscopic principle has been known since about 1830 and the first to apply it for laryngeal examinations was Oertel in 1878 (for details of the history see Schönhärl¹³). In the earliest constructions of stroboscopes for examination of the larynx, continuous light was interrupted by shining it through holes in a disc which rotated in front of the lamp (Greek: *στροβοσ* = whirl, rotation). Modern devices generally use flashes from a bulb, the frequency of which is electronically controlled by the fundamental pitch of the voice from the examined subject.

LARYNGEAL STROBOSCOPY

As in ordinary indirect laryngoscopy, the intermittent light from the stroboscope can be reflected onto the laryngeal mirror with the aid of a head mirror. High demands are made on the visual acuity of the examiner to observe fine details of the vibrations in this way. It is also possible to use a laryngeal endoscope or the flexible fiberoptic for stroboscopy¹⁷. The most rewarding method, however, uses a stroboscopic light in the ordinary operating microscope (focal distance of objective lens: 30 or 40 cm; magnification 6 x) when watching the image in the laryngeal mirror¹⁸. In this way it is possible not only to get very good magnifica-

tion but, more importantly, one also obtains a superb optic resolution. The most crucial quality of this "indirect microlaryngostroboscopy" compared to the aforementioned methods, however, is the fact that it permits the use of both eyes. Stereoscopic sight is a prerequisite for optimal evaluation of the mucosal wave, as the wave travels in a direction parallel to the optic axis of the observer's gaze. To obtain documentation of the stroboscopic findings, laryngeal endoscopes, flexible fiberscopes, and the operating microscope can be fitted with movie or video cameras. The resulting films can be analyzed frame by frame and the variations of the glottal area during phonation can be measured — stroboglottometry¹⁹.

STROBOSCOPIC CRITERIA

Due to the principle of stroboscopy, one observed period is in fact an average of many periods in the physical environment. The correct evaluation of the findings is very much a question of experience and the examination should always be carried out not only with open eyes but also with open ears. During initial training the observer should give himself the opportunity to examine several normal subjects at differing pitch, intensity, and quality of voice. As the vibratory pattern of the vocal folds is highly correlated with the kind of voice emitted, the stroboscopic examination sheet should always contain some remarks as to the acoustic voice signal in addition to the visual stroboscopic findings.

It is suggested that one note the following factors:

Acoustic

Pitch (psycho-acoustic) or voice fundamental frequency (as read out on the display of the stroboscope) — The higher the pitch, the smaller the vibrating mass and the higher the stiffness of the vocal folds, which both mean smaller vibrations.

Register — A correct evaluation of the mucosal waves can be done only in chest register and not in head register.

Intensity — Both the magnitude of

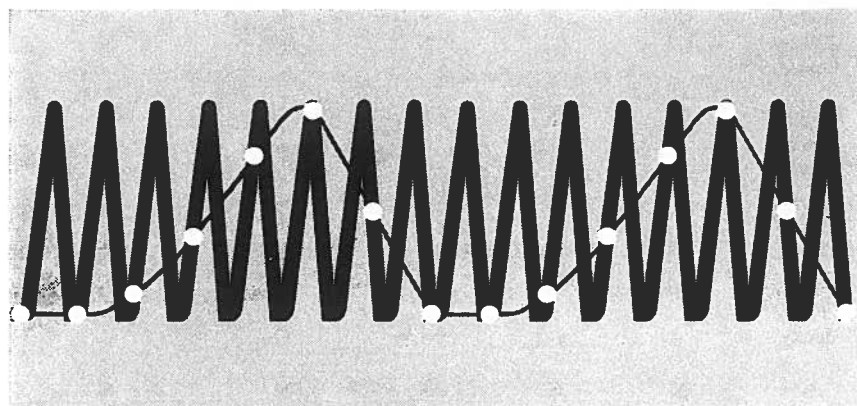


Fig. 4. The slow motion effect of stroboscopy. If a rapidly vibrating object is illuminated by flashes of a somewhat lower frequency than the vibrations it appears to move slowly. The configuration of the vibratory pattern is the same in the perceived slow vibrations as in the original ones.

the vibratory excursions of the folds and the part of the vibratory cycle when the glottis is closed depend very much on the intensity of the voice.

Visual

Symmetry — The normal vocal folds show symmetrical vibratory patterns. Asymmetric vibrations are a sign of differing mechanical properties of the folds. In exceptional cases there might be a 180° phase difference between the two sides; these alternating vibrations need not be pathological.

Periodicity — Aperiodic vibrations give rise to noise components in the voice, *i.e.* hoarseness. They may be caused by imbalance between the aerodynamic forces in the glottis and the mechanical properties of the vocal folds. In the stroboscopic examination they are perceived as a blurring.

Amplitudes — Large amplitudes are a sign of low tonus in the vocal muscle. The amplitudes increase with the intensity of the voice. They can best be seen when the voice quality is soft and low pitched. They may be exaggerated in vocal fold paresis (undulating amplitudes). In hyperfunctional dysphonia when the voice quality is strained, the amplitudes are diminished.

Mucosal waves — The size of the mucosal waves is generally related to the size of the amplitudes. Therefore, this laryngologically most important feature of the stroboscopic examination can best be studied at a low pitched, soft voice quality. There are no mucosal waves in denervated vocal folds, nor when the displacements of the superficial mucosal layer on the muscular core of the folds are arrested by adhesions or invasion. In these latter cases even the amplitudes may be missing, yielding complete vibratory arrest. This is a serious sign, pathognomonic of cancerous lesions.

Vibratory closure — Insufficient closure of the glottis during the vibrations causes the voice quality to be leaky or breathy. The sufficiency of the vibratory glottal closures can be properly estimated only under stroboscopic light because the appearance of the glottis is too blurred in continuous light.

STROBOSCOPIC DIAGNOSIS OF VOICE DISORDERS AND LARYNGEAL DISEASE

Among normal subjects the vibratory pattern of the vocal folds varies con-

siderably and depends decisively on the quality of the emitted voice. Nevertheless, there are a number of stroboscopic findings typical for several voice disorders or certain types of laryngeal disease. They are summarized in Table 1.

PRACTICAL HINTS AND CAVEATS

The stroboscopic phenomenon depends entirely on the inertia of the observer's eye. The perceived slow motions represent just an average of many periods. The method should not be confused with high speed cinematography, when there is a temporal resolution of every single vibratory cycle by many photographs. One necessary condition to get the stroboscopic effect is that the vibrations be (quasi) periodic during the time of observation. In very hoarse voices the vibrations may be too irregular (aperiodic) to get a clear stroboscopic appearance. Obviously, stroboscopy is of no use in aphonic patients.

Since it takes at least several seconds to make an appropriate evaluation of the stroboscopic findings, it is not sufficient to watch the larynx for just a moment as is often done in ordinary indirect laryn-

Table 1. *Typical Stroboscopic Findings in Certain Voice Disorders and Diseases of the Larynx*
(Normal voice intensity and breast register quality during the examination are assumed)

Type of disorder	Auditory				Visual		
	Pitch	Quality	Symmetry	Periodicity	Amplitudes	Mucosal waves	Vibratory closure
1. Hyperfunctional dysphonia	(+)	strained	N	N	-	-	+
2. Laryngitis	(-)	slightly hoarse	(-)	(-)	N	(-)	N
3. Edemas of the vocal fold margins, "soft nodules"	-	"rough"	N	N	N	+	+
4. Polyps, cysts	(-)	often hoarse	-	(-)	-	-	(-)
5. Fibrous, "hard" nodules	(-)	hoarse, leaky	N	N	-	-	(-)
6. Superficial keratosis	(-)	hoarse	(-)	(-)	-	-	N
7. Glottal carcinoma	(-)	hoarse (leaky)	-	-	O	O	(N)
8. Vocal fold paresis	(+)	leaky	-	(-)	+	O	-
9. Re-innervated paresis, ankylosis of TA-joint	N	N	N	N	N	N	N
10. Puberphonia (head register)	+	"thin"	N	N	-	(O)	(-)
11. Ventricular dysphonia	-	rough	Vocal folds cannot be examined. Distinct vibrations in the ventricular folds.				

gосcopy. The examiner must take his time and he must patiently guide the subject to cooperate adequately. Even with correct examination technique when using the laryngeal mirror, a surface anesthesia of the throat is necessary more often than in ordinary examinations of the larynx, when some gagging can be accepted.

The examiner must be able to guide the subject to phonate continuously and at a low pitched, relaxed voice quality. Sometimes it is necessary to have the subject raise his voice pitch to be able to visualize the vocal folds behind the epiglottis. Or the subject might not be able to produce other than a very strained voice quality during the examination. Any such aberrations of the voice quality from the relaxed conversational voice of the subject should be noted in the examination sheet, as the stroboscopic findings will not agree with the vibratory pattern of ordinary phonation.

For some examiners it may take

some time to adopt the correct examination technique as well as the habit of concentrating on the auditory and visual findings at the same time. Moreover, it takes some experience to master the correct clinical evaluation of the stroboscopic findings. However, notwithstanding these obstacles, the interested laryngologist, regularly adopting stroboscopy in his examination routines, will soon find

that this method opens up new and rewarding aspects of the function of the larynx and establishes a physiological basis for a deepened understanding of vocal disturbances.

ACKNOWLEDGMENT

The author is grateful to Derek E. Dunn, Ph.D., Experimental Department, Malmö General Hospital, for revising the English text.

Résumé. Lorqu'ils examinent le larynx, la majorité des spécialistes semblent n'avoir appris qu'à regarder les mouvements d'abduction et d'adduction. Certes, ces mouvements sont essentiels pour empêcher l'aspiration trachéale, pour une déglutition, une toux et une fonction sphinctérienne normales. Ceci fait partie de la fonction valvulaire, vitalemment indispensable, du larynx. Une autre fonction importante du larynx est la transformation d'une force aérodynamique en une énergie acoustique, la voix. Sans doute pour sacrifier à la tradition l'examen de la voix est en général laissé entre les mains des orthophonistes, qui peuvent faire une évaluation subjective des qualités vocales, avec parfois des analyses électroacoustiques.

En observant, à l'aide d'un stroboscope, les petits mouvements des cordes lors de la phonation, le laryngologiste peut apporter beaucoup au diagnostic des troubles vocaux. Pour le chirurgien du larynx, la stroboscopie est particulièrement intéressante en détectant les premiers stades de l'invasion cancéreuse et en précisant les caractéristiques d'une paralysie laryngée. Cet article décrit comment faire une analyse stroboscopique du larynx, en se basant sur quelques données fondamentales de la voix.

REFERENCES

1. Special Issue on Voice. *J Otolaryngol* 12: October, 1983.
2. Hirano M: In Proceedings of Conference on the Assessment of Vocal Pathology. *ASHA Report* 11, December 1981, p. 69.
3. Galen, about 200 A.D., Dodart O, 1700, Ferrein A, 1741, cited from van den Berg, 1958.
4. van den Berg JW: Myoelastic - aerodynamic theory of voice production. *J Speech Hear Res* 1: 227-244, 1958.
5. Farnsworth DW: High speed motion pictures of human vocal cords. *Bell Telephone Laboratories*, 1940.
6. Stevens KN: Physics of laryngeal behavior and larynx modes. *Phonetica* 34: 264-279, 1977.
7. Titze I: Biomechanics and distributed mass models of vocal fold vibration, pp. 245-270 in Stevens KN, Hirano M (Eds): *Vocal Fold Physiology*. University of Tokyo Press, 1981.
8. Smith S: Remarks on the physiology of the vibrations of the vocal cords. *Folia Phoniat* 6: 166-178, 1954.
9. Smith S: Chest register versus head register in the membrane cushion model of the vocal cords. *Folia Phoniat* 9: 32-36, 1957.
10. Hirano M: Morphological structure of the vocal cord as a vibrator and its variations. *Folia Phoniat* 26: 89-94, 1974.
11. Hirano M, Kakita Y, Ohmani K, Kurita S: Structure and mechanical properties of the vocal fold, pp. 271-297 in Lass NJ (Ed.): *Speech and Language. Advances in Basic Research and Practice*. Academic Press, New York, 1982.
12. Hirano M: *Clinical Examination of Voice*. Springer-Verlag, Wien, New York, 1981.
13. Schönhärl E: *Die Stroboskopie in der praktischen Laryngologie*. Georg Thieme Verlag, Stuttgart, 1960.
14. Fex S, Elmqvist D: Endemic re-current laryngeal nerve paresis. *Acta Otolaryngol* 75: 368-369, 1973.
15. Fex S: Judging the movements of vocal cords in larynx paralysis. *Acta Otolaryngol* 263: 82-83, 1970.
16. Fex S: Experimentall reinnervation av skelettmuskel och dess tillämpning vid larynxpareser. *Doctoral dissertation*, Lund, 1970 (In Swedish).
17. Gould WJ, Kojima H, Lambiase A: A technique for stroboscopic examination of the vocal folds using fiberoptics. *Arch Otolaryngol* 105: 285, 1979.
18. McKelvic GP, North C: Laryngeal strobomicroscope. *Lancet* 2: 503-504, 1970.
19. Wendler J, Otto C, Nawka Th: Stroboglottometrie - ein neues Verfahren zur Schwingungsanalyse der Stimmlippen. *HNO-Praxis* 8: 263-268, 1983.
20. Grant JCB: *A Method of Anatomy*. Williams and Wilkins Co., Baltimore, 1958, p. 783.